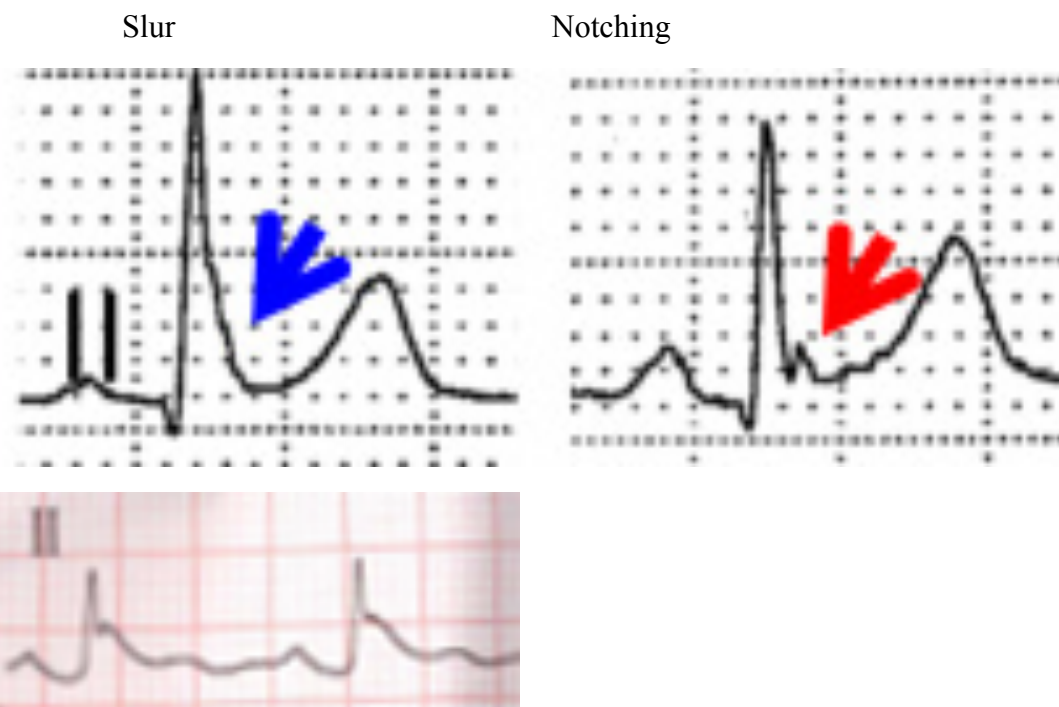


## The J wave and J wave syndrome, early repolarization syndrome, and early repolarization pattern current definitions

**J wave and others denominations** J deflection, "the camel's hump"/ camel-hump sign (Abbot 1976), "late  $\delta$  wave" (Yan 1996), elevated J-point, J point wave, hat hook junction, hypothermic wave, K wave, H wave, injury current (Osborn 1955) or Osborn wave. This point represents  $\approx$  the end of ventricular depolarization and the beginning of repolarization. There is an overlap of 10ms, corresponding to 25% of one small square of the 12-lead ECG (Mirvis 1982; Hurst 1998; Bjerregaard 1999.). Today the J wave is defined as either slur or notching at the QRS terminal  $\geq 0.1$  mV(1mm) above the isoelectric line and a duration of at least 10 ms **with** or **without** ST segment (ST-S) elevation at the end of the QRS (Perez 2012a) in at least in two contiguous leads. The ST-S shape may be concave upward, horizontal, or descending. Horizontal and descending ST segments are associated with a worse prognosis.

**Current definitions** The J wave is a positive deflection with a dome or hump shape on the downslope of the R wave notching or slurring which occurs at the end of the QRS and at the beginning of the ST segment (in the J point) (Lepeschkin 1952).



Dr Frank Torres's case

The term early repolarization pattern (ERP) unfortunately, erroneously has been used to denote the combination of "J waves" and "ST-segment elevation" (ST-SE) in apparently healthy individuals. The current concept of ERP following 2013 expert consensus document (Priori 2013) determine that the ERP can be diagnosed in the presence of J-point elevation  $\geq 1$  mm in  $\geq 2$  contiguous inferior and/or lateral leads of a standard 12-lead ECG. ERP is more prevalent in African Americans, young athletes men and it is

not predictive of cardiovascular death in this population and may represent a distinct electrophysiologic phenomenon.

The term early repolarization syndrome (ERS) is diagnosed in the presence of J-point elevation  $\geq 1$  mm in  $\geq 2$  contiguous inferior and/or lateral leads of a standard 12-lead ECG in a patient resuscitated from otherwise unexplained VF/polymorphic VT. Additionally, ERS can be diagnosed in an SCD victim with a negative autopsy and medical chart review with a previous ECG demonstrating J-point elevation  $\geq 1$  mm in  $\geq 2$  contiguous inferior and/or lateral leads of a standard 12-lead ECG

In conclusion, the J waves and ST-SE should be analyzed independently

### **J-wave syndromes**

J-wave syndromes are thus termed a seemingly dissimilar set of clinic-electrocardiographic entities, such as channelopathies Brugada syndrome (BrS), early repolarization syndrome (ERS) (**Gussak 2000**) idiopathic ventricular fibrillation (IVF), short QT syndrome, hypothermia mediated, ischemic heart disease/ischemia/reperfusion-induced VF, head injuries, severe hypocalcaemia and others miscellaneous that clinically share the tendency for outbreaks of ventricular tachyarrhythmia events that may lead to syncope or sudden cardiac and the presence of J-wave on the surface 12 leads electrocardiogram. These entities represent a continuous spectrum of phenotypic expression that Gan-Xin Yan (**Yan 2004**) proposes be termed J wave syndromes in Chinese journal.

### **J-wave syndrome classification proposal**

- A) Hypothermic mediated
- B) Normothermic conditions
  - I) Channelopathies
    - Early repolarization syndrome (ERS)
    - Brugada syndrome(BrS)
    - ERS + BrS in association
    - Idiopathic ventricular fibrillation with and without ERPattern
    - Short QT syndrome with and without ER
  - II) Acquired forms of J-Wave syndrome
    - Ischemia-mediated “J waves” induced by ischemia. : Acute myocardial infarction, Variant angina or Prinzmetal angina, ischemic heart disease
    - Neurogenic: head injuries, brain injury, subarachnoid hemorrhage, cardiopulmonary arrest from over sedation,
    - Severe hypocalcaemia
    - Miscellaneas

### **Channelopathies associated with J-wave syndrome**

Early repolarization syndrome (ERS) and Early repolarization pattern (ERP): “Putting the points on the ies”

ER is a common ECG pattern characterized by J-point and ST-segment elevation in two or more contiguous leads. The presence of an ER pattern(ERP) in the precordial leads has been considered a benign phenomenon, but recently its presence in the inferior and/or lateral leads has been associated with IVF in case-control studies (ERS). The ER ECG pattern (.1 mm) in the inferior/lateral leads occurs in 1%–13% of the general population and in 15%– 70% of the IVF cases. In the pediatric age group, it is even more prevalent. Male sex is strongly associated with the ER ECG pattern, since more than 70% of the subjects with ER are men. The ERP is more common in young physically active individuals, athletes, and African-Americans. There is an increased prevalence of ER reported in Southeast Asians.

**Clinical diagnosis** Patients with the ERP on the 12-lead ECG who have been resuscitated from an ECG-documented episode of IVF and/or polymorphic VT are those diagnosed with ERS. Similarly, SCD victims with a negative autopsy with an archived ECG showing the ERP are also diagnosed with ERS when evidence of other diagnoses have been excluded. At this stage of our understanding of ER, there is an unusual dilemma in which the ECG pattern is highly prevalent, the inheritance is not clearly monogenic in most cases, and the genetic substrate is not clearly defined. For this reason, Priori et al have chosen not to label family members with the ERP as ERS patients, pending a better understanding of their risk. High-risk features including extent of family history of SCD, arrhythmic syncope, and amplitude and morphology of the ERP may lead to consideration of a prophylactic ICD in conjunction with review by an expert center with a focus on inherited arrhythmias. Asymptomatic individuals with the ERP on ECG with a mutation considered pathogenic for ER as well as family members of a patient diagnosed with ERS who present with a diagnostic ECG may be affected by the disease.

**Genetic variants** Familial ER has been reported to have an autosomal dominant inheritance pattern with incomplete penetrance. Two independent population-based studies have also suggested some degree of inheritance of the ERP in the general population, but the familial inheritance of malignant ERP has not been clearly demonstrated.

### **Clinical manifestations**

Life-threatening arrhythmias are often the first and unexpected manifestation of ERS. The majority of population-based studies have shown that subjects with ER in the inferior leads are at a higher risk of all-cause mortality, cardiac mortality, and especially unexpected sudden death

### **Clues of the concept**

- I. ERS is diagnosed in the presence of J-point elevation  $\geq 1$  mm in  $\geq 2$  contiguous inferior and/or lateral leads of a standard 12-lead ECG in a patient resuscitated from otherwise unexplained VF/polymorphic VT.

- II. ERS can be diagnosed in a SCD victim with a negative autopsy and medical chart review, with a previous ECG demonstrating J-point elevation  $\geq 1$  mm in  $\geq 2$  contiguous inferior and/or lateral leads of a standard 12-lead ECG.
- III. ER pattern (ERP) can be diagnosed in the presence of J-point elevation  $\geq 1$  mm in  $\geq 2$  contiguous inferior and/or lateral leads of a standard 12-lead ECG.

### **Expert Consensus Recommendations on ER Therapeutic Interventions (Priori 2013)**

Class I: ICD implantation is recommended in patients with a diagnosis of ERS who have survived a cardiac arrest.

Class IIa: Isoproterenol infusion can be useful in suppressing electrical storms in patients with a diagnosis of ERS. Quinidine in addition to an ICD can be useful for secondary prevention of VF in patients with a diagnosis of ERS.

Class IIb: ICD implantation may be considered in symptomatic family members of ERS patients with a history of syncope in the presence of ST-SE  $\geq 1$  mm in two or more inferior or lateral leads.

ICD implantation may be considered in asymptomatic individuals who demonstrate a high-risk ER ECG pattern (high J-wave amplitude, horizontal/descending ST-segment) in the presence of a strong family history of juvenile unexplained SCD with or without a pathogenic mutation

Class III: ICD implantation is not recommended in asymptomatic

(ERS) and Brugada syndrome (BrS) are associated with an increased risk to PVT/VF, and SCD in subjects without apparent structural heart disease. The clinical impact of ERS was not fully appreciated until 2008. (Haissaguerre 2008). Consensus reports have been published aimed at proposing diagnostic criteria and treatment options for both syndromes.

### **Brugada syndrome**

BrS is a clinical-electrocardiographic entity characterized by J-point and ST-SE on right precordial leads and increased risk of PVT/VF syncope and SCD. In BrS, epicardial depolarization abnormality with delayed potential on the right ventricular outflow tract (RVOT) is reportedly the predominant mechanism underlying VF. Yet VF occurrence is also associated with early repolarization pattern (ERP) in the inferolateral ECG leads, which may represent the inferior and/or left lateral ventricular myocardium. The ERP has been linked to an increased risk for arrhythmic death in various clinical settings. There are limited and conflicting data regarding the prognostic significance of ERP in BrS. Recent meta-analysis (Georgopoulos 2017) suggests that the ERP is associated with a high risk of arrhythmic events in patients with BrS. In particular, BrS patients with inferolateral ERP (global ERP) displayed the highest arrhythmic risk. Nagase et al (Nagase 20017) recorded prominent J waves in unipolar electrogram and potentials after QRS complex in bipolar electrogram at the LV epicardium in BrS patients with global ERP. The prominent J waves coincided with the

potentials after QRS complex and the inferolateral ERP on ECG. The characteristics of the inferolateral ERP on ECG in these patients represent depolarization mechanism.

### **Similarities and difference between BrS and ERS**

BrS and ERS display several clinical similarities, suggesting similar pathophysiology. (**Priori 20013; Antzelevitch 2016**) males predominate in both syndromes and the highest incidence of VF or SCD occurs in the third or fourth decade of life. In both syndromes, the appearance of accentuated J waves and ST segment elevation are generally associated with bradycardia or pauses, and VF events have been proposed to occur mostly during sleep or at a low level of physical activities. ERS and BrS also share similarities with respect to the response to pharmacological therapy, e.g. quinidine.

### **Differences between the ERS and BrS have also been described, such as:**

- 1) The region of the heart most affected (right ventricular outflow tract in BrS vs. left ventricular inferior region in ERS);
- 2) The presence of (discrete) structural abnormalities in BrS and not perhaps in ERS;
- 3) Higher incidence of late potentials in signal-averaged ECGs in BrS vs. ERS,
- 4) Greater elevation of J-wave elevation in response to sodium channel blockers in BrS vs. ERS, and
- 5) Higher prevalence of atrial fibrillation in BrS vs. ERS.

The study by Kamakura et al. (**Kamakura 2016**) in this issue describes some other differences between these syndromes and challenges some previously accepted concepts. The role of vagal tone during sleep as a trigger of VF was not observed in patients with ERS in this Japanese study, which is contrast to some previous observations. On the contrary to previous studies, the investigators report here a low incidence of recurrent VF events among patients with J-pattern only in the inferior or lateral region of the left ventricle (ERS patients). Like prior studies, the investigators show that patients who have a widespread distribution of J-waves, i.e. combination of ECG patterns of BrS and ERS, have the highest risk of recurrent VF events. (**Priori 2013**) Short-coupled premature ventricular contractions, the so called short-long-short sequence, have commonly been considered to initiate VF both in BrS and ERS patients. In the present study, such phenomenon was mainly observed in patients with ECG pattern of ERS but not so often in those who had BrS ECG pattern. Thus, the present study provides some insight into the possible different pathophysiological background between these syndromes. Initiation of VF by short-long-short sequence has commonly described in patients with idiopathic VF and has been proposed to originate from Purkinje network, (**Haissaguerre 2002**) while premature contractions causing VF in BrS with long coupling intervals originate mostly from RVOT. The different pattern of initiation of VF between these syndromes does not provide insight into the question, whether either of these syndromes is due to depolarization of repolarization abnormality, respectively. The difference in the pattern of initiation of VF may only be related to a different anatomical region of the onset of VF. It should be noted that the observations presented here by Kamakura et al. are still based on relative low numbers

of Japanese patients and low number of VF events, especially among the ERS patients. Therefore, the results may not be applicable to all J-wave syndrome patients worldwide. Similar to the epidemiological differences between BrS and ERS, the former being more common in southern and eastern Asia, there may be some mechanistic geographical differences between the two syndromes, perhaps due to geographic variations of genetic background of the J-wave syndromes despite similarities in the ECG phenotypes. The present study by Kamakura et al. does not provide much clinical information for risk stratification of subjects with ECG patterns of either BrS or ERS. Perhaps, it may highlight the importance of long-term ECG recordings, especially in subjects with ECG ERP. If short-long short sequences and/or early coupled PVCs are observed in long-term ECG recording, these findings may indicate closer follow-up or even therapeutic interventions of these patients.

### **Idiopathic ventricular fibrillation**

Some cases of IVF that are linked to J wave in inferior leads were considered as different ECG or disease entities. Increasing basic and clinical evidences supports the initial proposal that it is appropriate to group these syndromes and entities under the heading of J wave syndromes because of their similarity in ECG characteristics, clinical outcomes, risk factors, an amplification of  $I_{to}$ -mediated J waves

**Acquired forms of J-Wave syndrome: We will address this issue at another opportunity**

### References

1. Antzelevitch A, Yan GX, Ackerman MJ, et al. J-wave syndromes expert consensus conference report: Emerging concepts and gaps in knowledge. *Heart Rhythm*, 2016 Oct;13(10):e295-324. Flores-González JC, Grujic B, Lechuga-Sancho AM. Thyroid hormone intoxication as a not yet described cause of J-wave syndrome in a pediatric patient. *Endocrine*. 2017 Jan 25. doi: 10.1007/s12020-017-1228-2.
2. Georgopoulos S, Letsas KP, et al. A meta-analysis on the prognostic significance of inferolateral early repolarization pattern in Brugada syndrome. *Europace*. 2017 Jan 13. pii: euw394. doi: 10.1093/europace/euw394. [Epub ahead of print]
3. Gussak I, Antzelevitch C. Early repolarization syndrome: clinical characteristics and possible cellular and ionic mechanisms. *J Electrocardiol*. 2000;33:299–309.
4. Haissaguerre M, Shoda M, Jais P, et al. Mapping and ablation of idiopathic ventricular fibrillation. *Circulation* 2002;106:962-7
5. Haissaguerre M, Shoda M, Jais P, et al. Mapping and ablation of idiopathic ventricular fibrillation. *Circulation* 2002;106:962-7
6. Haissaguerre M, Derval N, Sacher F, et al. Sudden cardiac arrest associated with early repolarization. *N Engl J Med* 2008;358:2016-23
7. Huikuri HV. Differences in characteristics between J-wave syndrome patients. *Heart Rhythm*. 2016 Dec 23. pii: S1547-5271(16)31323-6.

8. Kamakura T, Wada M, Ishibashi K, Inoue YY, Miyamoto K, Okamura H, Nagase S, Noda T, Aiba T, Yasuda S, Shimizu W, Kamakura S, Kusano K. Differences in the onset mode of ventricular tachyarrhythmia between patients with J wave in anterior leads and those with J wave in inferolateral leads. *Heart Rhythm*. 2016 Nov 23. 5271(16)31074-8.
9. Nagase S1, Tanaka M2, Morita H3, Nakagawa K2, Wada T2, Murakami M2, Nishii N3, Nakamura K2, Ito H2, Ohe T4, Kusano KF1. Local Left Ventricular Epicardial J Waves and Late Potentials in Brugada Syndrome Patients with Inferolateral Early Repolarization Pattern. *Front Physiol*. 2017 Jan 26;8:14. doi: 10.3389/fphys.2017.00014. eCollection 2017
10. Ortega Carnicer J. Acute inferior myocardial infarction masking the J wave syndrome. Based on four observations. *Med Intensiva*. 2008 Jan-Feb;32(1):48-53. Vlachos K, Giannopoulos G, Efremidis M, et al. A meta-analysis on the prognostic significance of inferolateral early repolarization pattern in Brugada syndrome. *Europace*. 2017 Jan 13. pii: euw394. doi: 10.1093/europace/euw394. [Epub ahead of print]
11. Priori SG, Wilde AA, Horie M, et al. Executive Summary: HRS/EHRA/APHRs Expert Consensus Statement on the Diagnosis and Management of Patients with Inherited Primary Arrhythmia Syndromes. *Heart Rhythm* 2013;15:1389-1406.
12. Yan GX, Yao QH, Wang DQ, Cui CC. Electrocardiographic J wave and J wave syndromes. *Chin J Cardiac Arrhythm*. 2004;8:360-5.