

**Hombre de 45 años con cuadro de disnea súbita e hipotensión
transitorias asociado a ECG con elevación del segmento ST (V_1 - V_2)
y onda de “Osborn like”(V_3 - V_4)**

**Man 45 year with sudden and transitory dyspnea and hypotension associated
with ST segment elevation (V_2 - V_3) and Osborn's like-Wave”(V_3 - V_4)**

Caso clínico del Dr. Marcelo Abud Argentina

Clinical case report Marcelo Abud M.D. from Argentina

Dear Andres,

We have a male, 45-year-old patient, admitted yesterday due to symptoms of dyspnea of sudden onset not related to effort. He does not mention precordial pain. He presented four weeks ago, an ankle fracture, related to a motorbike accident, with no chest trauma.

At admittance he was tachypneic with BP 80/50. Physical examination, including cardiac auscultation, was normal except for the verification of longilinear frame and mild pectus excavatum. Before the event he was completely asymptomatic and he does not mention personal or familial pathological history worthy of mention. He does not present coronary risk factors. He never practiced competitive sports, and he just walks 30 minutes per day.

After observing ECG1 (in right precordial leads it was absolutely normal), coronary angiography and emergency pulmonary arteriography was carried out, which shows normal coronary arteries, absence of pulmonary thromboembolism and PPA 30/17.

Anticoagulation treatment is started, and after two hours his BP is normalized (120/70) and he is eupneic with ECG2. Lab tests, including troponins, D-dimer, electrolytes and acid-base were all normal. Chest X-ray is normal.

Cardiac echo Doppler is normal. LV systolic function 65% without segmentary hypokinesia and normal RV. He evolved without symptoms and today ECG3 was made, including high precordial leads. We would like to know your interpretation of the ECGs and whether you may suggest a diagnosis.

Do you think it is proper to make a coronary angiography in this clinical scenario?

As usual thank you very much, regards, and we remain waiting for your reply or that from our colleagues.

Dr. Marcelo Abud M.D. Argentina

Spanish

Estimado Andrés:

Paciente masculino de 45 años que ingresa ayer por una cuadro de disnea súbita taquipneico no relacionada a esfuerzo e hipotenso (TA 80/50mm de Hg).. Y sin dolor precordial.

Habito longuilíneo con discreto pectus excavatum Auscultación cardiaca normal.

Hace cuatro semanas tuvo una fractura de tobillo, relacionada con un accidente de moto, sin traumatismo torácico. Previamente al evento se encontraba totalmente asintomático y no refiere antecedentes patológicos personales o familiares destacables.

No presenta factores de riesgo coronario. No realizó nunca deportes competitivos pero camina 30 minutos por día.

Por el ECG de admisión ECG 1 se le indica cinecoronangiografía y arteriografía pulmonar de urgencia que muestra arterias coronarias normales, ausencia de TEP y presión de arteria pulmonar de 30/17.

Se comienza con tratamiento anticoagulante y a las dos horas normaliza su TA (120/70)y se encuentra eupneico con un ECG2 El laboratorio incluyendo troponinas,dimero D, electrolitos y acido base fueron normales.La RX de tórax es normal.

El ecocardiograma dopler cardiaco es normal. FSVI 65% sin hipoquinesias segmentarias y VD normal.

Evoluciona asintomático y hoy se realiza un ECG 3 que incluye las derivaciones precordiales altas.

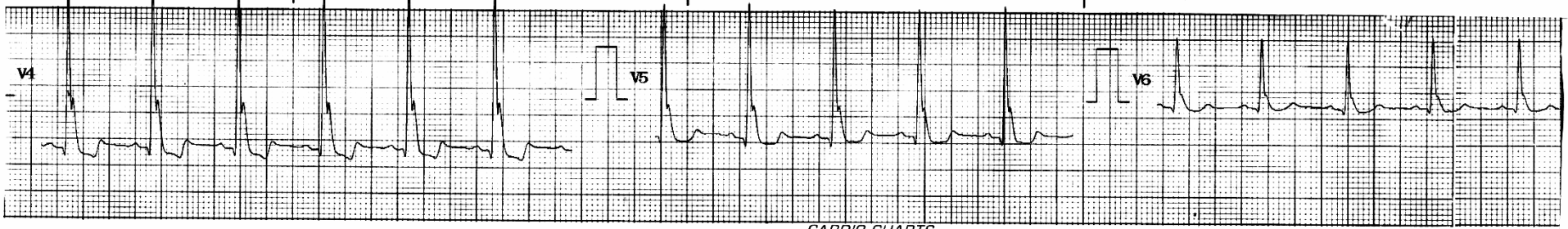
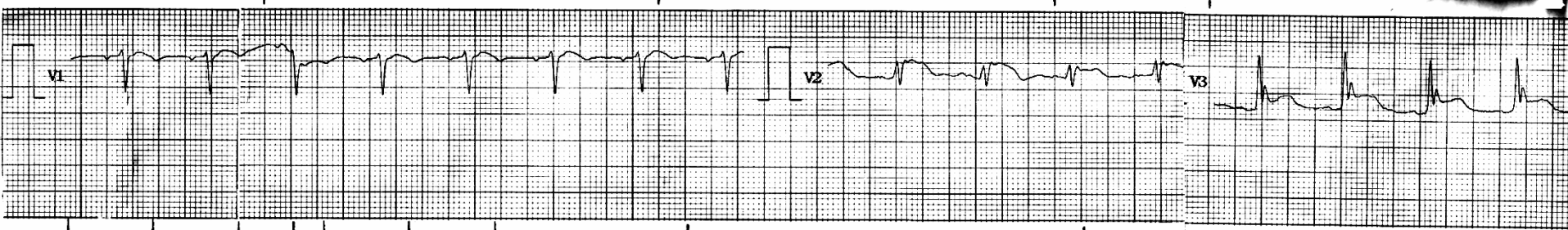
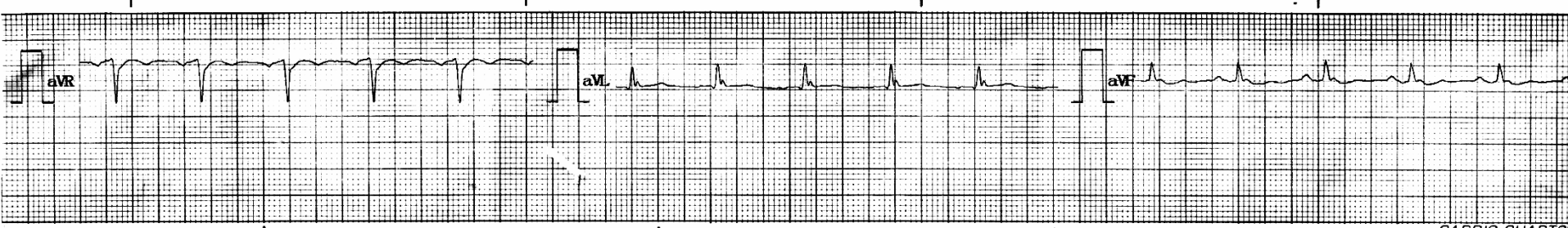
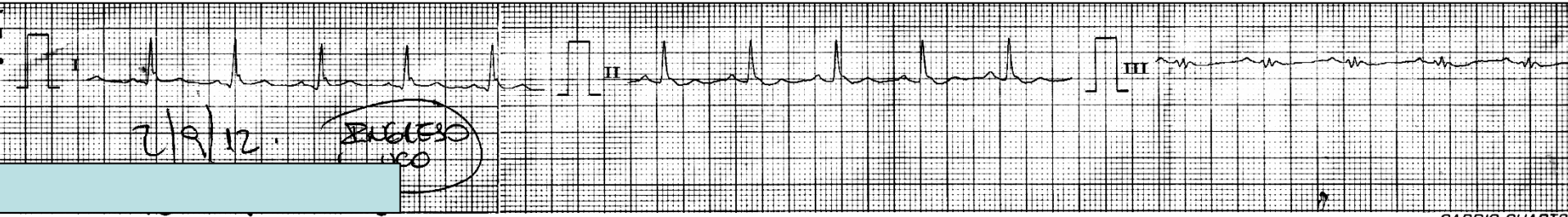
Nos gustaria conocer su interpretacion de los ECG y si sugiere algun diagnostico.

Le parece correcto la realización de una cinecoronariografía en este contexto clinico?

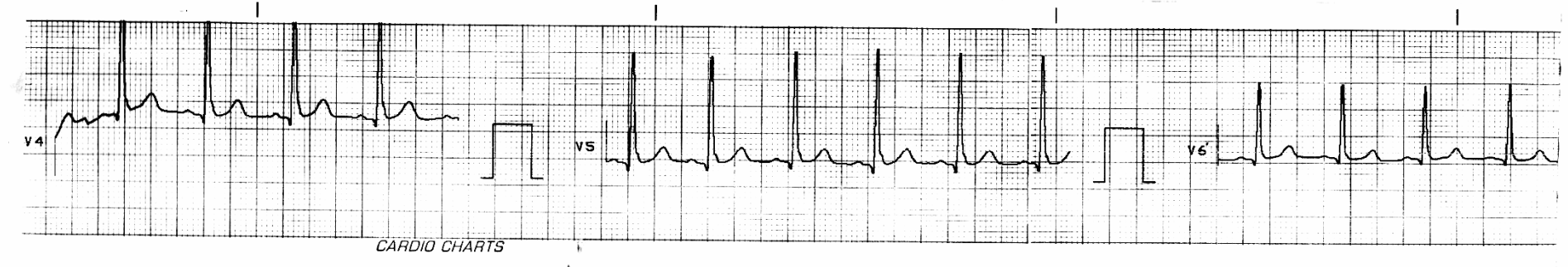
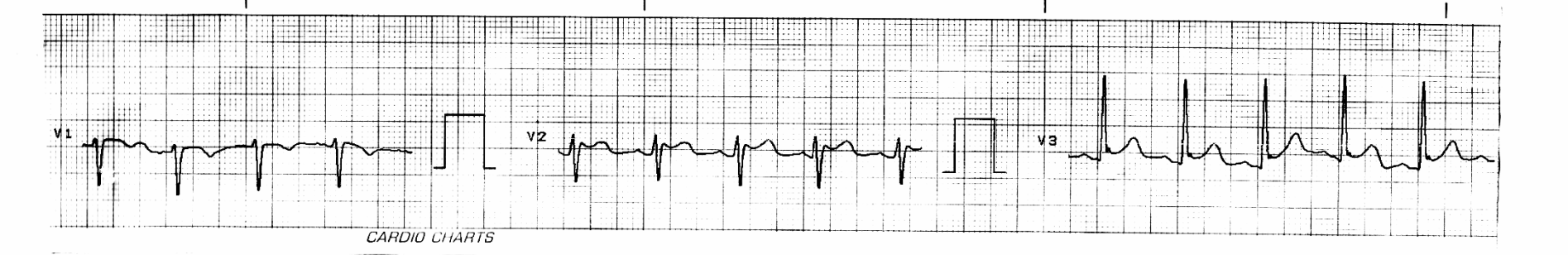
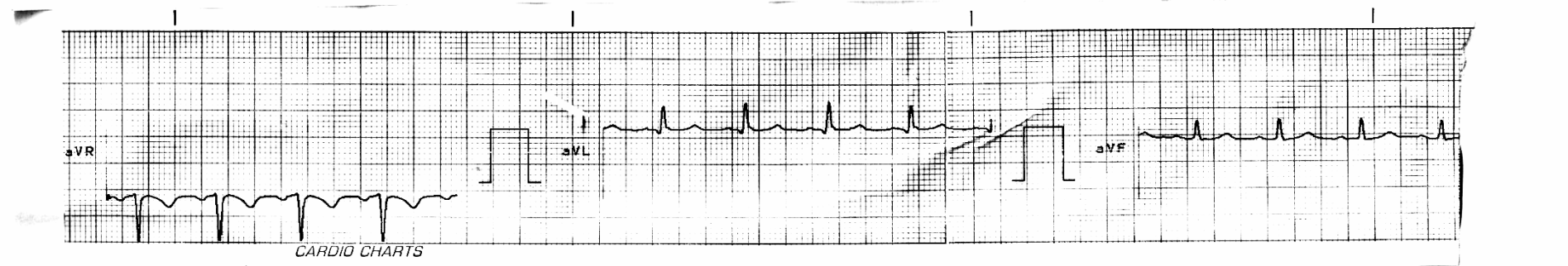
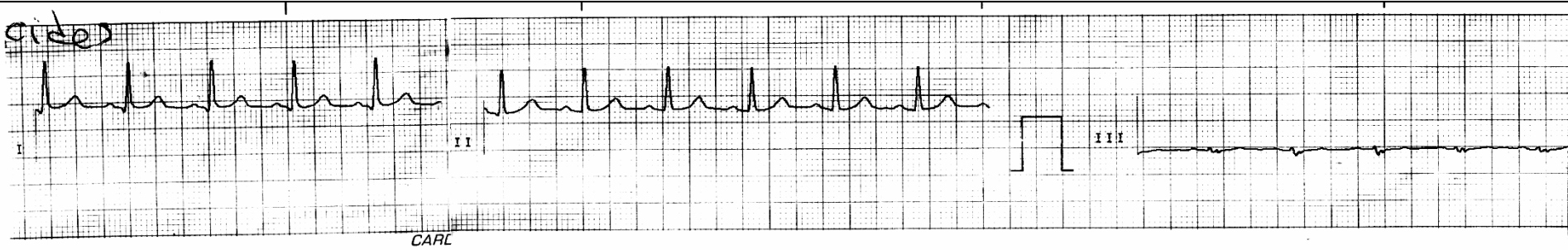
Como siempre muchas gracias, un gran abrazo y esperamos su respuesta o la de nuestros colegas.

Dr. Marcelo Abud

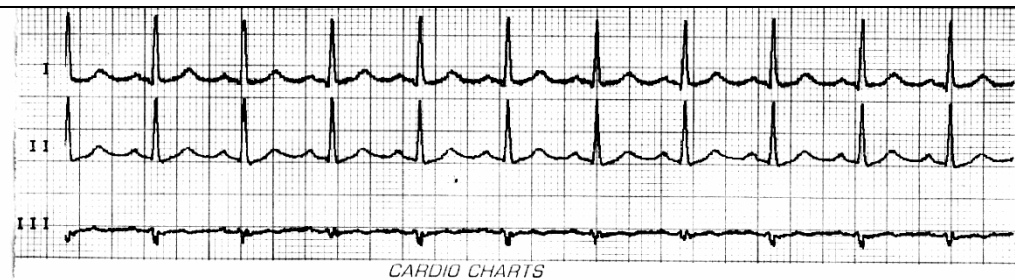
ECG 1



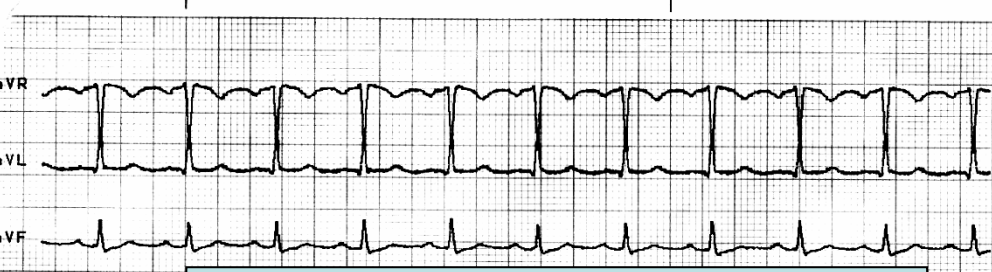ECG 2



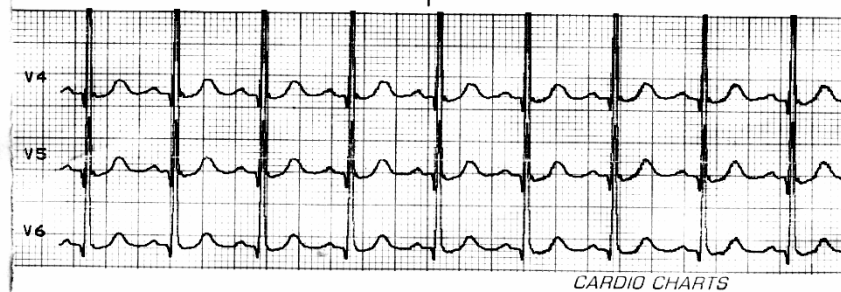
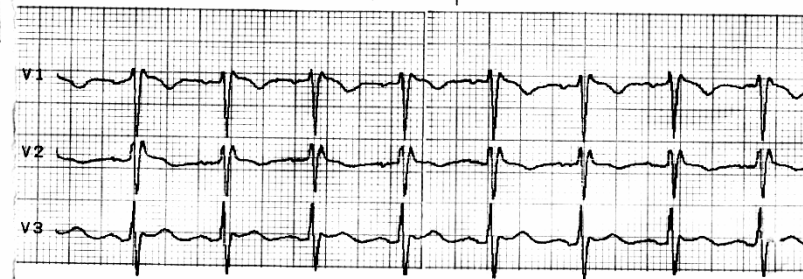
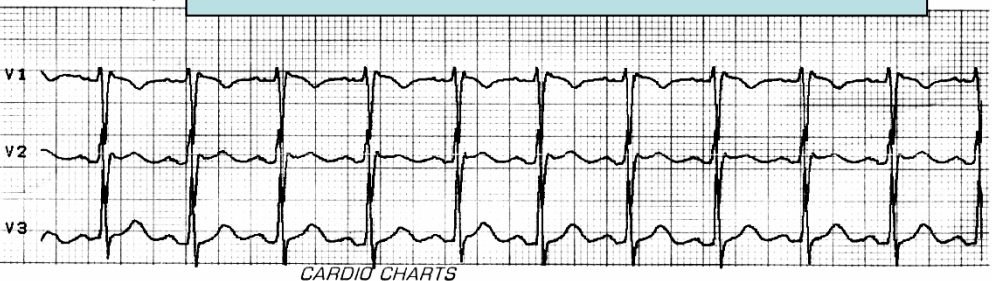
ECG 3



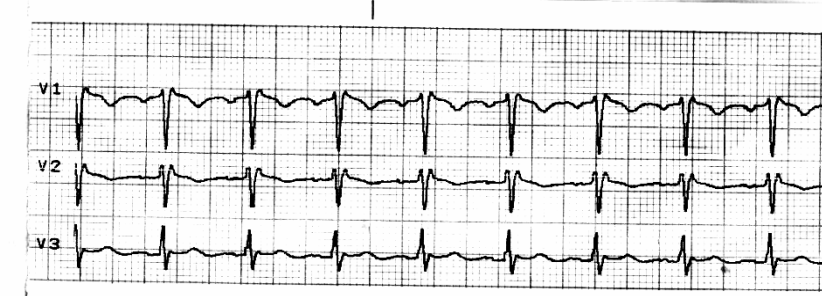
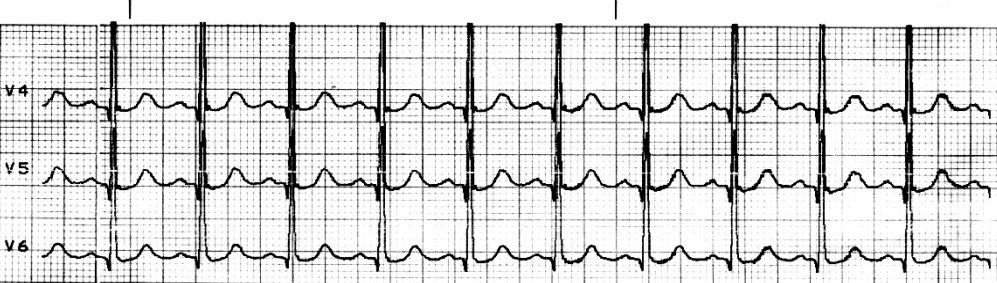
Over the 3rd intercostal space,



Over the 4th intercostal space.



Over the 2nd intercostal space.



Colleagues opinions

Estimado Dr Marcelo Abud: La elevación del segmento ST en un varón puede corresponder como en este caso a una repolarización precóz (high take off).

¿Porque no se trata de una isquemia aguda? Respuesta: Porque no se observan signos recíprocos o imagen en espejo (remodelación fisiológica)

¿Porque no se trata de una embolia pulmonar aguda? Respuesta: Porque no tiene eje eléctrico del QRS desviado a la derecha.

¿Porque no es pericarditis aguda? Respuesta: porque las derivaciones no están afectadas difusamente, el intervalo PR es isoeléctrico, no tiene precordialgia, fiebre y no está taquicárdico (en la pericarditis aguda la FC está casi siempre es alrededor de 120lpm.)

Entonces ¿que tiene el paciente? Respuesta: Efecto andrógénico sobre el corazón. Los andrógenos aumentan la fuerza contráctil selectivamente en el miocito del epicárdico incrementando el tenor de calcio del sarcómero, (ocasionando elevación del segmento ST) y concomitantemente produciendo mayor salida del potasio durante la fase 3 por estímulo del canal de salida lento de potasio “slow delayed potassium receptors” responsable por el aspecto puntiagudo de la onda T.

Esta hipercontractibilidad epicárdica observada en el sexo masculino aumenta el requerimiento del flujo coronario. Este ECG muestra que la pared anterolateral baja (de V4 a V6) y la anterolateral alta (aVL I) son hipercontráctiles especulo que la arteria circunfeja sea pequeña con predominancia de la arteria coronaria derecha. Esta circulación coronaria insuficiente puede ocasionar disnea o dolor precordial

Como se corrige esto? Respuesta: con beta bloqueadores adrenérgicos

No quiero criticar a los estudios invasivos que se le hicieron, pero pienso que en este caso con 20 pesos se hubiera solucionado el problema

Un fraternal abrazo

Samuel Sclarovsky

Dear Dr Marcelo Abud: ST segment elevation in a male may correspond such as in this case to an early repolarization pattern (high take off).

Why it is not an acute ischemia? Answer: Because there are no reciprocal or mirror image on the ECG1 (physiological remodeling)

Why he has not an acute pulmonary embolism? Answer: Because he has not QRS axis deviation to the right.

Why he has not an acute pericarditis? Answer: because the leads are not affected diffusely, the PR interval is isoelectric, there are not precordial pain, no fever and not tachycardia (In acute pericarditis the HR is almost always around 120lpm.)

So why this patient has? Answer: androgenic effect on the heart. The androgens selectively increase the contractile force in the epicardial layer myocytes with calcium overload inside of sarcomeres, (causing ST segment elevation) and concomitantly producing more K^+ output during phase 3 action potential by stimulating of slow delayed potassium channels (responsible for the sharp appearance of the T wave)

This selective epicardial hipercontractility observed in males increases the coronary flow requirement. This ECG shows both the low anterolateral (from V4 to V6) and high anterolateral (aVL I) walls hypercontractiles. I speculate that the Cx artery is small with a predominance of the right coronary artery(RCA). This can result in inadequate coronary circulation dyspnea or chest pain

How we approach this? Answer: with beta adrenergic blockers.

I do not want to criticize the invasive studies that were done, but I think that in this case with “20 pesos” we solved the problem.

A fraternal hug

Samuel Sclarovsky

Dudas y criticas al raciocinio del Profesor Samuel

*El ECG1 muestra clara elevación del segmento ST confinado apenas a V2-V3(región medioseptal). En la repolarización precoz la elevación del ST es de concavidad superior terminando en una T positiva amplia de V2 a V4 o V5 “**prominent J wave and ST-segment elevation, concave to the top, predominantly in left precordial leads, ending in a positive large T wave from V2 to V4 or V5**”. La repolarización precoz excepcionalmente tiene elevacion del ST en las precordiales derechas.*

En la repolarización precoz clásica benigna el supradesnivel de punto J y segmento ST de concavidad superior y seguido por onda T apiculada que se observa en la gran mayoría de los casos de V4 a V6 y/o en la pared inferior. En este caso, no se observa supradesnivel del segmento ST en esta área. Además no vemos bradlcardia sinusal que es lo que suele verse en la repolarizacion precoz.

*Si se fijan bien existe aqui discreto infradesnivel del ST de 1mm en V5 “**J point and ST segment depression**”*

Por otra parte este paciente asociado a la dispnea tuvo una importante hipotensión arterial transitória.

*Aqui claramente en el ECG 1 se observan muescas o empastamiento en la rama descendente de la R mas conspicuas de V3 a V5 pero tambien visibles en V2 y V6. Ese hayazgo si es compatible con repolarizacion precoz “**notching, irregular or slurring contour of the terminal QRS complex**”*

*Por otra parte querido maestro en este caso el aspecto del ST en V2 es de convexidad superior “**convex to the top**” absolutamente diferente del supradesnivel del ST de la repolarizacion precoz y va seguida de una onda T negativa.*

En la Repolarizacion precoz el supra de ST es de concavidad superior seguida por una T puntiaguda positiva concordante.

Andres,

Querido amigo amigo maestro Adrian Baranchuk disculpeme por mi condicion de otista, pero mas claro no puedo ser, y, sobre en hombre de 45 años con hipotensión Me supongo que alguien que vio el ECG con disnea le administró nitrito sublingual que ocasiona hipotensión transitória y taquicardia sinusal Seria interesante si el Dr Abud envíe otro ECG en reposo sin taquicardia y presion normal ,estoy casi seguro que el ST-T seran mas alto ,a pesar que a los 45 años estos hallazgos en el ECG estan atenuados Por suerte mi amigo profe Andrés Ricardo Pérez Riera, se tomo la molestia en traducirme, del español al español

Un fraternal abrazo y a todos los amigos de la colectividad judia feliz anio nuevo

Samuel Sclarovsky

Querido amigo

Que le hayan dado un nitrito es SOLO una suposicion, bastante facil es preguntarle al paciente, no cree?

Pero estoy seguro que Abud o Perez-Riera lo hubieran clarificado.

Por otro lado, hipotensión sostenida no es frecuente de ver en ese escenario que Ud describe. Digo todo esto, porque Ud en su email, usando un lenguaje un poco sarcástico, dijo que este caso Ud lo resolvía con 20 pesos y NO con el gasto de estudios invasivos. Yo estoy en desacuerdo. Porque? Porque Ud corre con el caballo del comisario, y sabe que todo dio normal, pero yo aqui en Canada, le hubiera hecho los mismos (o similares estudios).

Por favor, una cosa es la especulación luego de saber los resultados y otra muy distinta ser el colega de guardia que tuvo que decidir esta conducta.

Yo no se que tiene el paciente, pero le aseguro que tambien hubiera descartado TEP primero e isquemia después.

Eso de que NO tiene BCRD y por eso NO tiene TEP, es demasiado estricto ya que el BCRD se ve en solo el 60% de los casos (hay un lindo review que escribimos hace un tiempo, busquelo que ahi estan todos los cambios de TEP en el ECG...).

Un fuerte abrazo y disculpe mi descuerdo en este caso

AB

Samuel

1. Ud dice: "me parece que Ud esta errado". En la actualidad, es mejor discutir diciendo: "yo pienso que". No es necesario descalificar al otro por el simple hecho de no estar de acuerdo. Yo ya le dije, no se lo que tiene el paciente, pero hubiera hecho los mismos estudios. Eso NO es estar errado, es simplemente, estar en desacuerdo con Ud (y estoy seguro porque lo conozco, que Ud no se cree el dueño de la verdad...no cierto?)

2. Ud dice: "yo hace muchos años que me dedico a esto". Es cierto. Y? Eso lo transforma en dueño de la verdad. Yo me dedico con igual pasion que Ud, y eso NO me hace dueño de la verdad.

Concuerdo en el uso racional de los estudios, 100%. Pero ese NO es le tema del paciente en cuestion, sino que le produjo un cuadro tan severo, con un ECG tan anormal. A veces para aprender, hay que invertir. No hay otra.

Le mando un abrazo sincero.

AB

Professor Andrés e Caro Dr. Marcelo:

Interessantíssimo caso.

A história clínica sugere episódio tromboembólico => Trauma com fratura de tornozelo - Repouso ou imobilidade do membro => Trombo embolismo coronário - (MI Type 2 - Expert Consensus Document - European Heart Journal doi:10.1093/eurheartj/ehs184apub 09/12) - - Resolução do quadro com anticoagulante –

Quanto ao ECG-1 - Síndrome isquêmica aguda c/ ST supra V2-V3, imagem ST em espelho infra V4-V5. Discretíssimo supra em D1- aVL FC: 88bpm Quadro clínico e ECG praticamente normalizado 2 horas depois. Quanto as enzimas: foram seriadas? Embora o episódio todo possa ter ocorrido s/ alterações enzimáticas.

Observar que o " J Osborn -like" também desaparece e todos os fenômenos se normalizam nos ECGs do dia seguinte.

Não teria feito cateterismo.

Adail - Bahia - Brasil

Interesantísimo caso.: Elevación de segmento ST tipo Brugada o tipo infarto anterior en V2 y ondas J bastante localizadas en V3-V4. La respuesta a la última pregunta de Marcelo es fácil: Cualquier médico responsable hubiera hecho los estudios necesarios para excluir un infarto agudo y una embolia pulmonar en un paciente con disnea súbita y este electrocardiograma.

La otra pregunta de Marcelo, cual es la interpretación del electrocardiograma una vez sabiendo que no hay evidencia de lesiones coronaria o de embolia pulmonar también es fácil de contestar. Mi respuesta: “no tengo idea”. Que puede ser esto?

1. Respuesta a hiperventilación? Este tema ya no está de moda, pero estuvo muy de moda en el siglo pasado (hijos, que feo se oye eso..). Ejemplos(1;2;3)El problema con esta teoría es que la hiperventilación en gente sana produce inversión de onda T y depresión del segmento ST. Pero, en pacientes con enfermedad coronaria, la hiperventilación puede producir elevación de segmento ST(4) Por tanto, uno podría argumentar que las coronarias de este paciente aparentemente normales en la angiografía pero no son realmente normales.

2. Coronary spasm? Faltan los cambios recíprocos en otras derivaciones y en paciente no tubo dolor de pecho.

3. Pericarditis? No clásico pero siempre puede ser. Si usamos este diagnóstico cada vez que no tenemos idea que está pasando, por que no usarlo aquí?

4. Un infarto localizado de la arteria del cono “conal branch” de la arteria coronaria derecha(CD)? Es posible. Tan posible que movería esta posibilidad para arriba. Recientemente tuve un paciente con gran infarto inferior por oclusión de la CD. Tenía elevación del segmento ST en II, III y aVF

1. Savonitto S, et al. Different significance of hyperventilation-induced electrocardiographic changes in healthy subjects and patients with coronary artery disease. *Eur Heart J.* 1996;17(9):1302.

2. Lary D, Goldschlager N. Electrocardiographic changes during hyperventilation resembling myocardial ischemia in patients with normal coronary arteriograms. *Am Heart J.* 1974;87(3):383-90.

3. Lewis WC, Siebecker KL, Jr., Wasserburger RH. The effect of hyperventilation on the normal adult electrocardiogram. *Circulation.* 1956;13(6):850-5.

4. *Eur Heart J.* 1996;17(9):1302).

Fue sometido a intervención coronaria urgente con dilatación y “stenting” de el tramo próximo de la CD y al poner el stent se obstruyó la rama del cono “conal branch” ocasionando un patrón ECG “Brugada-like” muy semejante a este caso y el paciente desarrolló fibrilación ventricular. Mientras mas lo pienso, mas me gusta esta posibilidad.

5. Simple “repolarización precoz”? Puede ser. Pero el paciente presenta con disnea y tachycardia. El “stress” debería disminuir los efectos electrocardiográficos de repolarización precoz que generalmente aumentan durante tono vagal.

6. Síndrome de Brugada? Puede ser. El hecho de que desaparezca o disminuya al día siguiente no descarta esta posibilidad. Definitivamente yo le haría una prueba de ajmalina antes de mandarlo a la casa. Por cierto, que hay controversia en lo que se refiere al efecto del “stress” en el ECG del Brugada. En Ámsterdam el segmento de ST de Brugada supradesnivele durante el ejercicio(1). En Japón el ST normaliza durante el ejercicio y aumenta durante la fase de recuperación (2).

7. Medicamentos que “producen Brugada” (brugadadrugs.org)? La lista es grande y para la mayoría los efectos aumentan durante taquicardia.

8. Embolia pulmonar que resolvió? No se hizo tomografía CT del pulmón... sin ofender... la arteriografía pulmonar no es fácil de interpretar. Además, el paciente recibió anticoagulantes.

9. Tumores o “misceláneos” del mediastino? Esto es muy importante checarlo. (3;4)

Definitivamente solicitaría una tomografía (CT) de tórax antes de mandar al paciente a la casa.

Y pus total, siempre queda la otra posibilidad: No se!

Sami Viskin (Tel Aviv).

1. Min AS, de Groot EA, Ruijter JM, Wilde AA, Tan HL. Exercise-induced ECG changes in Brugada syndrome. *Circ Arrhythm Electrophysiol.* 2009;2(5):531
2. Augmented ST-segment elevation during recovery from exercise predicts cardiac events in patients with Brugada syndrome. *JACC.* 2010
3. Nakazato Y, et al. Brugada-like precordial ST elevation on ECG by anterior mediastinal infective mass lesion. *Indian pacing and electrophysiology journal.* 2003;3(3):184. Tarin N, Farre J, Rubio JM, Tunon J, Castro-Dorticos J. Brugada-like electrocardiographic pattern in a patient with a mediastinal tumor. *Pacing Clin Electrophysiol.* 1999;22(8):1264-6.

Descartada obviamente la hipotermia por exposicion laboral y/o accidental las intoxicaciones medicamentosas o por monoxido de carbono. Asi como tambien la infeccion posquirurgica con bacteriemia o sepsis. Brugada-Like ECG Pattern in Severe Hypothermia *Circulation*.2008;118:977-978, Dr Sami muy interesante su analisis y la evaluacion de los diagnosticos diferenciales.

El paciente se presenta con hipotension, taquicardico y cambios en el ECG muy similares a los descritos en el experimento en perros Cellular Basis for the Electrocardiographic J Wave [Gan-Xin Yan](#), MD, PhD; [Charles Antzelevitch](#) y analizan los cambios endo epicardio como los responsables posibles del origen de dicha onda y ademas en el experimento encontraban cambios ECG de v4 a v6 similar a este paciente y en precordiales derechas simulando un patron de Brugada interpretandolos por la hipotermia, y a la hipercalcemia transitoria y el desalloro de acidosis (cual papel sera el de esta en la velocidad de los potenciales de accion?)

Su analisis creo merece solo un comentario: en el TEP los cambios caracteristicos de S1Q3T3 o aparicion de BRD con eje desviado a la derecha se ve en la mayoria de los pacientes, no en todos.

El dimero D puede ser negativo (es un producto de la degradacion de la fibrina) en un 5% de estos, la angiografia pulmonar descarta los embolismos masivos o de arterias pulmonares, pero tampoco descarta totalmente el TEP.

El ecocardiograma al igual que los otros metodos solo resulta positivo en la mayoria de los casos, contribuye al diagnostico pero no lo excluye.

De lo referido llama la atencion un paciente sin patologia previa conocida, cirugia de tobillo reciente, en casos de politraumatismo la incidencia de TVP es del 20% con probabilidad de presentarse como TEP del 0,5 no refirio el Dr Abud si recibia profilaxis para trombosis venosa profunda. La ausencia de coagulo en MII disminuye las probabilidades de TEP, pero tampoco lo excluyen.

La TAC helicoidal (ya se realizo una arteriografia pulmonar) no creo aporte al diagnostico presenta una sensibilidad del 90% cuando el embolismo es de las arterias de primer y segundo orden, y al incluir los vasos subsegmentarios esta cae al 67%, los TEP subsegmentarios son alrededor del 6% en el estudio PIOPED .

La Escala de Shier para evaluar la probabilidad de embolias grasas en las primera 72 hs luego del accidente es util para predecir la probabilidad de TEP de este origen en este caso seria extremadamente raro se presentara tardiamente como han referido. La onda J de Osborn, descrita por este cuando experimentaba con perros al inducirle hipotermia(1), el primero en describirla fue Tomaszewski que encuentra cambios en el ECG de un hombre fallecido por hipotermia (1) No encuentro una explicacion concreta, pero en medicina todo tiene una explicacion y no hay casualidades sino causalidades, podremos diagnosticarlas correctamente o no, pero el criterio de estudio del paciente me parece el adecuado. Este paciente en particular presenta al ingreso una elevacion del punto J que disminuye pero no desaparece en los ECG posteriores, lo que lleva a pensar en un trastorno agudo de una patologia cronica, lo que va en contra de pensar en TEP. En el Brugada la elevacion del punto J en derivaciones inferiores esa descrita, pero en estudios experimentales tambien la presentan en cara lateral, estos estudios experimentales en laboratorio de la diferencia endo-epicardica de potenciales (les adjunto un link de un ECG exacto al presentado para que observen

<http://www.ncbi.nlm.nih.gov/pmc/articles/PMC2843811/figure/F5/> y se trata de un SBr no hipotermia, pero en este presenta repolarizacion precoz lo que no se observa en el paciente presentado. En la taquicardia la notched esta acentuada como ocurre en este paciente. Ya lo han anticoagulado o sea que esta recibiendo tratamiento para no repetir en caso de haber sido un TEP.

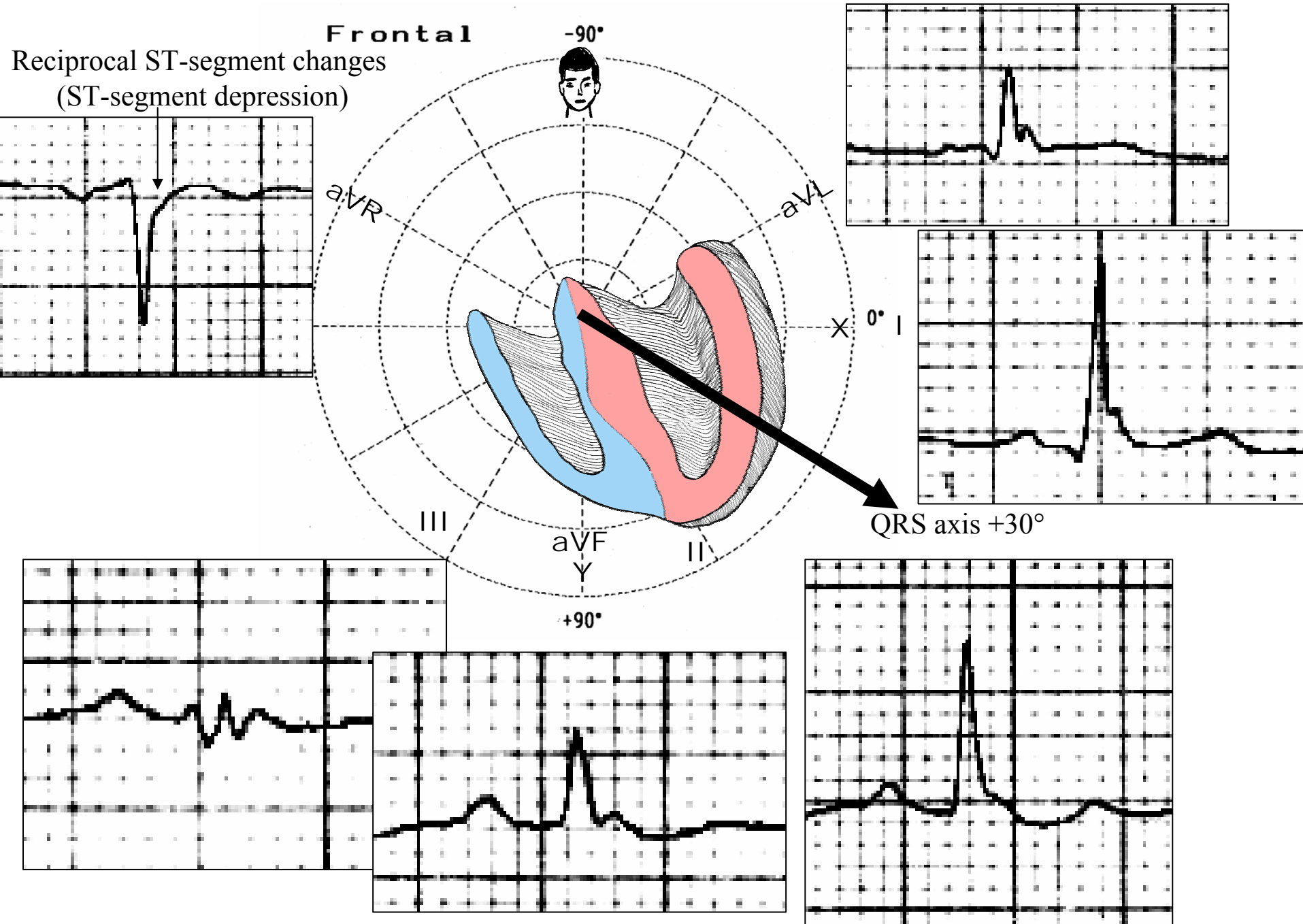
Podriamos excluir la probabilidad de que se tratara de un SBr asociado a repolarizacion precoz? Porque no realizarle una prueba con flecainida a fin de descartarlo? Un saludo Martin Ibarrola

1. Tomaszewski W. *Changements electrocardiographiques observes chez un homme mort de froid. Arch Mal Coeur* 1938;31:525) extraido de EKGWEB.
2. Osborn JJ. *Experimental hypothermia: respiratory and blood pH changes in relation to cardiac function. Am J Physiol* 1953;175:389
3. **Genetic, Molecular and Cellular Mechanisms Underlying the J Wave Syndromes** Charles Antzelevitch1) https://www.jstage.jst.go.jp/article/circj/76/5/76_CJ-12-0284/_pdf
4. **J Wave Syndromes** Charles Antzelevitch, PhD, FHRS1 and Gan-Xin Yan, MD, PhD2,3,4 <http://www.ncbi.nlm.nih.gov/pmc/articles/PMC2843811/>
5. **Paradoxical effect of ajmaline in a patient with Brugada syndrome** Biagio Sassone*, EP Europace Volume 8, Issue 4 Pp. 251-254.
6. **Brugada syndrome with atypical ECG: downsloping ST-segment elevation in inferior leads.** Riera ARP, Ferreira C, Schapachnik E, J Electrocardiol. 2004 Apr;37(2):101-4.

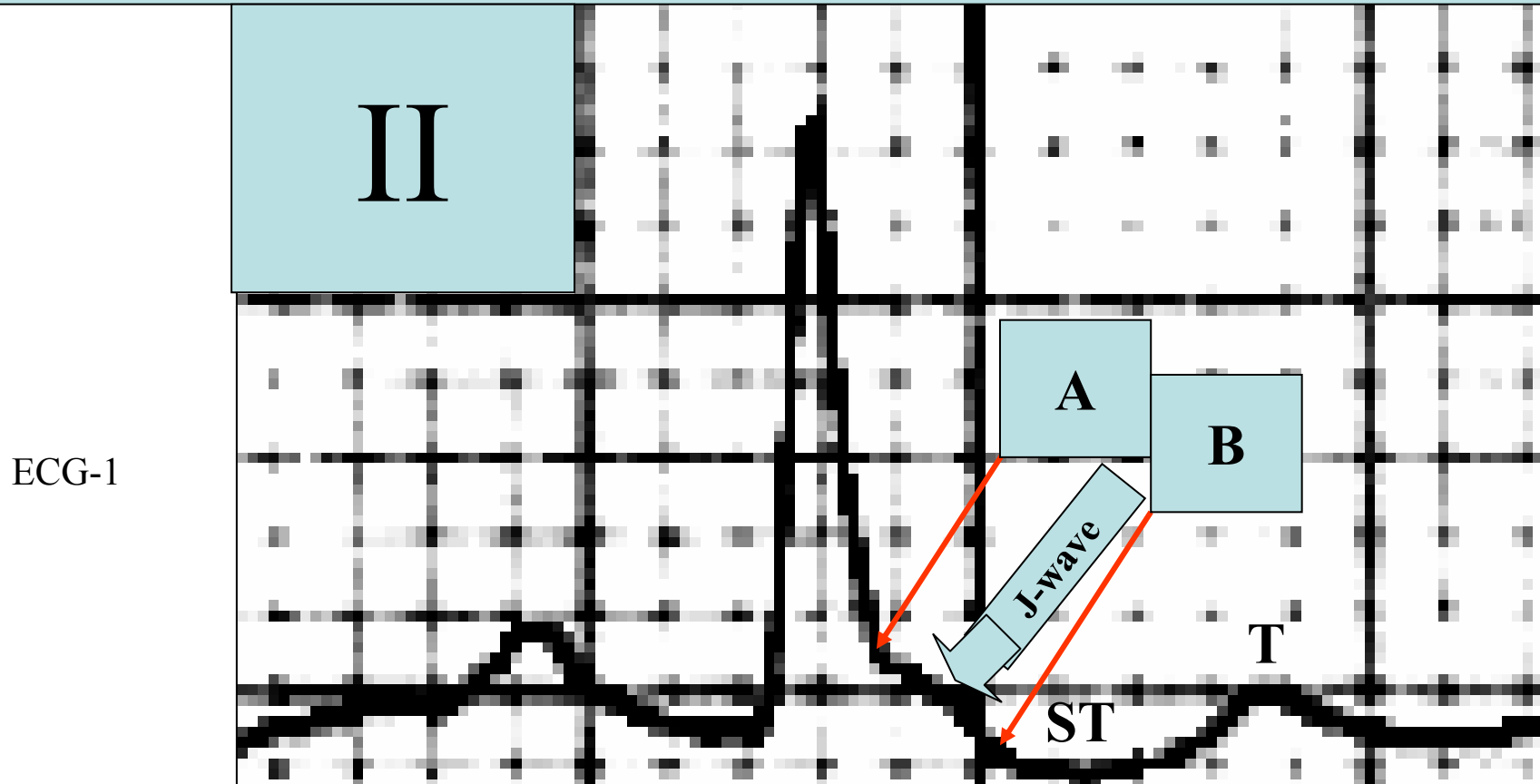
Final comments

By Andrés Ricardo Pérez-Riera M.D. Ph.D.

ECG-1 FRONTAL PLANE

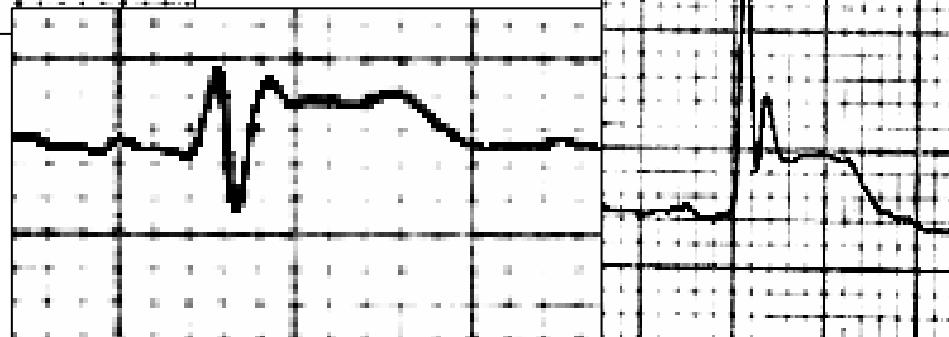
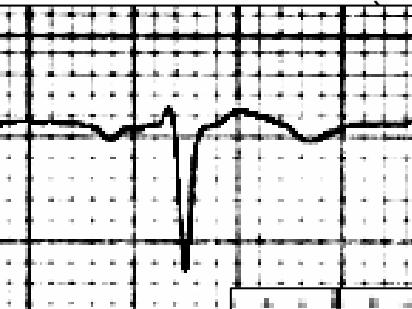
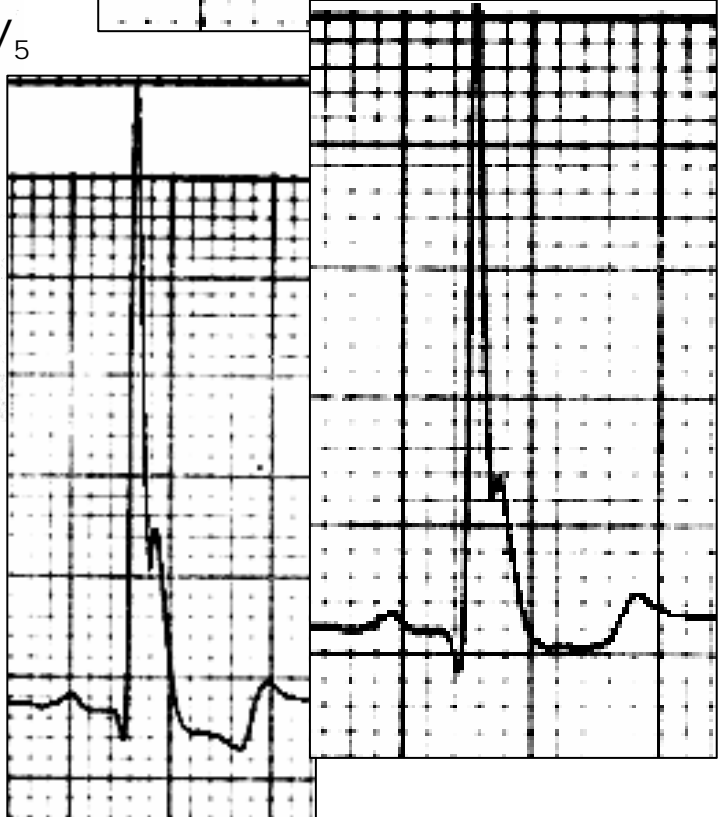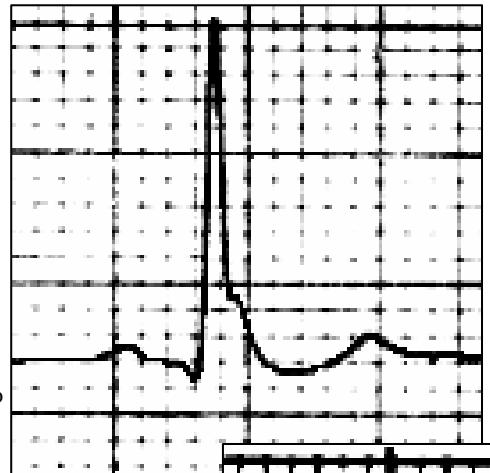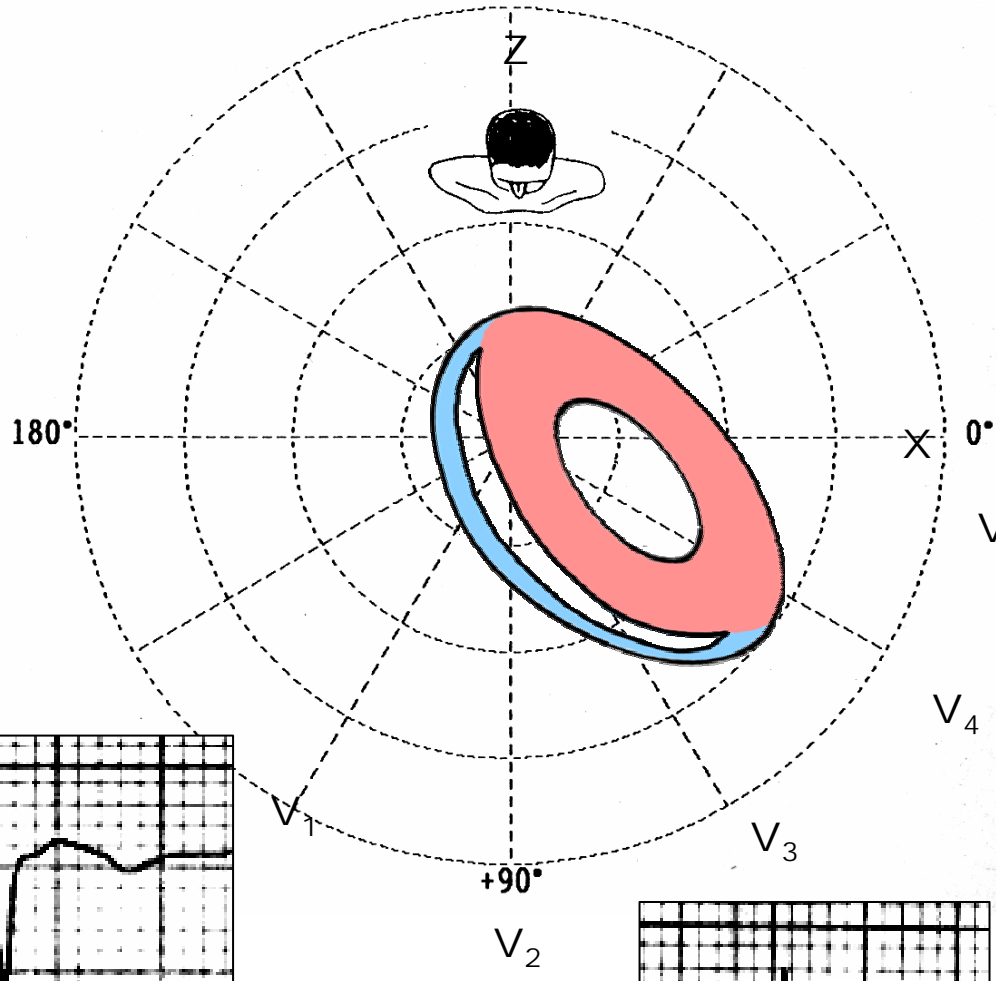


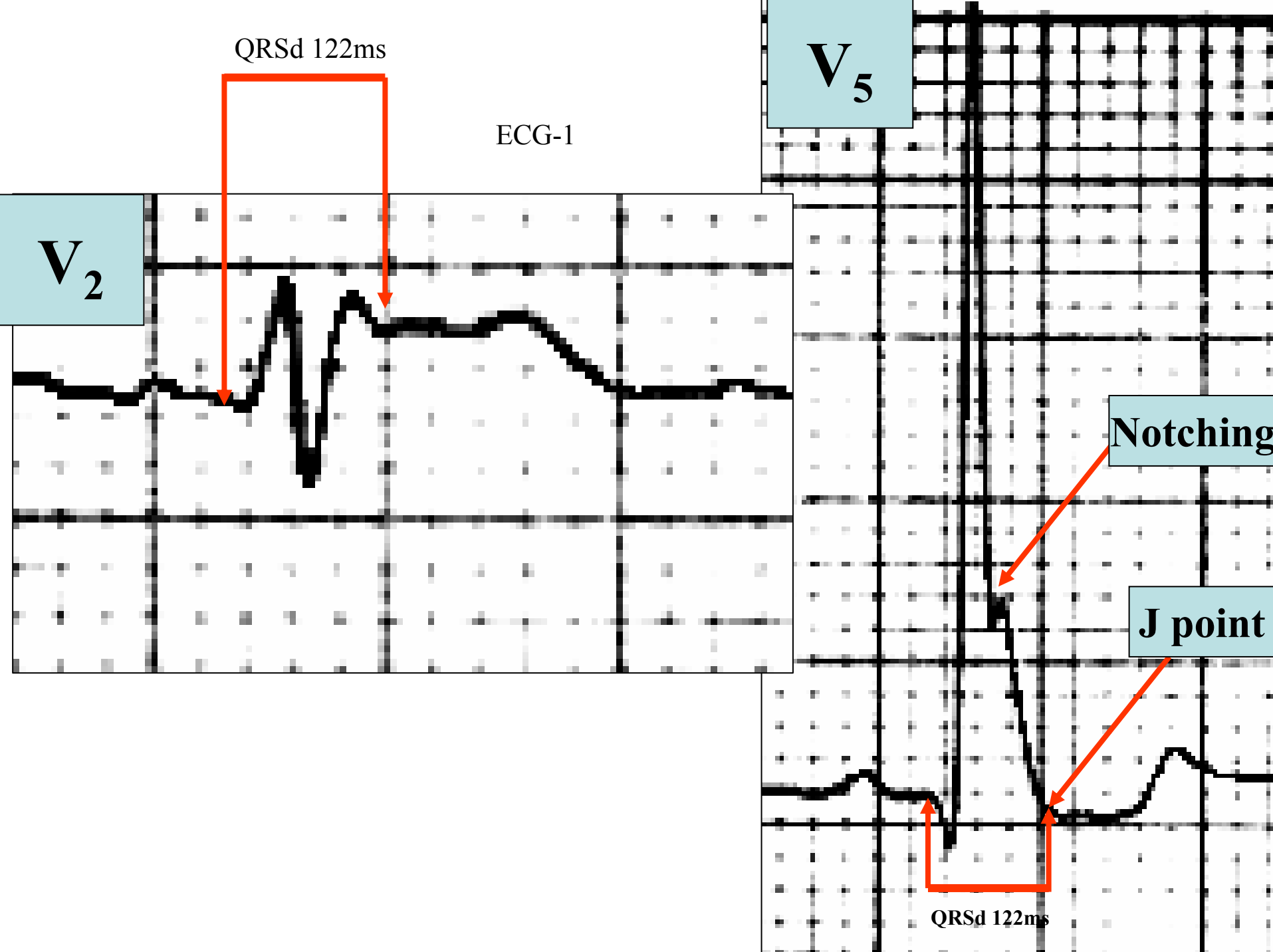
Where is the located the end of QRS complex? In A or in B? If the answer is B, QRSd is near 120ms If the answer is A, QRSd is near 70ms



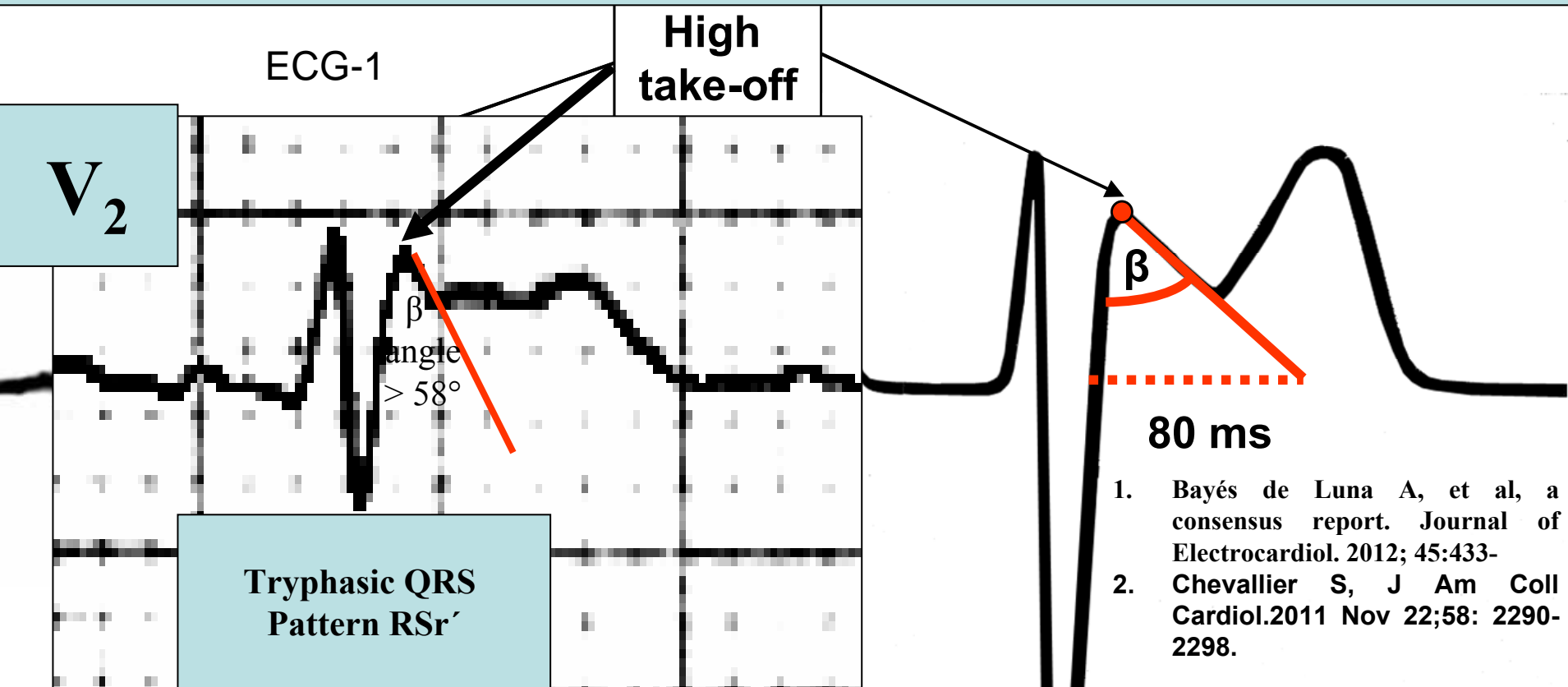
Early Repolarization Pattern (ERP) is defined as notching or slurring morphology of the terminal portion of the R wave (J-wave), that produces a positive hump, known as a J-wave, at the end of the QRS complex and beginning of the ST segment. J-point elevation ≥ 0.1 mV (or 1mm) above baseline in at least 2 in the mid-to-left precordial leads and/or inferior leads followed by concordant tall/ near symmetric (T waves having similarity in shape, ascending and descending ramps speeds). There is a distinct J wave and ST segment concave upward in the left precordial leads V_4 through V_6 . The ST elevation is most frequently evident in ECG lead V_4 .

Horizontal -90° ECG-1 HORIZONTAL PLANE





Is this a type 2 Brugada pattern or saddle-back pattern in V2 ?



High take-off of $r' \geq 2\text{mm}$, high take-off frequently does not coincide with J wave, descending arm of r' coincides with beginning of ST segment, the r' wave has rounded shape, wide and usually of relatively low voltage in Brugada pattern. Contrarily, in IRBB the r' wave is peaked, the angle between the upslope of the S-wave and the downslope of the r' -wave. (β angle) $> 58^\circ$, duration of the base of the triangle of r' at 5mm from high take-off $> 3.5\text{mm}$, the QRS duration is longer in Brugada pattern type 2 than in other cases with r' in V1 and there is a mismatch between V1 and V6. In Brugada pattern the QRS

RIGHT SAGGITAL PLANE ECG-1

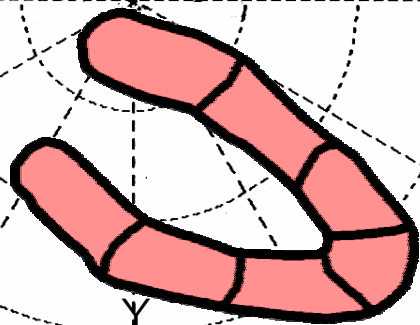
Sagittal

-90°



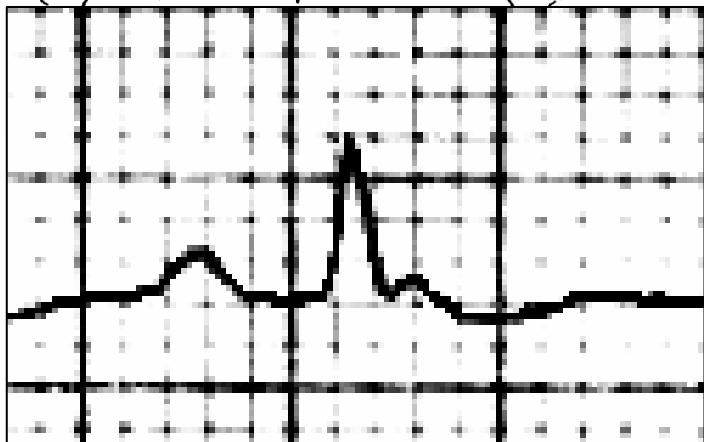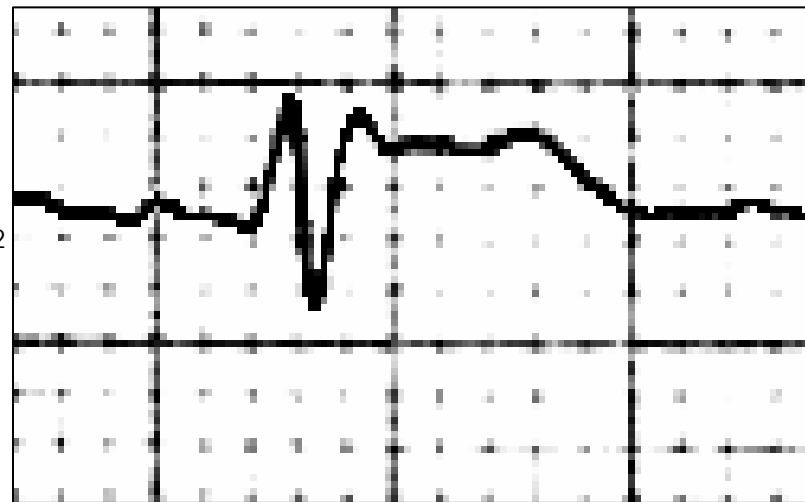
180°

Z

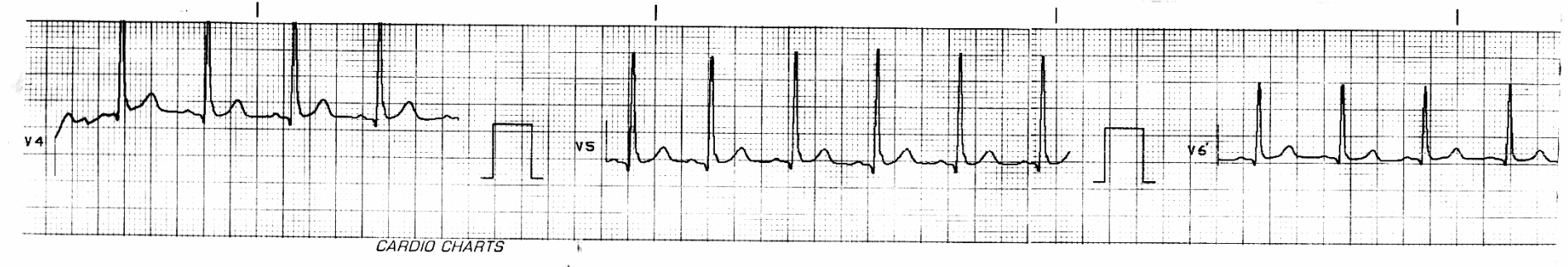
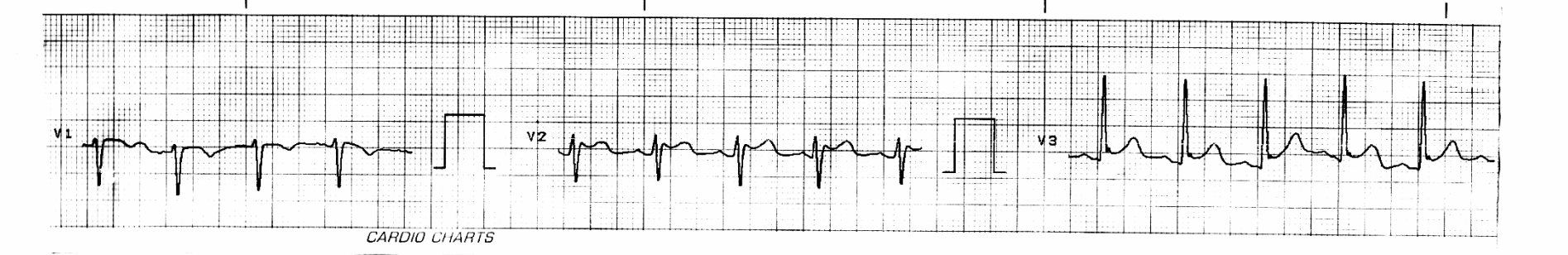
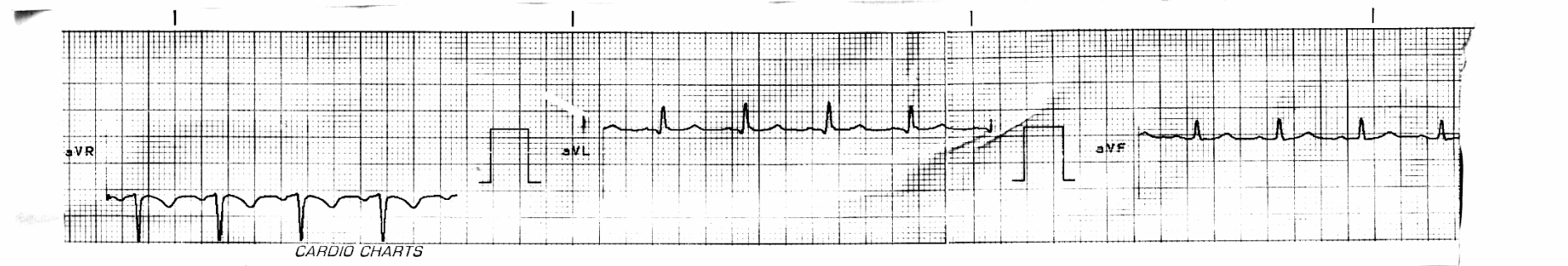
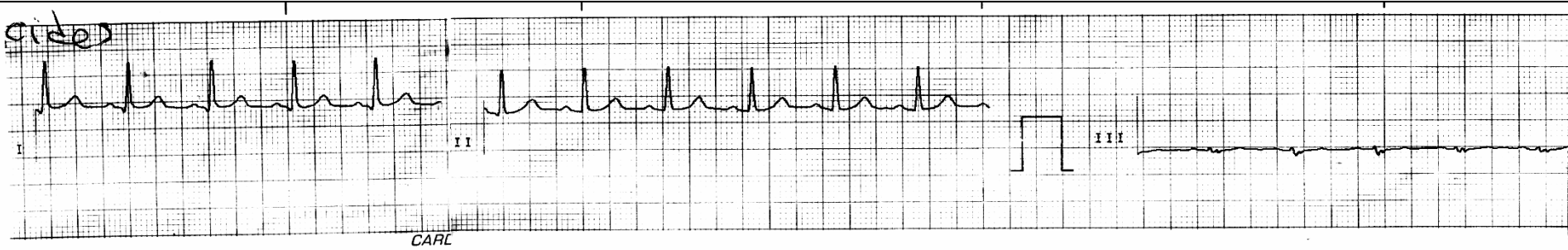


aVF

0° V₂



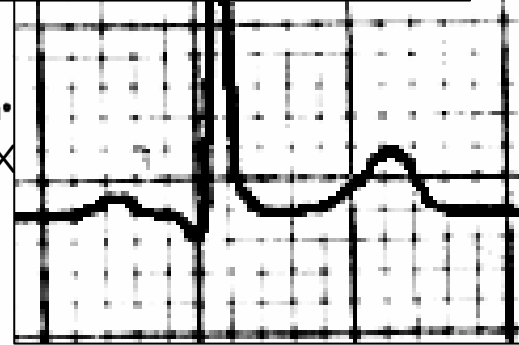
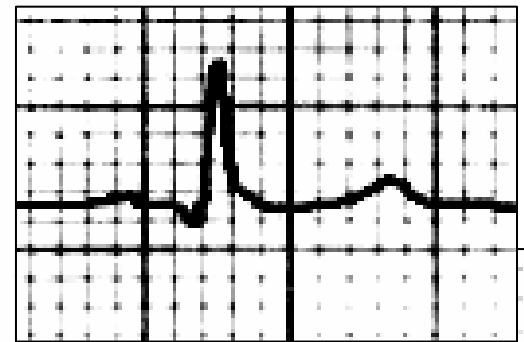
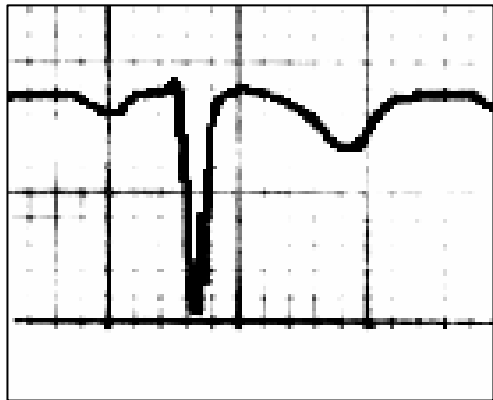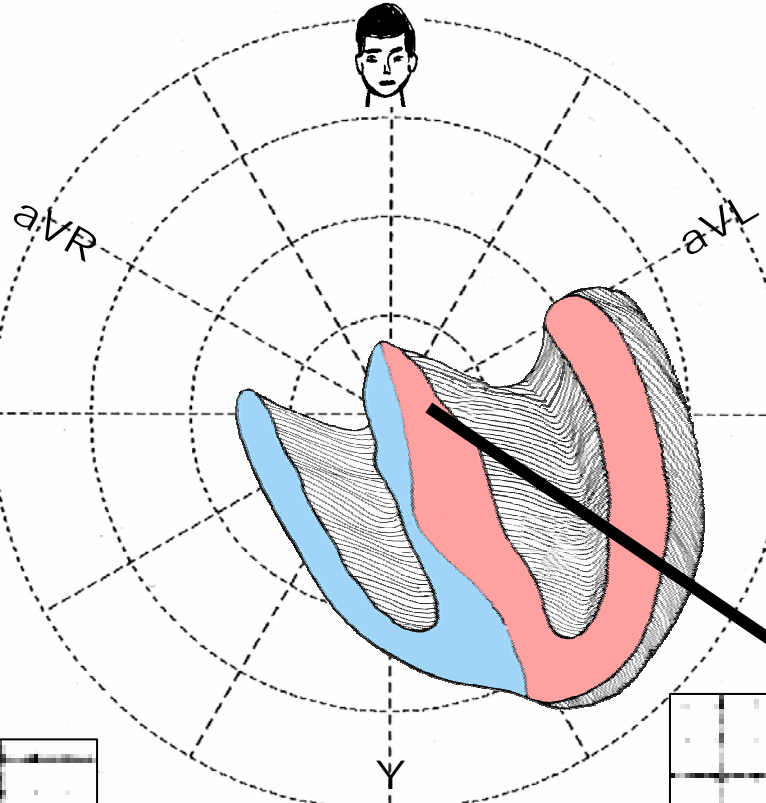
ECG 2



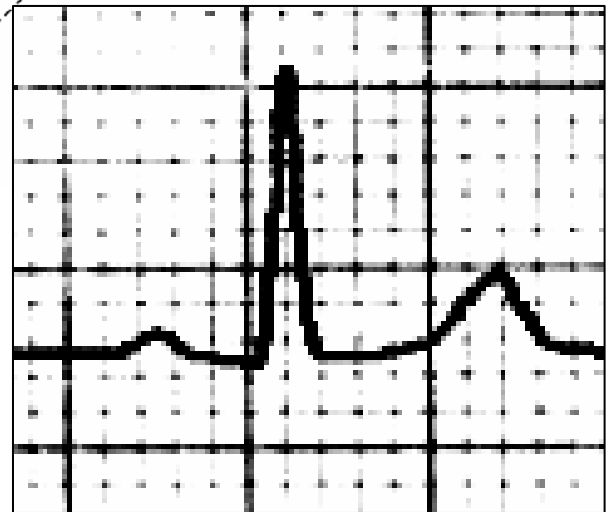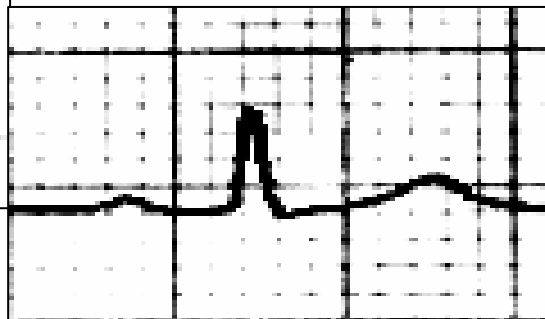
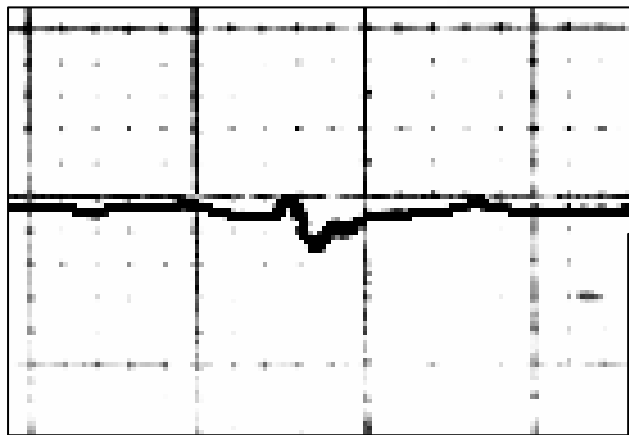
ECG-2 FRONTAL PLANE

Frontal

-90°

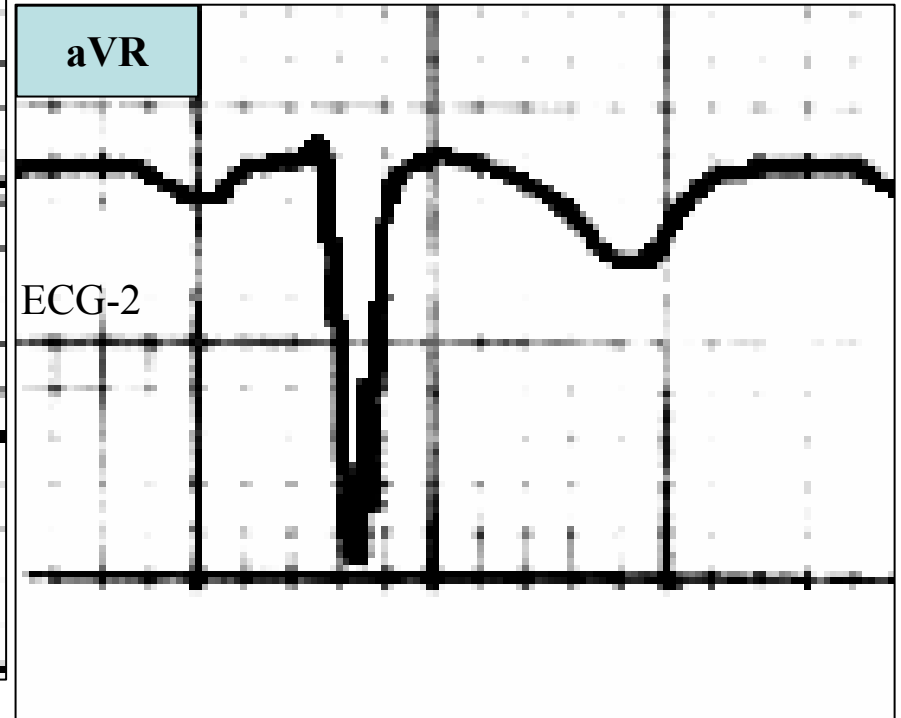
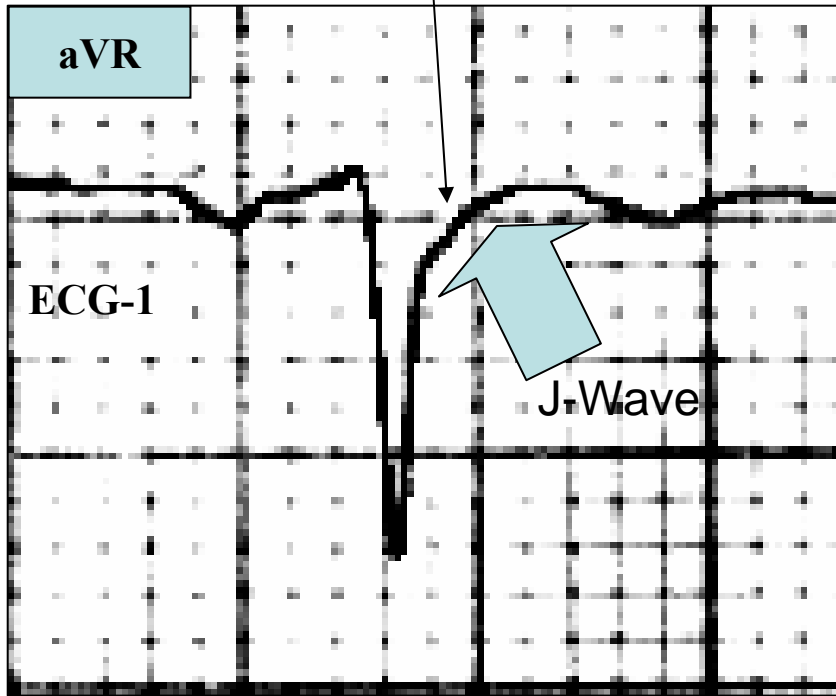


QRS axis +30°

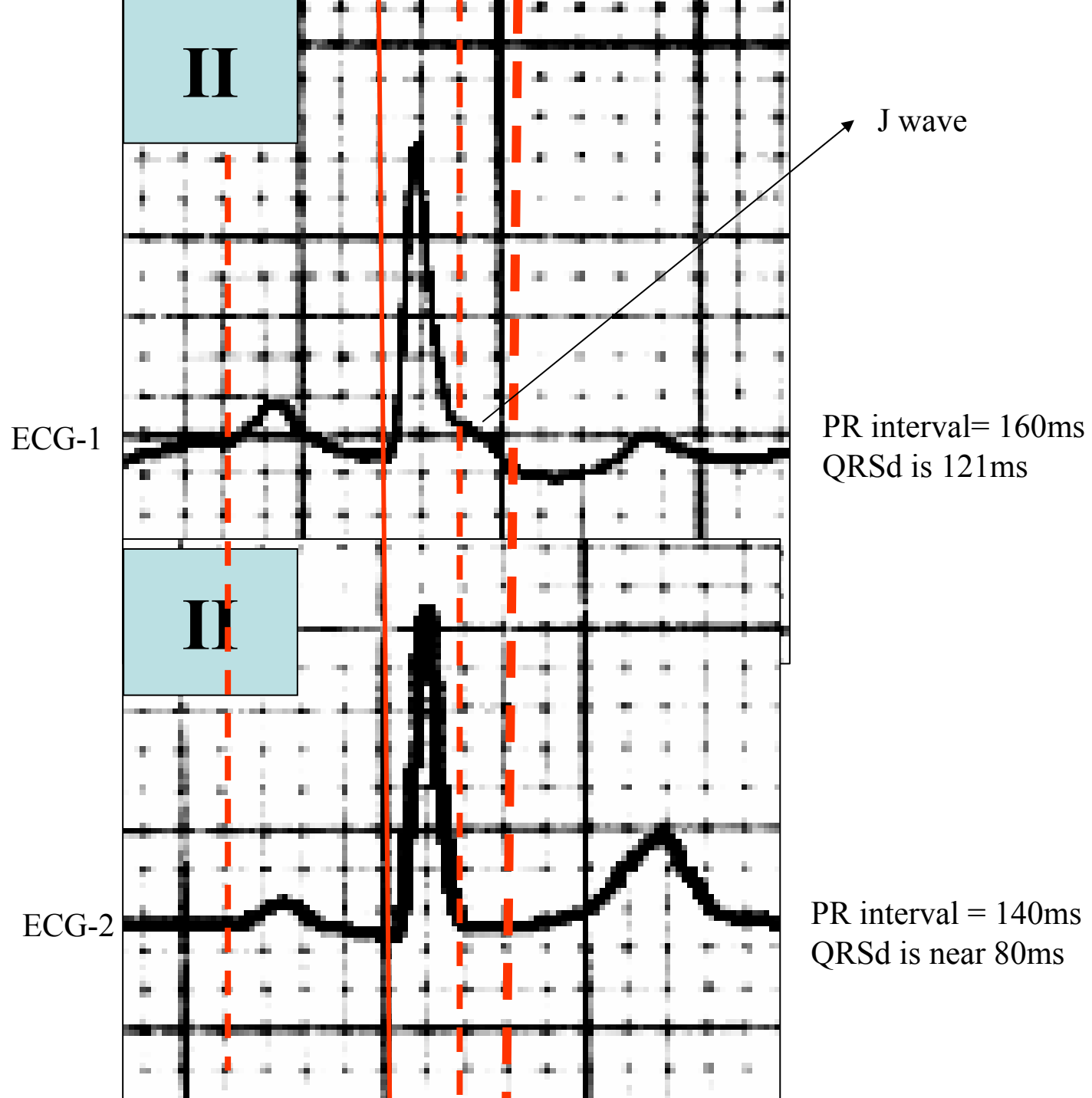


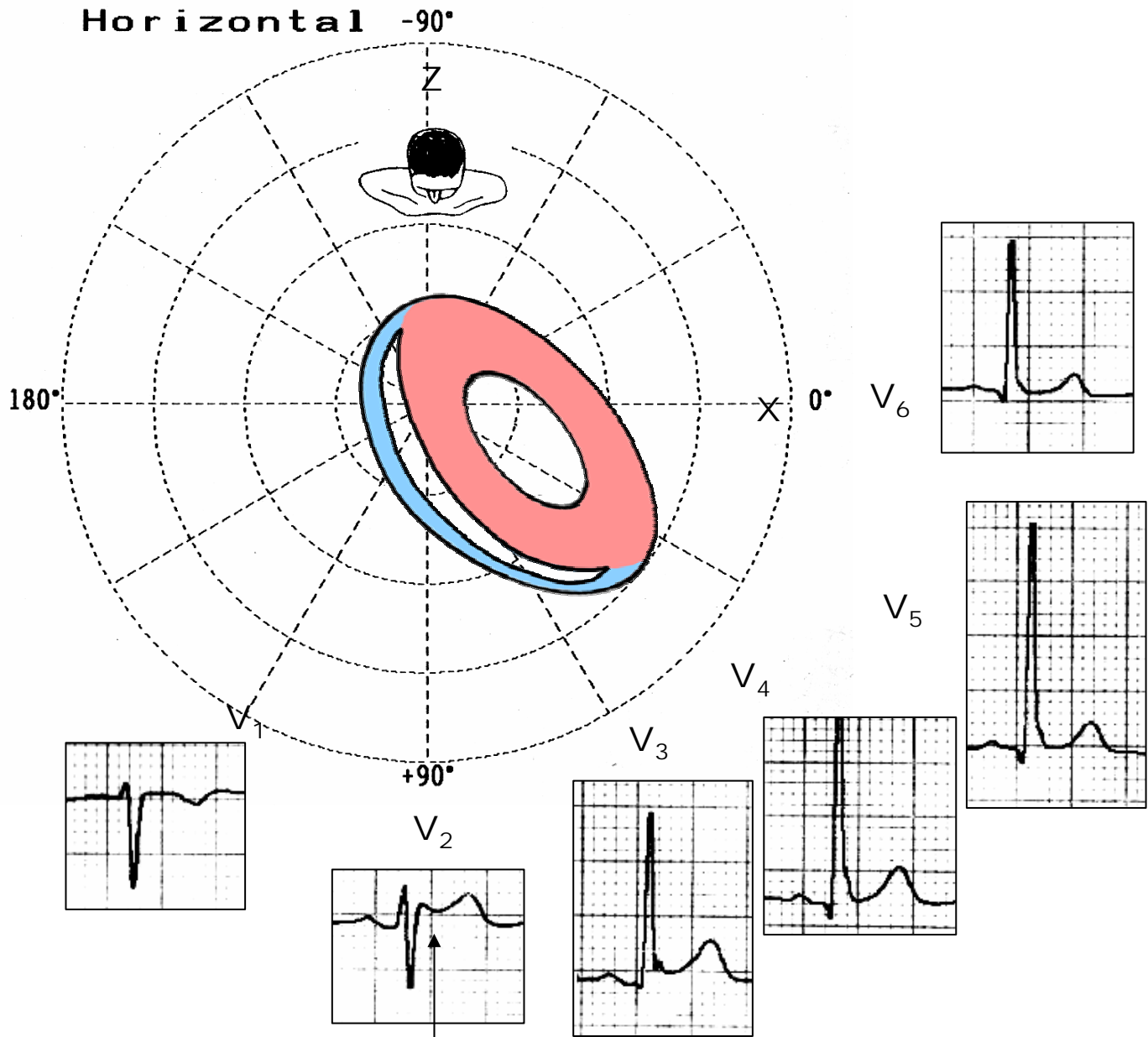
Reciprocal ST-segment changes
(ST-segment depression)

Without reciprocal changes or mirror image

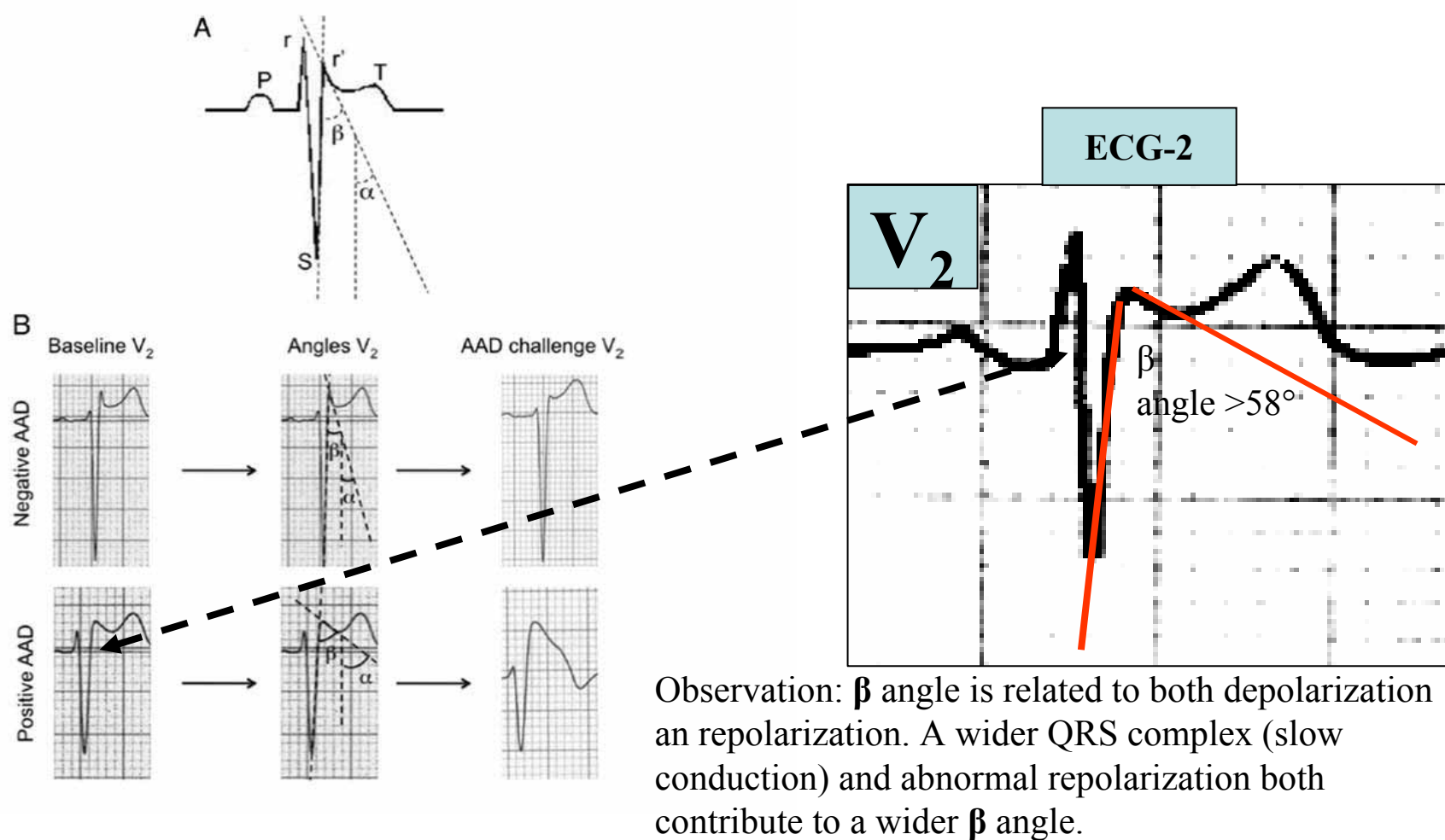


In Early Repolarization Pattern reciprocal ST-segment changes (ST-segment depression) are eventually confined the unipolar aVR lead. (Absence of reciprocal changes or mirror image in others leads).





Is this a type 2 Brugada ECG pattern? Answer in next slide



In patients with suspected Brugada syndrome, simple ECG criteria can enable discrimination between innocent incomplete RBBB from types 2 and 3 Brugada ECG patterns.

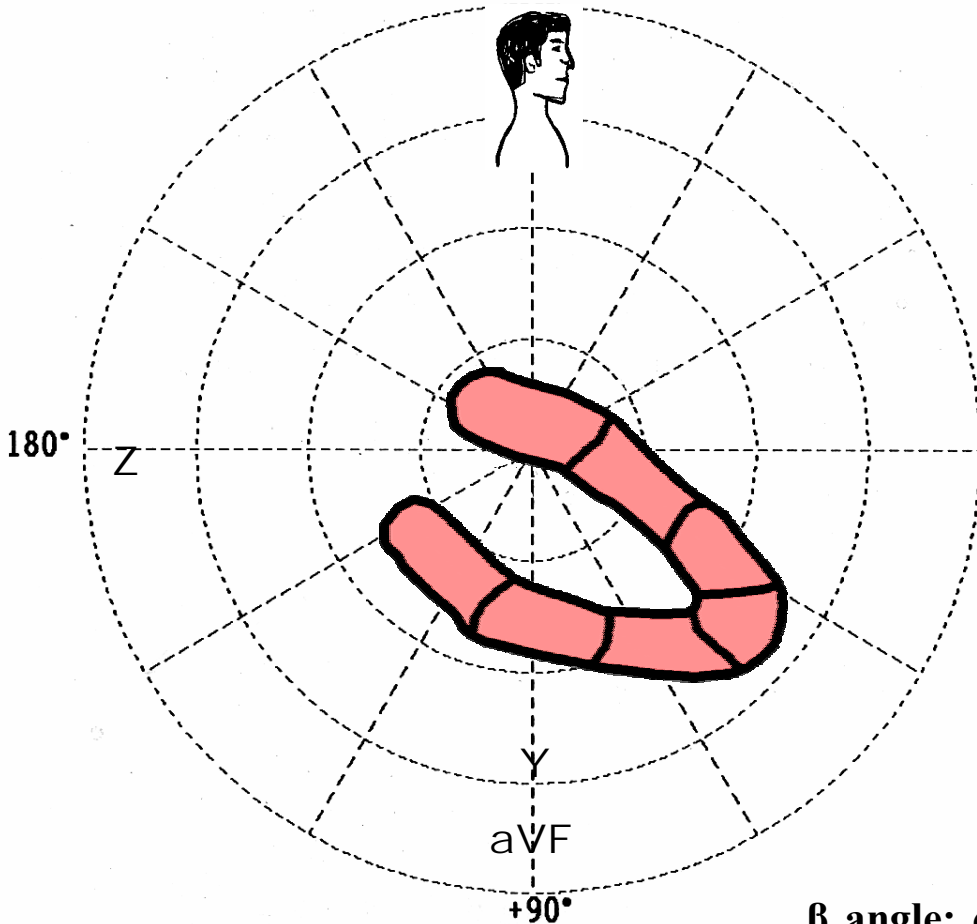
The mean β angle is significantly smaller in the patients with negative results on Antiarrhythmic Drug Challenge (ADC) compared with patients with positive results on ADC. Its optimal cutoff value is 58° , which yielded a positive predictive value of 73% and a negative predictive value of 87% for conversion to type 1 pattern on ADC; α is slightly less sensitive and specific compared with β . When the angles are combined with QRS duration, it tended to improve discrimination.

1. Chevallier S, J Am Coll Cardiol. 2011 Nov 22;58: 2290-2298.

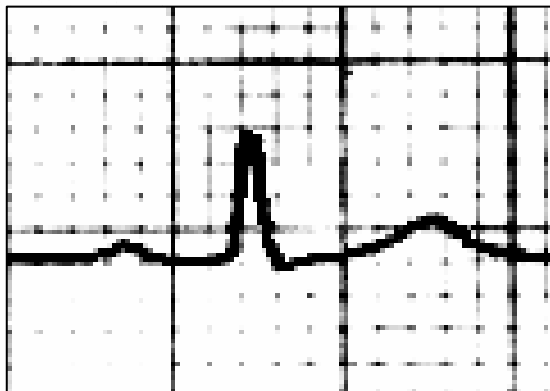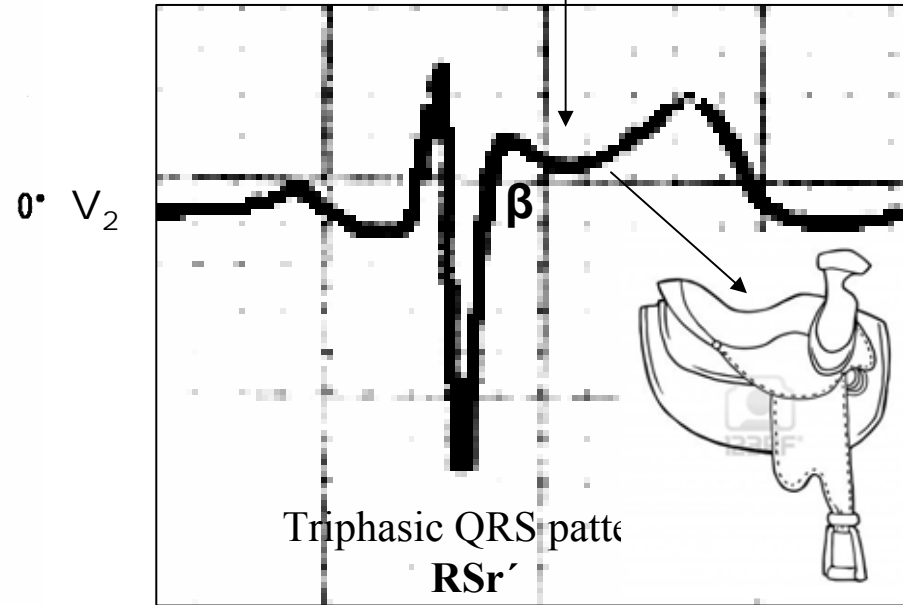
Right Sagittal Plane ECG-2

Sagittal

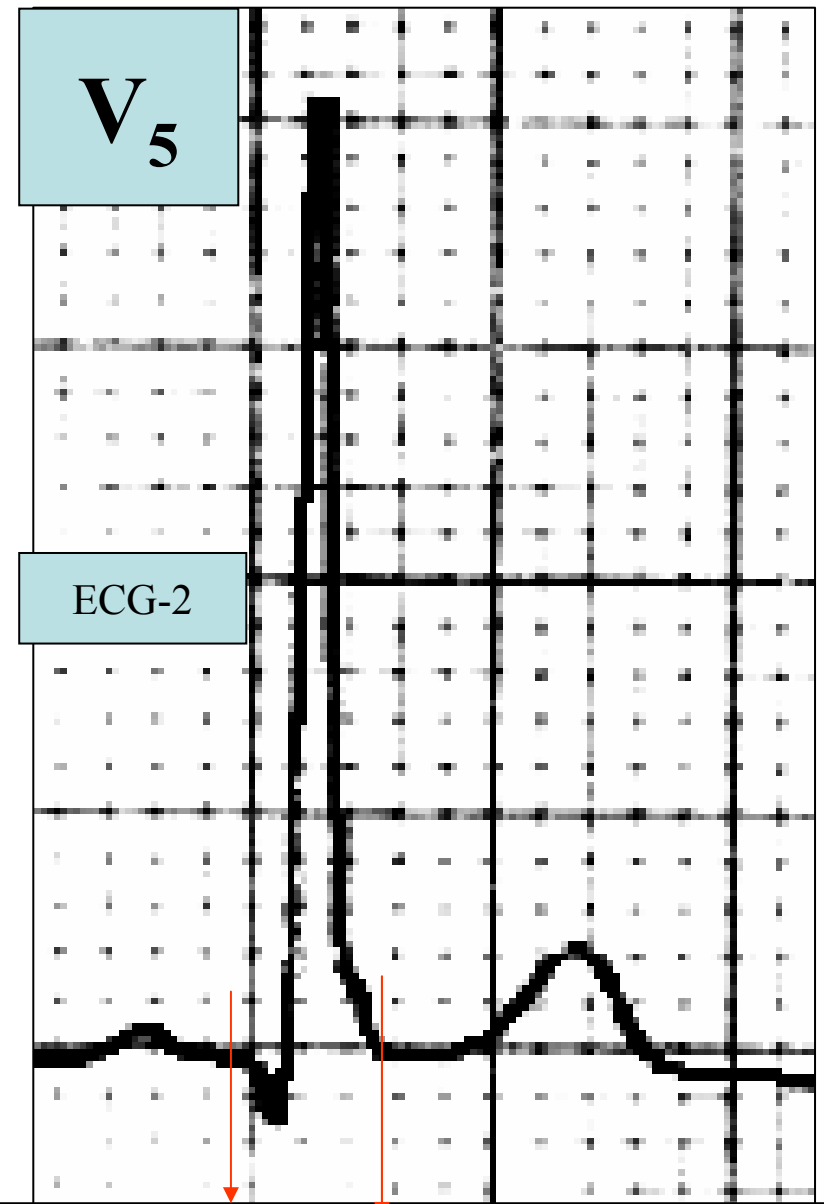
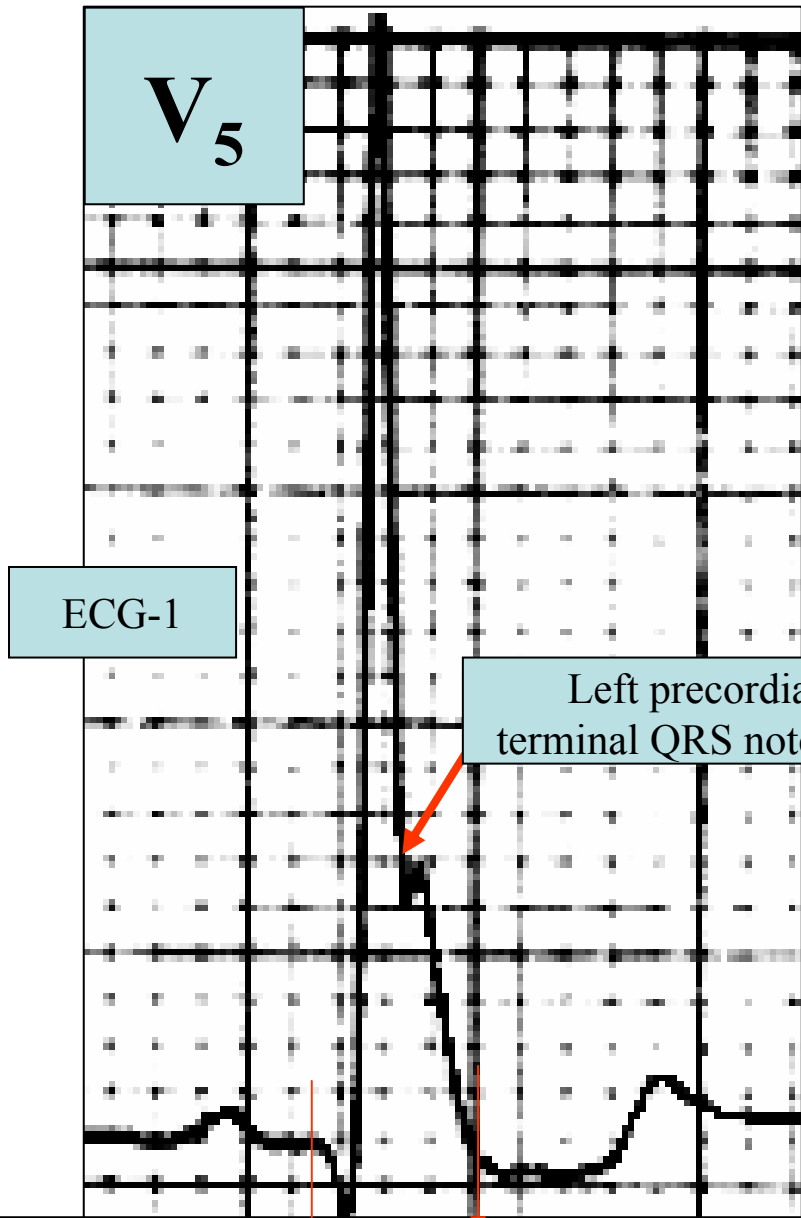
-90°



ST segment with saddleback appearance, followed by positive or biphasic T wave in V1-V2 or from V1 through V3.

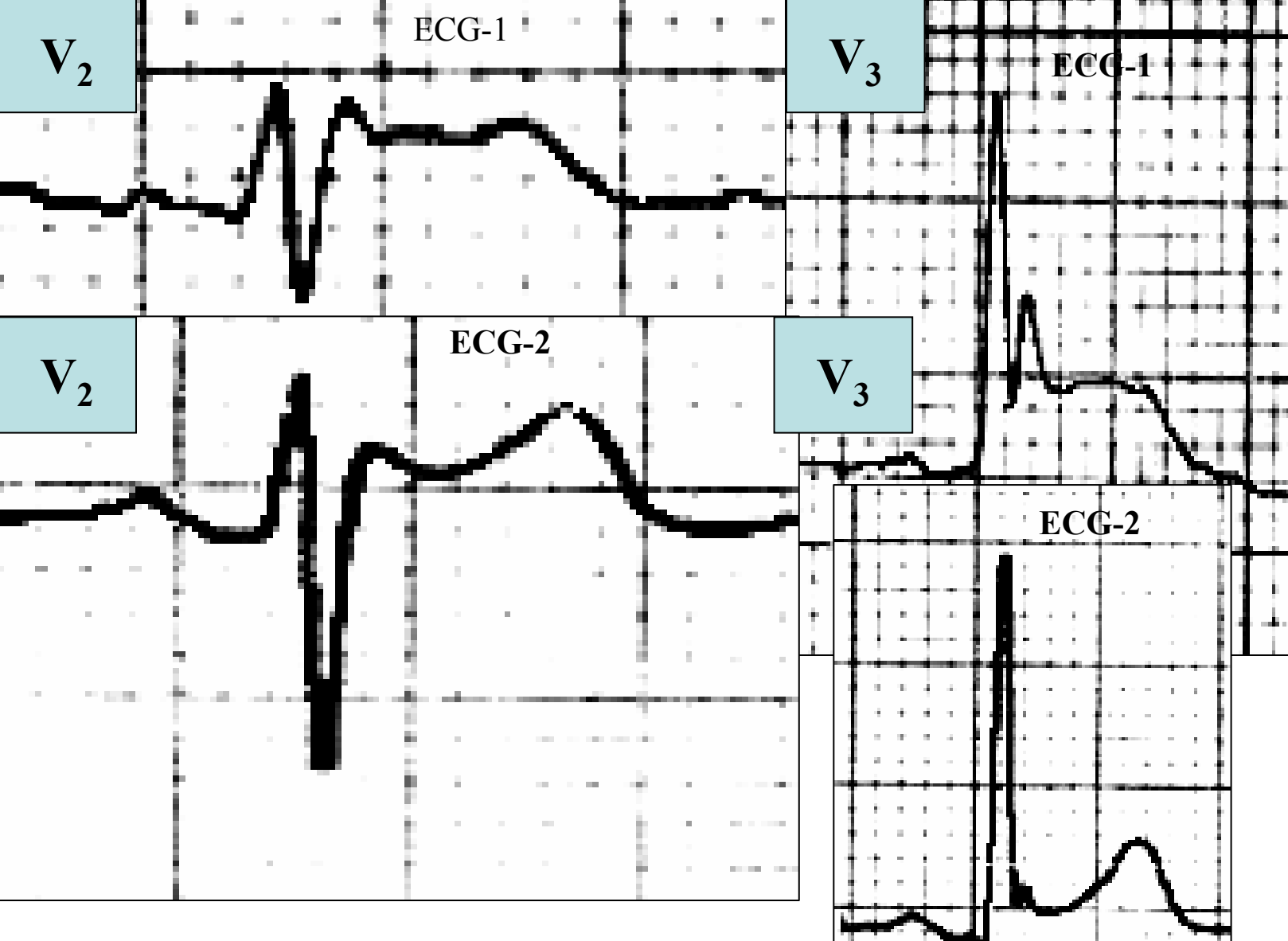


β angle: defined as the angle between the upslope of the S-wave and the downslope of the r'-wave. The mean β angle was significantly smaller in the 14 patients with negative results on AAD compared to the 24 patients with positive results on AAD. Its optimal cutoff value was 58°, which yielded a positive predictive value of 73% and a negative predictive value of 87% for conversion to type 1 pattern on AAD.



Left precordial terminal QRS notching is more prevalent in malignant early repolarization abnormalities

1. Merchant FM, et al. Am J Cardiol. 2009 Nov 15; 104:1402-1406



Dynamic, inconstant, or dramatic changes in repolarization are suggestive of malignant early repolarization abnormalities .

1. Haïssaguerre M, et al. J Cardiovasc Electrophysiol. 2009 Jan;20:93-98.

Conclusion this patient has high possibility of concomitant Brugada syndrome and early repolarization. In this a benign ERP? or malignant early repolarization abnormalities? We think it is very unlikely that is a Brugada phenocopy

In this case it is necessary additionally to perform

1. IV Ajmaline test
2. ECG-AR
3. Family study (first degree relatives: interrogatory, physical, ECGs)
4. Magnetic resonance image
5. Genetic screening

Ventricular biopsy is not considered mandatory but is recommended especially when it may clarify the nature of dubious findings identified with others test. In approximately 6--10% of survivors of cardiac arrest no cardiac abnormality can be identified despite extensive clinical evaluation. Autopsy data confirm that in a similar percentage of victims of SCD no structural heart disease or or "mors sine materia" can be identified at post mortem evaluation. Incompletely penetrant genetic defects may underlie at least some of these unexplained deaths. (1)

The ERP probably represents part of a spectrum of cardiovascular anomalies related to channelopathies, including BrS, IVF, congenital short QT syndrome and that it may also have a molecular genetic origin of variable penetrance.

The denomination Early Repolarization Pattern is appropriate, since it indicates that it is characterized by a given ECG pattern.

1. **Priori SG, et al Cardiovasc Res. 2001 May;50:218-223.**

Case Report similar

A 20 year-old male, mulatto professional soccer player from Santo André, Sao Paulo, Brazil. He didn't finish the second year in elementary school. Catholic.

Profession: Professional soccer player.

Reason for consultation: Presented to consultation due to two presyncopal episodes and one syncopal episode in the last 30 days. The first two episodes happened during a post-defecation period. Both were preceded by dizziness, nausea and vomiting. The syncopal episodes occurred at rest, with no prodromes.

The third one with express and brief loss of consciousness and sphincter relaxation, at dawn 48 hours ago.

His prior personal medical history was unremarkable and he successfully passed two prior periodical clinical-cardiovascular evaluations (twice a year always normal.).

Pre-competitive examination included 12-lead ECG, echocardiogram, and cardiopulmonary metabolic exercise testing (CMET). All normals. Intense training for the last 3 years.

Familial Background: One uncle from his father's side family died of sudden cardiac death when he was 35 years old. He ignores the cause.

His brother is being seeing by a cardiologist due to "cardiac arrhythmia" in treatment with a cardiologist from the Institute of the Heart from São Paulo (he cannot tell which is the cause).

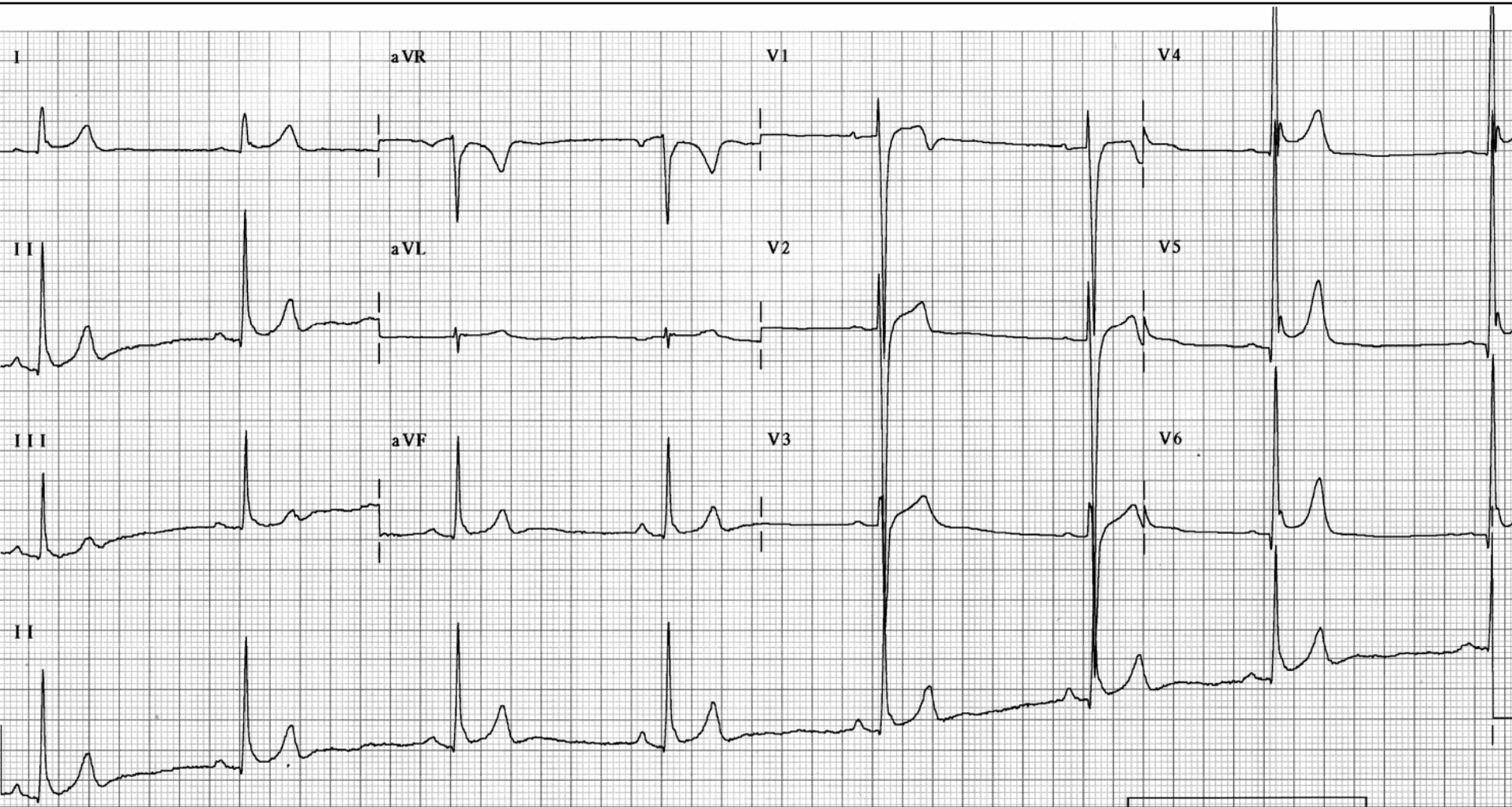
He denies having other relevant background details.

Physical: cardiovascular examination revealed bradycardia at 45 bpm with physiological sinus arrhythmia, blood pressure: 110/70 mmHg. The rest of the physical examination was unremarkable. He denied consuming any type of neither medications nor drugs. No addictions.

His first 12-lead ECG/Vectorcardiogram(VCG) (Fig. 1) showed sinus bradycardia at 44 bpm, P-wave axis of $+60^\circ$; PR interval of 186ms; QRS duration of 111ms; QRS axis at $+63^\circ$, QT interval 427ms and corrected QTc 367ms. There is a notch on the terminal portion of the QRS complex in the left precordial leads, voltage criteria for left ventricular hypertrophy ($SV1 + RV5 > 35$ mm – Sokolow index), prominent J-wave and concave ST-segment elevation in inferior leads, V4, V5 and V6.

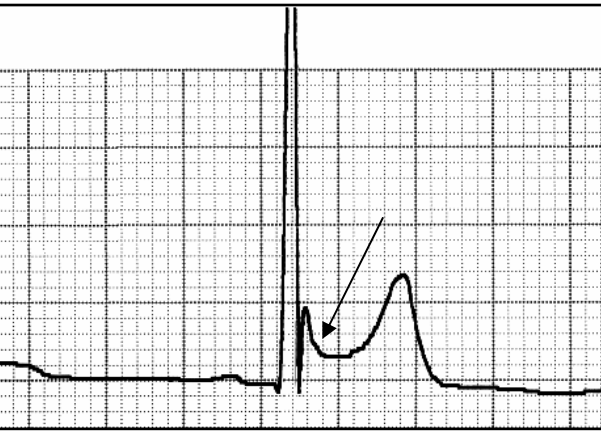
Deep and narrow Q-waves in the left precordial leads V5 and V6. All these features were considered as an Early Repolarization Pattern (ERP).

Name: JVS; **Gender:** Male; **Age:** 20 yo; **Ethnic Group:** Mulatto; **Weight:** 66 Kg;
Height: 1,72 m; **Biotype:** Normoline; **Date:** 11/26/2009 **Profession:** competitive athlete (soccer player).

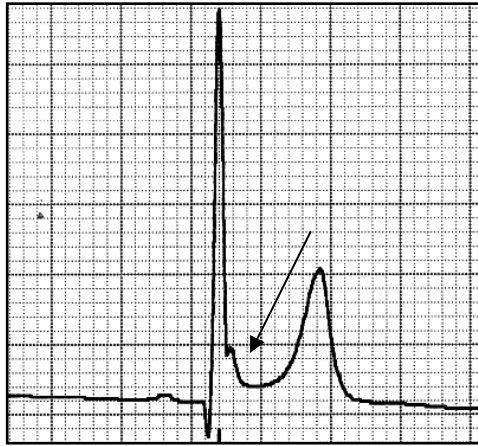

ECG diagnosis: Sinus bradycardia (SB); HR 44bpm, P axis: +60°; PR: 186ms; QRSd: 111ms; QRS axis + 63° QT 427ms; QTc: 367ms.

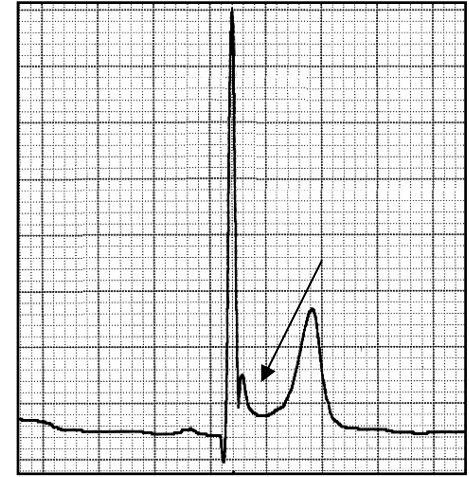Conclusion: SB + Early Repolarization Pattern (ERP): Notching or slurring of the terminal QRS complex, voltage criteria of left ventricular hypertrophy: SV1+ RV5 > 35 mm (Sokolow index). prominent J wave and ST-segment elevation concave to the top ending in a positive T wave from V4 to V6. Precordial greater than limb leads. Relatively deep but narrow q waves in the left precordial leads (V5 and V6.).

V₄

V5

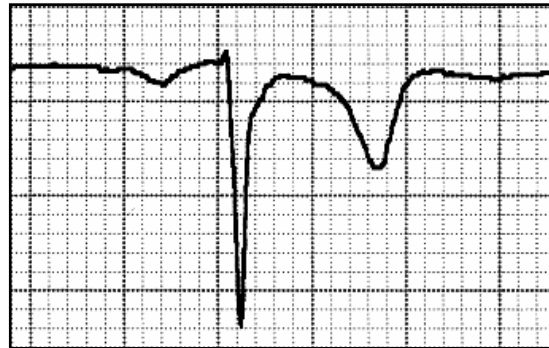


V6



Prominent J wave and ST- segment elevation concave to the top ending in a positive T wave from V₄ to V₆. Notching or slurring morphology of the terminal portion of the R wave (J-wave) that produces a positive hump, known as a J-wave. (Arrows)

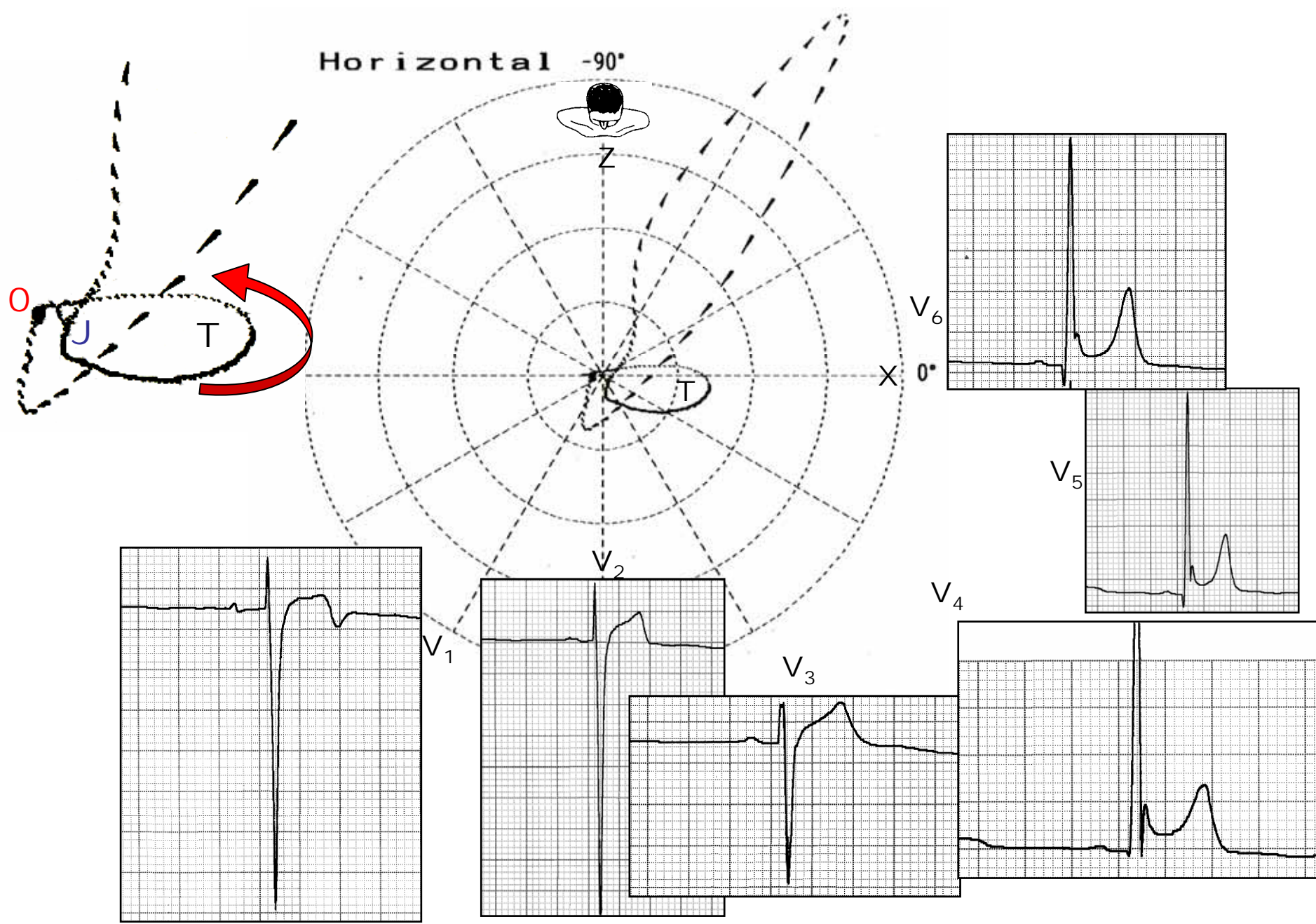
aVR



Eventually, reciprocal ST segment depression confined only in Lead aVR¹ observed in this particular case report.

1. Mehta M, Jain AC, Mehta A. Early Repolarization. Clin Cardiol. 1999 Feb; 22: 59-65.

ECG/VCG CORRELATIONS HORIZONTAL PLANE

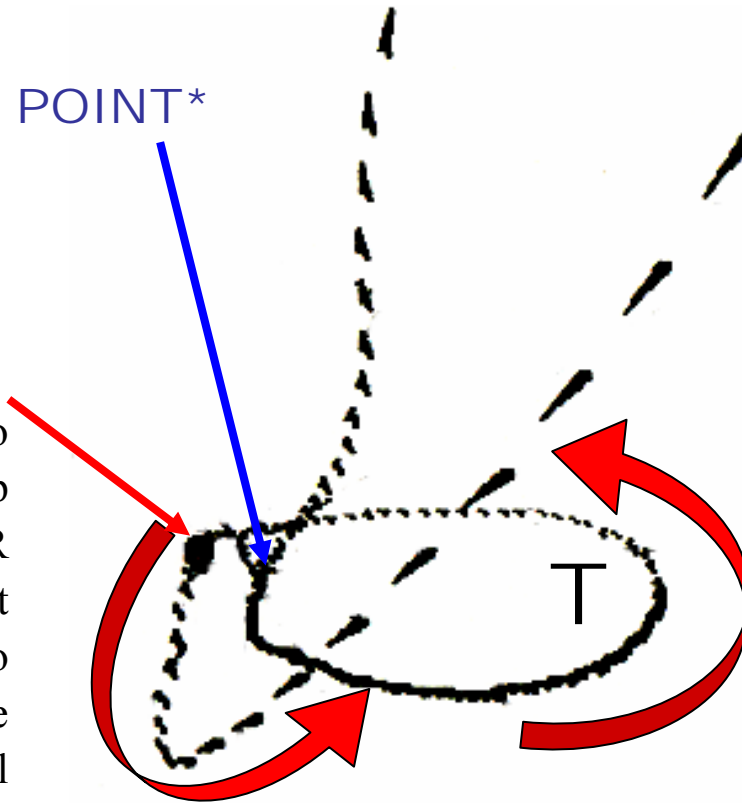


BEGINNING AND END OF QRS LOOP IN HP

0 POINT

It corresponds to the QRS loop onset (because PR segment does not exist.). Also correspond to the end of biatrial chamber activation,

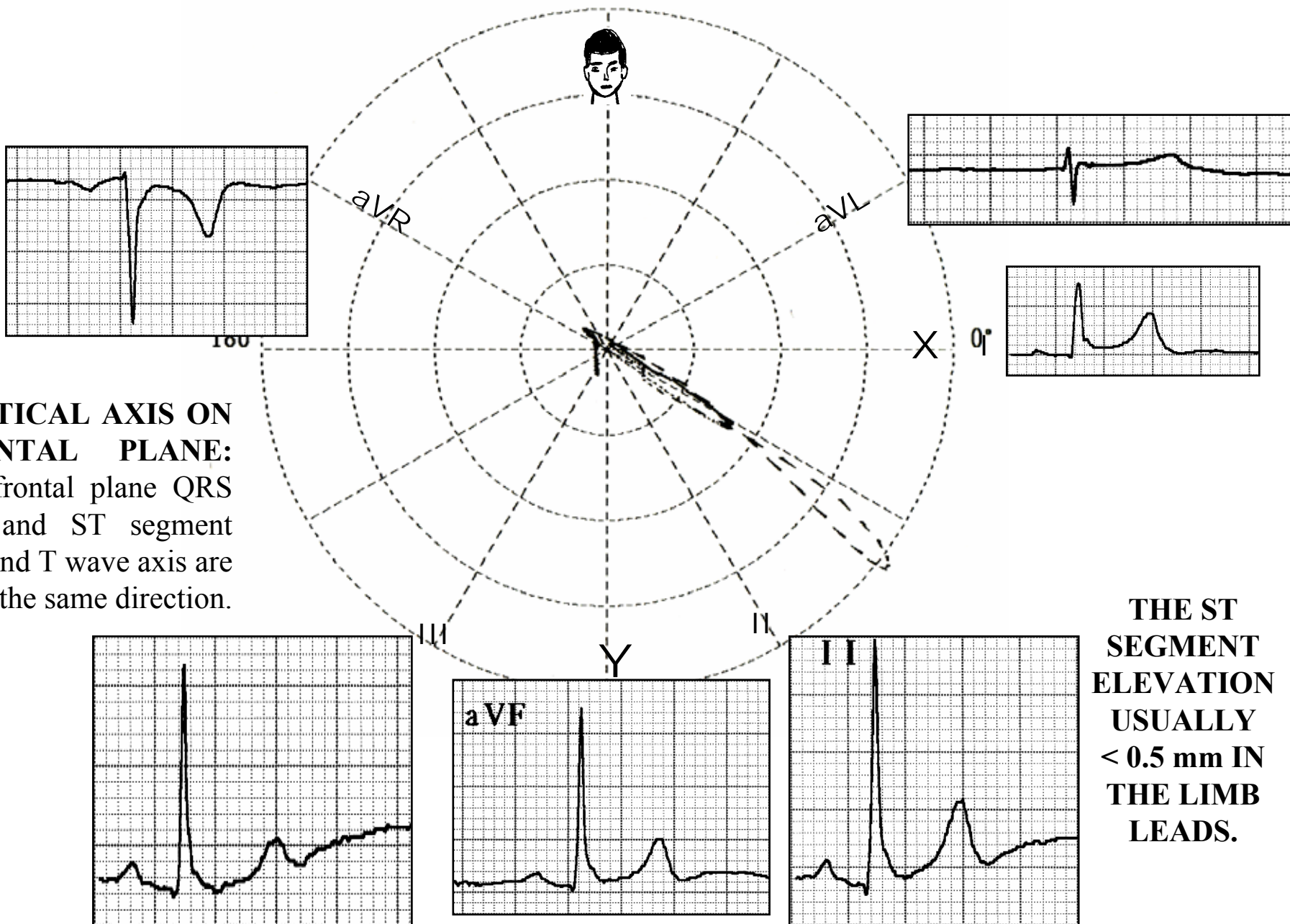
J POINT*



J POINT*: in vectorcardiography, it corresponds to 3 elements: end of ventricular depolarization (QRS loop); beginning of repolarization (ST segment) when it does not present depression or elevation, and T wave onset. In this case **0** point and **J** point are not coincident. In situations where there is depression or elevation of ST segment, the **J** point does not coincide with the **0** point, and the greater or lesser distance between both points indicate the greater or lesser ST segment elevation or depression. The phenomenon is observed in early repolarization pattern, acute phase of myocardial infarction, Prinzmetal variant angina, pericarditis, Brugada syndrome, arrhythmogenic right ventricular dysplasia, etc.

ECG/VCG CORRELATIONS FORNTAL PLANE

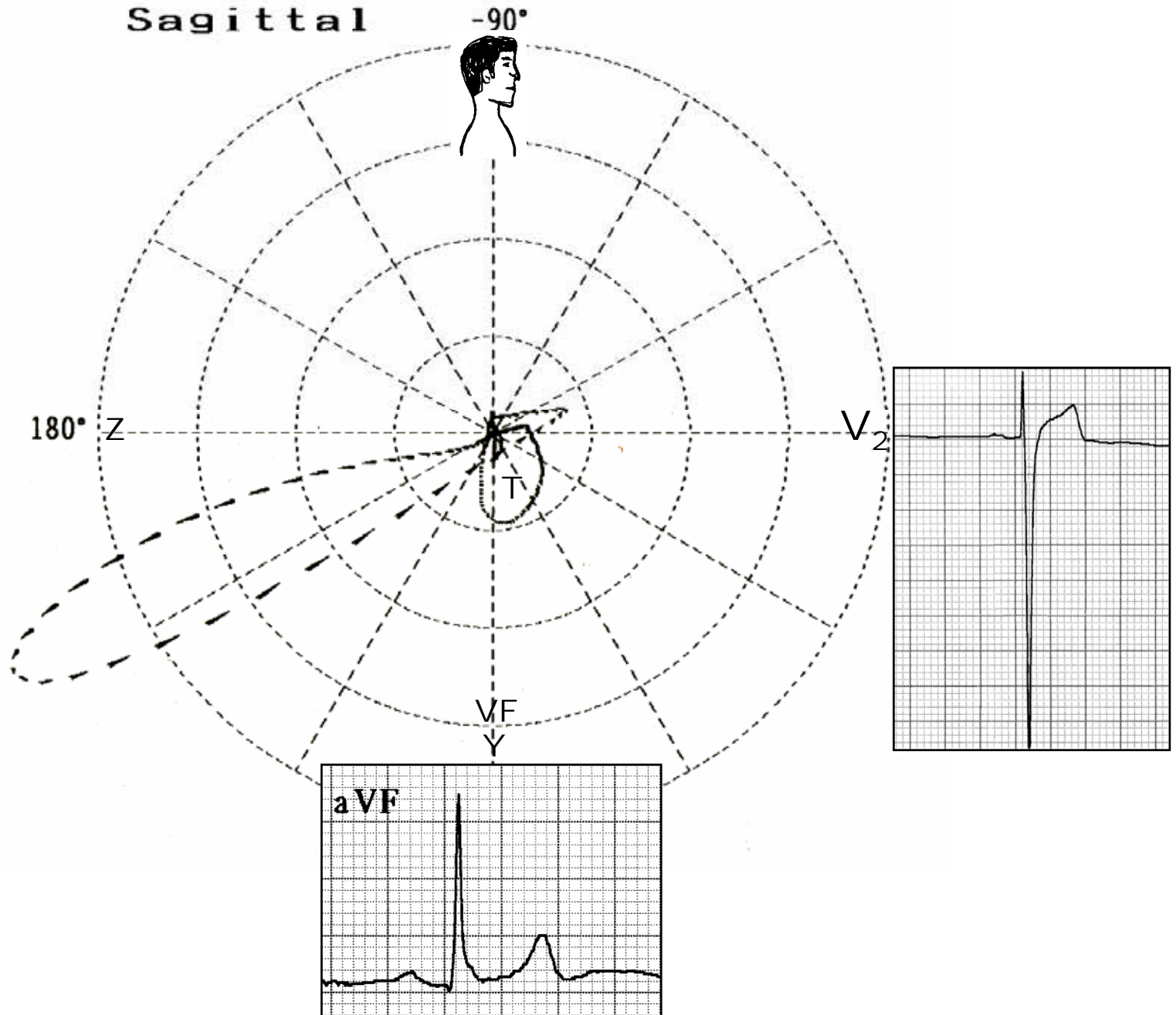
Frontal -90°



**VERTICAL AXIS ON
FRONTAL PLANE:**
The frontal plane QRS
axis and ST segment
axis and T wave axis
are all in the same
direction.

**THE ST
SEGMENT
ELEVATION
USUALLY
< 0.5 mm IN
THE LIMB
LEADS.**

ECG/VCG CORRELATIONS RIGHT SAGITTAL PLANE



A second 12-lead ECG (Fig. 2) performed 72 hours later showing:

- 1) Sinus bradycardia at 44 bpm
- 2) Similar p-wave axis and intervals duration
- 3) Dramatic modification of repolarização pattern in the right precordial leads: A coved-type (type 1) ECG brugada pattern can be distinguished.
- 4) Accentuation of j-waves and st segment elevation across the precordial leads was observed.
- 5) ST segment elevation on avr lead

See next slide

Name: JVS

Gender: Male

Age: 20 yo.

Ethnic Group: Mulatto

Weight: 66 Kg

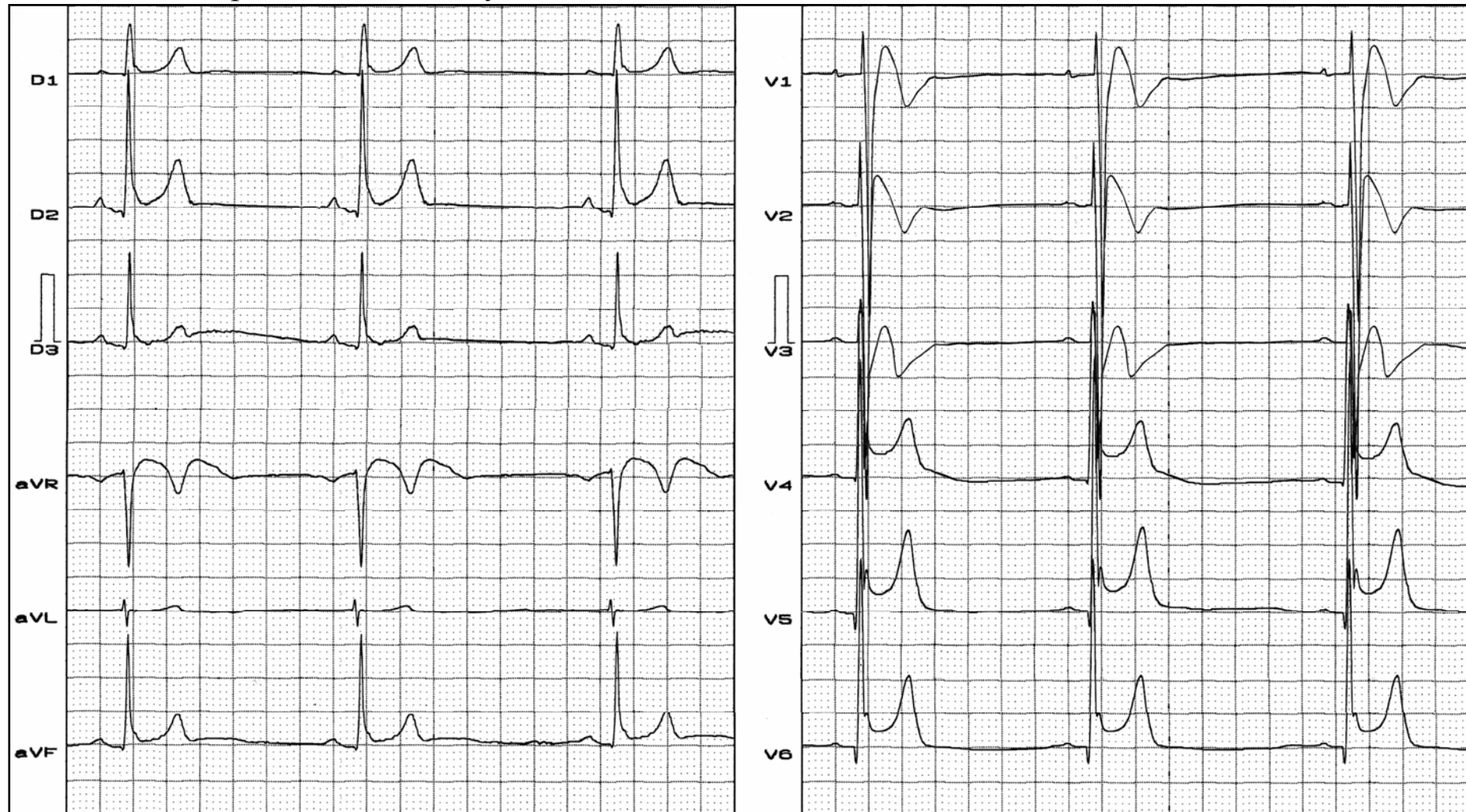
Height: 1,72 m

Biotype: Normoline

Date: 11/29/2009

Profession: Competitive Soccer Player

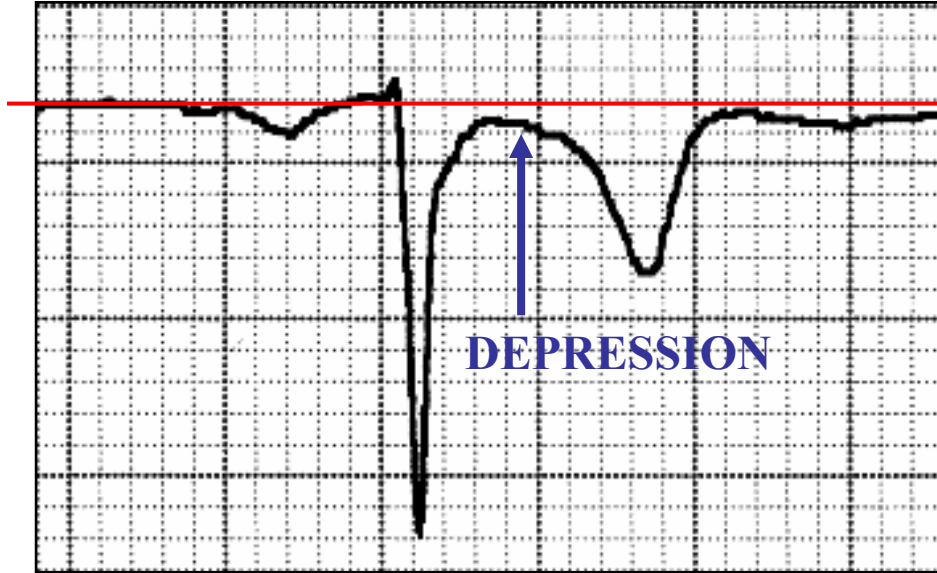
FIGURE 2



ECG diagnosis: Sinus Arrhythmia(SA), sinus bradycardia (SB); HR 44bpm, P axis: +60°; PR: 186ms; QRSd: 111ms; QT 427ms; QTc: 367. Conclusion: SA + SB + Early Repolarization Pattern (ERP). Type 1 Brugada ECG pattern. Dramatic accentuation of J waves across the precordial and limb leads. Transient augmentation of global J waves may be indicative of a highly arrhythmogenic substrate heralding multiple episodes of VF in patients with ERP.

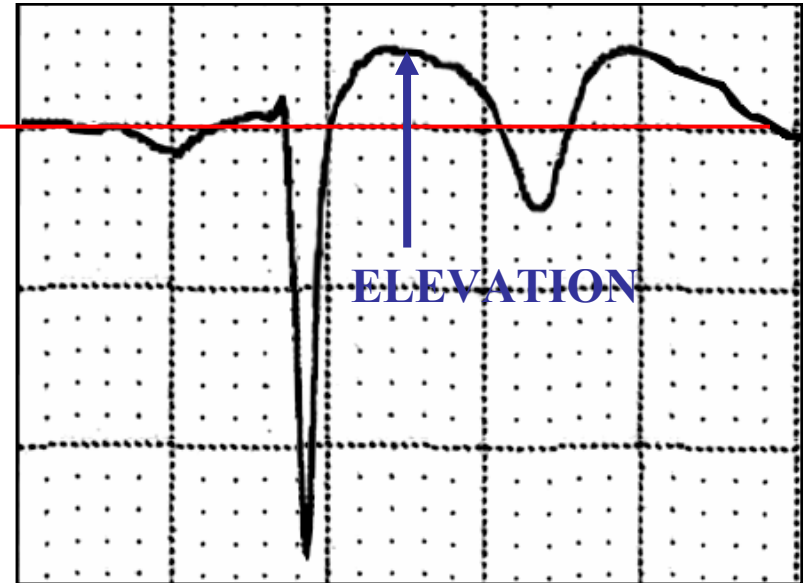
aVR LEAD

11/26/2009



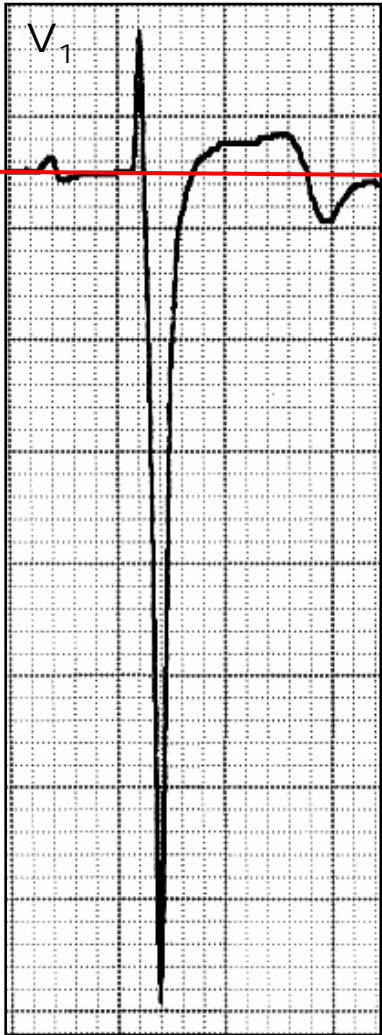
ST SEGMENT DEPRESSION IN aVR = 1mm

11/29/2009

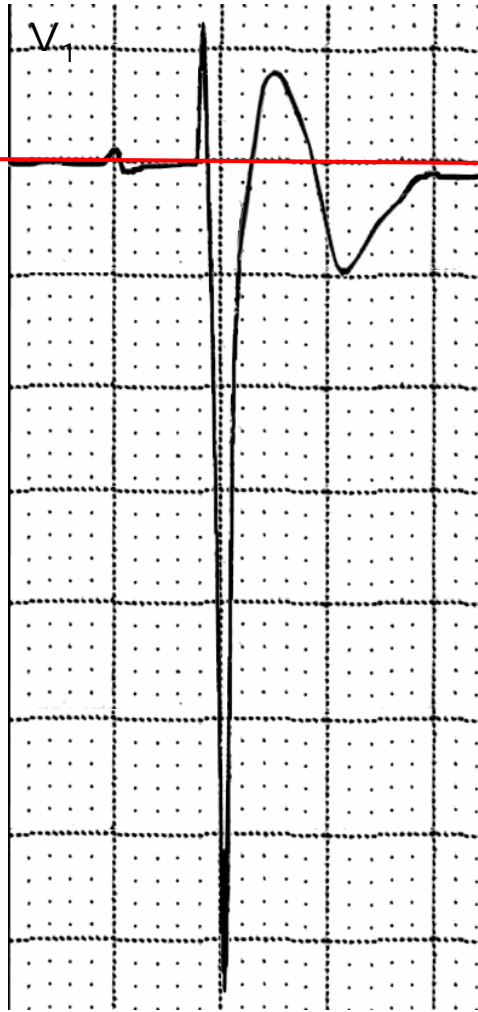


ST SEGMENT ELEVATION IN aVR = 2mm

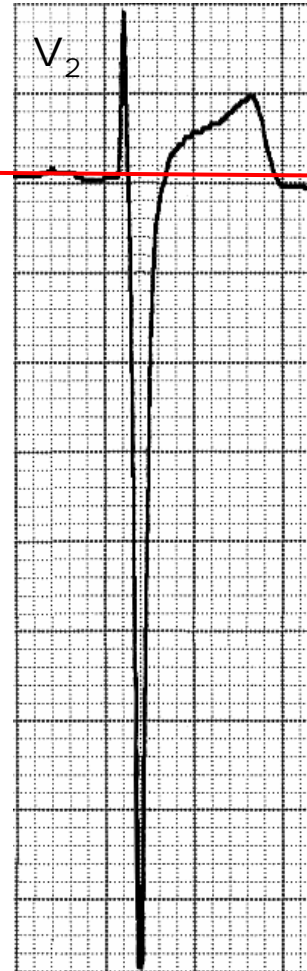
11/26/2009




11/29/2009



11/26/2009

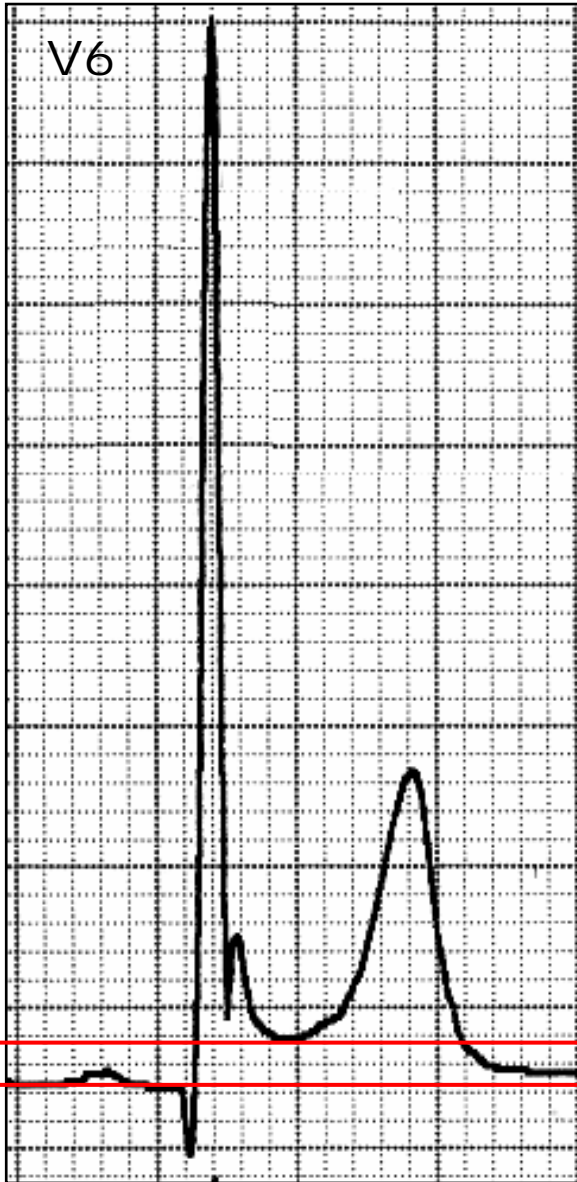


11/29/2009



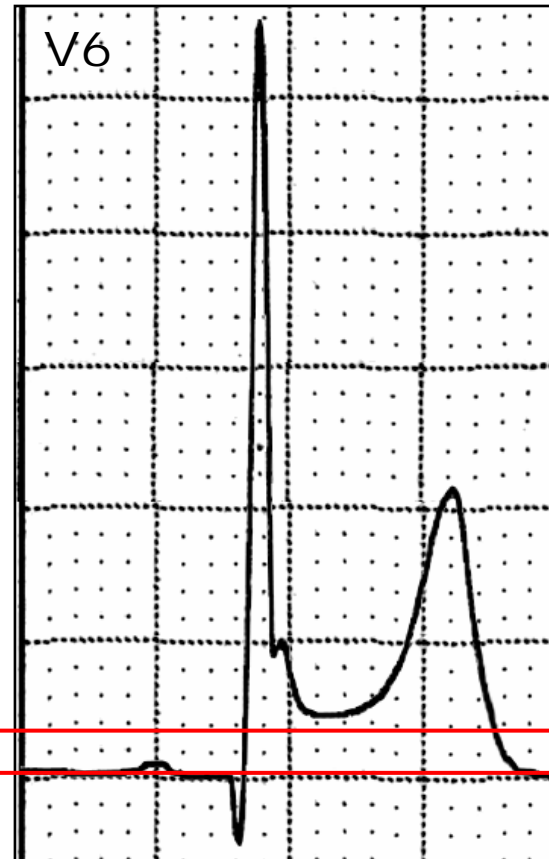
SPONTANEOUS MODIFICATION OF REPOLARIZATION TO TYPE 1 BRUGADA ECG PATTERN

11/26/2009



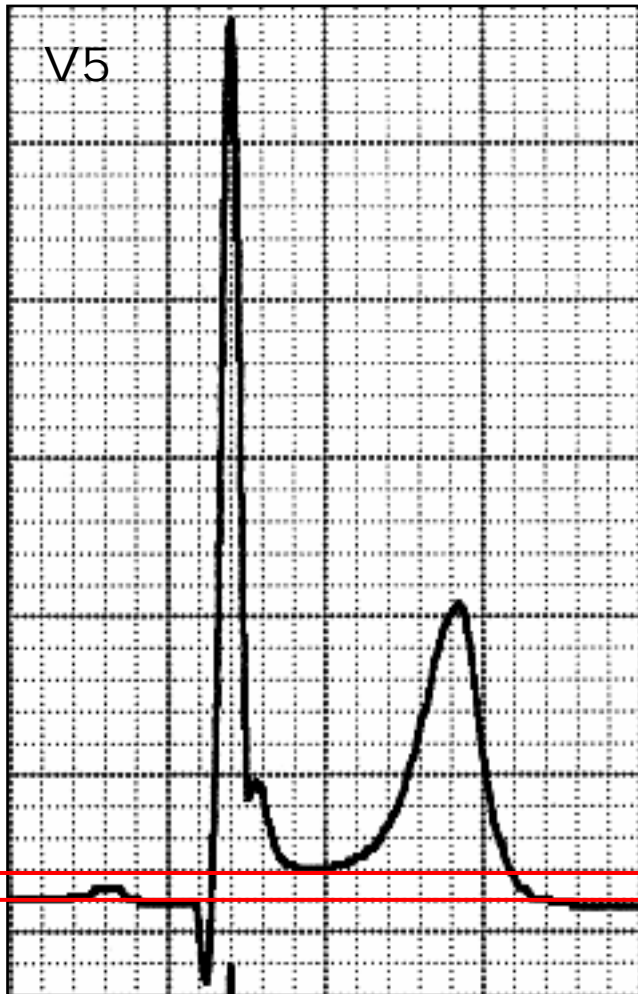
ST segment elevation < 2mm

11/29/2009



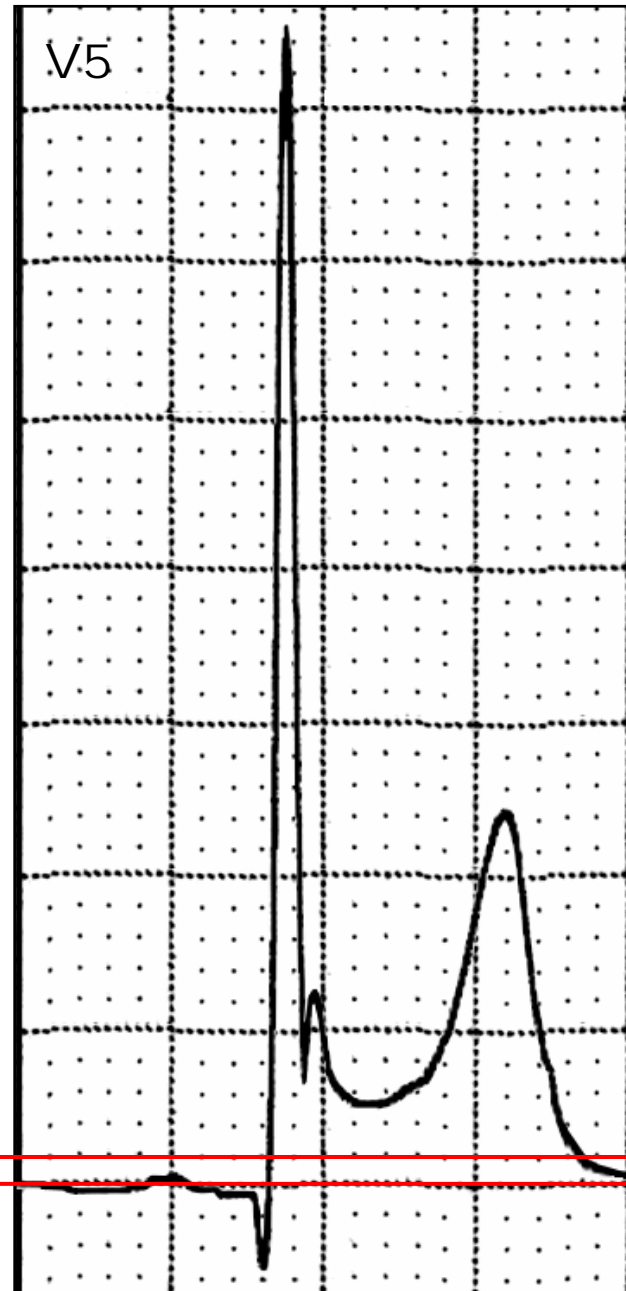
ST segment elevation > 2mm

11/26/2009



ST segment elevation = 1mm

11/29/2009



ST segment elevation = 2,5mm

EARLY REPOLARIZATION PATTERN CONCEPT

DEFINITION: Early Repolarization Pattern (ERP) is a well-recognized Enigmatic idiopathic electrocardiographic phenomenon characterized by notching or slurring morphology of the terminal portion of the R wave (J-wave) that produces a positive hump, known as a J-wave, at the end of the QRS complex and beginning of the ST segment. It is considered to be present when at least two adjacent precordial leads show elevation of the ST segment, with values ≥ 0.1 mV (or 1mm) above baseline followed by concordant tall/ near symmetric (T waves having similarity in shape, ascending and descending ramps speeds).

EPIDEMIOLOGY: ERP occur in 2% to 5% of the population, often in men, young adults, afro-descendents, and competitive athletes and in up to 13%¹ to 48%² of patients presenting with chest pain in the emergency rooms and coronary care units.

There is a distinct J wave and ST segment concave upward in the left precordial leads V4 through V6. The ST elevation is most frequently evident in ECG lead V4. The ST segment elevation is usually ≤ 2 mm (precordial greater than limb leads) and is < 0.5 mm in the limb leads.

Reciprocal ST-segment changes (ST-segment depression) are eventually confined to the unipolar aVR lead. (Absence of reciprocal changes or mirror image).

In ERP vertical QRS axis electrical is the rule: The frontal plane QRS axis, the ST segment axis and T wave axis are all in the same direction.

This ECG pattern has been considered a benign normal ECG variant for over six decades³.

1. Hasbak P, Engelmann MD. Early repolarization. ST-segment elevation as a normal electrocardiographic variant. *Ugeskr Laeger*. 2000; 162: 5928-5929.
2. Brady WJ, Chan TC. Electrocardiographic manifestations: benign early repolarization. *J Emerg Med*. 1999; 17:473-478.
3. Benito B, Guasch E, Rivard L, Nattel S. Clinical and mechanistic issues in early repolarization of normal variants and lethal arrhythmia syndromes. *J Am Coll Cardiol*. 2010 Oct 5; 56: 1177-1186.

MAIN ELECTROCARDIOGRAPHIC FEATURES IN ERP

Heart rate: Predominant sinus bradycardia frequently associated with respiratory sinus arrhythmia.

PR interval: First degree AV block is observed in 5% to 39% among professional athletes. In the non-athlete population it is observed in 0.65% of cases.

QRS axis: Vertical electrical axis is the rule. The frontal plane QRS axis and ST segment axis and T wave axis are all in the same direction.

QRS duration: (90 ± 10 ms) subjects than in age-matched healthy controls (80 ± 10 ms).

QRS morphology: Notching or slurring of the terminal QRS complex.

Prominent, relatively deep but narrow q waves may appear in the left precordial leads.

QRS voltage: Eventually, voltage criteria of LVH are observed in male competitive athletes: $SV1 + RV5 > 35$ mm (Positive Sokolow index). High QRS voltage is more frequent in male athletes, but its correlation with LVH is low. Voltage decreases after deconditioning is slow. The distinction between the physiological athlete's heart and pathological conditions has critical implications for professional athletes. An abrupt transition may occur from right-oriented complexes to left-oriented complexes in the precordial leads, secondary to counterclockwise rotation on precordial leads. About two-thirds of clockwise rotation and counterclockwise rotation could be attributed to the septal angle by anatomical rotation of the heart in one plane around the long axis, but other factors appear to be responsible for such ECG findings in the remaining one-third of cases. Relatively higher positions of the precordial ECG leads, as observed in the vertical heart, appeared to be responsible for clockwise rotation in some patients, and left septal fascicular block is suspected to be responsible for counterclockwise rotation in others patients.

J-point elevation: Notching, irregular or slurring contour of the terminal QRS complex (J point). Variant of Osborn wave is seen in ERP.

ST segment: Widespread ST segment elevation; (precordial greater than limb leads) The characteristic ST segment is elevated, upward, concave, confined more frequently in precordial leads, with reciprocal depression only in aVR. The concavity is observed at the initial up-sloping portion of ST segment or upwardly concave ST segment morphology. Unfortunately, concave ST morphology cannot be used to rule out ST elevation from AMI with left anterior descending coronary occlusion because it is common in these circumstances. The ST elevation is most frequently evident in ECG lead V4. There is a distinct J wave and ST segment in the left precordial leads V4 through V6. The ST elevation in ERP is usually < 2 mm (but can rarely be > 5 mm) in the precordial leads and the greatest ST elevation is usually seen in the mid-to-left precordial leads.

The ST segment elevation is usually < 0.5 mm in the limb leads.

T wave characteristics. Concordant T waves of large amplitude (prominent, matching T waves), typical pseudo-asymmetrical ('symmetroid') or slightly asymmetrical, matching T waves often of large amplitude, upright, tall and peaked, most conspicuously from V2 to V4 or V5, sometimes seen in leads DII, DIII and aVF as a rule. T waves may appear as of large amplitude, "peaked" or pointed, symmetric and matching. Vagotonic or high T wave voltages followed by U waves are frequent when sinus bradycardia is present. Tall, positive and symmetric or symmetroid T waves are not only seen occasionally in the very early stages of MI, but also in hyperkalemia and in ERP sinus bradycardia.

QT intervals:

QT maximum: The maximum Q-onset-T-end interval. This parameter is higher in ERV subjects than in normal controls.

QTp maximum: maximum Q-onset-T-peak interval. This parameter is higher in ERV subjects than in age-matched healthy controls.

Rate-corrected QTc maximum: This parameter is lower in ERP subjects than in age-matched healthy controls.

QTpc maximum: This parameter is lower in ERV subjects than in age-matched healthy controls.

U wave: because bradycardia U waves are frequent, in ERV they are best observed in the V3 lead. U waves are frequent when sinus bradycardia is present.

Other ECG characteristics of ERP

Relative temporal stability of the ST segment and T wave pattern is observed.

Reciprocal changes are not seen in ERP. There are no evolutionary short-term changes in the ST segment and T waves; and Q waves do not appear.

Discussions:

Early Repolarization Pattern (ERP) or Early Repolarization Variant (ERV) is an enigmatic electrocardiographic phenomenon, characterized by prominent J wave and ST-segment elevation in multiple leads.

Recently, there has been renewed interest in ERP because of similarities to the arrhythmogenic Brugada syndrome (BrS). Not much is known about the epidemiology of ERP and several studies have reported that this condition is associated with a good prognosis.

Both ERP and BrS exhibit some similarities including the ionic underlying mechanism, the analogous responses to changes in heart rate and autonomic tone, sympathicomimetics (isoproterenol test) as well as its response to sodium channel and beta-blockers. These observations raise the hypothesis that ERP may be not as benign as traditionally believed. Additionally, there are documents showing that ST-segment height in the man is greatly influenced by central sympathetic nervous activity, both at baseline and during physiologic and pharmacological stress. Central sympathetic dysfunction regularly results in multilead ST-segment elevation or J wave that decreases or below isoelectric baseline during low dose isoproterenol infusion. An early repolarization pattern in the inferior leads of a standard electrocardiogram is associated with an increased risk of death from cardiac causes in middle-aged subjects¹.

POSSIBLE SIMILARITIES BETWEEN ERV AND BrS

- More frequent in males
- Both occur more frequently in young adults and in individuals without apparent structural heart disease
- Both may influence just the V1-V2 leads: Rarely (9%), can ST elevation be observed in ERP only in the right precordial leads: V1-V2, or in the inferior ones².

1. Tikkanen JT, Anttonen O, Juntila MJ, Aro AL, Kerola T, Rissanen HA, Reunanen A, Huikuri HV. Long-Term Outcome Associated with Early Repolarization on Electrocardiography. *N Engl J Med.* 2009 Nov 16. [Epub ahead of print]
2. Hasbak P, Engelmann MD. Early repolarization. ST-segment elevation as a normal electrocardiographic variant. *Ugeskr Laeger.* 2000; 162: 5928-5929.

When ST elevation is normal, it can reach up to 3 mm in V2-V3, especially in young people. In those individuals over 40 years, it seldom exceeds 2 mm. Both can show incomplete RBBB pattern or right bundle branch conduction disorder: in BrS, it can present atypical features, RBBB-like and of the saddle type by exclusive elevation of the J point. S wave with delay in the left leads: DI, aVL, V5 and V6, could be absent as it is to be expected in a classic RBBB.

The elements considered as typical in BrS are: 1) elevation of the terminal part of QRS (prominent J wave); 2) elevated and descending ST, not related to lesion of ischemic (idiopathic) injury; 3) negative T wave in the right precordial leads; 4) normal QTc or near normal; 5) Eventually absence of final delay in left leads as it would be expected in a classic RBBB¹.

In ERV, when associated to athlete's heart, QRS can present a moderate extension (100 ms to 110 ms) in 15% of the cases, which in nonathlete, normal population, in a 2.4% is called outflow tract hypertrophy. In this case r' does not exceed the 5 mm and is lower than S in the same lead: rSr';

Both may improve repolarization during the stress test with use of isoproterenol;

Both respond to a shortening of AP phase 2 in a part of ventricular thickness, and intensification of fast repolarization notch (phase 1) mediated by transmural dispersion of ventricular repolarization by a larger notch in the *Ito* channel².

The alteration of the *Ito* and ICa^{2+} -L channels in BrS and in ERP are the electrophysiologic substrate that explains the J point and ST segment elevation, because they cause the intensified notch in phase 1 and suppression in phase 2 duration in the epicardium and in the endocardium of ventricular wall thickness.

1. Hiss RG, Lamb LE. Electrocardiographic findings in 122,043 individuals. *Circulation* 1962; 25:947-961.
2. Antzelevitch Ch, Xin Yan G, Shimuzi W, et al. Electrical heterogeneity, the ECG, and Cardiac Arrhythmias. In Zipes DP, Jalife J *Cardiac Electrophysiology From Cell to Bedside*, Third Edition. W.B. Saunders Company. 2000. Chapter 26 p: 222-238

ELEMENTS FOR DIFFERENTIAL DIAGNOSIS BETWEEN ERP AND BrS

I) Family background

ERP: negative

BrS: frequently positive

II) Ethnic Group

ERP: predominantly in African descendents⁽¹⁾, or equally common in all races⁽²⁾

BrS: predominantly in Asian group (58%) and Caucasian people⁽³⁾

III) Gender

ERP: male gender predominance.

BrS: great predominance in the male gender (male/female ratio – 8:1 in non Asian and 10:1 in Asian people).

IV) Response to IC group antiarrhythmic agents

BrS: flecainide, used in a 10 mg/Kg dosage in 10 minutes, increases ST elevation and QRS duration in a more significant way in patients with BrS than in individuals without the entity, and only in those it triggers ventricular extrasystoles⁽⁴⁾.

ERP: it can induce a pattern similar to BrS; however, the degree of ST elevation caused by the drug is much higher in patients with BrS than in patients without the disease.

1. Grusin H. Peculiarities of the African's electrocardiogram and the changes observed in serial studies. *Circulation* 1954; 9: 860-867.
2. Mehta M, Jain AC, Mehta A. Early Repolarization. *Clin Cardiol.* 1999 Feb;22:59-65.
3. Nademanee K, Veerakul G, Nimmannit S, Chaowakul V, Bhuripanyo K, Likittanasombat K, Tunsanga K, Kuasirikul S, Malasit P, Tansupasawadikul S, Tatsanavivat P. Arrhythmogenic marker for the sudden unexplained death syndrome in Thai men. *Circulation.* 1997; 96:2595-2600.
4. Shimizu W, Antzelevitch C, Suyama K, Kurita T, Taguchi A, Aihara N, Takaki H, Sunagawa K, Kamakura S. Effect of sodium channel blockers on ST segment, QRS duration, and corrected QT interval in patients with Brugada syndrome. *J Cardiovasc Electrophysiol* 2000; 11:1320-1329.

BrS patients with Inferior and lateral ECG repolarization abnormalities have longer baseline PR intervals⁽¹⁾.

Both an S wave width ≥ 80 ms in V1 and ST elevation ≥ 1.8 mm in V2 are highly specific indicators of VF and criteria for high-risk BrS⁽²⁾.

There are several references in literature to patients with elevation of the J point and ST segment convex to the top or straight descendent in inferior leads (Brugada sign) or concomitantly ST-segment elevation in the right precordial and inferior leads II, III, and aVF⁽³⁾ in absence of hypothermia, ischemia or electrolytic disorders, which we call “atypical Brugada pattern”, atypical BrS, variant BrS, or BrS variant or idiopathic VF (a variant of the BrS with ST-segment elevation in inferior leads⁽⁴⁾).

Pilsicainide may induce PVCs and PVT in atypical BrS and the infusion of isoproterenol suppress the arrhythmias and normalize the ST-segment elevation⁽⁵⁾.

1. Sarkozy A, Chierchia GB, Paparella G, Boussy T, De Asmundis C, Roos M, Henkens S, Kaufman L, Buyl R, Brugada R, Brugada J, Brugada P. Inferior and lateral electrocardiographic repolarization abnormalities in Brugada syndrome. *Circ Arrhythm Electrophysiol.* 2009 Apr; 2:154-161.
2. Atarashi H, Ogawa S, For The Idiopathic Ventricular Fibrillation Investigators. New ECG Criteria for High-Risk Brugada Syndrome. *Circ J* 2003 Jan; 67: 8-10.
3. Lombardi F, Potenza S, Beltrami A, Verzoni A, Brugada P, Brugada R. Simultaneous ST-segment elevation in the right precordial and inferior leads in Brugada syndrome. *J Cardiovasc Med (Hagerstown).* 2007; 8: 201-204.
4. Letsas KP, Efremidis M, Pappas LK, Gavrielatos G, Markou V, Sideris A, Kardaras F. Early repolarization syndrome: is it always benign? *Int J Cardiol.* 2007;114: 390-392.
5. Chinushi M, Izumi D, Furushima H, Watanabe H, Aizawa Y. Multiple premature beats triggered ventricular arrhythmias during pilsicainide infusion in a patient with inferior ST-segment elevation. *Pacing Clin Electrophysiol.* 2006; 29: 1445-1448.

Potet et al.⁽¹⁾ identified a G752R mutation on SCN5A that produced ST segment elevation and prominent J wave in leads II, III, and aVF. The authors provide genetic demonstration that Brugada ECG anomalies related to a unique SCN5A mutation can be observed either in the inferior or the right precordial leads.

The early repolarization pattern in inferolateral leads is not an uncommon finding in BrS, and this pattern is not associated with a worse outcome in subjects with BrS⁽²⁾.

The spontaneous ERP occurred more frequently among patients with BrS than in 283 family members not having BrS (11% versus 6%, P=0.03). Class I antiarrhythmic drug administration provoked inferior-lateral coved Brugada pattern in 13 patients with BrS. These patients had longer baseline PR intervals and Class I antiarrhythmic drug induced QRS interval prolongation (108 to 178 versus 102 ms to 131 ms, P<0.001). In 3 patients, the Class I antiarrhythmic drug provoked coved Brugada pattern only present in the inferior leads. Inferior-lateral ERP occurs spontaneously relatively frequently in BrS. These patients have a more severe phenotype. Class I antiarrhythmic drug administration provokes inferior-lateral coved Brugada pattern in 4.6% of patients. The Class I antiarrhythmic drug exceptionally provoked coved Brugada pattern only observed in the inferior leads⁽³⁾.

- 1. Potet F, Mabo P, Le Coq G, et al. Novel brugada SCN5A mutation leading to ST segment elevation in the inferior or the right precordial leads. J Cardiovasc Electrophysiol 2003; 14:2000-2003.**
- 2. Letsas KP, Sacher F, Probst V, Weber R, Knecht S, Kalusche D, Haïssaguerre M, Arentz T. Prevalence of early repolarization pattern in inferolateral leads in patients with Brugada syndrome. Heart Rhythm. 2008 Dec; 5: 1685-1689.**
- 3. Sarkozy A, Chierchia GB, Paparella G, Boussy T, De Asmundis C, Roos M, Henkens S, Kaufman L, Buyl R, Brugada R, Brugada J, Brugada P. Inferior and lateral electrocardiographic repolarization abnormalities in Brugada syndrome. Circ Arrhythm Electrophysiol. 2009 Apr; 2:154-161.**

Type 1 ECG Brugada pattern in the peripheral leads was observed in 4.2% of patients during ajmaline test (10.3% of positive tests) and was associated with longer QRS and greater QTc prolongation compared with the rest of the patients¹.

Atypical Brugada Syndrome or IVF with J waves in inferior, lateral or inferior lateral leads and Familial Idiopathic Ventricular Fibrillation and BrS

Several mutations in genes SCN5A, KCNJ8, DPP6, SCN3B, and CACNA2D1 had been identified

1. On SCN5A gene^{2;3}. Observation: We do not believe that SCN5A should be attributed to IVF because this report clearly shows conduction defects (as expected), so this is not IVF but conduction delay at different levels in the heart.

2. On KCNJ8 gene^{4;5}: Missense variant in exon 3 (NC-000012) of the KCNJ8 gene, a subunit of the $K_{(ATP)}$ channel^{2;3}. Genomic DNA sequencing of K(ATP) channel genes showed missense variant in exon 3 (NC_000012) of the KCNJ8 gene, a subunit of the $K_{(ATP)}$ channel, conferring predisposition to dramatic repolarization changes and ventricular vulnerability.

1. Batchvarov VN, Govindan M, Camm AJ, Behr ER. Brugada-like changes in the peripheral leads during diagnostic ajmaline test in patients with suspected Brugada syndrome. *Pacing Clin Electrophysiol.* 2009 Jun;32:695-703
2. Potet F, Mabo P, Le Coq G, Probst V, Schott JJ, Airaud F, Guihard G, Daubert JC, Escande D, Le Marec H. Novel Brugada SCN5A mutation leading to ST segment elevation in the inferior or the right precordial leads. *J Cardiovasc Electrophysiol.* 2003; 14: 200-203.
3. Akai J, Makita N, Sakurada H, Shirai N, Ueda K, Kitabatake A, Nakazawa K, Kimura A, Hiraoka M. A novel SCN5A mutation associated with idiopathic ventricular fibrillation without typical ECG findings of Brugada syndrome. *FEBS Lett.* 2000 Aug 11; 479: 29-34.
4. Haïssaguerre M, Derval N, Sacher F, Jesel L, Deisenhofer I, de Roy L, et al. Sudden cardiac arrest associated with early repolarization. *N Engl J Med.* 2008 May 8; 358:2016-2023.
5. Haïssaguerre M, Sacher F, Nogami A, Komiya N, Bernard A, Probst V, et al. Characteristics of recurrent ventricular fibrillation associated with inferolateral early repolarization: role of drug therapy. *J Am Coll Cardiol.* 2009 Feb 17; 53: 612-619.

On DPP6 gene¹: Dipeptidyl aminopeptidase-like protein 6, locus on chromosome 7q26, Voltage-gated potassium channels, OMIM:126141. The ECG shows rapid PVT. Monomorphic PVCs with very short coupling intervals. The PVC (302 +/- 52 msec) within 40 msec of the peak of the preceding. Absence of T wave. Pause-dependence.

Valdivia et al² reported a case with IVF and a novel mutation in the SCN3B-encoded sodium channel beta subunit Navbeta3 that causes a loss of function of Nav1.5 channels in vitro and provides molecular and cellular evidence implicating mutations in Navbeta3 as a cause of IVF. Mutation in this SCN3B gene causes also BrS type 7³.

L-type calcium channel (LTCC) mutations have been associated with BrS, SQTS, and Timothy syndrome (LQT8). Little is known about the extent to which LTCC mutations contribute to the J-wave syndromes associated with SCD. Mutations in the LTCCs are detected in a high percentage of probands with J-wave syndromes associated with inherited cardiac arrhythmias, suggesting that genetic screening of Ca(v) genes may be a valuable diagnostic tool in identifying individuals at risk. Burashnikov et al⁴ identify CACNA2D1 as a novel BrS susceptibility gene and CACNA1C, CACNB2, and CACNA2D1 as possible novel ERS susceptibility genes⁴.

- 1. Alders M, Koopmann TT, Christiaans I, Postema PG, Beekman L, Tanck MW, et al. Haplotype-sharing analysis implicates chromosome 7q36 harboring DPP6 in familial idiopathic ventricular fibrillation. Am J Hum Genet. 2009 Apr; 84: 468-476.**
- 2. Valdivia CR, Medeiros-Domingo A, Ye B, Shen WK, Algiers TJ, Ackerman MJ et al. Loss-of-function mutation of the SCN3B-encoded sodium channel {beta}3 subunit associated with a case of idiopathic ventricular fibrillation. Cardiovasc Res. 2010 Jun 1; 86: 392-400.**
- 3. Hu D, Barajas-Martinez H, Burashnikov E, Springer M, Wu Y, Varro A, et al. A mutation in the beta-3 subunit of the cardiac sodium channel associated with Brugada ECG phenotype. Circ. Cardiovasc. Genet. 2009; 2: 270-278.**
- 4. Burashnikov E, Pfeiffer R, Barajas-Martinez H, Delpón E, Hu D, Desai M, et al. Mutations in the cardiac L-type calcium channel associated with inherited J-wave syndromes and sudden cardiac death. Heart Rhythm. 2010 Dec;7:1872-1882.**

From a multicenter cohort of 122 patients (90 male, age 37 +/- 12 years) with IVF and ERP in the inferolateral leads.

Haïssaguerre et al¹ selected all patients with more than 3 episodes of VF (multiple) including those with electrical storms (≥ 3 VF in 24 h). Multiple recurrences of VF occurred in 27% of patients with ERP and may be life threatening. Isoproterenol in acute cases and quinidine in chronic cases are effective antyarrhythmic drugs. The last one is necessary associated to ICD.

The so-called atypical BrS is characterized by ECG abnormalities of the J wave, and ST-segment elevation appeared in the inferior and/or lateral leads. The ERP in inferolateral leads is not an uncommon finding in BrS². There is a high incidence of the ERP confined in inferolateral leads in patients with IVF. The ECGs have an elevation of the QRS-ST junction of at least 0.1 mV from baseline in the inferior or lateral lead, manifested as QRS slurring or notching. Among patients with a history of IVF, there is an increased prevalence of ERP.

- 1. Haïssaguerre M, Derval N, Sacher F, Jesel L, Deisenhofer I, de Roy L, Pasquié JL, Nogami A, Babuty D, Yli-Mayry S, De Chillou C, Scanu P, Mabo P, Matsuo S, Probst V, Le Scouarnec S, Defaye P, Schlaepfer J, Rostock T, Lacroix D, Lamaison D, Lavergne T, Aizawa Y, Englund A, Anselme F, O'Neill M, Hocini M, Lim KT, Knecht S, Veenhuyzen GD, Bordachar P, Chauvin M, Jais P, Coureau G, Chene G, Klein GJ, Clémenty J. Sudden cardiac arrest associated with early repolarization. *N Engl J Med.* 2008 May 8; 358:2016-2023.**
- 2. Letsas KP, Sacher F, Probst V, Weber R, Knecht S, Kalusche D, Haïssaguerre M, Arentz T. Prevalence of early repolarization pattern in inferolateral leads in patients with Brugada syndrome *Heart Rhythm.* 2008 Dec;5:1685-1689.**

Because a contingent percentage has not yet been well established, it has been suggested that BrS constitutes the same entity in a large number of IVF diagnosed cases since they have common clinical features:

- 1. BOTH ARE MORE FREQUENT IN MEN.**
- 2. BOTH HAPPEN IN MIDDLE-AGE PEOPLE.**
- 3. BOTH OCCUR IN APPARENT STRUCTURALLY NORMAL HEARTS¹**
- 4. BOTH CAN AFFECT THE SAME GENE (SCN5A).**
- 5. BOTH AFFECT EVENTUALLY THE SAME LOCUS (3p24-p21).**

Wellens et al² has pointed out that in order to be accurate about such a percentage, it is important to define the diagnostic criteria used to classify BrS in IVF patients. Curiously, the so-called Idiopathic VT in apparently healthy hearts, without structural heart disease and primary electrical disease, also affects the 3p21 locus, but not 3p24, and the gene is different: GNA1².

Survivors of SCD by VF without structural heart disease and a normal coronary angiogram are often diagnosed with IVT/IVF³.

A careful analysis of the ECG is essential in the differential diagnosis of this type of apparently unexplained SCD because intermittent or permanent RBBB with J point and ST-segment elevation in leads V1 to V3 is now classified as BrS.

- 1. Goethals P, Debruyne P, Saffarian M: Drug-induced Brugada syndrome Acta Cardiol1998; 53:157-60**
- 2. Wellens HJJ, Rodriguez LM, Smeets JL: Ventricular tachycardia in structural normal hearts. In Zipes DP, Jalife J, Editors: Cardiac Electrophysiology from cell to bedside, Philadelphia 1995, WB Saunders.**
- 3. Chen Q, Kirsch GE, Zhang D, Brugada R, Brugada P, Brugada J, et al. Genetic basis and molecular mechanisms for idiopathic ventricular fibrillation. Nature 1998;392: 293-296.**

DIAGNOSTICS TRACKS TO DIFFERENTIATE BENIGN ERP FROM MALIGNANT EARLY REPOLATIZATION ABNORMALITIES

	BENIGN ERP	MALIGNANT EARLY REPOLARIZATION ABNORMALITIES
Family history of unexplained SCD in young relatives(<45yo)	Absent	Possible however infrequent ¹ .
Personal history	Asymptomatic	Asymptomatic, repetitive syncope episodes or recovered of cardiac arrest
Left precordial terminal QRS notching	Less prevalent	More prevalent ² .
<p>ST/T ratio in lead V6 calculated by dividing the millimeters of ST-segment elevation by the millimeters to the tallest point of the T wave. Each value is measured from the isoelectric point.</p>	<0.25 ³	Non-tested

1. **Viskin S, Belhassen B. Idiopathic ventricular fibrillation American Heart Journal 1990; 120: 661-671.**
2. **Tikkanen JT, Anttonen O, Junttila MJ, Aro AL, Kerola T, Rissanen HA, Reunanen A, et al. Long-term outcome associated with early repolarization on electrocardiography. N Engl J Med. 2009 Dec 24;361: 2529-2537.**
3. **Ginzton LE, Laks MM. The differential diagnosis of acute pericarditis from the normal variant: new electrocardiographic criteria. Circulation. 1982 May; 65: 1004-1009.**

ST-segment elevation shape	Concave upward	Convex upward. J waves are present in $\approx 30\%$ IVF patients ¹ . Early repolarization is significantly prevalent in the subjects after cardiac arrest, (present in 31% of those resuscitated). Eventually "Lambda-wave" ^{2,3} .
J-point elevation and ST-segment degree	Usually < 2 mm $< 0,5$ mm in limb leads	Frequent > 2 mm. J-point elevation > 2 mm in inferior leads is associated with an increased risk of death from cardiac causes in middle-aged subjects ³ .
T wave characteristic	Positive large T wave from V_2 to V_4 or V_5 : Concordant	Frequent negative discordant
Reciprocal ST-segment changes (Mirror image)	Absent. With exception aVR ⁵ .	Frequently Present ³ .

1. **Viskin S. Idiopathic ventricular fibrillation "Le Syndrome d'Haïssaguerre" and the fear of J waves. J Am Coll Cardiol. 2009 Feb 17; 53: 620-622.**
2. **Gussak I, Bjerregaard P, Kostis J. Electrocardiographic "lambda" wave and primary idiopathic cardiac asystole: a new clinical syndrome? J Electrocardiol. 2004 Apr; 37: 105-107.**
3. **Riera AR, Ferreira C, Schapachnik E, Sanches PC, Moffa PJ. Brugada syndrome with atypical ECG: downsloping ST-segment elevation in inferior leads J Electrocardiol. 2004 Apr;37:101-104.**
4. **Tikkanen JT, Anttonen O, Junttila MJ, Aro AL, Kerola T, Rissanen HA, Reunanen A, et al. Long-term outcome associated with early repolarization on electrocardiography. N Engl J Med. 2009 Dec 24;361: 2529-2537.**
5. **Mehta M, Jain AC, Mehta A. Early Repolarization. Clin Cardiol. 1999 Feb; 22: 59-65.**

Monomorphic PVCs with very short coupling (250 to 350ms)	Absent	Characteristic ¹ . Pause-dependency absent ² .
QTc Interval	Normal	Minimally short in 35% among masculine gender. (Between 340 to 360ms³.)
Late Potentials(LPs)	Absent	Frequent if J wave present. Showing circadian variation with night ascendancy ⁴ .

- 1. Alders M, Koopmann TT, Christiaans I, Postema PG, Beekman L, Tanck MW, et al. Haplotype-sharing analysis implicates chromosome 7q36 harboring DPP6 in familial idiopathic ventricular fibrillation. Am J Hum Genet. 2009 Apr; 84: 468-476.**
- 2. Viskin S, Lesh MD, Eldar M, Fish R, Setbon I, Laniado S, et al. Mode of onset of malignant ventricular arrhythmias in idiopathic ventricular fibrillation. J Cardiovasc Electrophysiol. 1997 Oct; 8: 1115-11 20.**
- 3. Viskin S, Zeltser D, Ish-Shalom M, Katz A, Glikson M, Justo D, et al. Is idiopathic ventricular fibrillation a short QT syndrome? Comparison of QT intervals of patients with idiopathic ventricular fibrillation and healthy controls. Heart Rhythm. 2004 Nov; 1: 587-591.**
- 4. Abe A, Ikeda T, Tsukada T, Ishiguro H, Miwa Y, Miyakoshi M, Circadian variation of late potentials in idiopathic ventricular fibrillation associated with J waves: insights into alternative pathophysiology and risk stratification. Heart Rhythm. 2010 May; 7: 675-682.**

Conclusion

In spite of both malignant early repolarization abnormalities of IVF and benign early repolarization pattern being able to cause J point and ST segment elevation, the characteristics of both are clearly different, to the point of a differentiation being quite simple when ECGs are analyzed by experts. Any ER should raise the suspicion of IVF when it presents: ST segment elevation ≥ 2 mm, mainly in inferior wall, superior convexity, eventually lambda wave shape, pattern of dynamic presentation, inconstant with dramatic intensity of ST segment elevation, discordant T wave polarity, related ST segment shift, presence of reciprocal ST-segment changes (mirror image), tendency to discrete short QTc interval in male gender (≥ 340 ms), premature monomorphic ventricular contractions with very short coupling interval (250 to 350ms) not related with exercise, and late potentials with circadian variation and night ascendancy on SA-ECG. Contrarily, in benign ERP, ST elevation observed in the mid-to-left precordial leads is usually ≤ 2 mm and < 0.5 mm in the limb leads, and concave to the top followed by a positive concordant tall T wave.