

Sudden acute cardiac arrest in elderly man



Andrés Ricardo Pérez-Riera, M.D. Ph.D.
Design of Studies and Scientific Writing
Laboratory in the ABC School of Medicine,
Santo André, São Paulo, Brazil
<https://ekgvcg.wordpress.com>



Raimundo Barbosa-Barros, MD
Chief of the Coronary Center of the Hospital de Messejana Dr. Carlos
Alberto Studart Gomes. Fortaleza – CE- Brazil

Case report

Caucasian man, 76 years old, referred to the emergency care unit on April 21, 2017. He arrived at the unit convulsing, with diagnostic hypothesis of acute myocardial infarction, complicated with cardiac arrest.

Physical Examination:

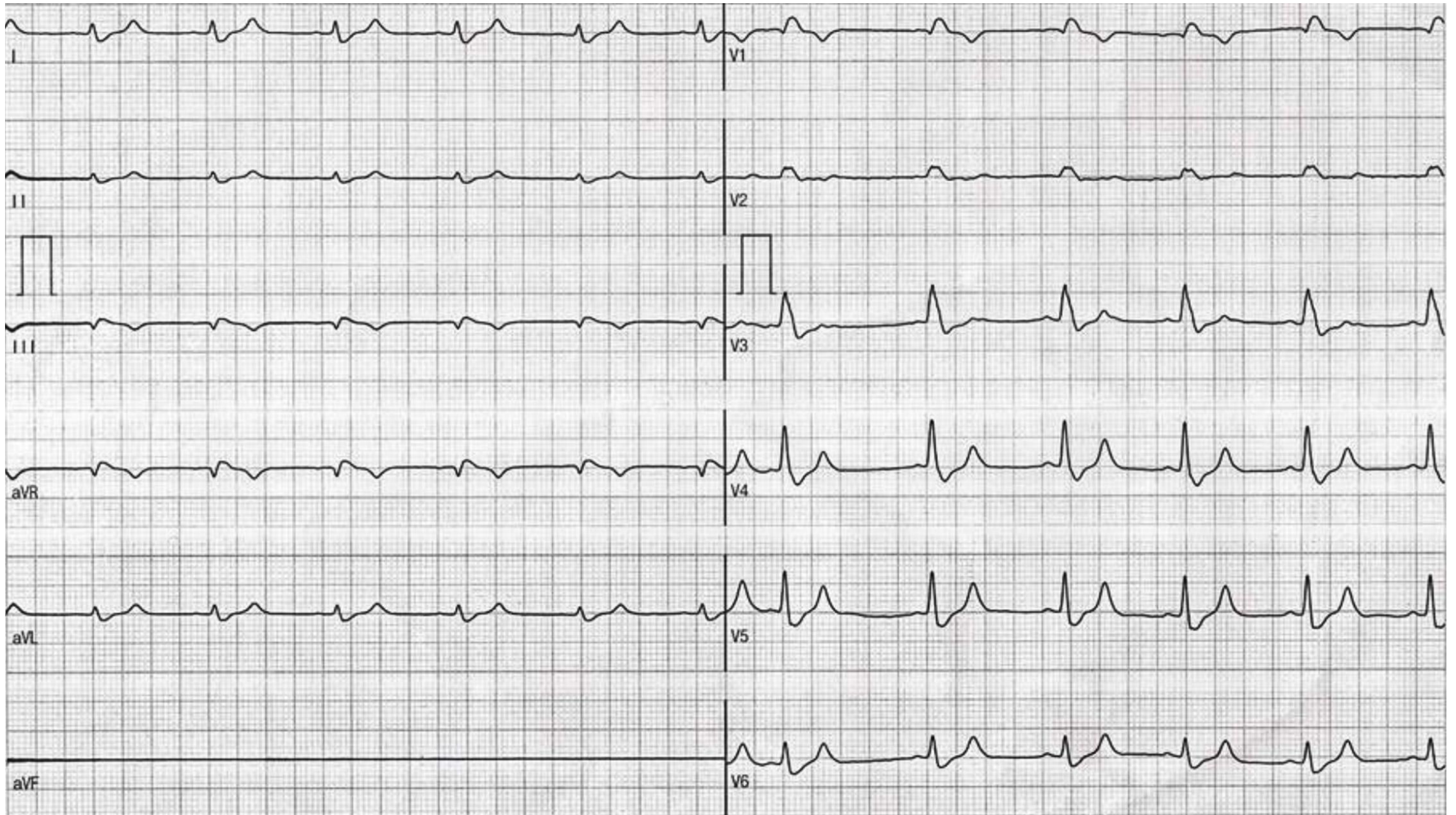
Patient brought in ambulance for stabilization at ER. Family member reports that arrived home and encountered patient sweating with psychomotor agitation, moaning, and precordial pain. Upon arriving, paramedics determined that patient was hypoxemic and with inaudible blood pressure. Transported to the ER, patient arrived with respiratory failure – gasping. It was performed orotracheal intubation, escalating to cardiorespiratory arrest at pulseless electrical activity. Resuscitation maneuvers with spontaneous circulation return during a total of 5 (3-2-2-2-2) cardiorespiratory arrest cycles and administration of adrenaline, bicarbonate and crystalloids, and noradrenaline. We are hospitalizing patient. We don't have a mechanical ventilator. ECG showed ST segment elevation in aVR lead and diffuse ST segment depression.

We performed ECG-2, laboratory and percutaneous cineangiography and biventricular angiography. This patient died in the hemodynamics room soon after procedure.

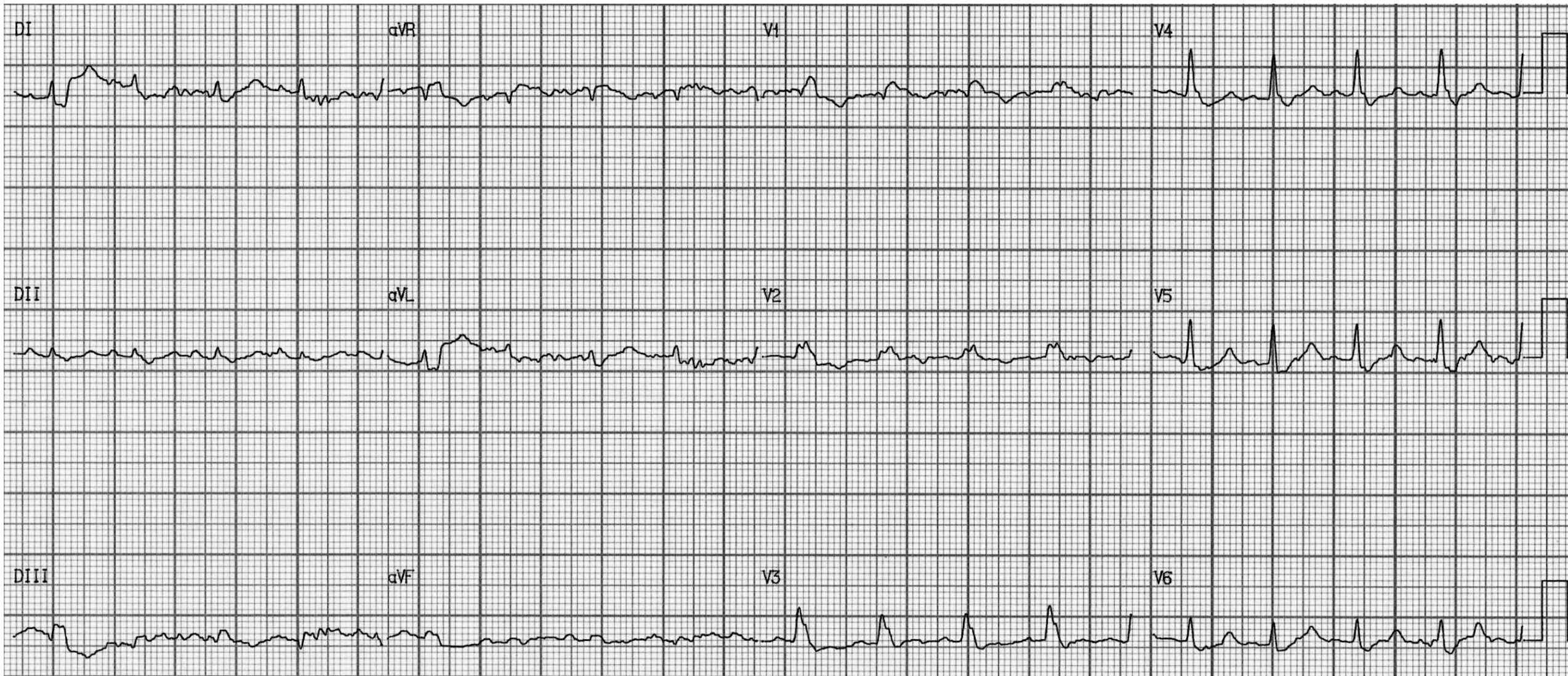
Questions:

1. Which is the etiology of cardiac arrest?
2. Which is the ECG-1 diagnosis?
3. Which is the ECG-2 diagnosis?

ECG-1 performed before arriving in the emergency room



ECG-2 performed at the admission in our ER



Colleagues opinions

Hello all.

- 1. Pulmonary embolism?**
- 2. RBBB with qR in V1. S1Q3T3, lateral ST depression with prominent T waves. Frontal axis almost impossible to determine.**
- 3. More widespread ST depression in the chest leads.**

Kind regards

Kjell C. Nikus M.D. Ph.D

Tampere University Hospital (TAUH) Professor of internal medicine/cardiology

Department of Cardiology

Tampere, Finland



References

- Gul EE, Nikus KC, Erdogan HI, Ozdemir K. Differential diagnostic dilemma between pulmonary embolism and acute coronary syndrome. *J Arrhythm.* 2016 Apr;32(2):160-1. doi: 10.1016/j.joa.2015.10.006.
- Zhan ZQ, Wang CQ, Wang ZX, Nikus KC, Baranchuk A, Yuan RX, Anselm DD, Pérez-Riera AR, Yang B1. Significance of ST-segment deviation in patients with acute pulmonary embolism and negative T waves. *Cardiol J.* 2015;22(5):583-9. doi: 10.5603/CJ.a2015.0023
- Zhan ZQ, Wang CQ, Nikus KC, Pérez-Riera AR, Baranchuk A. Brugada phenocopy in acute pulmonary embolism. *Int J Cardiol.* 2014 Dec 20; 177 (3): e153-5. Doi: 10.1016 / j.ijcard.2014.09.046
- Zhan ZQ, Wang CQ, Nikus KC, He CR, Wang J, Mao S, Dong XJ. Electrocardiogram patterns during hemodynamic instability in patients with acute pulmonary embolism. *Ann Noninvasive Electrocardiol.* 2014 Nov; 19 (6): 543-51. Doi: 10.1111 / anec.12163
- Zhong-Qun Z1, Bo Y, Nikus KC, Pérez-Riera AR, Chong-Quan W, Xian-Ming W. Correlation between ST-segment elevation and negative T waves in the precordial leads in acute pulmonary embolism: insights into serial electrocardiogram changes. *Ann Noninvasive Electrocardiol.* 2014 Jul; 19 (4): 398-405. Doi: 10.1111 / anec.12115
- Zhong-Qun Z, Chong-Quan W, Nikus KC, Sclarovsky S, Chao-Rong H. A new electrocardiogram finding for massive pulmonary embolism: ST elevation in lead aVR with ST depression in leads I and V(4) to V(6). *Am J Emerg Med.* 2013 Feb;31(2):456.e5-8. doi: 10.1016/j.ajem.2012.08.001
- Elvin Gul E, Soylyu A, Nikus KC. Wolff-Parkinson-White syndrome and acute pulmonary embolism: a case report. *Ann Noninvasive Electrocardiol.* 2012 Jul;17(3):283-5. doi: 10.1111/j.1542-474X.2012.00517.x
- Kajander OA, Seppänen J, Sioris T, Hautalahti J, Nikus KC. Multiple pulmonary arteriovenous malformations presenting as an acute myocardial infarction. *Am J Emerg Med.* 2009 Oct;27(8):1020.e5-7. doi: 10.1016/j.ajem.2008.12.026
- Ilva TJ, Eskola MJ, Nikus KC, Voipio-Pulkki LM, Lund J, Pulkki K, Mustonen H, Niemelä KO, Karhunen PJ, Porela P. The etiology and prognostic significance of cardiac troponin I elevation in unselected emergency J Emerg Med. 2010 Jan;38(1):1-5. doi: 10.1016/j.jemermed.2007.09.060department patients.

I would consider type A aortic dissection into the pericardium, resulting in tamponade. The clinical picture and ECG do not suggest an acute coronary syndrome or PE. Cordially.

Sergio L. **Pinski MD**

2950 Cleveland Clinic Blvd Weston, FL 33331 USA

Stanford classification

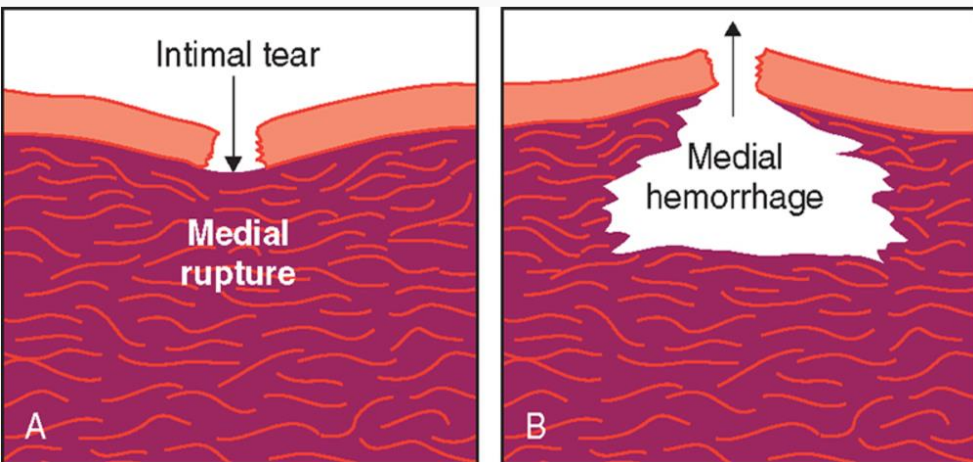
The Stanford classification divides dissections into 2 types, **type A** and **type B**. Type A involves the ascending aorta (DeBakey types I and II); type B does not (DeBakey type III).

This system helps to delineate treatment. Usually, type A dissections require surgery, while type B dissections may be managed medically under most conditions.

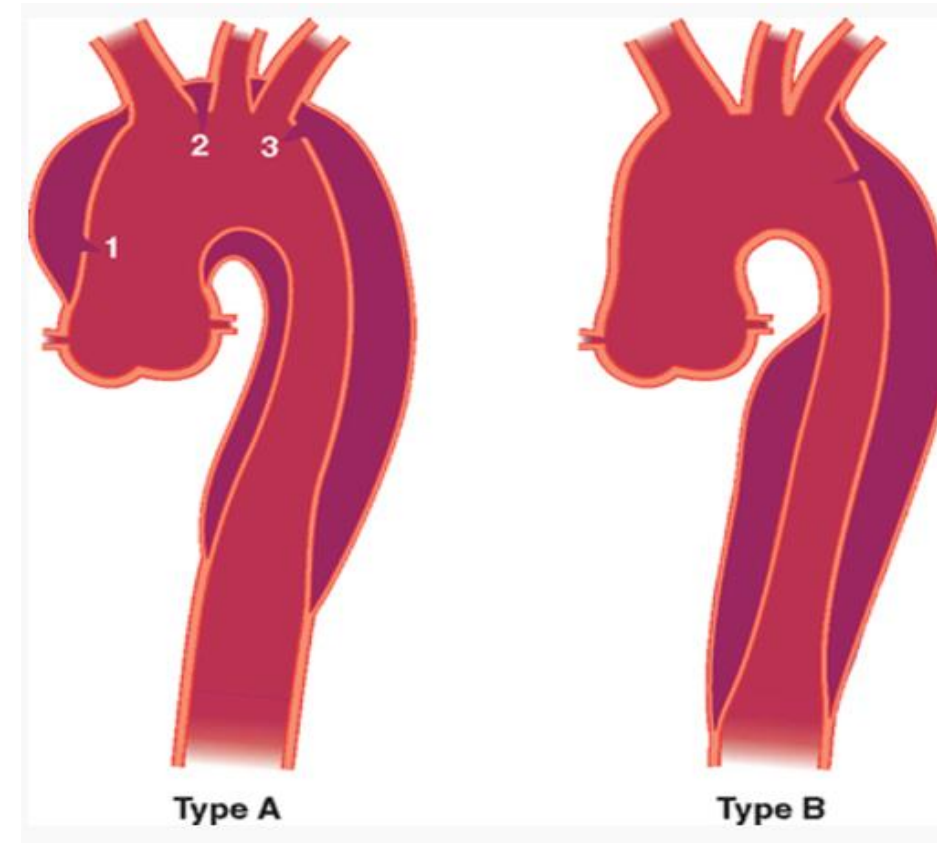

DeBakey classification

The DeBakey classification divides dissections into 3 types, as follows:

- Type I involves the ascending aorta, aortic arch, and descending aorta
- Type II is confined to the ascending aorta
- Type III is confined to the descending aorta distal to the left subclavian artery



Aortic dissection. The tear has penetrated the diseased media (A), with resultant rupture and hemorrhage (B)



Aortic dissection, Stanford types A and B. Type B aortic dissection does not involve the ascending aorta.

Hola

Amigos En ese contexto clínico de dolor precordial con severo compromiso hemodinámico, debo interpretar el Ecg : elevación del ST en avr mayor que en V1 y no tan significativo, por dirección del vector de injuria hacia arriba y derecha en plano frontal con alteraciones difusas de ST en las demás derivaciones, sugestivo de oclusion de tronco de coronaria izquierda.

Posiblemente el Cateterismo lo demuestre así.

De ser así ,pienso que es la causa de shock cardiogenico .

Por otro lado las derivaciones precordiales sugieren un trastorno de conducción de fascículo medioseptal irrigado exclusivamente por el tronco de coronaria izquierda.

De acuerdo también con la posibilidad de TEP y de disección de la aorta, pero los antecedentes referidos no son claros orientadores a ellos.

Saludos

Juan José Sirena MD. Santiago del Estero Argentina “Casas más casas menos igualito a mi Santiago”.



English

Hello Friends: In this clinical context of precordial pain with severe hemodynamic compromise, I must interpret ECG: ST Segment Elevation of ST in aVR greater than in V1 and not so significant, by direction of the upward and right injury vector in the frontal plane with diffuse ST alterations in the other leads, suggestive of LMCA obstruction.

Catheterization may prove so.

If so, I think it is the cause of cardiogenic shock.

On the other hand, the precordial leads suggest a conduction disorder of midseptal fascicle irrigated exclusively by the LAD.

Also agree with the possibility of acute pulmonary embolism and dissection of the aorta, but the antecedents referred are not clear guiding to them.

Thank you!

“Houses more houses less equal to my Santiago”

Juan José Sirena MD Santiago del Estero Argentina.

Initial thought was severe basal ischemia possibly Severe left main or proximal LAD occlusion but hard to explain ST elevation in lead 3 unless there was compound disease in RCA

Professor Melvin M Scheinman

Department of Cardiac Electrophysiology, University of California San Francisco, San Francisco, California, USA.

scheinman@medicine.ucsf.edu

Professor of Medicine

Electrophysiology Service

500 Parnassus Avenue

San Francisco, CA 94143-1354

Telephone/FAX/E-mail:

Phone: (415) 476-5706

Fax: (415) 476-6260

email: scheinman@medicine.ucsf.edu



Caros Andrés e Barbosa

Possível ruptura miocárdica com hemopericárdio e tamponamento

ECG 1: QRS de baixa voltagem no plano frontal, bloqueio de ramo direito, ondas T pontiagudas V4 a V6 (K^{\uparrow} ? - Isquemia?), voltagem da ondas P em I>II e aVF sem registro - Linha isoelétrica

ECG 2: Intensa interferência elétrica, mesmas alterações anteriores, exceto aVF que apresenta registro e agora ECG com alternância elétrica

Abraços

Adail **Paixão Almeida MD** Vitória da Conquista Bahia Brasil

Dear Andrés and Barbosa

Clinical diagnosis: Possible myocardial rupture with hemopericardium and tamponade

ECG 1: Low QRS voltage in the frontal plane, right bundle branch block, pointed T waves from V4 to V6 ($K^+ \uparrow$? - Ischemia?), P wave voltage in I > II and aVF Isoelectric line (no registry)

ECG 2: Intense electrical interference, same previous changes, except aVF that shows record and now ECG with electrical alternance.

Hugs

Adail **Paixão Almeida MD** Vitória da Conquista Bahia Brazil



Español

Los únicos datos que tenemos son que se trata de un hombre de 76 años, atendido aparentemente por presentar previamente precordialgia y convulsiones y un cuadro clínico que parece corresponder al de un shock cardiogénico; con disociación electro-mecánica.

El primer ECG presenta una frecuencia cardíaca alrededor de 62 latidos por minuto, la onda P impresiona como de origen auricular con un intervalo PR muy corto. Complejos QRS de aproximadamente 180 mseg que tienden a ser de bajo voltaje tanto en las derivaciones del plano frontal como precordiales. Presenta un patrón de BRD con desviación del eje hacia la derecha y trastornos de conducción intraventricular, rotación horaria y un gran empastamiento de la onda R en aVR.

Onda Q inicial en V1 y probablemente en V2 (secuela septal) con un bucle que se orienta rápido hacia adelante (disminución de fuerzas del VI y/o aumento de fuerzas del VD). No hay gran elevación ni depresión del punto J y segmento ST Este último rectificado seguido de ondas T simétricas casi en forma difusa por lo cual uno diagnosticaría una isquemia difusa del VI.

Como diagnóstico diferencial a los que ya han sido mencionados agregaría la ruptura cardíaca, probablemente en un paciente con una cardiopatía isquémica previa significativa.

Isabel **Konopka** MD Argentina

English

The only data we have is that it is a 76-year-old man, apparently attended for presenting precordial pain, convulsions, and a clinical picture that seems to correspond to that of cardiogenic shock, with electro-mechanical dissociation.

The first ECG has a heart rate around 62 bpm, the P wave impresses as atrial origin with a very short PR interval. The QRS duration complexes of ~ 180 msec tend to be of low voltage in both the frontal plane and precordial leads. It presents a RBBB pattern with QRS deviation to right and intraventricular conduction disturbance, clock wise rotation and a large final R wave in aVR. Additionally, I observe an initial Q wave in V1 and probably in V2 (septal sequelae) with a forward-facing loop (decrease in LV forces and / or increase in RV forces). There is no great elevation or depression of the J-spot and ST segment. The latter rectified followed by symmetrical T-waves almost in diffuse form whereby one would diagnose diffuse ischemia of the LV. As a differential diagnosis to those already mentioned, I would add **cardiac rupture**, probably in a patient with a previous significant ischemic heart disease.



Hola a todos: En el análisis del ECG (el N° 2, porque el N° 1 creo que tiene error en la colocación de los electrodos), observo que hay:

- Bajo voltaje. Es agudo o crónico?? Esta información me parece de suma importancia ya que si es agudo, hay casi certeza de hemopericardio severo, quizás taponamiento. Si es crónico, debo cambiar el eje del razonamiento.
- Taquicardia sinusal. (En el ECG N° 1 la frecuencia cardíaca es normal). El eje eléctrico en el plano frontal es indeterminado.
- Elevación del ST en aVR. Infradesnivel en el resto de las derivaciones.
- BRD +S1Q3T3 + qR en V1 .

Etiología? El relato de la historia clínica y el ECG dan pie para pensar en las siguientes posibilidades:

1) Si el bajo voltaje es agudo:

a) Infarto agudo, por oclusión de tronco + ruptura externa , ya que hubo (varios?) episodios de actividad eléctrica sin pulso palpable. Y tromboembolia pulmonar simultánea, con hipertensión pulmonar. En este caso, podría suponer que el paciente tiene trombosis múltiple, tanto en el tronco de la coronaria izquierda, como en una arteria pulmonar. (Embolia paradójal?)

b) Una disección aórtica tipo A con hemopericardio, también puede colocarse entre los diagnósticos diferenciales.

2) Si el bajo voltaje es crónico (enfisema pulmonar, obesidad, mixedema, etc):

-Pienso en TEP severo y no en infarto, ya que el supradesnivel en aVR también puede verse en un TEP, por la sobrecarga aguda del VD y/o la isquemia relativa en el tracto de salida del VD y la zona basal del septum.

La onda de lesión subendocárdica difusa también puede deberse a isquemia relativa, por hipoxemia.

La presencia de "gaspings" nos habla de la severidad de la hipoxemia y es indicativa de inmediato paro cardiorespiratorio, si el paciente no es conectado a respirador mecánico.

La "agitación psicomotriz" relatada también se debe a severa hipoxemia.

Se trata de un paciente en franca agonía, por falla aguda y grave del V.D.

Conclusión: Comparto el criterio de Kjell Nikus , creo que se trata de un severo tromboembolismo pulmonar en un paciente con bajo voltaje crónico en su ECG. (Patología pulmonar crónica previa?)

Espero que el cateterismo aclare tan grave situación.

Un detalle que también me llamó la atención es que hicieron angiografía BI- ventricular. Es posible que los colegas también han sospechado TEP.

Un abrazo, y gracias por compartir tan interesante caso.

Dr. Mario Heñin Resistencia, Chaco Argentina

Hello to everyone In the ECG analysis (No. 2), because No. 1 I think there is an error in the placement of the electrodes), I notice that there are:
- Low voltage. Is it acute or chronic? This information seems to me of the utmost importance since if it is acute, there is almost certainty of severe hemopericardium, perhaps tamponade. If it is chronic, I must change the axis of reasoning.

Sinus tachycardia. (In ECG No. 1, the heart rate is normal.), the electric axis in the frontal plane is indeterminate, ST elevation in aVR and depression in the rest of the leads, RBBB, SI-SII-SIII patten, and qR in V1. Etiology? The story of the clinical history and the ECG give rise to think of the following possibilities:

1) If the low voltage is high:

A) Acute infarction, by occlusion of the trunk + external rupture, since there were (?) Episodes of electrical activity without palpable pulse. And simultaneous pulmonary thromboembolism, with pulmonary hypertension. In this case, it could be assumed that the patient has multiple thrombosis, both in the trunk of the left coronary artery, and in a pulmonary artery. (paradoxical Embolia?)

B) A type A aortic dissection with hemopericardium can also be placed between differential diagnoses.

2) If the low QRS voltage is chronic (pulmonary emphysema, obesity, myxedema, etc.):

- I think of severe TEP and not of infarction, since the aVR elevation can also be seen in a TEP, due to acute RV overload and / or relative ischemia in the RVOT and basal septum.

The diffuse subendocardial injury current may also be due to relative ischemia, due to hypoxemia.

The presence of "gasping" tells us about the severity of hypoxemia and is indicative of immediate cardiorespiratory arrest if the patient is not connected to a mechanical respirator.

The reported "psychomotor agitation" is also due to severe hypoxemia.

It is a patient in frank agony, due to acute and severe failure of the right ventricle.

Conclusion: I agree with Kjell Nikus' criteria, I believe that this is a severe pulmonary thromboembolism in a patient with chronic low voltage on his ECG. (Previous Chronic Pulmonary Disease?)

I hope the catheterization will clarify this grave situation. One detail that also struck me was that they did BI-ventricular angiography. It is possible that colleagues have also suspected PE.

A hug, and thanks for sharing such an interesting case.

Mario **Heñin MD** Resistencia, Chaco Argentina



Spanish

Querido Andrés and Raimundo. Todos han expresado los diferentes diagnósticos diferenciales todos son probables.

Lástima no contar con precordiales derechas.

En el ECG de ingreso RS 70 por minuto con severa sobrecarga del VD y patrón S I y QIII y T negativa en III. Patrón sugestivo de TEP en un paciente con miocardiopatía previa. Dado los bajos voltajes observados en el ECG y una probable secuela septal.

Luego de la reanimación taquicardia sinusal BAV de primer grado y patrón Rsr' (trastorno de conducción ventricular derecha con signos de sobrecarga del VD).

El diagnóstico presuntivo es TEP y no encuentro motivos para sospechar taponamiento cardiaco dado que no observó alternancia eléctrica y en el segundo ECG los QRS son de baja amplitud pero no la onda P.

Un cordial saludo

Martín Ibarrola



English

Dear Andrés and Raimundo. All have expressed the different differential diagnoses. All are possible.

Unfortunately, we do not have the right precordial leads.

(MGW pattern). In the admission ECG-1 sinus rhythm, heart rate of 70bpm, severe overload of the RV and the classical pattern SI-QIII-TIII (McGinn White). Suggestive of acute pulmonary embolism in a patient with previous cardiomyopathy. Given the low voltages observed on the ECG and a probable septal sequela.

After resuscitation sinus tachycardia, first-degree BAV block, and Rsr 'pattern (right ventricular conduction disorder with signs of RV overload).

The presumptive diagnosis is acute PE acute pulmonary embolism and I do not find reason to suspect cardiac tamponade since no electrical alternance is observed and in the second ECG-2. The QRSs are of low amplitude but not the P waves.

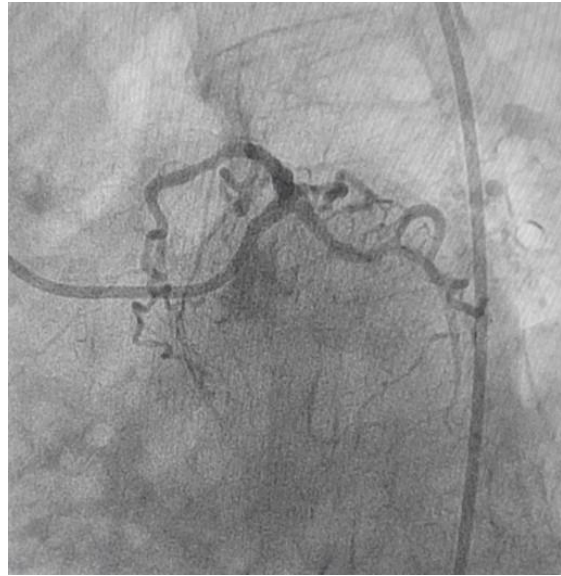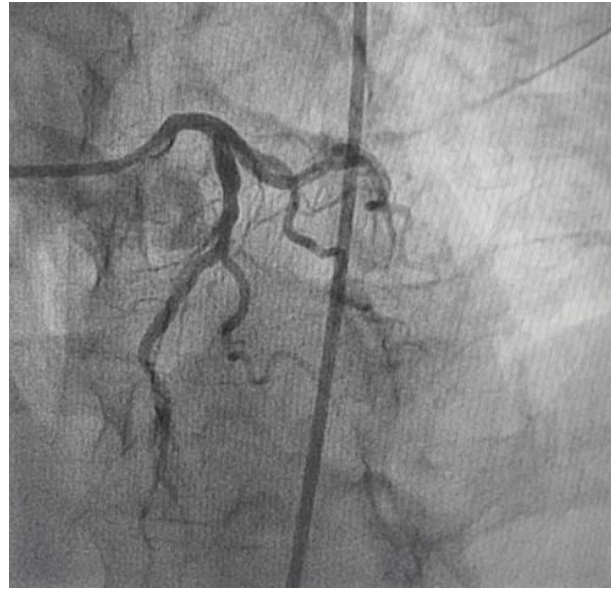
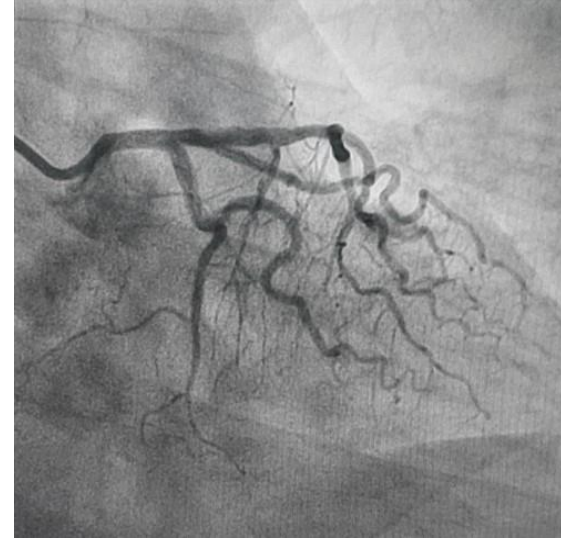
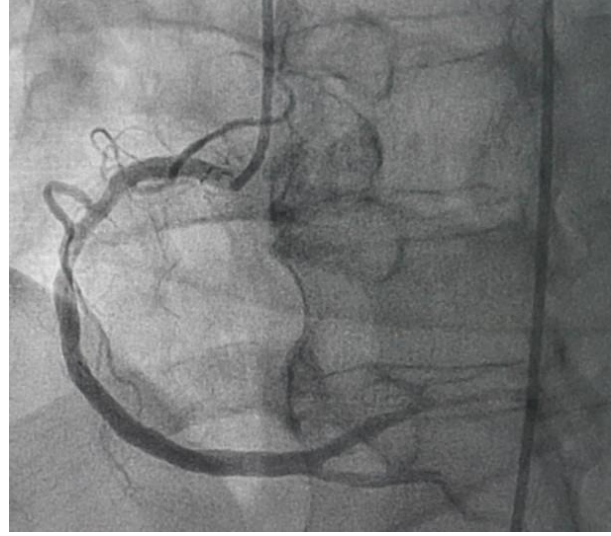
Kind regards

Martin Ibarrola M.D. Provincia de Buenos Aires Argentina

Final comments



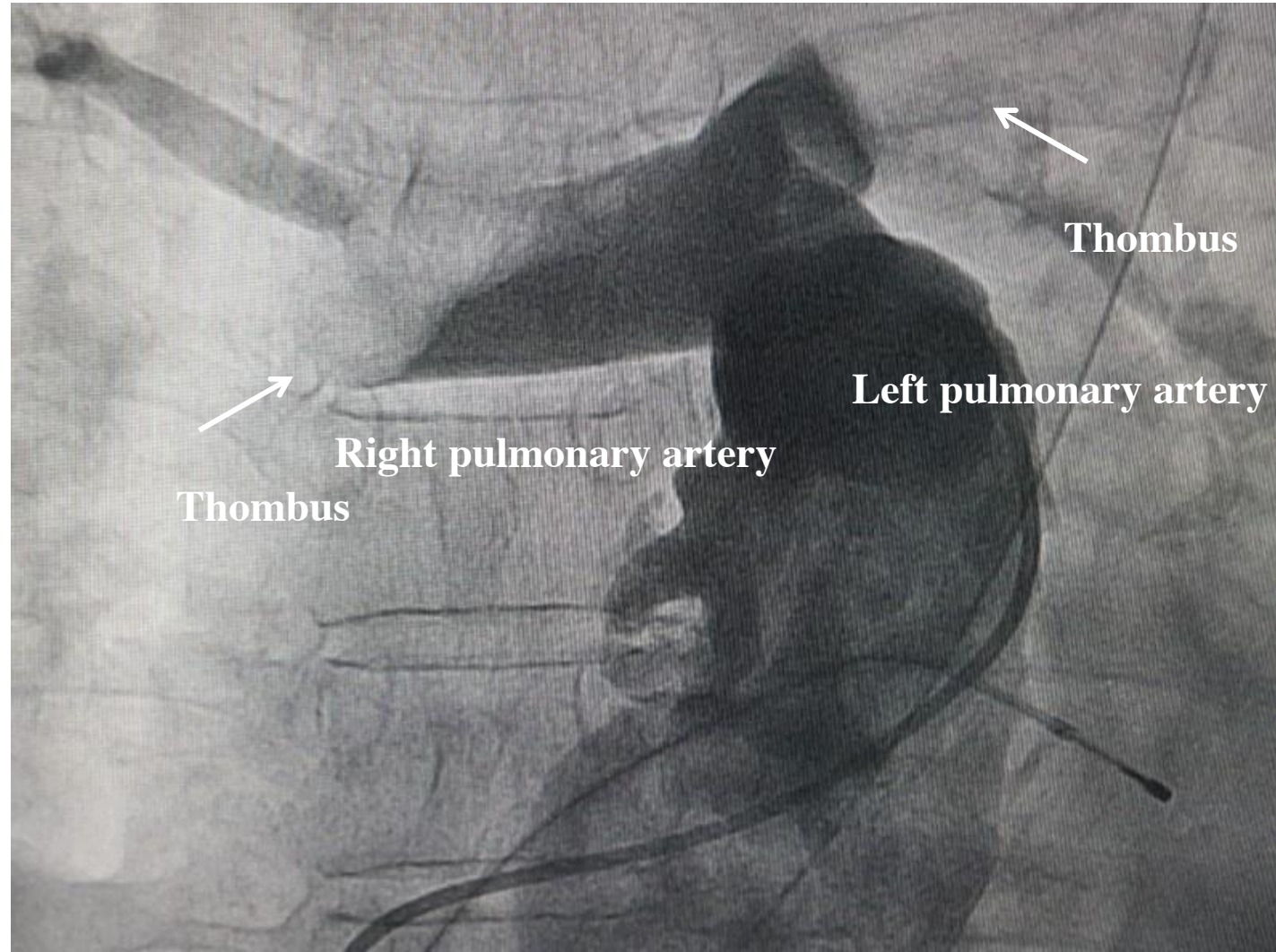
Coronariography



LMCA without obstruction; LAD = 40% of obstruction in the middle third; Diagonalis branch (DG) and Obtuse marginal of circumflex (OMCX) with parietal irregularities; RCA = 50% of obstruction in the middle third; PDA and VPA with parietal irregularities. This patient died in the hemodynamics room soon after pulmonary arteriography before attempting thrombolysis.

Transvenous Cardiac Pacing technique via femoral vein

Right heart Cath and pulmonary bed angiography



Right-Heart Cath and pulmonary angiography showed bilateral pulmonary embolism.

Laboratory results at admission

				ELECTROLYTES	
ARTERIAL SAMPLE			Na ⁺	147.7	mEq / L
24.01.2017	11:41		K ⁺	5.63↑	mEq / L
SYSTEM NAME	RP500-2 EMERG		Ca ²⁺	1.06↓	mmol / L
SYSTEM ID	0500- 37188		Cl ⁻	113↑	mmol / L
PATIENT ID	XX		mOsm	299.2	mmol / kg
NAME	SPCR				
ACID/BASE 37.0 °C				METABOLITES	
pH	6.806 ↓		Glu	68	mg / dL
pCO ₂	28.7 ↓	mmHg	La	15.26↑	mmol / L
pO ₂	384.0 ↑	mmHg			
HCO ₂ act	4.4	mmol/L			
HCO ₂ std	4.8	mmol/L			

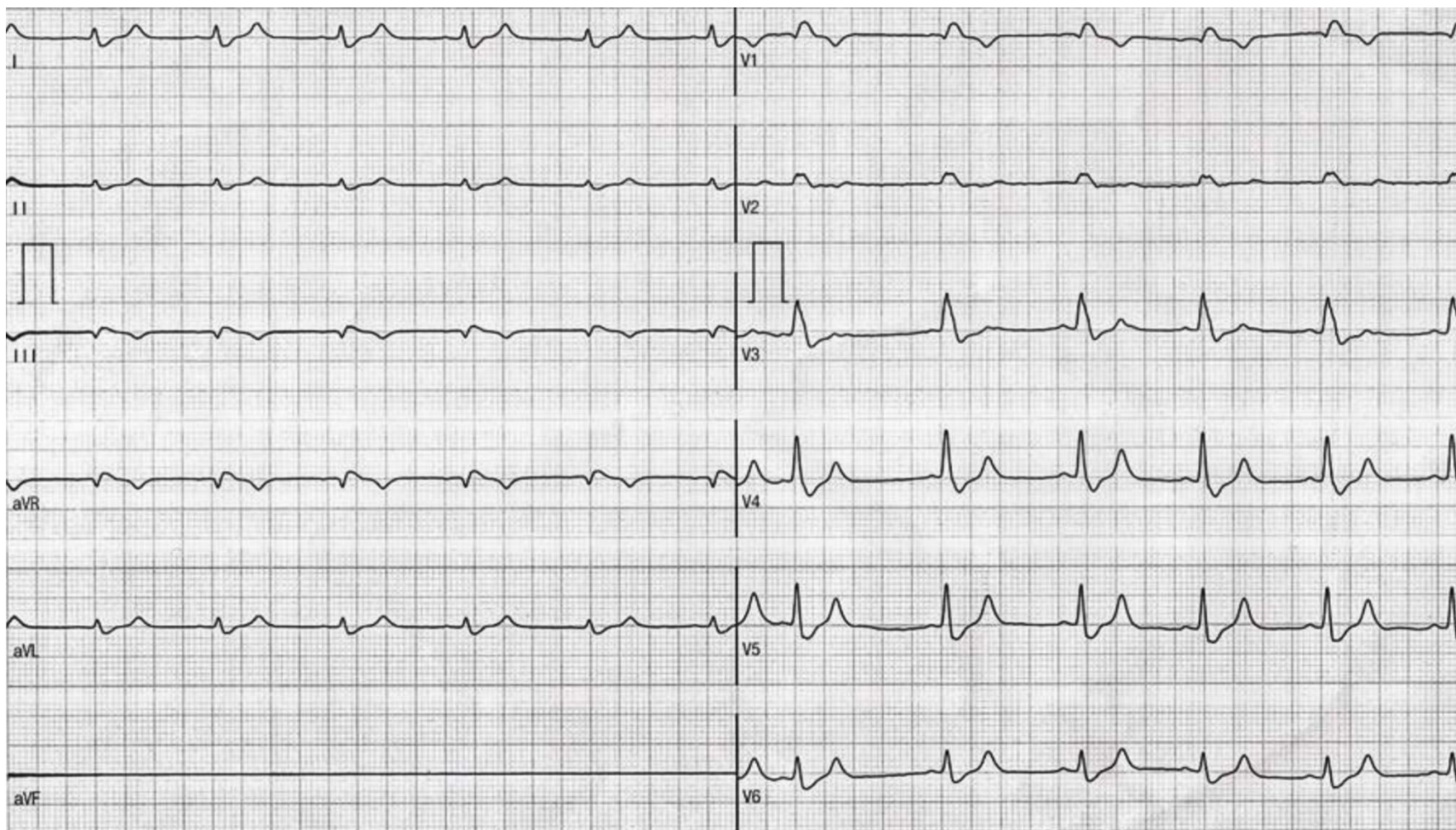
Hemogram: moderate anemia (3.1 million / mm³); White blood cells: normal; Platelets: thrombocytopenia (29,950 / mm³)

Ultra-sensitive Troponin T: 0.224 ng / ml; Creatinine: 1.62mg / dL; Urea: 62mg / dL; Kalemia: 5.63mEq / L; Prothrombin time: 37.2 s; INR: 2.52

Activated partial thromboplastin time:> 180s

P / C ratio:> 5.8

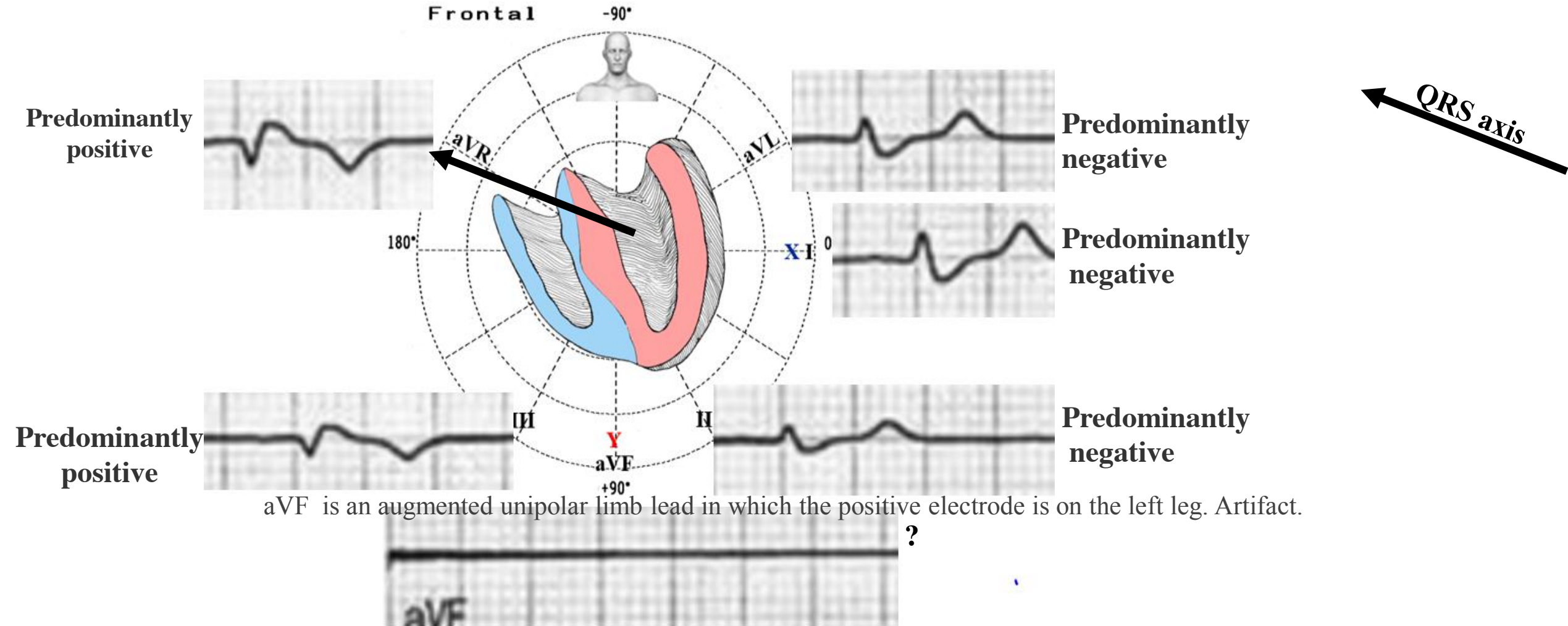
ECG-1 performed before arriving in the emergency room



ECG diagnosis: 1) Low QRS voltage complexes in limb leads: ≤ 5 mm and in the precordial leads (≤ 10 mm). Low voltage is defined as peak-to-peak QRS voltage ≤ 5 mm in all limb leads and ≤ 10 mm in all precordial leads (**Wagner 2001**). In the present case, low QRS amplitude in limb leads probably is caused by **posterior shifting of the SAQRS perpendicularly to the frontal plane**. Isolated low voltage in the limb leads is associated with the same conditions that cause diffuse low voltage in 50% of cases. In the remainder, more than 60% have dilated ventricles. (**Chinitz 2008**). Others causes are the “damping” effect of increased layers of fluid (pericardial effusion), fat (morbid obesity) or air (emphysema, pneumothorax) between the heart and the recording electrodes. Low voltage on the surface ECG has been ascribed to numerous

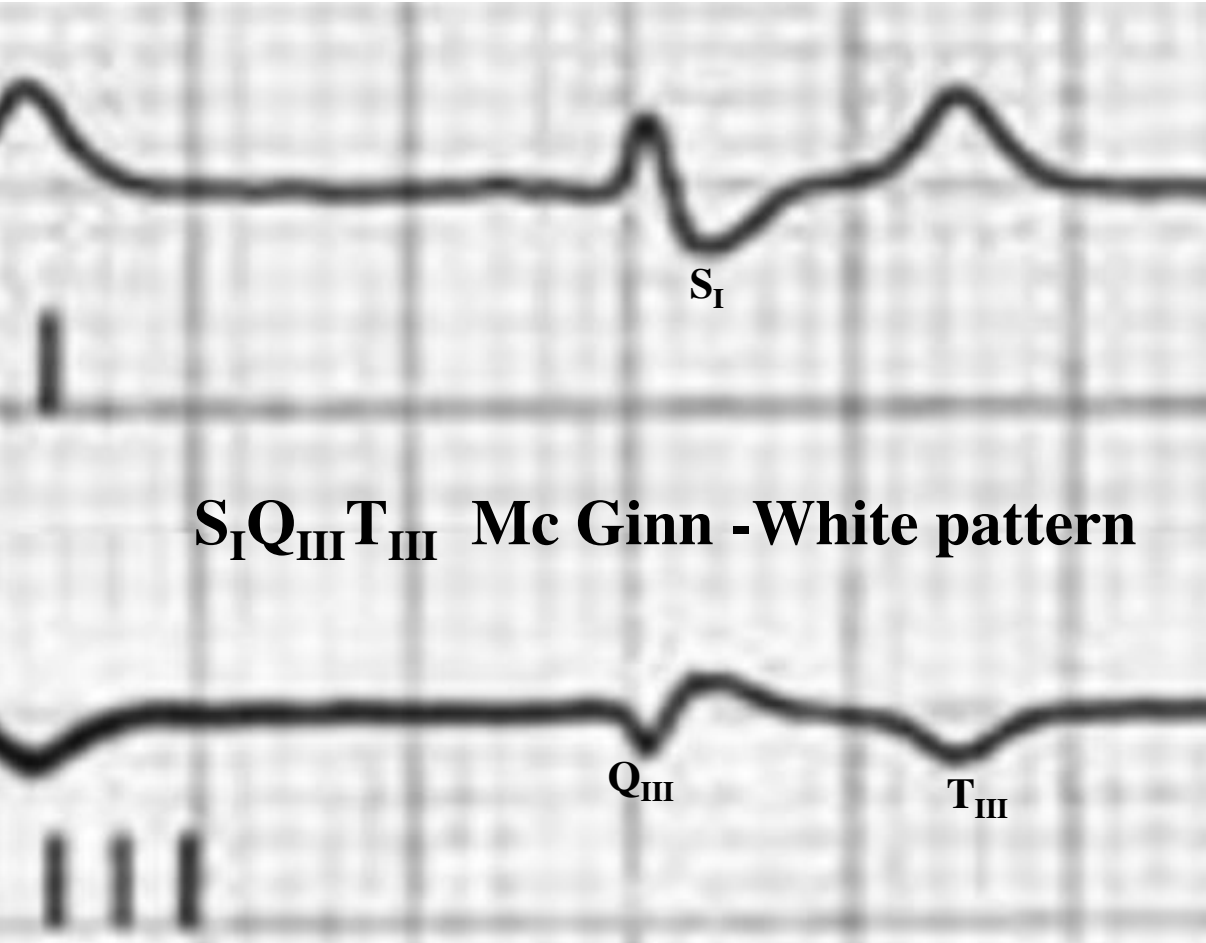
conditions that either low or alter current transmission from the myocardium to the skin electrodes. Altered voltage transmission may be the result of interposed fluid with high conductivity, as in pericardial effusion or anasarca, or an insulating layer of air or adipose tissue with low conductivity, as in emphysema, prominent epicardial fat, or obesity. (Bruch 2001) Other potential or rare causes of low voltage, such as multiple or massive previous myocardial infarctions, thyroid disease (Yamanaka 2010), and normal variation have also been described. (Feldman 1985) .Frequently, only the limb leads are used to determine low voltage in the literature, (Kamath 2006) and the meaning of low limb lead voltage is unclear in clinical practice. Low QRS voltage isolated to the limb leads is associated with significant pericardial disease, infiltrative cardiomyopathy, obesity, or emphysema in only half of patients. Bruch et al. have reported on the diagnostic value of low QRS voltage mostly in the identification of pericardial effusions. These studies have shown an inverse correlation between QRS voltage and size of the pericardial effusion, with the greatest reduction in QRS amplitude seen with effusions that result in frank tamponade. (Bruch 2001) Casale et al. reported a positive predictive value > 90% of low voltage QRS in both limb and precordial leads for the presence of effusions (Casale 1984). In other studies, however, only 12% to 61% of patients with tamponade had low voltage ECGs, indicating the poor sensitivity of this finding to diagnose pericardial effusion. (Oliver 2002) In addition to pericardial disease, patients with voltage discordance were found to have other conditions commonly associated with low voltage, such as infiltrative cardiomyopathies, obesity, and chronic obstructive pulmonary disease. The combination of low or normal QRS voltage and ventricular hypertrophy has been shown to be a specific, though insensitive, marker for infiltrative disease such as cardiac amyloidosis. (Hamer 1992) Studies of low voltage and obesity have demonstrated a higher frequency of low limb lead QRS amplitude in obese patients than in lean controls but have recorded an overall incidence of low voltage in obese patients. 12 Chronic obstructive pulmonary disease has also long been associated with low voltage, (Rodman 1990) but low voltage alone is not a sensitive or a specific finding for patients with COPD. Apparently, ECGs with low voltage in both the limb and precordial leads have a poor specificity for traditional clinical correlates, just as low voltage isolated to the limb leads did in this study. Patients with voltage discordance had a significantly increased frequency of small and trivial pericardial effusions compared to the frequency of these effusions seen in all echocardiograms performed. This is consistent with a series that found small pericardial effusions present in 18% of patients with low voltage present either in the limb leads or in the precordium. (Kamath 2006) Small effusions were present in more than 20% of patients with voltage discordance and no other identified etiologies of low voltage. Small effusions can occur in patients with poor ventricular function and the increased prevalence of these small effusions in patients with voltage discordance could only reflect an association with cardiomyopathy. The average LVEF among patients with small pericardial effusions (48%), however, was not significantly different from the mean LVEF among all subjects. It is therefore possible that even small pericardial effusions may alter current conduction enough to explain low voltage QRS, even when isolated to the limb leads. Alternatively, pericardial inflammation associated with effusions, regardless of size, might represent a separate mechanism of voltage attenuation apart from enhancement of current conduction by a layer of fluid.

Where is located the QRS axis in ECG-1?



This ECG has the QRS is predominantly downward (predominantly negative) in lead I and downward (negative) in lead aVF, then the axis is indeterminate and sometimes referred to as “northwestern axis”, no man's land, extreme right axis deviation(QRS axis between -90° and $\pm 180^{\circ}$ (AKA “Northwest Axis”). This finding is uncommon and usually from ventricular rhythms (ventricular tachycardia, premature ventricular contractions), artificial paced rhythms, lead misplacement(lead transposition), hyperkalemia, emphysema, right end conduction delay in RVOT, and certain congenital heart diseases.

	Normal Axis (0 to +90°)	LAD PHYSIOLOGICAL (0 to -30°)	LAD PATHOLOGICAL (-30° to -90°)	RAD (90° to 180°)	Extreme Axis (-90° to -180°)	Indeterminate (?)
LEAD I	POSITIVE	POSITIVE	POSITIVE	NEGATIVE	NEGATIVE	EQUIPHASIC
LEAD II	POSITIVE	EQUIPHASIC	NEGATIVE	POSITIVE	NEGATIVE	EQUIPHASIC
LEAD aVF	POSITIVE	NEGATIVE	NEGATIVE	POSITIVE	NEGATIVE ?	EQUIPHASIC



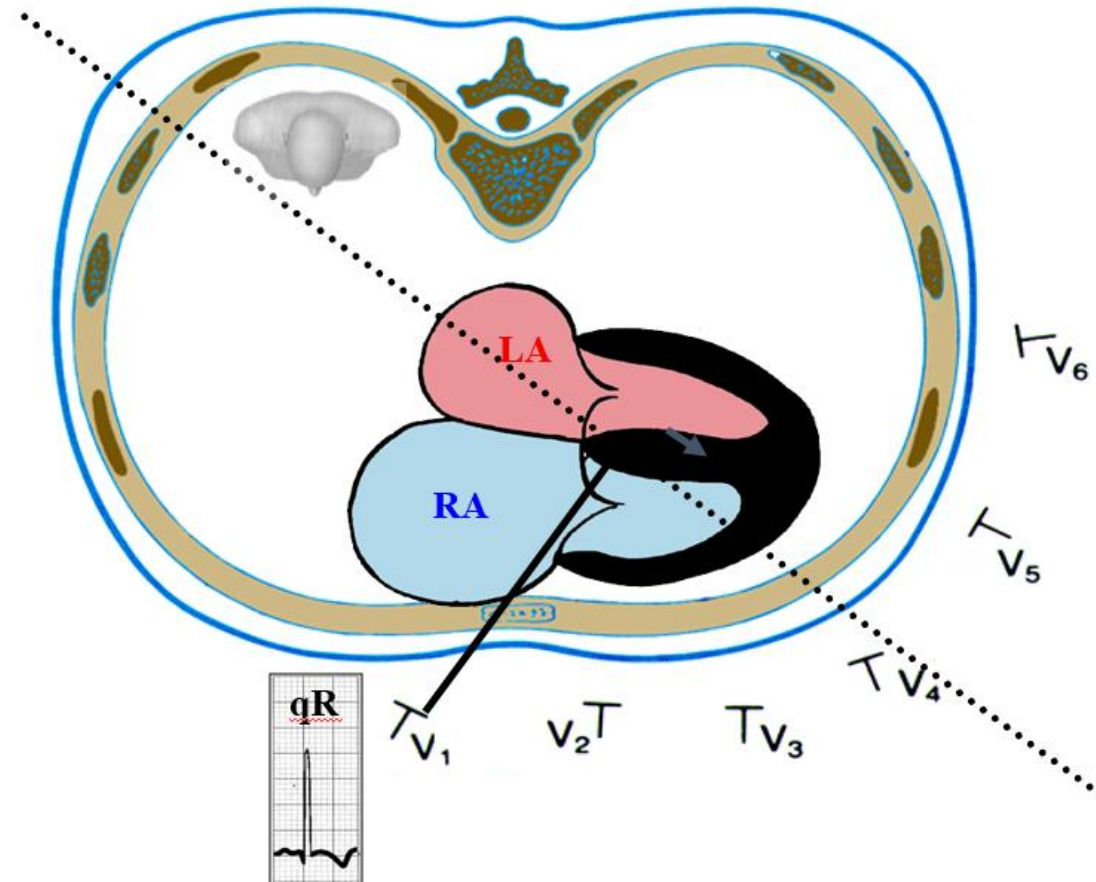
Seventy seventh years ago, Sylvester McGinn and Paul White described the first association between acute PE and specific ECG changes when they noted the S_IQ_{III}T_{III} pattern in 7 patients with acute cor pulmonale (**Mc Ginn 1935**): a classic S wave in lead I, Q wave in lead III and inverted T wave in lead III. The S_IQ_{III}T_{III} pattern seen on the ECG in the setting of acute pulmonary embolism or other causes of acute right heart strain (cor pulmonale). A large S wave in lead I, a Q wave in lead III, and an inverted T wave in lead III is the finding and only occurs in about 10%(insensitive) sign of right heart strain. of people with acute pulmonary embolisms. This ECG finding should not be confused with that of a left posterior fascicular block!!!!!! This ECG pattern is an insensitive. It is non-specific (as it does not indicate a cause) and is present in a minority of acute pulmonary embolisms cases. It can also result from acute changes associated with bronchospasm, and pneumothorax. Other ECG signs include a right bundle branch block as well as T wave inversions in the anterior leads, which are "thought to be the consequence of an ischemic phenomenon due to low cardiac output in the context of RV dilation and strain. Aside from echo and ECG, RV strain is visible with a CT scan of the chest and via cardiac magnetic resonance.

Ferrari et al (**Ferrari 1997**) observed that anterior T wave inversion was present in 85% of cases of massive PE and 19% of cases of non-massive PE, and that its reversibility before the 60th day pointed to a good outcome. They also found that ECG findings of sinus tachycardia and pulmonary P wave as determined by amplitude of ≥ 0.25 mV in lead II (both absent in this case) each had 100% specificity and 100% positive predictive value in assessing the severity of PE but had poor sensitivity and negative predictive value.



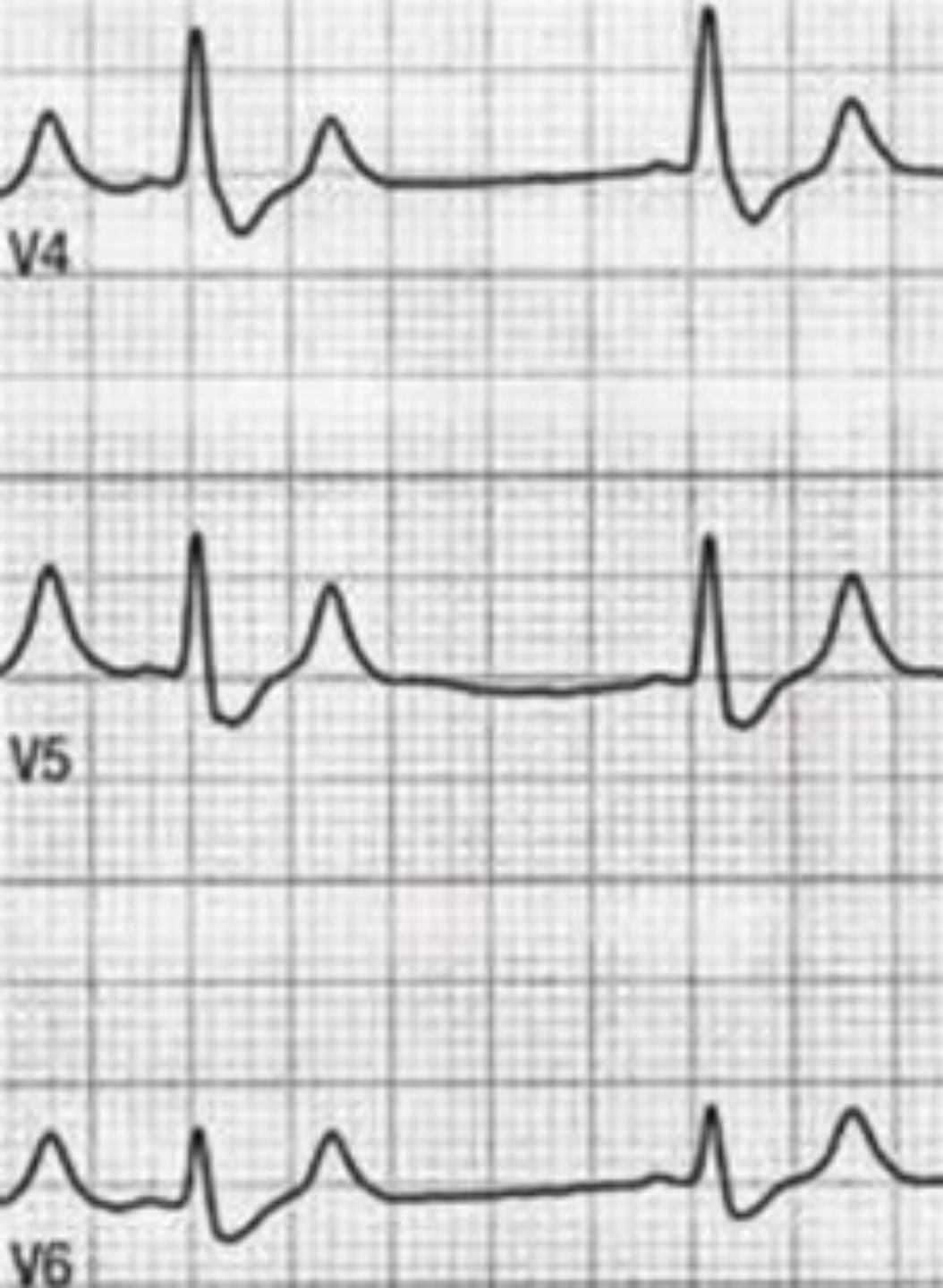
- I. **HR 60bpm.** The most frequent ECG signs found in patients with acute PE is tachycardia (38%) absent in this case.
- II. **Low QRS voltage = 3mm** ($\leq 10\text{mm}$ or $0,10\text{mV}$ is considered low QRS voltage) Low voltage is defined as peak-to-peak QRS voltage ≤ 5 mm in all limb leads and ≤ 10 mm in all precordial leads (**Wagner 2001**).
- III. **Very prolonged Ventricular Activation Time (VAT) in the right precordial leads.** greater than 40 ms in V_1 . A VAT in lead V_1 of <0.01 s excluded RVH. Only the VAT time in V_1 correlated with RV dilation and when >0.045 s confirmed its diagnosis. (**Kopec G 2012**)
- IV. **Broad QRS duration = 160 ms**
- V. **Sodi-Pallares sign** QRS complex with initial q in V_1 or V_1 and V_2 : qR, QR or qRs in V_1 and V_2 it is an indirect signal of significant dilatation of the right atrium. Right Atrial Enlargement (RAE) (See in the next slide a lucid explanation). Other causes of qR pattern in V_1 are: Systolic RVH with strain pattern (with suprasystemic right intraventricular pressure. E.g.: Pulmonary stenosis with the form of a point or extreme, RBBB associated to anterior myocardial infarction, RBBB with isoelectric initial r wave in V_1 , situs inversus consequence of inverted septal activation and Pectus excavatum
- VI. **Complete Right Bundle Branch Block Pattern:** This is a finding associated with increased risk of circulatory shock and death in acute pulmonary embolism, In a systematic review and meta-analysis revealed 10 studies, including 3,007 patients with acute PE, that demonstrate that six findings of RV strain on 12-lead ECG (heart rate > 100 beats/min, SI-QIII-TIII, complete RBBB, inverted T waves in V_1 - V_4 , ST elevation in aVR, and atrial fibrillation) are associated with increased risk of circulatory shock and death. (**Shopp 2015**)

Significant dilatation of Right Atrium: Indirect sign of RAE conditioning qR pattern in V₁ and V₃R (Sodi-Pallares' sign) (Sodi-Pallares 1952)



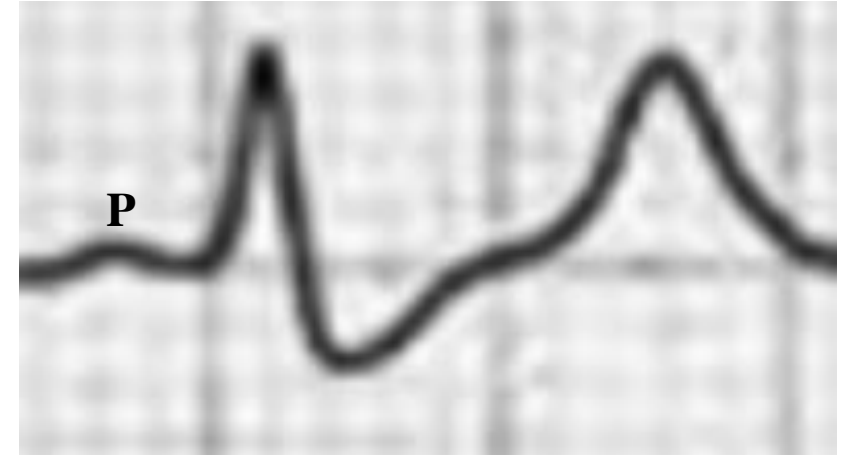
Outline that explains the indirect sign of RAE: qR in V₁ (sign of Sodi-Pallares). The volumetric increase of the RA, gets closer to the exploring electrode V₁, recording initial QRS negativity in this lead, because this electrode records the epicardial morphology of the right atrium. Isolated Pulmonary Hypertension: the ECG is very sensitive in symptomatic patients with isolated pulmonary hypertension (Bossone 2003). Important dilatation of the right atrium: E.g.: Ebstein's anomaly (Oliveira 2014), tricuspid insufficiency. The volumetric increase of the RA gets it closer to the exploring electrode of V₁, registering negatively q initially in this lead, because the electrode records the epicardial morphology of the RA.

Serum K⁺ level with light hyperkalemia between 5,5-6.5 mEq/L



T-waves become abnormally tall, peaked/pointed, symmetrical, with narrow base: “Eiffel tower T waves” or “desert tent T waves”

Eiffel tower T-wave shape

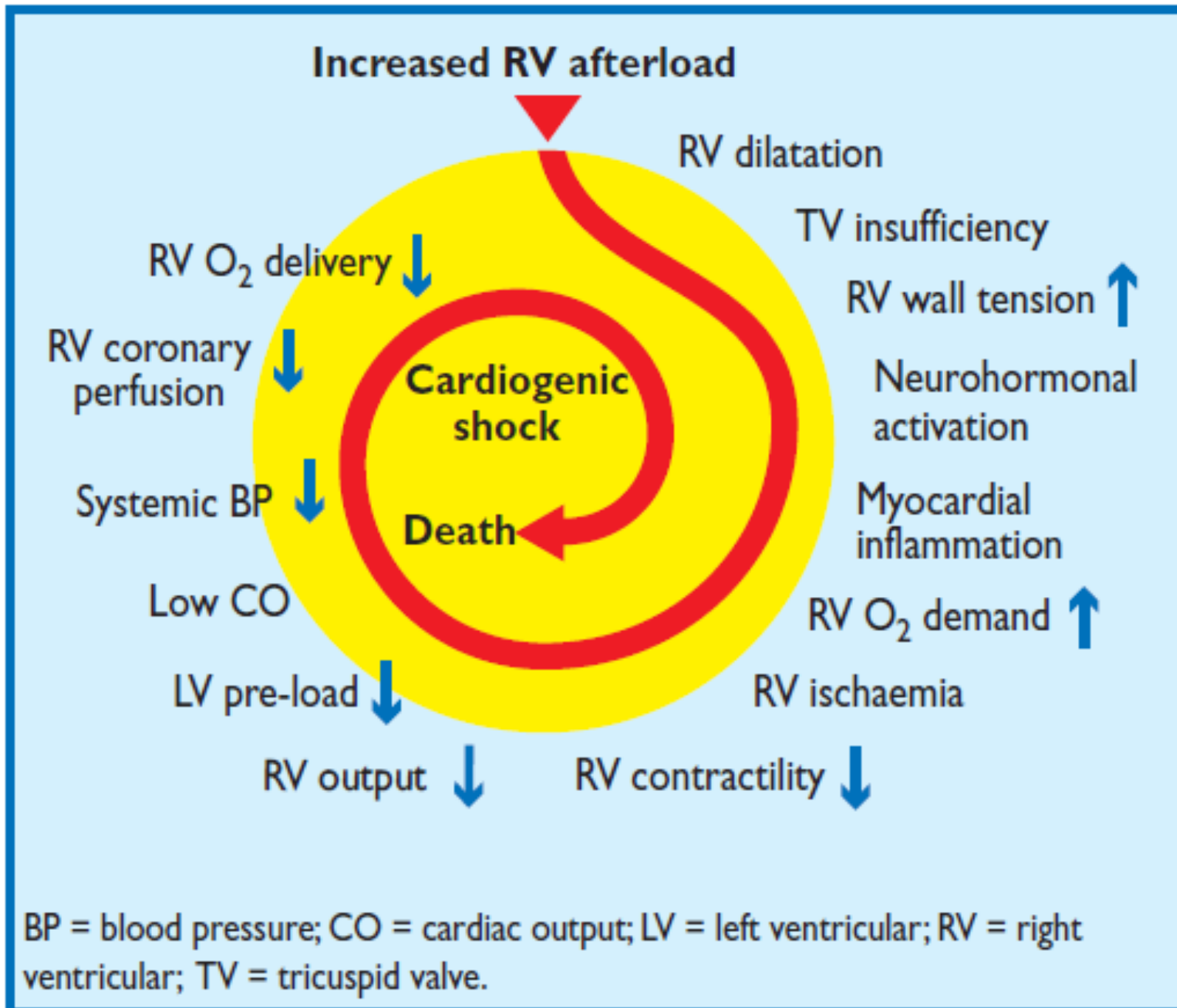


P-wave with low voltage. PR interval 120ms

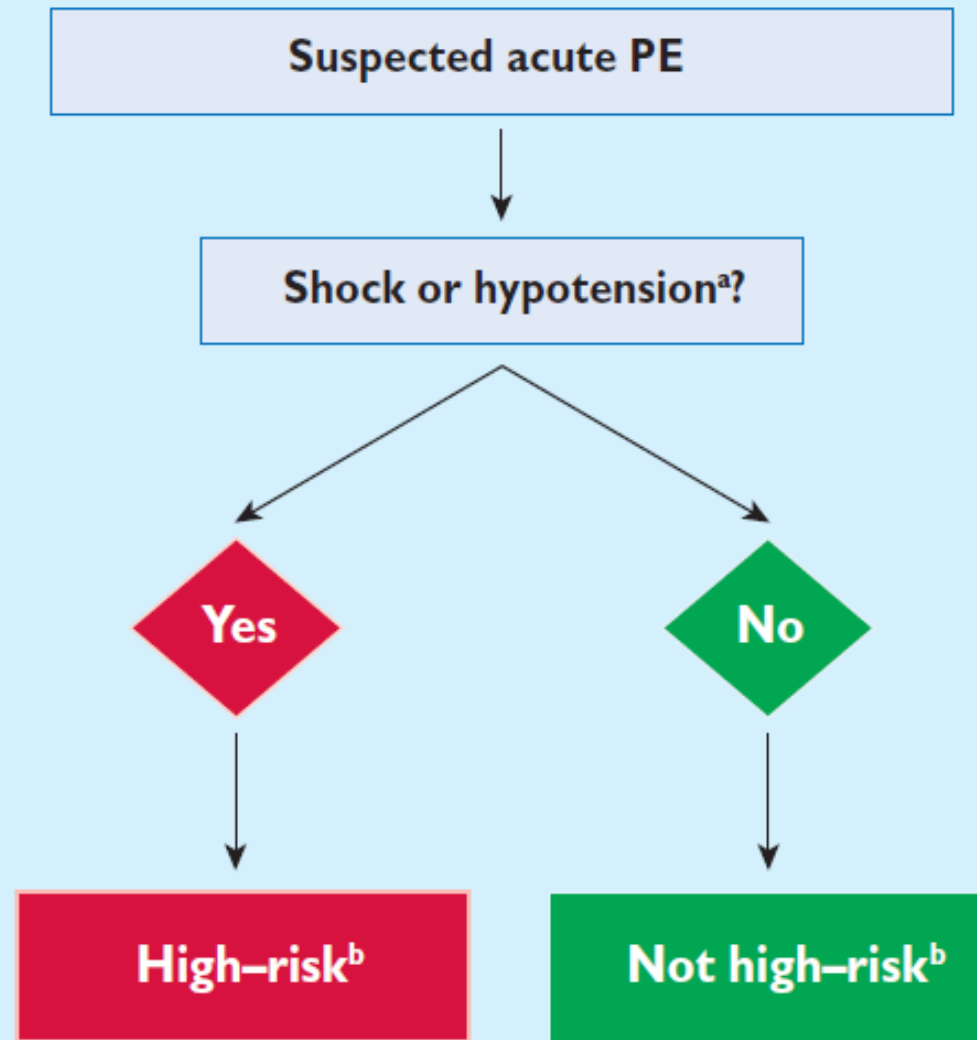
Potassium values

K ⁺	5.63↑	mEq / L
----------------	-------	---------

Key factors contributing to haemodynamic collapse in acute pulmonary embolism



Initial risk stratification of acute PE



PE = pulmonary embolism.

^aDefined as systolic blood pressure <90 mm Hg, or a systolic pressure drop by ≥ 40 mm Hg, for >15 minutes, if not caused by new-onset arrhythmia, hypovolaemia, or sepsis.

^bBased on the estimated PE-related in-hospital or 30-day mortality.

Acute Pulmonary thromboembolism (acute PE)

It is a common clinical entity responsible for numerous hospitalizations and associated with high rates of morbidity and mortality. When not identified the mortality is 4-6 times greater than in those in whom the diagnosis was promptly made and treated with early anticoagulation. The early treated to not treated ratio show in-hospital mortality of 6-8% vs 25-30% (**Cooksey 1977**). The symptoms are the consequence of occlusion in the main pulmonary artery or one of its branches by embolic thrombus originating in other locations in the body, mainly the veins of the lower extremities or veins in the pelvis. A small proportion of pulmonary embolism cases are caused by air embolism (**Falterman 2001**), fat embolism (**Fedullo 2003**), powder in users of IV drugs, and rarely amniotic fluid (**Ferrari 1997**).

Risk factors

The risk of acute PE is increased whenever there is prolonged immobility due to bed rest, immobilization of the limbs by plaster or restraints, prolonged time in the same position (e.g., long airplane trips), and in cases of advanced cancer. Deep venous thrombosis is classically related to three general causes known as Virchow's triad: *alterations in blood flow, factors in the vessel wall, and factors affecting the properties of blood*. Often, one or more of these conditions is present. Specific clinical situations increasing risk of pulmonary embolism include extensive burns and trauma, neoplasms (due to production of procoagulants), prolonged obstetrical labor and delivery, family history of clotting disorders or genetic thrombophilia (factor V Leiden, prothrombin G20210A mutations, protein C deficiency, protein S deficiency, antithrombin deficiency, plasminogen and fibrinolytic disorders), acquired thrombophilia (antiphospholipid syndrome, nephrotic syndrome, paroxysmal nocturnal hemoglobinuria), bone fractures especially in the hip and femur, myocardial infarction, heart failure, major surgery including heart, orthopedic or neurological surgery, sequelae from stroke, age above 40 years, previous venous thrombosis, use of contraceptive pills and therapy with estrogen, obesity and smoking. The most common sources of embolic material are the lower extremities with formation of deep proximal vein thrombosis (PVT) or pelvic vein thrombosis. Any risk factor for deep venous thrombosis also increases the risk for pulmonary embolism which may occur in up to 15% of all PVTs. Deep vein thrombosis in the extremities and pelvis is common even in patients without active cancer and is associated with high rates of recurrence. Considerable effort is often needed to prevent and reduce these recurrences (**Goldhaber 1992**).

Symptoms and signs

The symptoms of acute PE are typically of sudden onset and include dyspnea, tachypnea, pleuritic chest pain (worsened with inspiration), palpitations, coughing, and hemoptysis. More severe cases may include cyanosis of the lips and fingers (acrocyanosis), syncope or presyncope due to hemodynamic instability with abnormally low blood pressure, and SCD. Approximately 15% of all SCD cases are attributed to acute PE (**Cooksey 1977**). 30-day mortality may be higher among patients with syncope. It is important to risk stratify patients on admission in order to reduce mortality and morbidity associated with lethal disease. (**Iqbal 2017**)

Three clinical presentations may occur as a result of acute PE:

- 1) Pulmonary infarction: pleuritic pain, dyspnea, hemoptysis, and pleural friction rub;
- 2) Acute cor pulmonale: sudden dyspnea, cyanosis, right heart failure, hypotension, and shock;
- 3) Unexplained dyspnea.

Physical examination

The lungs are generally normal to auscultation. Occasionally a pleural friction rub is audible on the affected area of the lung especially in the setting of pulmonary infarction. Transudative pleural effusion is sometimes detectable by decrease in percussion, loud murmur and vocal resonance. Pulmonary artery hypertension may be detected by a loud-sounding pulmonary component in the second heart sound and increase in jugular venous pressure. Low fever may be present, particularly if there is pulmonary bleeding associated with infarction (**Karlen 1956**). Right ventricle failure may occur which results in peripheral edema, liver congestion, and possible mild jaundice and ascites.

Diagnosis

The diagnosis is based on the clinical history, symptoms, physical findings and simple lab tests including arterial oxygen saturation, chest X-ray, serial ECGs, echocardiography and Doppler ultrasound of the lower extremities. The most important reason to perform a venous Doppler scan of the lower limbs is to identify venous blood clots in the leg veins as a source of thromboemboli. Arterial blood gases (low specificity and moderate sensitivity), electrocardiography, and chest X-rays have limitations in the diagnosis of acute PE, but they are essential in ruling out other serious clinical diagnoses that lead to emergency room visits.

At present diagnostic confirmation is made by a helical chest CT scan. The list of vascular diseases in the chest has been reduced to three clinical situations where chest CT is considered fundamental (**Khan 2005**):

- 1) **Aorta dissection and variants, intramural hematoma and penetrating atherosclerotic ulcer;**
- 2) **Acute pulmonary thromboembolism: acute PE**
- 3) **Coronary artery disease (CAD).**

The spatial resolution of multidetector CT is such that CT has become the imaging modality of choice for detecting aortic dissection and acute PE. The use of angiography has decreased significantly over the last decade except for the evaluation of CAD.

The diagnosis of acute PE is frequently a challenge due to its frequent nonspecific and varied clinical presentations. According to data from the registry of Prospective Investigation of Pulmonary Embolism Diagnosis (PIOPED), the diagnosis is only made in 70% of the cases. The most important aspect is a clinical suspicion based on an awareness of predisposing conditions and pro-thrombotic risk factors as well as a history of current or previous deep venous thrombosis (**Cooksey 1977**).

The clinical presentation along with the findings from the history and physical examination allow the diagnosis to be made with high, medium or low probability. The Wells score is the most commonly used method to predict the clinical probability of acute PE (**Kosuge 2006**). The initial score was modified three years later in 2000 by Wells himself (**Laack 2004**), and a new review published with the aim of simplifying the prediction (**Lassnig 2005**). Wells et al proposed two different scoring systems using 2 or 4 cutoff points with the same prediction rule. In 2001, Wells et al (**Wells 2001**) published results using clinical criteria and the D-dimer test which measures a product of fibrin degradation. A positive D-dimer test has a high sensitivity (95%) but a low specificity (40-68%) and is important in ruling out acute PE in low risk patients. When measured with the ELISA method it has a high negative predictive value. Troponins and natriuretic peptides are important for the prognostic evaluation and estimating the severity of the event.

An additional version, called the “extended modified version”, uses the more recent cutoff of 2 points but also includes the results of the initial studies. More recently a more in-depth study used a clinical algorithm, D-dimer and CT scan. The authors concluded that the diagnosis management strategy using a simple clinical rule, the D-dimer test and CT scan was efficient in the assessment and treatment of patients with clinical suspicion of acute PE. Using this strategy to rule out acute PE showed a low risk for subsequent fatal and nonfatal recurrent acute PE.

The Wells criteria for diagnosis of acute PE include the following:

- Clinical suspicion of deep venous thrombosis (DVT) = 3 points.
- Clinical suspicion of thromboembolic venous disease: 3.0 points.
- An alternative diagnosis is less likely than acute PE: 3.0 points.
- Tachycardia (heart rate >100): 1.5 points.
- Immobilization (≥ 3 days) or surgery in the previous four weeks: 1.5 points.
- History of DVT or acute PE: 1.5 points.
- Hemoptysis: 1.0 points.
- Malignant disease (with treatment for a term of 6 months) or palliative: 1.0 points.
 - **Traditional interpretation**
 - Score >6.0: high (probability of 59% based on the data obtained)
 - Score 2.0 to 6.0: moderate (probability of 29% based on the data obtained).
 - Score <2.0: low (probability of 15% based on grouped data).
 - **Alternative interpretation**
 - Score >4: probable acute PE. Consider diagnostic imaging.
 - ✓ Rate of ≤ 4 : acute PE unlikely

Clinical characteristics of patients with suspected acute PE in the emergency department (Pollack 2011).

Feature	PE confirmed (n = 1880)	PE not confirmed (n = 528)
Dyspnoea	50%	51%
Pleuritic chest pain	39%	28%
Cough	23%	23%
Substernal chest pain	15%	17%
Fever	10%	10%
Haemoptysis	8%	4%
Syncope	6%	6%
Unilateral leg pain	6%	5%
Signs of DVT (unilateral extremity swelling)	24%	18%

DVT= deep vein thrombosis.

ECG and acute PE

There are no specific diagnostic criteria for this entity due to the low sensitivity and specificity the ECG findings. The ECG changes are variable and frequently dynamic as a result of the underlying cardiopulmonary pathophysiology, severity of the thromboembolic event, and the degree of hemodynamic instability (**Kosuge 2006; Sarin 2005**).

Causes of the ECG modifications in acute PE

The ECG changes usually appear early, are transient and are always the consequence of one or more of the following factors:

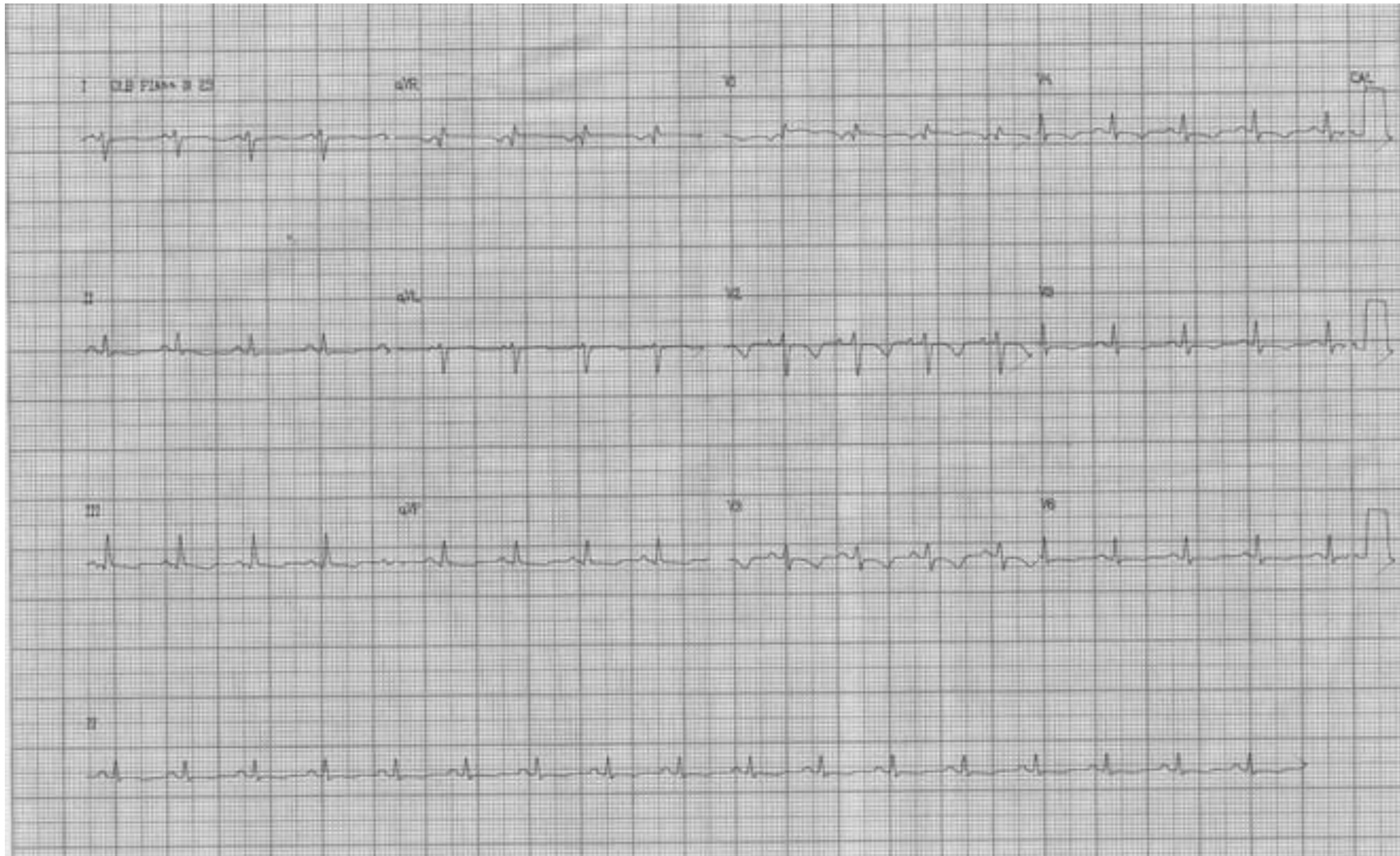- a) Acute pulmonary hypertension with systolic RV enlargement:
 - Sudden position changes of the heart: clockwise rotation on its longitudinal axis (from the tip to the base); observers watching the heart from the bottom up see the clockwise rotation. The RV volume increases pushing the LV backwards. As a result the precordial QRS transition (RS complex) is shifted leftwards and rS patterns continue up to V_4 in moderate clockwise rotation or beyond V_4 in more advanced rotations. The QRS loop is inscribed more rightwards with the electrical axis between $+90^\circ$ and $+130^\circ$. The first vector moves upward and leftwards resulting in q waves in lead III and the fourth vector moves upward and to the right generating S waves in lead I resulting in the typical SI-QIII pattern. This typical rotation is frequently seen in asthenic individuals with more vertically oriented hearts as well as in cases of right ventricular hypertrophy.
 - Diaphragmatic descent: The $\hat{S}\hat{A}\hat{Q}\hat{R}\hat{S}$ shifts to the right in the FP (beyond $+110^\circ$ in adults).
- b) Diastolic RV enlargement: an ECG pattern of transient incomplete or complete right bundle branch block due or sudden increase in RV diastolic pressure and volume with distal stretching of the branch in the moderator band: *peripheral* RBBB.
- c) Right atrial dilatation: this results in a qR pattern in V_1 (Sodi's sign) (**Sodi Pallares 1952**), the appearance of atrial arrhythmias including multifocal premature atrial contractions, acute atrial fibrillation, atrial flutter, etc.
- d) Low voltage electrical forces are often seen in the frontal plane leads due to the posterior shifting of the $\hat{S}\hat{A}\hat{Q}\hat{R}\hat{S}$ perpendicularly to this plane such as the present case.**
- e) Hypoxia and ischemia secondary to coronary artery spasm results in ST segment and T wave alterations and various arrhythmias.

Electrocardiographic abnormalities are found in 70% of acute PE cases (**Cheng 2005**). The ECG in this clinical entity is of great value and is useful in ruling out other pathologies with similar clinical presentation such as acute coronary syndrome and pericarditis. The ECG findings, however, are quite variable and include alterations in heart rate, rhythm, conduction and repolarization; the ECG may also remain within normal limits (**Punukollu 2005**).

The classic SI-QIII-TIII pattern, described by McGinn and White in 1935, is considered specific for acute PE but is infrequent in the initial presentation. It occurs more frequently in patients with acute massive acute PE with right ventricular (RV) enlargement and acute cor pulmonale. T wave inversion in III, aVF and right precordial leads is most frequently associated with massive acute PE and/or acute RV dysfunction. In a study by Ferrari et al (**Ferrari 1997**) these findings have the best sensitivity, specificity, positive and negative predictive value for the diagnosis of acute PE. They also better correlated with the severity of the event (greater vascular-pulmonary occlusion). Also the resolution of these T wave abnormalities (ECG normalization) before the 6th day of evolution was associated with a better prognosis and a higher level of therapeutic efficacy (as in this case). The ECG, therefore, is an important tool when suspecting massive or sub-massive acute acute PE as well as in following the response to therapy and in assessing prognosis in patients in whom this diagnosis has been confirmed.

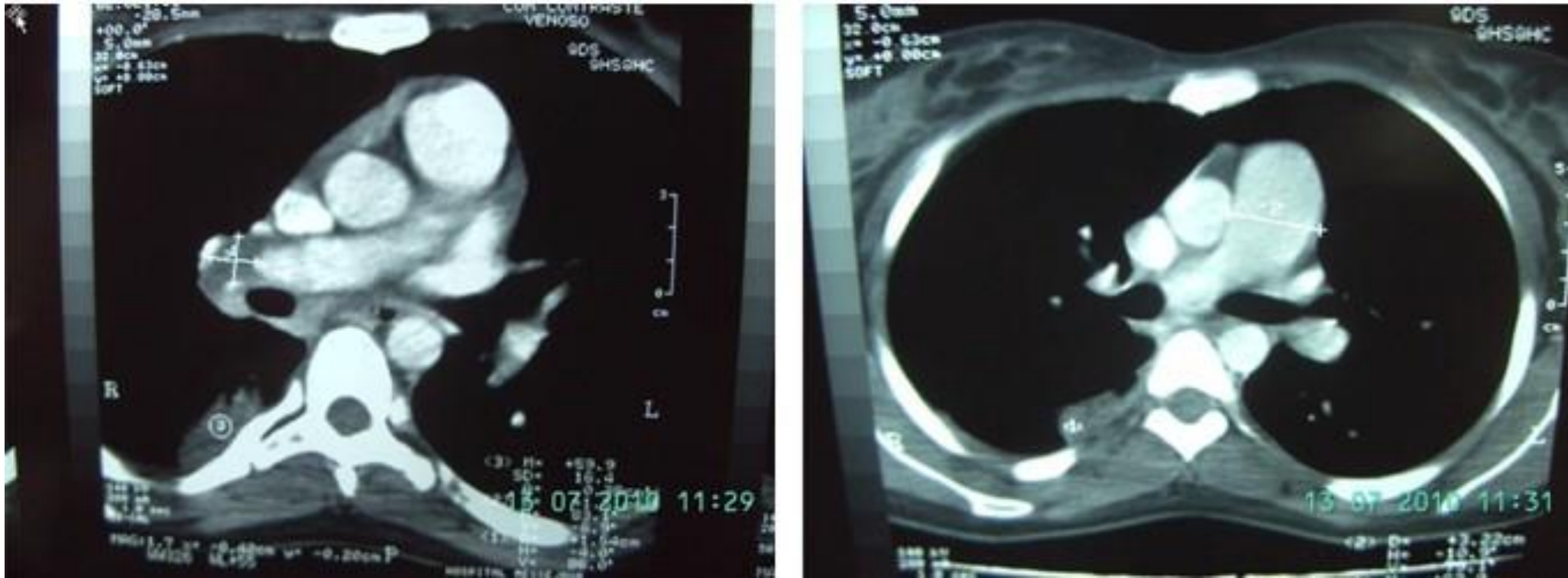
Several explanations were suggested to clarify frequent T wave alterations in massive or sub-massive acute PE. The exact mechanism of the inferior and anterior subendocardial ischemic pattern is still not completely clarified. Initially it was suggested that the acute increase in RV pressure associated with compromised left ventricular filling and cardiac output drop resulted in reduced coronary perfusion primarily affecting the right ventricle. Opposing this theory, however, most of the studies of using scintigraphy did not show RV ischemia, except in very late stages of the pathological process (**Ferrari 1997**). It is more likely that other factors associated with severe pulmonary thromboembolism are responsible for the ECG abnormalities. These include hypoxia, endothelial dysfunction, platelet activation, and release of histamine, serotonin and catecholamines that affect cellular metabolic alterations, especially the inhibition of glycolytic enzymes in myocardial cells (**Kosuge 2006; Punukollu2005**).

The T wave represents the sum of the repolarization wave fronts originating in the right and left ventricles. When the right ventricle enlarges due to pulmonary hypertension and acute PE, repolarization wave fronts become altered most likely due to recruitment of slow potassium channels. The T wave vector is directed superior and to the back with T wave inversion in the inferior (II, III, aVF) and anterior leads (frequently V₁-V₄) especially in cases of severe acute PE as illustrated in the next case Figure slide 35 (**Khan2005; Lassnig 2005**). In the following case the diagnosis of acute PE was confirmed by computed tomography (figure slide 36). This 20-year-old female was admitted to the ER with sudden onset of severe chest pain and dyspnea. The echocardiogram revealed increase in the right chambers, dilatation of the pulmonary artery trunk and signs of pulmonary hypertension (SPAP=78 mmHg).



Electrocardiographic diagnosis: sinus tachycardia, low QRS voltage, QRS axis $+120^\circ$ (isoelectric in aVR and positive in III), S_I - Q_{III} - T_{III} pattern associated with T wave inversion in the inferior and anterior leads which suggest acute RV strain.

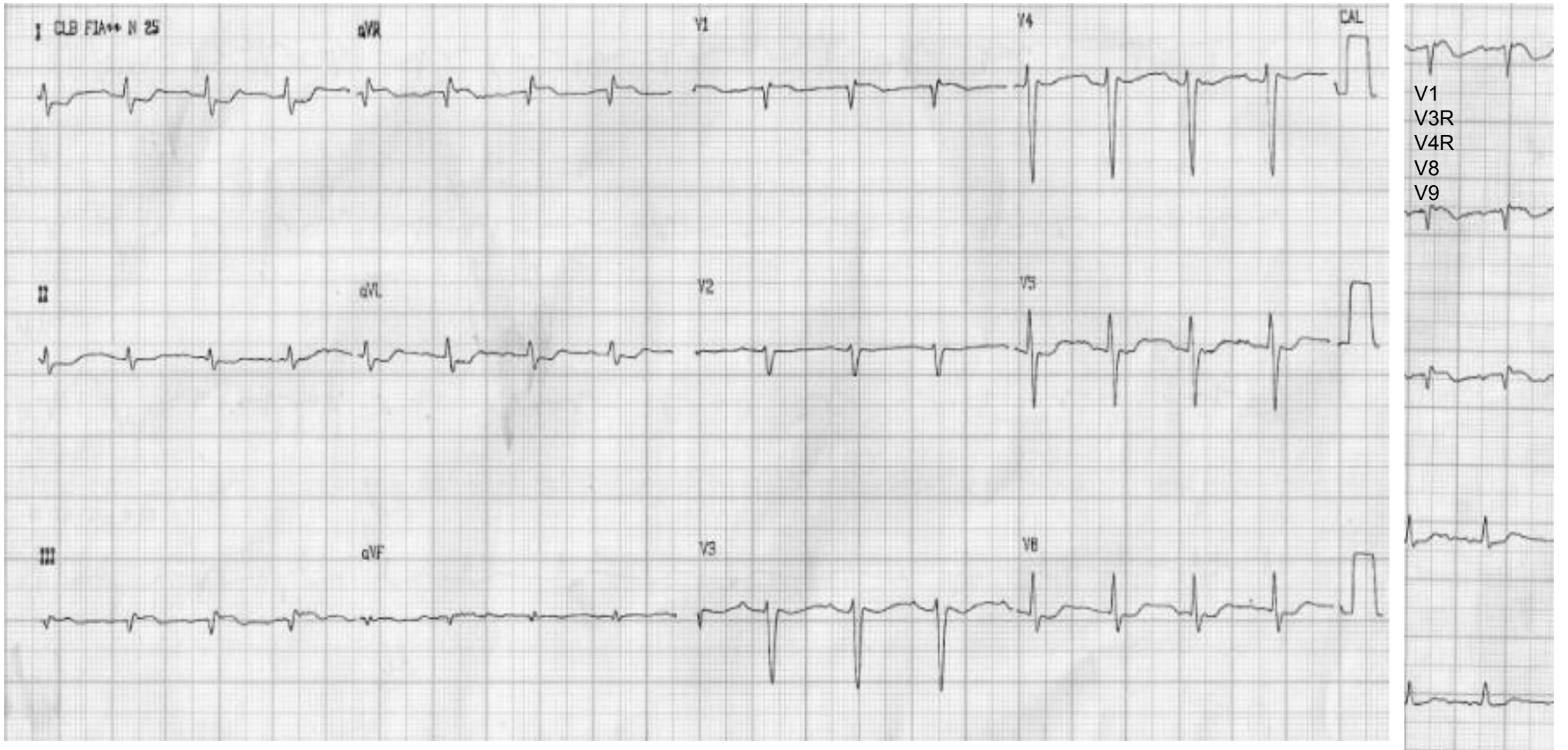
CT scan



Presence of thrombus at the level of the right pulmonary artery; increase of pulmonary artery trunk diameter (3.22 cm).

ST segment elevation in the precordial leads is a rare manifestation of acute PE and there are only a few reported cases in literature (**Kosuge 2006; Punukollu 2005**). The mechanism is unknown although some authors believe that paradoxical coronary embolism would be the most likely explanation (24). Others attribute the ischemic ECG pattern to hypotension and decreased myocardial perfusion due to reduced RV filling and LV preload. Other theories include ischemia induced by catecholamine-histamine release, and coronary spasm secondary to hypoxemia (**Falterman 2001; Cheng 2005**).

Another case is illustrated in the next slide. In addition to the $S_IQ_{III}T_{III}$ pattern, ST segment elevation is observed in leads III, V_1 , and right sided V_3R and V_4R resembling acute inferior myocardial infarction with RV involvement. ST segment depression is also present in the lateral leads. Coronary angiography was normal. Echocardiogram revealed right ventricular dilatation and dysfunction. The CT scan performed urgently confirmed the presence of thrombi in both pulmonary artery branches.



Electrocardiographic diagnosis: sinus tachycardia, S_I-Q_{III}-T_{III} pattern, ST segment elevation in III, V₁ and right precordial leads (V_{3R}, V_{4R}).

Main electrocardiographic modifications in acute pulmonary thromboembolism

Normal tracing: in $\approx 30\%$ of the patients (low sensitivity) (**Cheng 2005**)

Sinus tachycardia (observed in 37% to 47%). Sinus rhythm remains in 70% of the cases as a consequence of hypoxia and different degrees of increased sympathetic tone.

Arrhythmias are observed in $\approx 20\%$ of the cases: transient atrial or supraventricular tachycardia, multifocal premature atrial contractions, junctional tachycardia, different degrees of sinoatrial block, nodal rhythm, AV dissociation, sinus arrest and possible acute AFor atrial flutter ($\approx 5\%$).

Peaked P waves in the inferior leads; however, not reaching a voltage of 2.5 mm.

P waves of increased voltage ≥ 2.5 mm in II and ≥ 1.5 mm in V_1 "P- pulmonale" are rarely seen

A shift in the SAP to the right is very significant in the cases where a previous ECG prior to the embolic event is present (**Moffa 1997 29**).

QRS electrical axis is shifted rightward or becomes indeterminate, and low voltage of QRS complexes (< 5 mm) may appear in limb leads.

Extreme QRS axis shift to the left ($\geq -30^\circ$) seems to be twice as common as the shift to the right and is caused by stretching in the. LAFB (**Lynch 1972**).

Transient incomplete right bundle branch block (IRBBB).

Transient complete right bundle branch block (CRBBB) ($\approx 10\%$ of the cases). In massive acute PE CRBBB may be seen in up to 80-90% of cases. Transient IRBBB or CRBBB associated with ST segment elevation and negative T waves in V_1 is due to compression of the right bundle branch trunk by sudden RV outflow tract dilatation (focal neuropraxic block) or sudden RV dilatation with distal stretching of the branch in the moderator band. Peripheral RBBB.

Possible appearance of Q waves of pseudo-infarction in anteroseptal or inferior leads due to clockwise rotation and/or downward shift of the heart by descent of the diaphragm. These changes may also be found in chronic cor-pulmonale and pneumothorax. Deep Q waves of acute pulmonary embolism are observed more often in lead III, less frequently in aVF, and never in II and is accompanied by S wave in I. The differential diagnosis with acute myocardial infarction may be quite difficult (**Cooksey 1977**).

Qr or qR pattern in V_1 with $Q \geq 2$ mm (19%). qR pattern in V_1 is often a direct sign of RAE by chamber dilatation.

SI, SII, SIII pattern: S waves with depth ≥ 15 mm.

Pattern of McGinn White observed in $\approx 30\%$ of the cases.

Signs of RVH: $R > 5$ mm or $R/S \geq 1$ in V_1 .

Possible S wave in I and aVL with depth greater than 1.5 mm.

Clockwise rotation of the heart around its longitudinal axis with shift of transition area to the left (in V_5 or V_6) ($R = S$ or isoelectric complex) to the left in the precordium: the normal transition is usually in V_3 or V_4 . Occasionally, an isoelectric QRS does not occur in any precordial lead, with rS pattern remaining up to V_6 , and Qr, QR, qr or QS pattern possibly appearing.

Low voltage of QRS complexes in the limb leads: ≤ 5 mm.

ST segment elevation ≥ 1 mm in one or more leads, except in aVR in the absence of bundle branch block or ventricular hypertrophy.

Negative T waves in one or more leads except in aVR, aVL, III and V_1 without bundle branch block and ventricular hypertrophy.

The presence of three or more of the following ECG signs indicate a high probability of acute PE (**Sreeram 1994**):

- $\hat{S}\hat{A}\hat{Q}\hat{R}\hat{S}$ shift to the right $\geq +90^\circ$.
- Low QRS voltage (<5 mm) in the frontal plane.
- Late QRS Transition in V_5 .
- Large S waves in I and aVL >15 mm.
- $S_1 Q_3$ or $S_1 Q_3 T_3$ pattern.
- Transient incomplete or complete right bundle branch block associated with ST segment elevation and positive T wave in V_1 ;
- Negative T wave in II and aVL or from V_1 through V_4 ;
- Inverted ischemic T waves in the right precordial leads (*) (Modified from (**MacFarlane 1989**)).

(*) These electrocardiographic criteria associated with predisposing factors of deep venous thrombosis, age above 40 years, obesity, history of previous thromboembolism, cancer, patient in bed for more than five days, and signs of acute right heart failure (neck vein distention, gallop rhythm, tachypnea and tachycardia) are highly suggestive of acute PE (**Goldhaber1992**).

Other nonspecific elements frequently found are (enhanced from (**Chou 1986**)):

- Sinus tachycardia or unexplained atrial fibrillation;
- P pulmonale or peaked P waves <2.5 mm;
- $\hat{S}\hat{A}\hat{P}$ shift to the right;
- Extreme $\hat{A}\hat{Q}\hat{R}\hat{S}$ shift to the left;
- First degree AV block;
- Dextrorotation in longitudinal axis and shift of the transition area to the left (present in 36% of the cases);
- More vertical shift of the heart
- Possible presence of SI-SII-SIII pattern, QR or QS pattern in V_3R , V_1 and V_2 with T inversion: pseudo anteroseptal infarction;
- R wave >0.5 mV or R/S ratio >1 in V_1 ;
- Pseudo inferior infarction pattern;
- Ascending ST segment with staircase aspect in leads I or II;
- ST segment elevation in lead III;
- ST segment elevation or depression in the right precordial leads and T wave inversion (40%);
- Nonspecific modifications of the ST segment and T wave in left precordial leads;
- Vectorcardiographic (VCG) changes with characteristic location of the final vectors to the right, posterior and superior (type C RVH).

Differential diagnosis of the inferior myocardial infarction (MI) manifested as Q waves in inferior leads in cases of acute PE

Deep Q waves in cases of acute PE is sometimes observed in lead III, less frequently in aVF, never in II and is frequently accompanied by S waves with depth greater than 1.5 mm in leads I and aVL. In contrast, in coronary disease with an inferior EIA, residual pathological Q wave in are seen in all three leads in 65 to 70% of cases, in 15% only in III, in 25% only in aVF, and in 25 to 30% III and aVF. The ECG criteria for pathologic Q or q waves characteristic of electrically inactive areas are duration ≥ 40 ms, depth (voltage) equal ≥ 2 mm (except in III where Q waves up to 6 mm can still be normal) and Q/R ratio greater than 25%.

The greatest diagnostic problem arises when both acute PE and inferior EIA manifest q or Q waves only in leads III and aVF. In both cases of acute PE and inferior myocardial infarction this ECG finding may be seen. If in doubt the vectorcardiogram may contribute to differentiate these two conditions. In myocardial infarction with an inferior EIA the frontal plane VCG is characterized by:

- a) QRS loop with characteristic clockwise rotation from right to left (at least 80% of the loop rotating clockwise);
- b) Abnormal upward shift of the initial 20 to 40 ms vectors (at least 25 ms).
- c) The time from point zero to the intersection with the X line should be at least 25 ms; for this reason, if each dash were 2 ms, there should be more than 12 dashes above the X line;
- d) The maximal vector may range from -40° to $+30^\circ$; however, it is usually less than $+15^\circ$.
- e) Characteristic inferior concavity of forces from the initial 20 to 40 ms.
- f) The forces of the initial 10 ms may have a superior orientation (group I of Young and Williams) or more rarely an inferior one (group II).
- g) Possible alterations in the mid-final portion of the QRS loop (afferent branch), called by Young et al (**Young 1968**), as types A, B, C and D deformities present in quadrant I of the FP. This sign is useful in cases where the previous criteria are doubtful or absent.

The differential diagnosis of the anteroseptal MI of Q waves in the inferior leads in acute PE

Acute PE may cause modifications in the ECG that may be confused with anteroseptal MI. These modifications are:

- 1) T wave inversion from V1 to V3 or more rarely from V1 through V4. This manifestation is estimated to be present in 40% of cases of acute pulmonary embolism, and may be persistent (lasting up to 40 days).
- 2) Discrete ST segment elevation in the same precordial leads. This phenomenon is less frequently found (11%);
- 3) Association of both ST and T wave changes is present in 54%. These changes found in acute PE are attributed to RV strain with sudden enlargement of the chamber, as well as subendocardial ischemia secondary to drop in coronary perfusion pressure by shock; in addition arterial hypoxemia always present.

- 4) Qr, QR or Qs pattern in V_3R , V_1 and V_2 , resembling mid-septal necrosis, even more emphasized if ST segment elevation and T inversion are present in these leads.
- 5) Regression of R/S ratio along the precordial leads. Normally, the R/S ratio in the precordium from V_1 through V_4 is progressive; i.e. r increases its voltage. The phenomenon of the R/S ratio regression is due to selective hypertrophy of the basal posterior region of the RV (vector 3), with r decreasing from V_1 to V_3 .

Anteroseptal MI if concomitantly, $S\hat{A}QRS$ is at the right with S of I being >1 mm.

Acute PE may exist with chronic cor pulmonale and have the following ECG findings common:

- a) Signs of right atrial and right ventricular enlargement;
- b) Frequent clockwise rotation and more vertical orientation of the heart;
- c) Inverted T waves in the right precordial leads.

They are differentiated by the fact that in acute PE the electrocardiographic modifications are transient, while in chronic cor pulmonale they are stable.

VCG in acute PE (**Karlen 1956**)

- 1) P loop in the three planes with frequent criteria for RAE;
- 2) Characteristic location of the final vectors with delay at the right, posterior and superior.
- 3) The magnitude of the final vector is always lower in types A or C RVH patterns in mitral stenosis or in chronic cor pulmonale (**Cooksey 1977**).

Treatment

Treatment of acute PE is generally anticoagulation, including IV unfractionated heparin in doses of 24,000 to 30,000 units over 24 h for 5 to 7 days. Unfractionated heparin could be administered in a continuous way beginning with an initial bolus of 80 U/kg followed by continuing infusion of 18 U/kg/h. In cases of intermittent administration, the dose is 5,000 U every 4 h with control of APTT before each dose, keeping 1.5 to 2.5 times the basal value.

Subcutaneously, the dose is 17,500 U every 12 h. Severe cases may require thrombolysis with tissue plasminogen activator (tPA) or may surgical intervention by pulmonary thrombectomy in the cases of massive acute PE, in those in whom anticoagulation is contraindicated or in those patients that remain unstable even with anticoagulation medication.

Vena cava filters are indicated to prevent recurrent acute PE in patients with contraindications to anticoagulation or in those with recurrent acute PE in spite of the anticoagulation treatment. In patients with severe cardiac or pulmonary dysfunction – situation of high risk of thromboembolism – the filter in the vena cava is recommended by some authors as well as in those referred to embolectomy.

Treatment in the acute phase

Haemodynamic and respiratory support

Acute RV failure with resulting low systemic output is the leading cause of death in patients with high-risk PE. Therefore, supportive treatment is vital in patients with PE and RV failure. Experimental studies indicate that aggressive volume expansion is of no benefit and may even worsen RV function by causing mechanical overstretch, or by reflex mechanisms that depress contractility. On the other hand, modest (500 mL) fluid challenge may help to increase cardiac index in patients with PE, low cardiac index, and normal BP.²⁶⁴ Use of vasopressors is often necessary, in parallel with (or while waiting for) pharmacological, surgical, or interventional reperfusion treatment. Norepinephrine appears to improve RV function via a direct positive inotropic effect, while also improving RV coronary perfusion by peripheral vascular alpha-receptor stimulation and the increase in systemic BP. Its use should probably be limited to hypotensive patients. Based on the results of small series, the use of dobutamine and/or dopamine may be considered for patients with PE, low cardiac index, and normal BP; however, raising the cardiac index above physiological values may aggravate the ventilation–perfusion mismatch by further redistributing flow from (partly) obstructed to unobstructed vessels. Epinephrine combines the beneficial properties of norepinephrine and dobutamine, without the systemic vasodilatory effects of the latter. It may therefore exert beneficial effects in patients with PE and shock. Vasodilators decrease pulmonary arterial pressure and pulmonary vascular resistance, but the main concern is the lack of specificity of these drugs for the pulmonary vasculature after systemic (intravenous) administration. According to data from small clinical studies, inhalation of nitric oxide may improve the haemodynamic status and gas exchange of patients with PE. Preliminary data suggest that levosimendan may restore right ventricular–pulmonary arterial coupling in acute PE by combining pulmonary

vasodilation with an increase in RV contractility. Hypoxaemia and hypocapnia are frequently encountered in patients with PE, but they are of moderate severity in most cases. A patent foramen ovale may aggravate hypoxaemia due to shunting when right atrial- exceeds left atrial pressure. Hypoxaemia is usually reversed with administration of oxygen. When mechanical ventilation is required, care should be taken to limit its adverse haemodynamic effects. In particular, the positive intrathoracic pressure induced by mechanical ventilation may reduce venous return and worsen RV failure in patients with massive PE; therefore, positive end-expiratory pressure should be applied with caution. Low tidal volumes (approximately 6 mL/kg lean body weight) should be used in an attempt to keep the end-inspiratory plateau pressure, cm H₂O. Experimental evidence suggests that extracorporeal cardiopulmonary support can be an effective procedure in massive PE. This notion is supported by occasional case reports and patient series.

Anticoagulation

In patients with acute PE, anticoagulation is recommended, with the objective of preventing both early death and recurrent symptomatic or fatal VTE. The standard duration of anticoagulation should cover at least 3 months (also see Section 6). Within this period, acute-phase treatment consists of administering parenteral anticoagulation [unfractionated heparin (UFH), low molecular weight heparin (LMWH), or fondaparinux] over the first 5–10 days. Parenteral heparin should overlap with the initiation of a vitamin K antagonist (VKA); alternatively, it can be followed by administration of one of the new oral anticoagulants: dabigatran or edoxaban. If rivaroxaban or apixaban is given instead, oral treatment with one of these agents should be started directly or after a 1–2 day administration of UFH, LMWH or fondaparinux. In this latter case, acute-phase treatment consists of an increased dose of the oral anticoagulant over the first 3 weeks (for rivaroxaban), or over the first 7 days (for apixaban). In some cases, extended anticoagulation beyond the first 3 months, or even indefinitely, may be necessary for secondary prevention, after weighing the individual patient's risk of recurrence vs. bleeding risk.

Parenteral anticoagulation

In patients with high or intermediate clinical probability for PE, parenteral anticoagulation should be initiated whilst awaiting the results of diagnostic tests. Immediate anticoagulation can be achieved with parenteral anticoagulants such as intravenous UFH, subcutaneous LMWH, or subcutaneous fondaparinux. LMWH or fondaparinux are preferred over UFH for initial anticoagulation in PE, as they carry a lower risk of inducing major bleeding and heparin-induced thrombocytopenia (HIT). On the other hand, UFH is recommended for patients in whom primary reperfusion is considered, as well as for those with serious renal impairment (creatinine clearance, 30 mL/min), or severe obesity. These recommendations are based on the short half-life of UFH, the ease of monitoring its anticoagulant effects, and its rapid reversal by protamine. The dosing of UFH is adjusted, based on the activated partial thromboplastin time. LMWH needs no routine monitoring, but periodic measurement of anti-factor Xa activity (anti-Xa levels) may be considered during pregnancy. Peak values of anti-factor Xa activity should be measured 4 hours

after the last injection and trough values just before the next dose of LMWH would be due; the target range is 0.6–1.0 IU/mL for twice-daily administration, and 1.0–2.0 IU/mL for once-daily administration. Fondaparinux is a selective factor Xa inhibitor administered once daily by subcutaneous injection at weight-adjusted doses, without the need for monitoring. In patients with acute PE and no indication for thrombolytic therapy, fondaparinux was associated with recurrent VTE and major bleeding rates similar to those obtained with intravenous UFH. No proven cases of HIT have been reported with fondaparinux. Subcutaneous fondaparinux is contraindicated in patients with severe renal insufficiency (creatinine clearance <30 mL/min) because it will accumulate and increase the risk of haemorrhage. Accumulation also occurs in patients with moderate renal insufficiency (clearance 30–50 mL/min) and, therefore, the dose should be reduced by 50% in these patients.

Vitamin K antagonists

Oral anticoagulants should be initiated as soon as possible, and preferably on the same day as the parenteral anticoagulant. VKAs have been the ‘gold standard’ in oral anticoagulation for more than 50 years and warfarin, acenocoumarol, phenprocoumon, phenindione and flunidione remain the predominant anticoagulants prescribed for PE. Anticoagulation with UFH, LMWH, or fondaparinux should be continued for at least 5 days and until the international normalized ratio (INR) has been 2.0–3.0 for two consecutive days. Warfarin can be started at a dose of 10 mg in younger (e.g. >60 years of age), otherwise healthy outpatients, and at a dose of 5 mg in older patients and in those who are hospitalized. The daily dose is adjusted according to the INR over the next 5–7 days, aiming for an INR level of 2.0–3.0. Rapid-turnaround pharmacogenetic testing may increase the precision of warfarin dosing. In particular, variations in two genes may account for more than one-third of the dosing variability of warfarin. One gene determines the activity of cytochrome CYP2C9, the hepatic isoenzyme that metabolizes the S-enantiomer of warfarin into its inactive form, while the other determines the activity of vitamin K epoxide reductase, the enzyme that produces the active form of vitamin K. Pharmacogenetic algorithms incorporate genotype and clinical information and recommend warfarin doses according to integration of these data. A trial published in 2012 indicated that, compared with standard care, pharmacogenetic guidance of warfarin dosing resulted in a 10% absolute reduction in out-of-range INRs at one month, primarily due to fewer INR values >1.5 ; this improvement coincided with a 66% lower rate of DVT. In 2013, three large randomized trials were published. All used, as the primary endpoint, the percentage of time in therapeutic range (TTR) (a surrogate for the quality of anticoagulation) for the INR during the first 4–12 weeks of therapy. In 455 patients, genotype-guided doses of warfarin, with a point-of-care test, resulted in a significant but modest increase in TTR over the first 12 weeks, compared with a fixed 3-day loading dose regimen (67.4% vs. 60.3%; $P < 0.001$). The median time to reaching a therapeutic INR was reduced from 29 to 21 days. Another study in 1015 patients compared warfarin loading—based on genotype data in combination with clinical variables—with a loading regimen based on the clinical data alone; no significant improvement was found in either group in terms of the TTR achieved between days 4 and 28 of therapy. Lack of improvement was also shown by a trial involving 548 patients, comparing acenocoumarol or phenprocoumon loading—based on point-of-care

genotyping in combination with clinical variables (age, sex, height, weight, amiodarone use)—with a loading regimen based entirely on clinical information. In summary, the results of recent trials appear to indicate that pharmacogenetic testing, used on top of clinical parameters, does not improve the quality of anticoagulation. They also suggest that dosing based on the patient's clinical data is possibly superior to fixed loading regimens, and they point out the need to place emphasis on improving the infrastructure of anticoagulation management by optimizing the procedures that link INR measurement with provision of feedback to the patient and individually tailoring dose adjustments.

New oral anticoagulants

The design and principal findings of phase III clinical trials on the acute phase treatment and standard duration of anticoagulation after acute PE or VTE with non-vitamin K-dependent new oral anticoagulants (NOACs). In the re-cover trial, the direct thrombin inhibitor dabigatran was compared with warfarin for the treatment of VTE. The primary outcome was the 6-month incidence of recurrent, symptomatic, objectively confirmed VTE. Overall, 2539 patients were enrolled, 21% with PE only and 9.6% with PE plus DVT. Parenteral anticoagulation was administered for a mean of 10 days in both groups. With regard to the efficacy endpoint, dabigatran was non-inferior to warfarin. No significant differences were observed with regard to major bleeding episodes, but there were fewer episodes of any bleeding with dabigatran. Its twin study, re-cover II, enrolled 2589 patients and confirmed these results. For the pooled re-cover population, the HR for efficacy was 1.09 and for major bleeding 0.73. In the EINSTEIN-DVT and EINSTEIN-PE trials, single oral drug treatment with the direct factor Xa inhibitor rivaroxaban (15 mg twice daily for 3 weeks, followed by 20 mg once daily) was tested against enoxaparin/warfarin in patients with VTE using a randomized, open-label, non-inferiority design. In particular, EINSTEIN-PE enrolled 4832 patients who had acute symptomatic PE, with or without DVT. Rivaroxaban was non-inferior to standard therapy for the primary efficacy outcome of recurrent symptomatic VTE. The principal safety outcome [major or clinically relevant non-major (CRNM) bleeding] occurred with similar frequency in the two treatment groups, but major bleeding was less frequent in the rivaroxaban group, compared with the standard-therapy group. The Apixaban for the Initial Management of Pulmonary Embolism and Deep-Vein Thrombosis as First-line Therapy (AMPLIFY) study compared single oral drug treatment using the direct factor Xa inhibitor apixaban (10 mg twice daily for 7 days, followed by 5 mg once daily) with conventional therapy (enoxaparin/warfarin) in 5395 patients with acute VTE, 1836 of whom presented with PE. The primary efficacy outcome was recurrent symptomatic VTE or death related to VTE. The principal safety outcomes were major bleeding alone, and major bleeding plus CRNM bleeding. Apixaban was non-inferior to conventional therapy for the primary efficacy outcome. Major bleeding occurred less frequently under apixaban compared with conventional therapy. The composite outcome of major bleeding and CRNM bleeding occurred in 4.3% of the patients in the apixaban group, compared with 9.7% of those in the conventional-therapy group. The HokusaI–VTE study compared the direct factor Xa inhibitor edoxaban with conventional therapy in

8240 patients with acute VTE (3319 of whom presented with PE) who had initially received heparin for at least 5 days. Patients received edoxaban at a dose of 60 mg once daily (reduced to 30 mg once daily in the case of creatinine clearance of 30–50 mL/min or a body weight <60 kg), or warfarin. The study drug was administered for 3–12 months; all patients were followed up for 12 months. Edoxaban was non-inferior to warfarin with respect to the primary efficacy outcome of recurrent symptomatic VTE or fatal PE. The principal safety outcome, major or CRNM bleeding, occurred less frequently in the edoxaban group. In 938 patients who presented with acute PE and elevated NT-proBNP concentrations (≥ 500 pg/mL), the rate of recurrent VTE was 3.3% in the edoxaban group and 6.2% in the warfarin group. In summary, the results of the trials using NOACs in the treatment of VTE indicate that these agents are non-inferior (in terms of efficacy) and possibly safer (particularly in terms of major bleeding) than the standard heparin/VKA regimen. High TTR values were achieved under VKA treatment in all trials; on the other hand, the study populations included relatively young patients, very few of whom had cancer. At present, NOACs can be viewed as an alternative to standard treatment. At the moment of publication of these guidelines, rivaroxaban, dabigatran and apixaban are approved for treatment of VTE in the European Union; edoxaban is currently under regulatory review. Experience with NOACs is still limited but continues to accumulate. Practical recommendations for the handling of NOACs in different clinical scenarios and the management of their bleeding complications have recently been published by the European Heart Rhythm Association.

Thrombolytic treatment

Thrombolytic treatment of acute PE restores pulmonary perfusion more rapidly than anticoagulation with UFH alone. The early resolution of pulmonary obstruction leads to a prompt reduction in pulmonary artery pressure and resistance, with a concomitant improvement in RV function. The hemodynamic benefits of thrombolysis are confined to the first few days; in survivors, differences are no longer apparent at one week after treatment. The approved regimens of thrombolytic agents for acute PE. Accelerated regimens administered over 2 hours are preferable to prolonged infusions of first-generation thrombolytic agents over 12–24 hours. Reteplase and desmoteplase have been tested against recombinant tissue plasminogen activator (rtPA) in acute PE, with similar results in terms of hemodynamic parameters; tenecteplase was tested against placebo in patients with intermediate-risk PE. At present, none of these agents is approved for use in PE. Unfractionated heparin infusion should be stopped during administration of streptokinase or urokinase; it can be continued during rtPA infusion. In patients receiving LMWH or fondaparinux at the time that thrombolysis is initiated, infusion of UFH should be delayed until 12 hours after the last LMWH injection (given twice daily), or until 24 hours after the last LMWH or fondaparinux injection (given once daily). Given the bleeding risks associated with thrombolysis and the possibility that it may become necessary to immediately discontinue or reverse the anticoagulant effect of heparin, it appears reasonable to continue anticoagulation with UFH for several hours after the end of thrombolytic treatment before switching to LMWH or

fondaparinux. Overall, .90% of patients appear to respond favorably to thrombolysis, as judged by clinical and echocardiographic improvement within 36 hours. The greatest benefit is observed when treatment is initiated within 48 hours of symptom onset, but thrombolysis can still be useful in patients who have had symptoms for 6–14 days. A review of randomized trials performed before 2004 indicated that thrombolysis may be associated with a reduction in mortality or recurrent PE in high-risk patients who present with hemodynamic instability. In a recent epidemiological report, in-hospital mortality attributable to PE was lower in unstable patients who received thrombolytic therapy, compared with those who did not. Most contraindications to thrombolysis should be considered relative in patients with life-threatening, high-risk acute PE. In the absence of hemodynamic compromise at presentation, the clinical benefits of thrombolysis have remained controversial for many years. In a randomized comparison of heparin vs. alteplase in 256 normotensive patients with acute PE and evidence of RV dysfunction or pulmonary hypertension—obtained by clinical examination, echocardiography, or right heart catheterization—thrombolytic treatment (mainly secondary thrombolysis) reduced the incidence of escalation to emergency treatment, without affecting mortality. More recently, the Pulmonary Embolism Thrombolysis (PEITHO) trial was published. This was a multicenter, randomized, double-blind comparison of thrombolysis with a single weight-adapted intravenous bolus of tenecteplase plus heparin vs. placebo plus heparin. Patients with acute PE were eligible for the study if they had RV dysfunction, confirmed by echocardiography or CT angiography, and myocardial injury confirmed by a positive troponin I or -T test. A total of 1006 patients were enrolled. The primary efficacy outcome, a composite of all-cause death or hemodynamic decompensation/collapse within 7 days of randomization, was significantly reduced with tenecteplase. The benefit of thrombolysis was mainly driven by a significant reduction in the rate of hemodynamic collapse. In another randomized study comparing LMWH alone vs. LMWH plus an intravenous bolus of tenecteplase in intermediate-risk PE, patients treated with tenecteplase had fewer adverse outcomes, better functional capacity, and greater quality of life at 3 months. Thrombolytic treatment carries a risk of major bleeding, including intracranial hemorrhage. Analysis of pooled data from trials using various thrombolytic agents and regimens reported intracranial bleeding rates between 1.9% and 2.2%. Increasing age and the presence of comorbidities have been associated with a higher risk of bleeding complications. The PEITHO trial showed a 2% incidence of hemorrhagic stroke after thrombolytic treatment with tenecteplase (versus 0.2% in the placebo arm) in patients with intermediate-high-risk PE. Major non-intracranial bleeding events were also increased in the tenecteplase group, compared with placebo (6.3% vs. 1.5%; P, 0.001). These results underline the need to improve the safety of thrombolytic treatment in patients at increased risk of intracranial or other life-threatening bleeding. A strategy using reduced-dose rtPA appeared to be safe in the setting of ‘moderate’ PE in a study that included 121 patients, and another trial on 118 patients with hemodynamic instability or ‘massive pulmonary obstruction’ reported similar results. An alternative approach may consist of local, catheter-delivered, ultrasound-assisted thrombolysis using small doses of a thrombolytic agent. In patients with mobile right heart thrombi, the therapeutic benefits of thrombolysis remain controversial. Good results were reported in some series, but in other reports short-term mortality exceeded 20% despite thrombolysis.

Endovascular Management of Massive and Submassive Acute Pulmonary Embolism

Acute PE is a frequent condition associated with high morbidity and mortality. Prior studies have evaluated the role of systemic fibrinolysis and catheter-directed therapy (CDT) in the management of APE. Kosova et al, examined current data on risk stratification and the appropriate allocation of systemic fibrinolysis and CDT in acute PE patients with elevated risk of adverse outcomes. While systemic thrombolytics remain the frontline therapy for hemodynamically unstable PE patients, studies have suggested that CDT has a significant promise as the primary modality for treating hemodynamically stable patients at increased risk for clinical decompensation and as an alternative therapy for hemodynamically unstable patients who may not tolerate systemic thrombolytics. The appropriate use of CDT in patients with acute PE is dependent on accurate risk stratification. CDT offers the potential to reduce excessive bleeding while maintaining the efficacy of systemic thrombolytics, but will require data from larger randomized trials to support its use prior to widespread adoption as the frontline therapy for PE in patients at elevated risk of adverse outcomes. **(Kosova 2017)**

Surgical embolectomy for high-risk acute pulmonary embolism is standard therapy

Acute massive pulmonary embolism (AMPE) is a life-threatening condition that often induces rapid hemodynamic deterioration. The mortality of surgical embolectomy is still poor in patients with preoperative cardiopulmonary arrest (CPA). Shiomi et al analyzed the outcome of surgical pulmonary embolectomy for hemodynamically unstable patients. The authors concluded that surgical embolectomy for high-risk AMPE patients has an excellent operative mortality and long-term outcome. Preoperative percutaneous cardiopulmonary support (PCPS) may lead to an immediate stable hemodynamic state and improve surgical embolectomy results, especially in high-risk patients (e.g. those with preoperative CPA such as the present case). Surgical embolectomy for AMPE is an established operation and considered as the first-line therapy. **(Shiomi 2017)**

References

1. Aparicio G, Soler I, López-Durán L. Fat embolism syndrome after nailing an isolated open tibial fracture in a stable patient: a case report. *BMC Res Notes*. 2014;7(1):237.
2. Bossone E, Butera G, Bodini BD, Rubenfire M. The interpretation of the electrocardiogram in patients with pulmonary hypertension: the need for clinical correlation. *Ital Heart J*. 2003;4:850-854.
3. Bruch C, Schmermund A, Dages N, et al. Changes in QRS voltage in cardiac Tamponade and pericardial effusion: reversibility after pericardiocentesis and after anti-inflammatory drug treatment. 2001;38(1):219-26
4. Casale PN, Devereux RB, Kligfield P, Eisenberg RR, Phillips MC. Pericardial effusion: relation of clinical echocardiographic and electrocardiographic findings. *J Electrocardiol* 1984;17(2):115-21
5. Cheng ASH, Money-Kyrle A. Instructive ECG series in massive bilateral pulmonary embolism. *Heart* 2005;91(7):860-2.
6. Chinitz JS, Cooper JM, Verdino RJ. Electrocardiogram voltage discordance: interpretation of low QRS voltage only in the limb leads. *J Electrocardiol*. 2008;41(4):281-6.
7. Chou TC. *Electrocardiography in Clinical Practice*. 2nd ed. Orlando Florida: Grune and Stratton; 1986. P. 309-18.
8. Cooksey JD, Dunn M, Massie E. *Clinical Vectorcardiography and Electrocardiography*. 2nd ed. Chicago, Year Book Medical Publishers; 1977. P. 307-13.
9. Falterman TJ, Martinez JA, Daberkow D, et al. Pulmonary embolism with ST segment elevation in leads V1 to V4: case report and review of the literature regarding electrocardiographic changes in acute pulmonary embolism. *J Emerg Med* 2001;21(3):255-61.
10. Fedullo PF, Tapson VF. Clinical practice. The Evaluation of Suspected Pulmonary Embolism. *New Engl J Med*. 2003;349(13):1247-56.
11. Feldman T, Borow KM, Neumann A, Lang RM, Childers RW. Relation of electrocardiographic R-wave amplitude to changes in left ventricular chamber size and position in normal subjects. 1985;55(9):1168-74.
12. Ferrari E, Imbert A, Chevalier T, Mihoubi A, Morand P, Baudouy M. The ECG in pulmonary embolism. Predictive value of negative T waves in precordial leads – 80 case reports. *Chest*. 1997;111(3):537-43.
13. Goldhaber SZ, Morpurgo M. Diagnosis, treatment, and prevention of pulmonary embolism. Report of the WHO/International Society and Federation of Cardiology Task Force. *JAMA*. 1992;268(13):1727-33.
14. Hamer JP, Janssen S, van Rijswijk MH, Lie KI. Amyloid cardiomyopathy in systemic non-hereditary amyloidosis. *Eur Heart J*. 1992;13(5):623-7.

15. Iqbal U, Jameel A, Anwar H, Scribani MB, Bischof E, Chaudhary A. Does Syncope Predict Mortality in Patients With Acute Pulmonary Embolism? A Retrospective Review. *J Clin Med Res.* 2017;9(6):516-19.
16. Kamath SA, Meo Neto JP, Canham RM, et al. Low voltage on the electrocardiogram is a marker of disease severity and a risk factor for adverse outcomes in patients with heart failure due to systolic dysfunction. *Am Heart J* 2006 Aug;152(2):355-61.
17. Karlen WS, Wolff L. The vectorcardiogram in pulmonary embolism. II. *Am Heart J.* 1956;51(6):839-60.
18. Khan NUA, Movahed A. Pulmonary embolism and cardiac enzymes. *Heart Lung* 2005;34(2):142-6.
19. Kopeć G, Tyrka A, Miszalski-Jamka T, Sobień M, Waligóra M, Brózda M, Podolec P. Electrocardiogram for the diagnosis of right ventricular hypertrophy and dilation in idiopathic pulmonary arterial hypertension. *Circ J.* 2012;76(7):1744-9.
20. Kosova EC, Desai KR, Schimmel DR. Endovascular Management of Massive and Submassive Acute Pulmonary Embolism: Current Trends in Risk Stratification and Catheter-Directed Therapies. *urr Cardiol Rep.* 2017;19(6):54.
21. Kosuge M, Kimura K, Ishikawa T et al. Prognostic Significance of Inverted T Waves in Patients With Acute Pulmonary Embolism. *Circ J* 2006;70(6):750-5.
22. Laack TA, Goyal DG. Pulmonary embolism: an unsuspected killer. *Emerg Med Clin North Am.* 2004;22(4):961-83.
23. Lassnig E, Weber JT, Berent R, Kirchgatterer A, Eber B. Uncommon electrocardiogram in a patient with right atrial thrombus and pulmonary embolism. *Int J Cardiol.* 2005;103(3):345-7.
24. Lynch, RE. Stein PD, Bruce TA. Leftward shift of frontal plane QRS axis as a frequent manifestation of acute pulmonary embolism. *Chest.* 1972;61(5):443-6.
25. MacFarlane PW. & Veitch Lawrie TD: *Comprehensive Electrocardiology. Theory and Practice in Health and disease.* Pergamon Press, Inc; 1989. P. 689-90.
26. Martinez C, Cohen AT, Bamber L, Rietbrock S. Epidemiology of first and recurrent venous thromboembolism: A population-based cohort study in patients without active cancer. *Thromb Haemost.* 2014;112(2):255-63.
27. McGinn S, White PD. Acute cor pulmonale resulting from pulmonary embolism: its clinical recognition. *JAMA* 1935;114(17):1473-80.
28. Moffa PJ. Electrocardiograma O Método que impulsou a Cardiologia: O ECG de identidade. *Revista do InCor, ANO 2 - N° 24;* 1997. P. 14.
29. Neff MJ, ACEP. ACEP releases clinical policy on evaluation and management of pulmonary embolism. *Am Fam Physician.* 2003; 68(4):759–60.
30. Oliveira LD, Freitas AK, Mehta N, Ortiz MR, Mulinari LA, Cunha CL. Electrophysiological study in Ebstein's anomaly with no evidence of accessory pathway. *Arq Bras Cardiol.* 2014 Oct;103(4):e48-51.

31. Oliver C, Marin F, Pineda J, et al. Low QRS voltage in cardiac tamponade: a study of 70 cases. *Int J Cardiol* 2002;83(1):91-2
32. Pacouret G, Marie O, Alison D, et al. Association of D-dimer and helicoidal thoracic scanner for diagnosis of pulmonary embolism. Prospective study of 106 ambulatory patients. *Presse Med.* 2002;31(1 Pt 1):13-8.
33. Pollack CV, Schreiber D, Goldhaber SZ, et al. Clinical characteristics, management, and outcomes of patients diagnosed with acute pulmonary embolism in the emergency department: initial report of EMPEROR(Multicenter Emergency Medicine Pulmonary Embolism in the Real World Registry). *J Am Coll Cardiol* 2011;57(6):700–6.
34. Pudukollu P, Gowda RM, Vasavada BC, Khan IA. Role of Electrocardiography in Identifying Right Ventricular Dysfunction in Acute Pulmonary Embolism. *Am J Cardiol.* 2005;96(3):450-2.
35. Rath WH, Hoferr S, Sinicina I. Amniotic fluid embolism: an interdisciplinary challenge: epidemiology, diagnosis and treatment. *Dtsch Arztebl Int.* 2014;111(8):126-32.
36. Rodman DM, Lowenstein SR, Rodman T. The electrocardiogram in chronic obstructive pulmonary disease. *J Emerg Med* 1990;8(5):607-15
37. Rosenbaum MB, Elizari MV, Lazzari JO. *Los Hemibloqueos*, Editora Paidos , Buenos Aires; 1967.
38. Sanson BJ, Lijmer JG, Mac Gillavry MR, Turkstra F, Prins MH, Büller HR. Comparison of a clinical probability estimate and two clinical models in patients with suspected pulmonary embolism. “ANTELOPE-Study Group”. *Thromb. Haemost.* 2000;83(2):199–203.
39. Sarin S, Elmi F, Nassef L. Inverted T waves on electrocardiogram: myocardial ischemia versus pulmonary embolism. *J Electrocardiol.* 2005;38(4):361-3.
40. Scott RC. The S1Q3 (McGinn-White) pattern in acute cor pulmonale: a form of transient left posterior hemiblock? *Am Heart J.* 1971;82(1):135-7.
41. Shiomi D, Kiyama H, Shimizu M, Yamada M, Shimada N, Takahashi A, Kaki N. Surgical embolectomy for high-risk acute pulmonary embolism is standard therapy. *Interact Cardiovasc Thorac Surg.* 2017. doi: 10.1093/icvts/ivx091
42. Shopp JD¹, Stewart LK¹, Emmett TW², Kline JA^{3,4}. Findings From 12-lead Electrocardiography That Predict Circulatory Shock From Pulmonary Embolism: Systematic Review and Meta-analysis. *Acad Emerg Med.* 2015;22(10):1127-37.
43. Shujaat A, Shapiro JM, Eden E. Utilization of CT Pulmonary Angiography in Suspected Pulmonary Embolism in a Major Urban Emergency Department. *Pulm Med.* 2013; 2013:915213.
44. Sodi Pallares D, Bisteni A, Hermann GR. Some views on the significance of qR and QR type complexes in right precordial leads in the absence of myocardial infarction. *Am Heart J.* 1952; 43(5):716-34.

45. Sreeram N, Cheriex EC, Smeets JL, Gorgels AP, Wellens HJ. Value of the 12-lead electrocardiogram at hospital admission in the diagnosis of pulmonary embolism. *Am. J. Cardiol.* 1994;73(4):298-303.
46. Stein PD, Sostman HD, Hull RD, Goodman LR, Leeper KV Jr, Gottschalk A, Tapson VF, Woodard PK. "Diagnosis of Pulmonary Embolism in the Coronary Care Unit". *Am J Cardiol.* 2009;103(6):881-6.
47. van Belle A, Büller H, Huisman M, et al. Effectiveness of managing suspected pulmonary embolism using an algorithm combining clinical probability, D-dimer testing, and computed tomography. *JAMA* 2006;295(2):172-9.
48. Wagner GS. *Marriott's practical electrocardiography*. 10th ed. Philadelphia: Williams and Wilkens; 2001.
49. Wells P, Anderson D, Rodger M, et al. Derivation of a simple clinical model to categorize patients probability of pulmonary embolism: increasing the models utility with the SimpliRED D-dimer. *Thromb Haemost.* 2000;83(3):416–20.
50. Wells PS, Anderson DR, Rodger M, et al. Excluding pulmonary embolism at the bedside without diagnostic imaging: management of patients with suspected pulmonary embolism presenting to the emergency department by using a simple clinical model and d-dimer. *Ann Intern Med.* 2001;135(2):98–107.
51. Wells PS, Ginsberg JS, Anderson DR, et al. Use of a clinical model for safe management of patients with suspected pulmonary embolism. *Ann Intern Med* 1998;129(12):997–1005.
52. Wells PS, Hirsh J, Anderson DR, et al. Accuracy of clinical assessment of deep-vein thrombosis. *Lancet* 1995;345(8961):1326–30.
53. Xiao PX, Hu ZY, Zhang H, Pan C, Duan BX, Chen SL. Massive pulmonary air embolism during the implantation of pacemaker, case reports and literature analysis. *Eur Rev Med Pharmacol Sci.* 2013;17(23):3157-63.
54. Yamanaka S, Kumon Y, Matsumura Y, Kamioka M, Takeuchi H, Sugiura T. Link between pericardial effusion and attenuation of QRS voltage in patients with hypothyroidism. *Cardiology.* 2010;116(1):32-6.
55. Young E, Williams C. The frontal plane vectorcardiogram in old inferior myocardial infarction. Criteria for diagnosis and electrocardiographic correlation. *Circulation.* 1968;37(4):604-23