

## **Symptomatic elderly man (syncope) with critical coronary obstruction on LAD treated 6 Months ago with stent implantation and current dynamic dromotropic disorder on his successive ECGs**

Patient of 67 years carrying Coronary Artery Disease (CAD), with the antecedent of stent implantation on the LAD artery 6 months ago.

The first ECG was performed on admission at 10.14.02 08: 21' AM.

The second one was recorded shortly after the syncopal episode occurred approximately two hours after admission (02.10.14 10: 38').

The Holter monitoring 24h revealed an intermittent LBBB pattern. Later we will send the Holter study and the VCG.

The electrophysiological study (EPS) revealed HV interval prolongation = 84 ms (normal 55 ms). Concomitantly, the AH interval also was prolonged.

1 beyond the syncopal episode (patient was already hospitalized) there are reports of progressive dyspnea and angina in the last 4 meses. At this moment is compensated in functional class II after therapeutic optimization  
ECO-2: moderate diffuse hypokinesia, diastolic diameter of LV = 75/60 mm; LA = 41, LVEF = 40%; mild mitral and tricuspid insufficiency.

3-the patient underwent a new coronary angiography revealed significant LAD in-stent stenosis.

4 during the EPS to measure of the intervals (AH and HV) also conducted ventricular stimulation protocol (no induction)

5, the patient will be subjected to pharmacological stent implantation definitive + pacemaker

We would like to hear your valuable opinions.

Raiundo & Andrés

Português:

## **Idoso coronariano com lesão crítica da DA tratada com stent com síncope e distúrbio dromótropo dinâmico**

Paciente de 67 anos portador de Doença Arterial Coronariana (DAC), o qual implantara stent para descendente anterior há 6 meses.

O ECG 1 realizado na admissão (02-10-14 08:21' am).

O ECG 2 foi registrado logo após o episódio sincopal ocorrido aproximadamente duas horas após (02-10-14 10:38').

O estudo de holter/24h revelou em forma intermitente um padrão de BCRE. Mais tarde enviaremos o traçado holter e o VCG.

O estudo eletrofisiológico revelou significativo prolongamento do intervalo HV = 84 ms (normal 55 ms). Concomitantemente o intervalo AH também mostrou-se prolongado.

1-além do episódio sincopal(paciente já estava internado) há relato de dispnéia e angina progressiva nos últimos 4 meses. Atualmente está compensado em classe funcional II após otimização terapêutica

2-ECO:hipocinesia difusa de grau moderado do VE;VE=75/60 mm;AE=41;FE=40%;I.mitral e tricúspide leves

3-o paciente realizou novo CATE que revelou estenose significativa intra-stent da DA

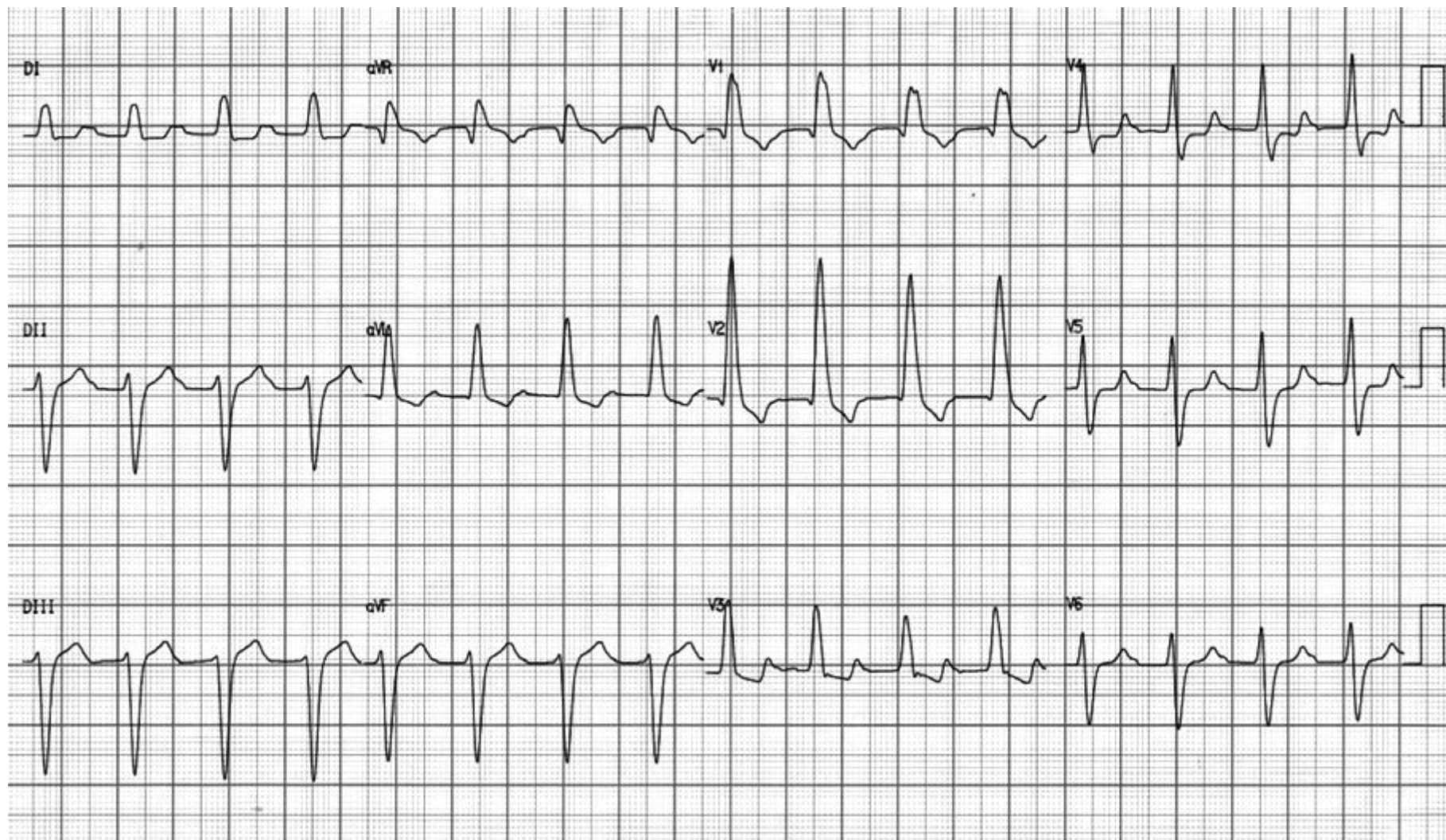
4-durante o estudo eletrofisiológico para medidas dos intervalos(AH e HV) também realizou protocolo de estimulação ventricular(não houve indução)

5-o paciente vai ser submetido à implante de stent farmacológico + MP definitivo

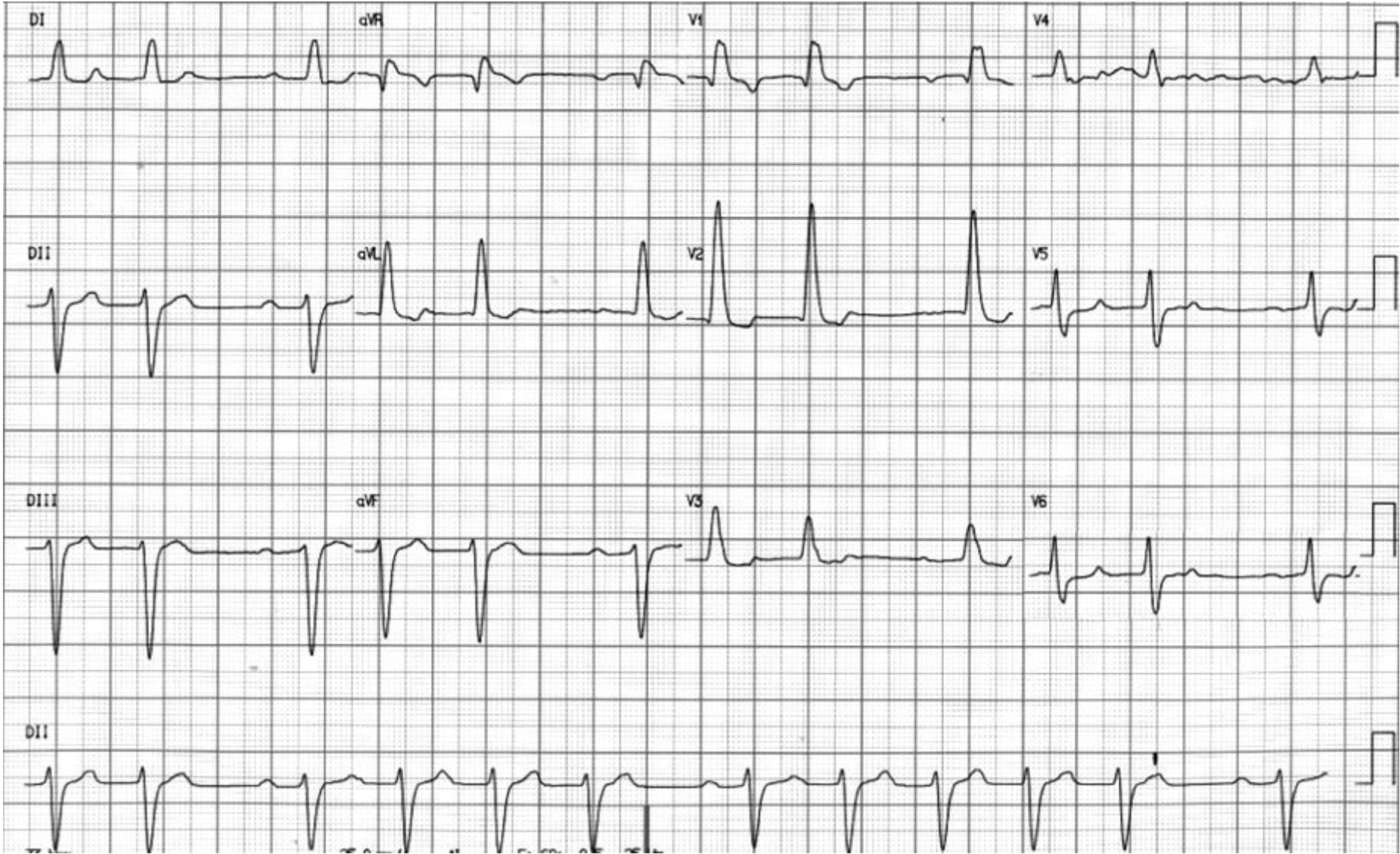
Gostaríamos de escutar vossas valiosas opiniões.

Raimundo & Andrés

ECG1=02-10-14 08:21' admissão



ECG2= 02-10-14 10:38'



**Colleagues opinions**

I think he has bilateral BBB. During Holter intermittent LBBB. Your ECG shows RBBB and LAH with Wenckebach. You also showed prolonged HV interval. He needs permanent pacing.

Thank you,

Mario D. Gonzalez ([mgonzalez@hmc.psu.edu](mailto:mgonzalez@hmc.psu.edu))

### **Portuguese**

O traçado 1 mostra BAV I grau, BRA, BDAS e BDAM. Trata-se do bloqueio mascarante de Rosenbaum, o atraso final, a S de D1 desaparece no alargamento do QRS. Como estes pacientes tem defeito severo da condução e evolução é para BAV total; no traçado 2 há BAV de II grau 2:1.

Saudações

Jose Claudio Kruse ([jckruse@terra.com.br](mailto:jckruse@terra.com.br))

### **English**

The first ECG shows first degree AV block, RBBB, LAFB and LSFB. Masquerading RBBB without final S wave in I. Severe intraventricular conduction defect. Frequently first degree AV block; on second ECG we can see second degree AV block type II 2:1.

Bonito caso, ese paciente tiene una indicación de marcapaso, asumimos que sus paredes ventriculares son estables, presenta lesión suprahisiana e infrahisiana. Hay un estudio español reciente donde los autores demuestran que sincope en ancianos asociado a bloqueo de ramo izquierdo y bloqueo AV de primer grado es indicación de marcapaso por si solo, no recuerdo el pappers pero fácilmente puede ser encontrado en pubmed.

Carlos Rodriguez ([crartuza@HOTMAIL.COM](mailto:crartuza@HOTMAIL.COM))

Spanish

Mi querido Andrés: Los ECG muestran un ritmo sinusal con segmento PR prolongado (bloqueo AV de I<sup>a</sup> grado) que por momento es de II<sup>o</sup> grado tipo Wenckewach (en el 2<sup>a</sup> ECG). Los complejos QRS muestran un BRD disfrazado estándar no de rama izquierdo como aparece en el estudio Holter (por lo cual sería muy interesante analizar dicho estudio), bloqueo del fascículo anterosuperior izquierdo y del fascículo medio, las primeras fuerzas que se despolarizan están ubicadas en el músculo papilar posterior y se dirigen hacia atrás en las precordiales V1 a V2, el aumento de fuerzas anteriores pueden ser secundarios al mismo trastorno de conducción. Estas alteraciones pueden evolucionar a un bloqueo AV completo que podrían ser los responsables del síncope.

Por otra parte el STT del primer ECG cambia con respecto al segundo, se observa un segmento ST rectificado y levemente descendido en cara anterolateral con ondas T que a pesar que se la suma la onda P, parecen ser -/+ y que tienden a normalizarse en el segundo por lo que no se puede descartar un evento coronario agudo o ser simplemente secundarios a una disminución del flujo coronario por el mismo motivo que originó el síncope. Supongo que en breve nos vas a desasnar.

Cordialmente Julia ([juliapaulapons@gmail.com](mailto:juliapaulapons@gmail.com))

---

English: My dear Andres: Electrocardiograms show sinus rhythm with prolonged PR segment (first-degree AV block) that is currently is second degree type Wenckewach (in the 2nd ECG). The QRS complexes show standard masquerading RBBB as shown in Holter study (which would be very interesting to analyze the study), LAFB and LSFB ( the first forces to depolarize are located in the posterior papillary muscle and head back in leads V1 to V2) the above forces increases may be secondary to the same conduction disorder. These changes can progress to complete AV block that could be responsible for the syncope.

Moreover, the ST-T on first ECG changes with respect to the second, grinding and ST segment decreased slightly with anterolateral T wave that although the sum is the P wave is observed, seem to be - / + and tend to normalize in the second so it can not be ruled out an acute coronary event or simply be secondary to decreased coronary flow for the same reason that caused the syncope.

I guess soon we'll desasnar.

Regards Julia Paula Pons MD. Buenos Aires

## Spanish

**Primeiro ECG: BRD, BDAS e BAV 1 grau.**

**Segundo ECG: BAV passa a ser de 2 grau Tipo 1. Consideraria além de MP novo estudo coronariano.**

**Camila Cavalcante**

[camilapcavalcante@yahoo.com.br](mailto:camilapcavalcante@yahoo.com.br)

## English

**First ECG: RBBB, LAFB, First-degree AV block**

**Second ECG: Second degree AV block Mobitz type I**

**Management: Pacemaker implantation + coronariography.**

**Camila Cavancante**

---

## Spanish

En mi modesta opinión corresponde

A ritmos sinusal de 90 cpm.

BRD+ HAI+ Bloqueo AV DE 1• grado y bloqueo AV de 2• grado tipo MOBITZ I.

Me impresiona que en el segundo ECG la observación del intervalo PR posterior a la actividad auricular bloqueada es de igual duración que los PR conducidos (prolongados), lo que platearia más un bloqueo de 2• grado tipo MOBITZ II

GRACIAS.

[cmassa57@gmail.com](mailto:cmassa57@gmail.com)

## English

Sinus rhythm, heart rate 90lpm, RBBB + LAFB + First-degree AV block anda second degree AV block Mobitz type I.

In the second ECG the conducted PR are equals, consequently Mobitz type II

Thanks



**Spanish** **Apreciado Dr. Pérez Riera:**

**Mi diagnóstico es: Primer ECG: Ritmo sinusal + Bloqueo AV de 1º grado + Bloqueo avanzado de rama derecha + bloqueo de la subdivisión anterior izquierda (bloqueo A-V infrahisiano trifascicular). Existe además pequeña "q" V1-2 que puede corresponder a bloqueo de la subdivisión anterior izquierda o a pequeña necrosis anterior.**

**El ST deprimido en V3-V4 me sugiere isquemia actual.**

**Segundo ECG: bloqueo A-V 2º grado, supuestamente Mobitz II.**

**La lesión severa con stent de la LAD podría ser responsable de todo el cuadro ECG.**

**Por la existencia de síncope revisaría la coronariografía (¿reestenosis stent LAD?) e indicaría marcapasos.**

**Valentin Valls.**

**Barcelona. España**

---

English Dear Dr Pérez-Riera

My diagnosis is:

First ECG: sinus rhythm + 1st degree AV block + Advanced Right Bundle Branch Block + left anterior subdivision block (Infra Hissian intraventricular trifascicular block). There are also small "q" waves in V1-2 which may correspond to LAFB or small anterior necrosis. The depressed ST segment in V3-V4 suggests ischemia.

Second ECG: 2nd degree AV block, Mobitz 2 supposedly.

Severe injury of the LAD stent could be responsible for all ECG picture.

For the existence of syncope I would make a new coronary angiography (LAD stent restenosis?) and I indicate pacemaker implantation.

**Valentin Valls.**

**Barcelona. Spain**

Spanish

Queridos Raimundo y Andrés,

Para mi es un auténtico y bello ejemplar de bloqueo bifascicular (BRD + HSA) enmascarado (falta de S en I e VL), más BAV 1er grado. Esto más sincope + BRI intermitente + HV↑ = marcapasos urgente. Con la intermitencia del BRI ya sería suficiente para el MP.

Muy buen caso. Si me permitís, lo mostraré en alguna sesión en vuestro nombre.

Un fuerte abrazo,

Antonio Bayés de Luna.

---

Dear Raimundo and Andrés

For me it is an authentic and beautiful example of bifascicular block (RBBB + LAFB) masquerading BBB (because lack of final S wave in I and VL) + first-degree AV block. These ECG features + syncope + intermittent LBBB on Holter monitoring + prolonged HV ↑ on EPS = mandatory urgent pacemaker implantation. With the flashing of LBBB and would be sufficient for the MP.

Very good case. If I may, I shall show in a session on your behalf.

A big hug,

**Professor Antoni Bayes de Luna. MD, FESC, FACC**

Honorary director of the Cardiac Department, St Creu and St Pau Hospital, Barcelona, Spain,

“One of the Most Esteemed Cardiologists in the World”

Português

Prezados,

Acredito que se trata de doença grave no sistema de condução.

O primeiro traçado evidencia um BAV do primeiro grau e distúrbio de condução intraventricular. O QRS tem padrão de BRE em D1 e aVL com desvio antero-superior do eixo elétrico, e padrão de BRD com ondas q em V1-2. A onda R cresce de V1 para V2, sugerindo bloqueio Antero-medial.

A obstrução de DA deve ter sido proximal.

O segundo traçado mostra BAV tipo Wenckbach, com os mesmos achados descritos anteriormente. Devemos implantar marca passo para tratamento da parte elétrica.

Saudações,

Joel Pinho. Salvador Bahia.

[joelpinho@terra.com.br](mailto:joelpinho@terra.com.br)

---

English

Dear friends,

I believe it is a serious disease of the conduction system.

The first trace shows a first-degree AV block and intraventricular conduction disturbance. The QRS has LBBB pattern in D1 and aVL with extreme left anterosuperior deviation of the QRS electrical axis, and RBBB pattern with q waves in V1-2. The R wave from V1 to V2 grows, suggesting LSFB in association. Proximal obstruction of proximal DA should have been!!.

The second tracing shows second degree AV block Mobitz type I (Wenckebach), with similar findings described above.

We must deploy pacemaker for treatment of electrical part.

Regards,

Joel Alves Pinho Filho M.D. Salvador Bahia.

Queridos amigos del fórum el caso del Prof. Andrés Pérez Riera MDPHD.: Mi diagnóstico es bloqueo trifascicular con hemibloqueo anterior y bloqueo de primer grado en presencia de una hipertrofia basal. Ondas S profundas en III  $\geq$  10 mm y R de aVL de gran voltaje + hipertrofia septal alta que habitualmente acompaña a las extrasístoles atriales y onda P onda en V1 que sugiere hipertrofia de la base con el septo alto que es un continuum anatómico

Aumento de la presión diastólica final de VI alta por la hipertrofia con insuficiencia diastólica. Parecería que la hipertrofia evolucionó para la dilatación porque la duración del QRS es casi de 200 ms

Esta patología nada tiene que ver con un proceso isquémico. El hallazgo de obstrucción en la arteria coronaria descendente anterior es accidental.

Este patrón electrocardiográfico es de alto riesgo para síncope cardiaco y el implante de marcapaso es mandatorio.

Como el paciente es brasileño hay que descartar enfermedad de Chagas.

En resumen: Bloqueo trifascicular, hipertrofia del ventrículo izquierdo que evolucionó a dilatación el ventrículo izquierdo y presión diastólica aumentada por fibrosis cardiaca.

Samuel Sclarovsky [samuel\\_s@NETVISION.NET.IL](mailto:samuel_s@NETVISION.NET.IL)

Andres

This could well be distal, intra or infraHisian Wenckebach. Did you see it in the EP study?

Intermittent LBBB in the Holter monitoring means alternating with "baseline" RBBB + LAFB? If so, both RB and LB are seriously ill.

Did he ever normalized the intraventricular conduction?

I am sure you guys have more interesting information found in the EP study.

Abrazo

Fabian ([farnaldo@gmail.com](mailto:farnaldo@gmail.com))

Realmente estoy de acuerdo con la valoración de presencia en el primer eco, de un bloqueo trifascicular. Y ya en el 2do evidentemente existe un Bloque AV tipo MoVitz I, en cuanto a los signos dvd, pueden corresponder a una http , sería necesario realizarle un eco para comprobar el diagnóstico y un BNP, por lo demás este paciente requiere de la implantación de un MP.

Dr Gonzalez Font ([aegfont49@gmail.com](mailto:aegfont49@gmail.com))

I really agree with the assessment of presence in the first ECG of a trifascicular block. And in the 2<sup>nd</sup> one there is real 2<sup>nd</sup> degree AV block Mobitz type I, regarding the DVD signs?, may correspond to a http?, be necessary to perform an echo to verify the diagnosis and BNP, otherwise this patient requires implantation a pacemaker.

Atrioventricular second degree Mobitz II + left anterior hemiblock + right bundle branch block (hence alternance of left and right BBB). --> trifascicular block.

Need for pacemaker.

I apologize for my mistakes: I am not a cardiologist

Marco Marano ([marano965@gmail.com](mailto:marano965@gmail.com))

Distinguidos doctores: mi humilde análisis sería en el primer ECG muestra un trastorno de conducción AV de primer grado con un bloqueo avanzado de rama derecha con una hipertensión pulmonar importante (qS) en V1 y V2 y la onda Q en V1 y V2 puede ser por cicatriz septal o por la misma hipertensión pulmonar, además un eje izquierdo que cumple criterios de hemibloqueo de la subdivisión anterior, por lo tanto cumple criterios para bloqueo trifascicular.

El segundo ECG llamativamente está haciendo un Wenchebach más los criterios anteriormente mencionados, pero vemos que la frecuencia cardíaca del segundo ECG es menor que la primera, por lo tanto está jugando un papel muy importante la conducción proximal (efecto vagal) lo anterior sugiere que por lo tanto tiene trastornos muy severos de conducción distal (trifascicular) y defectos de conducción proximal (en el nódulo AV) pues este tipo de bloqueo es proximal y más por efecto vagal, yo esperaría en este paciente hiciese con el aumento de la frecuencia cardíaca un bloqueo dos para uno o un bloqueo avanzado e inclusive bloqueo AV completo. Yo no dudaría de implantarle un marcapasos bicameral o tricameral si cumple criterios.

Mil gracias por compartir estos casos tan bonitos.

Mauricio Duque R, MD [mauricioduque@une.net.co](mailto:mauricioduque@une.net.co)

Director del Servicio de Cardiología. Clínica CES  
Profesor Titular Universidad CES y Pontificia Bolivariana  
Jefe del servicio de Electrofisiología Clínica las Américas  
Coordinador y profesor de la cátedra de Electrocardiografía Universidad CES  
Jefe de Postgrado de Cardiología y Electrofisiología, Universidad CES  
Medellín. Colombia

**Final conclusion by  
Raimundo Barbosa-Barros  
&  
Andrés Ricardo Pérez-Riera**

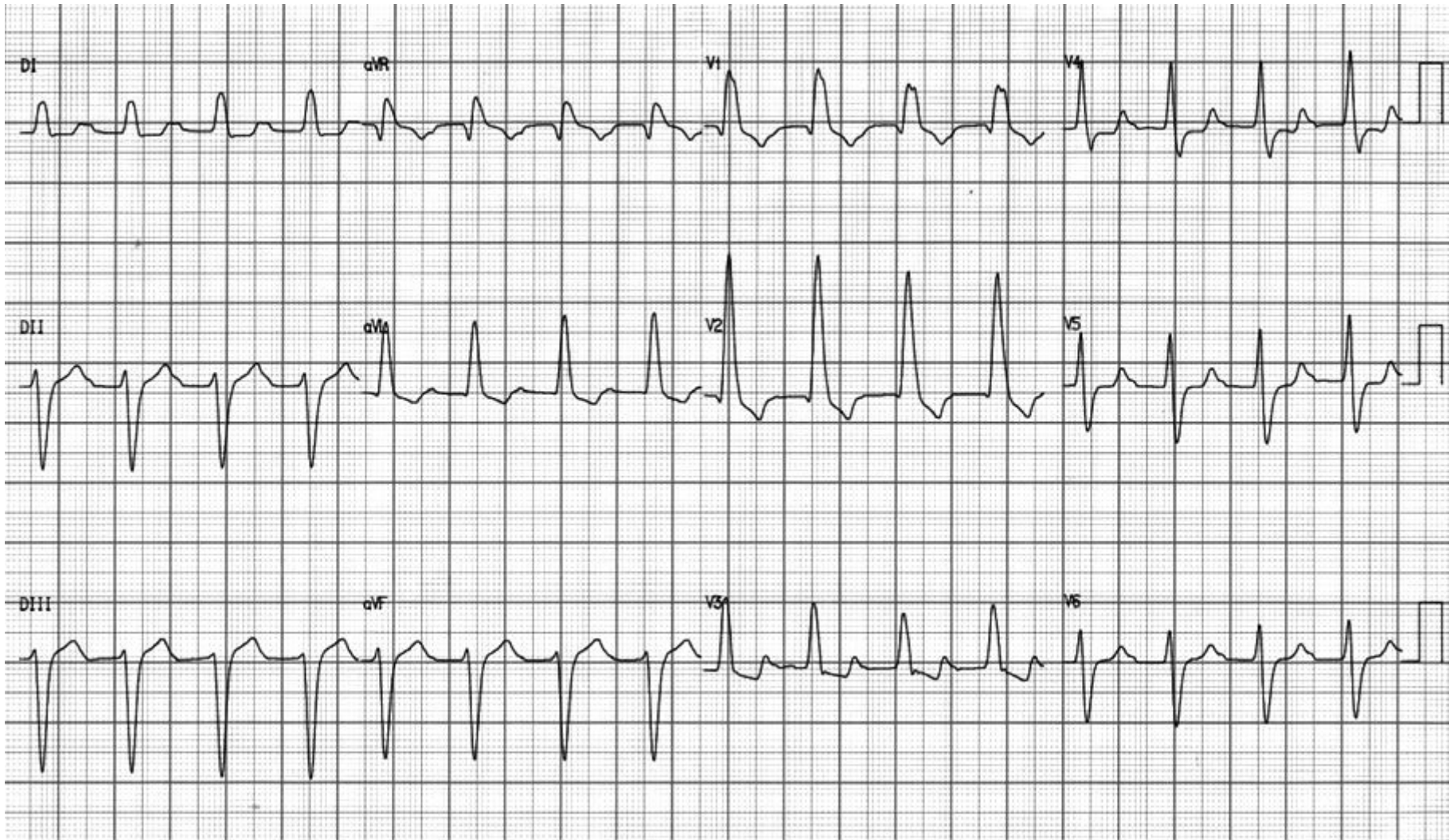


**Fox**



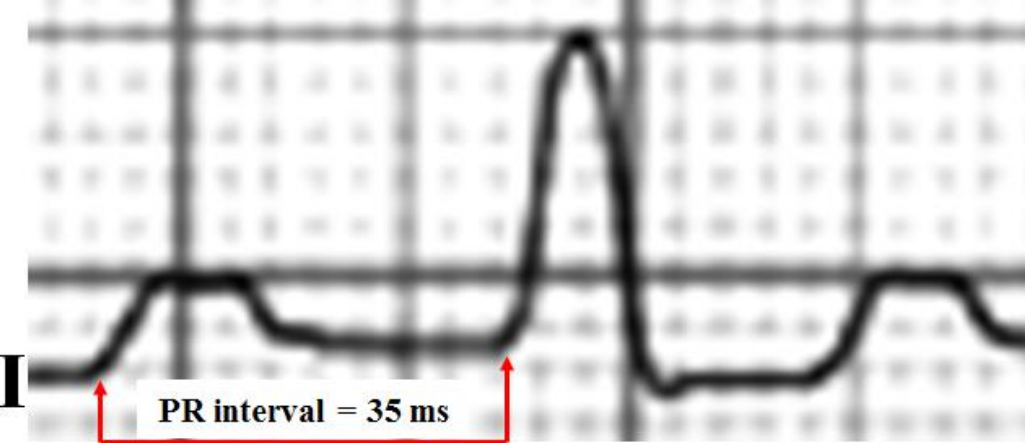**Foal**

**ECG1=02-10-14 08:21' admission**

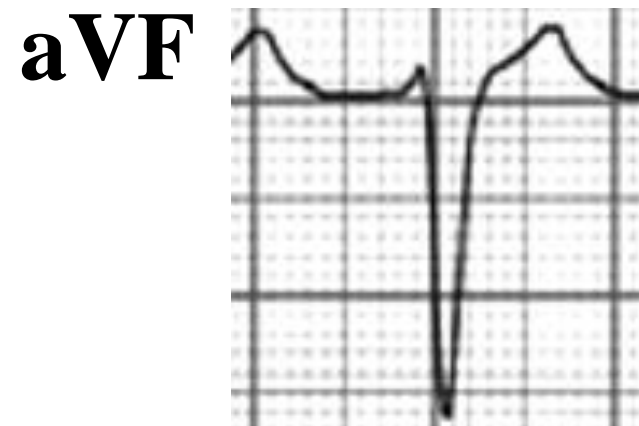
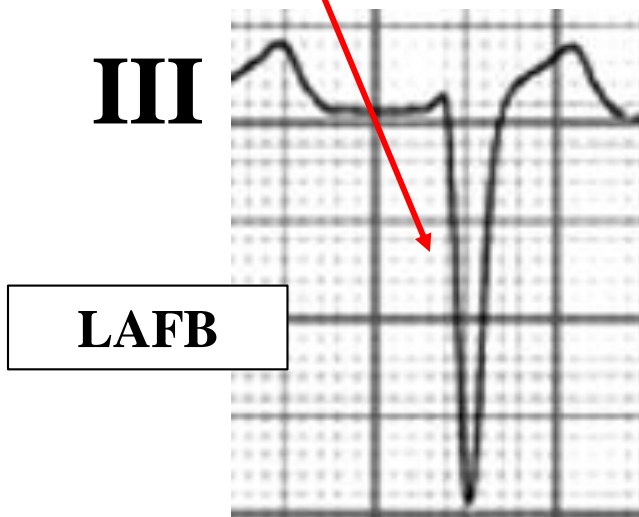
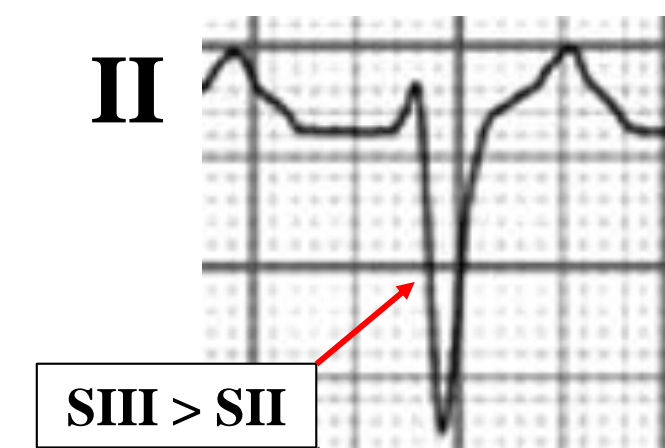
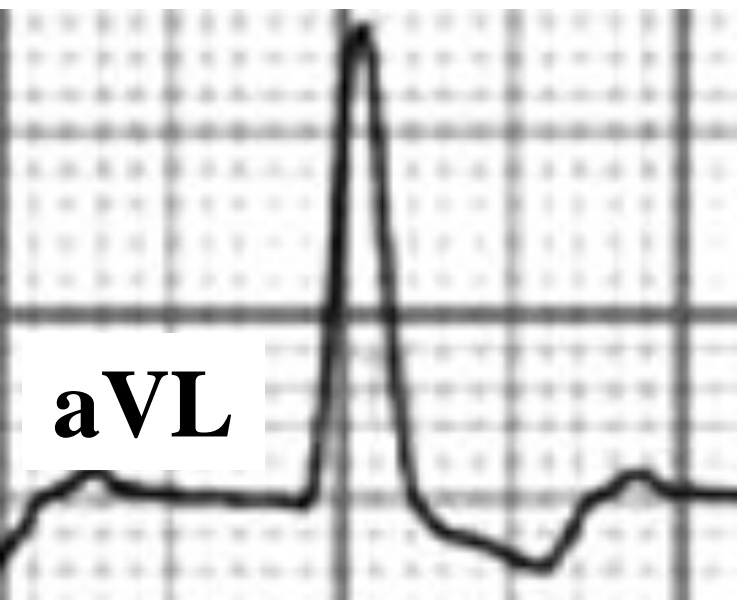
**ECG diagnosis:** Standard Masquerading Right Bundle-Branch Block +LAFB+LSFB+prolonged PR interval: probable claudication of Left Posteroinferior Fascicle (LPF) suggesting **tretrafascicular** block. This is a new term coined by us. Why ? See next slide.

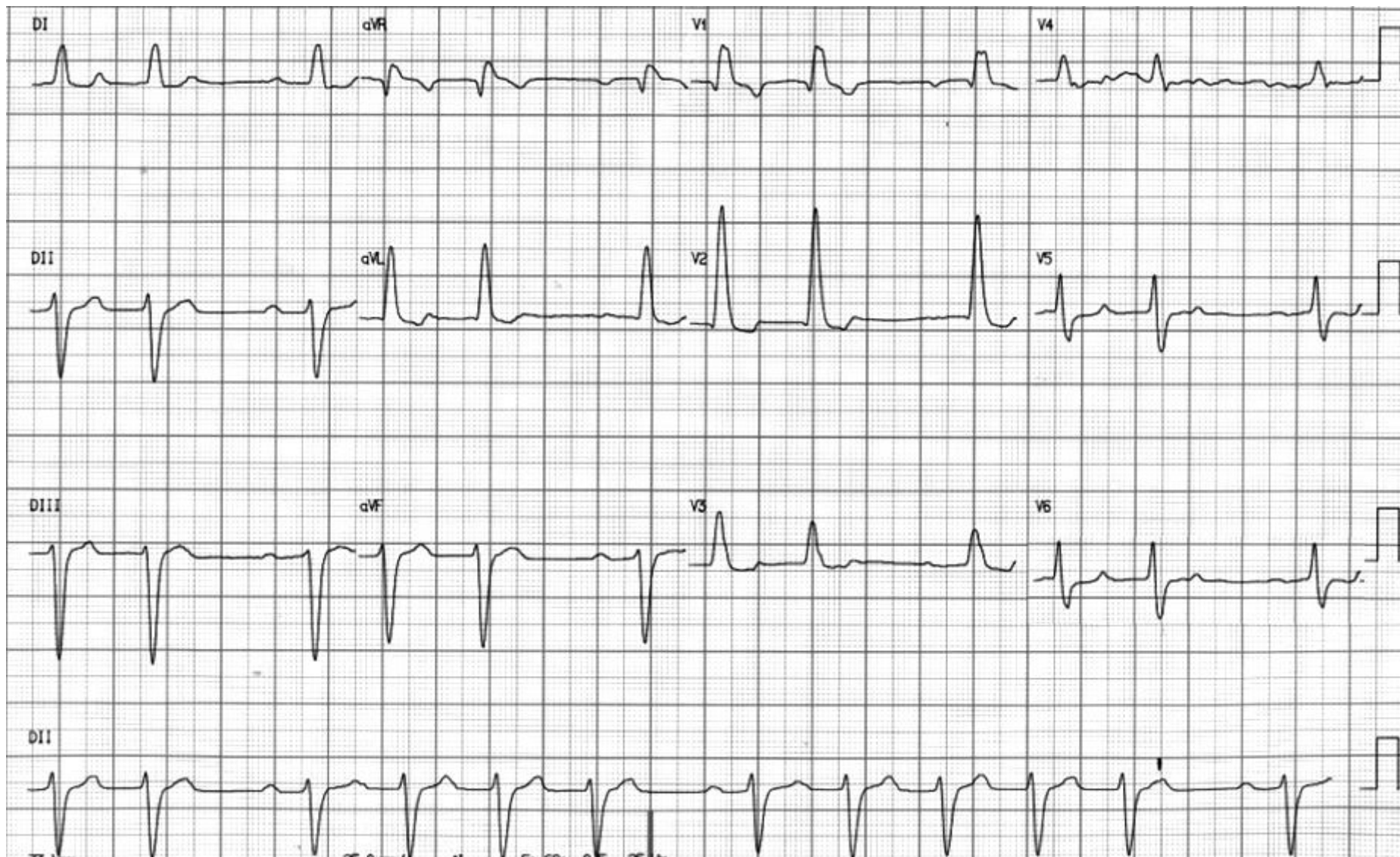




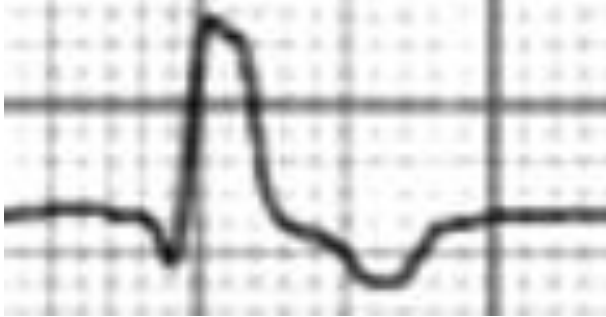In “*Standard Masquerading Right Bundle-Branch Block*” the presence of a high degree LAFB obscured totally or partially the diagnosis of RBBB only on FP by abolishing (or becomes very small) the final broad S wave in the leads I and aVL. Consequently, these limb leads may resemble LBBB although the precordial ECG remain typical for CRBBB.



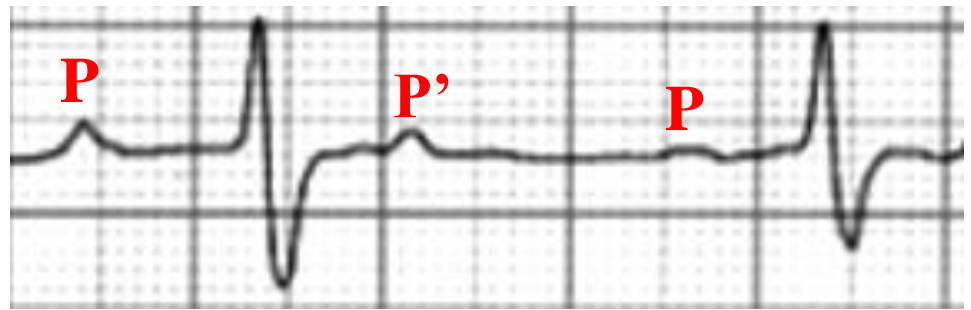
ECG2= 02-10-14 10:38'



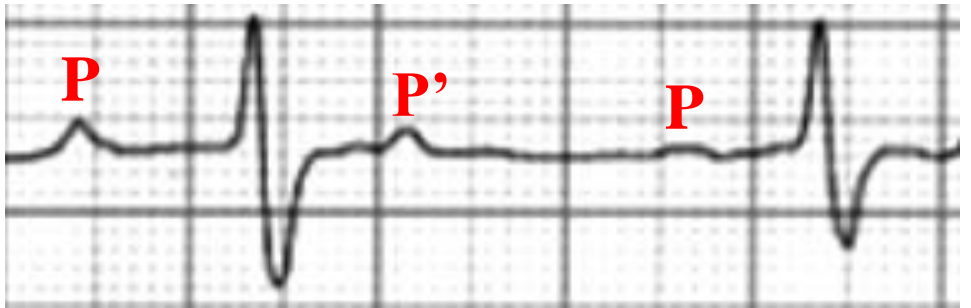
V1



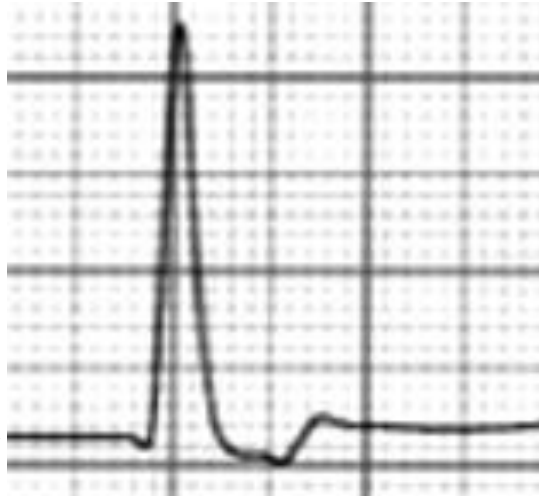V5



V6



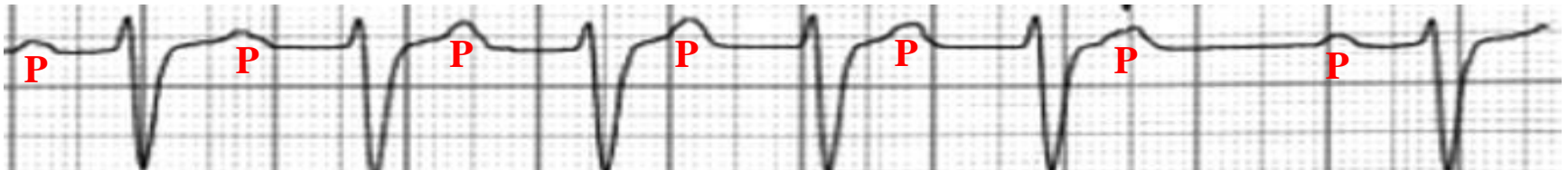
V2



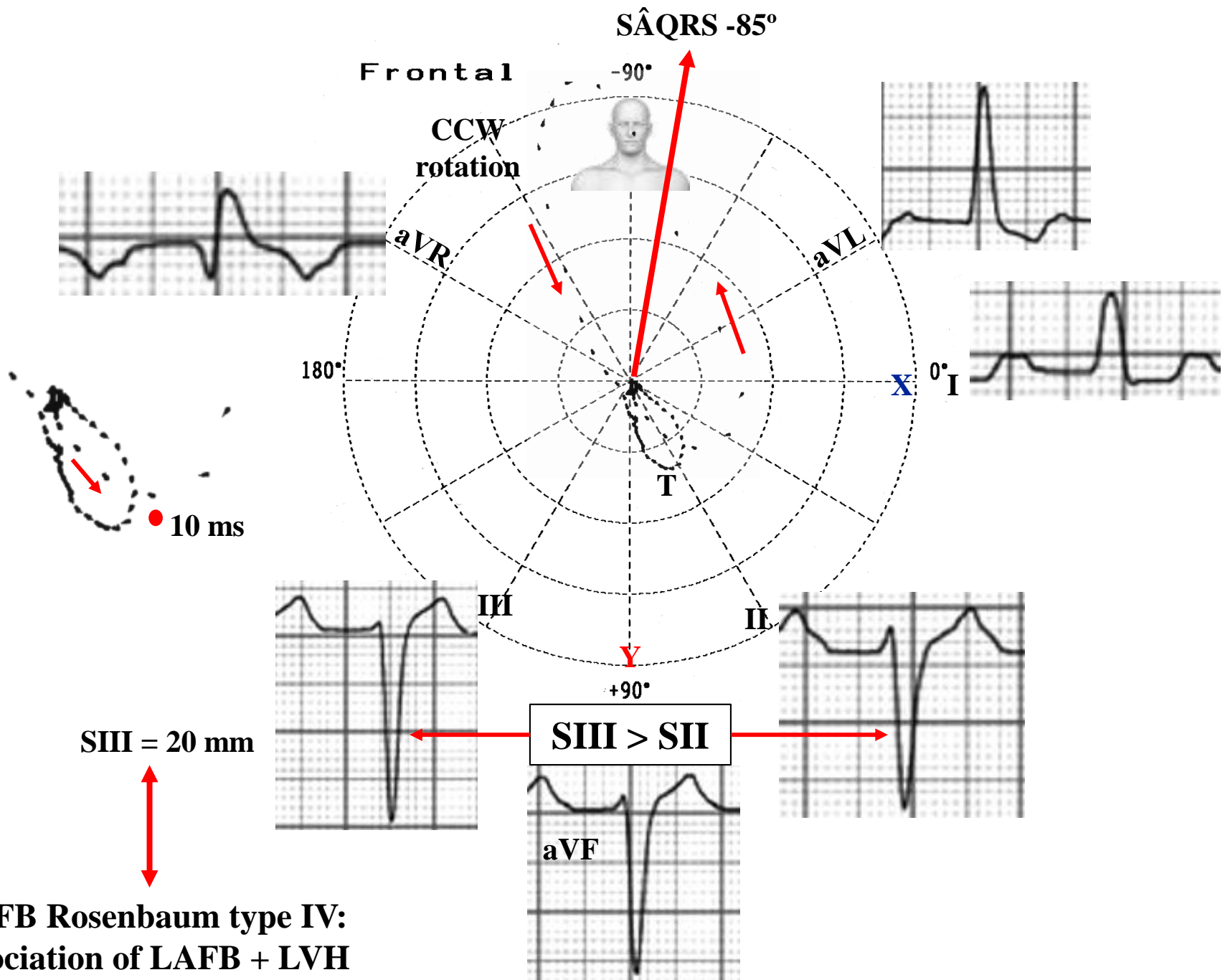
2:1 2nd degree AV block or pseudo 2:1 2nd degree AV block, the second (non conducted) and third P waves (P') have a different morphology from the conducted P wave, being ectopic, premature and not conducted: sinus rhythm with blocked atrial extrasystoles. P' waves are atrial extrasystoles.

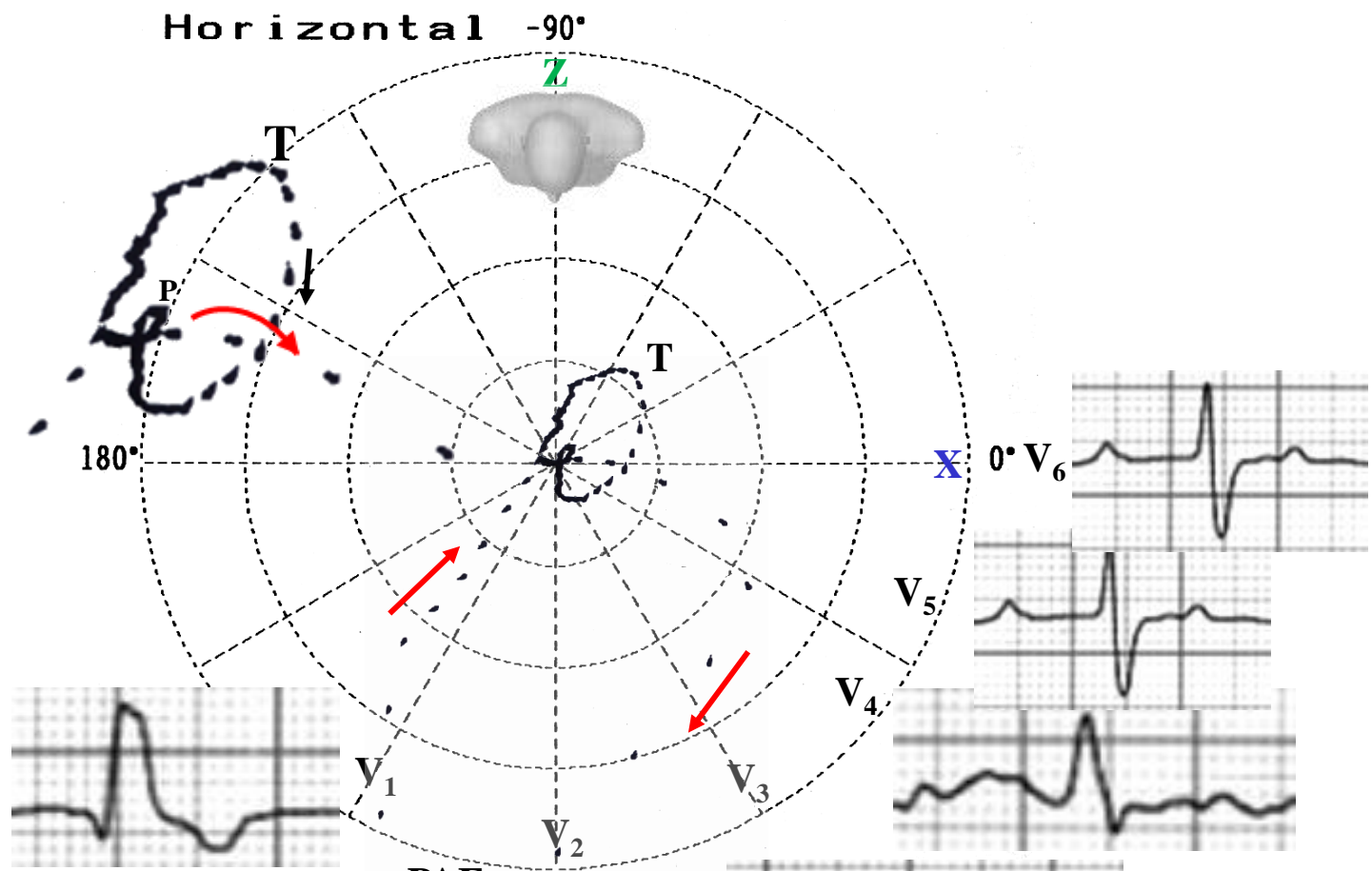
**V1:** qR pattern RBBB with septal myocardial infarction.

**V1-V2:** qR pattern, proeminente anterior forces (PAF), increased intrinsicoid deflection of V<sub>1</sub> and V<sub>2</sub>, R wave “in crescendo”, R wave voltage of V<sub>1</sub> ≥ 5 mm, small q wave in V2 or V1 and V2, R wave of V2 > 15 mm, absence of q wave in V5, V6 and I (by absence of the first septal vector 1<sub>AM</sub>): **Left Septal Fascicular Block.** ( **Uchida 2006 ; Riera 2008; Riera 2008; Pérez Riera 2011; Pérez-Riera 2014; Ibarrola 2014**)



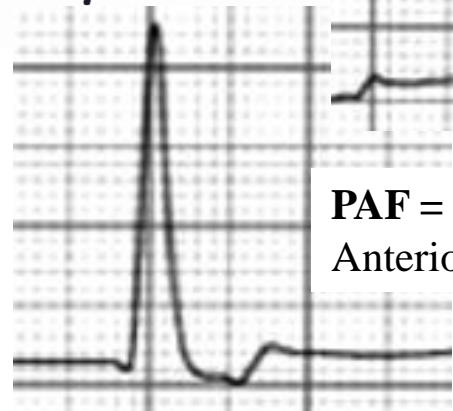
**ECG 2: Long II suggests Mobitz type I AV block (Wenkebach): progressive PR prolongation**

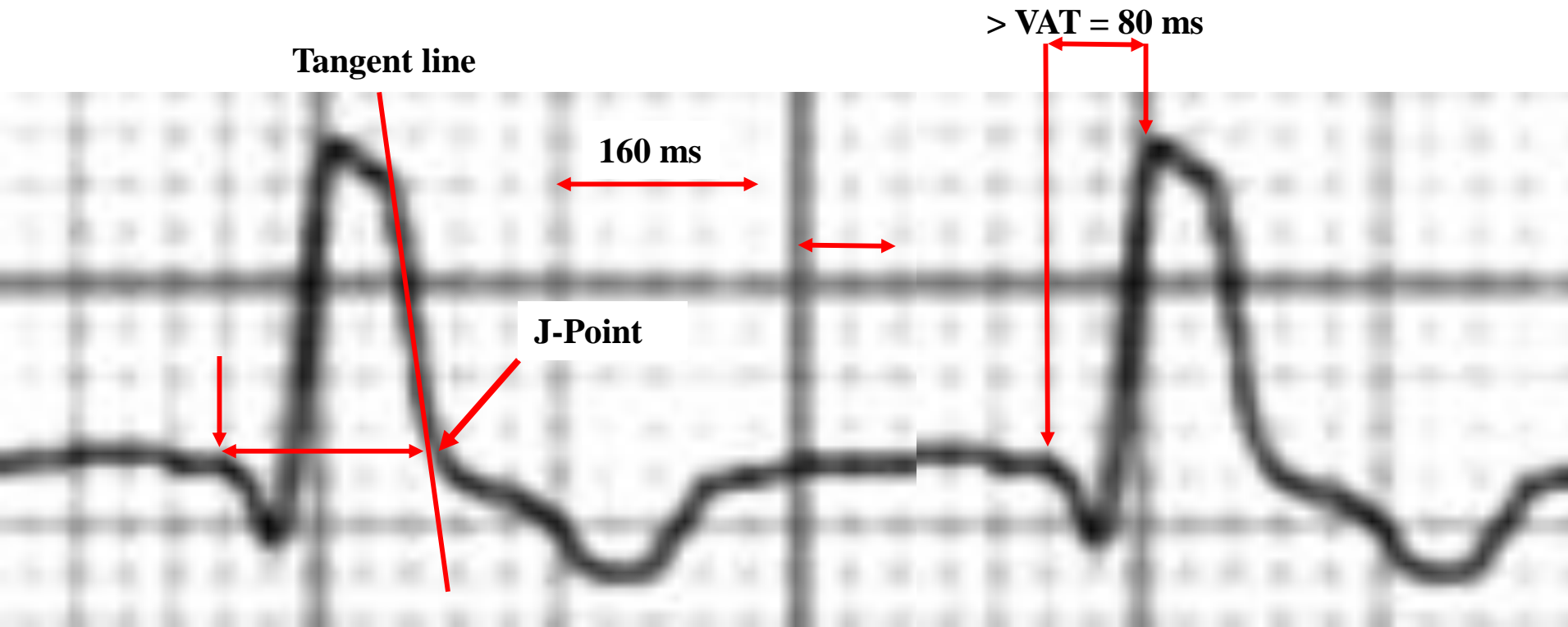




**V1: qR pattern**  
 Cause?  
 Septal infarction +  
 RBBB?  
 Liberation LPF  
 forces?  
 See explanation  
 next slide.

**PAF = Prominent  
 Anterior Forces**





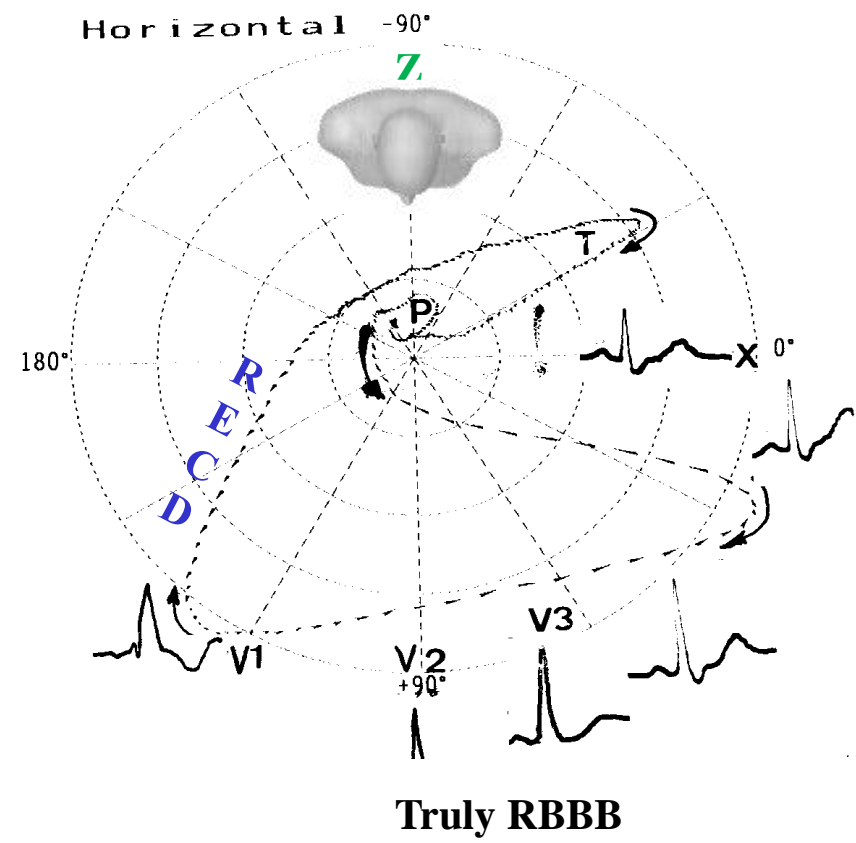
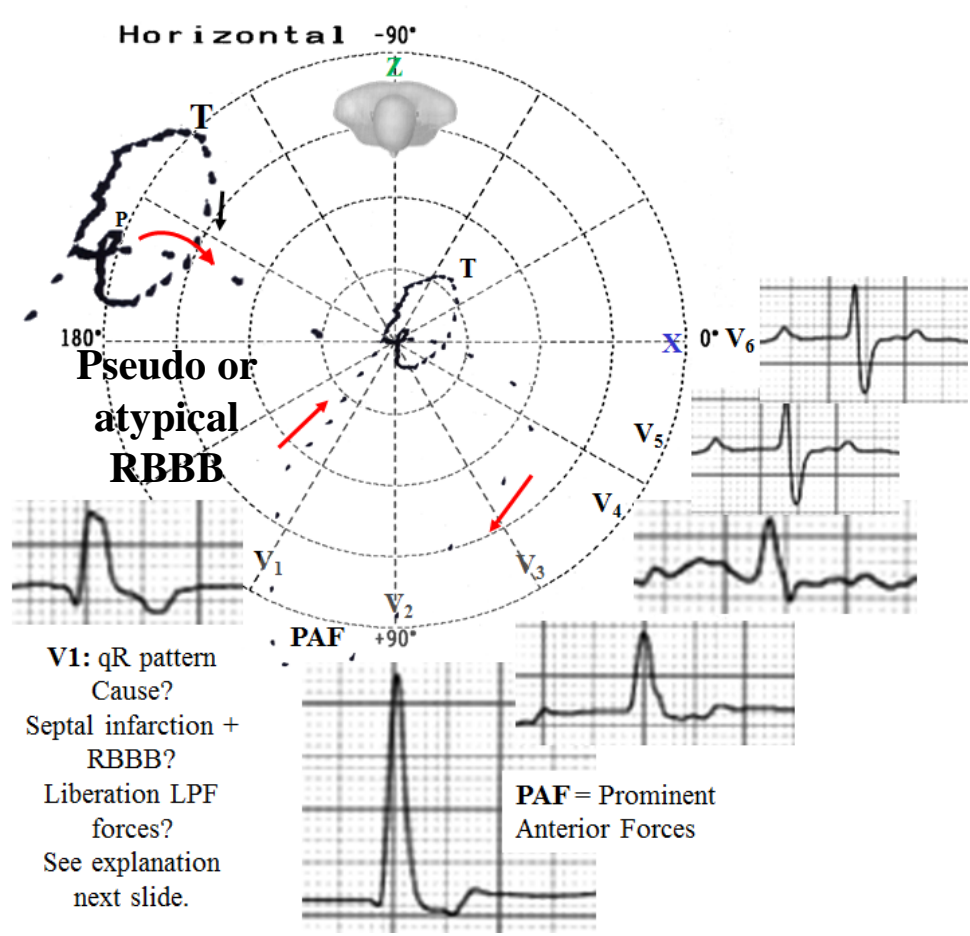
QRS duration = 160 ms. Why? Because normal QRS = 100 ms + 2 ms LAFB + 2 ms LSFB + 2 ms LVH = 160 ms. Additionally, he has very prolonged ventricular activation time (VAT) or “R peak time” or intrinsicoid deflection of  $V_1$  and  $V_2$ , and R wave is “in crescendo” from  $V_1$  to  $V_2$ .

Conclusion:

This patient does not have Complete RBBB associated with septal infarction. He has LAFB + LSFB + LVH + degree of LPFB.

The VCG on HP does not have [Right End Conduction Delay](#), consequently he does not have RBBB.

See next slide.



	<b>LSFB</b>	<b>RBBB KENNEDY TYPE III</b>
Initial 10 to 20 ms	To back and leftward	To front and rightward or to the left
Terminal or final forces	On right anterior quadrant and without slow inscription. Dashes are separated from each other. Conclusion: this patient has predominantly LSFB and atypical RBBB?	On right anterior quadrant and with slow inscription : Right End Conduction Delay ( <b>RECD</b> ). Dashes are very close to each other at the end of QRS loop. Necessary for RBBB diagnosis.

# ECG-VCG criteria for LSFb

## A) ECG:

- Normal QRS duration or with a discrete increase 2ms (up to 110 ms), if isolated.
- FP leads with no modifications: normal QRS.
- **Increased ventricular activation time or intrinsicoid deflection of  $V_1$  and  $V_2$** , present in this case.
- R wave voltage of  $V_1 \geq$  than 5 mm (present in this case);
- R/S ratio in  $V_1 > 2$ ;
- R/S ratio in  $V_2 > 2$ ;
- S wave depth in  $V_2 < 5$  mm.
- Possible small q wave in  $V_2$  or  $V_1$  and  $V_2$  (present in this case).
- R wave of  $V_2 > 15$  mm (present in this case);
- RS or Rs in  $V_2$  and  $V_3$  (frequent rS in  $V_1$ ) with R wave "in crescendo" from  $V_1$  to  $V_3$  and decreasing from  $V_5$  to  $V_6$  in absence of LVH
- **Absence of q wave in  $V_5$ ,  $V_6$  and I (by absence of the vector  $I_{AM}$ )** (present in this case).

## B) VCG: (all in the HP)

- QRS loop in the HP with an area predominantly located in the left anterior quadrant ( $> 2/3$  of the loop facing the orthogonal X line);
- Absence of normal convexity to the right of the initial 20 ms of the QRS loop;
- Discrete dextro-orientation with moderate delay of the vector from 20 ms to 30 ms;
- Anterior location of the vector from 40 to 50 ms;
- Posterior location with a reduced magnitude of the vector from 60 to 70 ms;
- Maximal vector of the QRS loop located to the right of  $+ 30^\circ$ ;
- T loop of posterior orientation (useful for the differential diagnosis with lateral/basal infarction);
- The QRS loop rotation may be: Counterclockwise: incomplete LSFb or Clockwise: advanced LSFb or in association with CRBBB, LAFB or LPFB.



# Conclusions and management

1. First degree AV block: most likely by dromotropic claudication of the posteroinferior fascicle of left bundle branch
2. Second degree AV block Mobitz type I (Wenkebach) in the second ECG and pseudo 2:1 2nd degree AV block?)
3. LAFB: extreme left axis deviation  $S_{III} > S_{II}$
4. LSFB: qR pattern, prominent anterior forces (PAF) increased ventricular activation time or intrinsicoid deflection of  $V_1$  and  $V_2$ , R wave “in crescendo” from  $V_1$  to  $V_2$ , R wave voltage of  $V_1 \geq 5$  mm, small q wave in  $V_2$  or  $V_1$  and  $V_2$ , R wave of  $V_2 > 15$  mm, absence of q wave in  $V_5$ ,  $V_6$  and I (by absence of the first septal vector  $1_{AM}$ ). The left septal fascicle (LSF) is irrigated exclusively by the septal perforating branches of the Left anterior descending artery (LAD). Critical lesions of the LADA before the first perforating septal(S1), constitute the main cause of LSFB in the developed countries. (this case had obstruction on LAD with stent implantation in the pass.( See irrigation of left fascicle of Left Bundle Branch at next slide
5. Standard Masquerading Right Bundle Branch Block. Atypical RBBB?
6. RBBB with septal myocardial infarction: qR pattern in  $V_1$
7. First degree AV block + bifascicular left fascicular block + RBBB = tetrafascicular block (this is a new nomenclature used by us.)
8. LBBB on Holter monitoring is indicative of **alternating BBB**, such as the following next three slides.

EPF study shows HV and AH prolongation and Holter monitoring transient LBBB pattern.

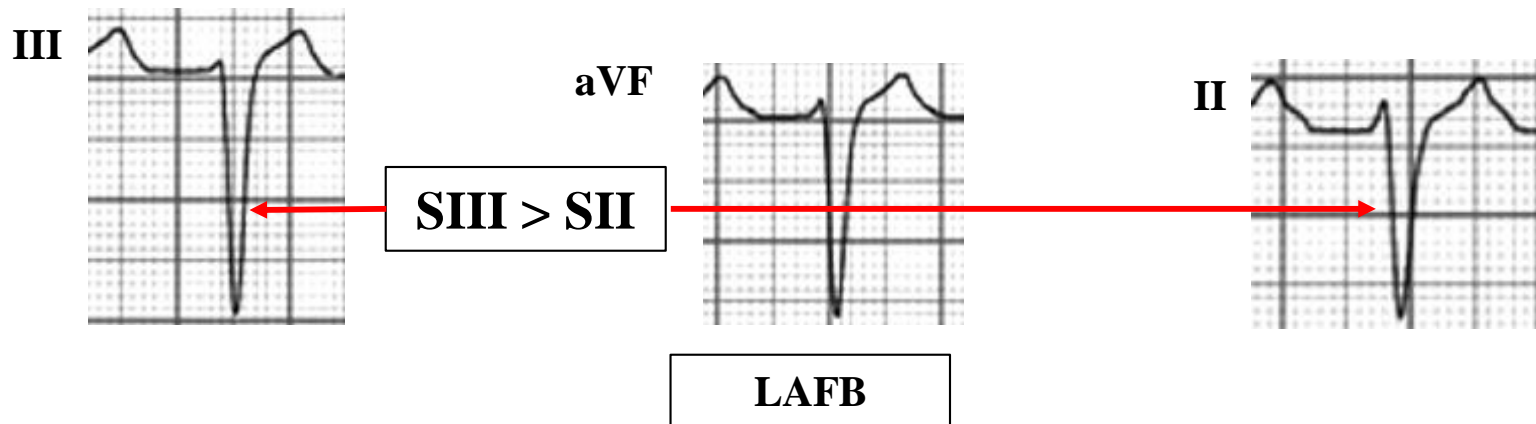
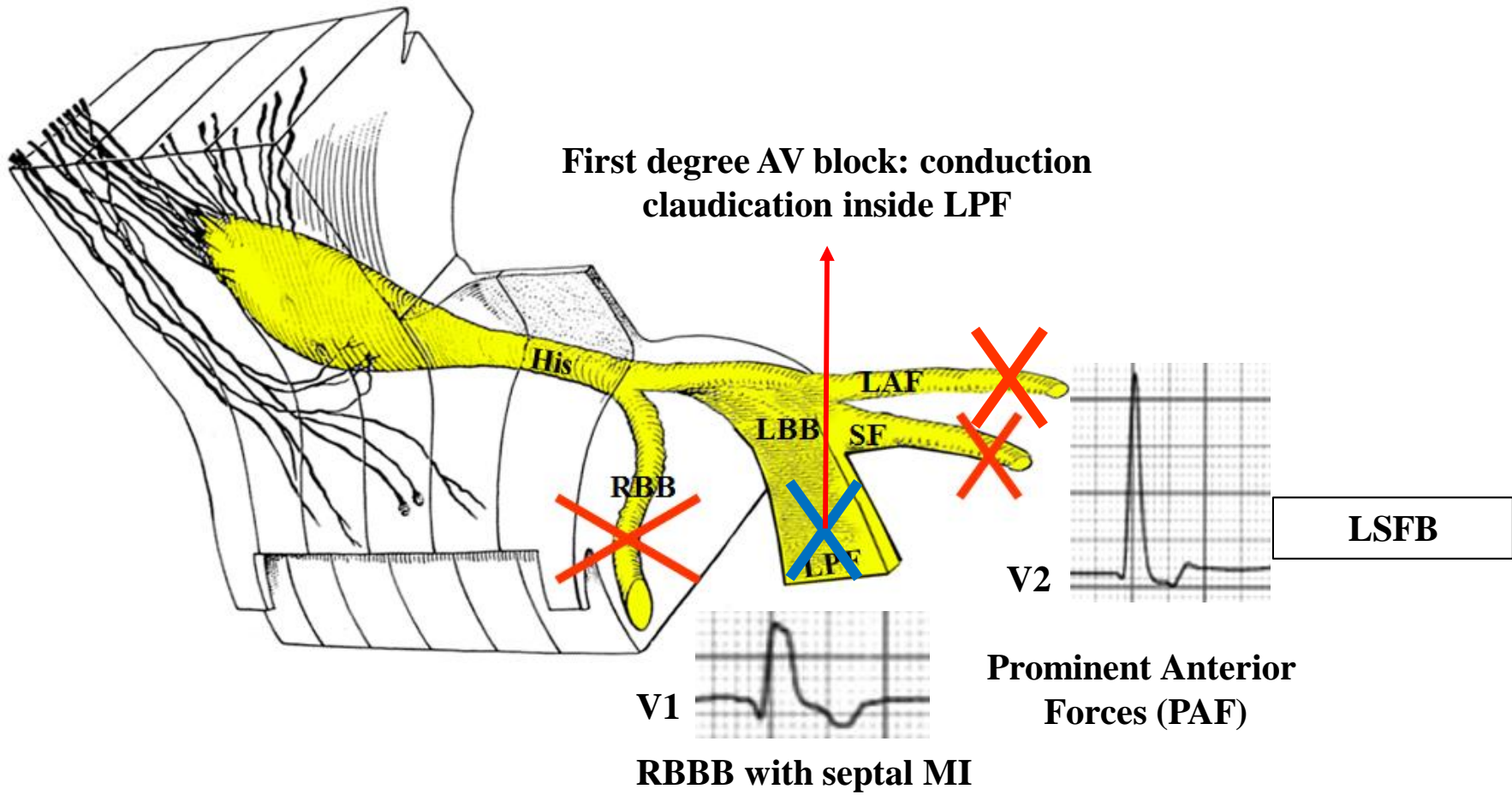
Management: mandatory pacemaker implantation.

## Blood Supply of left fascicles of left Bundle Branch

Responsible system	LAF	LPF	LSF
<b>Branches of the LAD</b>	40 %	10 %	100 %
<b>Double irrigation (LAD &amp; RCA)</b>	50 %	40 %	0 %
<b>RCA branches</b>	10 %	50 %	0 %

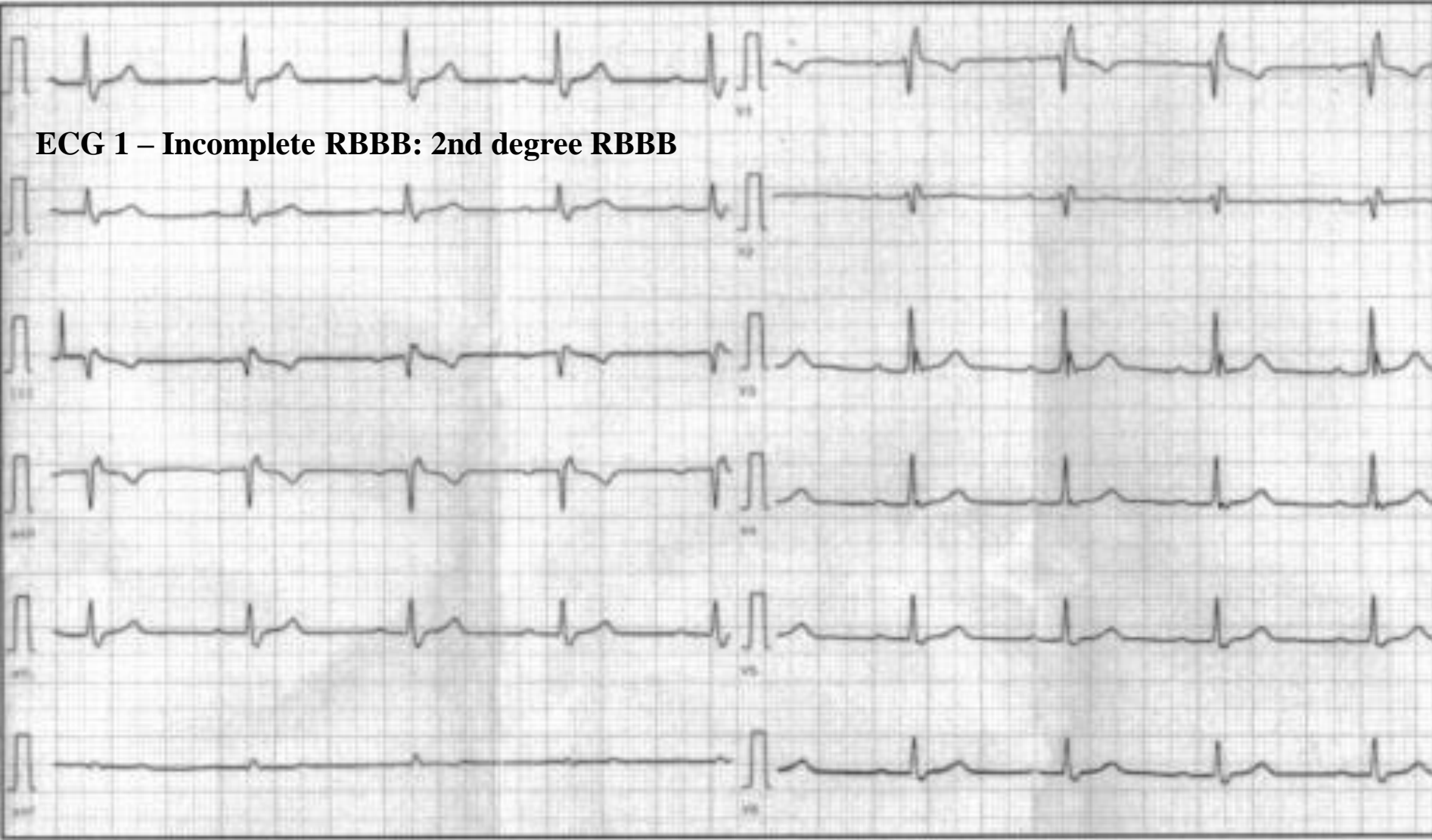
ADA - Anterior Descending Artery  
 RCA - Right Coronary Artery  
 LAF – Left Anterior Fascicle  
 LPF – Left Posterior Fascicle  
 LSF – Left Septal Fascicle

Irrigation of the three fascicles of the left bundle branch.

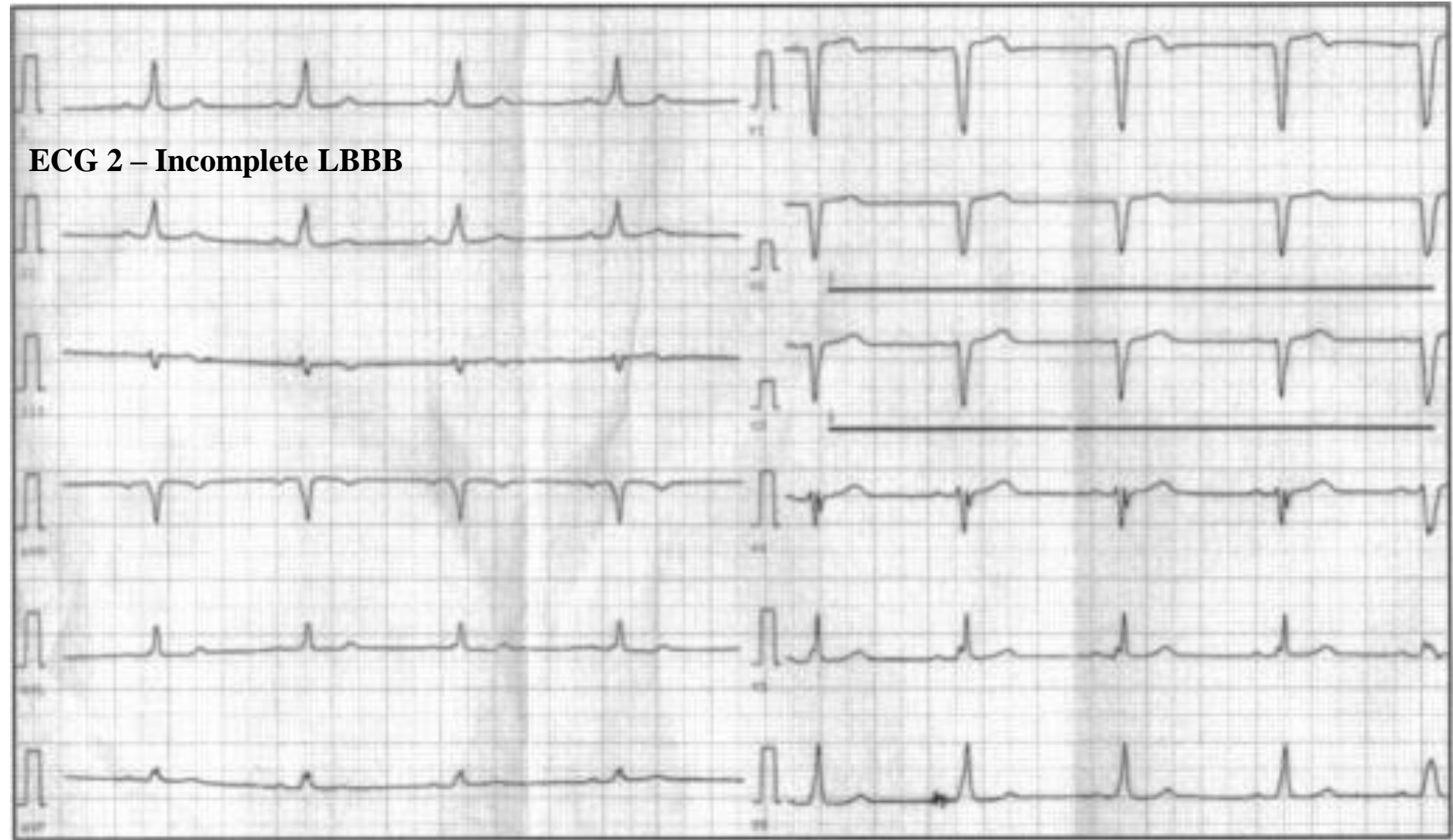


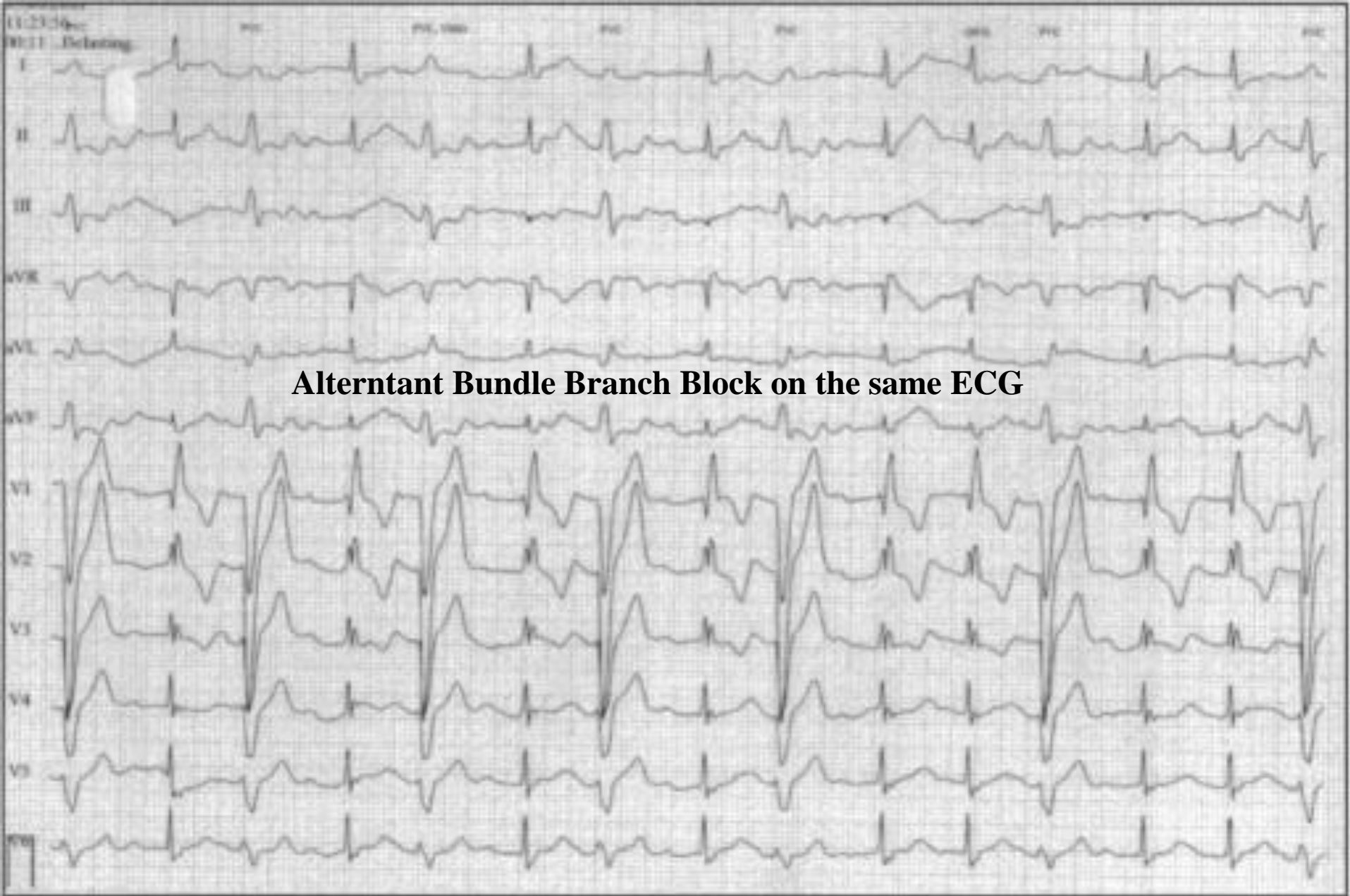
# Typical example of alternant bundle branch block

**ECG 1 – Incomplete RBBB: 2nd degree RBBB**



**ECG 2 – Incomplete LBBB**





# Masquerading Right Bundle Branch Block concept

The ECG complex coined since Richman as “masquerading bundle-branch block”(Richman 1954) to day we know that is essentially a complete RBBB and high degree LAFB, with further modifications of the initial and final QRS vectors, so that standard leads, and at times the left precordial leads, resemble left bundle-branch block (Schamroth 1975).

Masquerading BBB is not a specific entity but is an electrocardiographic complex the result of RBBB with varying combinations of LAFB, intramural left ventricular block, left ventricular enlargement/hypertrophy and anterior myocardial infarction or fibrosis.

Since the pioneer Rosembaum's et al studies (Rosembaum 1968; Rosembaum 1973) we know two ECG types of “Masquerading” Bundle-Branch Block. There are a third type that is the association of both:

- I. The “Standard Type” or Standard Masquerading Bundle-Branch Block: consisting of the pattern of left bundle-branch block (LBBB) in the limb leads and right bundle-branch block (RBBB) in the unipolar precordial leads.*
- II. The “Precordial Type” or Precordial Masquerading Bundle-Branch Block*
- III. The Standard and Precordial Masquerading Bundle-Branch Block in Association.*

# I. The “standard type” (“*standard masquerading right bundle-branch block*”)

In “*standard masquerading right bundle-branch block*” the presence of a high degree left anterior fascicular block (LAFB) obscured totally or partially the diagnosis of right bundle branch block (RBBB) only on frontal plane by abolishing (or becomes very small) the final broad S wave in the leads I and aVL (**Ortega-Carnicer 1986**). Consequently, the limb leads may resemble left bundle branch-block (LBBB) although the precordial ECG remain typical for CRBBB. The precordial leads reflect the feature of RBBB. Figure 2

## Conditions necessary for the presence of standard masquerading right bundle –branch block

1. High degree of left anterior fascicular block
2. Right Bundle-Branch Block
3. Bilateral bundle-branch lesions of considerable intensity, which do not completely disrupt the continuity of the branches (**Unger 1958**)
4. Left Ventricular Enlargement or Hypertrophy (LVE/LVH) and marked biventricular hypertrophy
5. Localized block in the left ventricle.
6. Frequent severe fibrosis, or truly massive myocardial infarction mainly in anterior wall.

## Etiologies

- 1) Coronary heart disease
- 2) Long standing systemic hypertension
- 3) Cardiomyopathy Ex. Chronic Chagasic myocarditis
- 4) Lev’s disease
- 5) Association of previous one.

**Prognosis:** always poor.

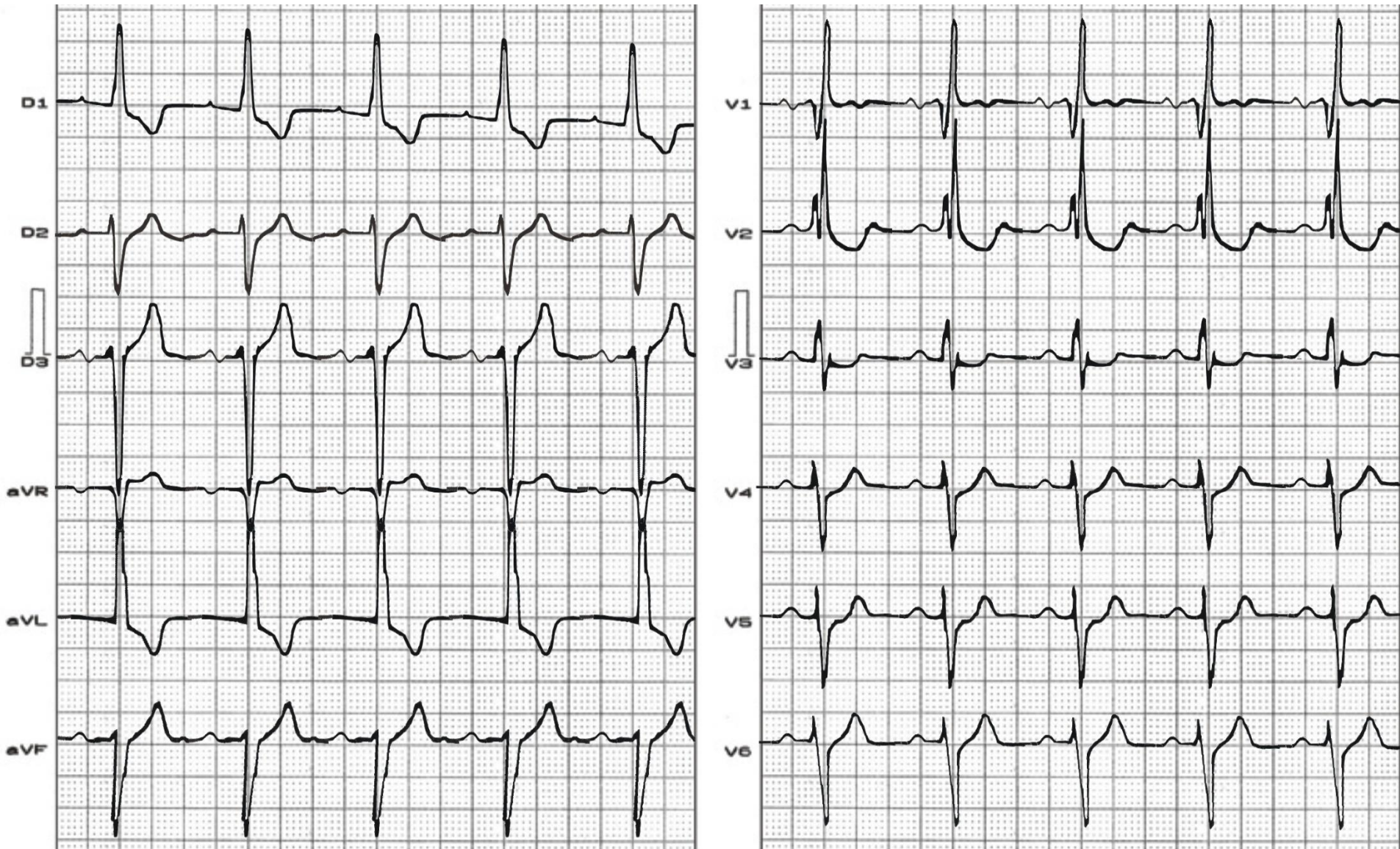


# Table

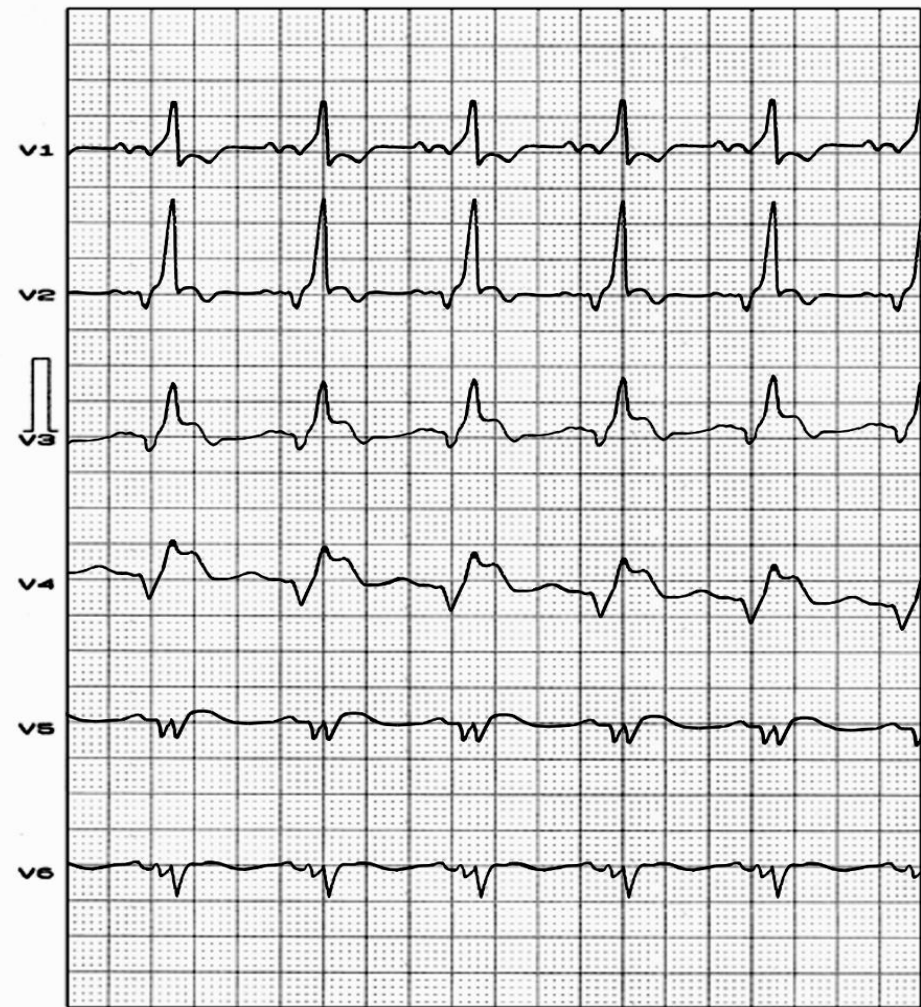
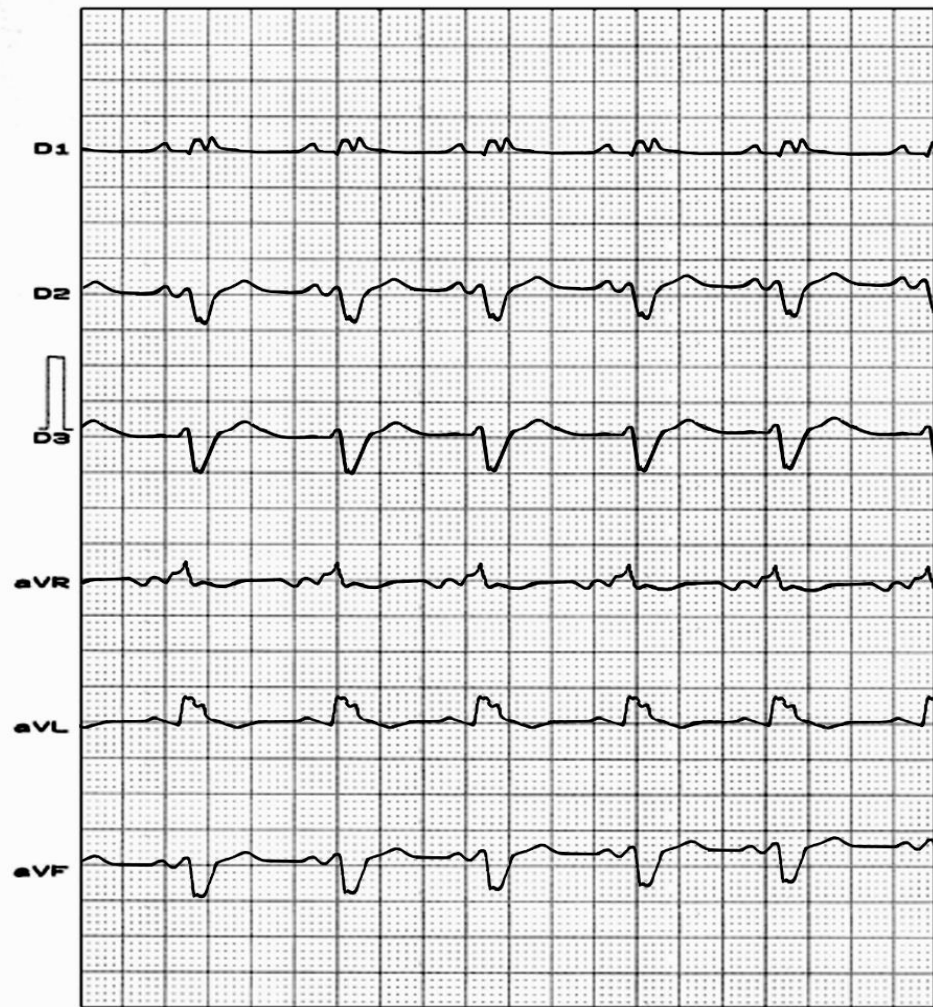
The four main developmental ECG patterns of standard type.

	aVL	I	II	III
1. Uncomplicated LAFB: QRS duration <120ms	qR	qR	rS	Rs (SIII>SII)
2. LAFB with CRBBB: QRS duration $\geq$ 120ms	qRS	qRS	rS with notch on ascending ramp of S	Rs with notch on ascending ramp of S
3. LAFB with CRBBB and diminution of the final QRS vectors. QRS duration $\geq$ 120ms	qR	qR	rS	rS
4. LAFB with CRBBB and diminution of the final QRS vectors and diminution of the initial QRS vectors	R	R	QS	QS

## Example of “Standard Masquerading Right Bundle-branch Block”



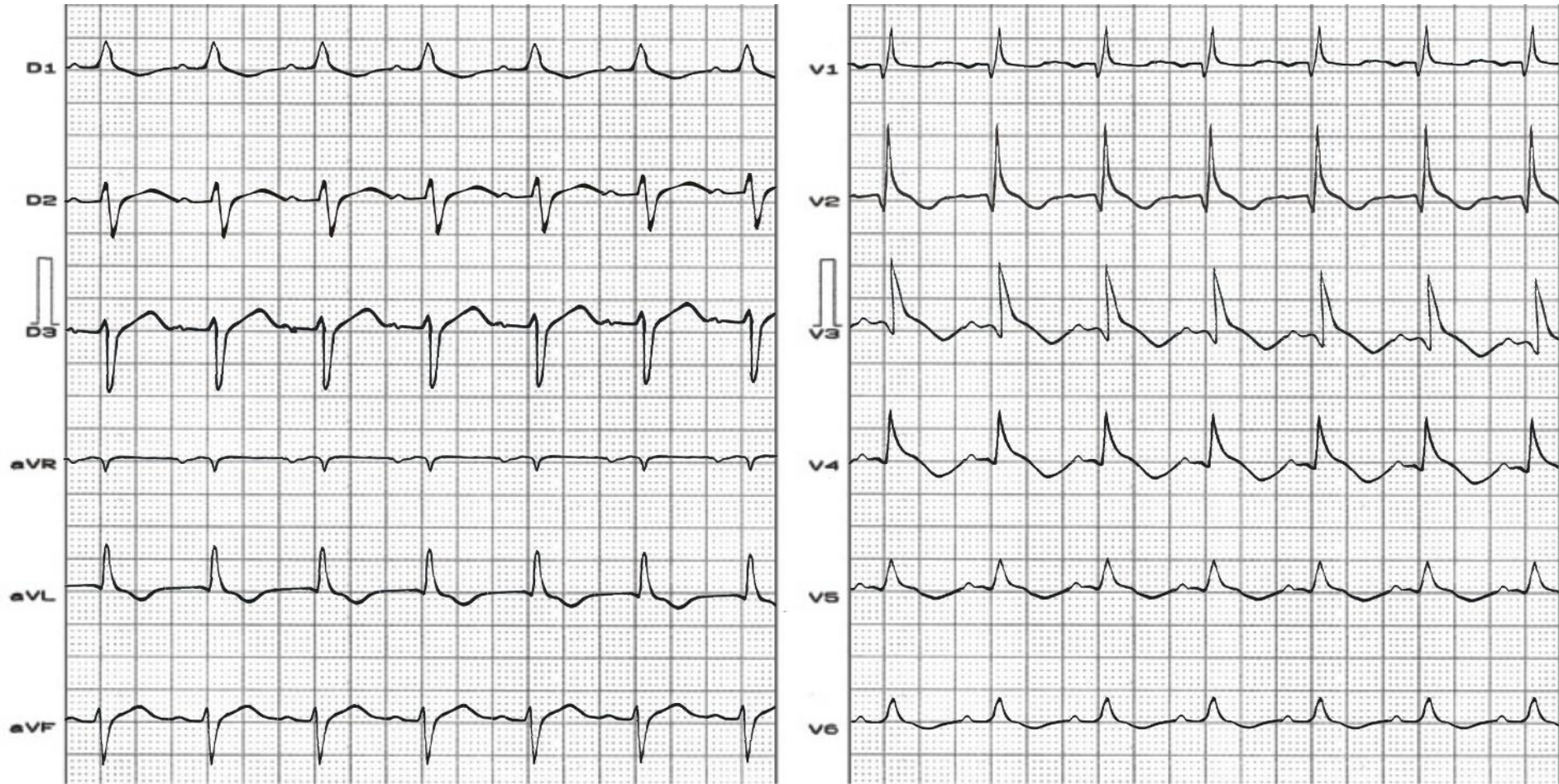
*Extreme QRS left axis deviation ( $\hat{S}AQRS -50^\circ$ ),  $S_{III} > S_{II}$ : LAFB. The limb leads show a LBBB-like pattern, but the precordial leads show a RBBB.  $S_{III} > 15\text{mm}$ : Type IV Rosebaum LAFB: association of LAFB + LVE or LVH.*



*Acute extensive anterior myocardial infarction associated with standard masquerading bundle branch block: LAFB associated with RBBB. Extreme QRS left axis deviation ( $S\hat{A}QRS -70^\circ$ ),  $SIII > SII$ : LAFB. The limb leads show an atypical LBBB-like pattern (isolated r wave in I and aVL), but the right precordial leads show a RBBB.*

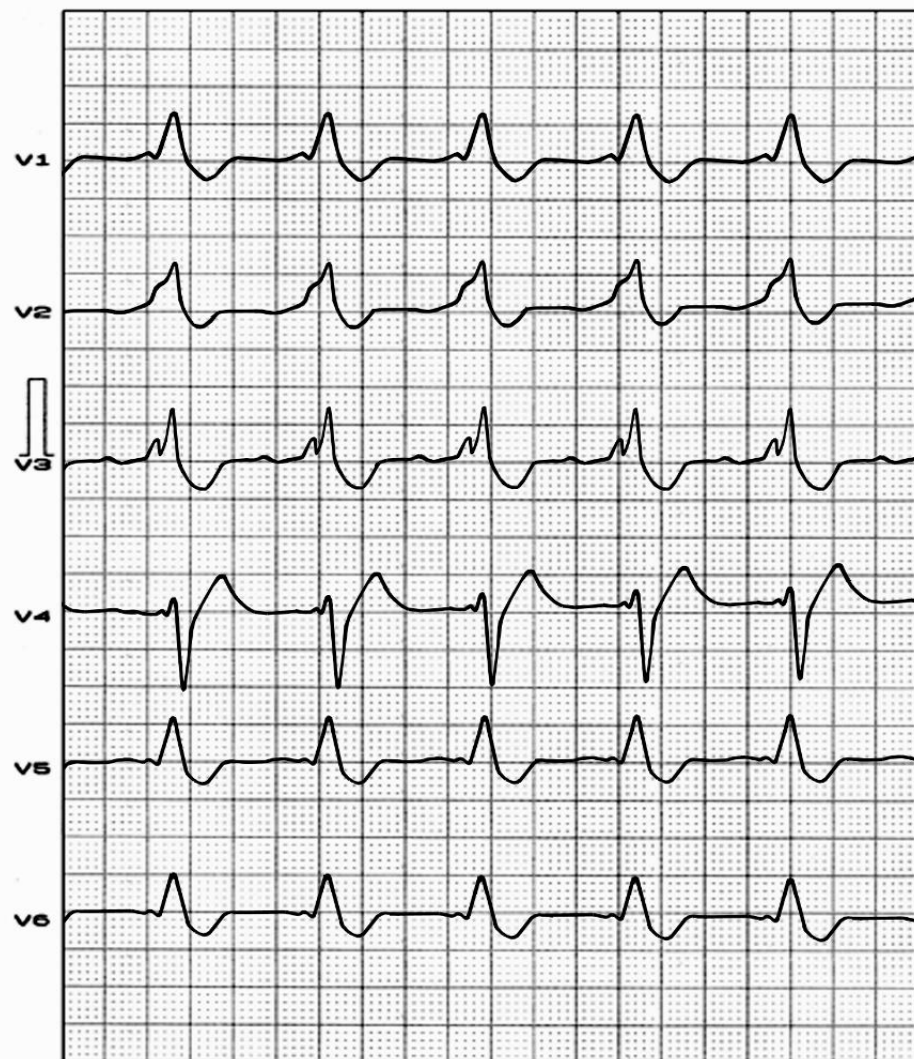
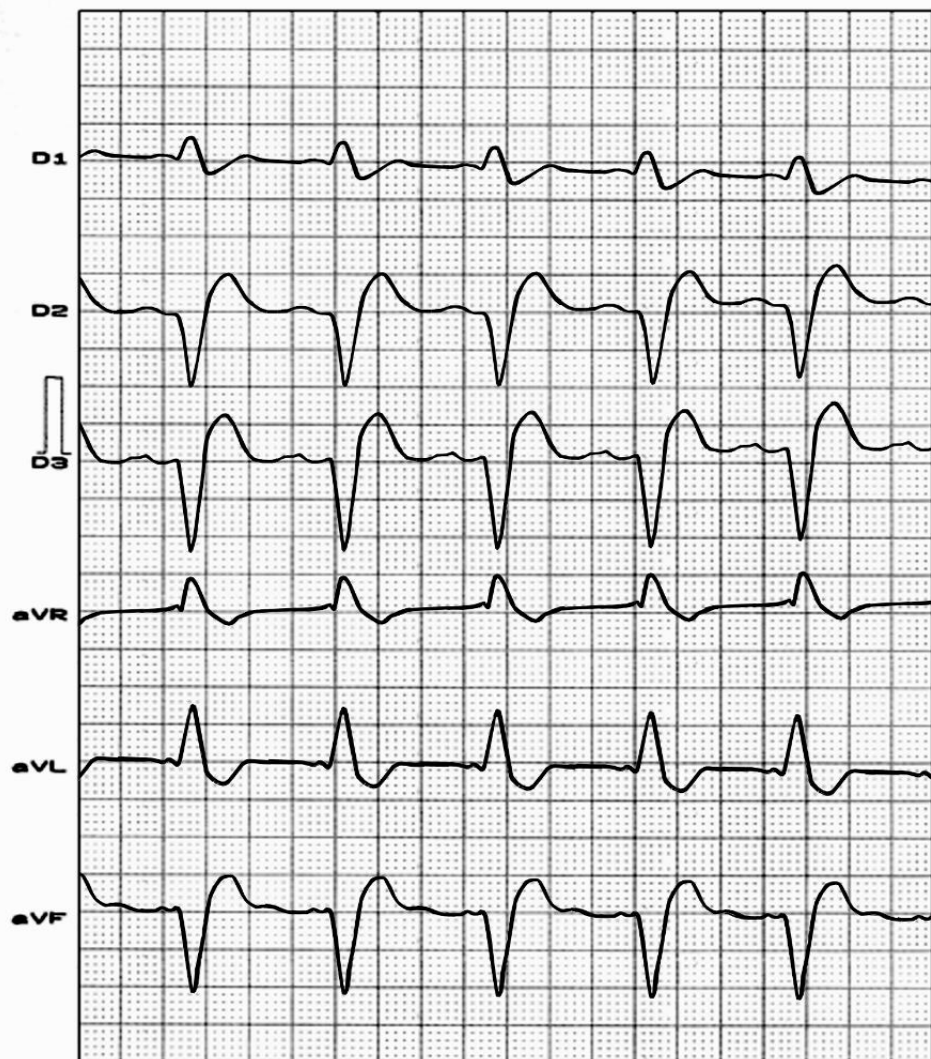
## II. The precordial type (*“precordial masquerading right bundle-branch block”*)

This type shows the pattern of CRBBB in the right precordial leads and complete left branch block pattern (CLBBB) in the left-side precordial leads. This result from CRBBB associated with severe left ventricular hypertrophy/enlargement (LVH/LVE), a localized block in the anterolateral wall of the left ventricle often due to myocardial infarction, and usually LAFB. Presumably, the intramural left ventricular block, together with the LVH or the LAFB, or both, produce predominant leftward forces which tend to cancel out the late rightward forces of the RBBB in the left precordial leads. Finally, masquerading bundle-branch block can be associated with severe and diffuse conduction system disease, and that patients with this finding may require permanent pacemaker implantation, especially if they are symptomatic (**Kowey 1989**).



### III. The Standard and Precordial masquerading bundle-branch block in association

In this case the limb leads show an apparent Left bundle-branch block pattern with extreme left axis deviation (LAFB) and the precordial leads exhibit the pattern of CRBBB in the right precordial leads and LBBB pattern in left precordial leads V5-V6. Additionally, an abnormal Q waves are frequently present on right precordial leads



## References:

1. Ibarrola M, Chiale PA, Pérez-Riera AR, Baranchuk A. Phase 4 left septal fascicular block. *Heart Rhythm*. 2014 Sep;11(9):1655-7
2. Kowey PR, Koslow M, Marinchak RA. Masquerading Bundle-branch block – Electrophysiological correlation. *J electrophysiol*. 1989; 3:156-159.
3. Ortega-Carnicer J, Malillos M, Muñoz L, Rodriguez-Garcia J. Left anterior hemiblock masking the diagnosis of right bundle branch block. *J Electrocardiol*. 1986 Jan; 19: 97-98. Penaloza D, Gamboa R, Sime F. Experimental right bundle branch block in the normal human heart. Electrocardiographic, vectorcardiographic and hemodynamic observations. *Am J Cardiol*. 1961 Dec;8:767-79.
4. Pérez Riera AR, Ferreira C, Ferreira Filho C, et al. Electrovectorcardiographic diagnosis of left septal fascicular block: anatomic and clinical considerations. *Ann Noninvasive Electrocardiol*. 2011 Apr;16(2):196-207..
5. Riera AR, Uchida AH, Schapachnik E, et al. The history of left septal fascicular block: chronological considerations of a reality yet to be universally accepted. *Indian Pacing Electrophysiol J*. 2008 Apr 1;8(2):114-28
6. Riera AR, Kaiser E, Levine P, et al. Kearns-Sayre syndrome: electro-vectorcardiographic evolution for left septal fascicular block of the his bundle. *J Electrocardiol*. 2008 Nov-Dec;41(6):675-8.
7. Riera AR, Ferreira C, Ferreira Filho C, et al. Wellens syndrome associated with prominent anterior QRS forces: an expression of left septalfascicular block? *J Electrocardiol*. 2008 Nov-Dec;41(6):671-4.
8. Pérez-Riera AR, Baranchuk A. Unusual Conduction Disorder: Left Posterior Fascicular Block + Left Septal Fascicular Block. *Ann Noninvasive Electrocardiol*. 2014 Jul 7. doi: 10.1111/anec.12185. [Epub ahead of print]
9. Richman JL, Wolff L. Left bundle branch block masquerading as right bundle branch block. *Am Heart J*. 1954 Mar; 47: 383-393.
10. Rosenbaum MB. Types of right bundles branch block and their clinical significance. *J Electrocardiol*. 1968; 1(2):221-232.

11. Rosenbaum MB, Elizari MV, Lazzari JO. Los hemibloqueos. Buenos Aires; Paidós 1968.
12. Rosenbaum MB, Yesuron J, Lazzari JO, Elizari MV. Left anterior hemiblock obscuring the diagnosis of right bundle branch block. *Circulation*. 1973 Aug; 48: 298-303.
13. Schamroth L, Dekock J. The concept of 'masquerading' bundle-branch block. *S Afr Med J*. 1975 Mar 15; 49: 399-400.
14. Uchida AH, Moffa PJ, Riera AR, et al. Exercise-induced left septal fascicular block: an expression of severe myocardial ischemia. *Indian Pacing Electrophysiol J*. 2006 Apr 1;6(2):135-8
15. Unger PN, Lesser ME, Kugel VH, Lev M, The Concept of "Masquerading" Bundle-Branch Block An Electrocardiographic-Pathologic Correlation *Circulation*. 1958;17:397-409.