

Diffuse Transient Pseudo-Brugada ECG pattern in the setting of a Left Anterior Descending Artery obstruction: Peri-ischemic block



Andrés Ricardo Pérez-Riera, M.D. Ph.D.
Laboratorio de Escrita Científica da
Faculdade de Medicina do ABC, Santo
André, São Paulo, Brazil
<https://ekgvvg.wordpress.com>



Raimundo Barbosa-Barros, MD
Centro Coronariano do Hospital de Messejana Dr.
Carlos Alberto Studart Gomes, Fortaleza – CE- Brazil

Case report

65-year-old Caucasian male, type2 diabetes, hypertension, smoking since long time ago. He was in regular use of losartan, furosemide, simvastatin, and metformin. He had previous medical history of cerebrovascular accident occurred 1 year ago with sequelae (hemiparesis and aphasia). There was no history of syncope, palpitations, or family history of sudden cardiac death.

He arrived in our Emergency Department (ED) after collapsing suddenly while he was watching TV. He was taken to the Hospital by his relatives, where he entered with FV (Figure 1). After 6 separate defibrillations and 5 min of CPR, the patient had his circulation spontaneously back.

Heart rate of 75 bpm and blood pressure of 154/100 mmHg.

Lab: Normal calcium and magnesium serum levels, cardiac troponin T (cTnT): 0.871, creatinine: 0.87, C-reactive protein (CRP): 3,27mg/L (CRP levels ≥ 2 mg/L likely need more intense management and treatment for heart disease). .

Serum potassium measured by gasometry = 2.81?

Electrocardiogram (figure 2) revealed broad QRS complexes and bizarre coved-type ST-segment elevation across precordial leads (V1 through V6), I and aVL, followed by negative T wave consistent with anterolateral type 1 Brugada pattern.

Emergent Coronary angiogram showed significant stenosis (80%) with thrombus in the proximal left anterior descending artery, which needed stent emergently. After, percutaneous transluminal coronary angioplasty (PTCA) with insertion of drug-eluting stent in the LAD, diffuse ST-segment elevation was solved and did not recur. In addition, broad QRS disappeared.

Echocardiography showed normal left ventricular ejection fraction and no segmental wall motion abnormality.

Question

Which is the clinical-electrocardiographic diagnosis?

He was resuscitated with 6 cycles of defibrillation

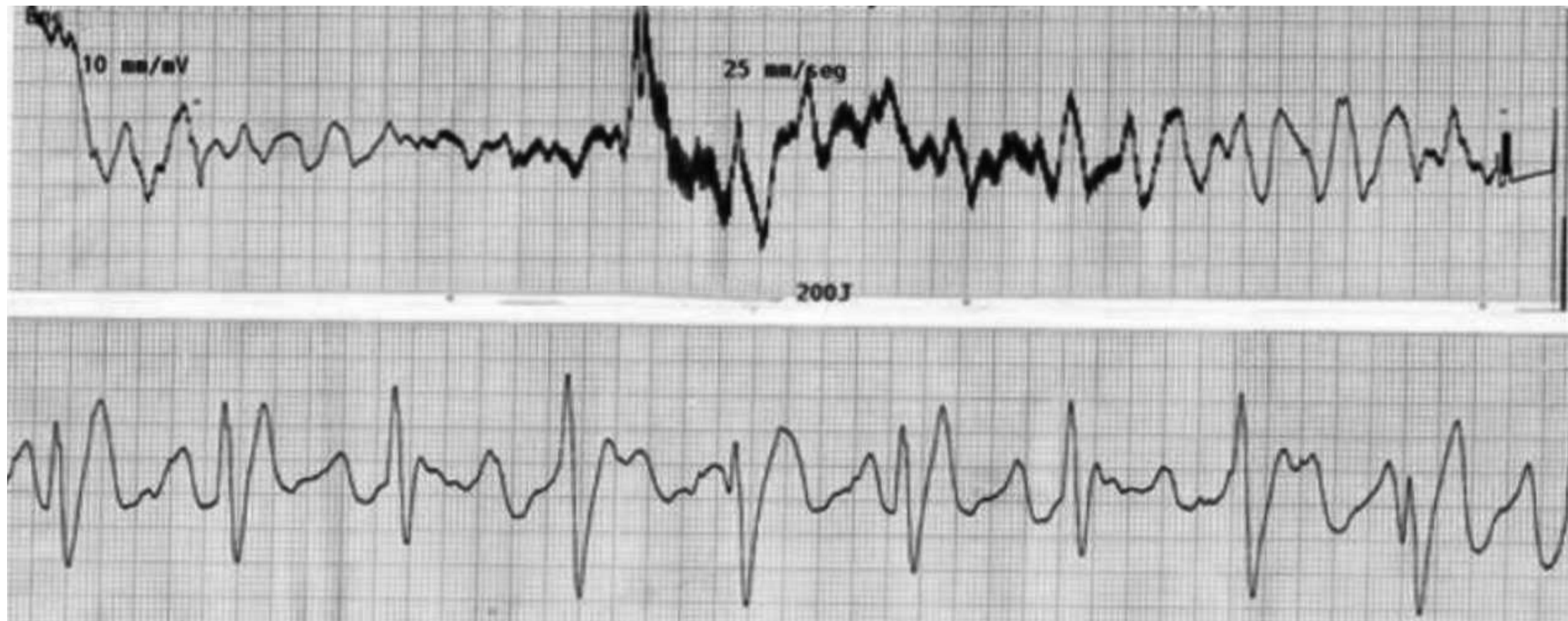


Figure 2 ECG performed immediately after cardioversion

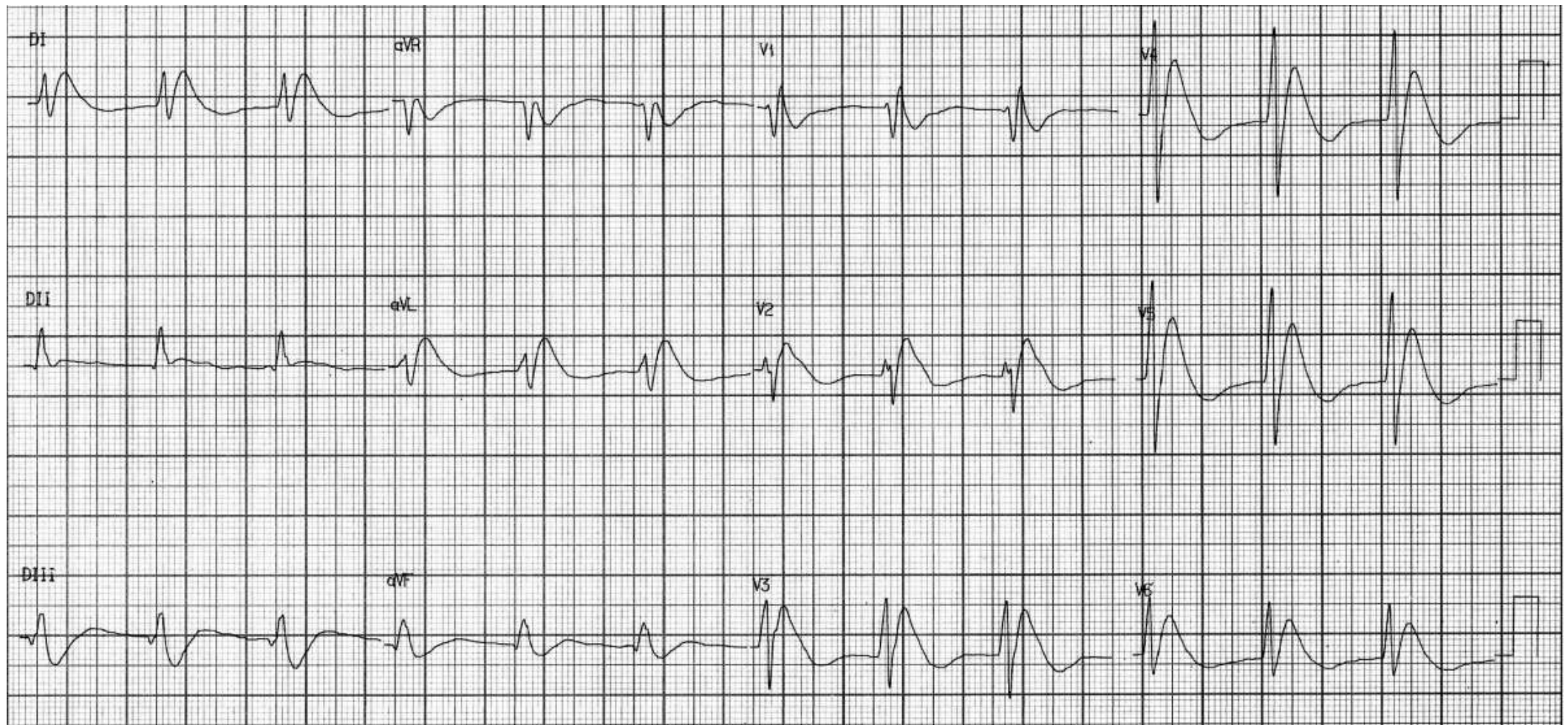
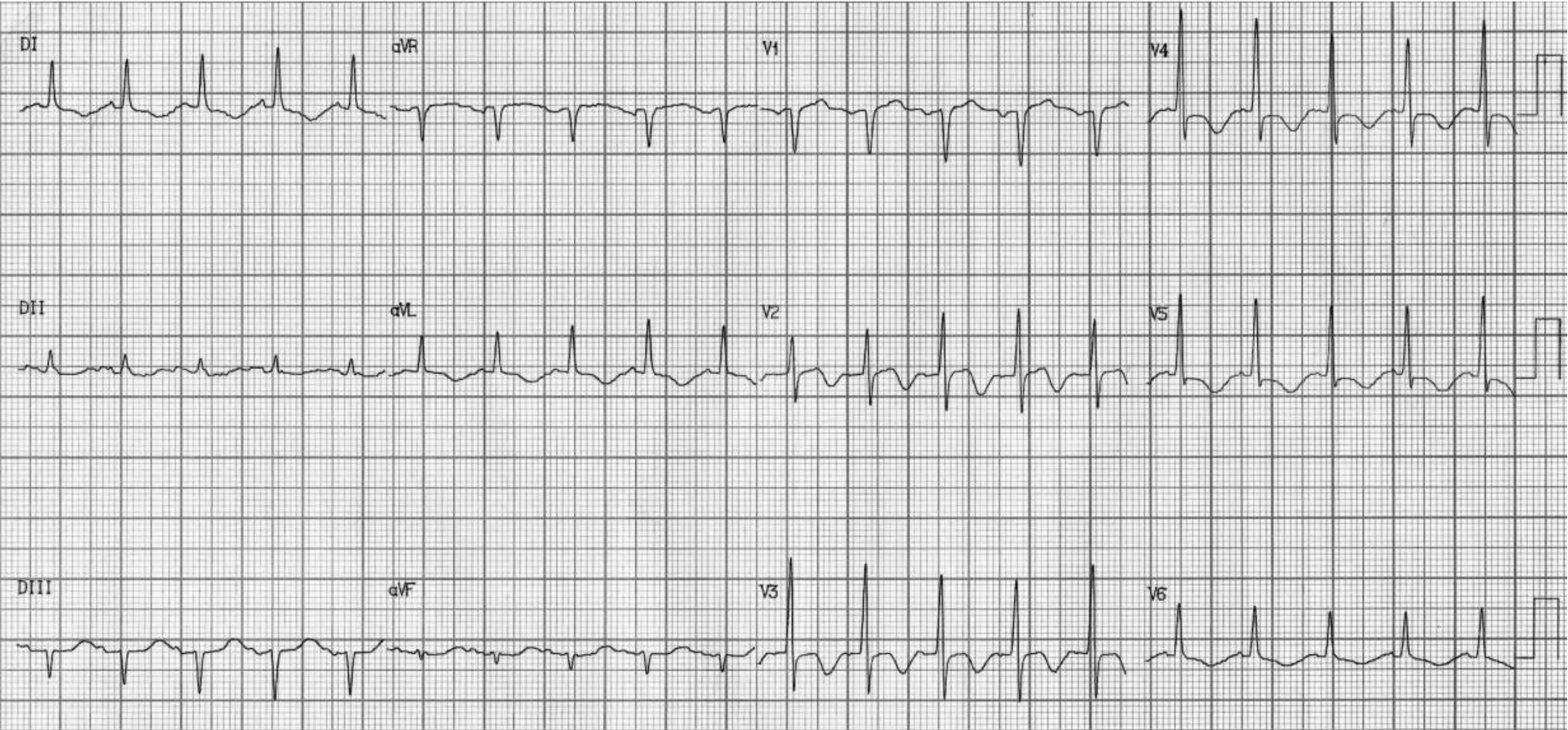
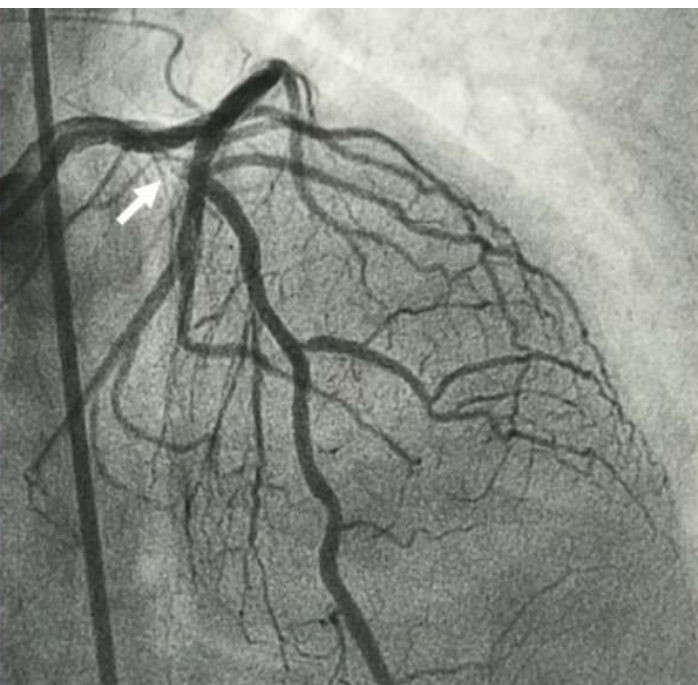
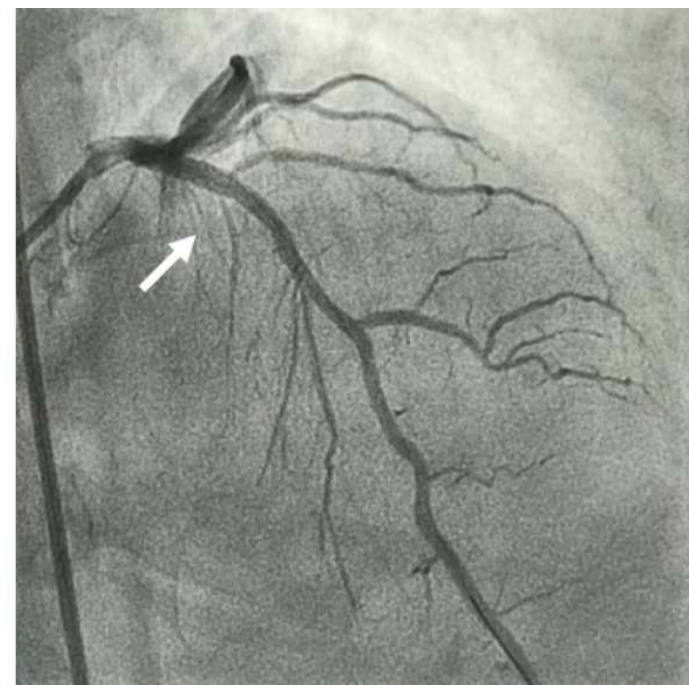
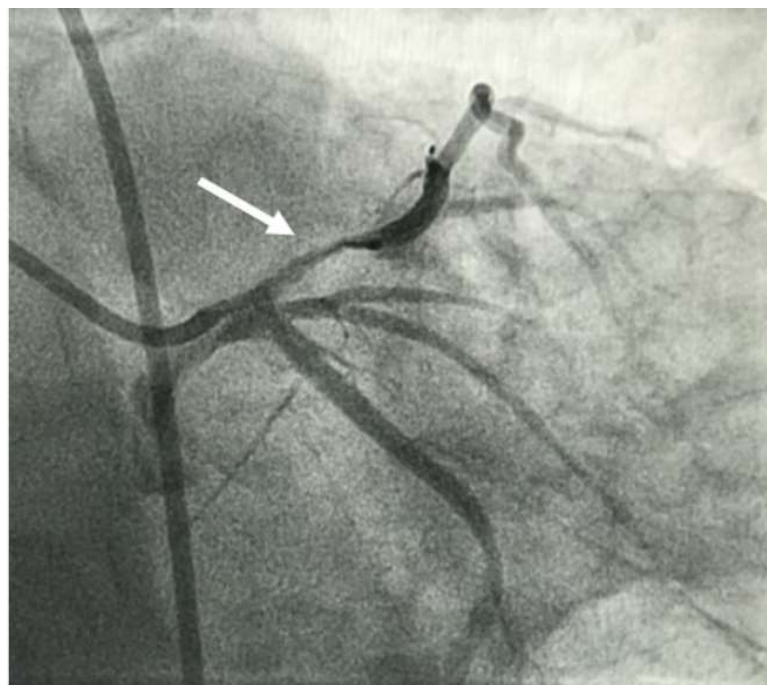


Figure 3 ECG performed immediately after percutaneous coronary intervention (PCI) with insertion of drug-eluting stent





Left anterior oblique.
LAD with 80% proximal obstruction with
thrombus.



After drug eluting stent (DES)
placement

Colleagues opinions

I would like to comment only 3 main points:

1. The ischemic origin of the ventricular arrhythmia is highly likely. Attributing it mainly to "Brugada syndrome" will be purely speculative.
2. I have no problem with the "Brugadanoid" pattern of the QRS-T complexes in Figure 2. However it should be noted that the rhythm on this ECG has certainly not a SINUS ORIGIN but rather a high septal origin.
3. Acute anterior MI and Brugada syndrome share many ECG and electrophysiologic features. Many cases of "acute MI" are in fact "Brugada - ECG patterns". However the fact that the trace Figure 1 was recorded immediately after multiple cardioversions may suggest a relationship with the latter rather than with ischemia. Please also note some T wave alternance on a few beats on ECG strip Figure 1 performed just after cardioversion.

In summary: my own diagnosis is: Acute ischemic event with VF; Bruganoid ECG Changes mainly due to multiple DC shocks.

BB

Bernard **Belhansen DM Israel**

DM Israel



Hello, a special case. Immediately after resuscitation, bizarre ECG patterns may be present. It does not look like sinus rhythm in the first ECG. Ventricular rhythm or junctional rhythm with broad QRS? Very prominent J/Osborn waves with “pseudo-Brugada”-type pattern. The location of the prominent J waves seem to be consistent with proximal LAD occlusion. Also RBBB? The post-PCI ECG is consistent with “post-ischemic” T-wave inversion in the LAD territory, including the first diagonal branch.

Best regards

Kjell Nikus MD PhD

**Tampere University Hospital (TAUH)
Tampere, Finland**



Hello,

Thank you for including me in your case distributions, all very interesting.

Likely acute MI from LAD occlusion with ECG after cardioversion demonstrating dominant profound anterior epicardial injury with some local conduction delay, probably compounded by metabolic acid-base disturbances related to cardiac arrest, and possibly also local epicardial injury related to CPR. Congratulations on reperfusion, with absence of Q wave infarction initially, loss of ST elevation with QRS narrowing, and likely reperfusion T wave inversions afterward. Is there a followup ECG a day or two later?

My only comment, possible not shared by others, is that I would not really think of this as "transient pseudo-Brugada ECG pattern," but rather think the reverse, with true Brugada syndrome as "pseudo anteroseptal injury pattern" -- with both situations potentially modulated by variable profound changes in anteroseptal epicardial action potential. Has there ever been a Brugada patient with such diffuse anteroseptal, anterior, and anterolateral ST segment changes?

Again, thank you for sharing the case. I look forward to seeing other responses.

Regards,

Paul

Paul Kligfield, MD

Professor of Medicine

Weill Cornell Medical College
New York, New York 10022 USA



Estimados colegas: Permitanme presentarme, soy Jose Joglar de La Universidad De Southwestern, en Texas
Soy el editor the la section the ECG en la revista Circulation.Por favor, consideren someter este case a la seccion the ECG de Circulation, me interesaria mucho.

Este caso es muy interesante. En la literatura se menciona el concepto the "Brugada Phenocopy"

https://www.researchgate.net/publication/269182327_Brugada_phenocopy_induced_by_ischemia_or_Brugada_syndrome_unmasked_by_ischemia

Jose A. Joglar, MD, FACC, FAHA, FHRS

Professor of Internal Medicine

Fellowship Program Director, Clinical Cardiac Electrophysiology

Director of Cardiology, Parkland Memorial Hospital

Elizabeth Thaxton Page and Ellis Batten Page Professorship in Clinical Cardiac Electrophysiology Research

UT Southwestern Medical Center

5323 Harry Hines Blvd, E5.310

Dallas, TX 75390-8830 Ph: 214-648-9638

Fax: 214-648-9639

Email: Jose.Joglar@UTSouthwestern.edu



Jose Joglar, M.D., is a Professor in the Department of Internal Medicine at UT Southwestern Medical Center. He heads the arrhythmia program for UT Southwestern, and he holds the Elizabeth Thaxton Page and Ellis Batten Page Professorship in Clinical Cardiac Electrophysiology Research. He was recognized as a *D Magazine* Best Doctor for Cardiac Electrophysiology in 2011, 2012, and 2014. After earning his medical degree from the University of Puerto Rico's School of Medicine, Dr. Joglar completed his residency in internal medicine, a fellowship in cardiology, and a fellowship in clinical cardiology electrophysiology at UT Southwestern. He is now the director of the Clinical Cardiac Electrophysiology Program, the Electrophysiology Laboratory and Device Clinic, and the Invasive Cardiac Laboratories (Cath and EP Labs). He conducts research in defibrillator medicine and leads his team in a variety of clinical trials for new devices and drugs to treat heart rhythm problems. A widely published author and editor, Dr. Joglar serves on the editorial board of the *Journal of Cardiovascular Electrophysiology* and reviews articles for the *New England Journal of Medicine*, *Heart Rhythm Society Journal*, *American Heart Journal*, *American Journal of Cardiology*, and *Pacing and Clinical Electrophysiology*. He is a member of the Dallas County Medical Society, and he is a fellow of the Heart Rhythm Society, the American Heart Association (AHA) and the American College of Cardiology (ACC). In 2014 he served on the writing committee for the AHA Guidelines of Cardiac Arrest in Pregnancy and is co-chair of the AHA/ACC Guidelines for SVT.

Thanks for showing a beautiful example of Brugada phenocopy due to severe ischemia. Similar tracings have been described with angioplasty of the LAD.

Melvin **Scheinman** Professor of Medicine
350 Parnassus Ave
San Francisco, CA 94117b/t Hillway Ave & Hill Point Ave
Inner Sunset USA.



Final comments



Andrés Ricardo **Pérez-Riera, M.D. Ph.D.**
Laboratorio de Escrita Científica da
Faculdade de Medicina do ABC, Santo
André, São Paulo, Brazil
<https://ekgvcg.wordpress.com>



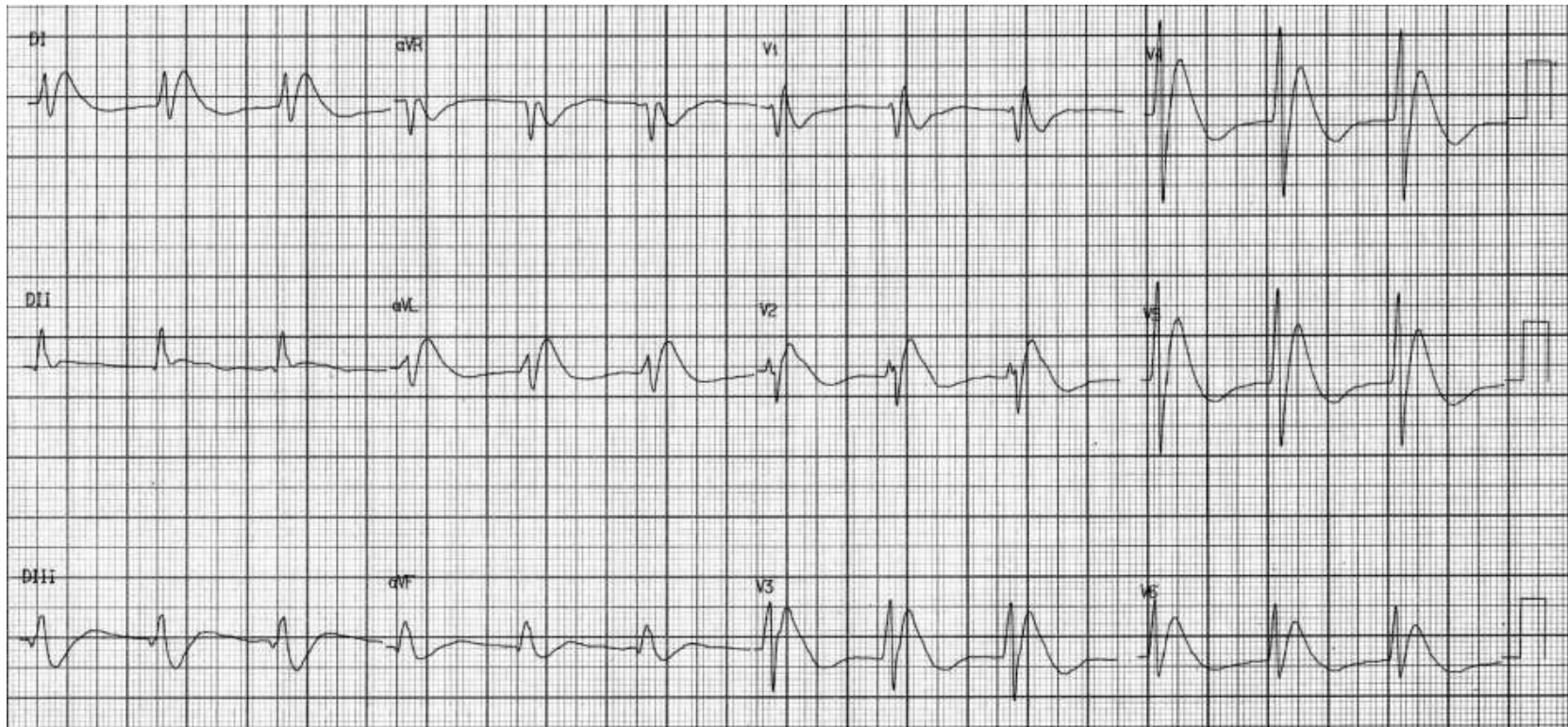
Raimundo **Barbosa-Barros, MD**
Centro Coronariano do Hospital de Messejana Dr.
Carlos Alberto Studart Gomes, Fortaleza – CE- Brazil

"Watch your thoughts, for they become words. Choose your words, for they become actions. Understand your actions, for they become habits. Study your habits, for they will become your character. Develop your character, for it becomes your destiny".

"Cuida do teus pensamentos, porque se tornarão palavras. Escolha tuas palavras, porque se tornarão ações. Entenda tuas ações, porque se tornarão hábitos. Estuda teus hábitos, pois eles se tornarão teu caráter. Desenvolva teu caráter, porque se tornará teu destino".

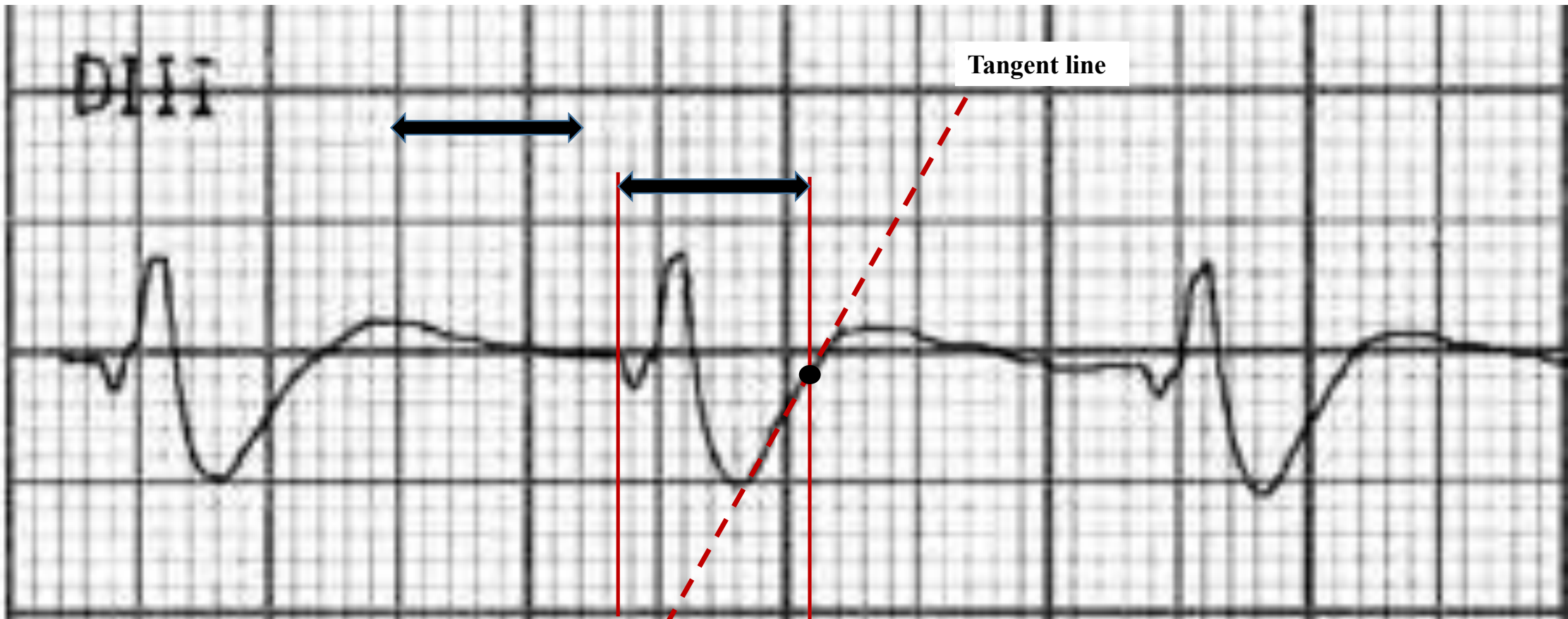
"Cuida tus pensamientos, porque se vuelven palabras. Elige tus palabras, porque se vuelven acciones. Comprende tus acciones, porque se vuelven hábitos. Estudia tus hábitos, porque se convertirán en tu carácter. Desarrolla tu carácter, porque se convierte en tu destino".

Figure 2 ECG performed immediately after cardioversion



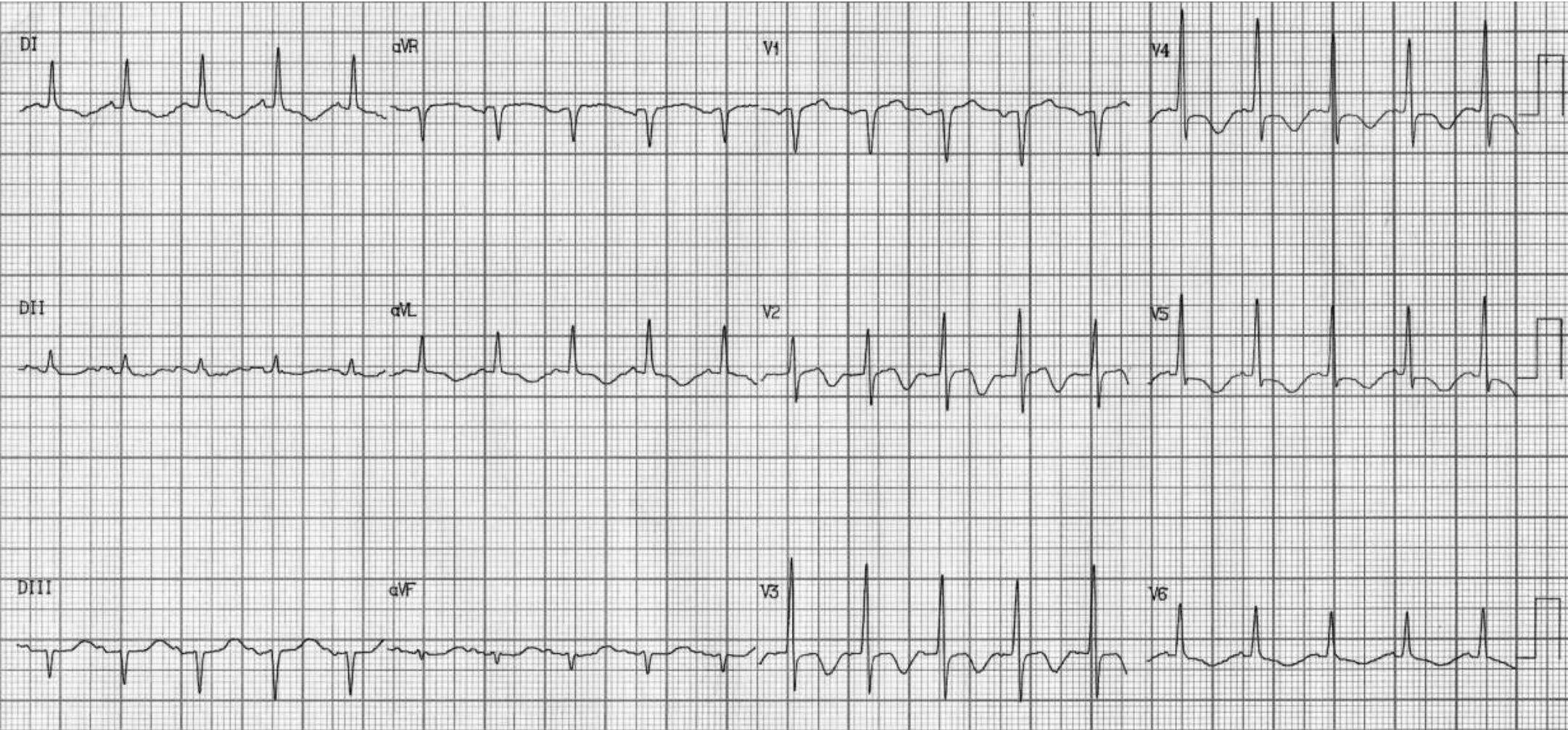
Regular no sinus rhythm: Accelerated junctional rhythm (this rhythm occurs when the rate of an AV junctional pacemaker exceeds that of the sinus node. This situation arises when there is *increased automaticity* in the AV node coupled with *decreased automaticity* in the sinus node), HR 94bpm + very broad QRS complexes (QRS duration =280ms!!!). J point and ST segment elevation >2mm in the anterolateral wall followed by negative T wave.

Diagnosis: Non specific intraventricular conduction disturbance: **Peri-ischemic block** is applied only to changes in QRS configuration associated with QRS widening (Surawicz 1997). It is transient \uparrow in QRS duration accompanies the ST-segment deviation seen with acute injury (the present case). This term is recommended when a transient increase in QRS duration accompanies the ST-segment deviation/T seen with acute injury. Reversible QRS changes during AMI are attributed to passive pull by the ST-segment shift and intraventricular conduction disturbance (Surawicz 1995; 1998).



The tangent line method is used to determine the exact end of the QRS complex. It consists of drawing a straight line tangent to the ascending branch of the last negative wave (S wave) or the last positive wave (R wave) of the QRS complex. The end of the QRS is considered the point when the straight tangent line separates from the ECG line.

Figure 3 ECG performed immediately after percutaneous coronary intervention (PCI) with insertion of drug-eluting stent



Post-ischemic diffuse T-wave inversion in the anterolateral wall (proximal LAD territory obstruction)

Why do we observe a diffuse T-wave inversion in the anterolateral wall?

Answer: The left main coronary artery (LMCA) arises from the left coronary cusp and the right coronary artery arises from the right coronary cusp.

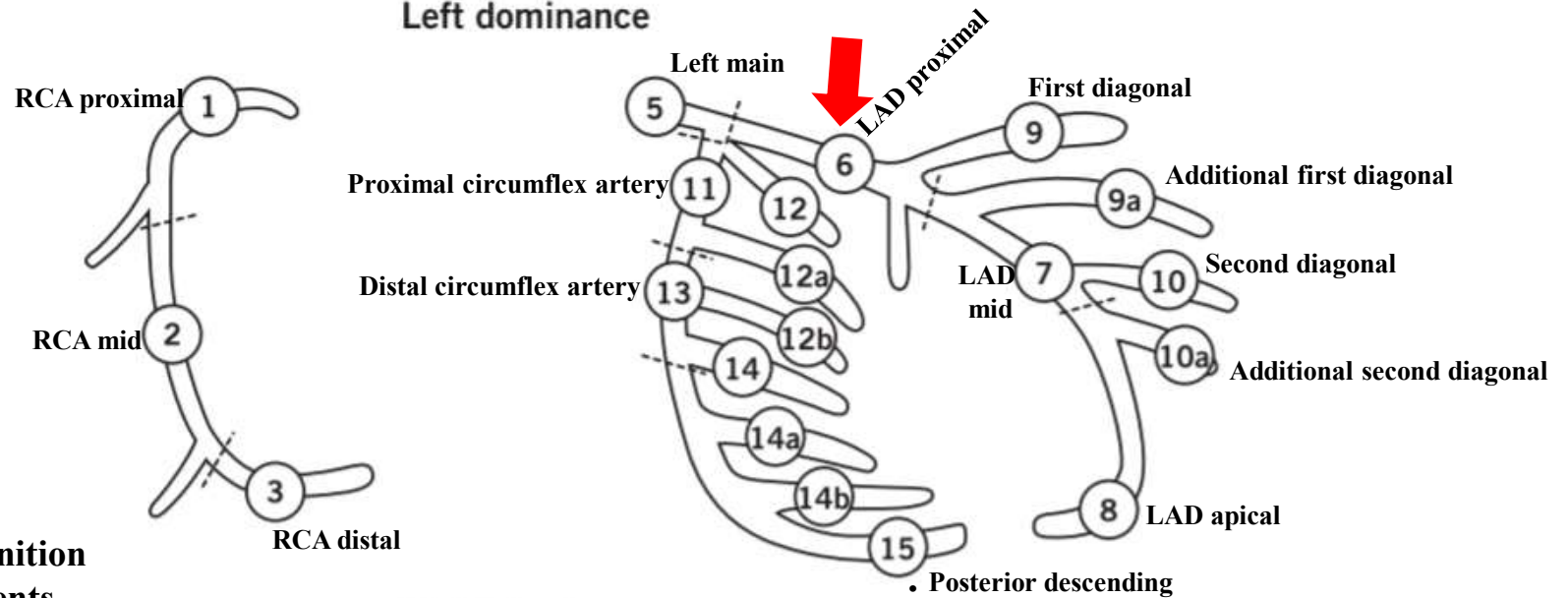
The LMCA artery usually divides into two branches, known as the **left anterior descending** (LAD) and the **left circumflex** (LCx) coronary arteries. In some patients, a third branch arises in between the LAD and the Cx. This is known as the ramus, intermediate (Int), or optional diagonal coronary artery. The LAD travels in the anterior interventricular groove that separates the RV and the LV, in the front of the heart. The diagonal (Dx) branch comes off the LAD and runs diagonally across the anterior wall towards its outer or LV lateral portion. Thus, the Dx supplies blood to the anterolateral portion of the left ventricle. A patient may have one or several Dx branches. The first Dx branch serves as the boundary between the **proximal** and **mid** portion of the LAD. Thus, the portion of the artery prior to the origin of the Dx is known as the **proximal** LAD, while the segment just below the Dx is the **mid** LAD. The **distal** segment of the LAD is the terminal third of the artery. Additionally, LAD is graded into three types: **Type 1**: Falls short of Apex. Patients with Type 1 LAD are at risk of LV apical ischemia if the dominant LCX /RCA is not supportive; **Type 2**: Reach up to the LV apex; **Type 3**: Wraps around LV apex and travels some distance in the posterior Inter-ventricular groove. When LAD wraps around the LV apex, anterior MI due to LAD occlusions can show changes in inferior leads (Antero Inferior MI).

In ideal anatomic /Physiologic conditions LAD should nearly meet the PDA to prevent any water shed area.

There is usually a trade off between the terminal LAD and length of PDA (whether it arises from LCx or RCA).

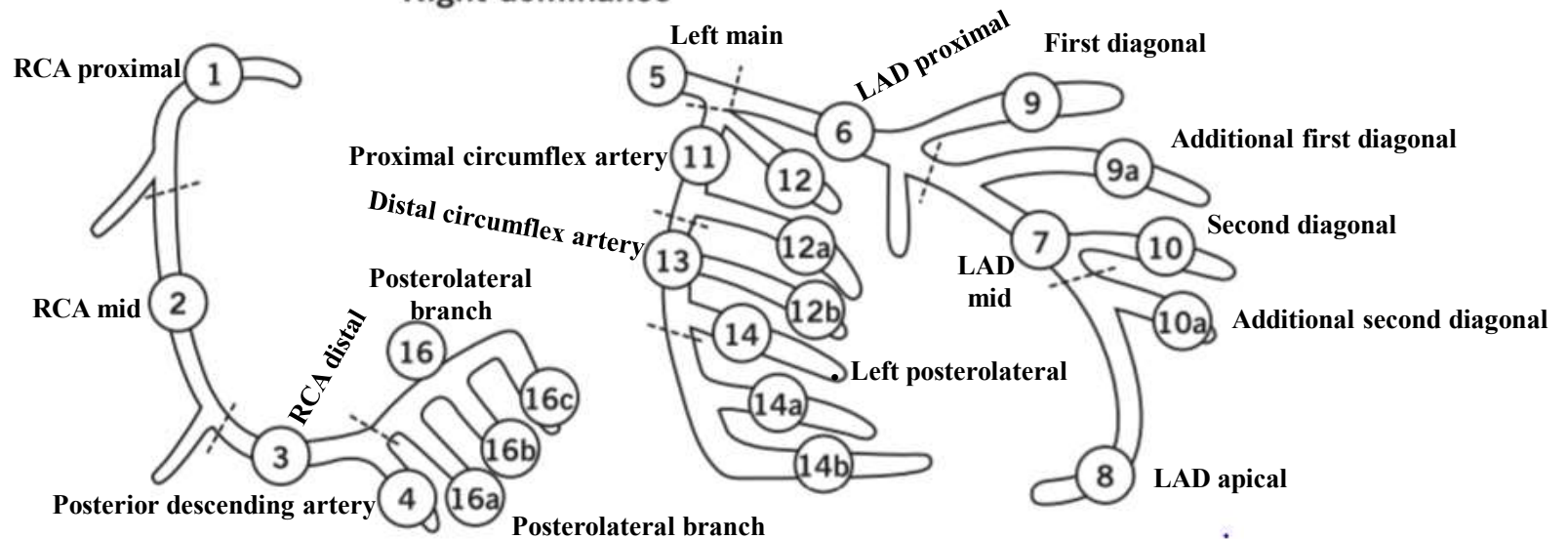
There is some evidence to suggest the site of ventricular rupture in anterior MI is related to the gap in the LAD/PDA drainage zones. A long LAD is definitely a hemodynamic advantage in physiology. Of course it goes without saying... when it's likely to get obstructed it is always better to have a **Type 1**.

Left dominance



See in the next slide the definition of the coronary tree segments

Right dominance



Definition of the coronary tree segments

- 1. **RCA proximal:** From the ostium to one half the distance to the acute margin of the heart.
- 2. **RCA mid:** From the end of first segment to acute margin of heart.
- 3. **RCA distal:** From the acute margin of the heart to the origin of the posterior descending artery.
- 4. **Posterior descending artery:** Running in the posterior interventricular groove.
- 16. **Posterolateral branch from RCA:** Posterolateral branch originating from the distal coronary artery distal to the crux.
 - 16a. **Posterolateral branch from RCA:** First posterolateral branch from segment
 - 16b. **Posterolateral branch from RCA:** Second posterolateral branch from segment
 - 16c. **Posterolateral branch from RCA:** Third posterolateral branch from segment
- 5. **Left main:** From the ostium of the LCA through bifurcation into left anterior descending and left circumflex branches.
- 6. **LAD proximal:** Proximal to and including first major septal branch.
- 7. **LAD mid:** LAD immediately distal to origin of first septal branch and extending to the point where LAD forms an angle (RAO view). If this angle is not identifiable this segment ends at one half the distance from the first septal to the apex of the heart.
- 8. **LAD apical:** Terminal portion of LAD, beginning at the end of previous segment and extending to or beyond the apex.
- 9. **First diagonal:** The first diagonal originating from segment 6 or 7.
 - 9a. **First diagonal a: Additional first diagonal** originating from segment 6 or 7, before segment 8.
- 10. **Second diagonal:** Originating from segment 8 or the transition between segment 7 and 8.
 - 10a. **Second diagonal a: Additional second diagonal** originating from segment 8.
- 11. **Proximal circumflex artery:** Main stem of circumflex from its origin of left main and including origin of first obtuse marginal branch.
- 12. **Intermediate/anterolateral artery:** Branch from trifurcating left main other than proximal LAD or LCX. It belongs to the circumflex territory.
 - 12a. **Obtuse marginal a:** First side branch of circumflex running in general to the area of obtuse margin of the heart.
 - 12b. **Obtuse marginal b:** Second additional branch of circumflex running in the same direction as 12.
- 13. **Distal circumflex artery:** The stem of the circumflex distal to the origin of the most distal obtuse marginal branch, and running along the posterior left atrioventricular groove. Caliber may be small or artery absent.
 - 14. **Left posterolateral:** Running to the posterolateral surface of the left ventricle. May be absent or a division of obtuse marginal branch.
 - 14a. **Left posterolateral a:** Distal from 14 and running in the same direction.
 - 14b. **Left posterolateral b:** Distal from 14 and 14 a and running in the same direction.
- 15. **Posterior descending:** Most distal part of dominant left circumflex when present. It gives origin to septal branches. When this artery is present, segment 4 is usually absent.

Non specific or unspecified intraventricular conduction disturbance, defect/or delay (NICD)

Other denominations: Non-Specific Intraventricular Conduction Delay (NSIVCD) or Non-specific Intraventricular Conduction Defect (NIVCD)

Definition

It is defined as an ECG pattern characterized by a wide QRS (≥ 120 ms in adults, >90 ms in children 8 to 16 years of age, and >80 ms in children younger than 8 years of age) without the appearance of LBBB, RBBB, ventricular pre-excitation, or masquerading bundle branch block (Surawicz 2009).

Observation: Masquerading bundle branch block is characterized by precordial leads that show a RBBB pattern while the limb leads resemble a LBBB+LAFB (extreme superior QRS axis deviation between -80° to -120°) (Elizari 2013). When LAFB is advanced, the QRS axis is $\approx -60^\circ$. It can lead to a very small or even absent final s wave in lead I. In this scenario, ECG masquerading RBBB and it imitates LBBB in limb leads. When RBBB with LAFB resembles LBBB in the limb leads, it is called “standard masquerading bundle branch”. The so called precordial masquerading, the final S wave is absent in the left precordial leads (V5 and V6). In both, RBBB is diagnosed by typical QRS pattern in lead V1. This dromotropic disturbance is a rare but important finding on the ECG that usually indicates severe and diffuse conduction system disease with poor prognosis. This finding on an ECG is almost invariably associated with severe underlying heart disease.

Etiological and morphological classification of Non-specific Intraventricular Conduction Defects/Disturbance (NICD)

- 1. Severe hyperkalemia**
- 2. Some types of left ventricular enlargement/hypertrophy.**
- 3. Sodium Channel Blocking Medications**

3a Tricyclic antidepressants (TCAs) overdose: e. i. amitriptyline, nortriptyline, trimipramine, despiramine, protriptyline, and dothiepin poisoning. These are caused by blockage of cardiac fast sodium channels leading to disturbances of cardiac conduction and QRS prolongation.

3b Class Ia antiarrhythmic drugs intoxication (Vaughan-Williams classification): Quinidine, procainamide, and dysopiramide. These are sodium channel blockers with intermediate association/dissociation, prolongation of action potential duration and QRS complex prolongation for values >140 ms or >35% of the baseline tracing, constitutes absolute indication of interruption of the drug (**Heissenbuttel 1970**).

3c Class Ic antiarrhythmic drugs -sodium channel blockers with slow association/dissociation, pronounced reduction in phase 0 slope; no effect on action potential duration or effective refractory period (flecainide, propafenone, and moricizine).

3d Local anaesthetics (bupivacaine, ropivacaine)

3e Antimalarials (chloroquine, hydroxychloroquine)

3f Dextropropoxyphene

3h Carbamazepine

3g Quinine

- 4. Hypothermia**
- 5. Peri-ischemic block (this is the present case)**
- 6. Peri-infarction block**
- 7. Atypical LBBB**
- 8. Intraventricular parietal blocks**

Note: To date, no prospective, randomized, blinded trials have been performed to assess the benefit of CRT in patients with NICD. Indeed, the majority of patients included in the major CRT clinical trials were patients with LBBB, because this therapy had been initially proposed to specifically target the detrimental impact of the LBBB ventricular activation sequence (**Eschaliier 2015**).

Prevalence of the Nonspecific intraventricular conduction delay (NICD)

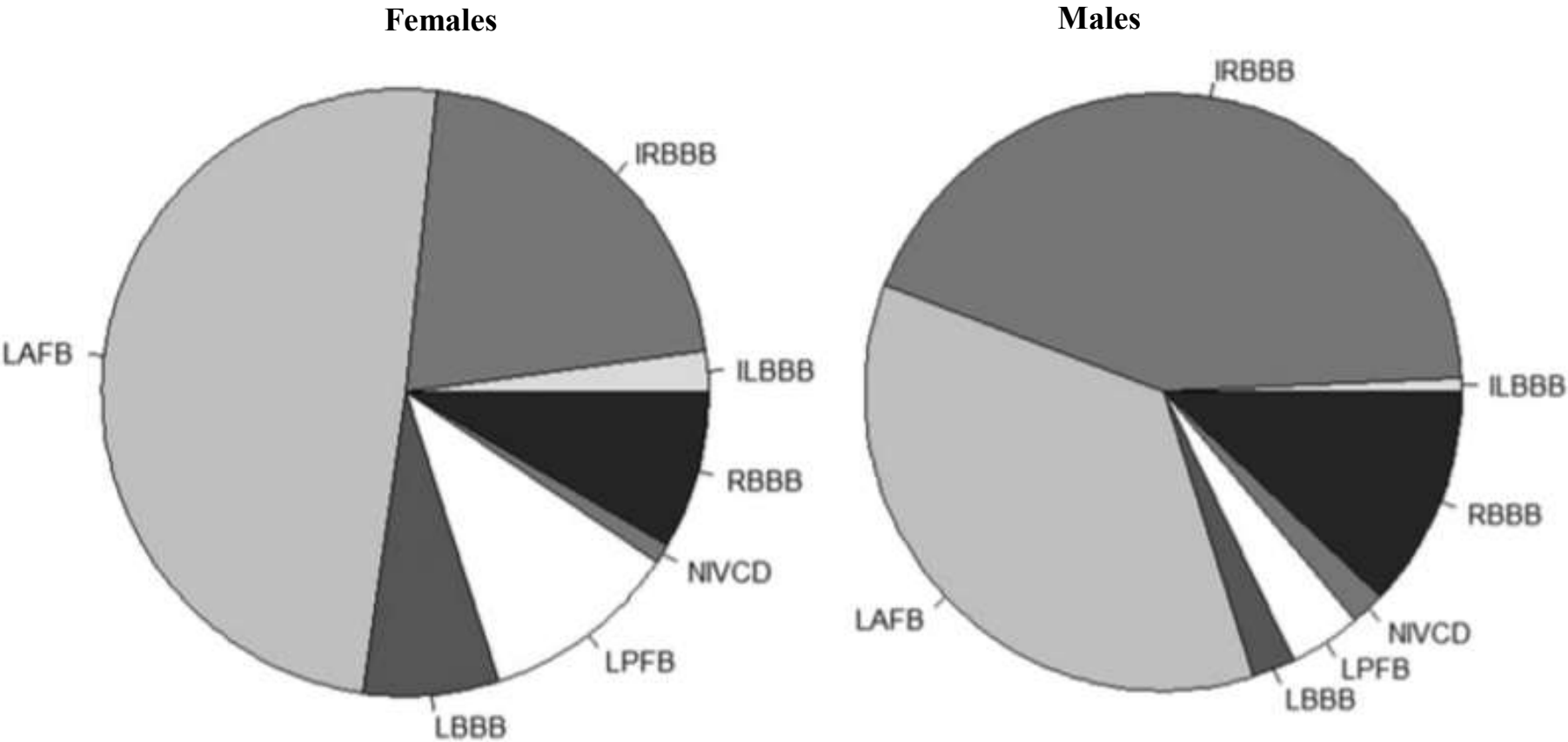
Among patients with QRS duration ≥ 120 ms NICD represent (6.1%–30.3% in dilated cardiomyopathy) is relatively small and less than that with LBBB (25%–36% with LBBB) (Wilensky 1988) Sandhu et al (Sandhu 2004) observed that adverse outcomes in heart failure(HF) occur more frequently with QRS prolongation. The results of this study shows that 25% of community hospital patients with HF of sufficient severity leading to hospitalization have a QRS duration ≥ 120 ms and that this degree of QRS prolongation is associated with substantially more severe left ventricular (LV) systolic dysfunction, LV dilation, and mitral regurgitation. This authors noted that patients with NICD represented 3.8% of the overall HFREF population and 15.3% of HFREF patients with QRS duration ≥ 120 ms (Sandhu 2004). In the Spanish Network for the Study of Heart Failure (REDINSCOR), which included 1762 patients with LVEF $\leq 40\%$, 5.8% patients presented with an NICD pattern (Cinca 2013). Clinical variables and outcomes after a median follow-up of 21 months were analyzed in 1762 patients with chronic HF and LBBB (n = 532), RBBB (n = 134), LAFB (n = 154), and NICDs (n = 942). LBBB was associated with more marked LV dilation, depressed LVEF, and mitral valve regurgitation. Patients with RBBB presented overt signs of congestive HF and depressed RV motion. The LAFB group presented intermediate clinical characteristics, and patients with NICDs were more often women with less enlarged LVs and less depressed LVEF. Death occurred in 332 patients (interannual mortality = 10.8%): cardiovascular in 257, extravascular in 61, and of unknown origin in 14 patients. Cardiac death occurred in 230 (pump failure in 171 and SCD in 59). An adjusted Cox model showed higher risk of cardiac death and HF death in the LBBB and RBBB than in the LAFB and the no NICD groups.

The Brugada electrocardiogram type 1 pattern is characterized by coved- J-point-ST-segment elevation (≥ 2 mm) in the right precordial leads followed by negative T wave. The entity is estimated to be responsible for at least 4% of all sudden cardiac deaths (SCDs) and for at least 20% of SCDs in patients with apparent structurally normal hearts (Antzelevitch 2005). In familial cases, this syndrome transmits by autosomal-dominant mode of inheritance with variable penetrance (Brugada 1992; Abriel 2013). There are 18 genes that, when mutated, can cause the disease, but most of them represent only a minority of BrS cases (Selga 2015). The only gene accounting significant portion of BrS patients is *SCN5A* gene, which encodes the α -subunit of the Nav1.5 cardiac sodium channel. Mutations in this gene can be found approximately in 15% to 30% of BrS cases. Ischemia/infarction of the ventricular septum and/or right ventricle can cause an ECG pattern suggestive of the BrS (Brugada phenocopy) and lead to malignant ventricular arrhythmias (Jastrzebski 2015). This can be confused with STEMI; it mask the findings of an anterior STEMI and led to a delay in primary percutaneous coronary intervention (PCI). The findings of ST segment elevation beyond V3 or in other leads, without 'reciprocal' changes (ST segment depression) should alert one to the diagnosis of an acute coronary syndrome. It is important that a STEMI is recognized promptly and PCI or revascularization achieved as quickly as possible, because this has implications on mortality and cardiac function. Although premature beats originating in areas of ischemia have been shown to be important in initiating ventricular fibrillation (VF), the participation of the ischemic zone in maintenance of VF has not been investigated. Rankovic et al studied 10 normal dogs underwent induction of two separate episodes of VF, before and 10 minutes after left anterior descending coronary artery ligation. Ischemic VF was allowed to occur spontaneously or was by burst pacing after 10 minutes of ischemia. Unipolar epicardial electrograms were recorded using an 8 x 14 plaque electrode array (interelectrode distance 2.5 mm) placed over the anterior wall. Activation during VF was characterized by VF cycle length (CL) and wavefront organization based on linking analysis of epicardial activation directions at adjacent sites. Individual plaque sites were separated into regions based on electrogram morphology during ischemia: R1 = no ischemia; R2 = mild-to-moderate ischemia (minor ST elevation and QRS widening); and R3 = severe ischemia (marked ST elevation and QRS widening). Percent conduction block was calculated based on the percent of cycles during which sites were not activated during VF. There were no significant differences noted in mean CL or mean percent conduction block in the peri-ischemic region R1 compared to the same region under nonischemic (control) conditions. During ischemia, the mean CL was noted to increase in R2 from 111 \pm 14 ms (control) to 128 \pm 29 ms (ischemia) and in R3 from 113 \pm 14 ms (control) to 150 \pm 42 ms (ischemia) ($P < 0.05$). The percentage conduction block in R2 increased from 6 \pm 11% (control) to 14 \pm 16% (ischemia) and in R3 from 4 \pm 6% (control) to 44 \pm 21% (ischemia) ($P < 0.05$). Linking analysis revealed no significant changes in VF organization at distances of 2.5 mm in regions R1 and R2 under both control and ischemic conditions. Premature beats initiating VF originated at the border between the normal and mildly ischemic zones. (1) Some VF characteristics are altered in ischemic regions including a longer VFCL and greater percentage of

functional block. (2) VF characteristics are unchanged in immediately adjacent nonischemic myocardium. (3) Although the ischemic zone may be involved in the initiation of VF and has unique activation characteristics during VF, it does not affect VF characteristics in the adjacent nonischemic zone, suggesting that it may not play a major role in VF maintenance.

The QRS duration ECG performed after cardioversion has extreme prolongation (330 ms!!!!) without criteria of complete right or left bundle branch block, or ventricular pre-excitation pattern. (Surawicz 2009; Bonner 1978; Robles de Medina 1978) Consequently, this pattern is a **transient ischemic NICD**: QRS duration greater than 110 ms in adults, greater than 90 ms in children 8 to 16 years of age, and greater than 80 ms in children less than 8 years of age without criteria for RBBB or LBBB. The definition may also be applied to a pattern with RBBB criteria in the precordial leads and LBBB criteria in the limb leads, and vice versa (Masquerading bundle branch block). Masquerading bundle branch block is a rare but important finding on the ECG. It is usually an indication of severe and diffuse conduction system disease and usually indicates poor prognosis. The precordial leads show a Right Bundle Branch Block (RBBB) pattern while the limb leads resemble a Left Bundle Branch Block (LBBB) or vice versa. This finding on an ECG is almost invariably associated with severe underlying heart disease. From 01/31/1996 to 09/22/2010, an ECG was performed at each visit for all aircrew members examined for fitness assessment in an aeromedical center. The prevalence of left bundle branch block (LBBB), right bundle branch block (RBBB), incomplete LBBB, incomplete RBBB, NIVCD, left anterior fascicular block (LAFB), and left posterior fascicular block (LPFB) was measured and compared by age and gender. The global prevalence of intraventricular conduction disturbance in a Large French Population of 69,186 patients studied by Monin et al (Monin 2016) was 3.09%. The most frequent types of ventricular blocks were IRBBB (1.25%) and LAFB (1.10%), whereas CRBBB (0.46%), LBBB (0.08%), ILBBB (0.03%), NICD (0.05%), and LPFB (0.13%) were rare findings. intraventricular conduction disturbance are more frequent for males and older age groups. The authors did not mention or did not take into account the left septal fascicular block (LSFB). Data, including 12-lead ECGs, were collected by Haataja et al (Haataja 2013) from 6315 subjects. The prevalence of LBBB, RBBB, NICD, ILBBB, IRBBB, R-R'-pattern, LAFB, and LPFB was calculated for both genders in three age groups. Their association with risk factors and cardiovascular diseases was studied. R-R'-pattern was the most common ventricular conduction block in all age groups (3.9%, $p < 0.001$ for comparison between groups), but it showed no association with cardiovascular diseases. Males had more RBBB (1.5% vs. 0.7%, $p < 0.001$), incomplete LBBB (1.8 vs. 0.4, $p < 0.001$) and NICD (1.1% vs. 0.1%, $p < 0.001$). With increasing age (<45 years vs. >55 years) LBBB, RBBB and NLAFFB (0 vs. 2.2%, 0.3 vs. 2.2%, 0.2 vs. 1.9% respectively, p -values < 0.001) became more prevalent. LBBB, RBBB and NICD were associated with coronary heart disease such as the present case (angina pectoris in 28.3, 20.3 and 22.9%, respectively) and HF (25.0, 10.1 and 11.4%, respectively). LBBB and RBBB were also associated with peripheral vascular disease (8.8%). The authors concluded that NICD differ in prevalence between sexes and age groups

They also show disparate association with cardiovascular diseases. These differences need to be taken into consideration in everyday clinical practice. This study has a few limitations. First, the study population was young and healthy, examined for a fitness assessment in an aeromedical expertise center, and it cannot strictly be representative of the general population. In addition, males were more represented than females (Male/female ratio 2.5). Finally, they did not study the association between intraventricular conduction defects and cardiovascular diseases.

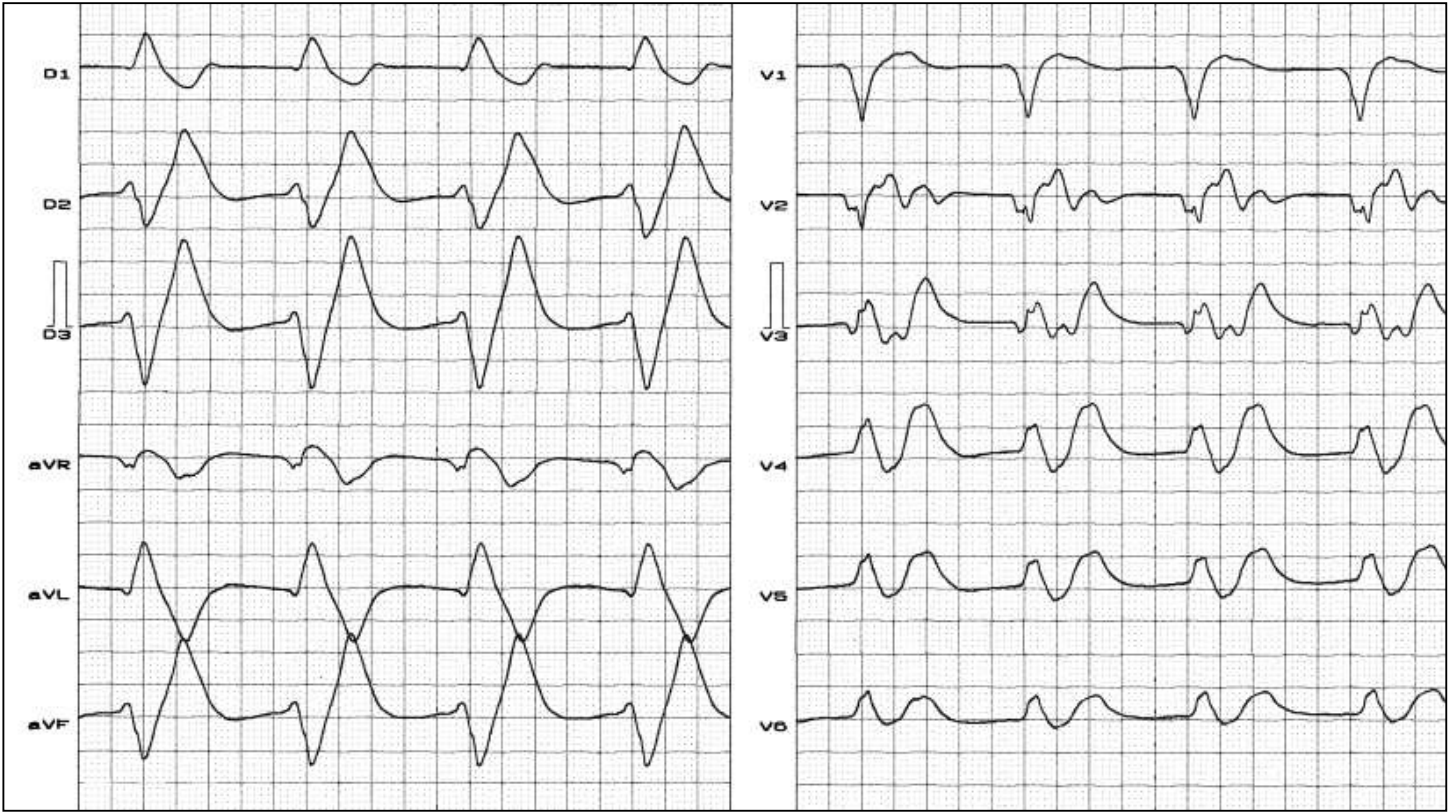


Distribution of intraventricular conduction disturbance (ICoD) depending on sex. ILBBB = incomplete left bundle branch block; IRBBB = incomplete right bundle branch block; LAFB = left anterior fascicular block; LBBB = complete left bundle branch block; LPFB = left posterior fascicular block; NIVCD = nonspecific intraventricular conduction disturbance; RBBB = complete right bundle branch block

Possible etiologies of Nonspecific intraventricular conduction disturbance

1) Severe hyperkalemia

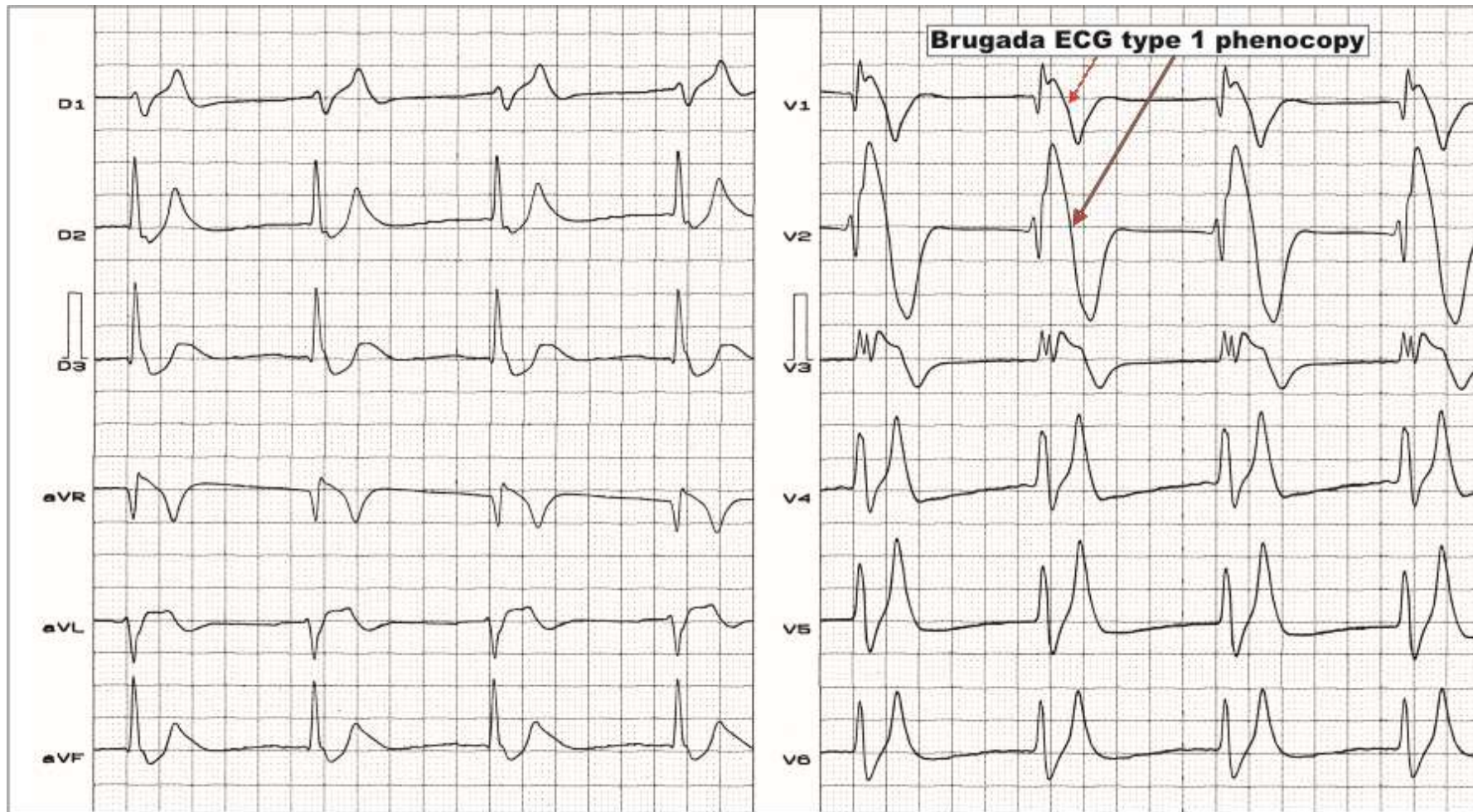
Typical ECG example of patient with extremely high level of serum potassium



Clinical diagnosis: chronic renal insufficiency and in dialysis. The patient delayed 72 hours the dialysis session. Severe hyperpotassemia of 9 mEq/L.

ECG diagnosis: absence of P wave, sinoventricular rhythm, 57 bpm, morphology of bizarre intraventricular severe disorder (QRSd: 240 ms) that is similar to complete LBBB. T waves with polarity matching with QRS from V3 to V6. Convergence of QRS with T wave that outlines smooth diphasic wave or sine curve.

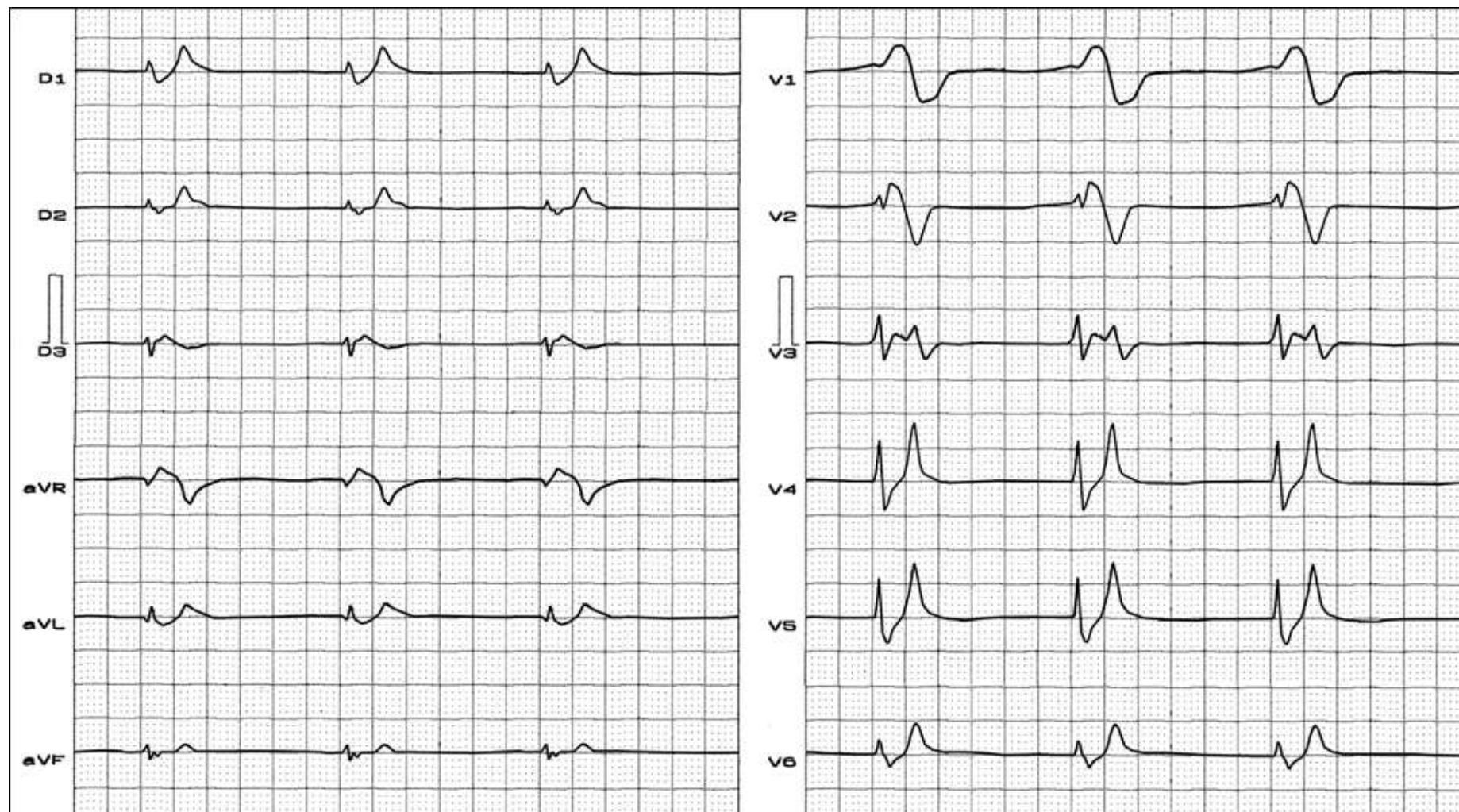
Severe hyperkalemia



Clinical diagnosis: terminal renal insufficiency. Severe hyperkalemia: K^+ 8.7 mEq/L. This sign is known as “dialyzable injury current”. ECG diagnosis: very likely, junctional with P waves near the J point, HR: 54 bpm, QRSd: 160 ms, ST segment elevation from V1 to V3 and I, aVL and aVR. V1 to V3 displays ST segment with upwardly convex pattern, similar to Brugada syndrome or Brugada phenocopy”, typical T waves in “tent”, pointed, and with a narrow base. Numerous conditions which resemble the type-1 BrS pattern should be ruled out. These are called “acquired forms of BrS”, “Brugada-like ECG pattern” or Brugada phenocopies (Nguyen 2011; Riera 2010) (an environmental condition that imitates or mimics one produced by a gene).

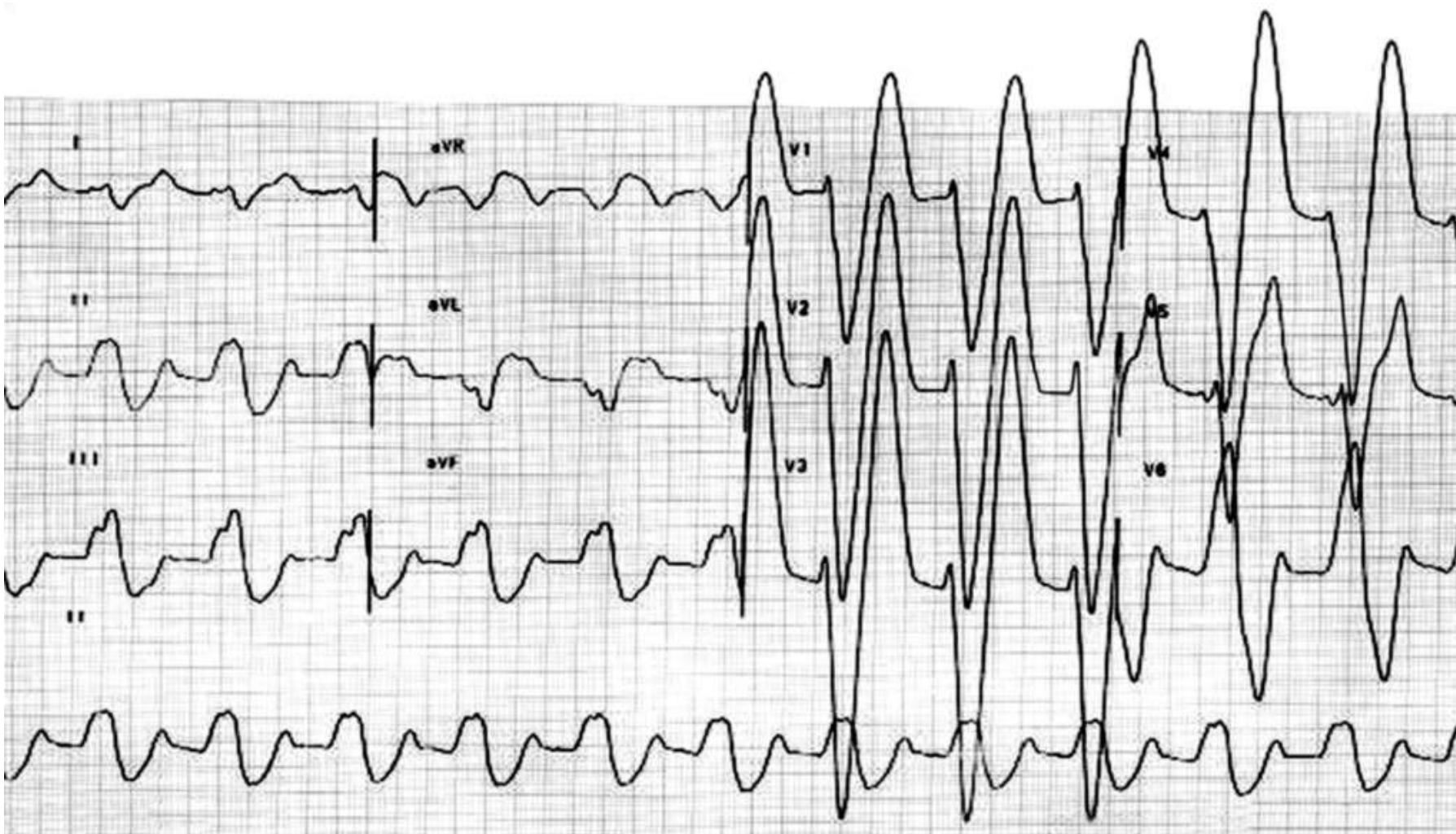
Typical ECG of hyperpotassemia associated to Brugada-like pattern

Name: FHM; **Sex:** M; **Age:** 56 y/o; **Ethnic group:** Mulatto; **Weight:** 65 Kg; **Height:** 1.62 m; **Date:** 05/11/2003



P wave is not identified; sinoventricular rhythm. Severe hypercalcemia with electrocardiographic Brugada-like pattern. Chronic renal insufficiency with hypercalcemia has been described transitorily, and reversed with dialysis. Apiculate T waves in "tent" from V4 through V6.

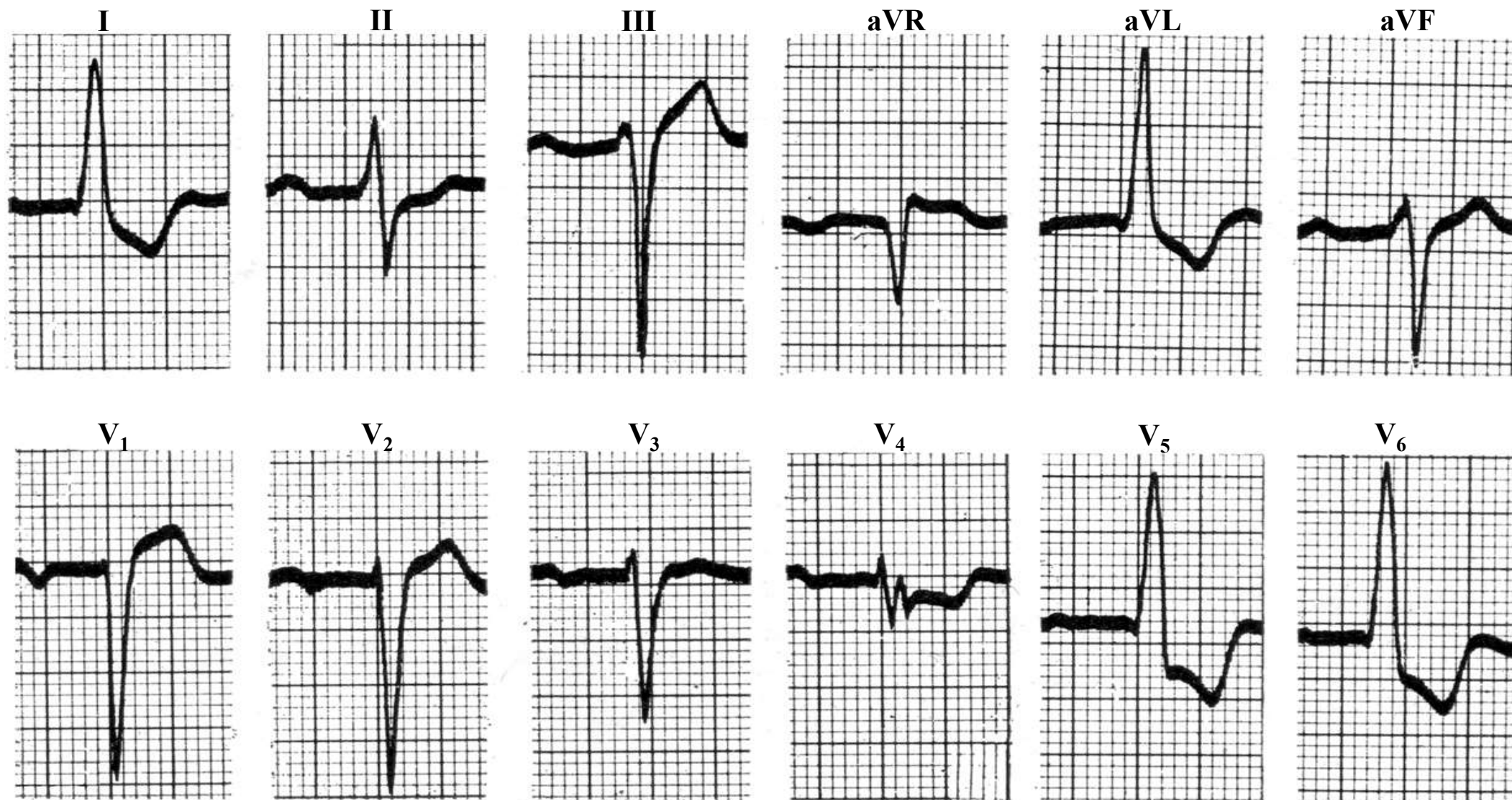
Severe hyperkalemia associated to NSIVCD



Nonspecific or unspecified intraventricular conduction defect/disturbance or nonspecific intraventricular conduction delay (NSIVCD). Very prolonged QRS duration without a specific bundle branch block pattern can also occur due to intramyocardial conduction slowing by severe hyperkalemia. Lead I suggests RBBB (rS pattern) and precordial leads LBBB. A “sine QRS wave” appearance is observed in II.

2) Some types of left ventricular enlargement/hypertrophy

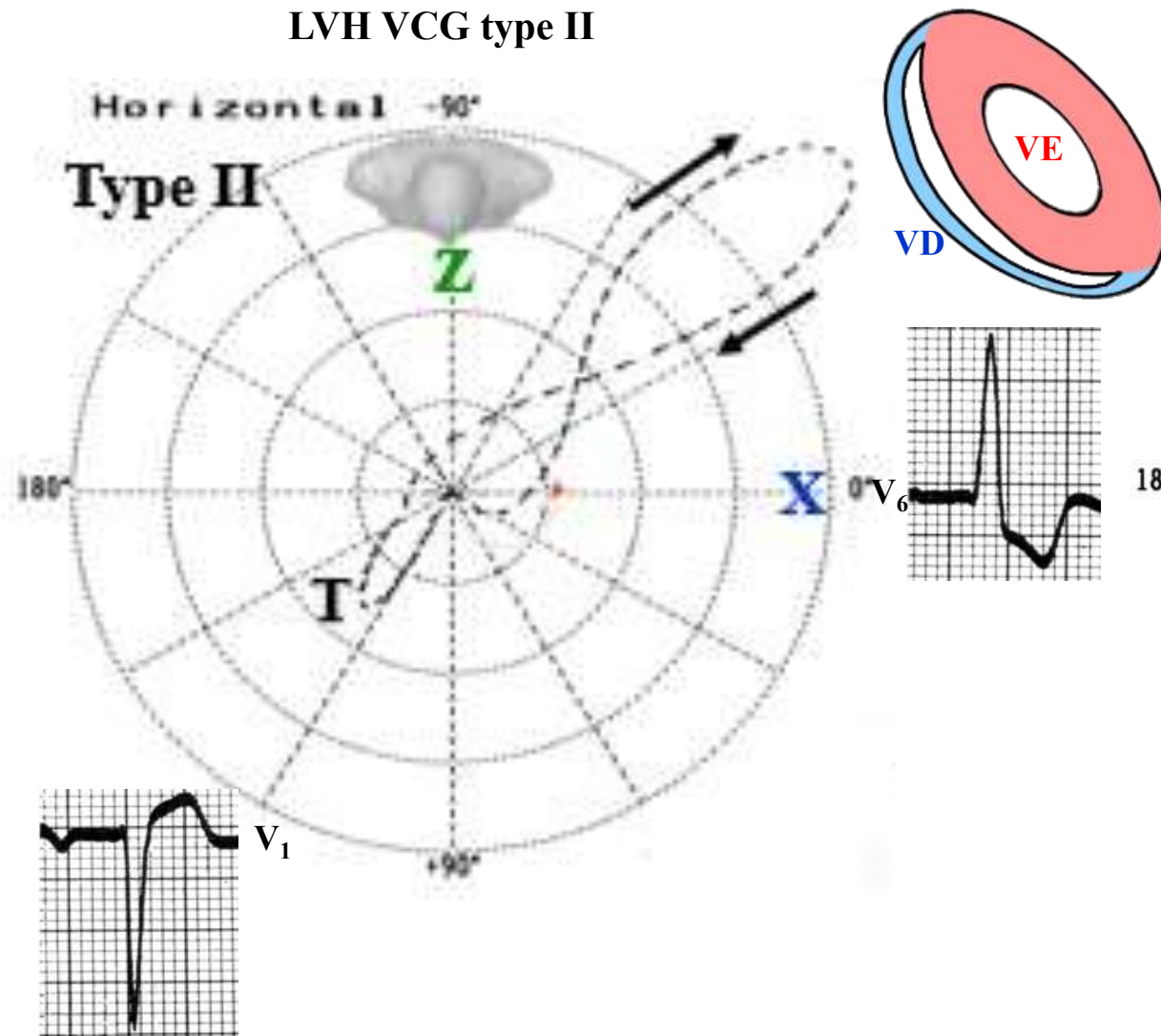
	LVH	STSEMI
Evolutionary changes	Absent (static or constant)	Evolving ischemic event
ST-segment changes	<p>Appropriate discordance: The ST segment is below baseline when the QRS complex is positively deflected (1), whereas the ST segment is above baseline when the QRS complex is negatively deflected</p> <p>Strain pattern: downsloping ST segment ending followed by terminally negative, and asymmetric T wave.</p>	Convex upward. The magnitude of ST-segment deviation in STSEMI is high,
Amplitude R waves	High-amplitude R waves occur in the lateral precordial leads. A downsloping ST segment ending	Absence or diminution R waves



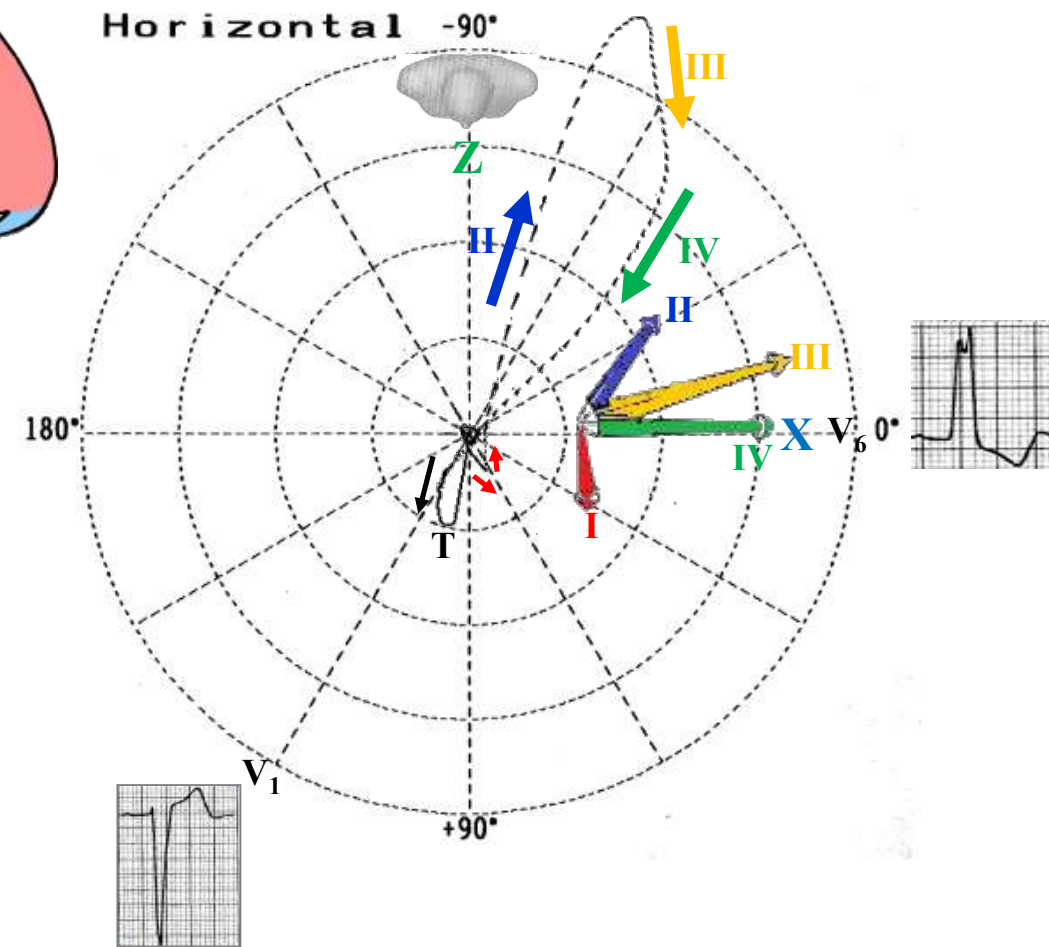
LAE (Morris criteria) + 1st degree AVB; PR= 24° ms; SÂQRS – 30° , QRS duration: 120 ms, LVH systolic pattern: SÂT + 120° in the FP and to the front and the right in the HP. ILBBB? Initial embryonic q wave in left leads I, aVL, V5-V6. Pseudo LBBB

VCG differential diagnosis between LVH type II from genuine CLBBB

LVH VCG type II



Genuine CLBBB



Absence of middle final conduction delay of QRS loop (dashes closer to one another).

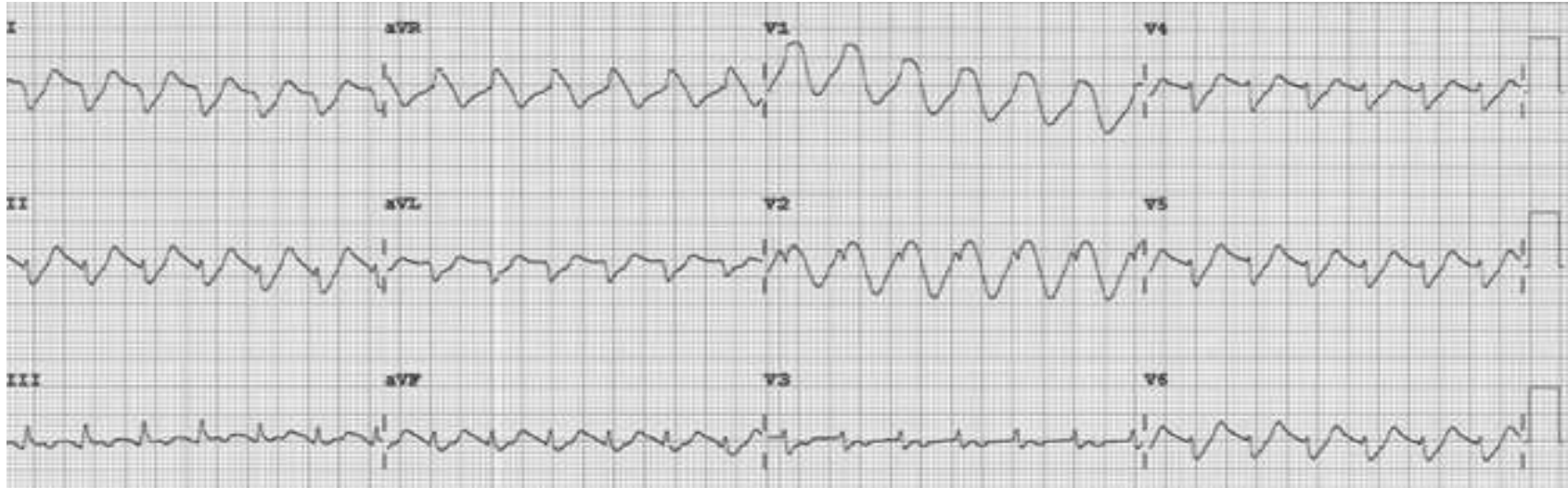
Characteristic middle final conduction delay of QRS loop (tears closer to one to another) (vector IV).

3a Tricyclic antidepressants (TCAs) overdose(Amitriptyline overdose)

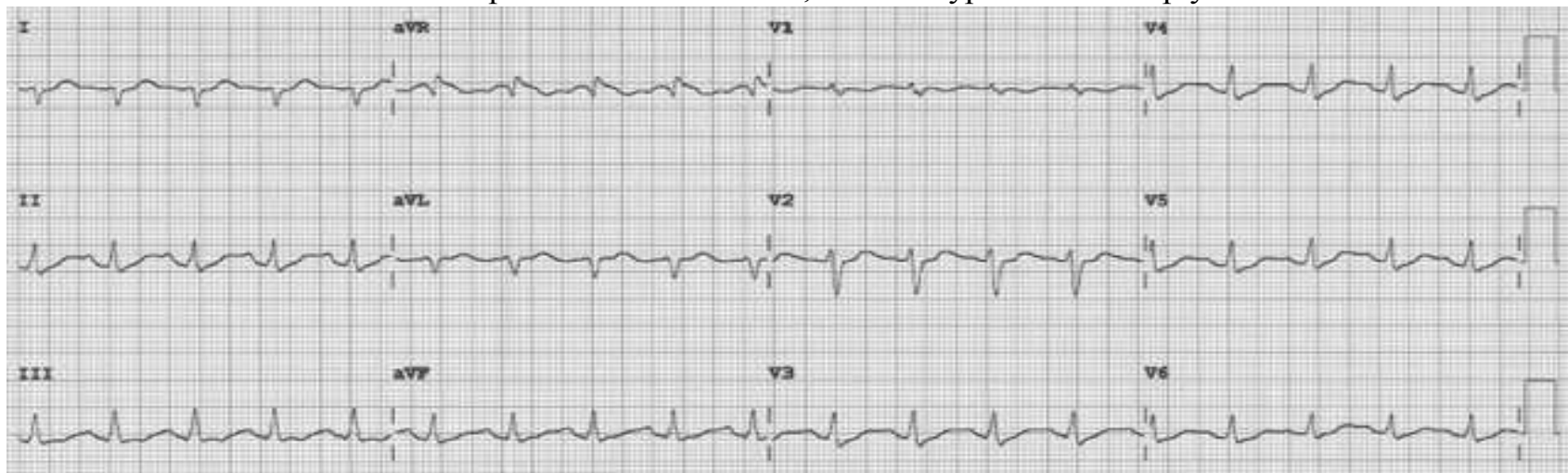
The main TCAs overdose are: amitriptyline, nortriptyline, trimipramine, despiramine, protriptyline, and dothiepin poisoning. These drugs in overdoses cause characteristically on the ECG terminal QRS vector between $+130^{\circ}$ and -270° . TCAs is a group of drugs used for the depression treatment. One of the effects of these drugs is sodium channel blocking ability causing severe arrhythmias such as VT and Torsades de pointes (TdP). Tricyclics have a narrow therapeutic index, *i.e.*, the therapeutic dose is close to the toxic dose. In the medical literature the lowest reported toxic dose is 6.7 mg per kg body weight. Although there are differences in toxicity with the drug class, ingestions of 10 to 20 mg per kilogram of body weight are a risk for moderate to severe poisoning, however, doses ranging from 1.5 to 5 mg/kg may even present a risk. For all TCAs except desipramine, nortriptyline, trimipramine, and protriptyline, this dose is >5 mg/kg. For desipramine it is >2.5 mg/kg; for nortriptyline it is >2.5 mg/kg; for trimipramine it is >2.5 mg/kg; and for protriptyline it is >1 mg/kg.

Case report

A 49-year-old woman with a history of depression, bipolar disorder, and chronic back pain was brought to the emergency department unresponsive after having taken an unknown quantity of amitriptyline tablets. On arrival, she was comatose, with a score of 3 (the lowest possible score) on the 15-point Glasgow Coma Scale. Her blood pressure was 65/22 mmHg, heart rate 121 beats per minute, respiratory rate 14 per minute, and oxygen saturation 88% on room air. The rest of the initial physical examination was normal. She was immediately intubated, put on mechanical ventilation, and given an infusion of a 1-L bolus of normal saline and 50 mmol (1 mmol/kg) of sodium bicarbonate. Norepinephrine infusion was started. Gastric lavage was not done. Results of initial laboratory testing showed a serum potassium of 2.9 mmol/L (reference range 3.5–5.0) and a serum magnesium of 1.6 mmol/L (1.7–2.6), which were corrected with infusion of 60 mmol of potassium chloride and 2 g of magnesium sulfate. The serum amitriptyline measurement was ordered at the time of her presentation to the emergency department. She remained hypotensive, with regular wide-complex tachycardia on the ECG. She was given an additional 1-L bolus of normal saline and 100 mmol (2 mmol/kg) of sodium bicarbonate, and within 1 minute the wide-complex tachycardia resolved to narrow-complex sinus tachycardia. At this point, an infusion of 150 mmol/L of sodium bicarbonate in dextrose 5% in water was started, with serial ECGs to monitor the QRS duration and serial arterial blood gas monitoring to maintain the pH between 7.45 and 7.55. Arterial blood gas analysis showed; pH 7.15 (normal range 7.35–7.45); PaCO₂ 66 mm Hg (34–46); PaO₂ 229 mm Hg (85–95); Bicarbonate 22 mmol/L.



The ECG shows regular wide-complex tachycardia with a ventricular rate of 157 bpm, a QRS duration of 198 ms, a corrected QT interval of 505 ms, and a QRS axis of $+179^\circ$. Note the negative QRS complexes in leads I and aVL and the final R wave amplitude >3 mm in aVR, features typical of amitriptyline overdose.



The ECG performed few minutes after infusion of 100 mmol of sodium bicarbonate. Sinus tachycardia (HR = 113 bpm), QRSd of 116 ms, QTc of 478 ms, and QRS axis of $+112^\circ$. The R wave in lead aVR < 3 mm.

She was then transferred to the intensive care unit (ICU), where she remained for 2 weeks. While in the ICU, she had a single recurrence of wide-complex tachycardia that resolved immediately with an infusion of 100 mmol of sodium bicarbonate. A urine toxicology screen was negative, and the serum amitriptyline measurement, returned from the laboratory 48 hours after her initial presentation, was 594 ng/mL (reference range 100–250 ng/mL). She was eventually weaned off the norepinephrine infusion after 20 hours, the sodium bicarbonate infusion was discontinued after 4 days, and she was taken off mechanical ventilation after 10 days. Also during her ICU stay, she had seizures on day 3 and developed aspiration pneumonia.

From the ICU, she was transferred to a regular floor, where she stayed for another week and then was transferred to a rehabilitation center. This patient was known to have clinical depression and to have attempted suicide once before. She had recently been under additional psychosocial stresses, which likely prompted this second attempt. She reportedly had no neurologic or cardiovascular sequelae after her discharge from the hospital.

Comments: Amitriptyline causes a relatively high number of fatal overdoses, at 34 per 1 million prescriptions (Henry 1995). Death is usually from hypotension and VT caused by blockage of cardiac fast sodium channels leading to disturbances of cardiac conduction such as wide-complex tachycardia. Other manifestations of amitriptyline overdose include seizures, sedation, and anticholinergic toxicity from variable blockade of gamma-aminobutyric acid receptors, histamine 1 receptors, and alpha receptors (Shannon 1988). Of the various changes on ECG described with amitriptyline overdose, sinus tachycardia is the most common. A QRS duration greater than 100 ms, right to extreme-right axis deviation with negative QRS complexes in leads I and aVL, and an R-wave amplitude greater than 3 mm in lead aVR are indications for sodium bicarbonate infusion, especially in hemodynamically unstable patients (Liebelt 1995). Sodium bicarbonate increases the serum concentration of sodium and thereby overcomes the sodium channel blockade. It also alkalinizes the serum, favoring an electrically neutral form of amitriptyline that binds less to receptors and binds more to alpha-1-acid glycoprotein, decreasing the fraction of free drug available for toxicity (Sayniuk 1984). Patients with amitriptyline overdose, wide-complex VT and hypotension refractory to sodium bicarbonate infusion can be treated with lidocaine, magnesium sulfate, direct-current cardioversion, and lipid resuscitation (Kiberd 2012; Harvey 2012). Treatment with class IA, IC, and III antiarrhythmics is contraindicated, as they block sodium channels and thus can worsen conduction disturbances.

3c. Class Ia antiarrhythmic drugs intoxication (Vaughan-Williams classification): Quinidine

Mechanisms of action of quinidine. Pharmacokinetics

Antiarrhythmic agent of group 1A – Alkaloid of cinchona, d-isomer of quinine, both extracted from the tree of cinchona. Chemically, the drug is made up by two rings: quinoline and quinuclidine, joined by an alcoholic ligation.

- I. The main mechanism of action is moderate block of inflow of Na^+ in rapid cells (prototype of membrane depressor drug or local anesthetic effect), a fact that decreases AP amplitude (amplitude of phase 0), dv/dt (rate of AP ascension or velocity of ascension of phase 0) and conduction velocity. This union is greater in the activate state. The effect is greater in the presence of acidosis and ischemia.
- II. It blocks the multiple K^+ outflow currents in phases 1 and 3, so that AP duration is increased, and consequently, the effective refractory period: JT and QTc interval increase, it favors the appearance of early post-potentials, and these in turn, triggered activity that would lead to a greater tendency to appearance of “Torsade de Pointes”.
- III. The channels affected by quinidine action are: 1) **I_{to}** : quinidine acts in phase 1, allowing the slow outflow of K^+ “in crescendo”. In normal conditions, this channel is found in a high concentration only in the epicardium and in M cells of the midmyocardium, but not in the endocardium. The characteristics of the I_{to} channel are considered significant in the genesis of PVT in BrS. Quinidine causes homogenization of ventricular repolarization, decreasing ST segment elevation in right precordial leads, thus preventing the electrophysiological substrate of reentry in phase 2. Other class I drugs present the opposite effect in BrS, increasing J point and ST-SE due to their capacity to block the Ito channel leading to a greater tendency to arrhythmic events. 2) **Delayed rectifier outward K^+ channels**: these channels enable outflow of K^+ in phases 3 and 4 of the SA node. They are channels considered as essential in normal automatism. They have there subtypes: 1) of slow kinetics (I_{ks}); 2) rapid (I_{kr}); and 3) ultrarapid (I_{kur}), i.e. with activation and inactivation in variable velocities. 3) **IK1 or “Inward rectifier”**: this channel enables outflow of K^+ in phase 3. This is a K^+ channel responsible for the state of balance of diastolic transmembrane potential. 4) **ICa^{+2}L type “long-lasting”**: this channel acts in phase 0 of slow cells of SA-N and AV-N and in phase 2 or “plateau” of rapid fibers. In phase 3, inactivation of this channel occurs. 5) **IK_{ATP}** : this channel activates when intracellular concentration of ATP decreases. It enables the outflow of K^+ in phase 3. It inactivates when cellular ATP concentration increases. Pathologically, it activates in case of ischemia. 6) **IK_{ACh}** : this channel enables outflow of K^+ in phase 3 in the atria, causing shortening of refractory period. This K^+ channel of is activated by the muscarinic receptor M^2 , being significant in SA and AV nodes, and the atria. In the two former, it may produce hyperpolarization, and in the atria it shortens the refractory period. 7) **IK_{ACh}** – It seems to be the same as the adenosine receptor or $\text{IK}(\text{Ado})$.

Other electrophysiological actions of quinidine

1. It decreases ascension velocity in phase 4: negative dromotropism;
2. Vagolytic effect by block of muscarinic receptor M_2 : sinus tachycardia;
3. Anti α adrenergic action: by block of α_1 and α_2 receptors: bradycardia;
4. It increases excitability and ventricular fibrillation threshold.
5. It may originate or exacerbate early post-potentials¹.
6. It may suppress delayed post-depolarizations, while it may increase them too.

Effects of quinidine on functional properties of cardiac cells: automatism, dromotropism, inotropism, and excitability

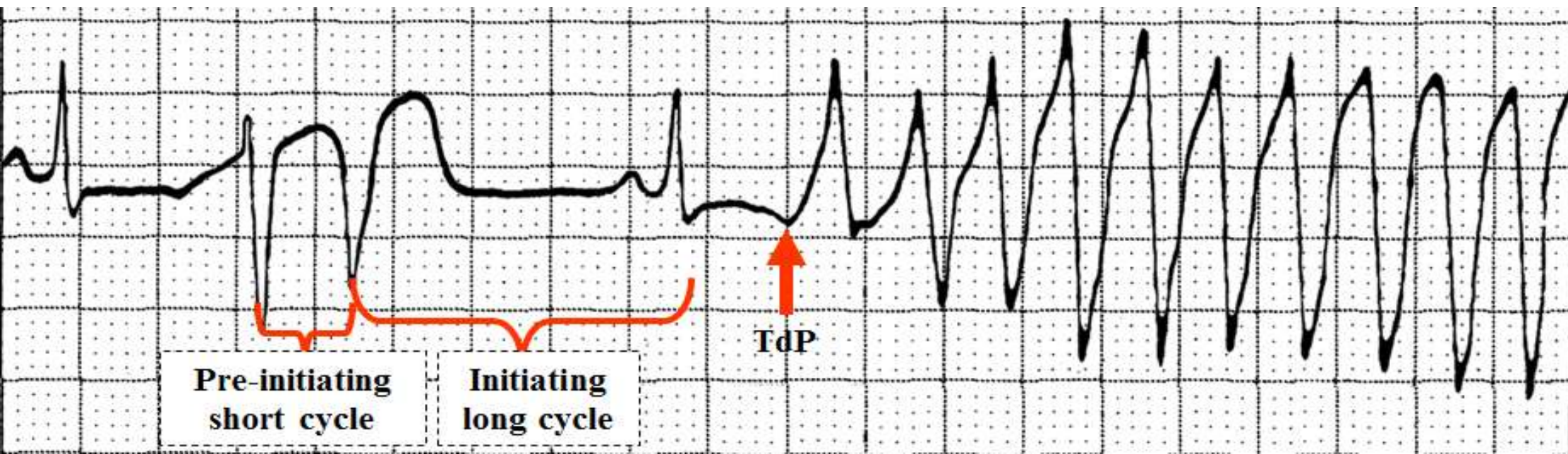
1. **Automatism, rhythmicity or diastolic depolarization: NEGATIVE** by decreasing the degree of slant of the ascension ramp in phase 4, the threshold potential is shifted to more positive levels, and increases AP duration.
2. **Dromotropism (conduction velocity): NEGATIVE** by decrease of amplitude in phase 0 of AP and V_{max} . By blocking rapid Na^+ channels, it decreases the amplitude of action potential of the rapid fiber, V_{max} and ascension velocity in phase 0 of atrial, ventricular and His-Purkinje system myocardial cells (rapid fibers depending on Na^+).
3. **Inotropism (contractility): MILDLY NEGATIVE** by discrete negative effect on contractility, leading to increase in LVEDP, and possible exacerbation of CHF; however, most times, the effect is offset by vasodilating action¹. This double negative inotropic effect and peripheral vasodilator, is due to α adrenergic block.
4. **Batmotropism (excitability):** it increases refractoriness in atrial and ventricular and His-Purkinje contractile muscle, by prolonging action potential by block of K^+ channels in phase 3, virtually not altering the “plateau” in phase 2. Excitability and ventricular fibrillation threshold increases.
5. Class Ia antiarrhythmic drugs are sodium channel blockers with intermediate association/dissociation, prolongation of AP duration and effect. These drugs are known as fast-channel blockers-affect QRS complex (quinidina, procainamide, and dysopiramide). If the conduction delay is uniform the QRS/T angle remain normal. If a drug like quinidine is being taken and can be related temporally to the NSIVCD then increasing dosage is not indicated, and in specific case of this drug, a QRS complex prolongation for values >140 ms or $>35\%$ of the baseline tracing, constitutes absolute indication of interruption of the drug. (Heissenbittel 1970).

Electrocardiographic modifications with Quinidine

Heart rate: SA-N: Direct effect – it mildly depresses automaticity (bradycardia). **Indirect effect** - vagolytic M_2 and block of α_1 and α_2 receptors of the drug increase HR. For this reason, SA node automaticity is considered not to be affected in therapeutic doses. In toxic doses, it may cause both bradycardia and sinus tachycardia or sinus arrest. **AV node:** It shortens junctional conduction time (A-H interval) and effective refractory period of AV node (PRE-AV), by anticholinergic indirect effect (vagolytic) and by the direct effect, it increases these periods. Predominance of the first effect is observed when used in therapeutic doses and with medium plasmatic levels of 4.6 mg/L. (Josephson 1974). In toxic doses (levels >10 mg/L), it may cause AV block. In patients carriers of 2:1 flutter by anticholinergic effect, it may transform it into 1:1 with the subsequent hemodynamic worsening by increase of ventricular rate. It prolongs effective refractory periods of atria, AV-N, His-Purkinje system (it prolongs HV); 1 and of the ventricles at ventricular level, as well as accessory bundles. It may cause block in the His-Purkinje system¹. It prolongs HV interval. It increases refractory periods throughout the heart: atria, AV node, His-Purkinje system, ventricular contractile myocardium and accessory bundles. **QRS complex duration:** in therapeutic doses, it causes discrete prolongation in QRS complex duration (10-20%). The QRS complex prolongation may be diffuse or only in the final part. QRS complex prolongation in values ≥ 140 ms or >35% of the baseline tracing, constitutes absolute indication of interruption of the drug. The increase in QRS complex duration is directly related to the plasmatic concentration of the drug. On the contrary, QTc interval prolongation is not related with such concentration. **T wave modifications:** as a consequence of the effect on rectifier delayed outward potassium channels in phase 3 of action potential: it increases duration and affects T wave polarity of ECG - **In leads where the T wave has positive polarity:** it initially decreases voltage and finally causes notches or discrete inversion. **In leads where T wave has negative polarity:** T waves decrease their depth. In general, the T vector has an orientation opposite to the final vector of the QRS complex. **On the JT interval:** this interval is the distance existing between the J point and the onset of T wave. Quinidine causes prolongation in a degree somewhat greater than the QRS complex. **On the QTc interval:** it causes prolongation. If the QTc interval reaches 440 ms and the QT interval 600 ms, the drug caused acquired LQTS. QT interval prolongation is mainly due to the block of different delayed outward K^+ rectifier channels in phase 3. When the QTc interval is significantly prolonged, there is a greater possibility for EAD to appear, capable of causing triggered activity, and in turn, polymorphic VT of the “Torsades de pointes” type, which may degenerate into VF and quinidine syncope.

QTc interval prolongation: This severe form of VT appears almost always after a pause, and it is known as “pause-dependent” VT, to distinguish it from adrenergic-dependent torsades.

QT interval syndrome may be the consequence of intoxication with other antiarrhythmic agents of the IA group, sotalol, or the calcium antagonist bepridil, neuroleptic agents of the phenothiazine type, tricyclic and tetracyclic antidepressants, cisapride, hypokalemia, hypomagnesemia, intoxication by organophosphate insecticides, mitral valve prolapse, intracranial hemorrhage, subarachnoid hemorrhage, carotid dissection over the course of endarterectomy, nutritional state alterations (parenteral liquid-protein diets), severe bradyarrhythmias, SA node disease, total AV block, and two congenital syndromes: Jervell-Lange-Nielsen with deafness (autosomal recessive) and Romano-Ward (dominant autosomal). “long-short” sequence or in bradyarrhythmias, complete AV block and sudden PR interval prolongation. TdP that started by intoxication with quinidine. The cycle interrupted by TdP is longer than the prior cycle.



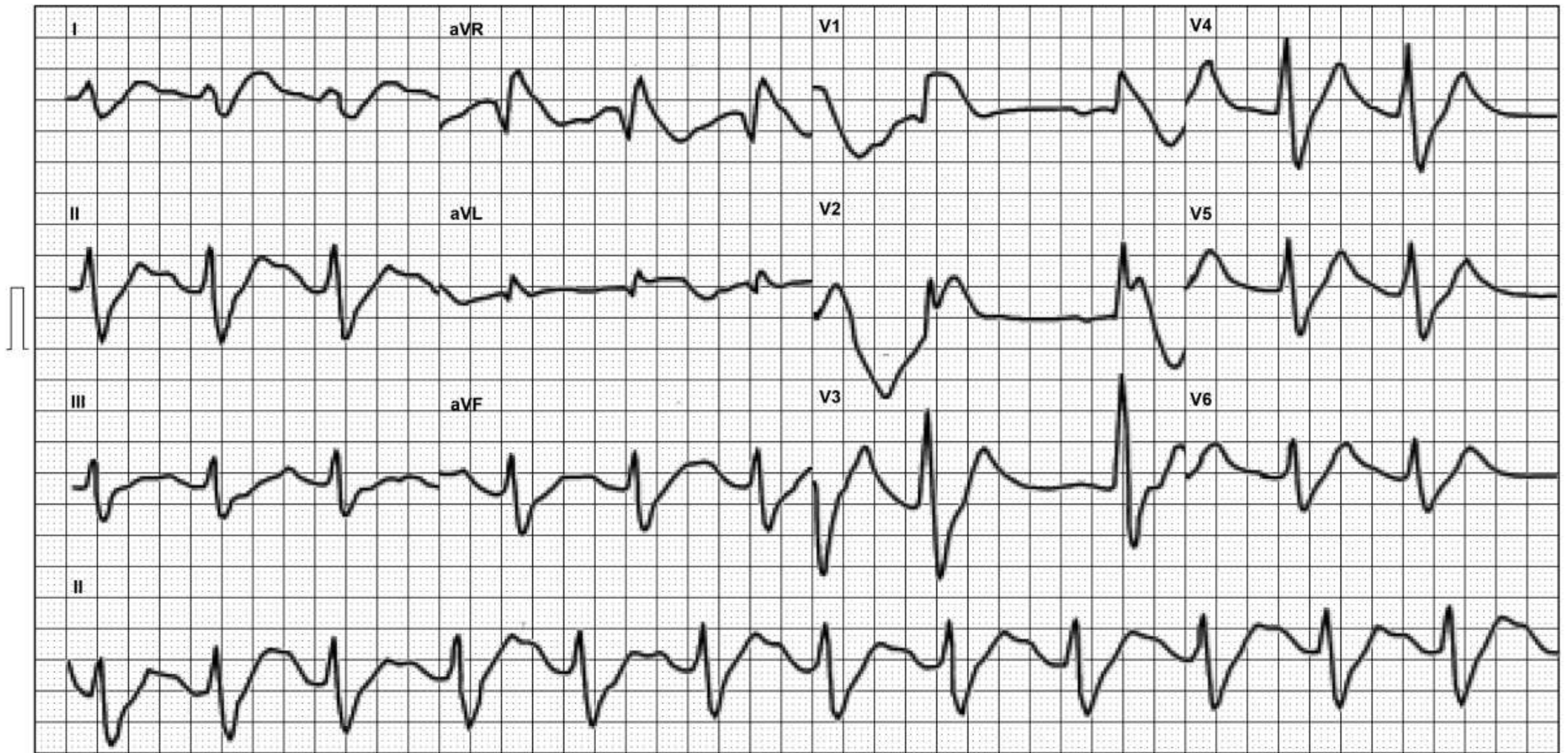
Electrocardiographic modifications of quinidine were grouped by Chou into therapeutic and toxic effects¹.

THERAPEUTIC EFFECTS OF QUINIDINE	TOXIC EFFECTS OF QUINIDINE
Decrease of T wave voltage	Broader QRS: if it reaches 140 ms or with 25% increase in initial duration, the drug must be suspended.
T wave polarity inversion	A-V block in different degrees and with origin in the His-Purkinje system.
Prominent U wave: > 1.5 mm	Important sinus bradycardia, sinus arrest, or sinoatrial block.
P wave notches or modifications	PR interval prolongation: it constitutes a late sign and it occurs with levels above 10 mg/L.
In 2 to 8% of the cases, polymorphic VT, even in therapeutic or subtherapeutic doses.	

3c Class Ic antiarrhythmic drugs -sodium channel blockers intoxications flecainide acetate intoxication: ECG main features

Flecainide is a Vaughn-Williams class IC antiarrhythmic and a sodium channel blocking agent used mainly for the treatment of supraventricular dysrhythmias. Adverse cardiac effects include moderate negative inotropic action and depression of all major conduction pathways.² With increasing concentration, flecainide's action on conduction pathways is manifested on electrocardiogram as an increased PR interval and QRS duration. Toxicity is suggested when a 50% increase in QRS duration (0.18 sec) or 30% prolongation in PR interval (0.26 sec) occurs. The QTc interval can also be prolonged in cases of flecainide overdose. Treatment of acute flecainide overdose includes administration of activated charcoal (for patient presenting early in course of ingestion), administration of sodium bicarbonate (reverses action of sodium channel blockade), pressors (eg, dobutamine) for profound hypotension, and transthoracic or transvenous pacing. Although less than 1% of drug overdoses are fatal, the average mortality of 22.5% and the rate of mortality after flecainide overdose is approximately 10%. Severe flecainide overdose is frequently fatal because of the rapid onset of hypotension and ventricular arrhythmias. Its cardiotoxicity is mainly due to its sodium and potassium channels blocking effects. Commonly recommended therapies like haemolysis or haemoperfusion is not helpful because of its large volume of distribution. As a result, the treatment goals are to decrease the amount of blockade; correct aggravating conditions for arrhythmias, such as electrolytes disturbances or hypoxia; avoid drugs with sodium channels blocking effects. Recently, there are some successful data on using peripheral cardiopulmonary bypass technique in the treatment of severe flecainide intoxication. This may be a promising treatment option in this type of drug overdose. Daily therapeutic dose of flecainide is 200-300 mg. Doses in excess of 400 mg per day are associated with a high incidence of adverse effects and are usually not required for the control of arrhythmias. In the first 30 minutes after overdose, nausea and vomiting are common early symptoms. After 30 minutes to 2 hours of ingestion, cardiotoxicity will appear and bradyarrhythmias are more common than tachyarrhythmias. Other cardiac arrhythmias include various heart block, Torsade de pointes, other ventricular arrhythmias, VF and asystole. Cardiac arrest has been reported in 1/4 of all patients with flecainide overdose. Serious ventricular tachyarrhythmias may be provoked in 5-25% of patients, who had depressed LV function, sustained VT or taking a daily dose of more than 400 mg. Other clinical features like dizziness, headache, blurred vision, seizure and hypotension had been reported. Flecainide may elevate pacing or defibrillation thresholds, therefore, higher energy level will be required during resuscitation. Flecainide has a large volume of distribution and negative inotropic effect. In cases of overdose, PR and QRS intervals correlate well with drug level. Prolongation of PR or QRS intervals of more 50% of normal indicate toxicity.³ Cardiac complications can occur as early as 30 minutes and bradyarrhythmias are more common. In flecainide overdose, the threshold for pacing and defibrillation will be increased and class 1 antiarrhythmics and magnesium should be avoided. Aggressive use of NaHCO₃ should be considered early, and atropine and pacing should be given before gastric lavage. Recent reports indicate the potential usefulness of CBS/ECMO in the treatment of flecainide overdose.

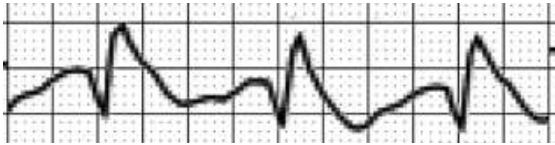Flecainide acetate intoxication



ECG diagnosis: sinus rhythm, HR 75bpm, QRS axis in upper right quadrant ("Norwest axis, "no man's land" or (i.e., "N-M-L".).) prolonged PR interval(290ms), very broad QRS duration (200ms), dominant R wave in aVR , NICD RBBB-like. Brugada phenocopy

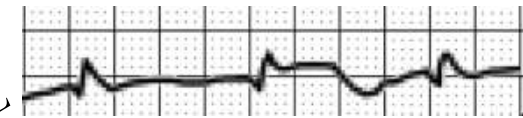
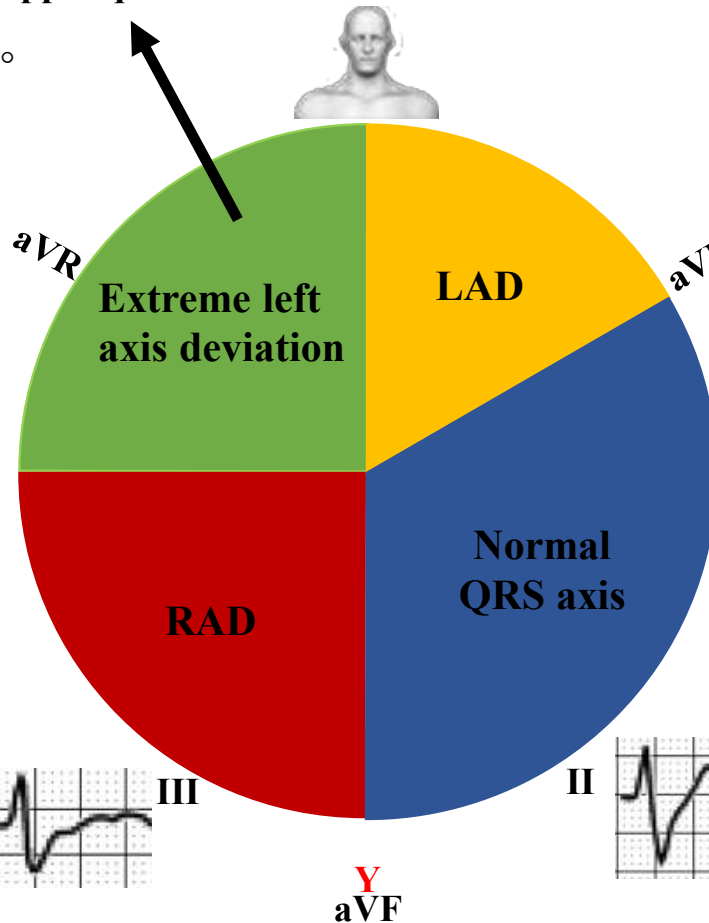
QRS axis located in the
right upper quadrant

The QRS axis is between -90° to $\pm 180^{\circ}$

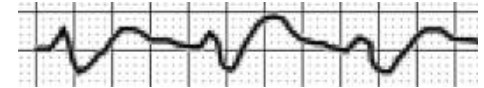


Dominant R wave in aVR

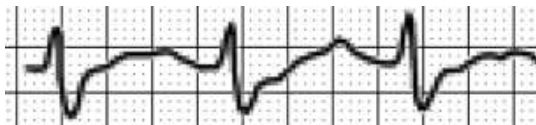- I. Poisoning with sodium channel blocking drugs (e.g., Flecainide intoxication)
- II. Dextrocardia
- III. Incorrect lead placement (left / right arm leads reversed)
- IV. ventricular tachycardia (VT)



X I

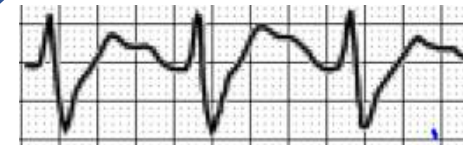

LAD: Left Axis Deviation
RAD: Right Axis Deviation

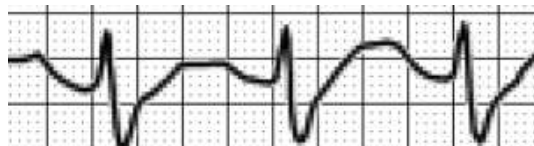

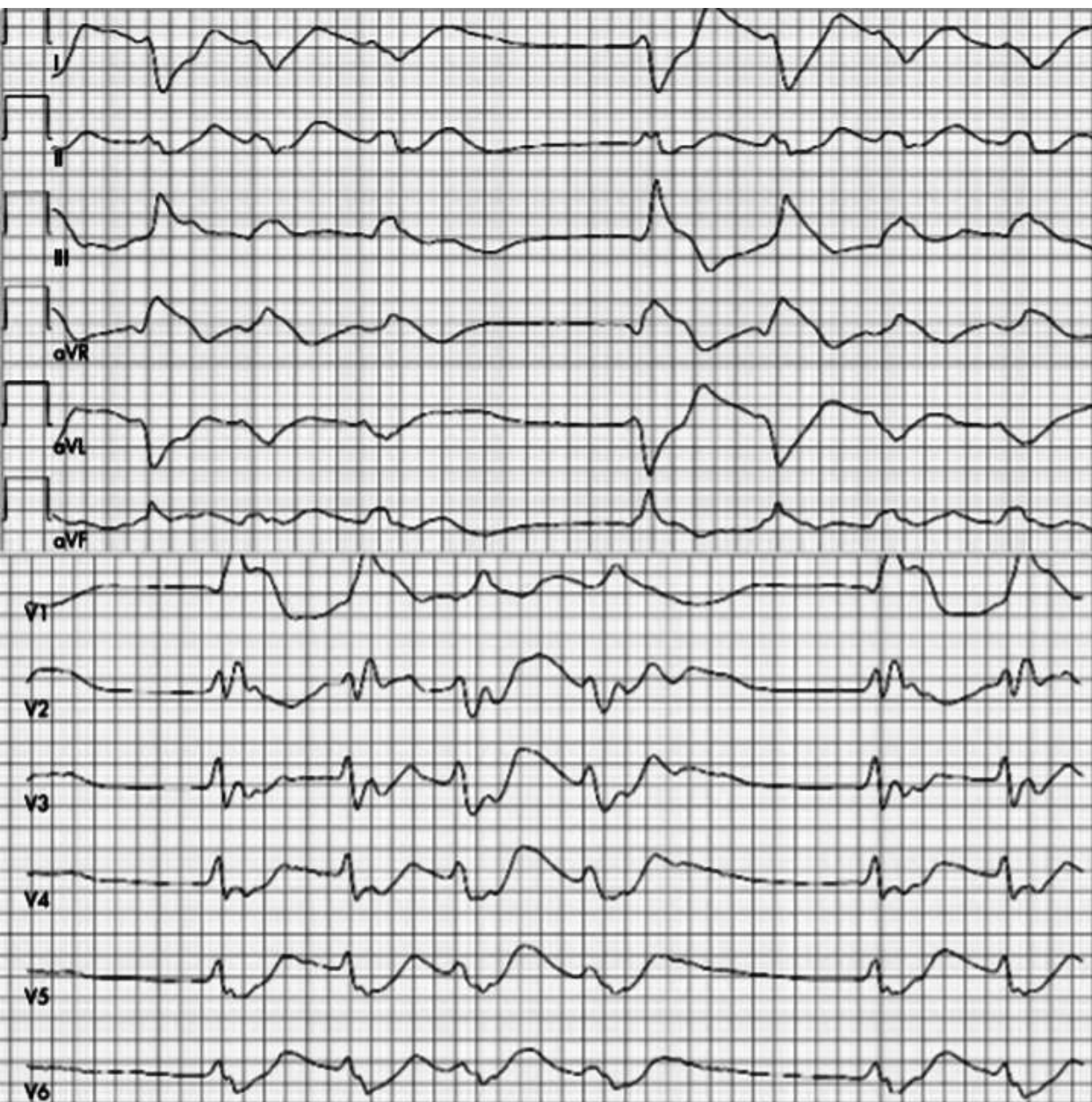
III

II



Y aVF





A 32-year-old man called an ambulance because of rapidly worsening nausea and dyspnea. When contacted he was pre-comatous and no clear history could be taken. Patient records showed that he was taking flecainide 200 mg and bisoprolol 5 mg daily for atrial fibrillation.

In the emergency room, his systolic blood pressure was low (70–85 mm Hg) and his pulse was irregular (panel). Echocardiography showed no specific acute abnormalities, but the ECG was typical for flecainide intoxication. The condition worsened rapidly. A temporary pacemaker was introduced, but a 2:1 block was observed already with a pacing rate of 70–80 bpm.

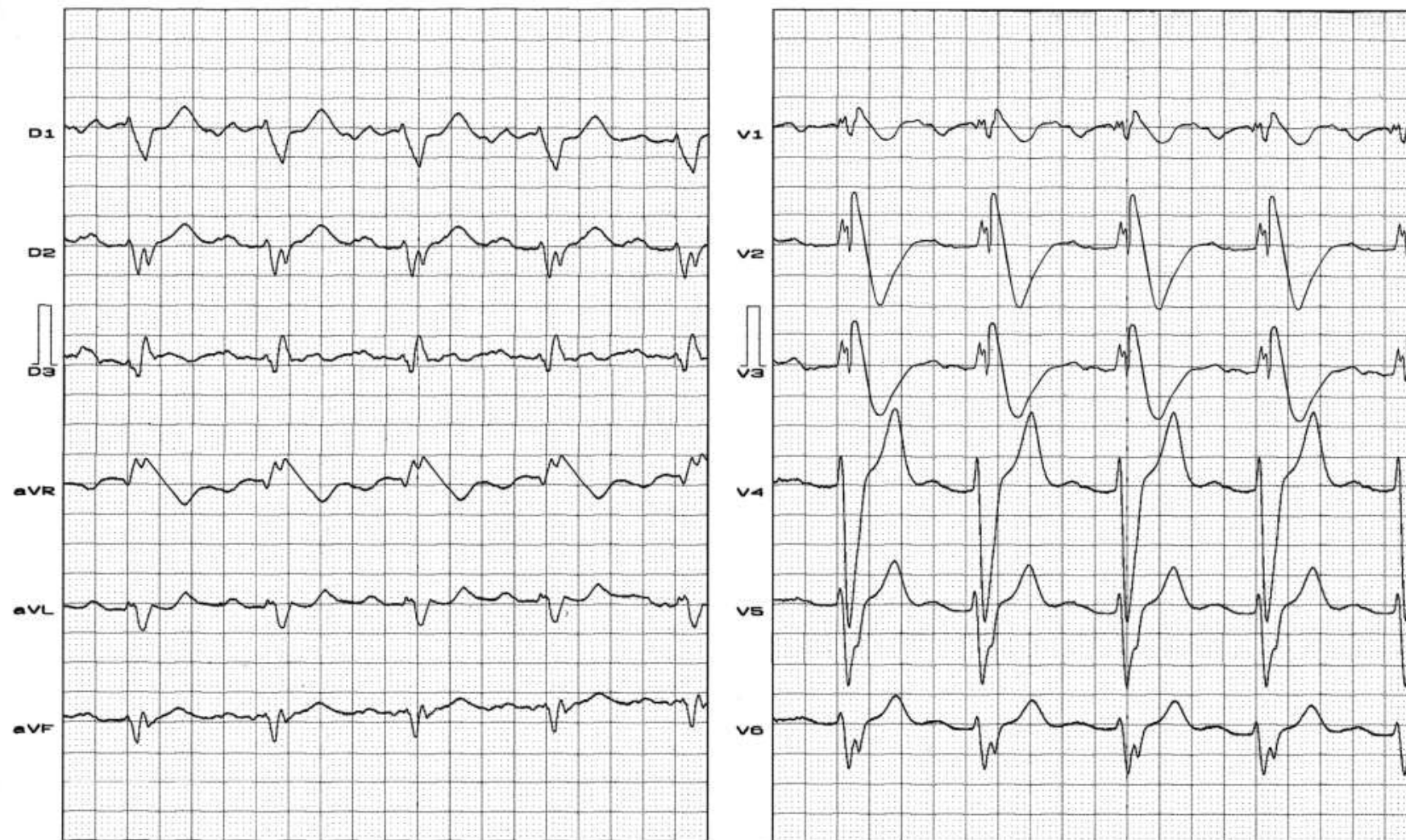
Despite a trial with extracorporeal life support the patient died a few hours later.

The flecainide concentration turned out to be very high—8.4 mmol/l (therapeutic level 0.4–2.1).

The therapeutic window for flecainide is narrow and fatal intoxications can occur accidentally with a few extra pills, especially in elderly subjects.

Class Ic antiarrhythmic drugs -sodium channel blockers intoxications Propafenone intoxication: ECG main features

Name: PAQ; **Gender:** M; **Age:** 41 y/o; **Race:** Caucasian; **Weight:** 72 Kg; **Height:** 1.78 m; **Biotype:** Asthenic; **Date:** 01/07/2008



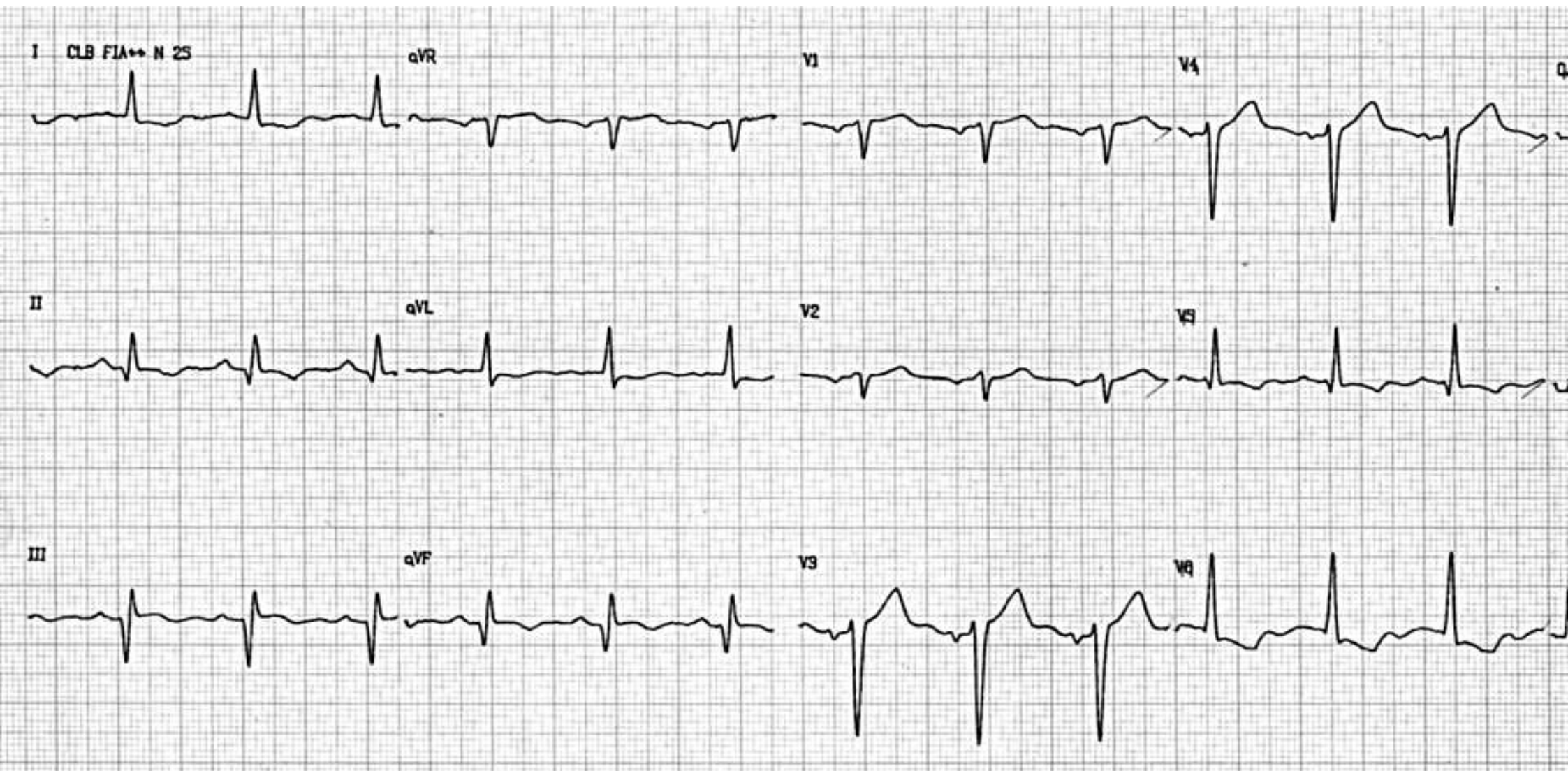
Accidental plasma concentrations of Propafenone in the toxic range. See ECG analysis in the next slide.

ECG analysis

Measurement	Result	Comments
Rhythm	Sinus	
Heart Rate	68 bpm	
P wave axis, shape, duration, voltage	+40°, bimodal, broad (160 ms) 1.5 mm high	
PR interval duration	320 ms	First-degree AV block.
QRS duration	180 ms	Wide and bizarre QRS-complex. It does not satisfy the criteria of either LBBB or RBBB. Propafenone causes slower depolarization by blocking of sodium channel. Widening of the QRS complex and markedly abnormal ventricular activation pattern is characteristic of intoxication.
QT interval	480 ms	Prolonged (upper normal limit 401 ms)
QTc	475 ms	Prolonged.
ST segment level	ST segment elevation convex to the top from V1 to V3	Induced Brugada phenocopy ECG is a sign for imminent malignant arrhythmias.
T wave axis, shape	Negative T waves from V1 to V3	Brugada phenocopy ECG.
Specific finding	LAE, 1 st degree AV block, non-specific intraventricular conduction disturbance, LQT interval, Brugada phenocopy ECG.	

Propafenone intoxication: main ECG features

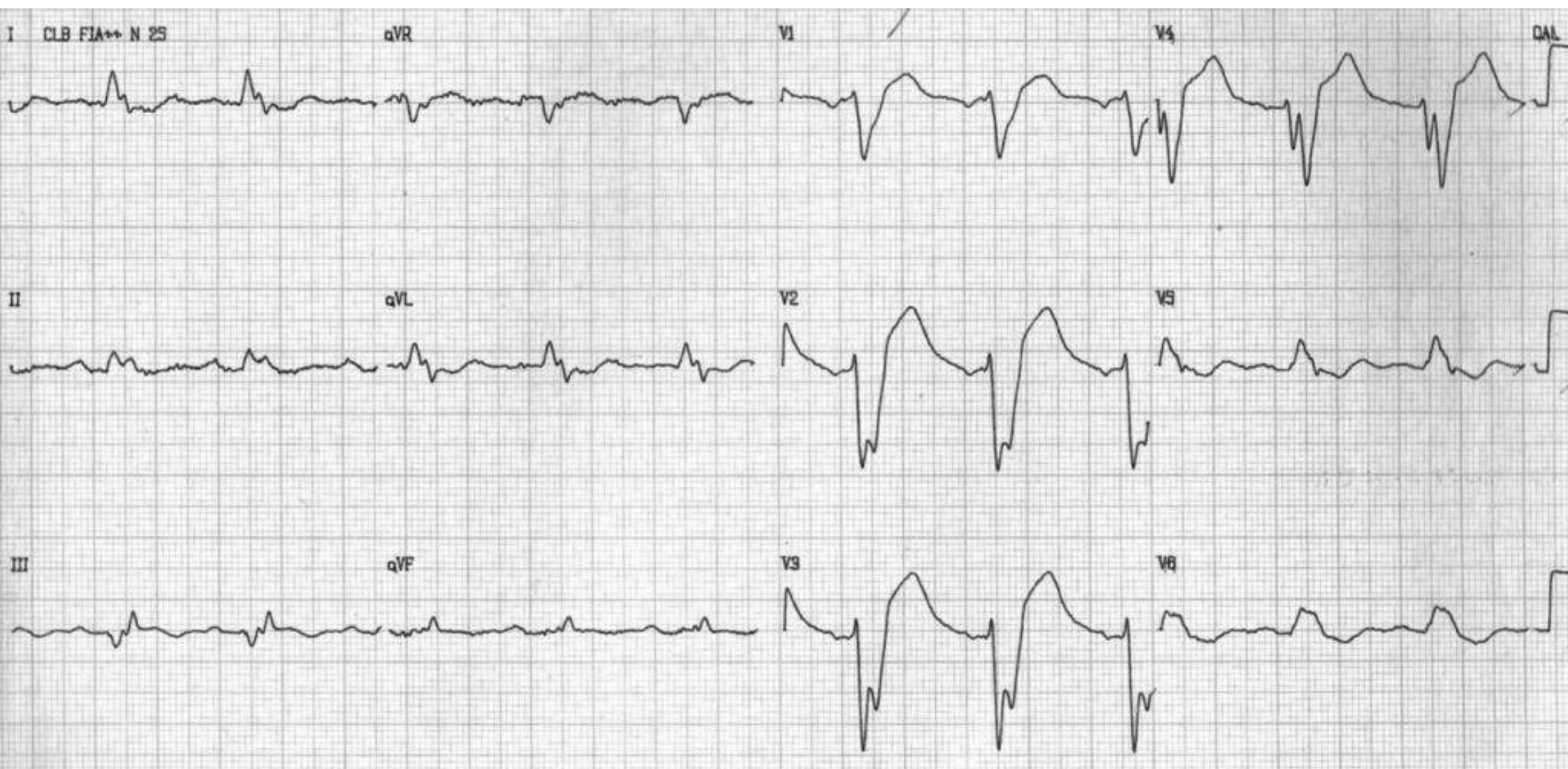
- PR interval prolongation secondary to augmentation of effective refractory periods of atrioventricular node ($>$ AH interval), His-Purkinje system ($>$ HV interval)
- Prolongation of the effective refractory period of accessory pathways
- QRS interval prolongation: in the toxic serum range, widening of the QRS-complex
- Marked abnormal ventricular activation pattern (bizarre): does not satisfy the criteria of either LBBB or RBBB
- QT interval prolongation with normal JT interval
- Eventual presence of the “memory phenomenon”: persistent T-wave changes (Wylie 2007).
- Brugada-type ECG pattern and extreme QRS complex widening with propafenone overdose is possible (Hasdemir 2006), eventually mistaken as acute myocardial infarction (Jastrzebski 2008; Chutani 2008).
- Induced Brugada-type electrocardiogram, is a sign for imminent malignant arrhythmias (Junttila 2008).
- In Brugada syndrome patients the provocation test by propafenone brought about recurrent spontaneous polymorphic VT; and programmed ventricular stimulation test during the electrophysiology study revealed both monomorphic and polymorphic VT (Karaca 2006).
- Proarrhythmic effects are more frequent in patients with previous hepatopathy. Sudden ventricular arrhythmias are described, with the characteristics of a non-responsive electrical storm following the appearance of clinical symptoms of drug intoxication (Hrovatin 2002).
- **Class Ic antiarrhythmic drugs -sodium channel blockers** have slow association/dissociation, pronounced reduction in phase 0 slope; no effect on action potential duration or effective refractory period (flecainide, propafenone, and moricizine). Propafenone intoxication (Class Ic) (see ECG later)



Clinical background: patient with coronary artery disease and high blood pressure. Before propafenone.

ECG diagnosis: left atrial enlargement + left ventricular hypertrophy with strain pattern of repolarization. Chronic inferior non-extensive myocardial infarction.

After administration of propafenone



ECG diagnosis: left atrial enlargement, LBBB-like, wide fragmented QRS (notched S-wave from V2 to V4), low QRS voltage in the FP;

4. NICD in Hypothermia

Concept: hypothermia is defined as the condition where central temperature (rectal, esophageal or tympanic) is below 35°C. Hypothermia may be accidental, metabolic, or therapeutic.

Accidental hypothermia is more frequent in countries with cold weather, during winter season. The hypothermal state is characterized by drop in basal metabolism, decrease in O₂ consumption and greater production of CO₂ (Reuler 1978).

During hypothermia, a gradual decrease of heart rate is observed and systolic volume, with progressive drop of blood pressure later, which becomes significant when central temperature values close to 23°C are reached (Gebauer 2006).

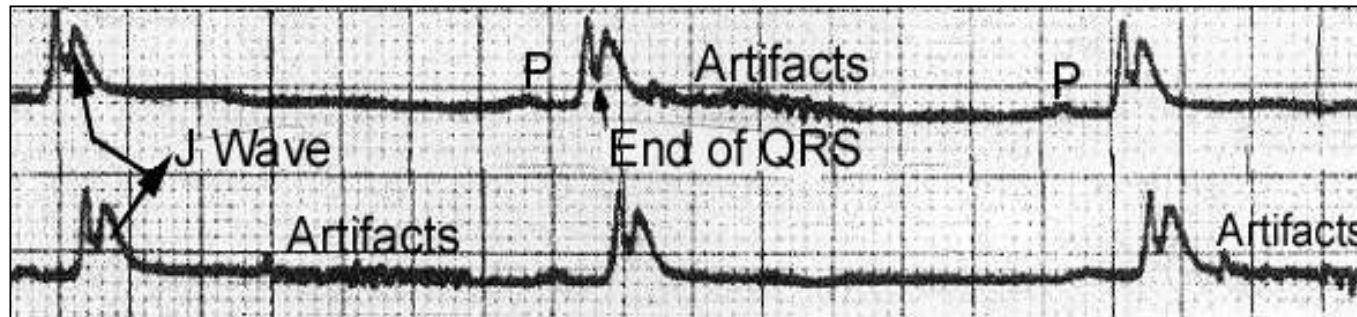
ECG in hypothermia

ECG features in a hypothermal patient include:

- Sinus bradycardia.
- Frequent atrial fibrillation (present in 50% of cases).
- PR interval prolongation.
- QT and QTc intervals prolongation.
- Different types of arrhythmias (both supraventricular and ventricular).
- Appearance of very characteristic extra wave, called J wave, sign of “camel hump”, hump-like deflection, injury potential, and the eponym Osborn wave, located between the end of QRS complex and ST segment onset. J wave is characteristic of hypothermia; however, not pathognomonic, since it may be observed in other conditions in normothermia.

ECG in hypothermia

- 1) **Rhythm:** sinus or AF present in 50-60% of the cases, when temperature is lower than 32°C (Okada 1984). Less frequently, atrial flutter may be found, junctional rhythm and even degeneration into VF. These events appear in the second phase of hypothermia (out of exhaustion) when temperature is between 27°C and 34°C. Idioventricular rhythm and total AV block are described.
- 2) **Artifacts:** frequent fluctuation in the baseline as a consequence of artifact caused by the muscular trembling of the patient. This fact is found only in the initial phase (of struggle), when body temperature is between 36 and 32°C.



- 3) **Heart rate:** in the initial phase there may be tachycardia by release of adrenaline, and later sinus bradycardia in 30% of the cases, in patients since hypothermia is in the struggle phase. Characterized by being progressive, with intensification of hypothermia (Harumi 1989). There is no linear correlation with the intensity in body temperature drop.

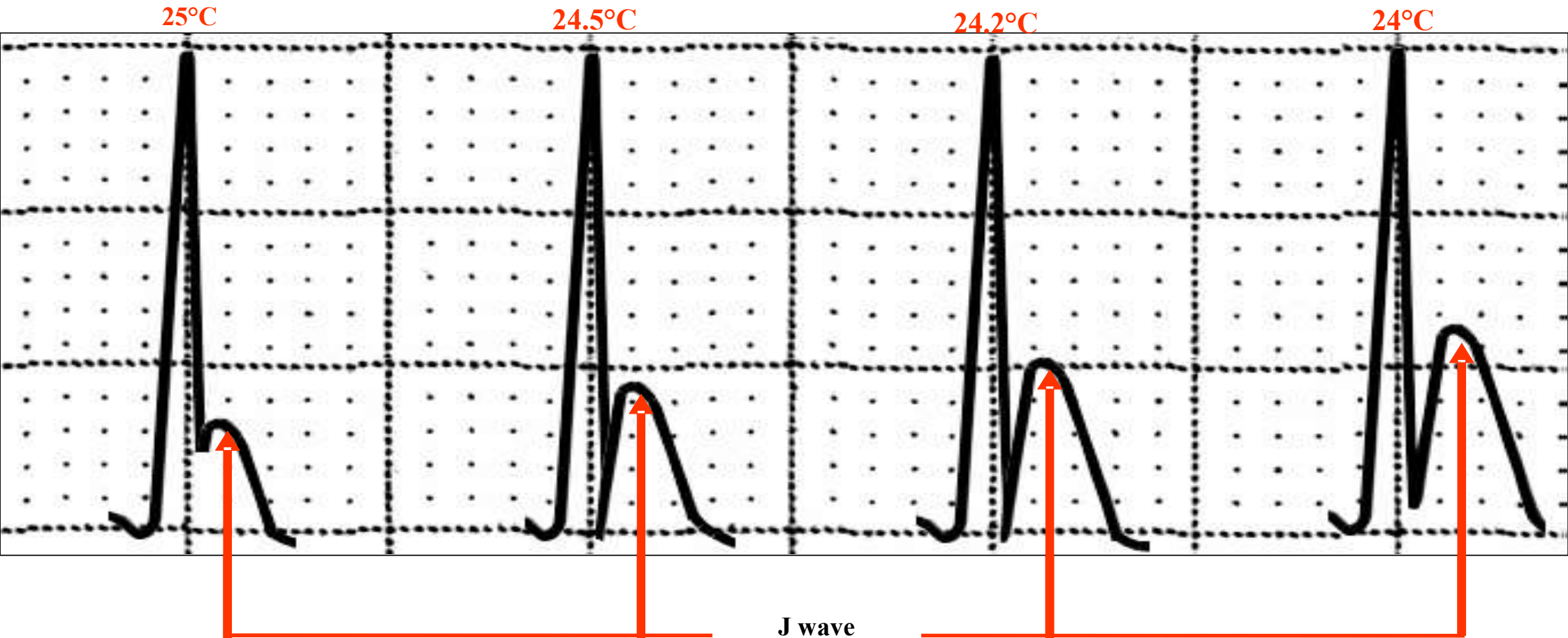
Bradycardia is due to decrease in the ascending ramp in phase 4 in the P cells of the sinus node (decrease of diastolic depolarization, rhythmicity or automatism) by increased vagal reflex, even coexisting with increase of circulating catecholamines.

Hypothermia constitutes one of the three causes for chronic metabolic bradycardia; the other two being obstructive jaundice (by bradycardizing effect of biliary salts on the sinus node) and myxedema (Constant 1984). On the other hand, hypothyroidism is one of the causes for metabolic hypothermia.

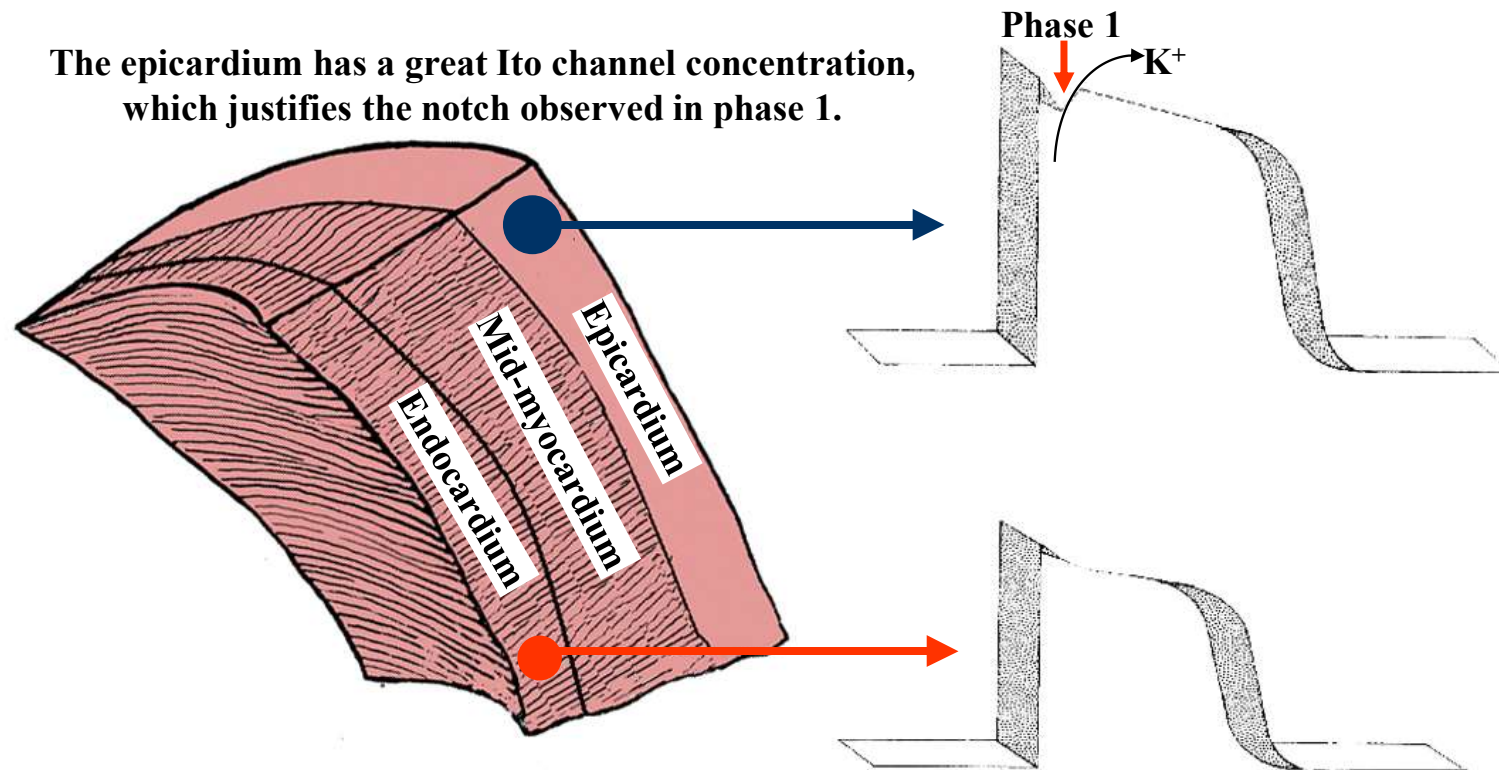
- 4) **P wave:** voltage decrease is described (Okada 1984). Also widening of P wave (decreasing of the velocity of intra-atrial conduction)
- 5) **PRi interval:** it tends to be prolonged as body temperature decreases (Emslie-Smith 1959);
- 6) **QRS complex:** decrease in voltage and increase in duration. The latter may be mistakenly considered to be increased, by the presence of the so-called J wave (see item as belonging to QRS), resembling branch block or intraventricular disorder of the stimulus. The explanation for QRS broadening is in the decrease of rest potential and consequently, phase 0 rise velocity and negative dromotropism.

- 7) **J wave:** it constitutes the most typical electrocardiographic element; however, not pathognomonic, since it may be found in other clinical circumstances. It is located at the point where QRS ends (late δ wave) and the initial part of the ST segment (J point). It corresponds to phases 1 and 2 of action potential. The J wave is due to different densities in the Ito channels concentration (phase 1) in ventricular myocardium thickness. These channels of the initial potassium outflow are very numerous in the epicardium and scant or absent in the endocardium. This fact justifies phase 1 of AP in the epicardium showing a notch. On the contrary, phase 1 of endocardial cells lacks a notch (Yan 1996). The J wave “per se” is not significant for ventricular fibrillation (VF) appearance, since QRS complex duration prolongation constitutes a reliable sign for VF appearance. When rapidly induced hypothermia for heart surgery causes QRS prolongation, it causes VF in almost all patients (Fleming 1957). J wave presents the following features:
- **Location:** the J wave is located at the point where the QRS complex ends (late δ wave) occupying the initial part of the ST segment, corresponding to phase 1 and 2 of monophasic action potential (Alsafwah 2001).
 - **Polarity:** always positive and prominent in the leads that face the left ventricle: V_5 and V_6 and possibly and mainly in hearts in a vertical position in inferior wall leads (Sgobba 1982), unlike J wave found in Brugada syndrome, located in right precordial leads V_1 to V_2 or V_3 .
 - **Voltage:** slow and lasting inscription, and voltage greater in left leads V_5 and V_6 and inversely proportional to the severity of hypothermia, i.e. the lower the central temperature, the greater the voltage of J wave. In certain cases, J wave acquires a great voltage associated to superior convexity, mimicking the acute phase of myocardial infarction: "evolving myocardial infarction", which reverses with central temperature normalization (Sain 2002). There is inverse and significant correlation between J wave voltage (mm) and central temperature in hypothermia.
 - **Aspect:** it may appear resembling small secondary R wave (R'), falsely mimicking RBBB. . The J wave is characteristic of hypothermia; however, not pathognomonic, since it may observed in normo-thermal circumstances (Patel 1994).

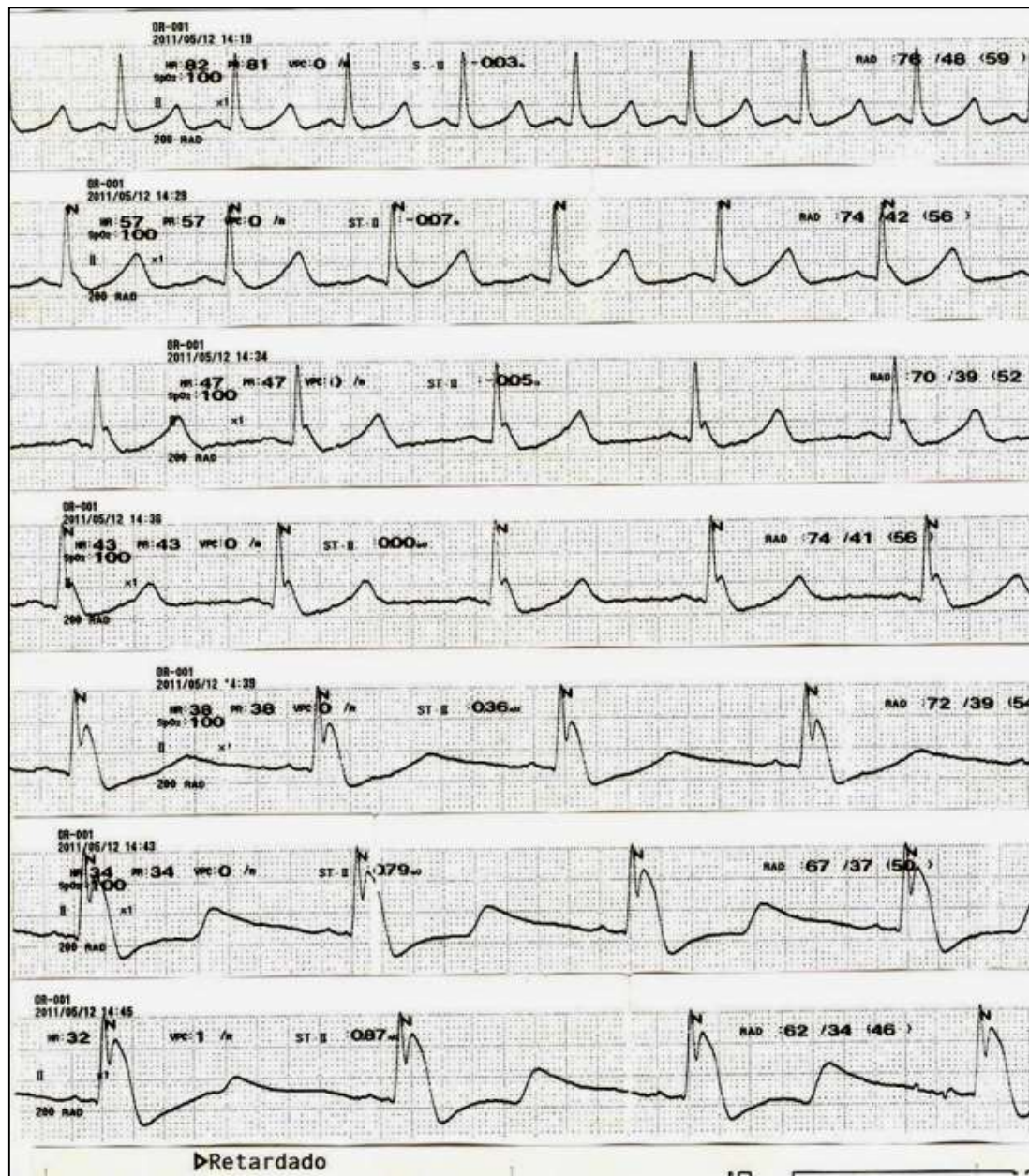
Inverse and significant correlation between J wave voltage (mm) and central temperature in hypothermia



Outline of heterogeneity in the profile of action potential (AP) in ventricular wall thickness



The endocardium does not have Ito channels, which conditions the absence of notch in phase 1 of AP in these cells.



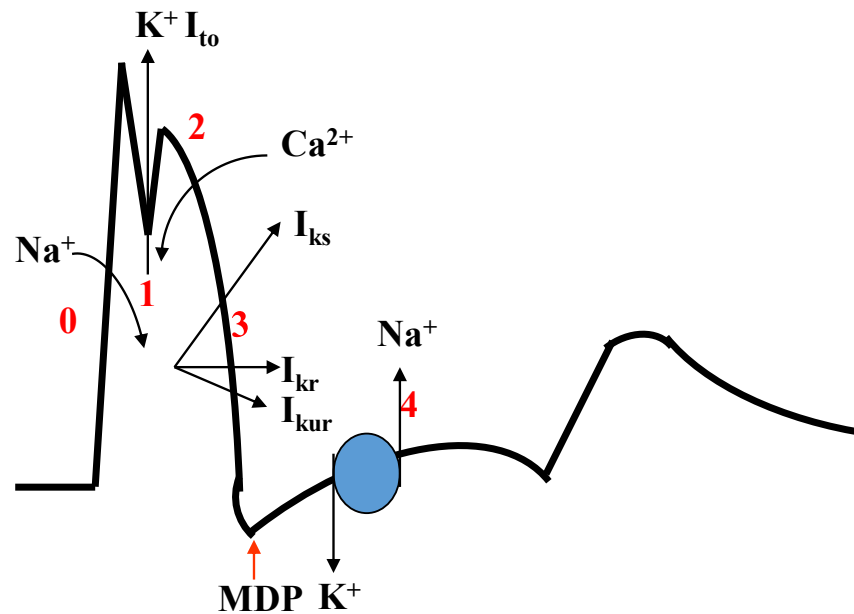
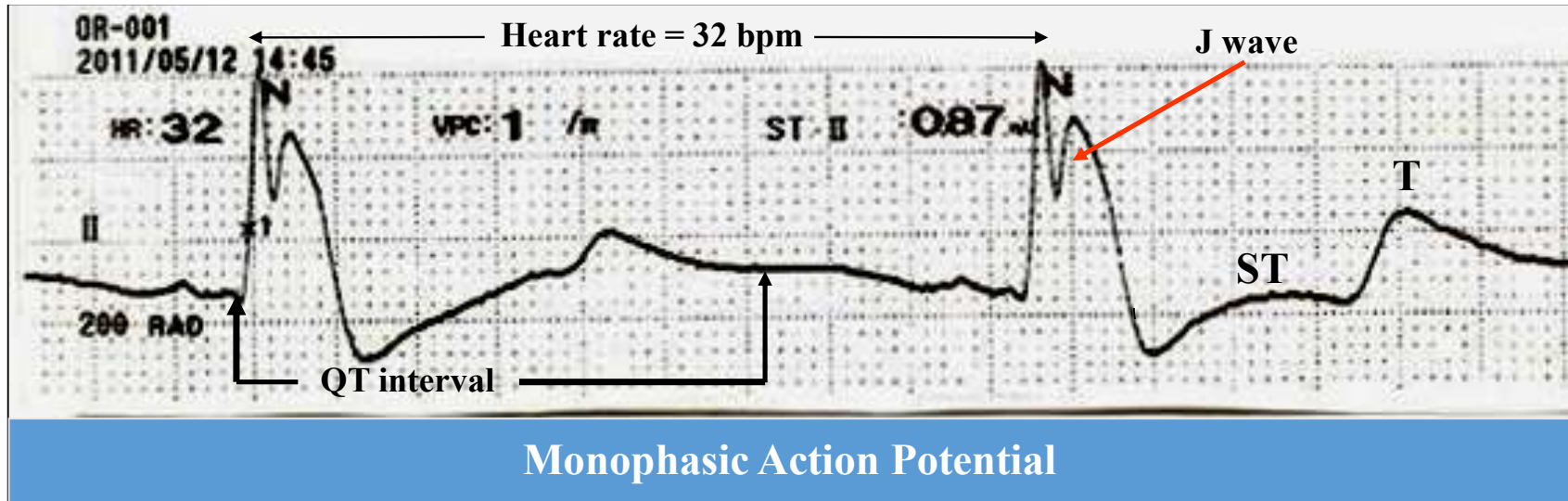
The tracing was obtained during cooling of the blood before a surgical procedure of the heart.

Although the ECG obtained was somewhat expected, what was striking is that the progressive development and augmentation of the J wave was recorded.

Most of the hypothermia cases are published in the moment when the patient is rescued and after recovery. On the other hand, in this case we can see the time course of changes up to the simulation of a monophasic action potential.

Additionally, significant bradycardia is observed and the QT interval was too prolonged, something that usually is not given much attention in the published cases.

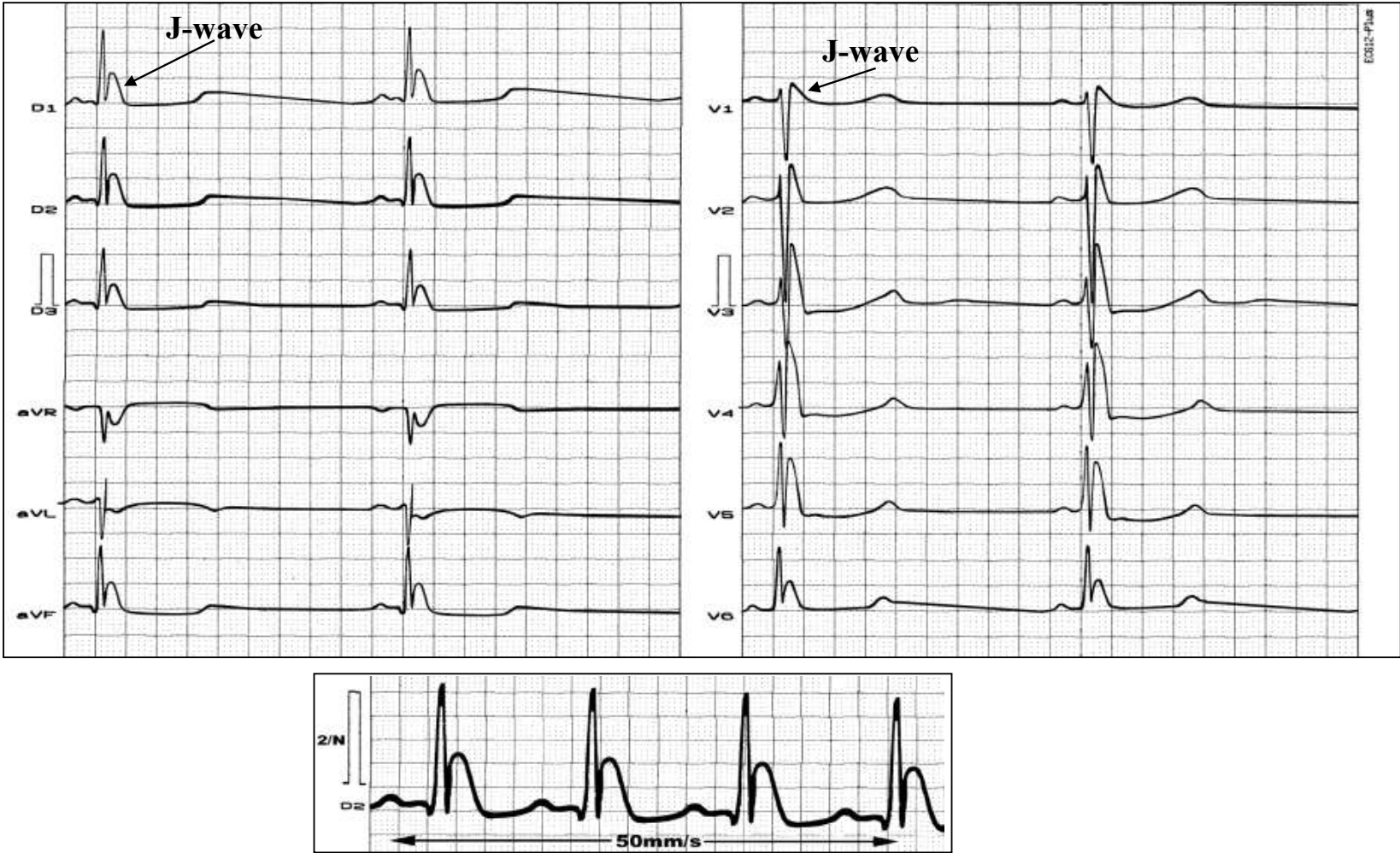Courtesy from Prof. Dr. Raimundo Puerta from Cuba



Maximum diastolic potential (**MDP**): the most negative transmembrane potential achieved by a cardiac cell during repolarization.

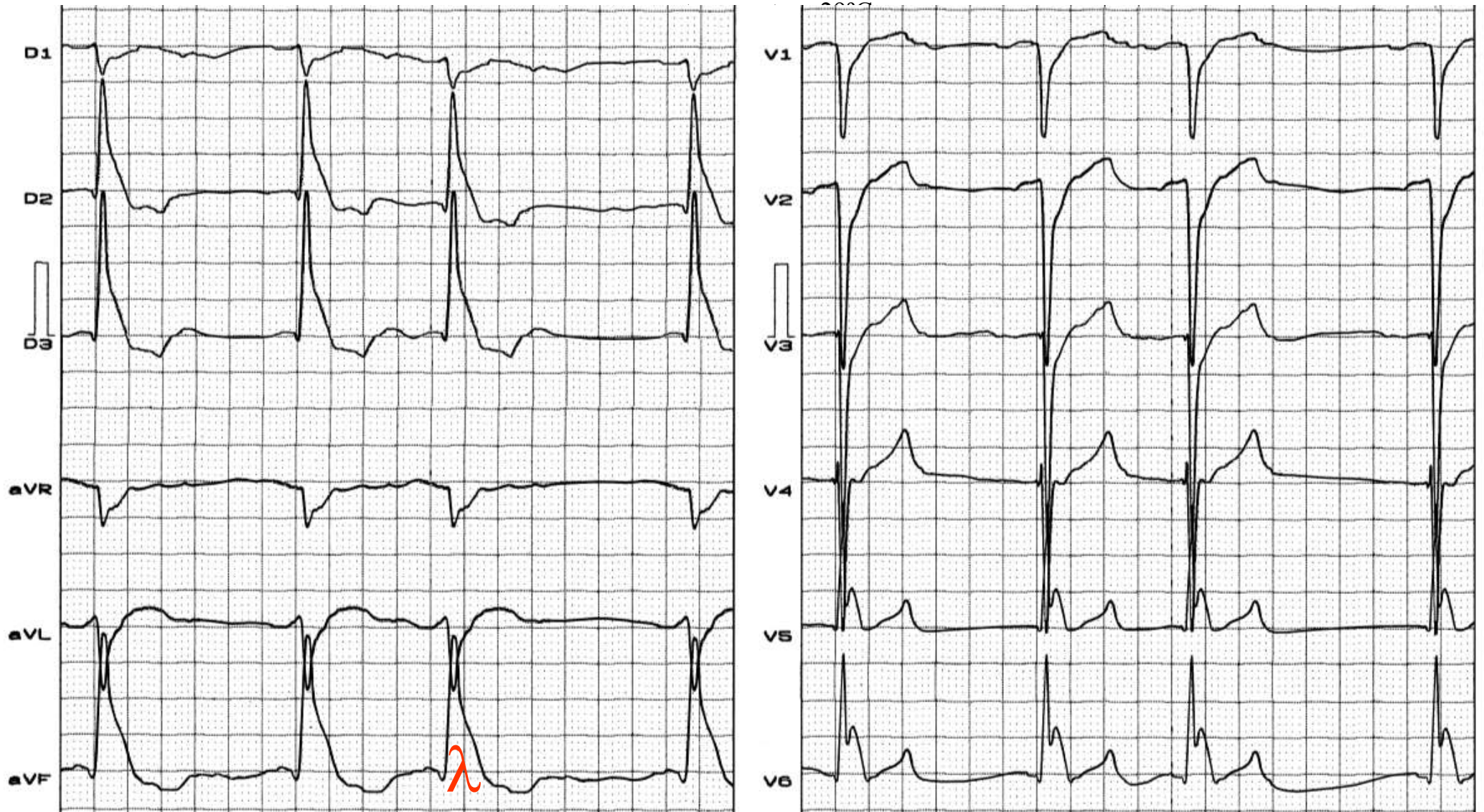
Name: ADS; **Gender:** Male; **Age:** 32 y/o; **Ethnic group:** mulatto; **Weight:** 68 Kg; **Height:** 1.64 m; **Date:** 03/04/2002; Steps to increase body temperature.

Characteristic ECG of patient in severe hypothermia



ECG diagnosis: sinus bradycardia of 30 bpm, prominent J wave, very evident in inferior leads and I, as well as in all precordial leads. Pseudo CRBBB determined by J wave, which is not part of the QRS complex.

Name: PASA; **Gender:** Male; **Age:** 47 y/o; **Ethnic group:** Afro-descendant; **Weight:** 61 Kg; **Height:** 1.68 m; **Date:** 03/07/2008; Central body



Severe hypothermia. Atrial fibrillation with slow ventricular response. Left posterior fascicular block pattern. Gussak wave or lambda wave.

5) Peri-ischemic block: this term is applied only to changes in QRS configuration associated with QRS widening (Surawicz 1997). It is transient \uparrow in QRS duration accompanies the ST-segment deviation seen with acute injury (the present case). is term recommended when a transient increase in QRS duration accompanies the ST-segment deviation seen with acute injury. Reversible QRS changes during AMI are attributed to passive pull by the ST-segment shift and intraventricular conduction disturbance (Surawicz 1995; 1998).

6) Peri-infarction block the term was suggested by First, Bayley, and Bedford in 1950 (First 1950) to describe a type of intraventricular conduction defect that develops following MI. They described alteration in the direction of the early portion of the QRS complex (initial QRS forces) that produced definite manifestations of MI (Q waves) and slurring and prolongation of the terminal portion of the QRS complex (terminal QRS forces), giving rise to a total QRS duration of ≥ 120 ms. The authors postulated that the normal radial spread of excitation to the epicardium was interrupted by subendocardial MI and that the overlying active myocardium was activated through circuitous routes of slower conducting myocardial fibers. It is characterized by a wide QRS complex with a Q wave followed by an R wave in which the R-wave peak time is prolonged, whereby part of the QRS (most often the terminal portion) appears greatly slowed, irregular, or notched, without bundle branch block or fascicular block patterns (next figure). The delayed R-wave peak time is explained by a widening of the trajectory of the electrical depolarization wave bypassing the infarcted area to reach the epicardium, with the endocardial necrosis zone representing an obstacle to the normal excitation of the healthy subepicardial layers or areas of the wall located beyond the infarction. The increase in QRS duration is only observed if the block is both significant and extensive; otherwise, it only results in QRS deformation, such as a notched appearance, stuttering, or delayed R-wave peak time (ie, fragmented QRS).

In summary, these various subgroups of patients with NICD share a common feature (widening of the QRS complex without the typical features of LBBB or RBBB) but correspond to very different clinical and pathophysiological entities. Thus, they are associated with abnormal terminal QRS forces directed toward the infarct, with an angle of $\geq 100^\circ$ between the initial and the terminal QRS forces with prolongation of the QRS complexes. These can be called peri-infarction block. **The term *possible peri-infarction block*** is recommended when, in the presence of an abnormal Q wave generated by a MI in the inferior or lateral leads, the terminal portion of the QRS complex is wide and directed opposite to the Q wave (ie, a QR complex in the inferior or lateral leads). In the vast majority of instances it can be differentiated from bundle branch block and from intraventricular block of other types. The importance of the lesion is emphasized, as the name implies, by its association with (usually) an old MI. A long time ago, Wilson and his associates have preferred to refer to the lesion as "arborization block," indicating that they do not necessarily agree with the implications of the name "arborization block" (Wilson 1944). The diagnostic criteria of peri-infarction block include: (1) evidence of MI of the subendocardial region of the ventricular wall, or transmural MI with a circumferential region of subendocardial damage;

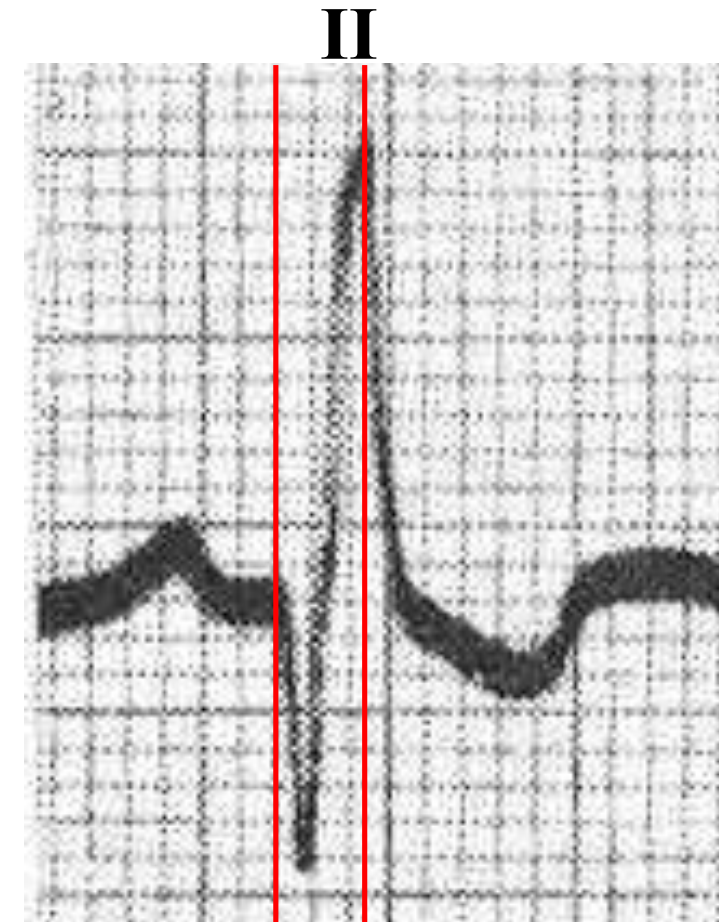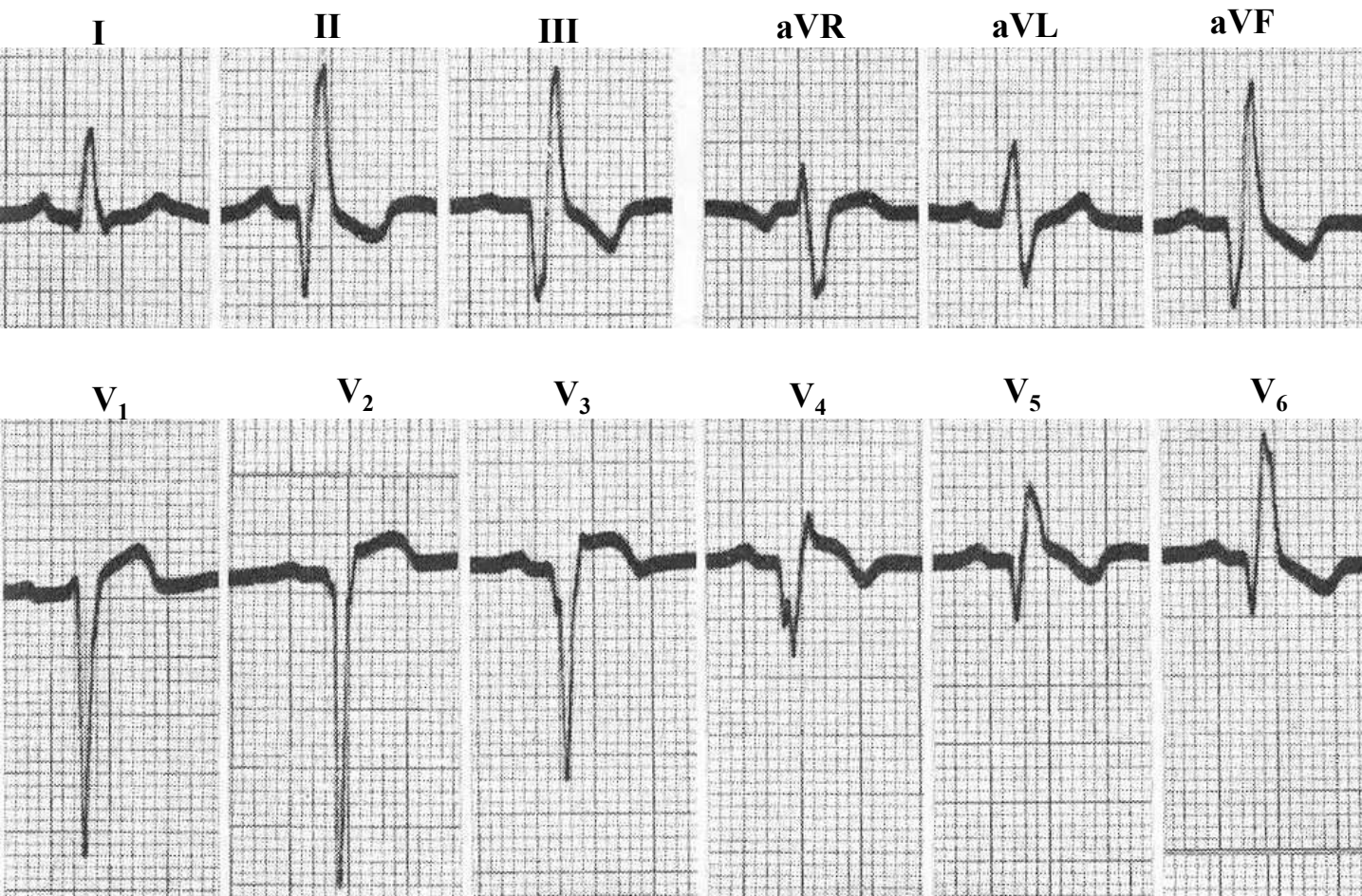
(2) QRS complexes in the limb leads with QRS duration $\geq 120\text{ms}$; a characteristic QRS pattern in the unipolar precordial and extremity leads. When the exploring electrode is placed over the center of a transmural MI with a circumferential region of subendocardial damage, the associated deflection will be of a QS type. As the exploring electrode is moved over the living muscle comprising the outer layer of the involved part of the ventricular wall, there is late activation of this region and the ECG demonstrates an initial Q wave followed by a broad R wave, the downstroke (R-peak time) of which terminates the long QRS interval. It follows that, when the exploring electrode is placed directly over an MI which involves only the subendocardial lamina, tracings of the latter type, namely, a Q wave with a broad R wave, will be obtained.

1. Peri-infarction block produces a characteristic ECG pattern which may often closely resemble that of bundle branch block or intraventricular block of other types, particularly in so far as Leads I, II, and III are concerned.
2. Infarctions of the subendocardial region of the myocardium are responsible for the production of peri-infarction block.
3. The term "arborization block" is objectionable since its implication limits the nature of the blocking process by directly incriminating the Purkinje network and, at the same time, fails to emphasize its association with MI. Moreover, a reasonable explanation appears to depend upon local damage of the myocardium
4. The R-wave peak time (RWPT) in precordial leads overlying uninvolved portions of the LV wall occurs at the normal time but is delayed in leads overlying the peripheral zone of the infarction.
5. The ECG presents evidence of MI. If the latter is an anterior infarction, the ECG often has a superficial resemblance to LBBB.
6. The more important ECG feature of peri-infarction block is the mean QRS vector for the first 40ms is abnormally directed; pointing away from the site of the infarct, and the mean vector for the last 40ms of the QRS interval is also abnormal in direction, pointing in a direction more or less opposite to the mean initial vector. With few exceptions, this combination of findings is diagnostic of peri-infarction block. In other words, the initial and final QRS forces in peri-infarction block are directed differently. The spatial angle subtended by the initial and terminal 40ms mean QRS spatial vectors usually exceeds 60° (Grant 1954).
7. The limb lead ECG does not ordinarily furnish sufficient information for the differentiation between subendocardial infarction complicated by peri-infarction block and intraventricular block of other types.
8. In ECG peri-infarction block pattern evidence for disease of the LV was found in 80% of cases. LVH and diffuse scarring of the LV are the most common abnormalities on pathologic examination. Definite MI is found in $\approx 22\%$ subjected to postmortem examination (Castle 1965).
9. The peri-infarction block refers to an ECG abnormality caused by delayed activation of the myocardium in the affected region. Using computer modeling Baracharova et al. .” (Bacharova 2013) showed that the localized slowing in impulse propagation (peri-infarction block) not only modified the QRS complex, but produced also changes in the ST segment that are consistent with changes that are usually interpreted as effect of the “injury current.”

Flowers et al.([Flowers 1990](#)) explores the relation of the presence of peri-infarction block to ventricular late potentials in patients with inferior wall MI. The hypothesis was that both the peri-infarction block pattern and subtle low-level ventricular late potentials are expressions of conduction abnormality associated with MI. The consequent question arose whether peri-infarction block may have the same association with sustained VTs that has been demonstrated in postinfarction patients with ventricular late potentials(LPs). Seventy patients with documented Q-wave MI were divided into those with and those without peri-infarction block. Signal-averaged electrocardiograms were obtained. Analysis of the vector magnitude complex revealed that the total duration of that complex and the duration of terminal potential under 40 microV in the peri-infarction group exceeded that in the group without peri-infarction block. The voltage in the last 40 ms of the vector magnitude complex was also significantly less in the peri-infarction group. There were 13 instances of sustained VT/VF or SCD occurring subsequent to MI not associated with the acute ischemic event, 11 of which occurred in the peri-infarction group. The significantly higher incidence of late potentials along with the significantly higher incidence of sustained VTs in the peri-infarction block on the surface ECG may provide another marker for identifying persons at increased risk for these arrhythmias subsequent to MI.

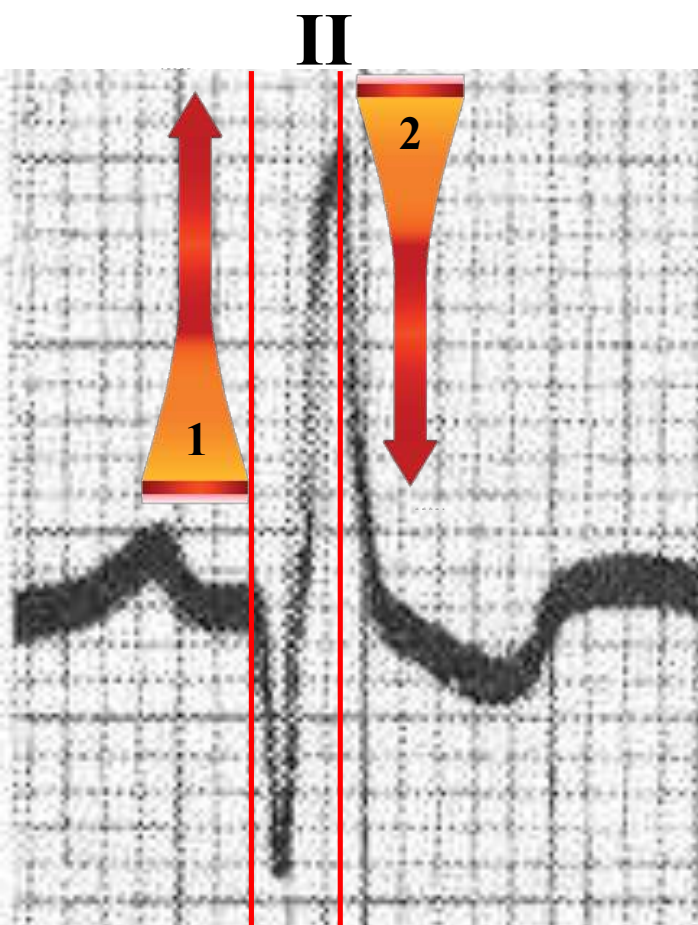
A terminal QRS deflection on a 12-lead ECG (described as peri-infarction block) most likely represents slowed conduction in a large area of myocardium near the infarct zone. Santolin et al. ([Santolin 1991](#)) described a patient with peri-infarction block, abnormal findings on signal-averaged electrocardiogram, and reentrant VTs. This observation underscores the need to recognize the importance of terminal QRS deflections in the appropriate clinical situation.

Typical example of peri-infarction block in inferior and anterolateral myocardial infarction

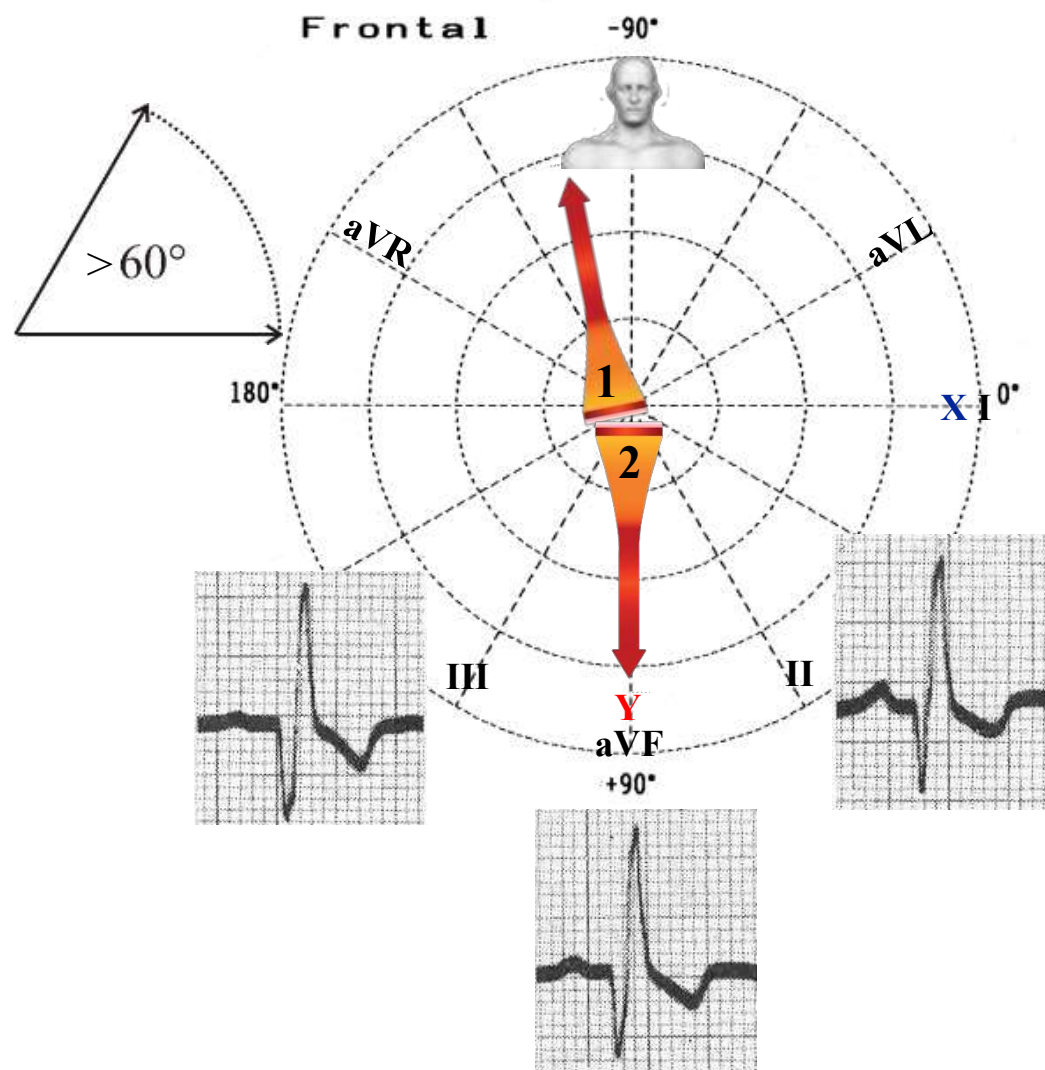


Prolonged RWPT

QRS duration 120ms, Q waves followed by tall broad R waves in inferior leads and V₅-V₆. Very prolonged R-wave peak time (RWPT): 90ms (normal ≤ 35 ms). We can see a wide angle between the initial and terminal 40ms vectors when plotted on the triaxial reference figure (next slide). The initial 40ms vector pointing away from the diaphragm and the terminal 40ms vector pointing toward the diaphragm.

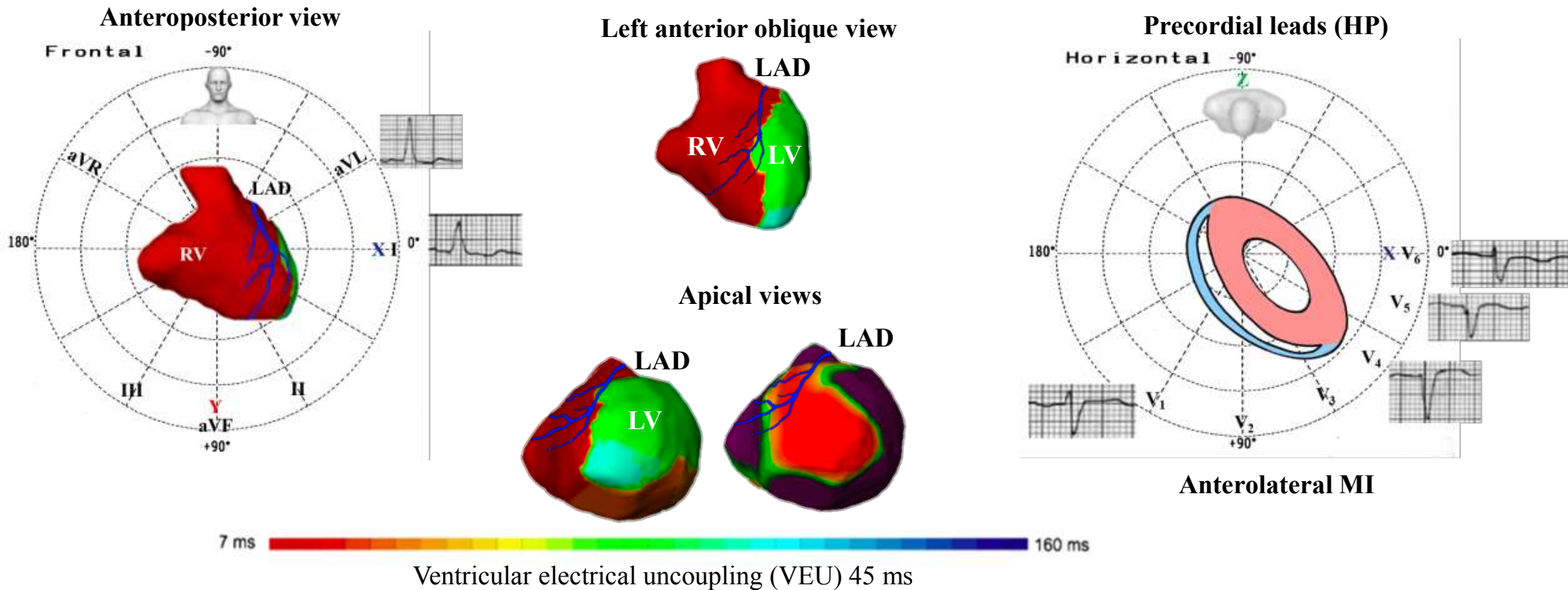


The initial 40ms vector (1) pointing away from the diaphragm and the terminal 40ms vector (2) pointing toward the diaphragm.



The initial and terminal 40ms mean QRS spatial vectors usually exceeds 60° .

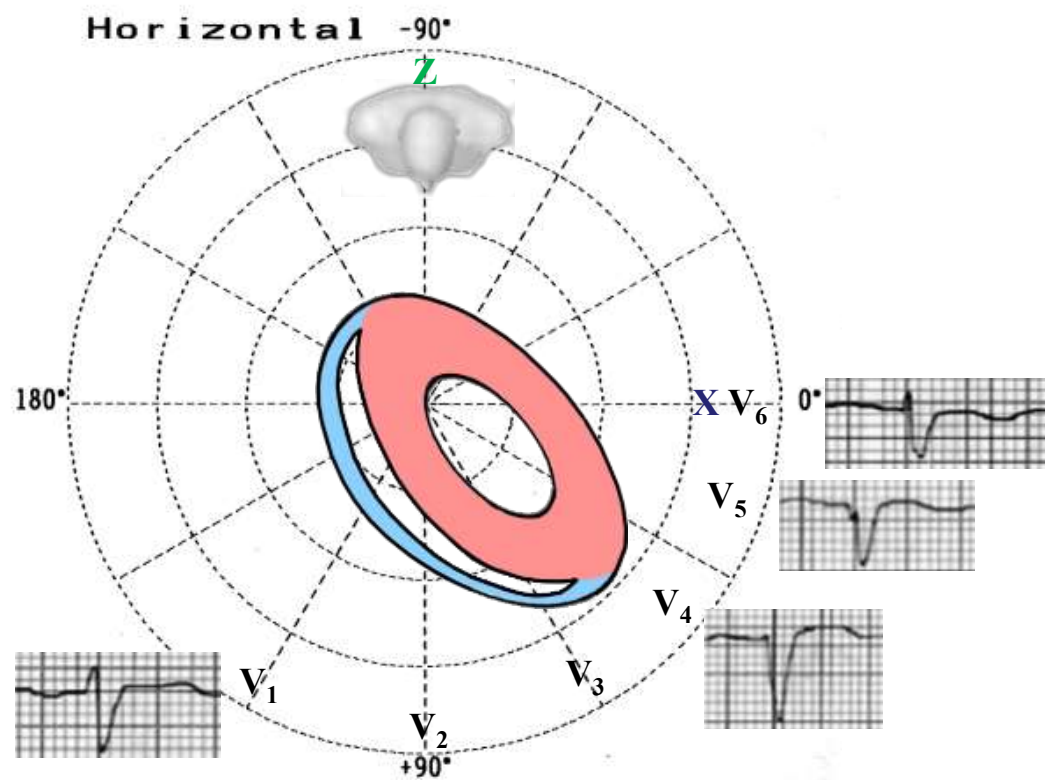
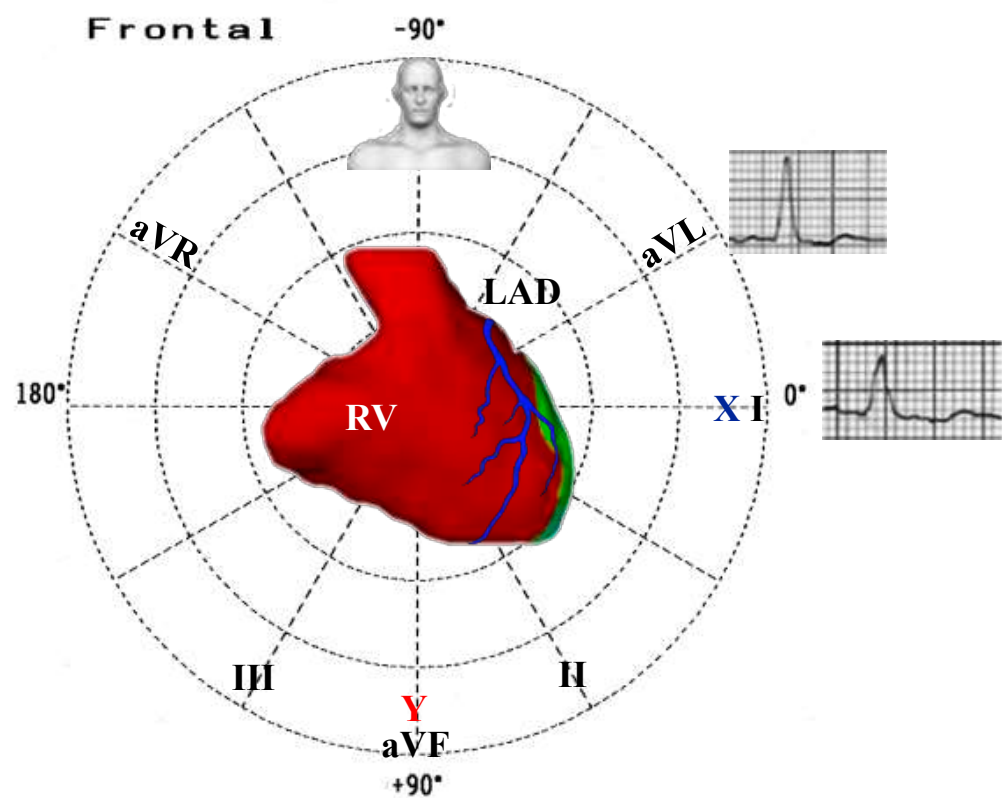
ECG activation maps in a non-responder to CRT. Both ventricles are displayed in 3 views: anteroposterior (AP), left anterior oblique (LAO), and apical. Additionally, we show the main precordial leads



Clinical: 77-years old woman with ischemic cardiomyopathy and occlusion of mid segment of LAD coronary artery. LVEF of 20%.

ECG: prolonged QRS duration (135ms), nonspecific intraventricular conduction delay (NICD).

In the HP, anterolateral MI, QS wave in lead V5 and rS in V4 and V6 are against the diagnosis of LBBB. The RV breakthrough is followed by a rapid activation of the RV. The apical necrotic area slows the LV wave front.

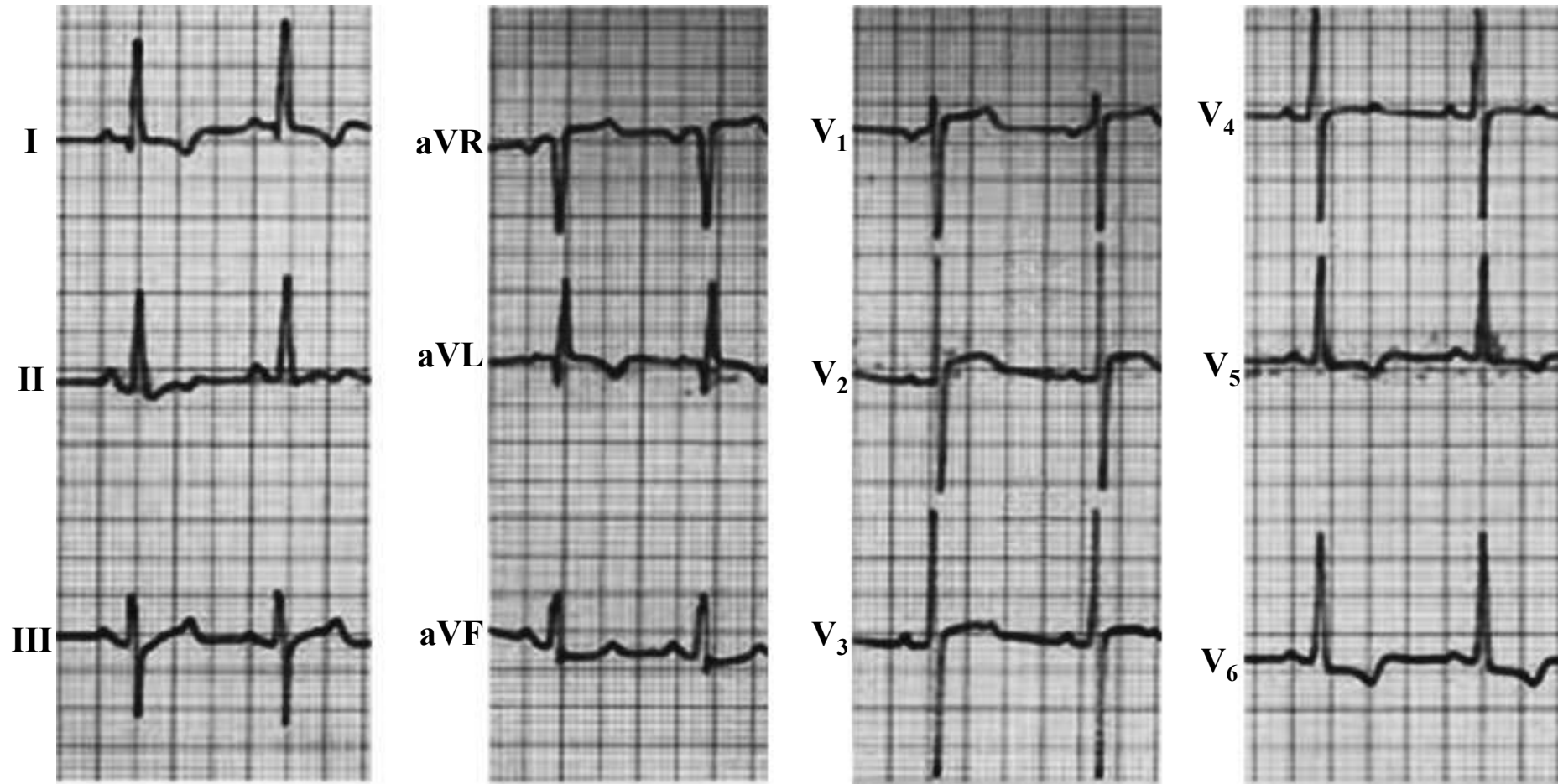


7. Atypical LBBB In the NICD subgroup, one must include the appearance of atypical bundle branch block observed in post-myocardial infarction patients that corresponds to the probable existence of a true LBBB, in which the superposition of the electrical abnormality in relation to the necrotic area alters the typical ECG appearance (Figure). The ECG reveals the presence of wide, deep Q waves in multiple leads after a massive myocardial infarction or that affect multiple areas (eg, in a patient with a preexisting LBBB, a QS complex may be present in the anterior leads and a QR wave in lateral leads after an anterior or lateral myocardial infarction. A part of the fragmented bundle branch block described by Das et al has been shown to be related to scar in patients with known or suspected coronary artery disease. The activation sequence in these patients should be very close to that observed in patients with a typical LBBB.

Example of atypical LBBB case report

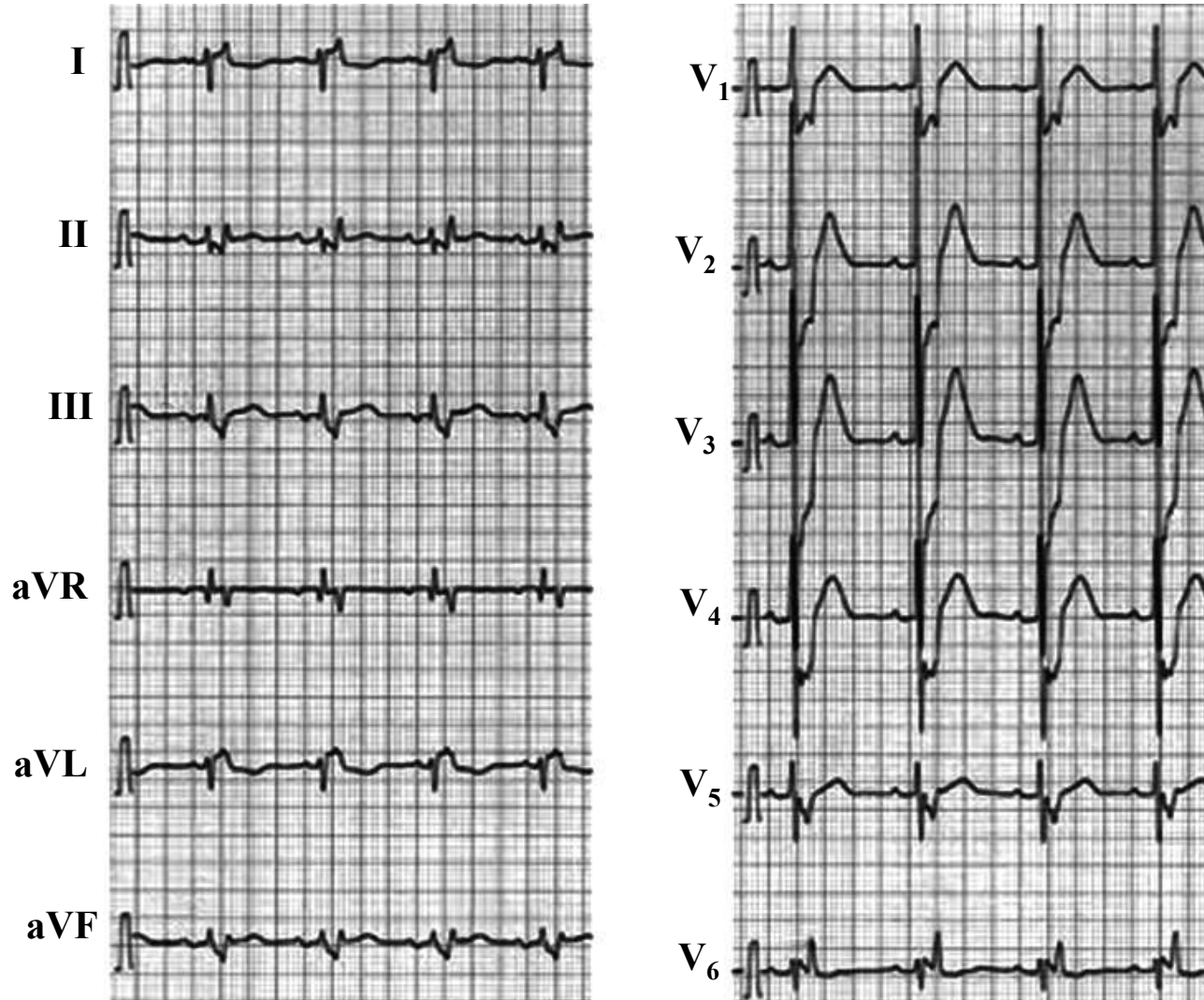
A 70-year-old man was admitted into the hospital in congestive heart failure. The patient was diagnosed 22 years ago of non-obstructive hypertrophic cardiomyopathy (NO-HCM). The ECG on his current admission showed sinus rhythm and a very peculiar form of left bundle branch block (LBBB) (ECG -2004). A 2D-echocardiogram revealed an LV end-diastolic diameter (Dd) of 53 mm, with an LVEF=25%, and a septal thickness of 10.6 mm. On echocardiograms performed 10 years ago, the septum was 16 mm thick and the posterior wall 13 mm. In 1998, a coronary arteriogram revealed normal coronary arteries and LVEF=40%. An echocardiogram performed in 2002 showed thinning of the ventricular septum (11 mm) with a generalized hypokinesia and dilation of the LV cavity (Dd 59 mm). The evolution of HCM toward a dilated “burned-out” phase is not frequent. The unique finding of this patient is represented by this extremely rare manifestation of LBBB and his pathological evolution along the time.

A ECG - 1982



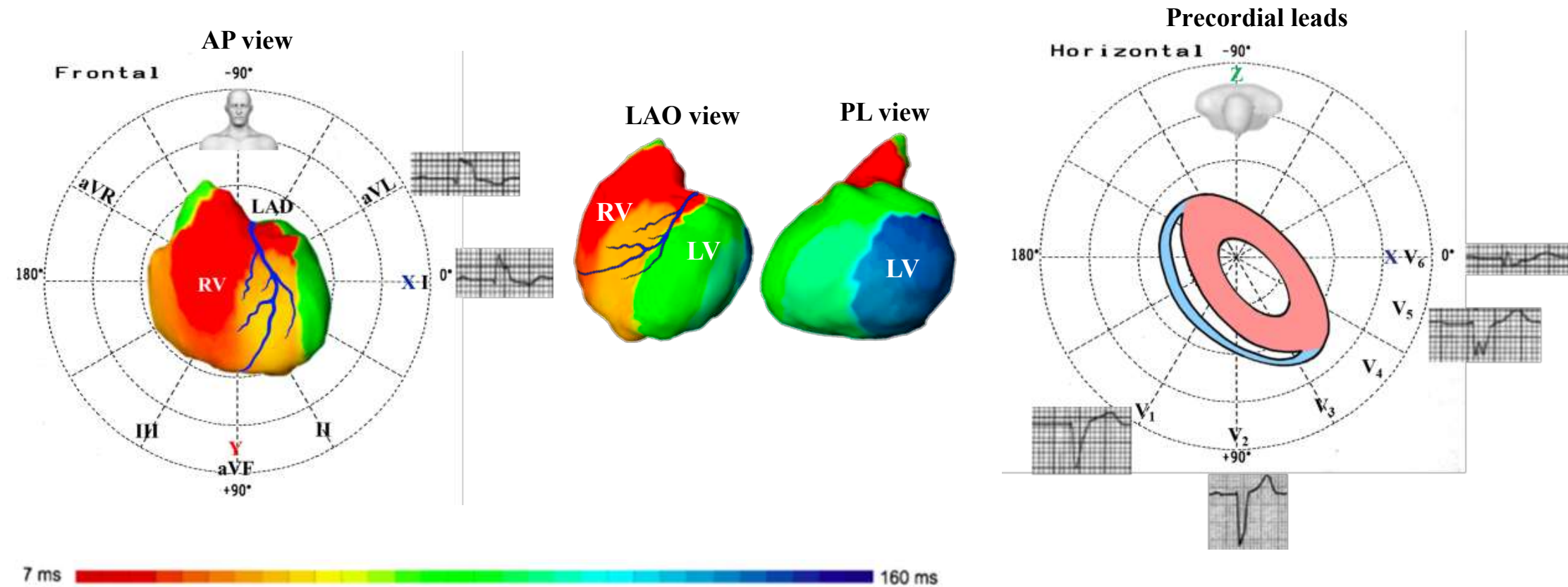
Normal QRS width, abnormal Q waves in aVL with strain pattern of repolarization in left leads I, aVL, V5, and V6: LVH

B. ECG-2004



ECG performed in 2004: The QRS complexes are splitting into two components. The first one inferiorly directed in the frontal plane and corresponds to depolarization of the right ventricle, which is not opposed by vectors of the LV due to LBBB, and shows a huge R wave in the right anterior lead V1 and in the right and inferior lead III. The second one with a slight left axis deviation corresponds to the pathological depolarization of the left ventricle. **Conclusion:** Very unusual form of LBBB

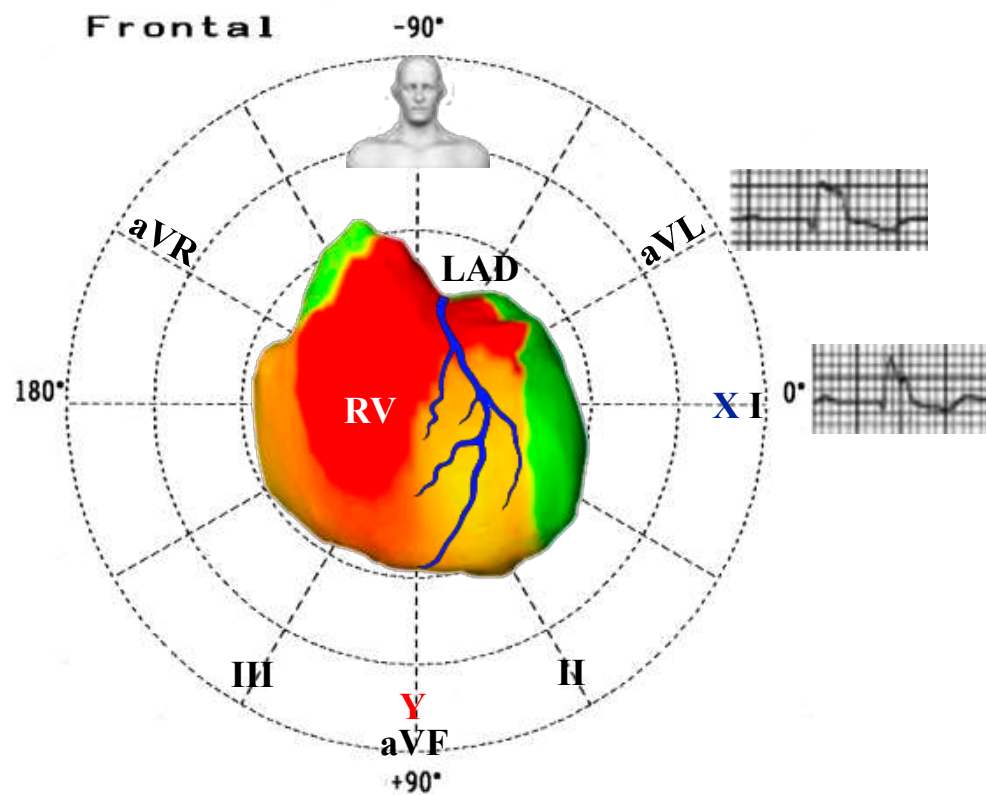
Epicardial ventricular surfaces of both ventricles are displayed in 3 views: anteroposterior (AP), left anterior oblique (LAO), posterolateral (PL) and precordial leads (HP)



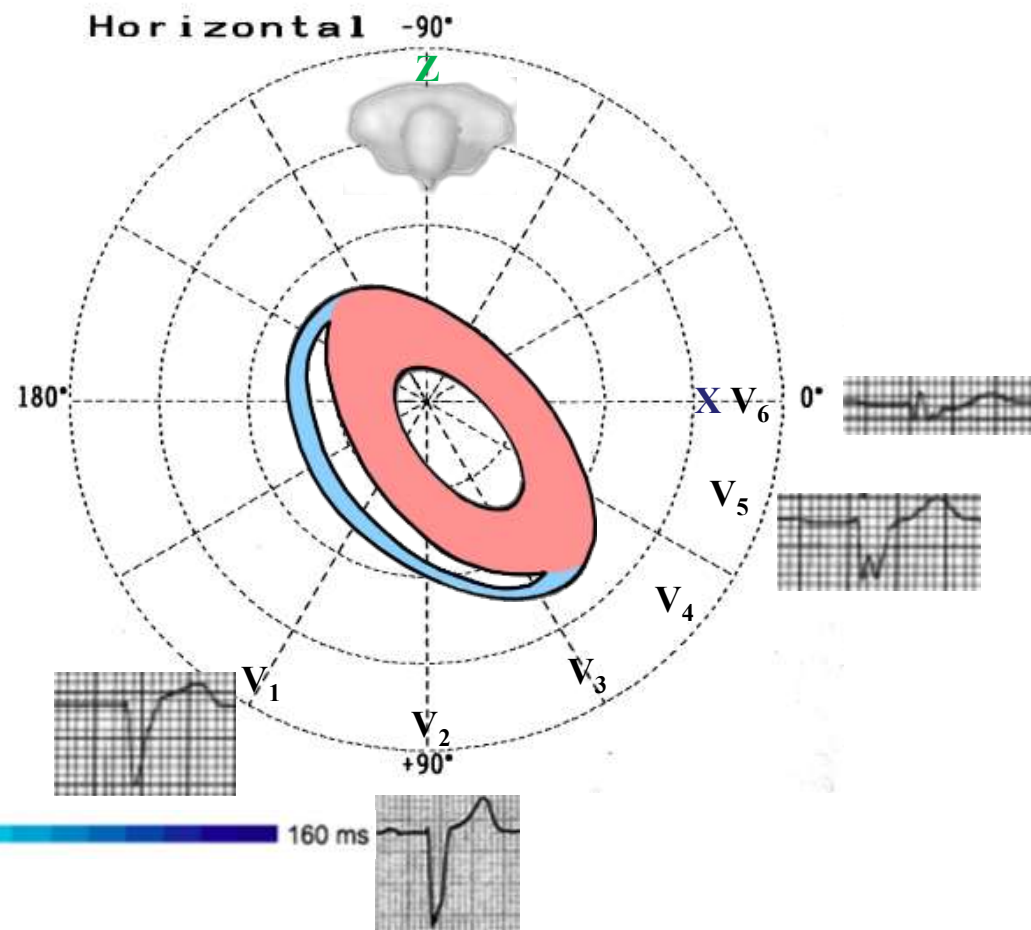
Ventricular electrical uncoupling (VEU) = 62 ms

Clinical: 60-year-old man with nonischemic cardiomyopathy. LVEF = 34%. Patient responder to CRT.

ECG: QRSd = 160 ms, NICD pattern (atypical LBBB). qR in I, embryonic rS with notch in V5 and qrs pattern in V6 against the diagnosis of LBBB. RV lateral breakthrough is followed by rapid activation of the RV. The wave front spreads to the LV. with a first base-to-apex line of slow conduction (crowding of isochrones). The final activation of the LV is laterobasal.



7 ms 160 ms

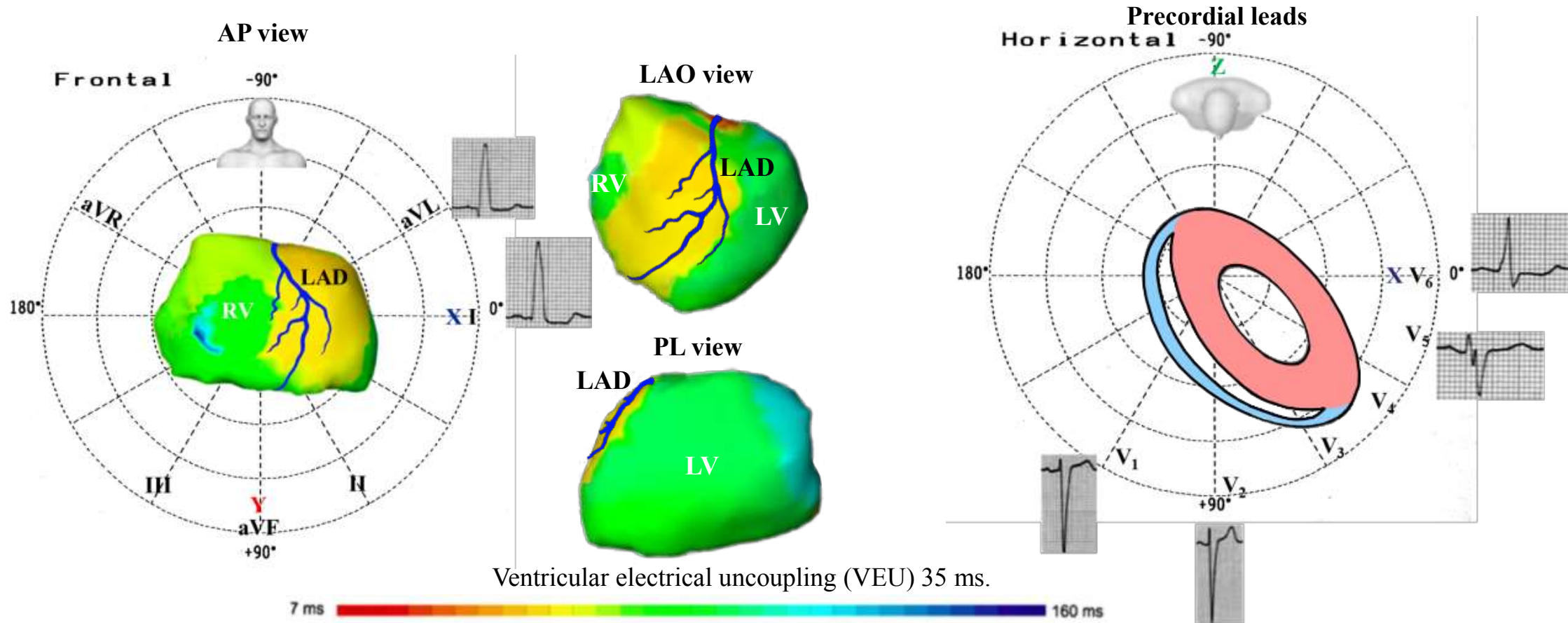


8. Intraventricular parietal blocks intraventricular conduction disturbances

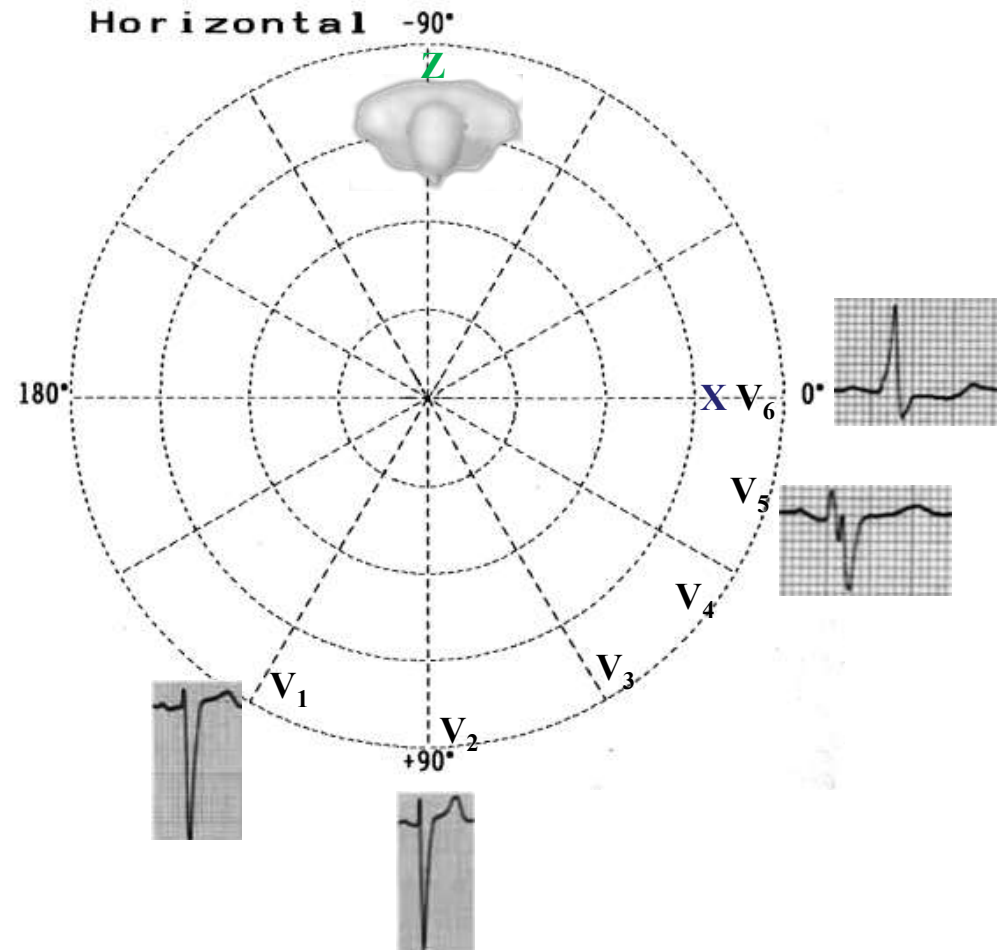
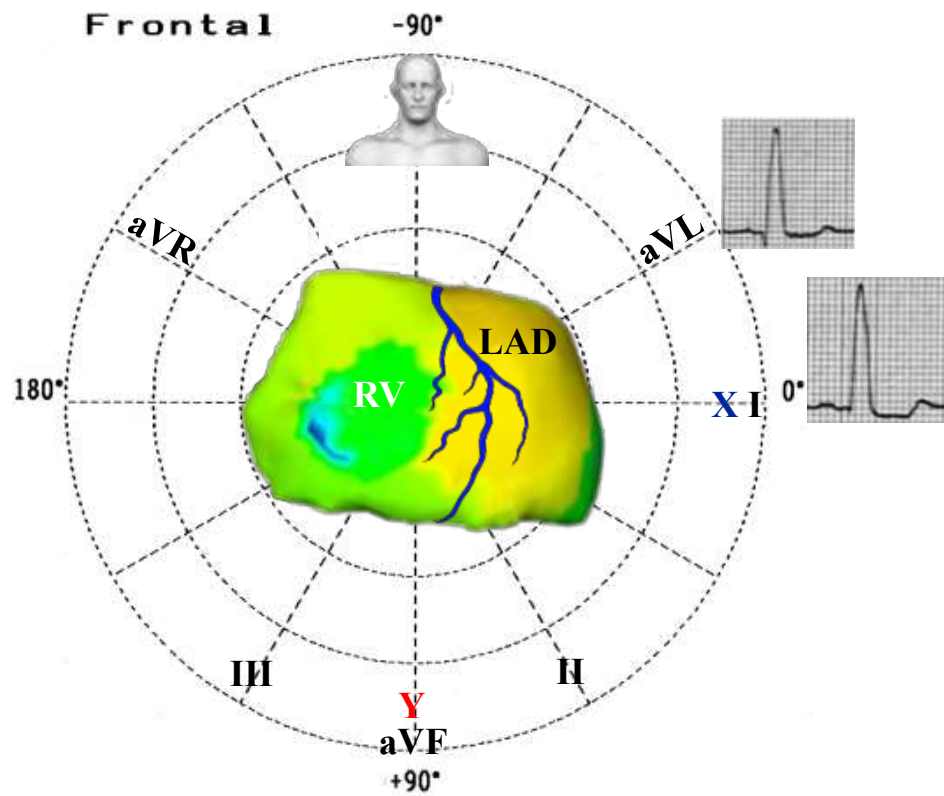
These are divided into three groups:

- a) The proximal type corresponding to block impulses in the main trunk of one intraventricular specific system(RBBB or LBBB);
- b) Distal or peripheral type, due to a block in the fascicles of the LBBB or RBBB (fascicular blocks) These cause a segmentary delay of the activation phenomenon of ipsilateral ventricular myocardium. This is revealed by slurred R waves and prolonged R-wave peak time of only in those leads which explore the affected region. In left anterior fascicular block (LAFB), the R-peak time in lead aVL is prolonged (>45 ms), while is normal in V6. (de la Iglesia 1977) In LPFB the R-peak time in leads aVF or V6 > aVL by early initial activation of the high lateral leads (aVL and I) related to the low leads such as aVF and V6. (Rusconi 1980). In left septal fascicular block (LSFB), the R peak time is prolonged in the right precordial leads V1–V3. 3 (>35 ms).(Pérez Riera 2011)
- c) Regional myocardial alterations (parietal) : conduction disturbance affected site is located beyond the fascicles of the bundle branch (Figure next slide). These may include the Purkinje fiber network or the pathologic myocardium (eg, hypertrophy, fibrosis) of the ventricular wall. This intraventricular conduction disorder can be observed in various cardiomyopathies and occurs in the presence of a preserved proximal conduction system (His bundle plus branches and fascicles). A significant LVH can be accompanied by prolongation of the QRS without any major modification of the ECG complex with the exception of an increase in voltage corresponding to hypertrophy. The prolongation of the QRS can be linked to the increase in LV myocardial mass to be depolarized but also to an intramyocardial conduction disturbance linked to modification in myofibrillar organization and possibly increased myocardial fibrosis. The experimental reproduction of this type of conduction disorder is more difficult than that of a specific and isolated section of one of the conduction pathways and involves many processes that, for many investigators, depart from human pathophysiological processes, thereby resulting in sparse animal data.(Alzamora-Castro 1953; Nosedá 1963) The explanation originally retained was that NICD “applies to any pattern of intraventricular conduction disturbance that cannot be ascribed to block in a specific portion (bundle branches or fascicles) of the specialized conduction system.” (Willems 1985)

Activation maps of a clinical nonresponder to CRT with ECG showing NICD. Epicardial ventricular surfaces of both ventricles are displayed in anteroposterior (AP), left anterior oblique (LAO), posterolateral (PL) views, and right and left precordial leads



Clinical: 58-year-old woman carrier of a post-hypertensive dilated cardiomyopathy (LVEF = 35%). **ECG:** QRSd = 166 ms, qR pattern in lead I, absence of a broad notched R wave and large S waves in V5-V6 are against the diagnosis of LBBB. There is a basal septal breakthrough with an eccentric activation followed by a heterogeneous and abnormally slow activation of the RV with a delayed activated midlateral area. LV activation is slowed by an incomplete anterolateral line of slow conduction. The latest site of activation is the basal lateral wall of the LV.



Prognosis of Nonspecific intraventricular conduction delay

The presence of a nonspecific block is a poor prognostic factor in patients with or without heart disease and is associated with an increased risk of death. A wide underlying QRS complex more than doubles the cardiac mortality compared with a narrow QRS complex. (Kashani 2005) A prolonged QRS duration appears common in patients with reduced LVEF who are hospitalized for heart failure and is an independent predictor of high postdischarge morbidity and mortality.(Wang 2008; Zimetbaum 2004; Bongioanni 2007)

In the Coronary Heart Disease Study, (Zimetbaum2004) which consisted of 10,899 subjects in the Finnish social security system (Finnish Social Insurance Institution) who had undergone clinical baseline ECG examinations between 1966 and 1972, compared with subjects without NICD (all patients including LBBB and RBBB), those with NICD (0.6% of the total population, 45.6% of subjects with QRS duration ≥ 110 ms) but no evidence of cardiac disease had an increased risk of death (relative risk [RR] 1.75, 95% confidence interval [CI] 1.27–2.40, $P = .002$), an elevated risk of death of cardiac causes (RR 1.87, 95% CI 1.08–3.25, $P = .04$), and a high risk of death attributable to arrhythmia (RR 2.90, 95% CI 1.49–5.63, $P = .007$). For patients with coronary artery disease plus reduced LV systolic function and nonsustained ventricular tachycardia, QRS prolongation resulting from LBBB or NICD has also been associated with a 50% increase in the risk of both arrhythmic and total mortality.(Zimetbaum 2004.)

Effects of cardiac resynchronization therapy with NICD and relative percental distribution of LBBB, RBBB and NICD

- I. **MIRACLE study (Aranda 2004):** The Multicenter InSync Randomized Clinical Evaluation (MIRACLE) investigators assessed the efficacy of CRT in patients with CHF with QRS durations ≥ 130 ms. This study had 81% LBBB, 10% RBBB, and 9% NICD. The authors found that CRT lead to improvement in several measures of functional capacity and exercise tolerance. Patients with CHF with RBBB and IVCD do benefit from CRT. Improvement with CRT in patients with RBBB may be due to concomitant left-sided conduction abnormalities. Further subgroup analyses of other CRT trials are necessary to validate these results. In patients with NICD there is no improvement in 6-minute walking test.
- II. **CARE-HF study (Gervais 2009)** cardiac resynchronization therapy (CRT): This study had: 95% of LBBB, 4% of RBBB, and 1% of NICD. lowered morbidity and mortality in patients with moderate to severe HF. The authors examined whether baseline and follow-up ECG characteristics might predict long-term outcome. They randomly assigned 409 patients to medical therapy (MT) plus CRT, and 404 patients to MT alone. ECG measurements were made at baseline during sinus rhythm, and at 3 months during paced or spontaneous rhythm depending on treatment assignment. Favorable outcome was defined as freedom from death, urgent transplantation, or cardiovascular hospitalization. Among patients assigned to CRT, 39% had unfavorable outcomes including 55 deaths. By single variable analysis, prolonged PR interval, left QRS axis (but not QRS duration), and LBBB at baseline, and heart rate, PR, and QRS duration at 3 months predicted unfavorable outcome. By multiple variable analysis, treatment assignment, PR, and RBBB at baseline predicted outcome, whereas baseline JTc and QRS duration at 3 months predicted all-cause mortality and HF hospitalization.
- III. **Effectiveness of CRT by QRS Morphology in the Multicenter Automatic Defibrillator Implantation Trial-Cardiac Resynchronization Therapy (MADIT-CRT study) (Zareba 2011):** This study had: 79% of LBBB, 13% of RBBB, and 17% of NICD and aimed to determine whether QRS morphology identifies patients who benefit from CRT with a CRT-D and whether it influences the risk of primary and secondary end points in patients enrolled in the MADIT-CRT trial. The authors concluded that HF patients with NYHA class I or II and $LVEF \leq 30\%$ and LBBB derive substantial clinical benefit from CRT-D: a reduction in HF progression and a reduction in the risk of VT events. No clinical benefit was observed in patients with RBBB or NICD.

IV. The Resynchronization/Defibrillation for Ambulatory Heart Failure Trial (RAFT) study (Tang 2008): This study had: 79% of LBBB, 11% of RBBB, and 10% of NICD. This trial show that adding CRT to ICD therapy improves survival in patients with moderate HF symptoms, a wide QRS complex, and LV systolic dysfunction. RAFT demonstrated that in people with fewer symptoms of HF, this therapy also helped to prevent them from developing further HF symptoms or going into the hospital because of HF and also improved their longevity. Many of these people are just getting an ICD . . . because that's the proven therapy, and RAFT proved that many of these people probably should now at least be given the option of CRT. Inclusion Criteria: NYHA) Class II, LVEF \leq 30% by multigated acquisition scan (MUGA)/catheterization or LVEF \leq 30% and LV end diastolic dimension \geq 60 mm (by echocardiogram) within 6 months prior to randomization, QRSd \geq 120 ms or paced QRS measurement \geq 200 ms, ICD indication for primary or secondary prevention, optimal HF pharmacological therapy, normal sinus rhythm; or chronic persistent atrial tachyarrhythmia with resting ventricular HR \leq 60 bpm and 6 minute hall walk ventricular HR of \leq 90 bpm; OR chronic persistent atrial tachyarrhythmia with resting ventricular HR $>$ 60 bpm and 6 minute hall walk ventricular HR of $>$ 90 bpm and booked for atrioventricular junction ablation.

V. The Resynchronization Reverses Remodeling in Systolic LV Dysfunction (REVERSE) study (Gold 2012): This study had: 60,5% of LBBB, 10% of RBBB, and 29,5% of NICD. It was a multicenter randomized trial that studied the effect of QRSd (the mean baseline QRS duration was 151 \pm 23 ms) and morphology on CRT outcomes in mild HF. REVERSE demonstrated that only LBBB and QRS prolongation are markers of reverse remodeling and clinical benefit with CRT in mild HF.

References

1. Abriel H, Zaklyazminskaya EV. Cardiac channelopathies: genetic and molecular mechanisms. *Gene*. 2013;517(1):1–11.
2. Alzamora-Castro V, Abugattas R, Rubio C, et al. Parietal focal block: an experimental and electrocardiographic study. *Circulation*. 1953;7(1):108-15
3. Antzelevitch C, Brugada P, Borggrefe M, et al. Brugada syndrome: report of the second consensus conference. *Heart Rhythm*. 2005;2(4):429–40.
4. Aranda JM Jr, Conti JB, Johnson JW, Petersen-Stejskal S, Curtis AB. Cardiac resynchronization therapy in patients with heart failure and conduction abnormalities other than left bundle-branch block: analysis of the Multicenter InSync Randomized Clinical Evaluation (MIRACLE). *Clin Cardiol*. 2004;27(12):678-82.
5. BacharovaL, Mateasik A, Szathmary V. November–December, 2013;46(6):616–7.
6. Birnie DH, Ha A, Higginson L, et al. Impact of QRS morphology and duration on outcomes after cardiac resynchronization therapy: Results from the Resynchronization-Defibrillation for Ambulatory Heart Failure Trial (RAFT). *Circ Heart Fail*. 2013;6(6):1190-8.
7. Bongioanni S, Bianchi F, Migliardi A, et al. Relation of QRS duration to mortality in a community-based cohort with hypertrophic cardiomyopathy. *Am J Cardiol* 2007;100(3):503-6.
8. Bonner RE, Caceres CA, Cuddy TE, et al. Recommendations for ECG diagnostic coding. Prepared by Working Group 'Diagnostic Codes'. *Eur J Cardiol*. 1978;8(2):173-6.
9. Brugada P, Brugada J. Right bundle branch block, persistent ST segment elevation and sudden cardiac death: a distinct clinical and electrocardiographic syndrome. A multicenter report. *J Am Coll Cardiol*. 1992;20(6):1391–96.
10. Castle CH, Keane WM. Electrocardiographic "peri-infarction block". A clinical and pathologic correlation. *Circulation*. 1965;31:403-8.
11. Cinca J, Mendez A, Puig T, et al; Investigators of the Spanish Heart Failure Network (REDINSCOR). Differential clinical characteristics and prognosis of intraventricular conduction defects in patients with chronic heart failure. *Eur J Heart Fail* 2013;15(8):877–84.
12. Chou TC. *Electrocardiography in Clinical Practice Adult and Pediatric*. 4th Edition. pg: 512, 1996.
13. de la Iglesia Huerta A. Left and anterior hemiblocks and intrinsicoid deflection in aVL: Their occurrence among the working population. *Rev Clin Esp* 1977;144(1):27–32 .
14. Elizari MV, Baranchuk A, Chiaie PA. Masquerading bundle branch block: A variety of right bundle branch block with left anterior fascicular block. *Expert Rev Cardiovasc Ther* 2013;11(1):69–75.

15. Emslie-Smith D, Sladden GE, Stirling GR. The significance of changes in the electrocardiogram in hypothermia. *Br Heart J*. 1959;21:343-51.
16. Eschaliier R, Ploux S, Ritter P, et al. Nonspecific intraventricular conduction delay: Definitions, prognosis, and implications for cardiac resynchronization therapy. *Heart Rhythm*. 2015;12(5):1071-9.
17. First SR, Bayley RH, Bedford DR. Peri-infarction block; electrocardiographic abnormality occasionally resembling bundle branch block and local ventricular block of other types. *Circulation*. 1950;2(1):31-6.
18. Flowers NC, Horan LG, Wylds AC, et al. Relation of peri-infarction block to ventricular late potentials in patients with inferior wall myocardial infarction. *Am J Cardiol*. 1990;66(5):568-74.
19. Gebauer CM, Knuepfer M, Robel-Tillig E, Pulzer F, Vogtmann C. Hemodynamics among neonates with hypoxic-ischemic encephalopathy during whole-body hypothermia and passive rewarming. *Pediatrics*. 2006;117(3):843-50.
20. Gervais R, Leclercq C, Shankar A, et al. Surface electrocardiogram to predict outcome in candidates for cardiac resynchronization therapy: a sub-analysis of the CARE-HF trial. *Eur J Heart Fail*. 2009;11(7):699-705.
21. Gold MR, Thébault C, Linde C, et al. Effect of QRS duration and morphology on cardiac resynchronization therapy outcomes in mild heart failure: results from the Resynchronization Reverses Remodeling in Systolic Left Ventricular Dysfunction (REVERSE) study. *Circulation*. 2012;126(7):822-9.
22. Grant RP, Murray RH. The QRS complex deformity of myocardial infarction in the human subject. *Am J Med*. 1954;17(5):587-609.
23. Haataja P, Nikus K, Kähönen M, et al. Prevalence of ventricular conduction blocks in the resting electrocardiogram in a general population: the Health 2000 Survey. *Int J Cardiol*. 2013;167(5):1953-60.
24. Heissenbuttel RH, Bigger JT Jr. The effect of oral quinidine on intraventricular conduction in man: correlation of plasma quinidine with changes in QRS duration. *Am Heart J*. 1970;80(4):453-62.
25. Jastrzebski M, Kukla P, Baranchuk A, Czarnecka D. Right ventricular tombstoning as a Brugada phenocopy. *Int J Cardiol*. 2015;199:213-4.
26. Josephson ME, Seides SF, Batsford WP, et al. The electrophysiological effects of intramuscular quinidine on the atrioventricular conducting system in man. *Am Heart J*. 1974;87(1):55-64.
27. Kashani A, Barold SS. Significance of QRS complex duration in patients with heart failure. *J Am Coll Cardiol*. 2005;46(12):2183-92.
28. Monin J, Biscoste S, Nicaise A, Hornez AP, Manen O, Perrier E. Prevalence of Intraventricular Conduction Disturbances in a Large French Population. *Ann Noninvasive Electrocardiol*. 2016; 21(5):479-85.
29. Nosedá V, Santi A, Aguggini G, Filotto U, Bergamaschi M. Experimental focal block in the sheep and the dog. An electrocardiographic and histological study. *Cardiologia*. 1963;42:243-55.

30. Okada M. The cardiac rhythm in accidental hypothermia. *J Electrocardiol.* 1984;17(2):123-8.
31. Patel A, Getsos J. Images in clinical medicine. Osborn waves of hypothermia. *N Engl J Med.* 1994;330(10):680
32. Pérez Riera AR, Ferreira C, Ferreira Filho C, et al. Electrovectorcardiographic diagnosis of left septal fascicular block: Anatomic and clinical considerations. *Ann Noninvasive Electrocardiol* 2011;16(2):196–207.
33. Rankovic V, Patel N, Jain S, Robinson N, Goldberger J, Horvath G, Kadish A. Characteristics of ischemic and peri-ischemic regions during ventricular fibrillation in the canine heart. *J Cardiovasc Electrophysiol.* 1999;10(8):1090-100.
34. Reuler JB. Hypothermia: pathophysiology, clinical settings, and management. *Ann Intern Med.* 1978;89(4):519-27.
35. Robles de Medina EO, Bernard R, Coumel P, et al. Definition of terms related to cardiac rhythm. WHO/ISFC Task Force. *Eur J Cardiol.* 1978;8(2):127-44.
36. Rusconi L, Nava A, Sermasi S, et al. The left posterior fascicular block: Is the diagnosis possible only by ECG? *G Ital Cardiol* 1980;10(9):1129–34.
37. Sandhu R, Bahler RC. Prevalence of QRS prolongation in a community hospital cohort of patients with heart failure and its relation to left ventricular systolic dysfunction. *Am J Cardiol* 2004; 15;93(2):244-6.
38. Santolin CJ, Mukerji V, Alpert MA, Graham BM. Signal-averaged electrocardiographic detection of terminal QRS deflection suggesting late potentials. *South Med J.* 1991;84(11):1402-4.
39. Selga E, Campuzano O, Pinsach-Abuin ML, et al. Comprehensive genetic characterization of a Spanish Brugada syndrome cohort. *PLoS One.* 2015;10:e0132888
40. Surawicz B, Orr CM, Hermiller JB, Bell KD, Pinto RP. QRS changes during percutaneous transluminal coronary angioplasty and their possible mechanisms. *J Am Coll Cardiol.* 1997;30(2):452-8.
41. Surawicz B. Reversible QRS changes during acute myocardial ischemia. *J Electrocardiol.* 1998;31(3):209-20.
42. Surawicz B, Childers R, Deal BJ, et al; American Heart Association Electrocardiography and Arrhythmias Committee, Council on Clinical Cardiology; American College of Cardiology Foundation; Heart Rhythm Society. AHA/ACCF/HRS recommendations for the standardization and interpretation of the electrocardiogram: part III: intraventricular conduction disturbances: a scientific statement from the American Heart Association Electrocardiography and Arrhythmias Committee, Council on Clinical Cardiology; the American College of Cardiology Foundation; and the Heart Rhythm Society: endorsed by the International Society for Computerized Electrocardiology. *Circulation.* 2009;119(10):e235-40.

43. Surawicz B. In: Electrophysiologic Basis of ECG and Cardiac Arrhythmias. 1995; Chapter 25 pp: 507-534. Abnormal Depolarization: Intraventricular Conduction Disturbances. Williams & Wilkins.
44. Tang AS, Wells GA, Arnold M, et al. Resynchronization/defibrillation for ambulatory heart failure trial: rationale and trial design. *Curr Opin Cardiol*. 2009;24(1):1– 8.
45. Wang NC, Maggioni AP, Konstam MA, Efficacy of Vasopressin Antagonism in Heart Failure Outcome Study With Tolvaptan (EVEREST) Investigators, et al. Clinical implications of QRS duration in patients hospitalized with worsening heart failure and reduced left ventricular ejection fraction. *JAMA*. 2008;299(22):2656-66.
46. Wilensky RL, Yudelman P, Cohen AI, et al. Serial electrocardiographic changes in idiopathic dilated cardiomyopathy confirmed at necropsy. *Am J Cardiol*. 1988;62(4):276-83.
47. Willems JL, Robles de Medina EO, Bernard R, et al. Criteria for intraventricular conduction disturbances and pre-excitation. World Health Organizational/International Society and Federation for Cardiology Task Force Ad Hoc. 1985 ;5(6):1261-75.
48. Zareba W, Klein H, Cygankiewicz I, et al. Effectiveness of Cardiac Resynchronization Therapy by QRS Morphology in the Multicenter Automatic Defibrillator Implantation Trial-Cardiac Resynchronization Therapy (MADIT-CRT). *Circulation*. 2011;123(10):1061-72.
49. Zimetbaum PJ, Buxton AE, Batsford W, et al. Electrocardiographic predictors of arrhythmic death and total mortality in the Multicenter Unsustained Tachycardia Trial. *Circulation* 110(7):766-9.