

**Syncope episodes in old woman
Pseudo-epilepsy picture**

**Case of Dr Raimundo Barbosa Barros MD Fortaleza –Ceará-
Brazil**

Dear Andrés: acredite. Esta senhora idosa (81 anos) estava sendo tratada pelo neurologista com diagnóstico de "epilepsia", em uso de hidantal (difenilhidantoína). As crises "epilépticas" cederam após implante de MP definitivo.

Qual é o diagnóstico eletrocardiográfico.

Um abraço

Raimundo Barbosa Barros Fortaleza-Ceará Brasil

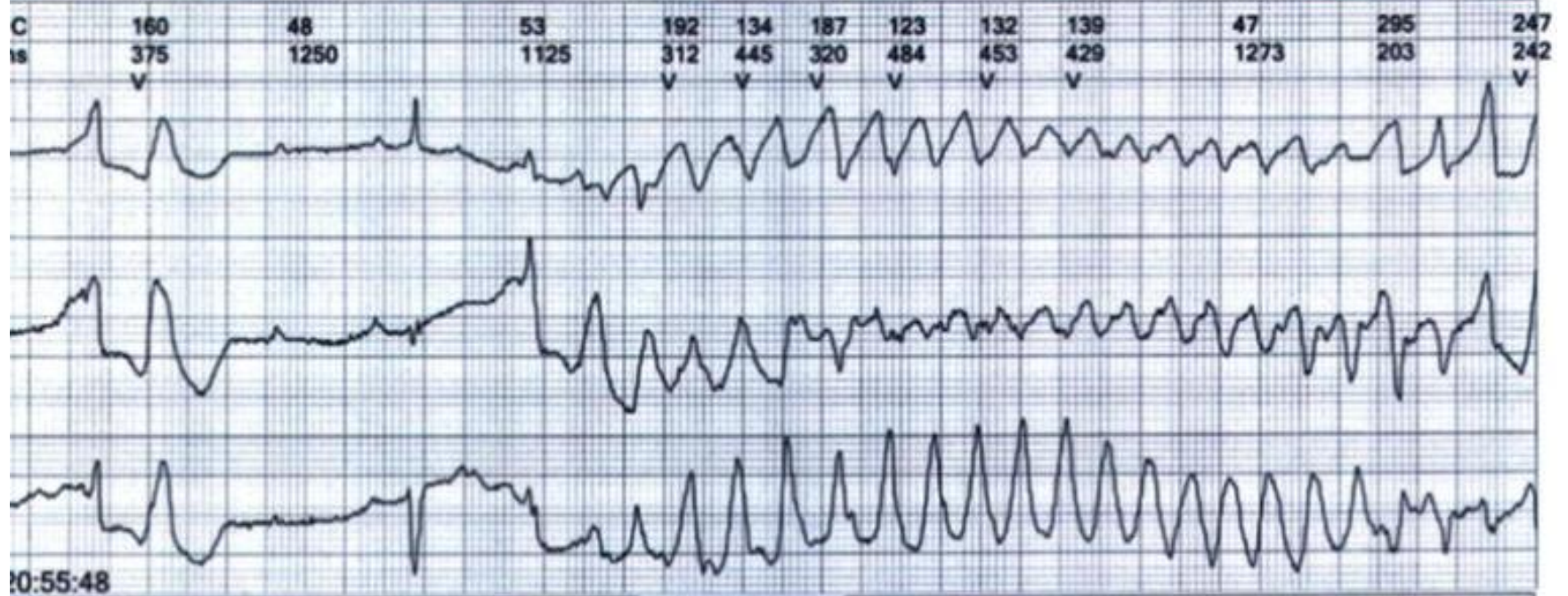
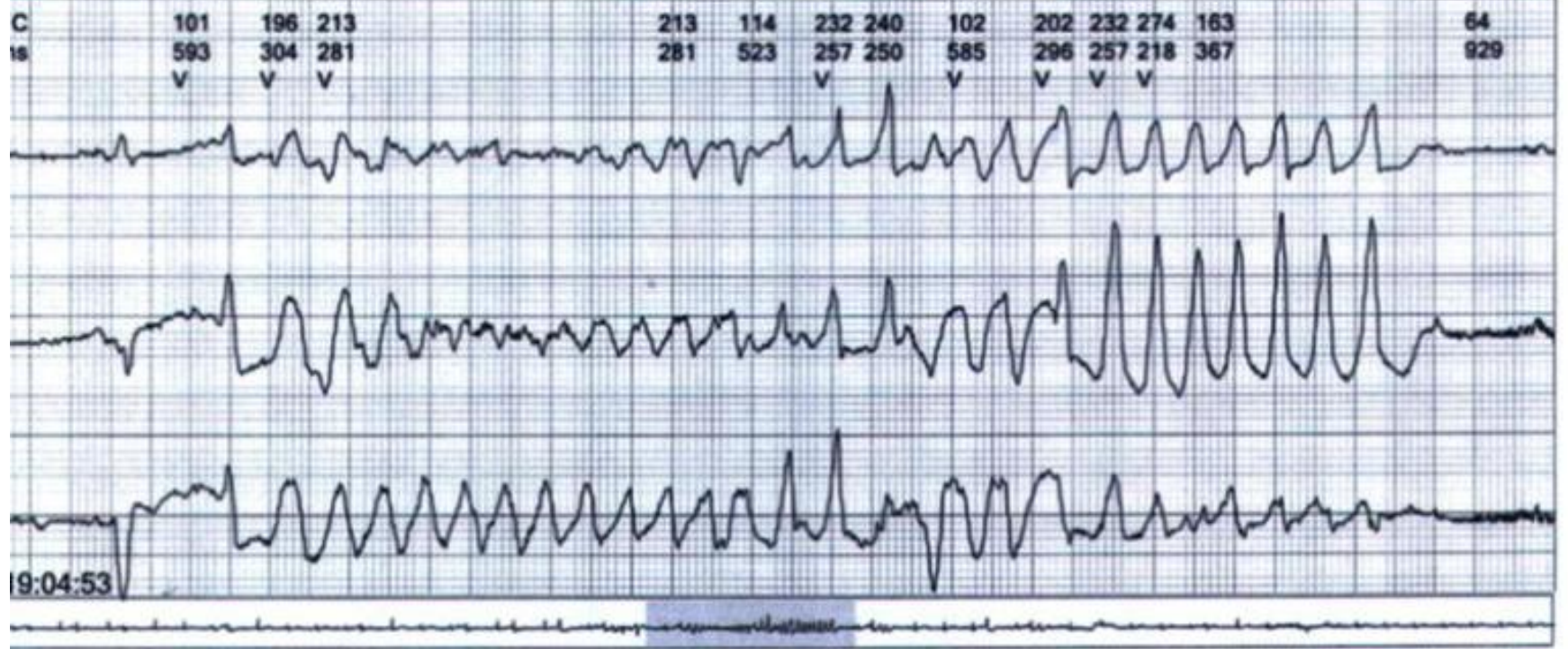
Dear Andrés: .This senior lady (81 years old) was being treated by the neurologist with "epilepsy diagnosis".

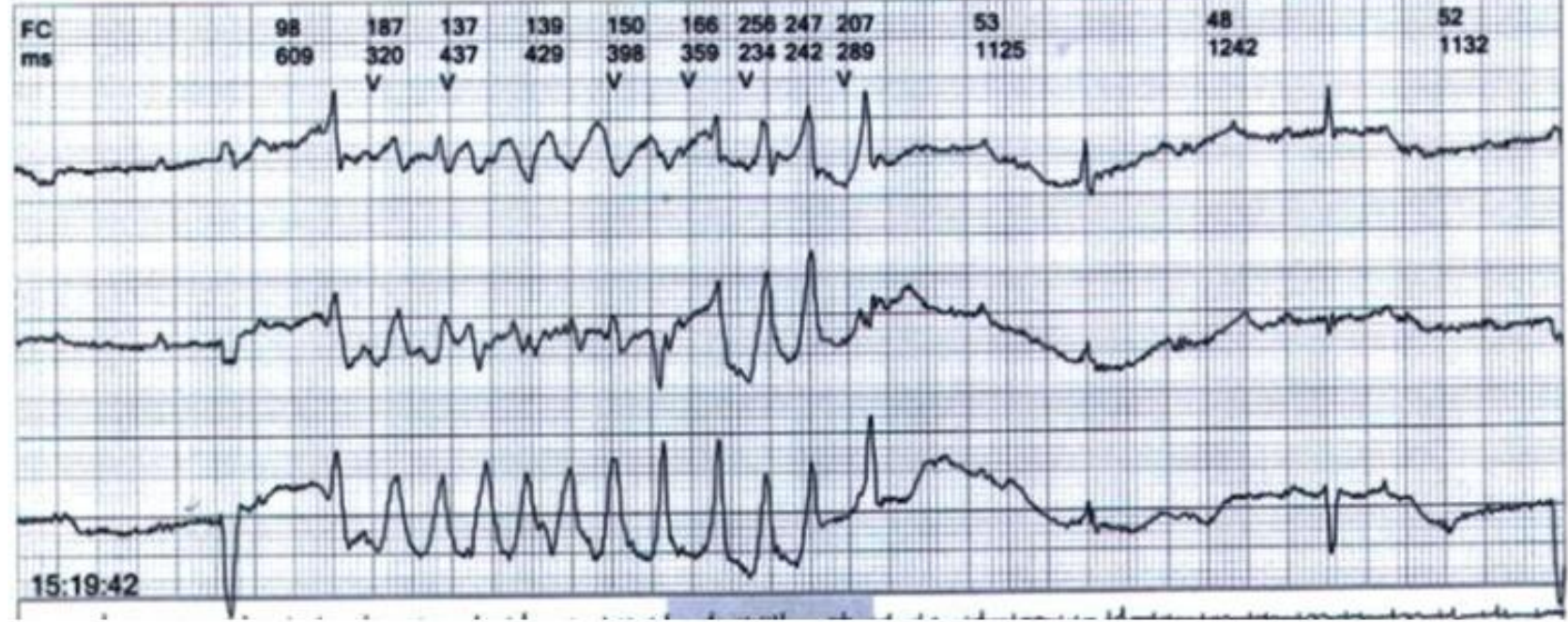
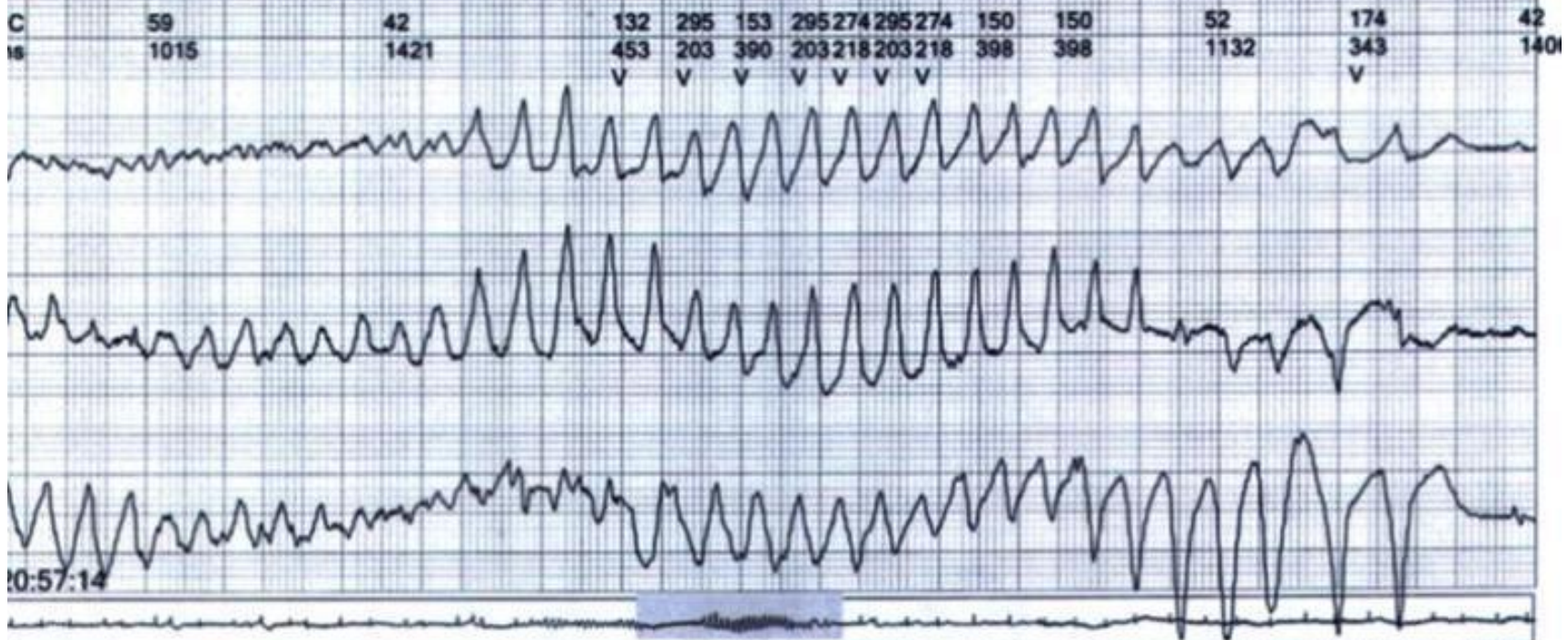
In regular use of hidantal (difenilhidantoína).

The "epileptic" crises gave way after implant of definitive cardiac pacemaker. What is the electrocardiographic diagnosis?

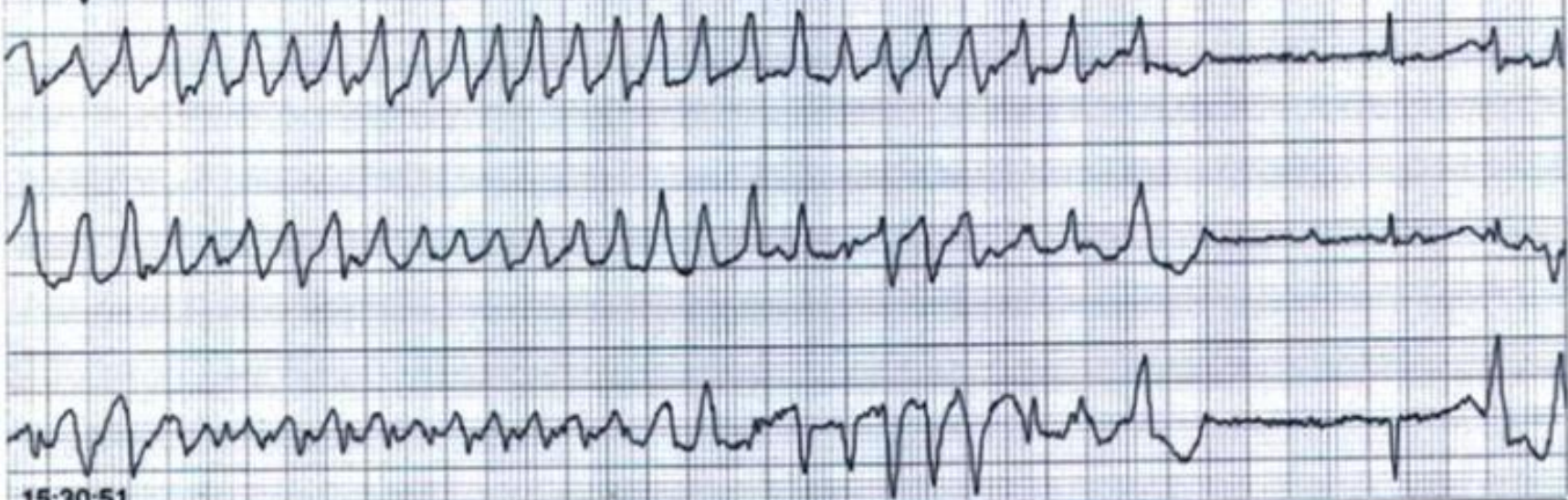
A hug

Raimundo Barbosa Barros Fortaleza Ceará. Brazil



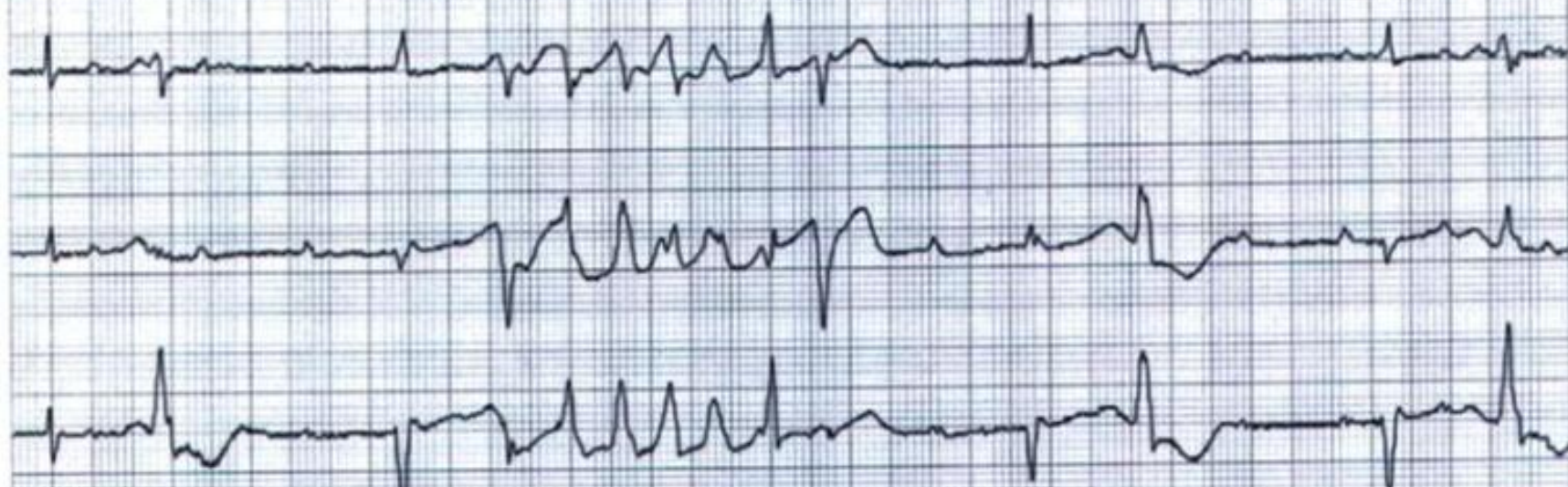


FC	121	256	70	96	274	219	284	142	114	170	49	105	37
ms	492	234	851	625	218	273	210	421	523	351	1218	570	1585
	V				V	V	V						

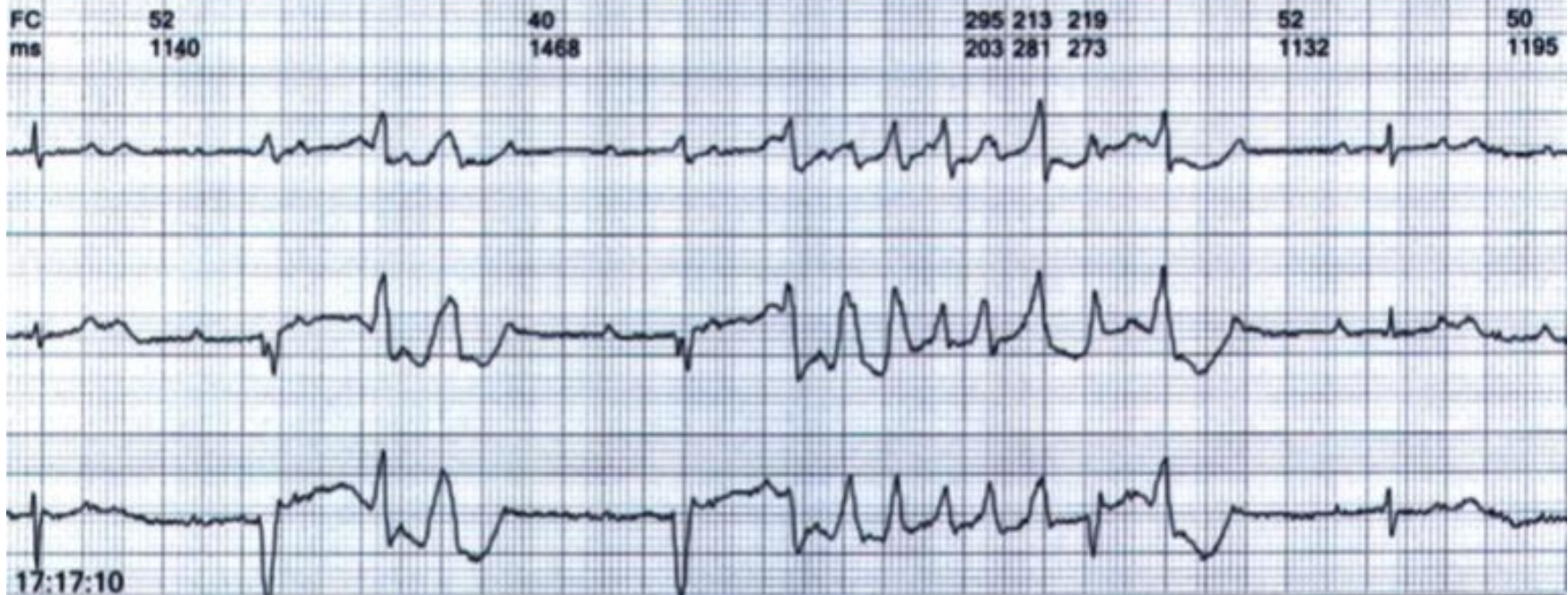
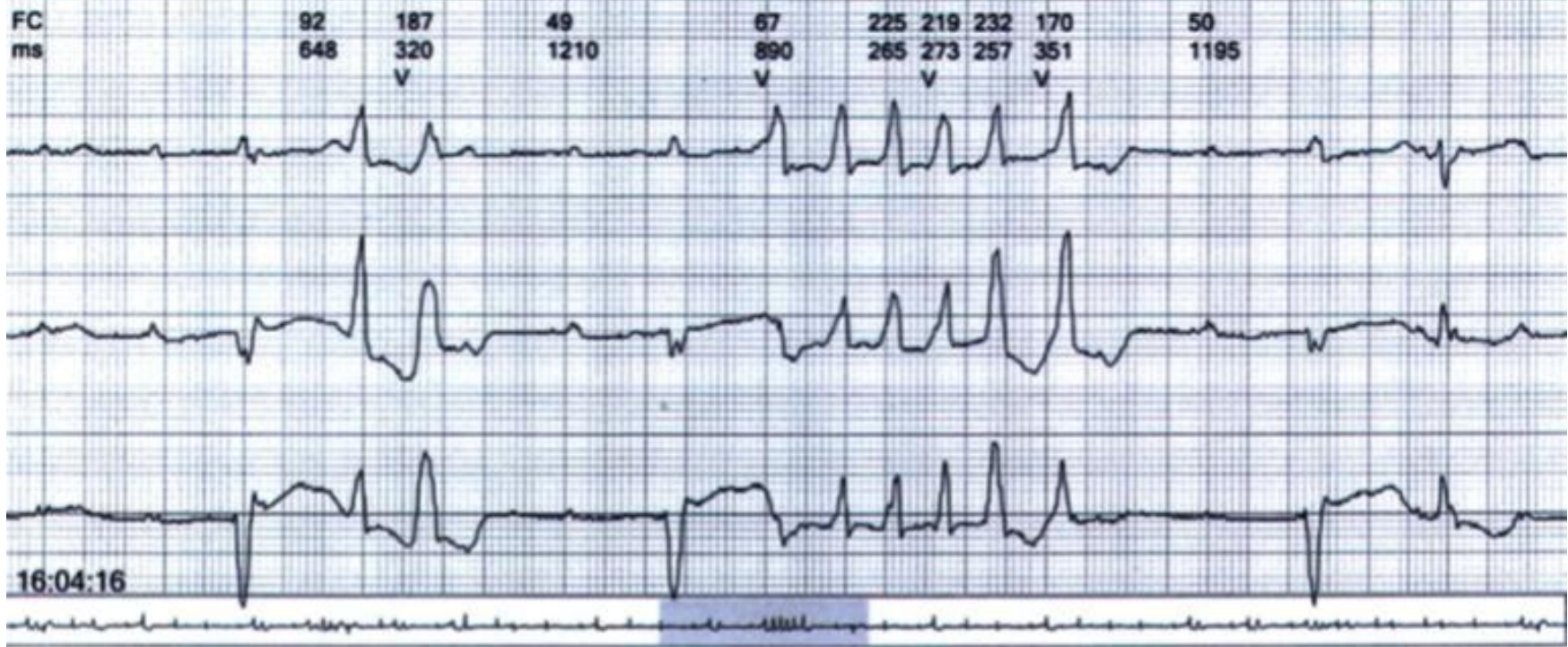


15:30:51

FC	105	48	56	256	54	106	47
ms	570	1250	1070	234	1093	562	1257
				V			



16:01:46



FC
ms

54
1109

202
296
V

51
1164

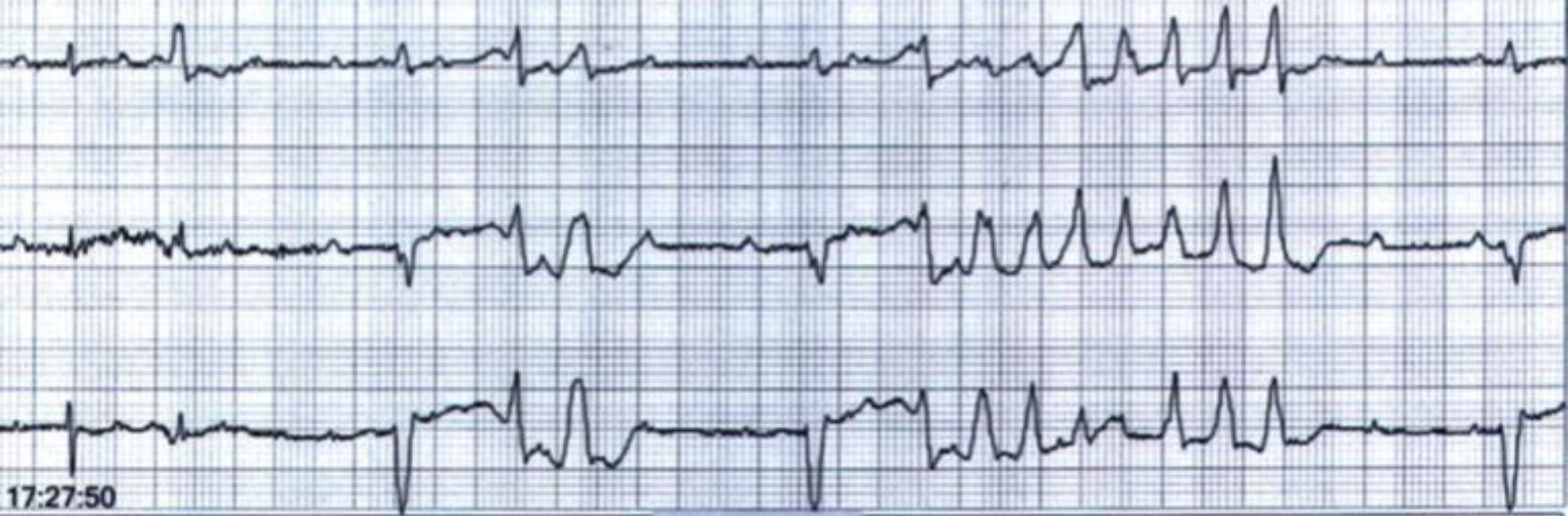
101
593
V

109
546
V

256
234

240
250
V

52
1148



17:27:50

Estimado Andrés

El trazado ECG muestra los siguientes câmbios:

- 1. Bloqueo AV completo**
- 2. Intervalo QT prolongado secundário**
- 3. Torsade de pontes.**

Gracias por compartir este fantástico trazado.

Li

Zhang, Li MD

ldlzhang@gmail.com

Director, Cardiovascular Outcomes Research- Main Line Health Heart Center

Lankenau Hospital- Associate Professor

Lankenau Institute for Medical Research- 558 MOB East- 100 Lancaster Avenue

Wynnewood, PA 19096- U.S.A. Tel: 610-645-2694 Cell: 484-222-1876

Dear Andres,

The ECG tracings show major changes of following:

- 1. Complete AVB**
- 2. Prolonged QT interval (secondary to complete AVB)**
- 3. TdP**

This patient had recurrent syncope due to TdP.

Thanks much for sharing those fantastic tracings,

Li

Querido Prof Andrés

Diagnóstico

Torsades de Pointes recurrentes

**Factores de riesgo para TdP: Género femenino y bradiarritmia
consecuencia del bloqueo AV completo**

Dear Prof. Andres Ricardo Pérez Riera

Diagnosis :

Recurrent torsade de pointes

Risk factor for TdP:

- 1. Female sex**
- 2. Bradycardia due to 3 degree -AV block**

All the best

Piotr Kukla From Poland M.D. PhD.

This is a nice case of CAVB complicated by recurrent TdP. There is an excellent paper about this issue in JACC 2007, taking especially about the QT, QTc duration and the morphology of the QT interval notched T wave. Please see below:

Topilski I, Rogowski O, Rosso R, Justo D, Copperman Y, Glikson M, Belhassen B, et al. The morphology of the QT interval predicts torsade de pointes during acquired bradyarrhythmias. J Am Coll Cardiol. 2007 Jan 23;49:320-328.

Abstract: OBJECTIVES: The purpose of this study was to define the ECG predictors of TdP during acquired bradyarrhythmias. BACKGROUND: CAVB might lead to downregulation of potassium channels, QT interval prolongation, and TdP. Because potassium-channel malfunction causes characteristic T-wave abnormalities in the congenital LQTS, we reasoned that T-wave abnormalities like those described in the congenital LQTS would identify patients at risk for TdP during acquired bradyarrhythmias. METHODS: In a case-control study, we compared 30 cases of bradyarrhythmias complicated by TdP with 113 cases of uncomplicated bradyarrhythmias. On the basis of the criteria used for the congenital LQTS, T waves were defined as LQT1-like (long QT interval with broad T waves), LQT2-like (notched T waves), and LQT3-like (small and late) T waves.

RESULTS: Neither the ventricular rate nor the QRS width at the time of worst bradyarrhythmia predicted the risk of TdP. However, the QT, corrected QT (QTc), and T(peak)-T(end) intervals correlated with the risk of TdP. The best single discriminator was a T(peak)-T(end) of 117 ms. LQT1-like and LQT3-like morphologies were rare during bradyarrhythmias. In contrast, LQT2-like "notched T waves" were observed in 55% of patients with TdP but in only 3% of patients with uncomplicated bradyarrhythmias ($p < 0.001$). A 2-step model based on QT duration and the presence of LQT2-like T waves identified patients at risk for TdP with a positive predictive value of 84%. CONCLUSIONS: Prolonged QT interval, QTc interval, and T(peak)-T(end) correlate with increased risk for TdP during acquired bradyarrhythmias, particularly when accompanied by LQT2-like notched T waves.

Raed Abu Sham'a, M.D from Jerusalem-Palestine

Spanish

Este es un lindo caso de bloqueo AV completo complicado con TdP recurrentes. Existe un excelente manuscrito acerca de este tema publicado en el JACC en 2007 teniendo en cuenta especialmente la duración del intervalo QT, la morfología del intervalo QT y onda T con muescas. Por favor vea abajo:

Topilski I, Rogowski O, Rosso R, Justo D, Copperman Y, Glikson M, Belhassen B, et al. The morphology of the QT interval predicts torsade de pointes during acquired bradyarrhythmias. J Am Coll Cardiol. 2007 Jan 23;49:320-328.

El propósito de este estudio fue definir los predictores del ECG para TdP durante bradiarritmias adquiridas. El bloqueo AV completo podría ocasionar una disminución en la regulación de los canales de K⁺ una vez que en las formas congénitas un malfuncionamiento de estos canales de potasio lleva a anomalías de la onda T en las formas congénitas de QT prolongado. Nos pensamos que anomalías en la T como las descritas en el síndrome congénito del QT prolongado identifican pacientes con riesgo para desarrollar TdP durante las bradiarritmias adquiridas. Se trata de un estudio caso/control donde comparamos 30 casos de TdP con 113 casos de bradiarritmias sin TdP. Sobre la base de los criterios empleados para las formas congénitas donde se considera LQT1-like cuando tiene T de base ancha, LQT2-like cuando existe T con escotadura; y LQT3-like cuando el ST es largo y la T tardía. Ni la FC, ni el ancho del QRS fueron predictores sin embargo el QTc, el intervalo Tp-T-end de 117ms, y LQT1-like fueron predictores de TdP. Contrariamente un patrón LQT2-like con T presentando muescas se observó en 55% de los pacientes con TdP pero en solo 3% de los pacientes con bradiarritmia o complicada. Un segundo paso basado en la duración del QT y la presencia de LQT2-like y intervalo Tp-Te prolongado identifica pacientes en riesgo para TdP.

Raed Abu Sham'a, M.D from Jerusalem-Palestine

Pareceria que la paciente no es epileptica, sino que tiene un SQT, bradicardia-dependiente. Se aprecian ciclos corto-largo-corto gracias a su BAV avanzado y a las multiples EEV sobre onda T, que degeneran frecuentemente en TdP.

Parece ser también que el marcapasos tiene fallas de sensado de la onda R, al menos durante las salvas de TV. Quiero pensar que durante las tiras que se nos presentan esta programado a con LIF a 30 lpm, ya que no se aprecia ningun VP de escape hasta 40 lpm.

Ermengol Vallès

Ermengol Vallès

ermenvg@GMAIL.COM

I think that the patient is not epileptic. She has a LQTS bradychardic-dependent with long and short QT cycles.

Advanced AV block and several PVCs with R-on-T phenomenon are observed.

Probably the pace has flaw in sensed R waves at least during the salves of VT.

I want to think that a PACE Program on Life Support to 30bpm because we do not observe ventricular escape beats until 40bpm.

Dear Dr. Ermengol Vallès

El marcapaso fue implantado después .Este Holter que muestra episodios de TdP se realizó antes del marcapaso.

Raimundo Barbosa

Dear Dr Ermengol Vallés: the pace was implanted after this Holter record that shows these TdP episodes.

Querido Andrés y Raimundo, hermoso caso,

Bloqueo AV completo, no puedo medir bien el QT, pero ante una Torsada de pointes, seguro tiene el qt prolongado bradicardicodependiente, sumado a esto el efecto de la Difenilhidantoina, marcapasos urgente y estimulación a 90/minutos, para homogenizar la repolarización ventricular, y además controlar el perfil electrolítico, especialmente potasio y magnesio,

Abrazo

Hotdog

Dear Andrés and Raimundo: beautiful case!

Complete AV block, before the TdP. I can not to measure the QT interval, but I'm sure that this patient has bradycardia- dependent prolonged QT interval associated to *diphenylhydantoin* prolongation effect.

Management: urgent pacemaker implantation with stimulation at 90bpm with focus on homogenize ventricular depolarization. Additionally, correction of eventually electrolyte imbalance mainly potassium and magnesium.

Hug

Dr Francisco Femenia Mendoza - Argentine Republic.

Andrés Ricardo Pérez Riera M.D.
Theoretical/historical commentaries

Clinical/ECG diagnosis

- 1) **Complete AV block**
- 2) **Prolonged QT interval:** consequence of third degree-AV block, toxic phenytoin serum levels ?, feminine gender, old patient, fulminant myocarditis secondary to phenytoin toxicity¹? hypersensitivity syndrome leading to reversible myocarditis²?
- 3) **PVCs with R-on-T phenomenon**
- 4) **Long and short QT cycles.**
- 5) **Repetitive episodes Torsades de Pointes(TdP)**
- 6) **Hypersensitivity myocarditis due to phenytoin³ ?**
- 7) Gerbezius-Morgagni-Adams-Stokes syndrome.**

Cardiovascular Side Effects of Phenytoin

Cardiovascular side effects include hypotension, bradycardia, other arrhythmias and cardiac arrest consequence of **fulminant myocarditis**. These complications are most likely to occur in patients receiving parenteral phenytoin or in patients with underlying cardiovascular disease. Phenytoin has been implicated as a possible cause of myocarditis related to drug hypersensitivity.

1. Atwater BD, Ai Z, Wolff MR. Fulminant myopericarditis from phenytoin-induced systemic lupus erythematosus. *WMJ*. 2008 Sep;107(6):298-300.
2. Zaidi AN. Anticonvulsant hypersensitivity syndrome leading to reversible myocarditis. *Can J Clin Pharmacol*. 2005 Winter;12(1):e33-40.
3. Nakasu Y, Okada T, Nakasu S, Kuribayashi K, Handa J. Hypersensitivity myocarditis probably due to phenytoin *Nippon Geka Hokan*. 1988 Jan 1;57:97-101.

Why Gerbezius-Morgagni-Adams-Stokes Syndrome?

A syncope triggered by heart arrhythmia. The condition is characterized by sudden transient attacks of lightheadedness or unconsciousness, with or without convulsions, due to a temporary cessation of blood supply to the brain. Caused by complete or incomplete AV heart block due to disturbances of the conductive path of the heart. Deep and fast respiration changes to weak and slow pulse and respiration, convulsions and respiratory pauses that may last for 60 seconds. Other symptoms may be fixed pupils, incontinence, bilateral Babinski's sign with resumption of heart beats, and flushing of the face. Onset usually after 40 years of age. Occurs in diseases of the brain and the heart and is usually a serious symptom.

The Austrian physician **Marcus Gerbezius** gave the first description in 1691. According to many sources, he made the first description in 1717, but we have not been able to the bibliographic reference for this. The next description of the phenomenon was by the Italian anatomist **Giovanni Battista Morgagni** (1682-1771), who described Adams-Stokes attacks in a Padua merchant. He begins his somewhat stilted description thus: " When visiting by way of consultation, I found with such a rarity of the pulse that within the 60th part of an hour the pulsations were only 22 - and this rareness which was perpetual - was perceived to be even more considerable, as often as even two (epileptic) attacks were at hand - so that the physicians were never deceived from the increase of the rareness they foretold a paroxysm to be coming on."The Scottish physician **Thomas Spens** (1764-1842) in 1792 reported a 54 year old patient which most probably suffered from the same condition. The first more scientific and systematic description was done by **Robert Adams** in 1827, while **William Stokes**, also he Irish, described it in 1854. Gerbec reported on one of his patients: "... a melancholic, a hypochondriac, otherwise basically healthy, had such a slow pulse that the pulse of a healthy person would beat three times before his pulse would beat for a second time...he was very sluggish, frequently dizzy, and from time to time subject to mild epileptic seizures..."

References:

- Marcus Gerbezius:
Pulsus mira inconstantia.
Miscellanea curiosa, sive Ephemeridum medico-physicarum Germanicum Academiae
Caesareo-Leopoldinae Naturae, 1691, Norimbergae, 1692, 10: 115-118. The journal title is
uncertain.
First reported case of temporary cardiac arrest with syncopal attacks.
- G. B. Morgagni:
De sedibus, et causis morborum per anatomen indagatis libri quinque.
2 vols. in 1. Venetis, typ. Remondiniana 1761.
His classical descriptions of mitral stenosis and heart block in the ninth letter, volume 1, page
70. Reprinted in English translation in Willius & Keys, Cardiac Classics, 1941, pp. 177-182.
- T. Spens:
History of a case in which there took place a remarkable slowness of the pulse.
[Andrew Duncan's] Medical and Philosophical Commentaries, Edinburgh, 1792. volume 7, pp.
458-465.
- R. Adams:
Cases of Diseases of the Heart, Accompanied with Pathological Observations.
Dublin Hospital Reports, 1827, 4: 353-453.
- W. Stokes:
Observations on some cases of permanently slow pulse.
Dublin Quarterly Journal of Medical Science, 1846, 2: 73-85.
Reprinted in Medical Classics, 1939, 3: 727-738

Dr. Marcus Gerbezius(1658-1718) brief biography¹

Marcus Gerbezius was born in Slovenia (Sentvid near Stiêan not far from Ljubjana), in what was until some years ago Yugoslavia, on October 24, 1658.

Upon completing his study of philosophy at the University of Laibach (today Ljubljana), he studied medicine at the Universities in Vienna, Padua and Bologna, and graduated from Bologna in 1684. Gerbezius then commenced his medical practice in Carniola and Ljubljana.

In 1689, he became a member of the renowned German Academy of Natural Scientists in Halle (Academia Caesarea Leopoldina Carolina Naturae Curiosorum).

From the start of his members-ship in the Academy of Natural Scientists until his death in Ljubjana on March 9, 1718, Marcus Gerbezius published a great number of his medical observations in the Academy's periodonticals.

In 1717, based on extremely accurate pulse analysis Gerbezius described the symptoms of bradycardia most probably induced by complete atrioventricular AV block. However, these observations were not published until 1718 (posthumously) in the book *Constitutio Anni 1717 A. D. Marco Gerbezio Labaco 10. Decem. Descripta. Miscellanea-Ephemerides Academiae Naturae Curiosorum Cent. VII, VIII.(1718) in Appendice.*

Gerbezius´ descriptions preceded those of Morgagni by 44 years. In factm Morgagni mentions Gervezius several times in his work *De sed-indagatis* when referring to the characteristics of the pulse , symptoms,and the course of the disease in a patient with AV block. Hence, it is to suggest that Morgagni-Adams-Stokes syndrome can be known as **Gerbezius-Morgagni-Adams-Stokes syndrome**.

1. Luderitz Berndt, *History of the Disorders of Cardiac Rhythm* Third Edition. 2002. Futural Publishing Company ,Inc.