

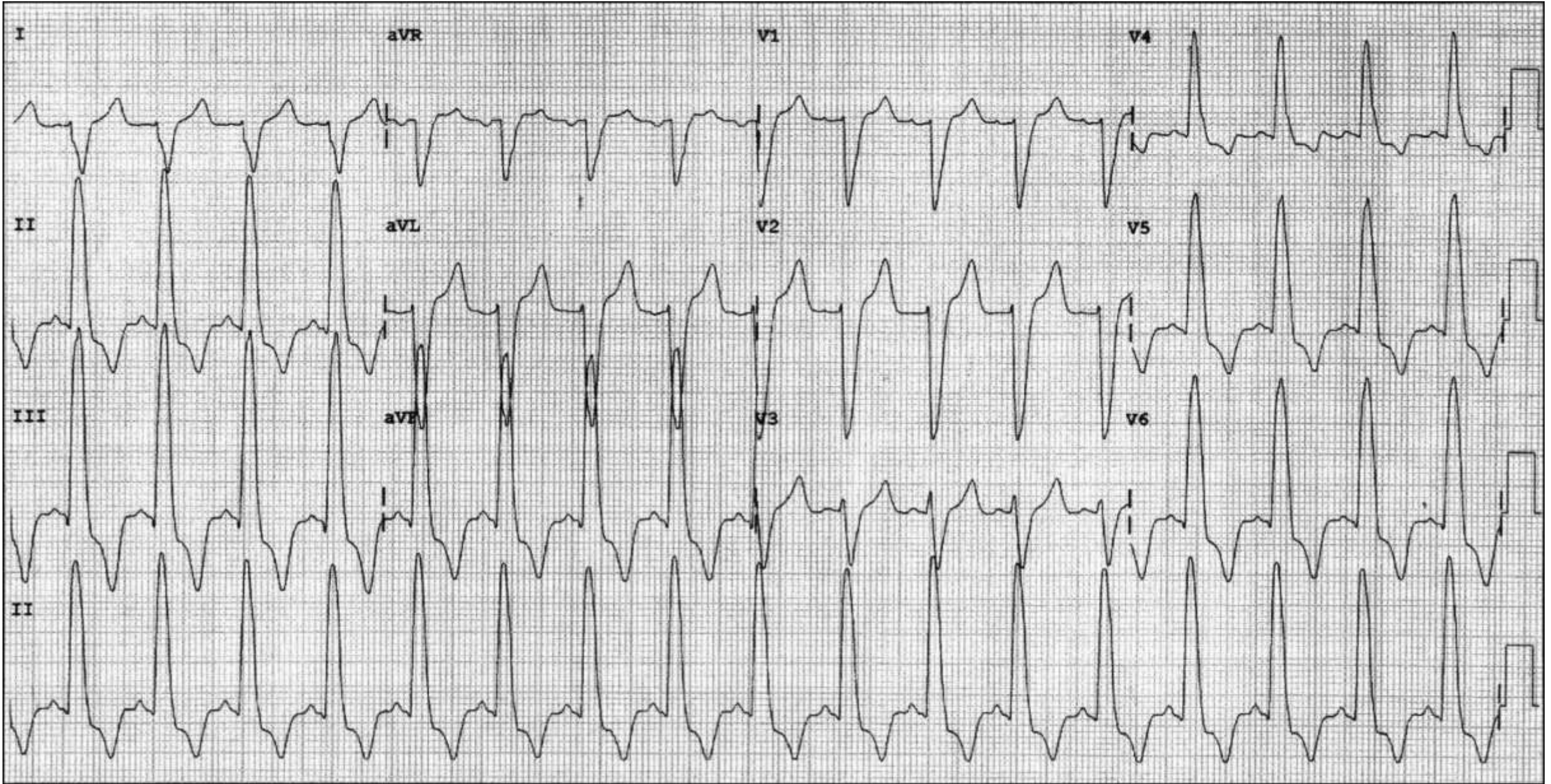
A very unusual ECG

A case from the staff of ECG sector - Incor – São Paulo, Brazil

Professor Carlos Alberto Pastore and Nelson Samesima



LO, 48 years old, female, typical precordial pain at the minimum efforts of moderate intensity



Which is the ECG diagnosis?

Colleagues opinions

Spanish

Estimados colegas. No es un caso fácil, especialmente por no conocer otro datos clinicos. Tiene ritmo sinusal, el AQRS a +120° grados, con retardos medio y finales del QRS y con q conservada en precordiales izquierdas.

Lo primero que haría es efectuar derivaciones precordiales altas y bajas, porque el hemibloqueo postero-inferior con sus pronunciadas fuerzas hacia abajo y a la derecha en el plano frontal puede afectar las fuerzas horizontales de las precordiales (ya figura en el libro original del los Hemibloqueos).

Con afecto

Gerardo J Nau MD Buenos Aires Argentina

English

Dear colleagues,

This is no easy case, particularly as there are no other clinical data. The patient presents sinus rhythm, AQRS at +120°, with middle and final delays of QRS and with preserved q in the left precordial leads.

The first thing I would do is use high and low precordial leads, because the posterior-inferior hemiblock with its pronounced forces heading below and to the right in the frontal plane may affect the horizontal forces of precordial leads (it is already included in the original book on Hemiblocks).

Gerardo J Nau MD Buenos Aires Argentina



Dr Naum was a member of the legendary team of Professor Mauricio Rosembaum

Spanish

Realmente es un hermoso y enigmático ECG. En el plano frontal el eje se orienta hacia la derecha a los 120° , y en las derivaciones precordiales parecería que se dirige hacia la izquierda con una onda R pura en V6, es como si la colocación de electrodos estuviesen invertidos en las derivaciones precordiales. Esta discrepancia se justificaría en presencia de una agenesia, hipoplasia o atelectasia del pulmón izquierdo. El corazón estaría desplazado y recién se registrarían potenciales derechos en las derivaciones izquierdas. Este alteración en la posición cardíaco generalmente se acompaña de rotaciones del mismo, por lo cual no podría asegurar que trastornos de conducción y/o agrandamiento de cavidades cardiacas presenta, a pesar de que por el plano frontal me inclinaría a pensar en una HVD (hipertensión pulmonar, estenosis pulmonar o una CIV asociada).

Afectuosamente

Isabel Konopka MD Buenos Aires Argentina

English

It really is a beautiful and enigmatic ECG. In the frontal plane, the axis is heading to the right at 120° and it seems that in the precordial leads is heading to the left with a pure R wave in V6; it is as if the electrodes were placed reversed in the precordial leads. This discrepancy would be justified in the presence of agenesis, hypoplasia or atelectasis in the left lung. The heart seems to be shifted and right potentials would only be recorded in the left leads. This alteration in the cardiac position is generally accompanied by rotations of it, so I would not be able to state if the patient presents conduction disorders and/or cardiac chambers enlargement, although I would lean to RVH in the frontal plane (pulmonary hypertension, pulmonary stenosis or with associated ventricular septal defect).

Isabel Konopka MD Buenos Aires Argentina



Hola Isabel gracias por tu aporte. No cumple con los criterios de bloqueos de rama. La severa HVI a predominio medio septal como afectaría la manifestación del 2do vector de despolarización ?. El primer vector septal basal está conservado ya que presenta R en I y aVL y V1-V2. Los electrodos están bien colocados lo que se evidencia al observar la onda P. Además, observo un emplastamiento inicial de la onda S en I, aVL y aVR. Que las derivaciones precordiales cambia y el emplastamiento lo observo en la parte final del QRS. Lo que expresa un retraso de la activación ventricular por aumento de la masa muscular, no por cicatriz ni desplazamientos. Si la paciente presenta un severo aumento de la masa muscular no sería lo que observó en el ECG?



Un saludo Martín Ibarrola

Hello, Isabel, thank you for your input. It does not meet the branch blocks criteria. How would a severe LVH with mid-septal predominance affect the manifestation of the 2nd depolarization vector?

The first basal septal vector is preserved, as it presents R in I and aVL and V1-V2. The electrodes are properly placed, which becomes manifest by observing the P wave. Moreover, I see initial S wave slurring in I, aVL and aVR. I see the precordial leads changing and widening in the final part of QRS. This expresses a ventricular activation delay by increase in muscle mass, not by scarring or shifts. If the patient presents a severe increase in the muscle mass, wouldn't this be observed in the ECG?

Respuesta Estimado Martín el primer vector se dirige hacia la izquierda arriba y adelante, el asa del complejo QRS en el plano frontal se dirige en forma horaria hacia los 120°, con una duración de 150 mseg. Yo no veo ni fuerzas septales ni del VI, si tiene HVI realmente no la puedo diagnosticar; con esa duración del complejo QRS tengo que pensar en trastornos de conducción. Yo siempre tengo que corroborar lo que observo en el plano frontal, que es fehacientemente una diferencia de potencial, con lo que me muestra el plano precordial que depende de la posición de los electrodos. Gerardo tiene razón en lo que expresa con respecto al mapeo; en relación a la presencia de un HBPI al cual yo le tendría que sumar determinado grado de BRD (por la duración del QRS) me gustaría que la R de V4 fuese mayor que la de V5 y V6, porque estas 3 derivaciones estarían en una posición baja; pero no lo puedo descartar.

Cordialmente Isabel.

Answer from Isabel: Dear Martín, The first vector is heading to the left, upward and forward, the QRS complex loop in the frontal plane is heading clockwise to 120°, with a 150 ms duration. I don't see any septal forces in the LV, I cannot diagnose whether there is really LVH, with this QRS complex duration I would think of conduction disorders. I always have to corroborate what I see in the frontal plane, which is reliably a difference in potential, with what the precordial plane shows, which depends on the position of the electrodes. Gerardo is right in what he states in terms of the mapping; in relation to the presence of left posterior hemiblock, to which I would add a certain degree of RBBB (due to QRS duration). I would like for the R in V4 to be greater than that of V5 and V6, because these 3 leads would be in a low position, but I cannot rule it out.

That's a cardiomyopathy. There is nothing wrong with the lungs. Rori Childers had a paper on LBBB with right axis deviation.

Cordially

Sergio Pinski, MD, USA



Answer from Andrés

Effectively dear Sergio, here it is.

Childers R, Lupovich S, Sochanski M, et al. Left bundle branch block and right axis deviation: a report of 36 cases. J Electrocardiol. 2000;33 Suppl:93-102.

Left bundle branch block with predominant slowing in the posterior division of the left bundle compared to the anterior division. Left ventricular hypertrophy. Differential diagnosis include hypertrophic CM, aortic stenosis, and other CM.

Mario D. Gonzalez, MD, USA



Buenas noches queridos y estimados Andrés y Raimundo.

ECG ritmo sinusal, FC 100 lpm, intervalo PR normal, duración del QRS 160 ms, eje eléctrico del QRS $>100^\circ$ y QTc 650 ms. Criterios de sobrecarga auricular izquierda, HBPI (rS en I y aVL, qR en III $>$ II, Qr en aVR, criterios de hipertrofia VI (Sokolov-Lyon y Cornell positivos), ángulo QRS/ST-T $>100^\circ$ (strain pattern) en V1-V2, elevación del segmento ST >1 mm cóncavo hacia arriba seguido de onda T positiva, y en las derivaciones izquierdas depresión del segmento ST de convexidad superior seguido de ondas T negativas asimétricas.

Coincido con Dr. Martin, en referencia al diagnóstico etiológico: miocardiopatía hipertrófica asimétrica septal basal. Disnea por obstrucción en el tracto de salida del VI y opresión precordial por isquemia secundaria (alteración de la relación oferta/demanda y de la microcirculación por crecimiento desorganizado de las fibras musculares, compresión de los vasos septales, intramurales y subepicardicos).

Talvez la isquemia septal sea la causa del HBPI.

Saludos respetuosos

Dr Juan Carlos Manzzardo, Mendoza, Argentina

Good evening dear Andrés and Raimundo.

ECG sinus rhythm, HR 100 bpm, normal PR interval, QRS duration 160 ms, QRS axis $>100^\circ$ and prolonged QTc (650 ms). There are criteria of left atrial enlargement, LPFB (rS in I and aVL, qR in III $>$ II, Qr in aVR, criteria of LVH (positive Sokolov-Lyon and Cornell indexes), QRS/ST-T angle $>100^\circ$ (strain pattern) in V1-V2, ST segment elevation >1 mm concave upwards followed by positive T wave, and in the left leads ST segment depression with superior convexity followed by asymmetric negative T waves.

I agree with Dr. Martin, regarding the etiological diagnosis: obstructive asymmetrical basal septal HCM. Dyspnea due to obstruction in the LVOT and precordial pain due to secondary ischemia (alteration of supply/demand ratio and microcirculation disturbance by disorganized growth of muscle fibers, compression of septal, intramural and subepicardic vessels).

Septal ischemia may be the cause of LPFB.

Respectful greetings

Dr Juan Carlos Manzzardo, Mendoza, Argentina



Dear Andres: sorry to be late. I am in Vienna. Nice meeting.

The case of this 48-year old woman with effort chest pains and present ECG is certainly very intriguing. Let us start with the ECG: sinus rhythm with normal PR and wide QRS complex displaying all well known features of CLBBB but a right axis deviation. Such an extreme right axis deviation should suspect some abnormal cardiac pathology (congenital?) or in the absence of such pathology the presence of an associated left posterior hemiblock. Patient's cardiac examination, echocardiogram and coronary angiography or coronary-CT should be first performed followed by exercise ECG testing. I would like to further comment on the presence of chest pains during exercise in patients with CLBBB. I am aware of a case of a patient with rate related LBBB without significant heart disease who developed chest pains marked hemodynamic changes (elevation of LV filling pressures and drop in LV ejection fraction upon appearance of the LBBB (J Cardiovasc Electrophysiol, reference?? # 15 years ago). I am also aware of a series of patients published in Heart Rhythm in 2015-2016 by the group of the late Mark Josephson (Heart Rhythm. 2016 Jan;13(1):226-32. doi: 10.1016/j.hrthm.2015.08.001. Epub 2015 Aug 30.

Painful left bundle branch block syndrome: Clinical and electrocardiographic features and further directions for evaluation and treatment). These patients had marked right axis deviation. The Josephson case had associated CAD and RVA pacing resolved intractable chest pains. In other words: first echocardiography and coronary investigation. Secondly a hope for resolving patient symptoms using RVA (and probably better CRT) pacing.

I found the superb paper to which I referred in my comments: J Cardiovasc Electrophysiol. 2006 Jan;17(1):101-3. Acceleration-dependent left bundle branch block with severe left ventricular dyssynchrony results in acute heart failure: are there more patients who benefit from cardiac resynchronization therapy? Zeppenfeld K, Schalij MJ, Bleeker GB, Holman ER, Bax JJ. Abstract: Cardiac resynchronization therapy (CRT) has been proposed to improve hemodynamics in patients with heart failure and left bundle branch block (LBBB) by resynchronization of left ventricular (LV) dyssynchrony. The current report concerns a patient with narrow QRS complex without LV dyssynchrony who experienced an acute exacerbation of heart failure following exercise. Careful analysis revealed that an increase of heart rate induced acceleration-dependent LBBB with severe LV dyssynchrony and mitral regurgitation followed by acute heart failure and hemodynamic collapse. CRT prevented these adverse reactions. Accordingly, optimal evaluation for CRT may include testing for LV dyssynchrony during exercise

Prof. Bernard Belhassen, Israel



Final comments



Andrés Ricardo Pérez-Riera, M.D. Ph.D.

Design of Studies and Scientific Writing
Laboratory in the ABC School of Medicine,
Santo André, São Paulo, Brazil

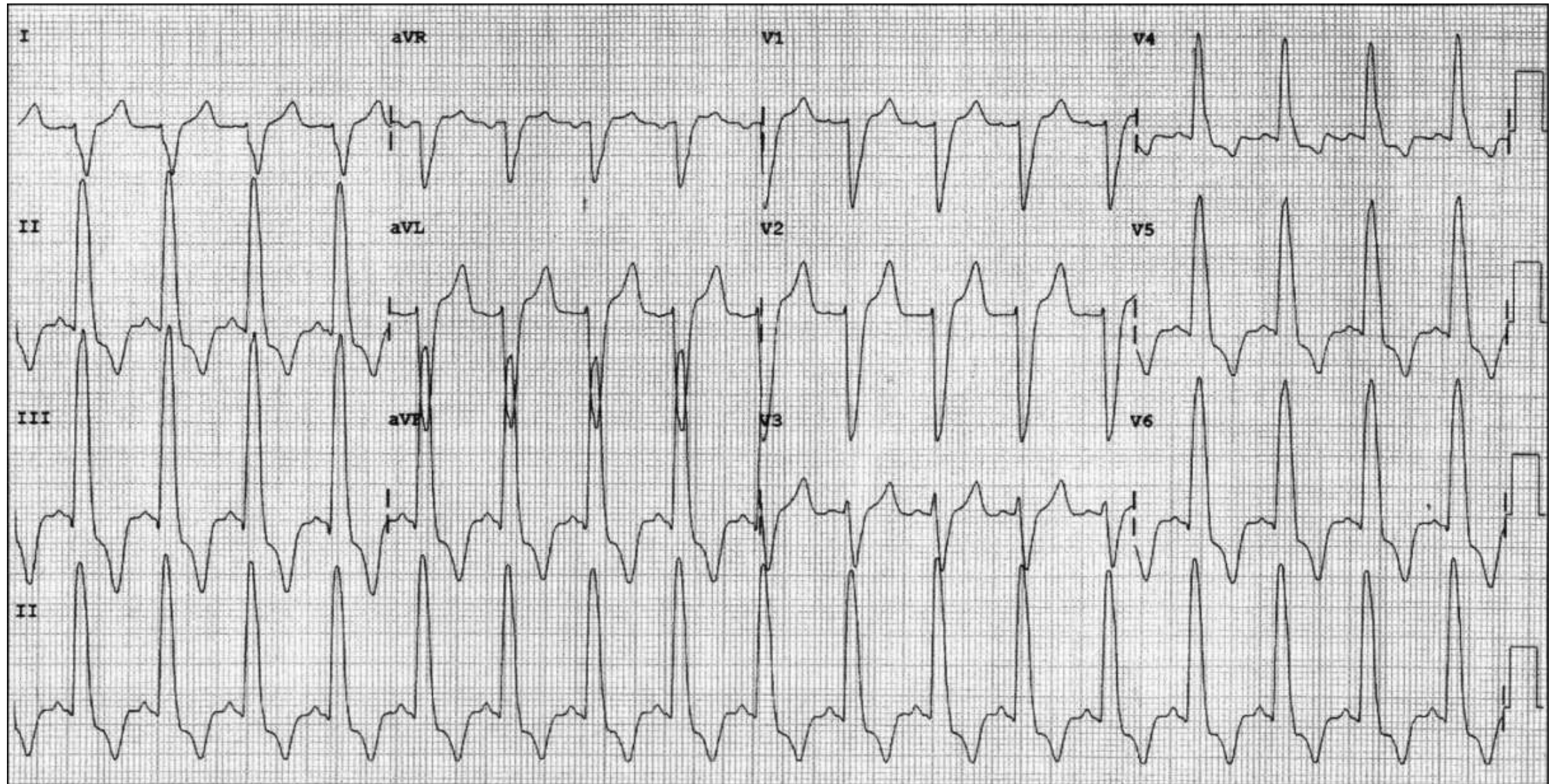
<https://ekgvcg.wordpress.com>



Raimundo Barbosa-Barros, MD

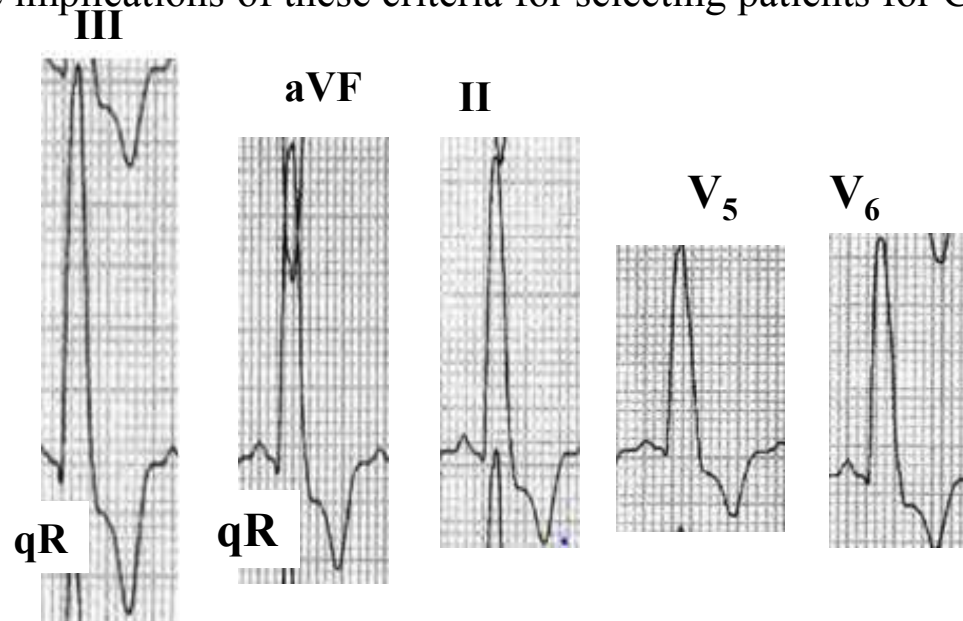
Chief of the Coronary Center of the Hospital de Messejana Dr. Carlos
Alberto Studart Gomes. Fortaleza – CE- Brazil

LO, 48 years old, female, typical precordial pain at the minimum efforts of moderate intensity

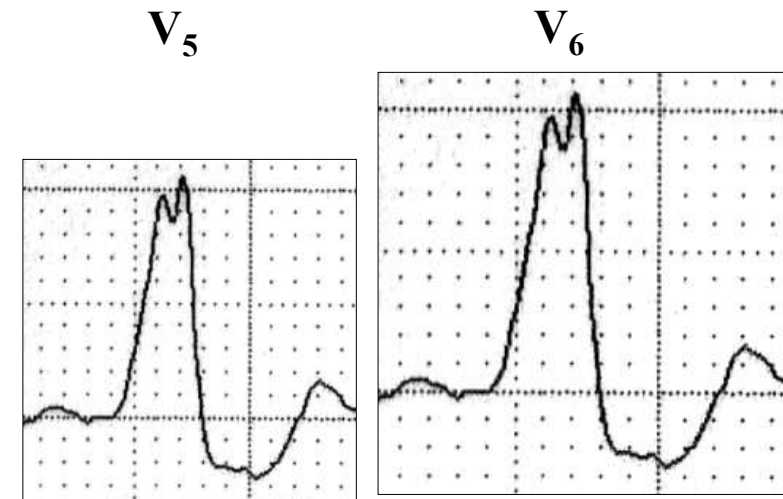


ECG diagnosis: Sinus rhythm, HR 100 bpm, P-wave with normal duration and axis between $+60^\circ$ and $+90^\circ$, PR interval duration 120 ms, QRS duration 140ms, QRS axis near $+120^\circ$ (for LBBB is considered extreme right deviation), rS in I, aVL, and aVR, qR in II, III and aVF, $R_{III} > R_{II}$, rS from V1 to V3 and qR from V4 to V6, secondary repolarization abnormality strain pattern type.

According to the American Heart Association/American College of Cardiology and the Heart Rhythm Society (AHA/ACCF/HRS) recommendation (2009), Nonspecific or Unspecified Intraventricular Conduction Disturbance (NICD) (**Surawicz 2009**): *QRS duration ≥ 120 ms in adults, >90 ms in children 8 to 16 years of age, and >80 ms in children less than 8 years of age without criteria for RBBB or LBBB. The definition may also be applied to a pattern so called masquerading BBB: RBBB criteria in the precordial leads and LBBB criteria in the limb leads, and vice versa.* Consequently, this tracing does not fulfill the classical LBBB criteria, and we could properly denominate NICD. Additionally, we observe that this tracing does not have the stricter criteria for complete LBBB: QRS duration ≥ 140 ms for men and ≥ 130 ms for women, along with mid-QRS notching or slurring in ≥ 2 contiguous leads. This new values are used for Cardiac Resynchronization Therapy (CRT) (**Strauss 2011**). Current criteria for CRT eligibility include a QRS duration ≥ 120 ms. However, studies have suggested that only patients with LBBB benefit from CRT, and not patients with RBBB or nonspecific intraventricular conduction delay. Strauss et al (Strauss 2011) review the pathophysiologic and clinical evidence supporting why only patients with complete LBBB benefit for Cardiac Resynchronization Therapy (CRT). Additionally, they review how the threshold of 120 ms to define LBBB was derived subjectively at a time when criteria for LBBB and RBBB were mistakenly reversed. These authors propose stricter criteria for complete LBBB that include a QRS duration ≥ 140 ms for men and ≥ 130 ms for women, along with mid-QRS notching or slurring in ≥ 2 contiguous leads. Further studies are needed to reinvestigate the electrocardiographic criteria for complete LBBB and the implications of these criteria for selecting patients for CRT. Let's see:

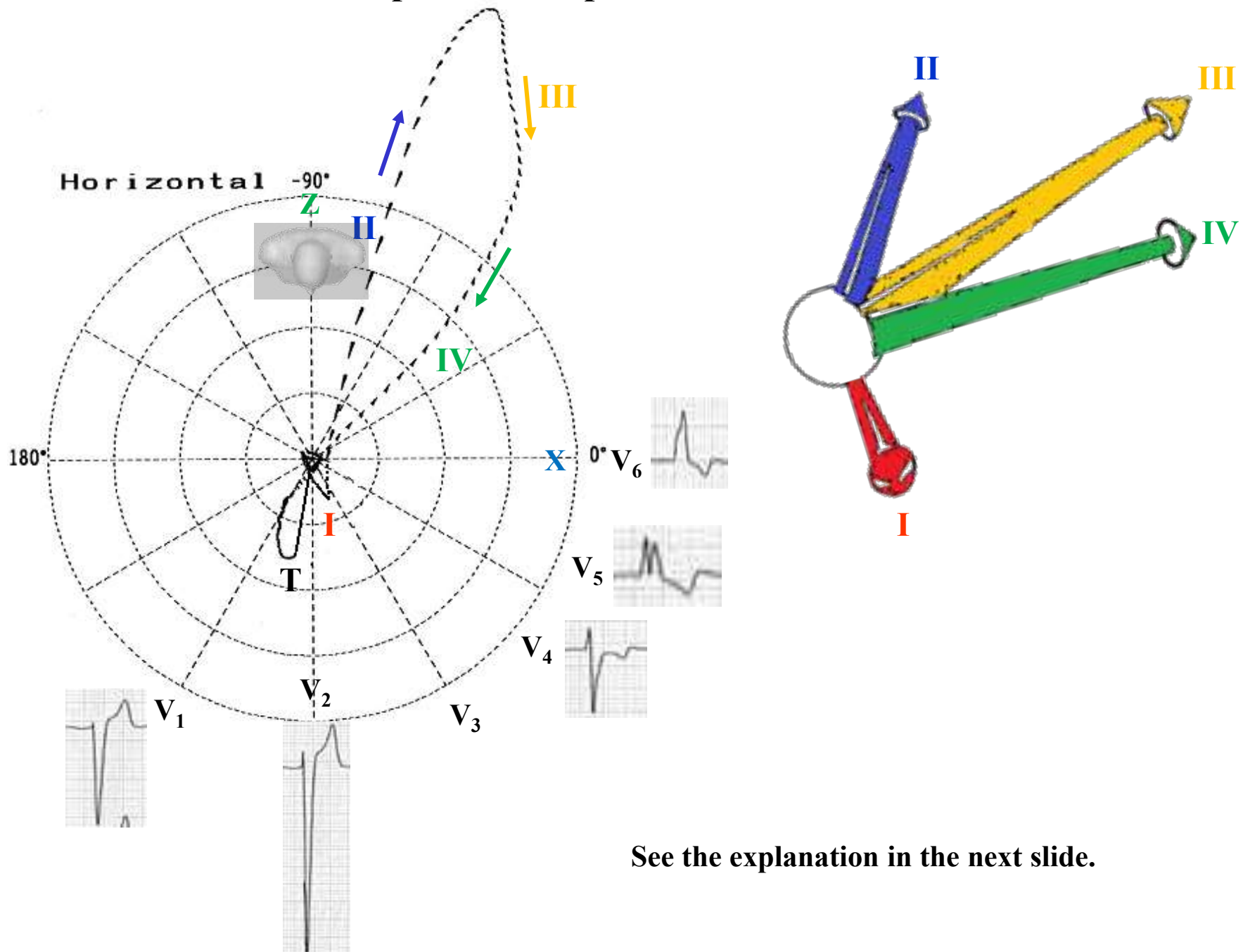


Absence of mid-QRS notching or slurring in ≥ 2 contiguous leads. Consequently, we do not have truly LBBB.



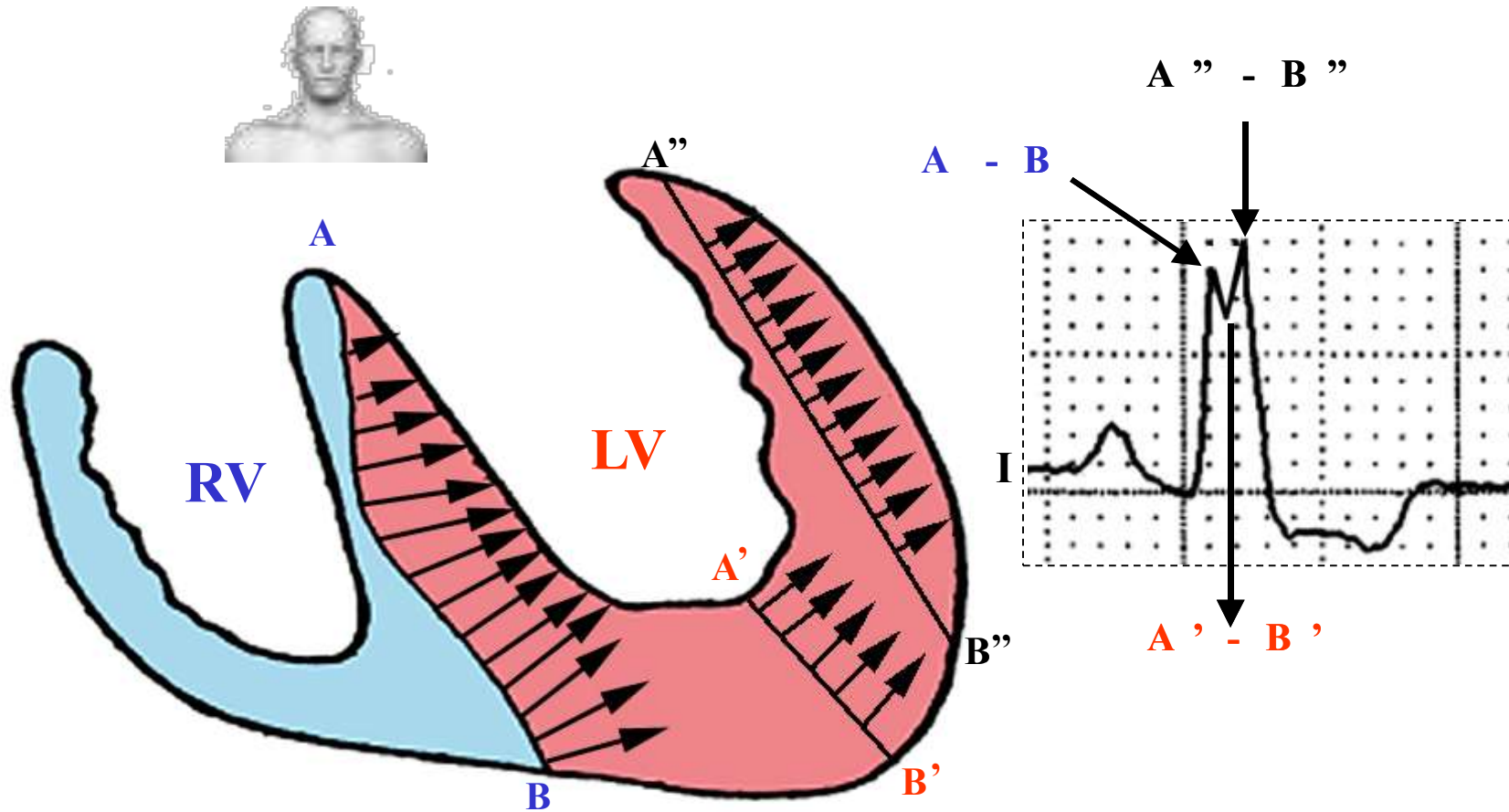
Truly LBBB by stricter criteria: mid-QRS notching at the apex of R-wave in ≥ 2 contiguous leads. In VCG, notching corresponds to middle end conduction delay. See next slide.

ECG/VCG correlation of uncomplacate Complete Left Bundle Branch Block in the Horizontal Plane



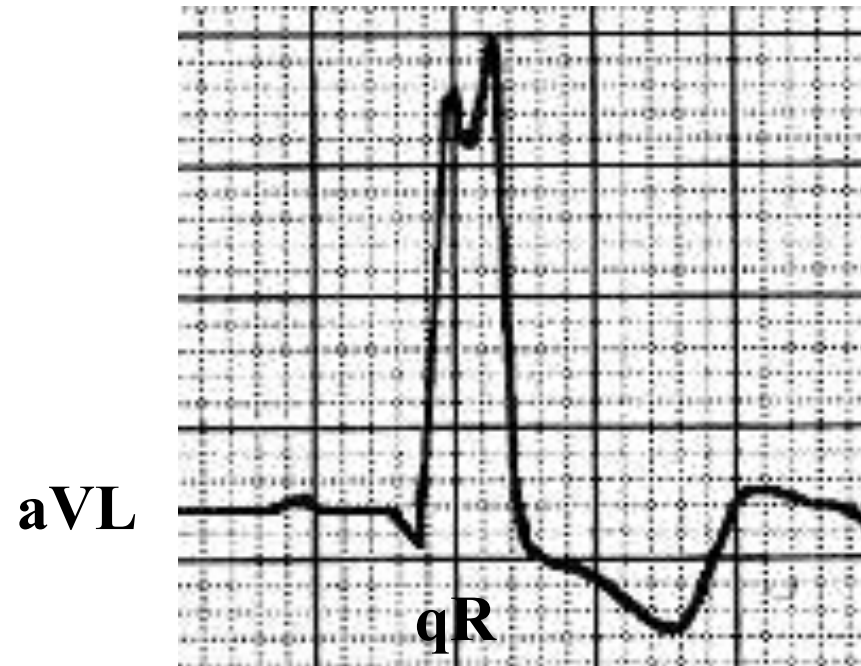
See the explanation in the next slide.

Monophasic R wave of slow recording in left leads I, aVL, V5 and V6 and electrophysiological explanation



Septal depolarization from right to left makes a wide **A-B** wave front; however, when the stimulus reaches the central portion of the LV (cavity), it suffers a marked decrease in wavefront width (**A'-B'**) responsible for the notch in the apex of R wave. Next, the wavefront reaches the LV free wall increasing again the width of the wavefront (**A''-B''**), responsible for the second apex of R wave. In the severe hypertrophies of the free wall, this second apex presents a higher voltage related to the first one.

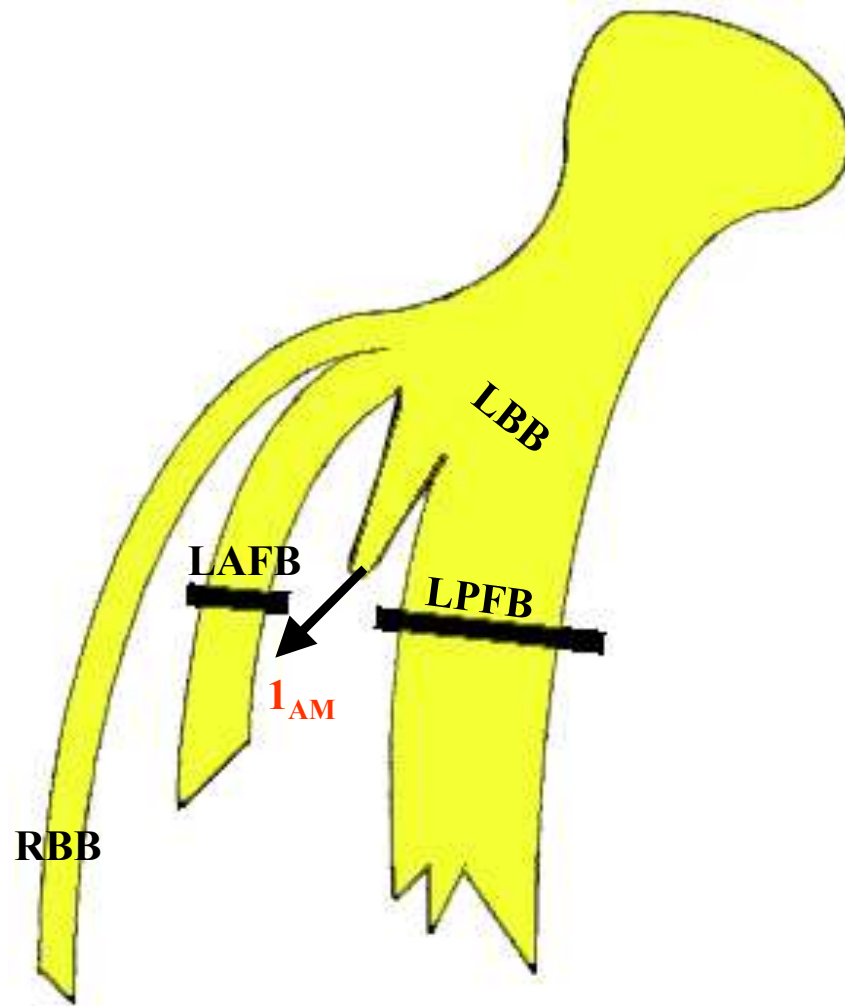
Initial q wave left leads in CLBBB



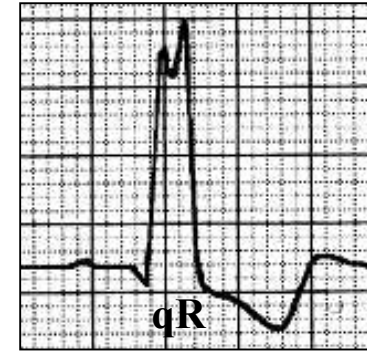
In uncomplicated complete LBBB is characteristic the absence of initial q waves in leads I, V5 and V6, but in the lead aVL a narrow q wave may be present in the absence of myocardial pathology.

The pure monophasic R wave is characteristic in the left leads (I, aVL, V5 and V6). Since the aVL lead is higher, it can rarely show qR pattern in absence of complicated LBBB. When the left septal division emerges before the block area, preserving septal vector I as normal, heading to the right and the front: qR in left leads (atypical CLBBB). See next slide.

Divisional CLBBB with initial q wave in left leads



aVL
I
V₆
V₅



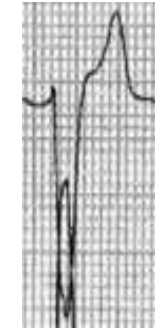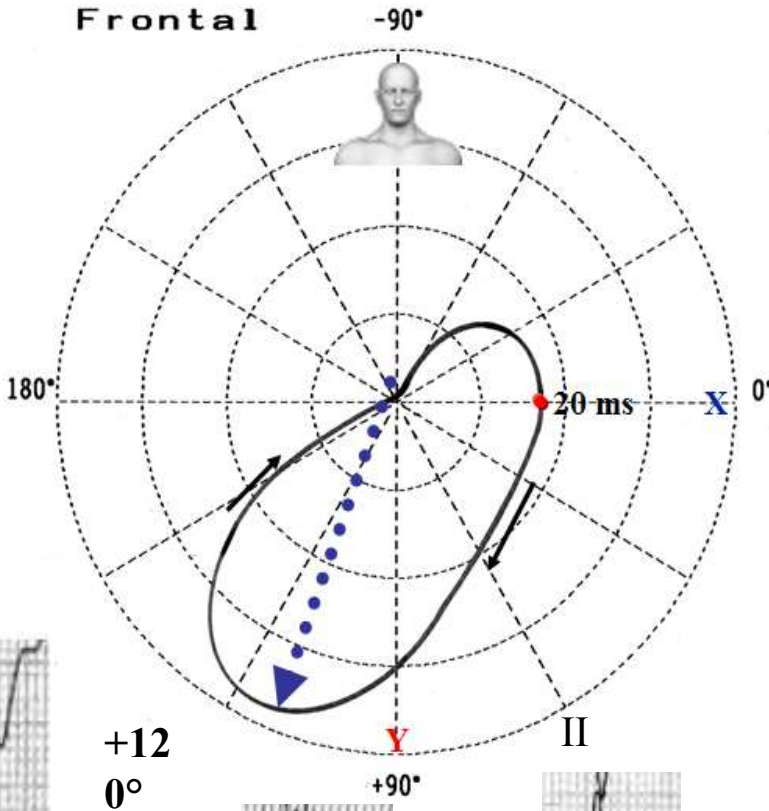
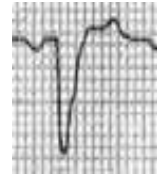
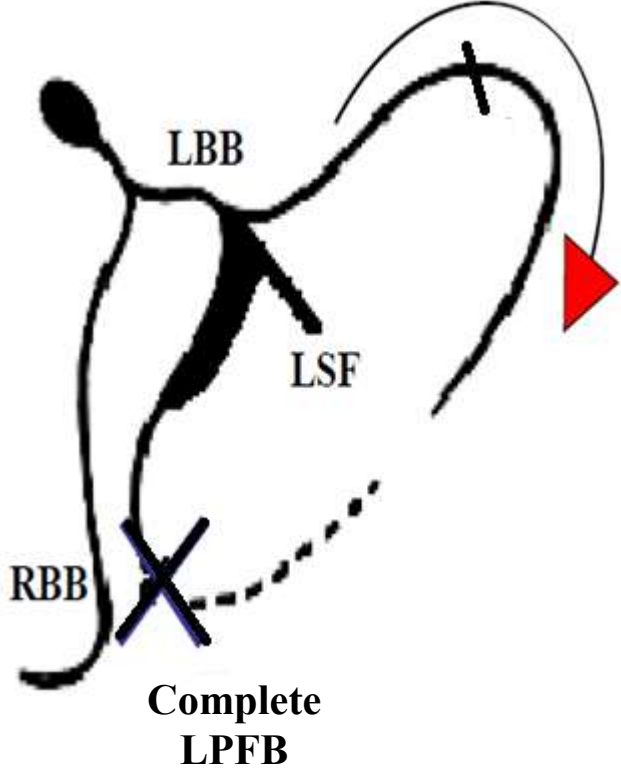
According to Medrano (**Medrano 1970**), if the fibers of the septal fascicle (SF) originate proximally to the block of the LAF and LPF, the middle-septal activation is preserved (I_{AM}), causing atypical CLBBB with q waves in left leads.

Outline of CLBBB with q wave in left leads. The left septal division emerges before the block area, preserving septal vector I as normal, heading to the right and the front: qR in left leads (atypical CLBBB).

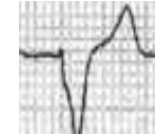
Hypothetic depolarization pattern suggests **complete** LPFB associated with **incomplete** LAFB. QRS duration of Bundle branch block



Incomplete LAFB

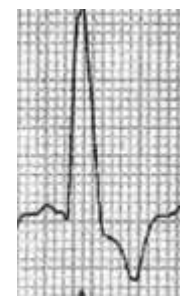


rS




V₅


V₆




RIII>R
II



q
R



q
R

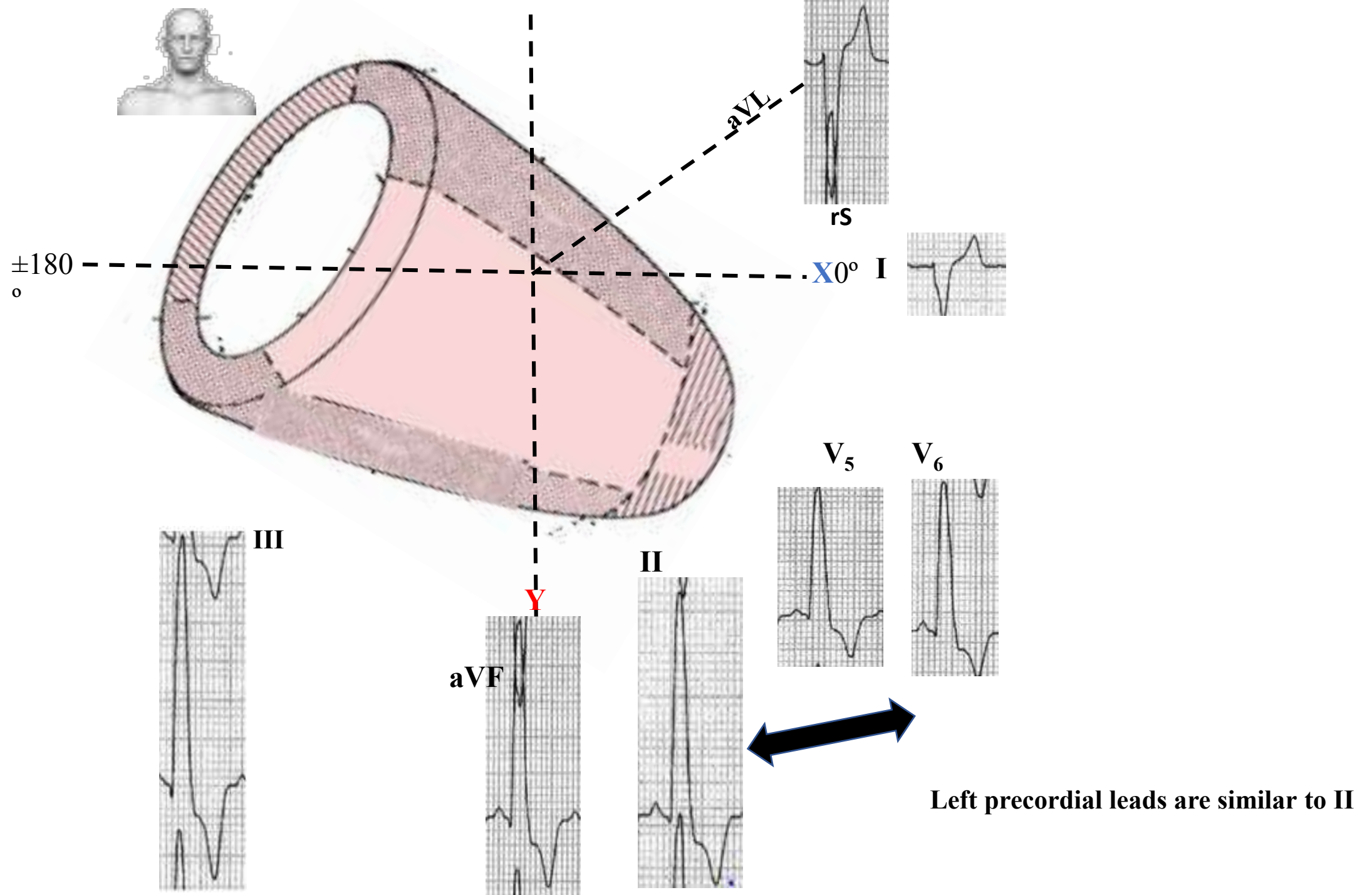


II



Left precordial leads are similar to II
It is necessary high and low precordial leads mapped on left precordial leads

Complete LPFB+ Incomplete LAFB



What are the electrocardiographic basics for the diagnosis of complete LPFB associated with incomplete LAFB

1. The QRS axis in the frontal plane shift to the right(beyond $+90^\circ$) in absence of longiline biotype, right ventricular hypertrophy, or lateral myocardial infarction,
2. QRS complexes type rS in I and aVL;
3. QRS complexes type qR in inferior leads
4. $R_{III} > R_{II}$.
5. QRS duration ≥ 120 ms.

Note There are references in the literature that severe aortic regurgitation by the diastolic regurgitant that strikes the posterolateral wall may cause LPFB.

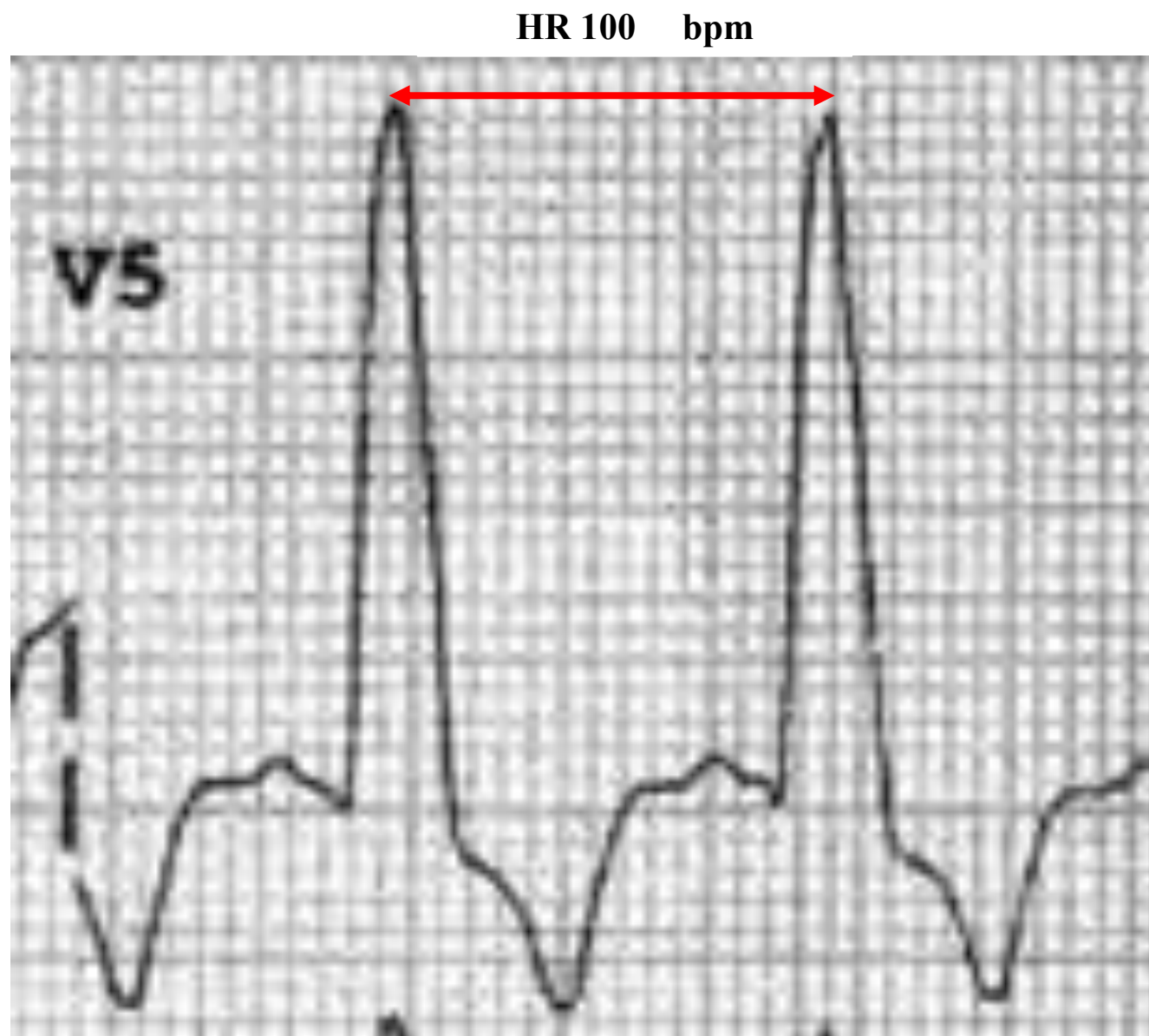
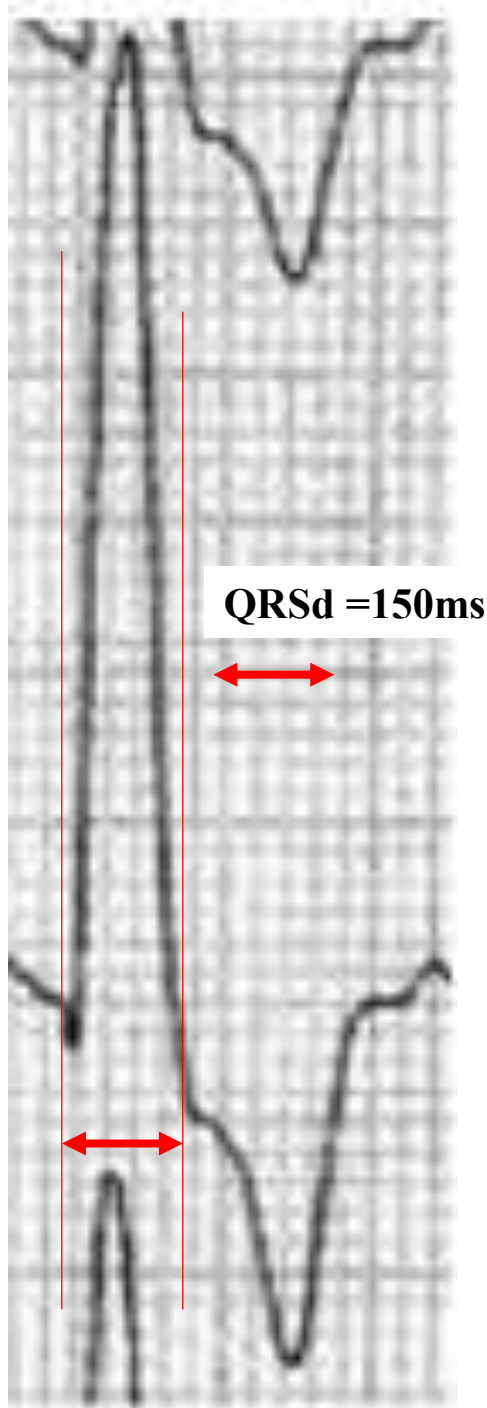
Clinical significance / prognosis of LBBB with extreme right QRS axis (beyond $+90^\circ$, "paradoxical type of Lipeschkin")

The LBBB with extreme QRS deviation to the right (beyond $+90^\circ$) in most cases is indicative of severe congestive cardiomyopathy with diffuse involvement of the myocardium and the intraventricular conduction system (**Nikolic 1985**).

The presence of LBBB with extreme deviation of the QRS axis to the right is a marker of poor prognosis (**Deharo 2000**).

Possible causes of extreme right axis deviation in the presence of LBBB

- 1) Divisional or fascicular LBBB with complete LPFB + incomplete LAFB
- 2) LBBB associated with RVH: Acquired causes: dilated cardiomyopathy with right heart failure or end stage of coronary artery disease(**Chia 1992**), end stage of hypertensive cardiomyopathy, verticalization of the heart consequence of chronic pulmonary heart disease and congenital causes: postoperative correction of ostium primum atrial septal defect (ASD), aorta coartation with secondary pulmonary hypertension
- 3) LBBB associated with left free wall myocardial infarction (lateral Myocardial infarction)
- 4) Wegener granulomatosis (**Khurana 2000**)
- 5) LBBB with accidental electrode change,

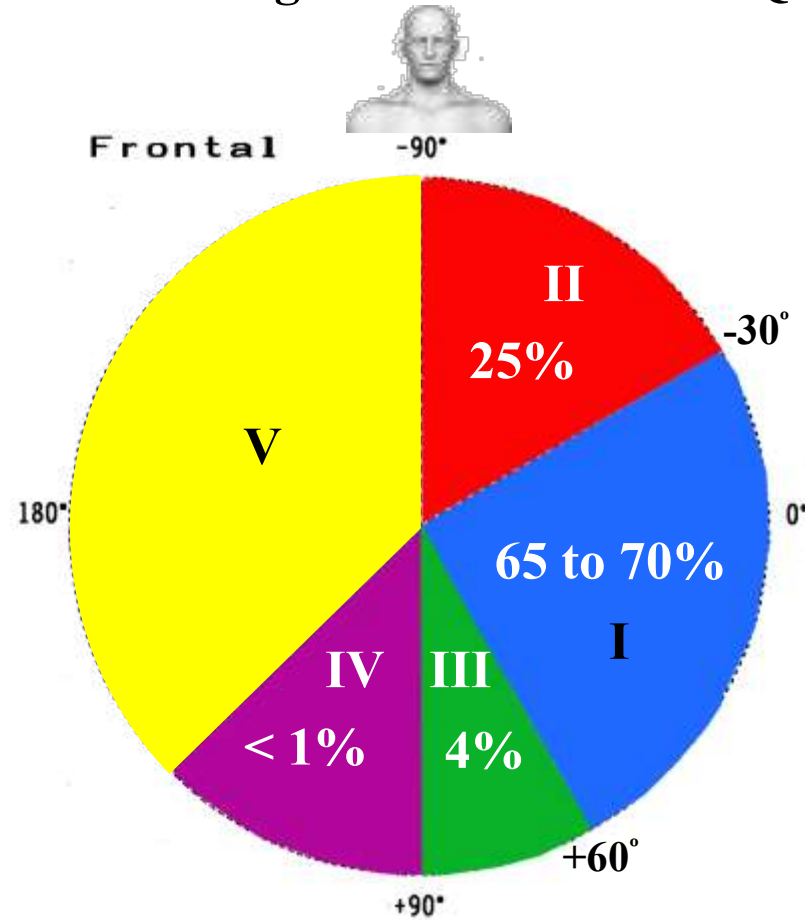


Electrocardiographic classification criteria for Left Bundle Branch Block according the QRS complex electrical axis in the Frontal Plane

See figure next slide.

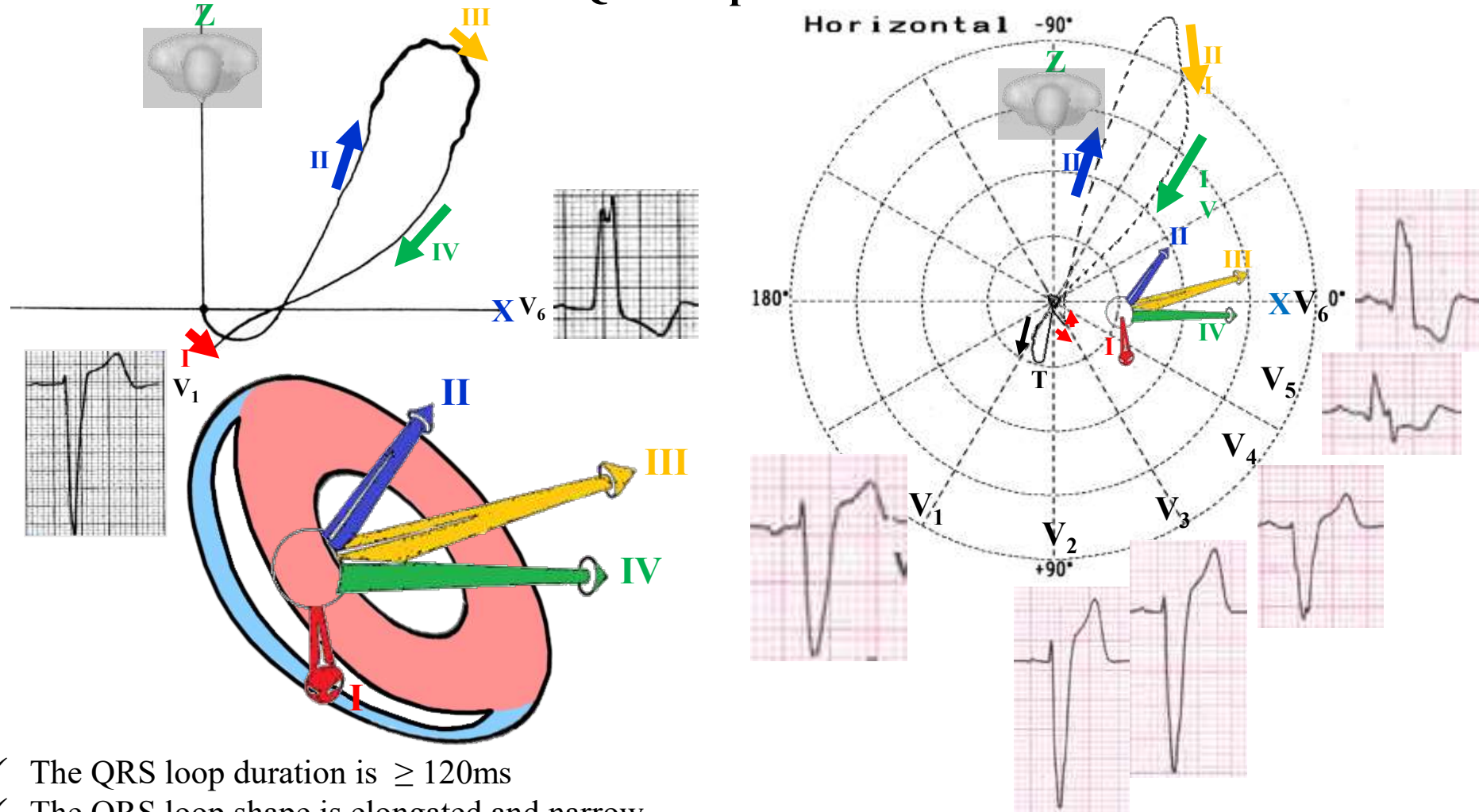
- a) With QRS axis not deviated: between -29° and $+60^{\circ}$ ($\approx 65\%$ to 70% of cases)
- b) With QRS axis with extreme deviation to the left: beyond -30° : between -30° and -90° (**Parharidis 1997**) ($\approx 25\%$ of cases). The presence of left axis deviation had a 41.9% sensitivity and a 91.6% specificity for the presence of organic heart disease. Aortic valve disease in LBBB pts seems to be frequently accompanied by left axis deviation. In LBBB patients, those without left axis deviation seem to benefit more from cardiac resynchronization therapy with defibrillator (CRT-D) than those with left axis deviation (**Brenyo 2013**).
- c) With QRS axis deviated to the right: between $+60^{\circ}$ and $+90^{\circ}$ (≈ 3.5 a 5% of cases)
- d) With QRS axis with extreme deviation to the right: beyond $+90^{\circ}$ ($<$ than 1% of cases). It is named "paradoxical type of Lipeschkin" (**Lipeschkin 1951**). The majority of subjects had dilated cardiomyopathy with biventricular enlargement (**Childers 2000**). The uncommon combination of LBBB and right axis deviation is a marker of severe myocardial disease, specially primary congestive cardiomyopathy. The mechanism of production of this ECG pattern appears to be diffuse conduction system involvement in advanced myocardial disease (**Nikolic 1985**). Causes that determine paradoxical complete LBBB:
 - Complete LBBB associated to right ventricular hypertrophy/enlargement or severe cardiomyopathy with biventricular enlargement. or diffuse advanced myocardial disease.(3) $>98\%$ of cases.
 - Fascicular Complete LBBB (LAFB + LPFB) with a higher degree of block in the postero-inferior division. In presence of AF LBBB with intermittent right axis deviation is explained by an additional LPFB accompanying predivisional LBBB (**Patenè 2008; 2012**)
 - LBBB in Wegener granulomatosis (**Khurana 2000**)
 - Complete LBBB associated to lateral infarction (free wall of left ventricle)
 - Complete LBBB with accidental exchange of limb electrodes
 - Complete LBBB associated with true dextrocardia (**Salazar 1978**)

Types of CLBBB according to electrical axis of QRS complex in the FP



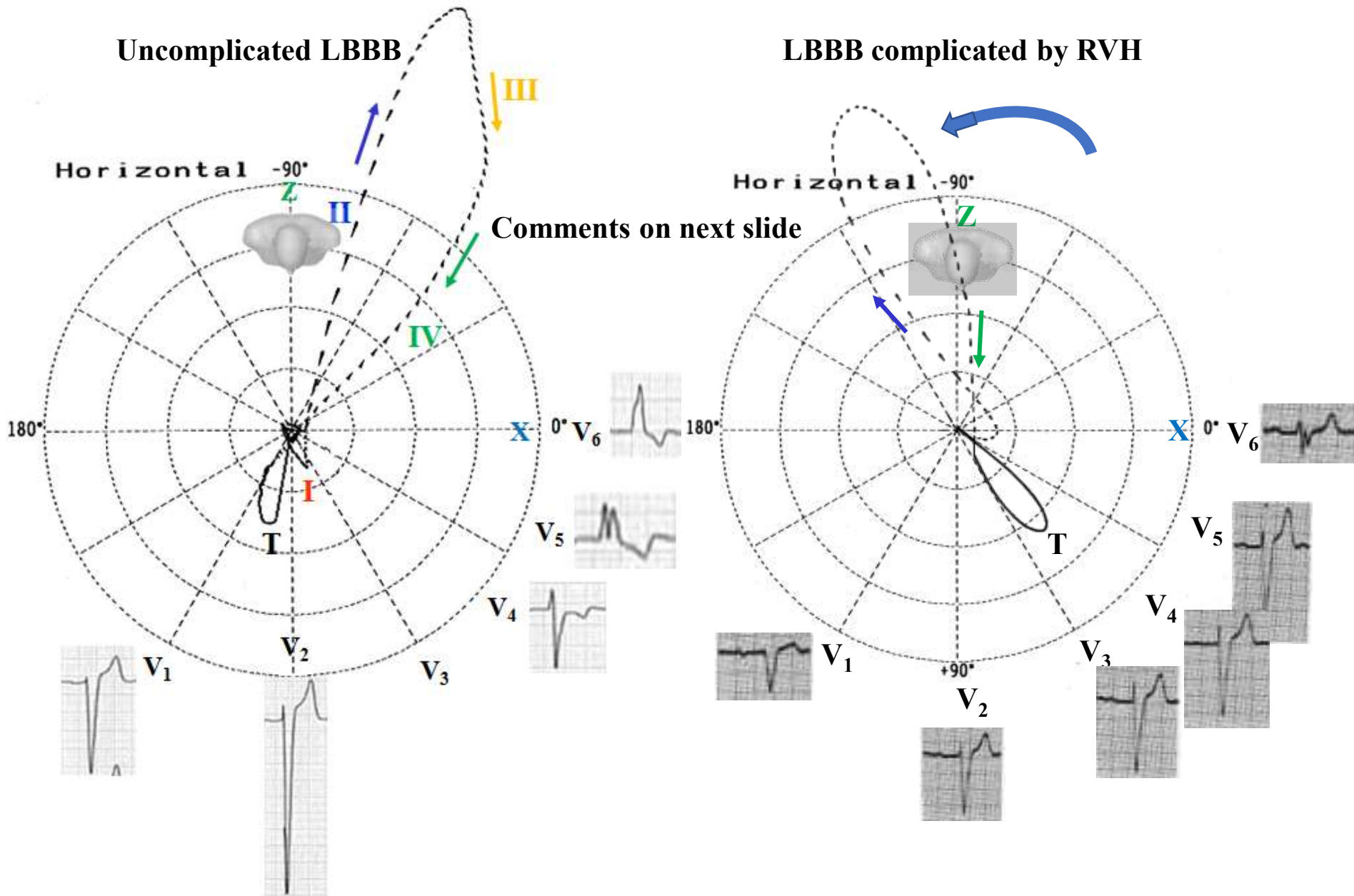
- I. With QRS axis not deviated: between -30° and $+60^{\circ}$ ($\approx 65\%$ to 70% of cases)
- II. With QRS axis with extreme deviation to the left: beyond -30° ($\approx 25\%$ of cases)
- III. With QRS axis deviated to the right: between $+60^{\circ}$ and $+90^{\circ}$ (≈ 3.5 a 5% of cases)
- IV. With QRS axis with extreme deviation to the right: beyond $+90^{\circ}$ ($<$ than 1% of cases). It is named "paradoxical type of Lepschkin" (**Lepeschkin 1951**). Causes that determine paradoxical complete LBBB:
- V. Some congenital heart disease (extremely rare).

Outline that shows the four despolarization-activation vectors in CLBBB in the HP. There is an ECG/VCG correlation of the QRS loop and the leads V1 and V6



- ✓ The QRS loop duration is $\geq 120\text{ms}$
- ✓ The QRS loop shape is elongated and narrow
- ✓ The main body of the QRS loop is inscribed posteriorly and to the left within the range -90 to -40° .
- ✓ Conduction delay noted in the mid and terminal portion
- ✓ The main body of QRS loop is inscribed clockwise (CW)
- ✓ The magnitude of the max QRS vector is increased above normal exceeding 2mV .
- ✓ ST segment and T wave vector are directed rightward and anteriorly (opposite to QRS-loop)

ECG / VCG difference between LBBB and LBBB associated with RVH on Horizontal Plane



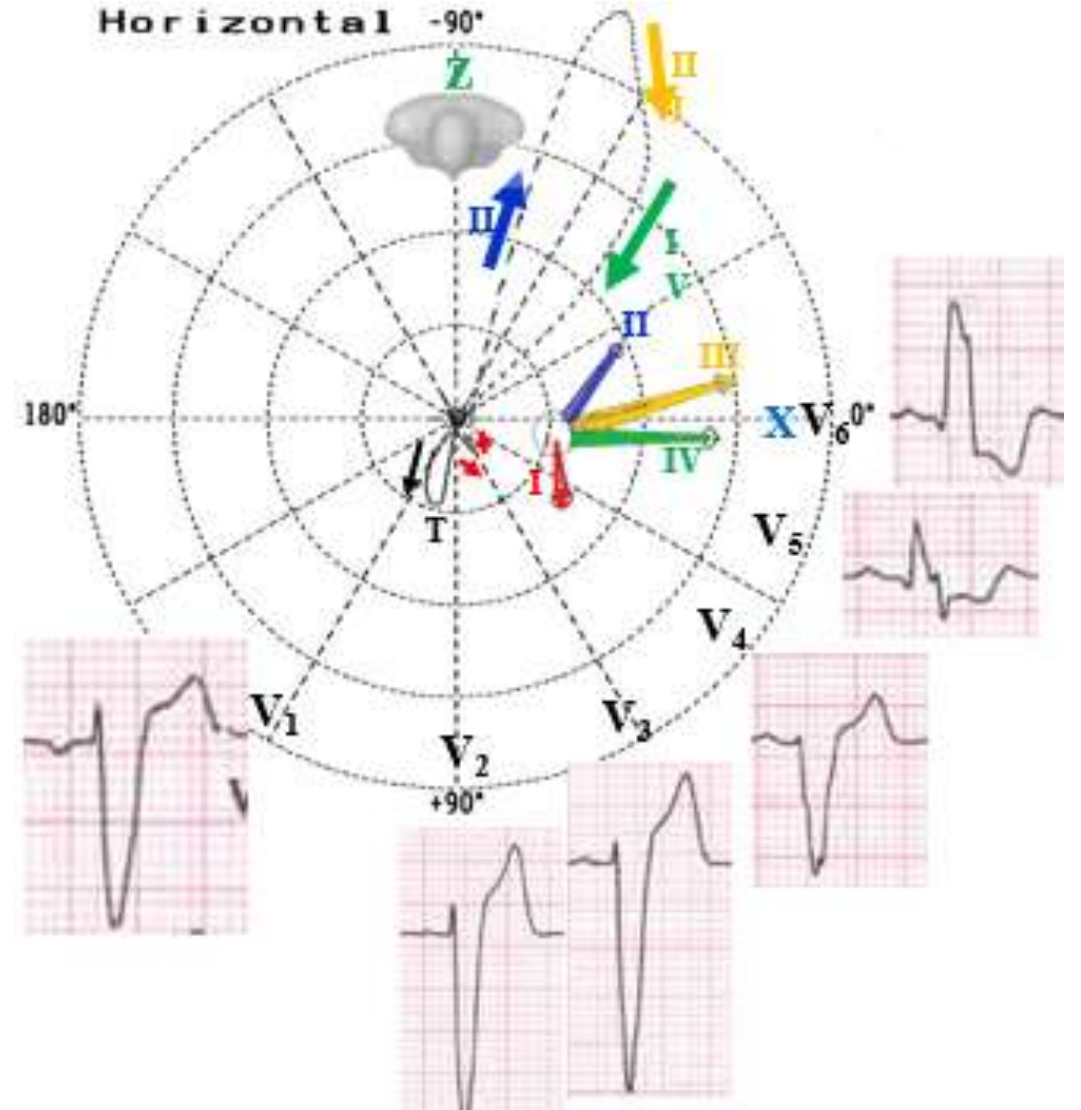
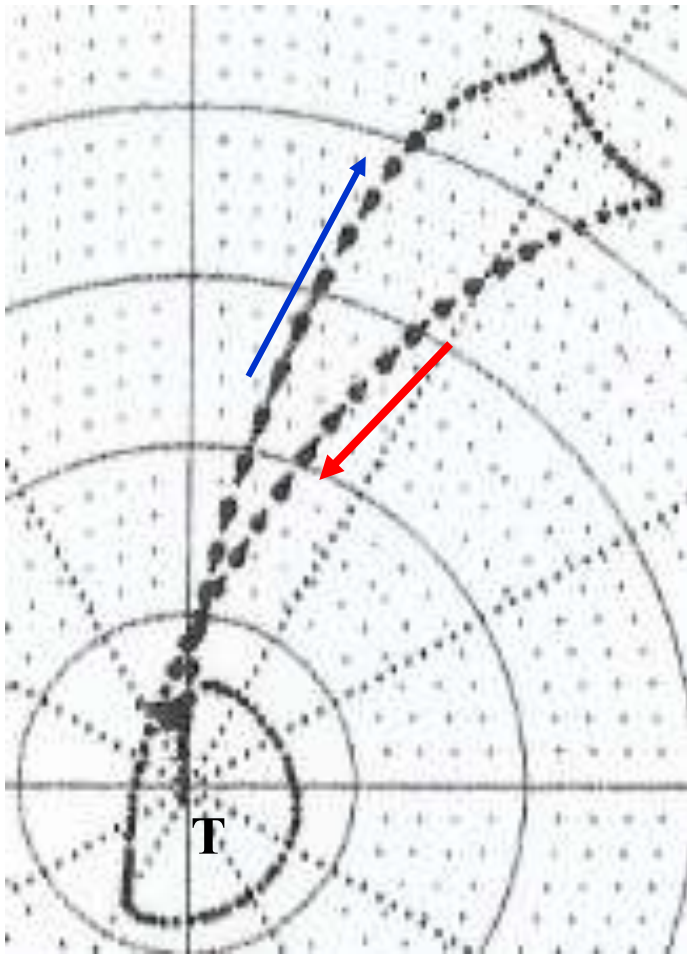
Schematic ECG/VCG correlation comparing the HP VCG of typical LBBB with LBBB complicated by RVH (Chou-Helm 1971)

Vectocardiographic criteria of uncomplcate CLBBB in the HP

- Narrow, long QRS loop, and with morphology usually in 8.
- The QRS loop duration is $\geq 120\text{ms}$
- The QRS loop shape is elongated and narrow
- The main body of the QRS loop is inscribed posteriorly and to the left within the range -90 to -40° .
- Maximal vector of QRS located in the left posterior quadrant (between -40° to -80°) and of increased magnitude ($>2\text{ mV}$).
- Main portions of QRS loop of clockwise rotation. CCW rotation may indicate parietal CLBBB or complicated with lateral infarction or severe LVH.
- The efferent limb (II) located to right related afferent limb (III and IV).
- Conduction delay noted in the mid and terminal portion
- The main body of QRS loop is inscribed clockwise (CW)
- The magnitude of the max QRS vector is increased above normal exceeding 2mV .
- ST segment and T wave vector are directed rightward and anteriorly.
- T loop of counterclockwise recording. The clockwise rotation of T wave in this plane suggests CLBBB complicated with infarction or LVH.

Meaning according to the location of the conduction delay on QRS loop of VCG

- I. Initial conduction delay on QRS loop** = *Preexcitation, WPW syndrome/ delta wave.*
- II. Middle and End conduction delay on QRS loop** = *Genuine or truly Complete Left Bundle Branch Block.*
- III. End conduction delay on QRS loop** = *Complete or incomplete Right Bundle Branch Block.*
- IV. Uniform conduction delay** = *Nonspecific, Unspecified Intraventricular Conduction Disturbance (NICD) Non-specific Intra-ventricular Conduction Defect* example *Hyperkalemia; drugs effects such as quinidine effect; tricyclic antidepressant intoxication, intra-infarction, intramural.* NICD reflects intramyocardial conduction delay. NICD is most often associated with cardiomyopathy (eg, ischemic or hypertensive). Conduction pathways can be either healthy or affected. Results from CRT are contradictory in this patient group, despite a seemingly neutral trend. Unfortunately, prospective studies are lacking. Guidelines recommending implantation of CRT devices in this group are based solely on analyses of subgroups with small sample sizes.



	Pseudo LBBB	Truly LBBB ECG-VCG correlation in the HP
Conduction delay location on QRS loop	Conduction delay only in the middle portion of the QRS loop	Conduction delay noted in the mid and terminal portion of the QRS loop
T-loop shape and limbs speed	Primary T-loop rounded and equal velocity of afferent and efferent limb	Elongated T-loop and with the efferent limb of inscription slower than the afferent one.

VCG characterization of right ventricular hypertrophy in the presence of LBBB

The VCG characteristics are:

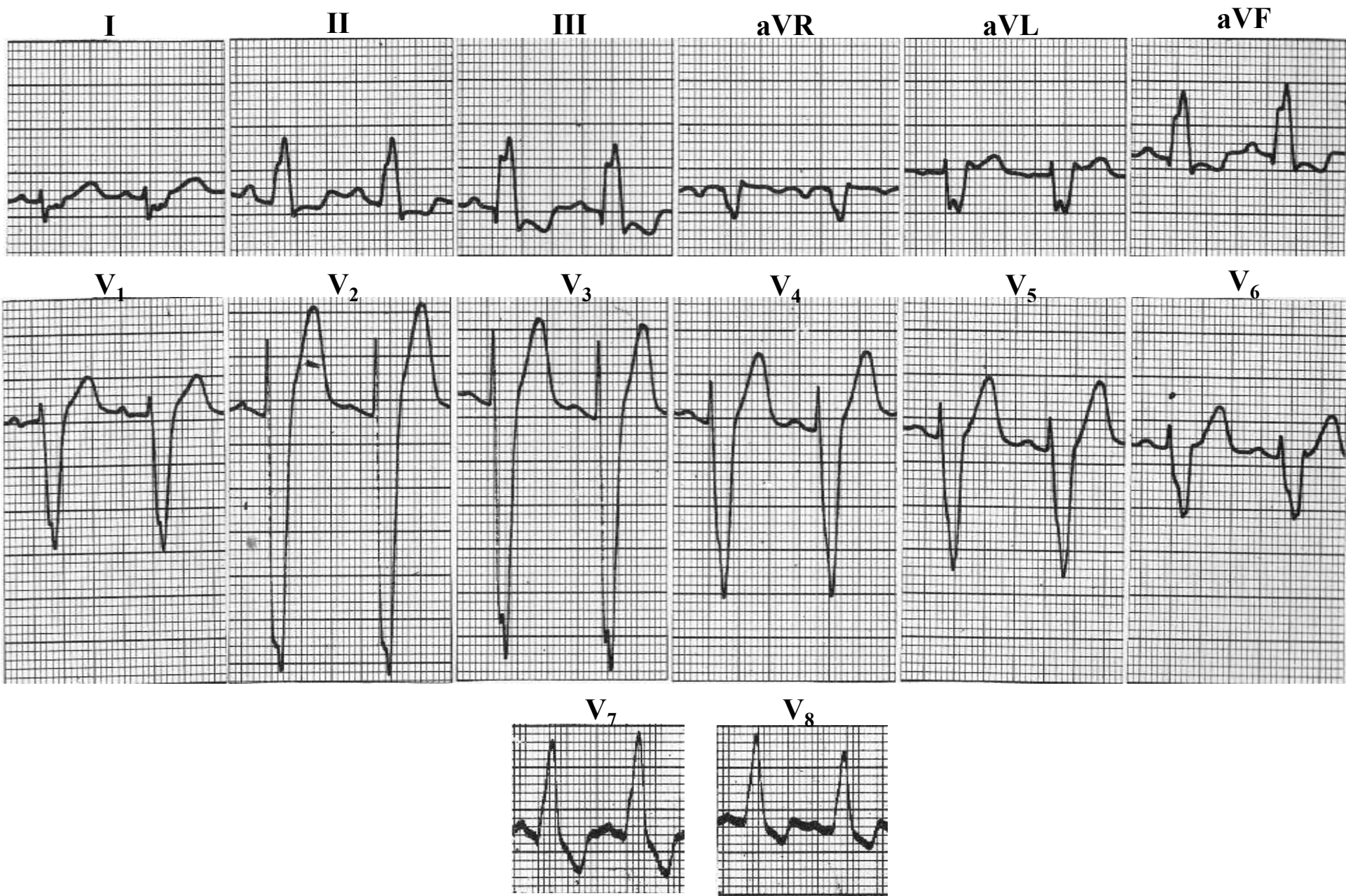
1. QRS loop duration with prolongation;
2. Slow inscription of the mid and late portion of the QRS loop;
3. Leftward and inferior orientation of the initial QRS vectors;
4. Posterior and rightward displacement of the maximum QRS vector;
5. Clock-wise inscription of the major portion of the QRS loop in the HP;
6. Anterior and leftward orientation of the ST vector and T-loop.

Final comments:

The changes in the HP VCG differed from the typical LBBB pattern only in the rightward displacement of the QRS loop and leftward orientation of the ST vector and T-loop.

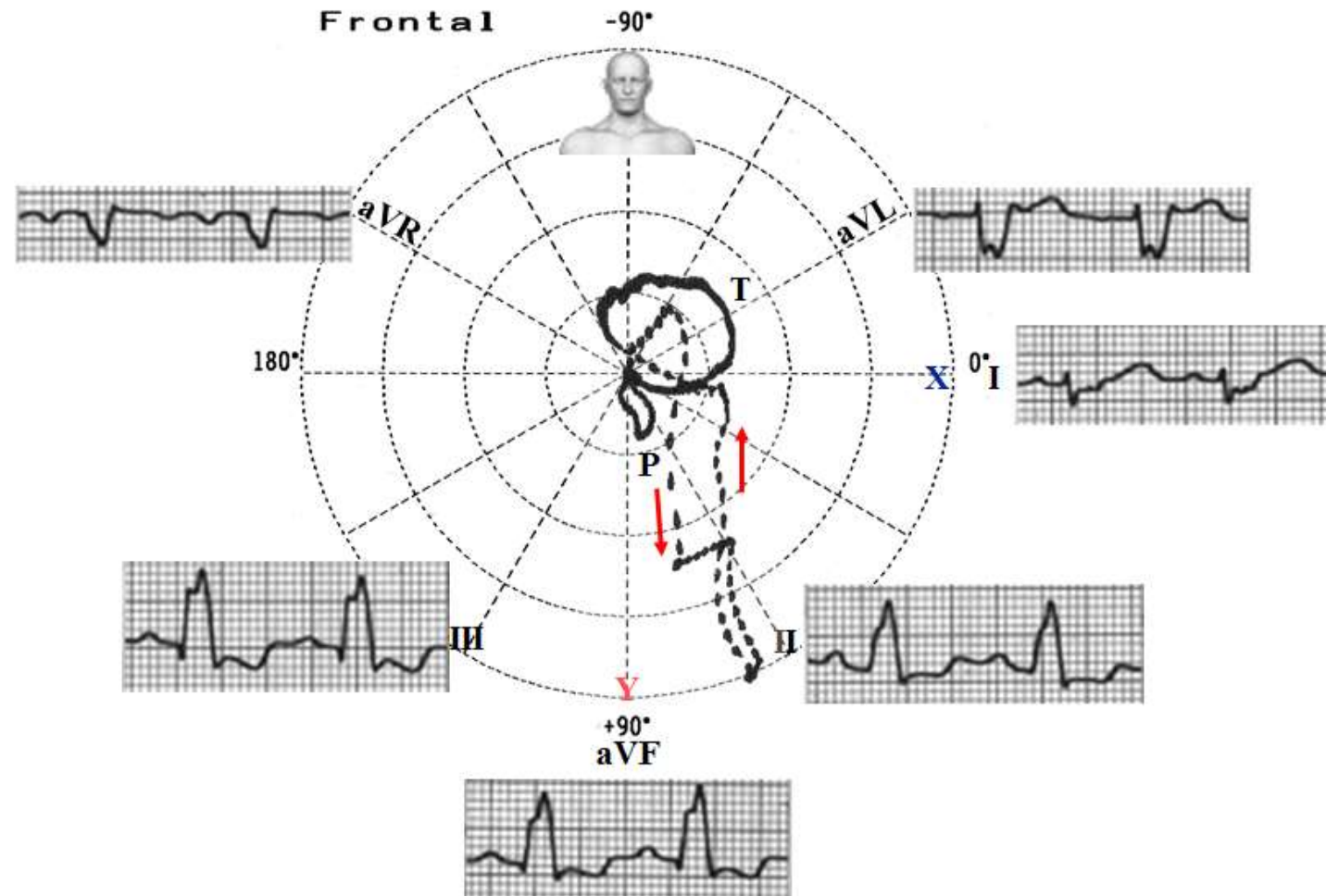
	Isolated LBBB	LBBB + RVH
HP QRS loop	Leftward displacement	Rightward displacement
ST vector and T-loop	Righthward orientation	Leftward orientation
ECG lead I	Monophasic R wave	Presence of S wave
QRS axis	From -30° to $+60^{\circ}$ ($\approx 65\%$ to 70% of cases) From -30° to -90° ($\approx 25\%$ of cases)	Beyond $+90^{\circ}$ ($<$ than 1% of cases)

Examples of LBBB with right axis deviation



Atypical LBBB because rs in I and rS in aVL and rS from lead V1 through V6. The typical LBBB upward QRS is observed only in inferior and posterior leads (V7-V8) (Tranchesi 1971)

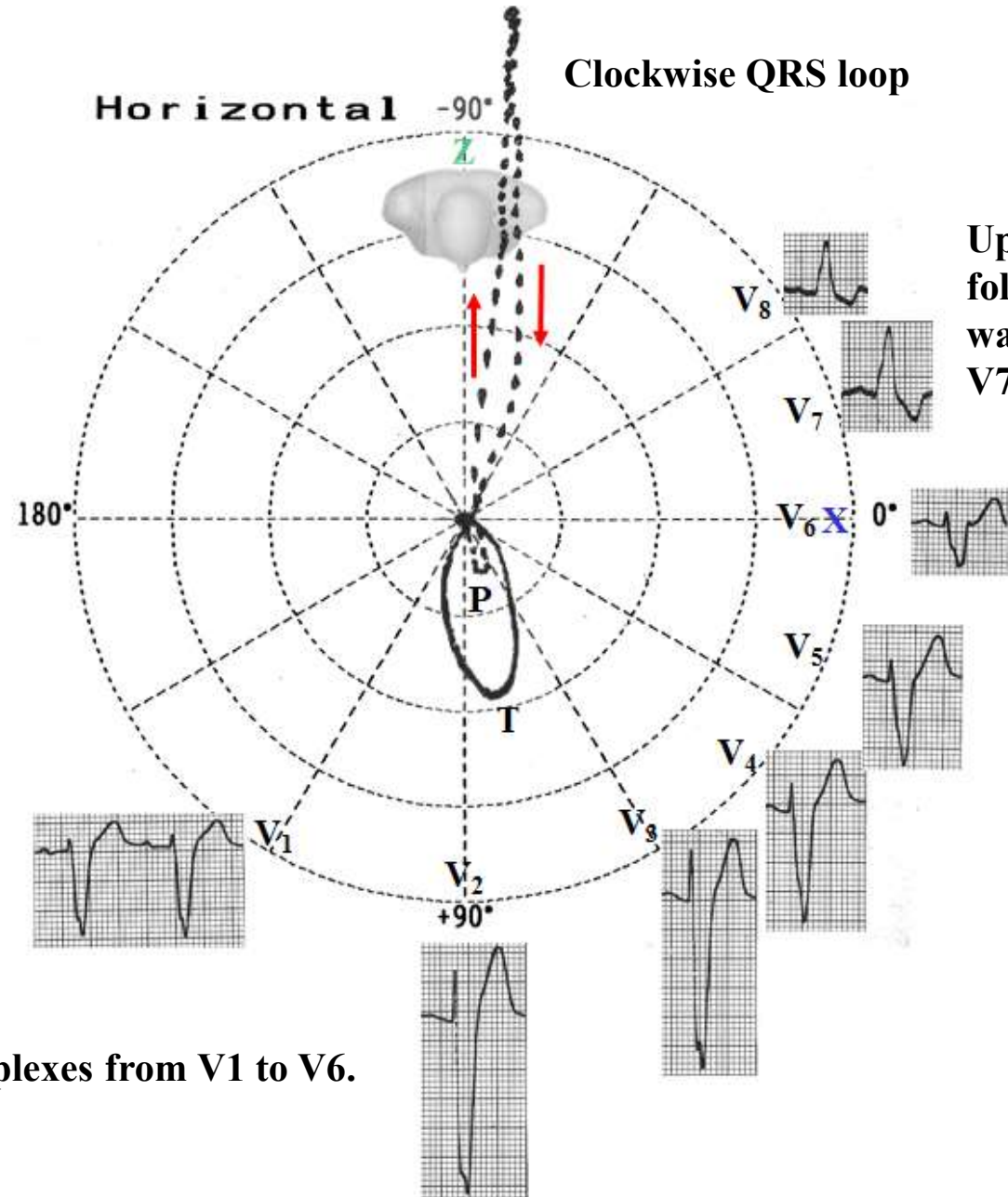
ECG/VCG correlation on FP



Right axis deviation. $\hat{S}\hat{A}\hat{Q}\hat{R}\hat{S}$ at $+110^\circ$.

QRS loop with predominant CCW rotation with maximal QRS vector $+74^\circ$.

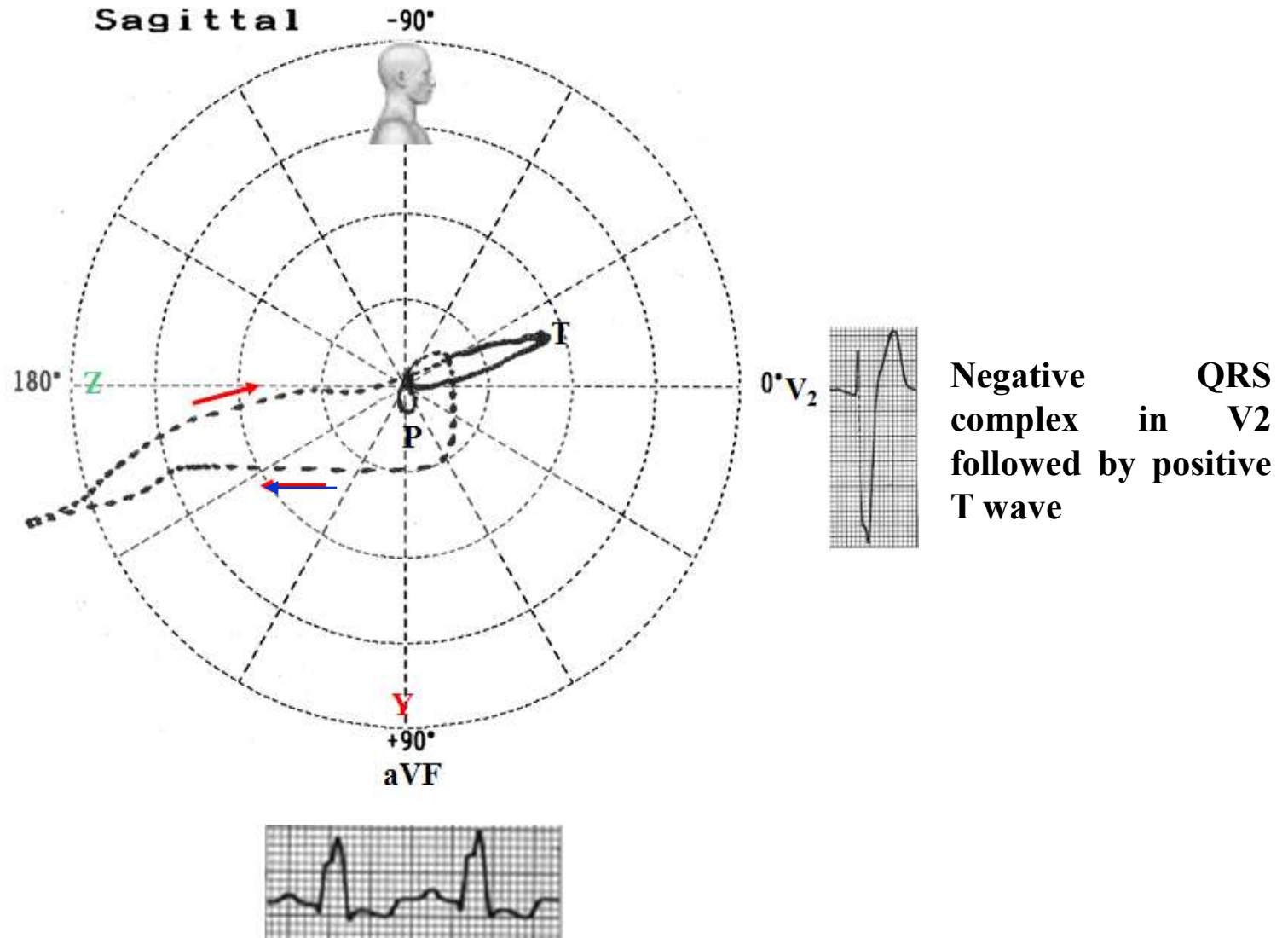
ECG/VCG correlation on HP



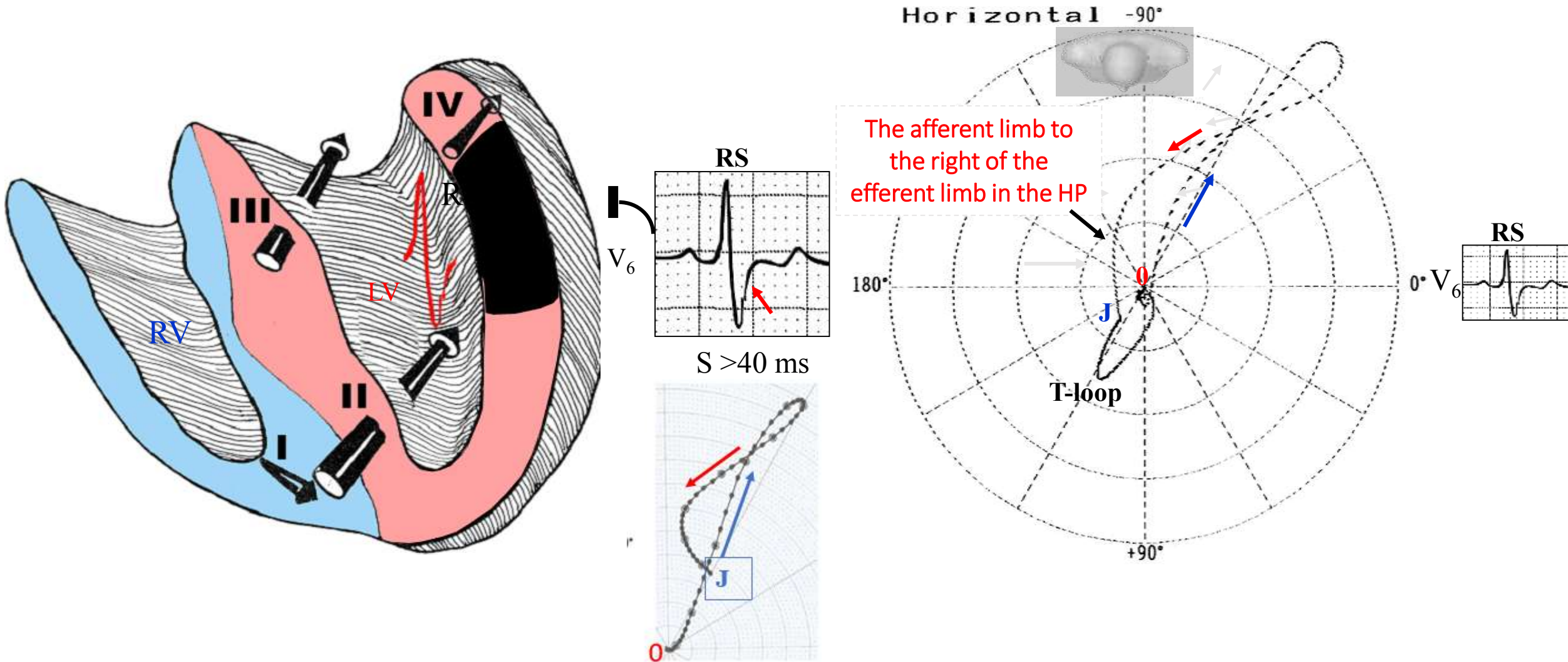
Upward QRS complexes followed by negative T waves in the back (leads V7 and V8).

Negative QRS complexes from V1 to V6.

ECG/VCG correlation on RSP



LBBB associated with LV free wall Myocardial Infarction



When electrocardiography was starting, Wilson postulated that the S wave of V₆ in the LBBB associated to lateral infarction was due to the sensing by the exploring electrode of V₆ of intracavitary potential of the LV (RS): it is called the “electric window” of Wilson. Today we know that the afferent limb is dislocated to right (red color arrow) of the efferent limb (blue arrow). 0 point (beginning of QRS loop) and J point are very far one to another (This means ST segment elevation)

References

1. Brenyo A, Rao M, Barsheshet A, et al. QRS axis and the benefit of cardiac resynchronization therapy in patients with mildly symptomatic heart failure enrolled in MADIT-CRT. *J Cardiovasc Electrophysiol*. 2013;24(4):442-8.
2. Cheng TO. Intermittent right axis deviation in the presence of complete left bundle branch block. *Int J Cardiol* 2006;113(3):406–7
3. Chia BL. Left bundle branch block and right axis deviation due to severe coronary heart disease. *Singapore Med J*. 1992; 33(4):413-4.
4. Childers R, Lupovich S, Sochanski M, et al. Left bundle branch block and right axis deviation: a report of 36 cases. *J Electrocardiol*. 2000;33 Suppl:93-102.
5. Chou TC, Helm RA. The Diagnosis of right ventricular hypertrophy in the presence of left bundle branch block. *Proc. XI International Vectorcardiography Symposium North Holland Publishing Company*.1971; 289 296.
6. Deharo JC. Left bundle branch block. Electrocardiographic and prognostic aspects *Arch Mal Coeur Vaiss*. 2000; 93:31-37.
7. Khurana C, Mazzone P, Mandell B. New onset left bundle branch block with right axis deviation in a patient with Wegener's granulomatosis. *J Electrocardiol*. 2000;33(2):199-201.
8. Lepschkin E. *Modern Electrocardiography: vol. 1. The P-Q-R-S-T-U complex*. Williams & Wilkins, Baltimore; 1951.
9. Medrano GA, Brenes C, De Micheli A, et al. Simultaneous block of the anterior and posterior subdivisions of the left branch of the bundle of His (biphasic block), and its association with the right branch block (triphasic block). Experimental and clinical electrocardiographic study. *Arch Inst Cardiol Mex*. 1970;40(6):752-70.
10. Nikolic G, Marriott HJ. Left bundle branch block with right axis deviation: a marker of congestive cardiomyopathy. *J Electrocardiol*. 1985;18(4):395-404.
11. Parharidis G, Nouskas J, Efthimiadis G, et al. Complete left bundle branch block with left QRS axis deviation: defining its clinical importance. *Acta Cardiol*. 1997;52(3):295-303.
12. Patanè S, Marte F, Di Bella G. Atrial fibrillation with left bundle branch block and intermittent right axis deviation during acute myocardial infarction. *Int J Cardiol*. 2008;127(1):e1-2.
13. Patanè S, Marte F, Di Bella G, Chiribiri A. Atrial fibrillation with intermittent right axis deviation in the presence of complete left bundle branch block. *Int J Cardiol*. 2008;129(1):e1-2. b
14. Patanè S, Marte F, Dattilo G, et al. Acute myocardial infarction and left bundle branch block with changing axis deviation. *Int J Cardiol*. 2012;154(3):e47-9.
15. Rosenbaum MB. Types of left bundle branch block and their clinical significance. *J Electrocardiol* 1969;2:197–206.

16. Salazar J, Lej FA. Electrocardiographic changes following surgical repair of ostium primum defect. *Acta Cardiol.* 1978;33(1):55-61.
17. Strauss DG, Selvester RH, Wagner GS. Defining left bundle branch block in the era of cardiac resynchronization therapy. *Am J Cardiol.* 2011;107(6):927-34.
18. Surawicz B, Childers R, Deal BJ, et al. AHA/ACCF/HRS recommendations for the standardization and interpretation of the electrocardiogram: part III: intraventricular conduction disturbances: a scientific statement from the American Heart Association Electrocardiography and Arrhythmias Committee, Council on Clinical Cardiology; the American College of Cardiology Foundation; and the Heart Rhythm Society. Endorsed by the International Society for Computerized Electrocardiology. *J Am Coll Cardiol.* 2009;53(11):976-81.
19. Te-Chuan Chou, Helm RA. The diagnosis of Right Ventricular Hypertrophy in the presence of Left Bundle Branch Block. In *Proc. Xith International Vectorcardiography Symposium – North Holland Publishing Company; 1971. pp. 289-96.*
20. Tranchesi J, Moffa P, Ebaid M. Right axis deviation in left bundle branch block: An electrovectorcardiography. *Proceedings of the Xith International Symposium on Vectorcardiography. New York, North-Holland, 1971.*
21. Vera Z, Ertem G, Cheng TO. Left bundle branch block with intermittent right axis deviation. Evidence for left posterior hemiblock accompanying predivisional left bundle branch block. *Am J Cardiol* Dec 1972;30 (8):896–901.