

Different ECG patterns at presentation in ACS

D. Goldwasser

F. Molina

A. Bayes de Luna

Acute Coronary syndromes:

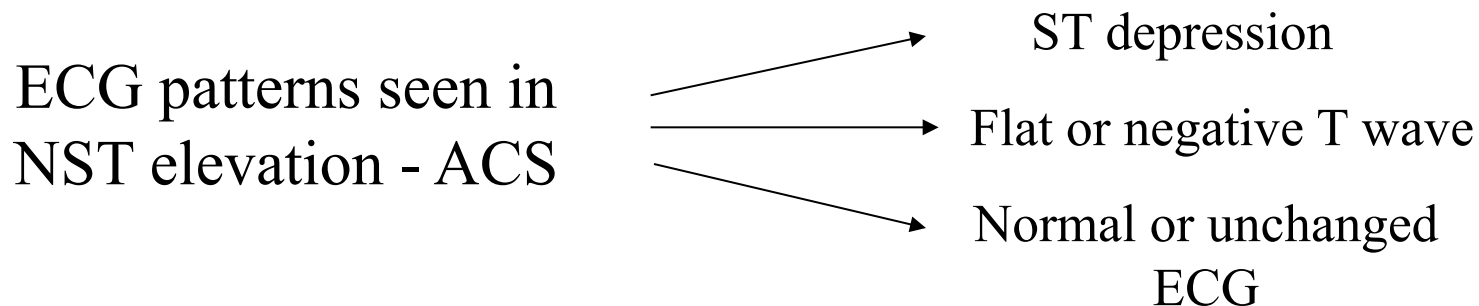
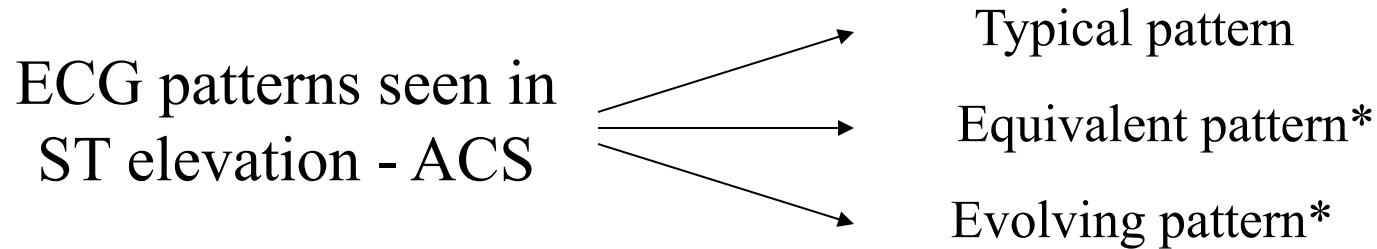
The importance of the ECG

- There are two types of ACS: STE- ACS and Non STE-ACS
- The most important differences may be seen in next figure.

	Stable Angina	Non- ST Elevation ACS	ST Elevation ACS evolving to Q wave MI
Angiographic Thrombus	0-1%	40-75%	>90%
Morphology	Smooth	Ulcerated	Occluded
Acute Coronary Occlusion	0-1%	10-25%	>90%
Angioscopy	No clot	"White clot"	"Red clot"

- With the help of the ECG is possible to decide if a patient presents a STE- ACS or a Non STE-ACS and has great importance for risk stratification and therapeutics implications.
- In this lecture we will comment all the ECG changes that can be present in both types of ACS.

ACS - Classification basing on ECG changes



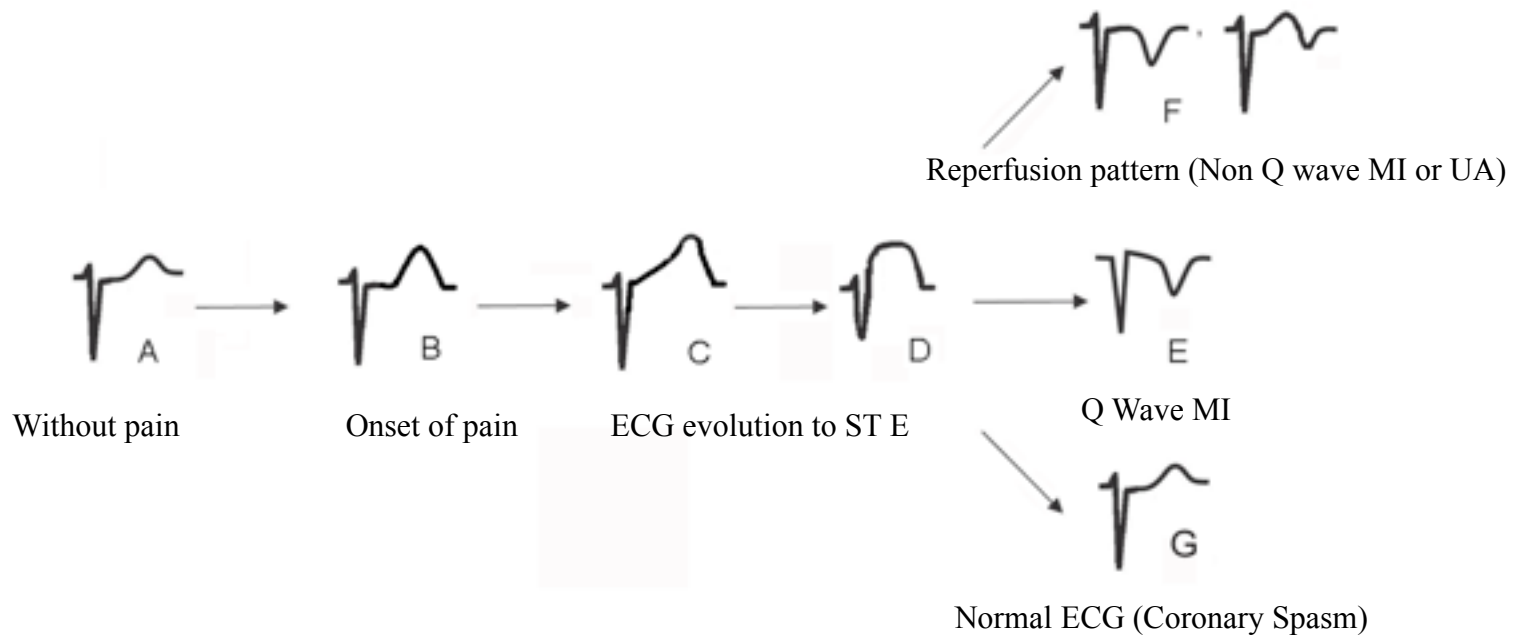
* This patterns does not present evident ST elevation but are seen in patients with STE-ACS

See next slides

STE: Clinical Syndromes

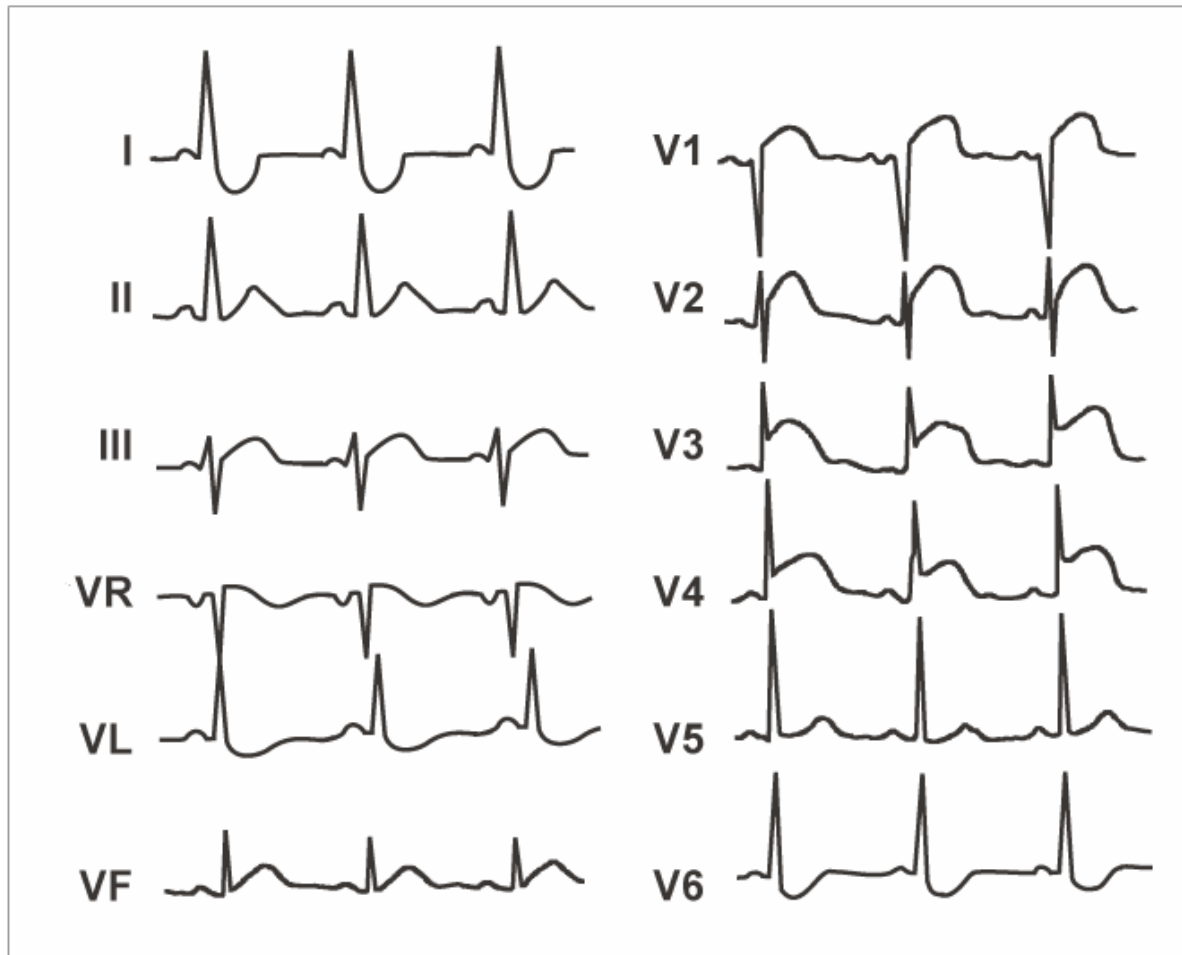
- The STE in the context of ACS is an ECG change that usually means a complete and sudden coronary artery occlusion.
- This ECG change helps to choose the best treatment.
- There are different ECG changes that we may see in this situation (see next figure)
 - A) Basal ECG without pain
 - B) Rectified ST and tall and peaked T wave with a lengthening of the QTc at the first seconds or minutes after the onset of pain.
 - C) and D) ST elevation if the artery still occluded
- At this moment the patient evolves to different clinical situations
 - E) Q wave MI or equivalent, with negative T wave secondary to necrosis
 - F) Reperfusion pattern (spontaneous or therapeutic) with deep, symmetric and negative T wave
 - G) Rarely the ECG returns to basal, this happens in cases of coronary spasm (Prinzmetal angina)

STE-ACS - Clinical syndromes



STE-ACS - Typical pattern

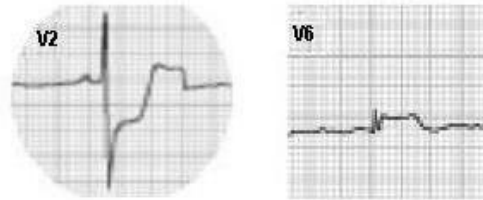
- ST elevation in 2 or more contiguous leads is the typical pattern of STE-ACS



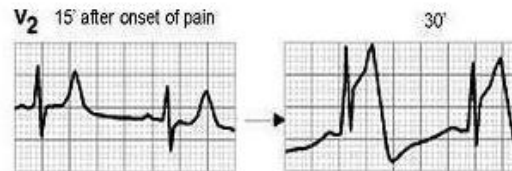
- The STE-ACS may present other ECG patterns than ST elevation
- In the next slides we will show the most important patterns

Atypical patterns of ACS with ST elevation (ACS - STE)

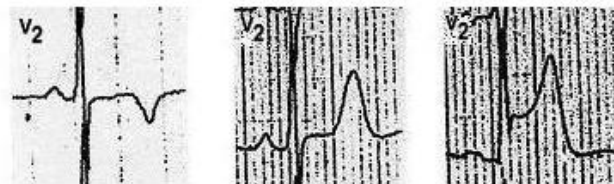Pattern A:



Pattern B:



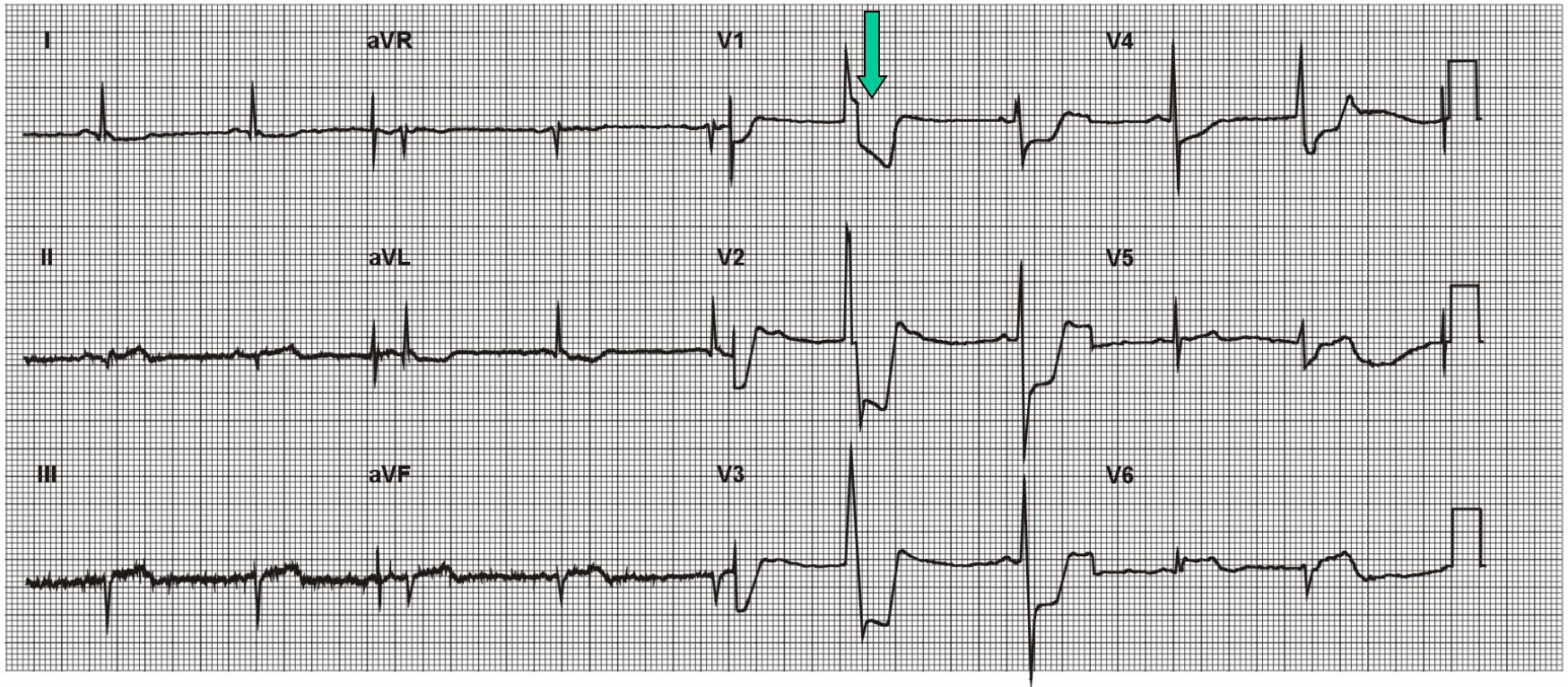
Pattern C:



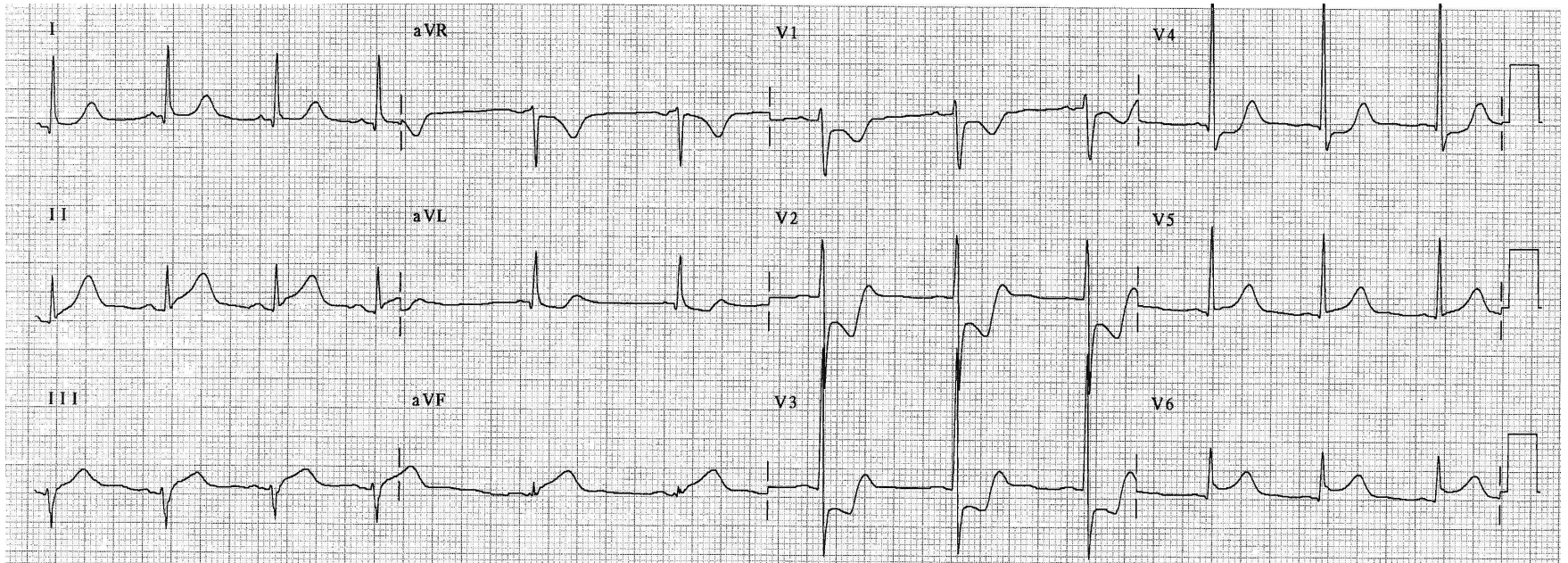
Pattern A: STE-ACS - Equivalent pattern

- STE-ACS in which the ECG pattern is ST depression is the most important change with maximal change in V1-V3 as a mirror image of the lateral and infero-basal area.
- Usually, but not always, is evident a low ST elevation in inferior leads and V5-V6
- The culprit artery is usually LCX and the area at risk is the infero-lateral zone
- This pattern usually is wrongly confounded with NSTEMI ACS
- Is an equivalent of STE-ACS with this clinical and therapeutic implications.

- In the next figure we can see an example of this pattern, look the ST depression in V1 to V4. Observe that the major ST depression occurs in presence of ventricular premature beat (arrow).
- In the other hand we can see the minimal ST changes in the inferior and lateral leads (see figure)

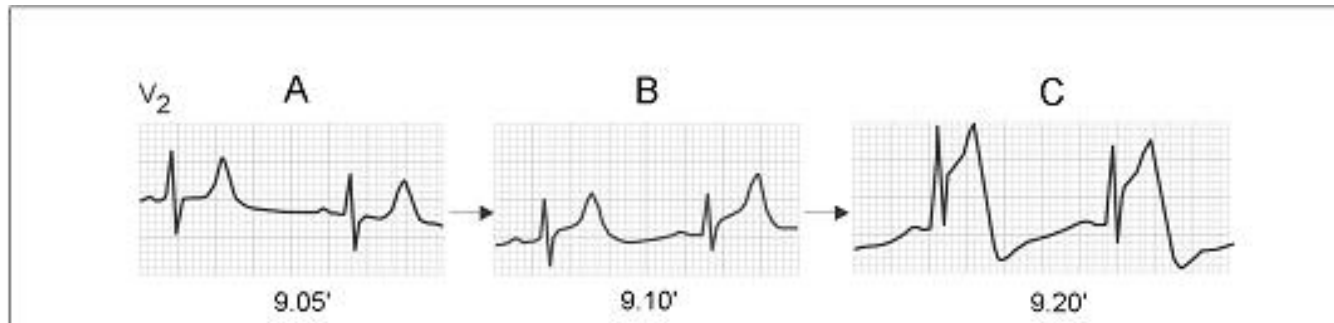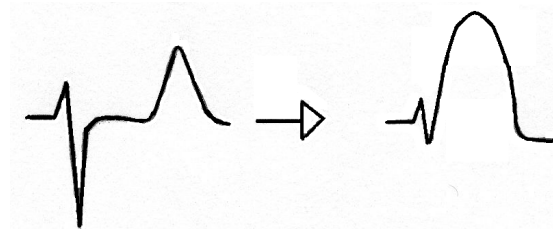


- The next figure shows another example of the equivalent pattern.



Pattern B: STE-ACS - Evolving pattern

- Hyperacute phase
- The first seconds/minutes in the STE-ACS
- The changes are secondary to the initial subendocardial ischemia
- Rectified ST and tall and peaked T wave with a lengthening of the QTc are the most important changes.



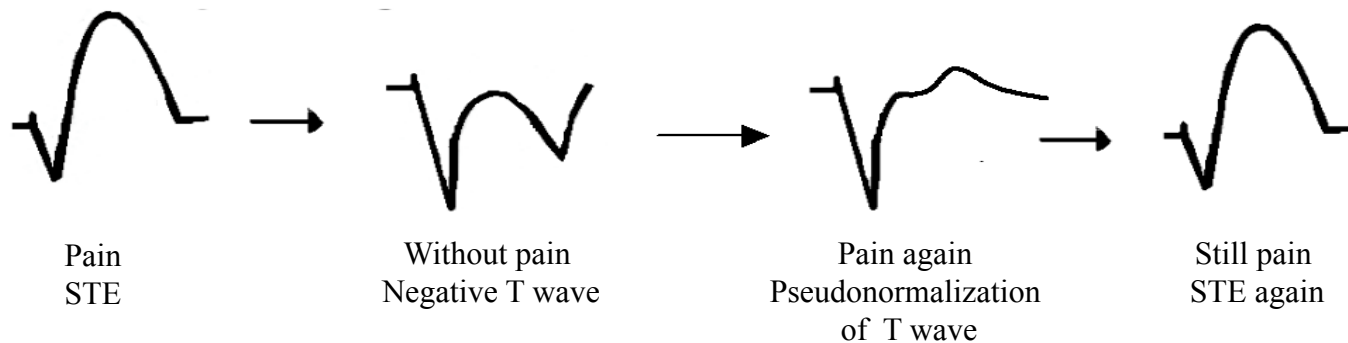
Pattern C: STE-ACS - Evolving pattern

- Post-ischemic changes: Negative T wave

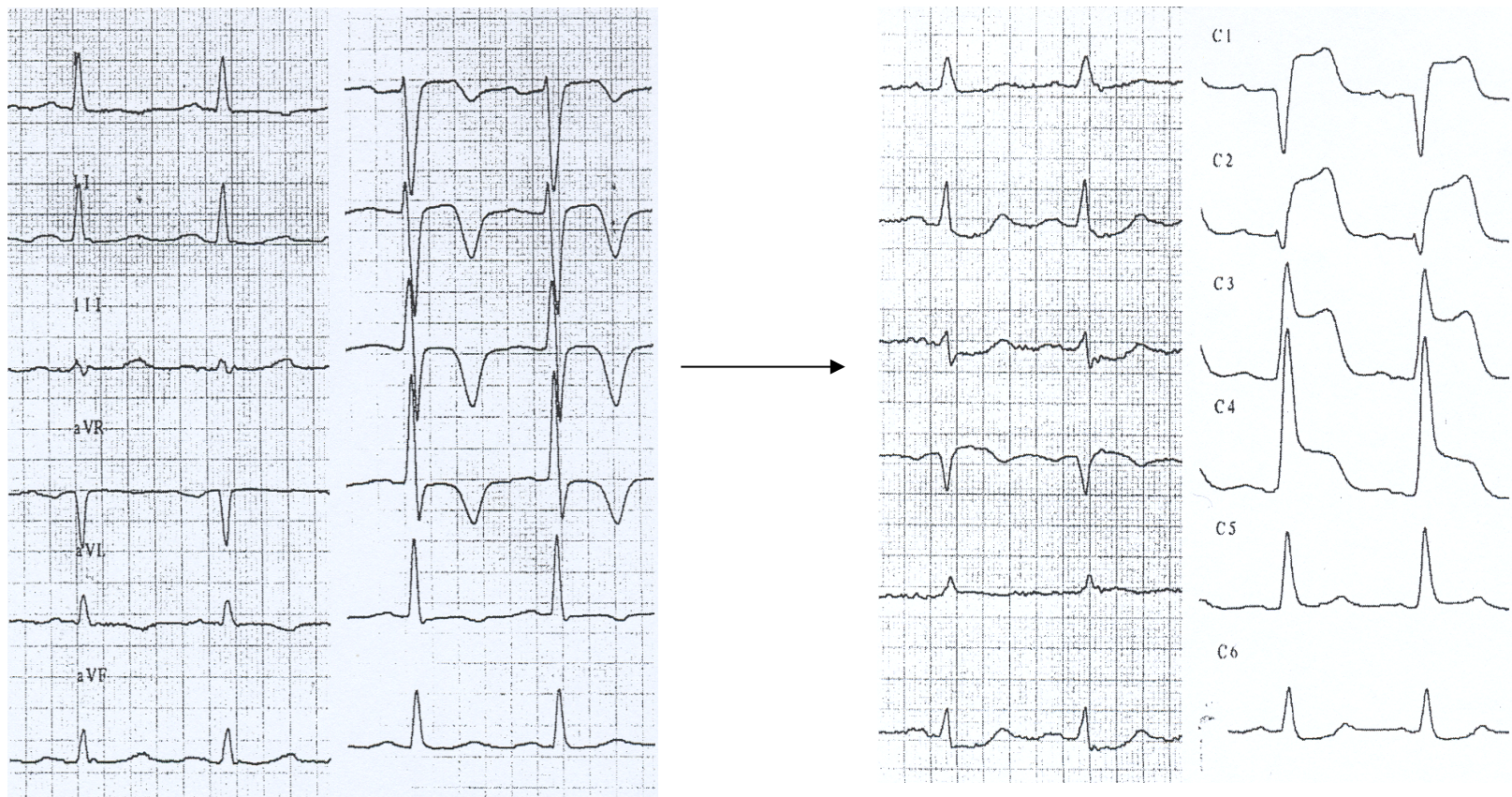
- Deep, symmetric and negative T wave usually in absence of pain but with history of recently chest pain.
- There is not active ischemia, but the ECG shows changes due to reperfusion (spontaneous or therapeutic)
- The artery is more or less open but there are differences between spontaneous or therapeutic reperfusion.

1) A new occlusion is possible in the next hours and then the STE appears especially if the pattern appears without therapeutic reperfusion (spontaneous) in which case the urgent coronariography is recommended .

2) If the patient presents this pattern as a result of therapeutic procedures (thrombolysis or PCI), the artery is open and is a sign of good response to the treatment.

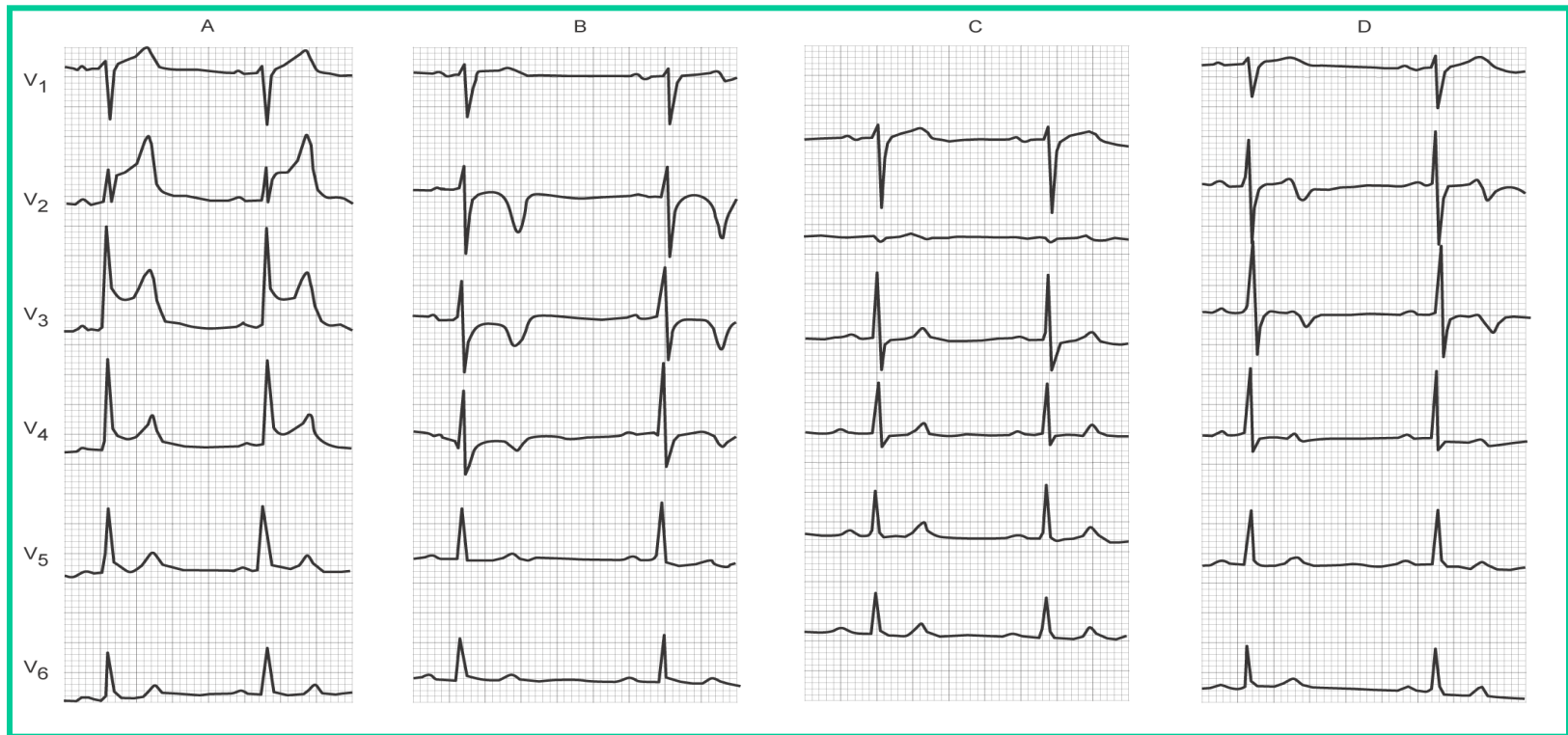


- In the next figure we will see an example of this pattern.
- A: ECG at basal state without pain. The patient was admitted because he suffered anginal pain in the last 6 hours.
- B: The ECG was recorded from the same patient in the hospital when a new episode of anginal pain began. Compare the repolarization (ST/T) with the first ECG.



The next figure shows the ECG evolution of a patient who presents STE- ACS (A) During pain with ST elevation, (B) after PCI with negative T waves (reperfusion pattern), (C) Six hours after the PCI with a new event of pain, note the normalization of the ECG. In some cases with not very typical pain it is possible to think in other causes of chest pain, but in this context we must think that this 'normal' ECG is an intermediate situation between negative T wave and ST elevation (pseudonormalization of the T wave)(see next slide). (D) ECG post new PCI with evidence again of new negative T waves (reperfusion pattern).

In some cases with not very typical pain it is possible to think in other causes of chest pain, but in this context we must think that this 'normal' ECG is an intermediate situation between negative T wave and ST elevation (pseudonormalization of the T wave)(see next slide). (D) ECG post new PCI with evidence again of new negative T waves (reperfusion pattern).



Pain

Post PCI

Again pain

Post PCI

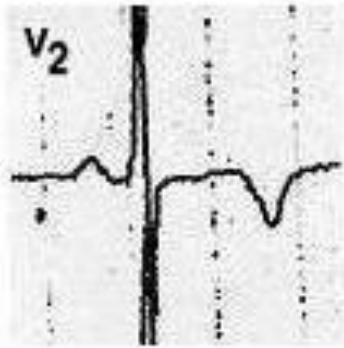
3 PM

5 PM

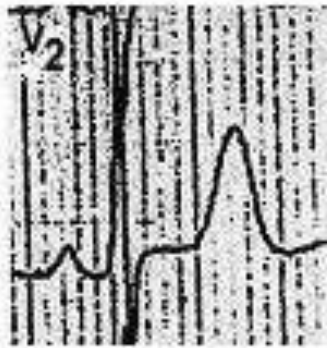
11 PM

2 AM

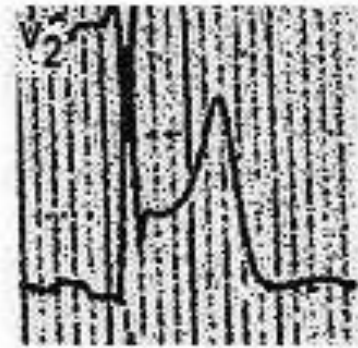
This figure shows the lead V2 from a patient who has suffered a chest pain episode. In A: Patient who has presented an anginal pain episode recently now without pain. Is evident the negative and symmetric T wave. B: A new episode of pain in the same patient with pseudo normalisation of the T wave. C: Evolving to ST elevation with persistence of pain.



A



B

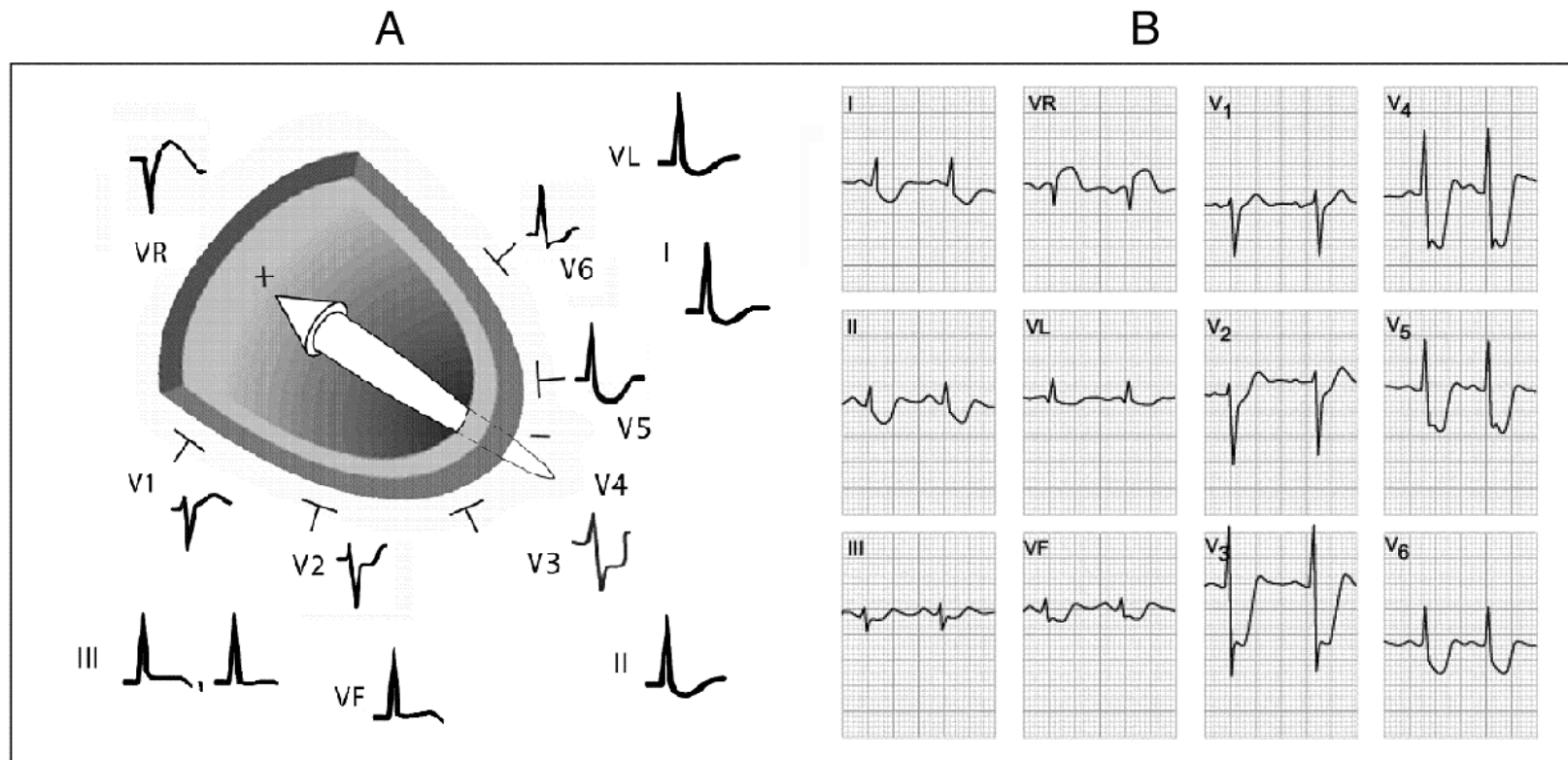


C

Non STE-ACS: Clinical Syndromes

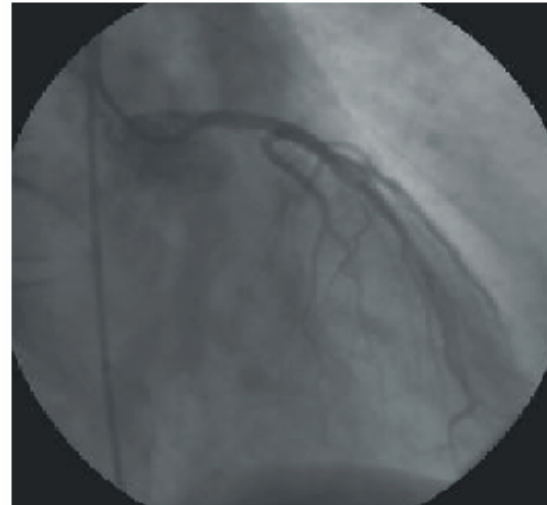
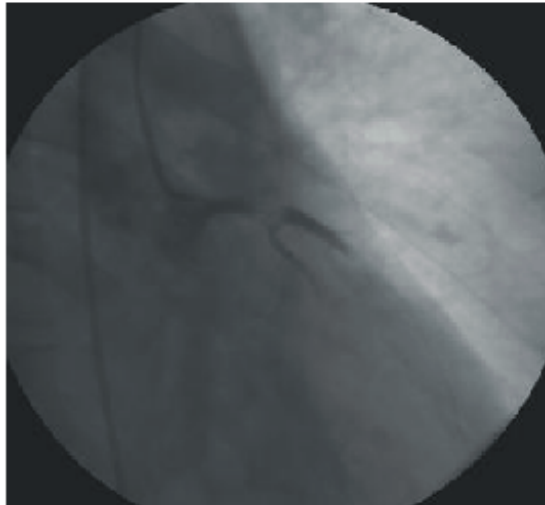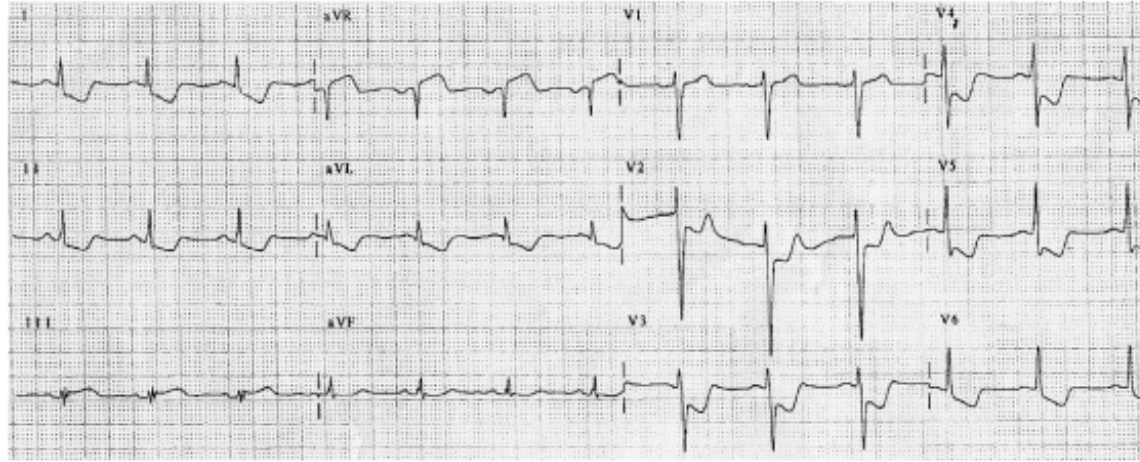
Extensive ischemia:

- Presence of ST depression in > 7 leads
- Usually the T wave is negative
- STE in aVR and V1 is frequent
- Left main trunk (LMT) or equivalent is the culprit vessel.
- Is the pattern with worst prognosis in the group of NSTEMI ACS



In A: Direction of the injury vector in cases of extensive ischemia, look that the head of the vector faces aVR . In B: ECG from a patient with LMT disease, the ECG with pain presents more than 7 leads with ST depression and ST elevation in aVR

Another example of extensive ischemia due to Left main trunk (LMT) in which we can see ST depression in more than 7 leads with ST elevation in VR. Below the coronariography of this patient.

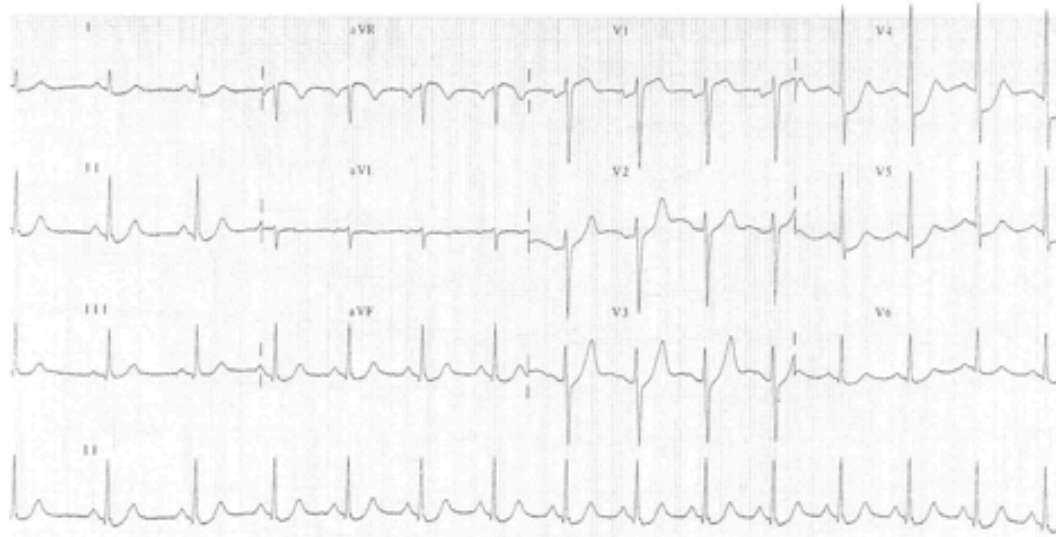


NSTE-ACS:

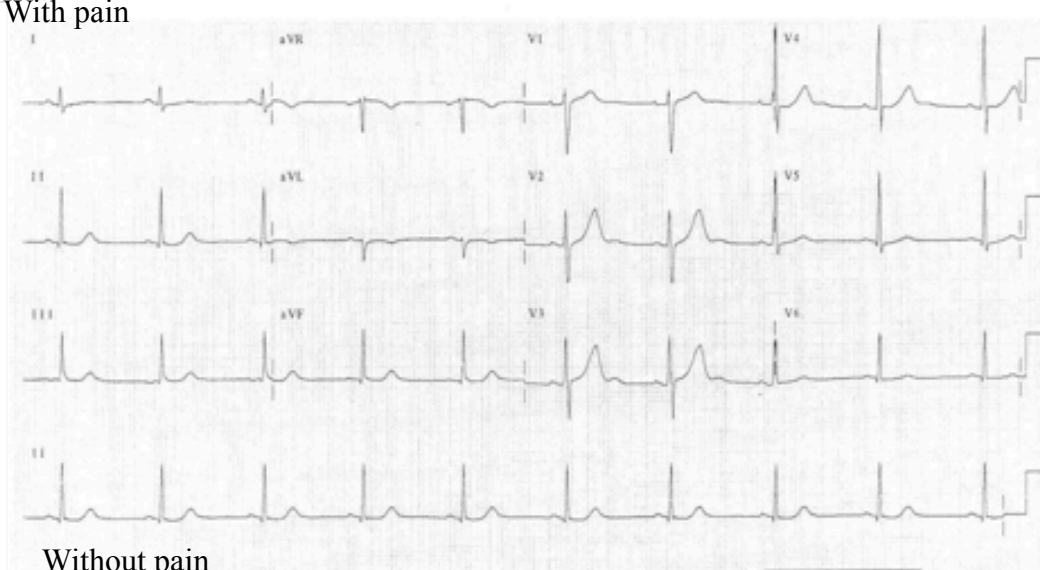
Regional ischemia

- If the ST depression is seen in < 6 leads the ischemia is regional
- Usually is due to subocclusion of 1 vessel
- However ST depression in > 6 leads is seen frequently.
Therefore the differential diagnosis with extensive ischemia is difficult and also is usually impossible to locate the culprit vessel (see next figures)

ECG of a patient with regional involvement (ST depression in less than 6 leads)
Culprit vessel: LCX middle portion

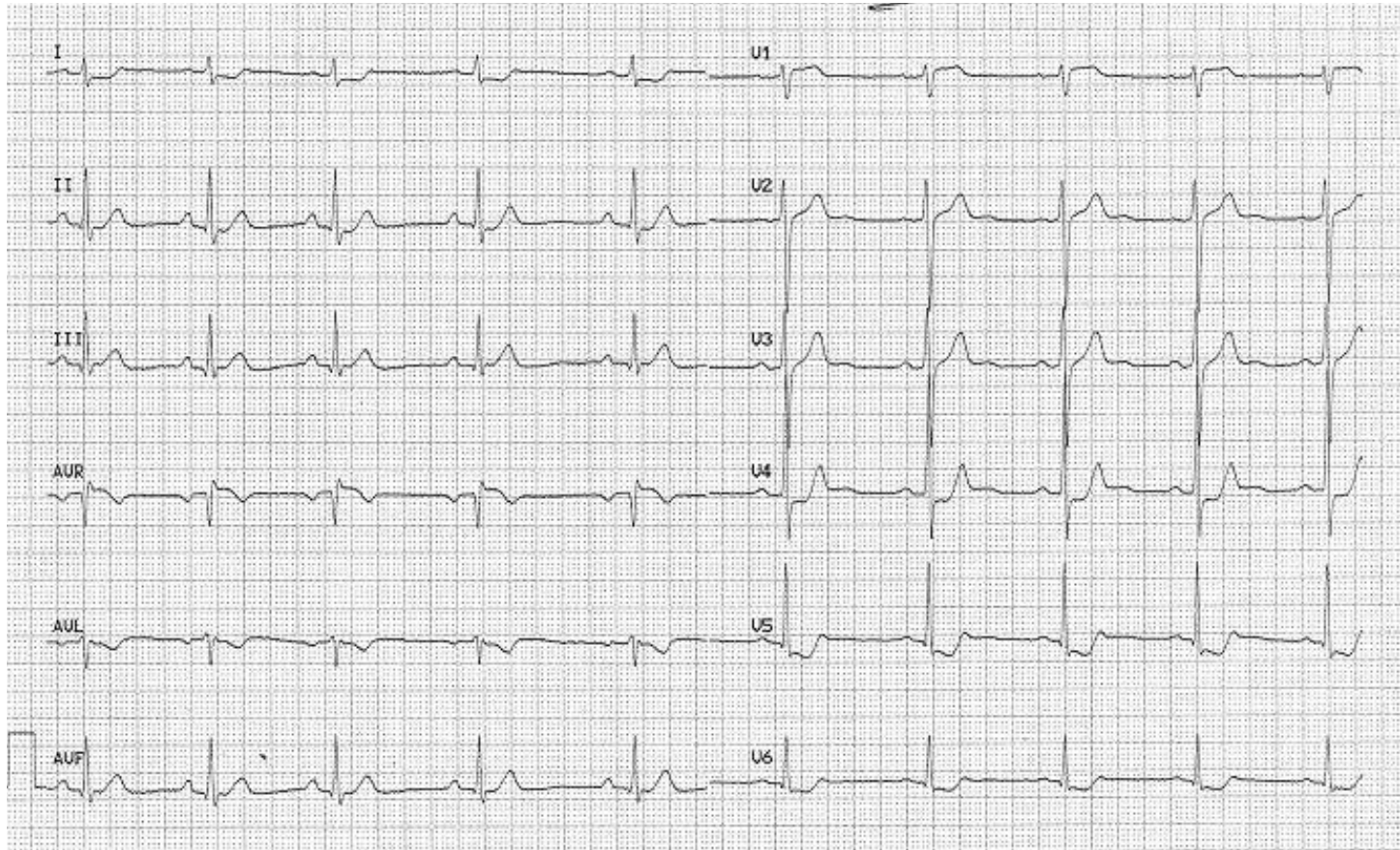


With pain

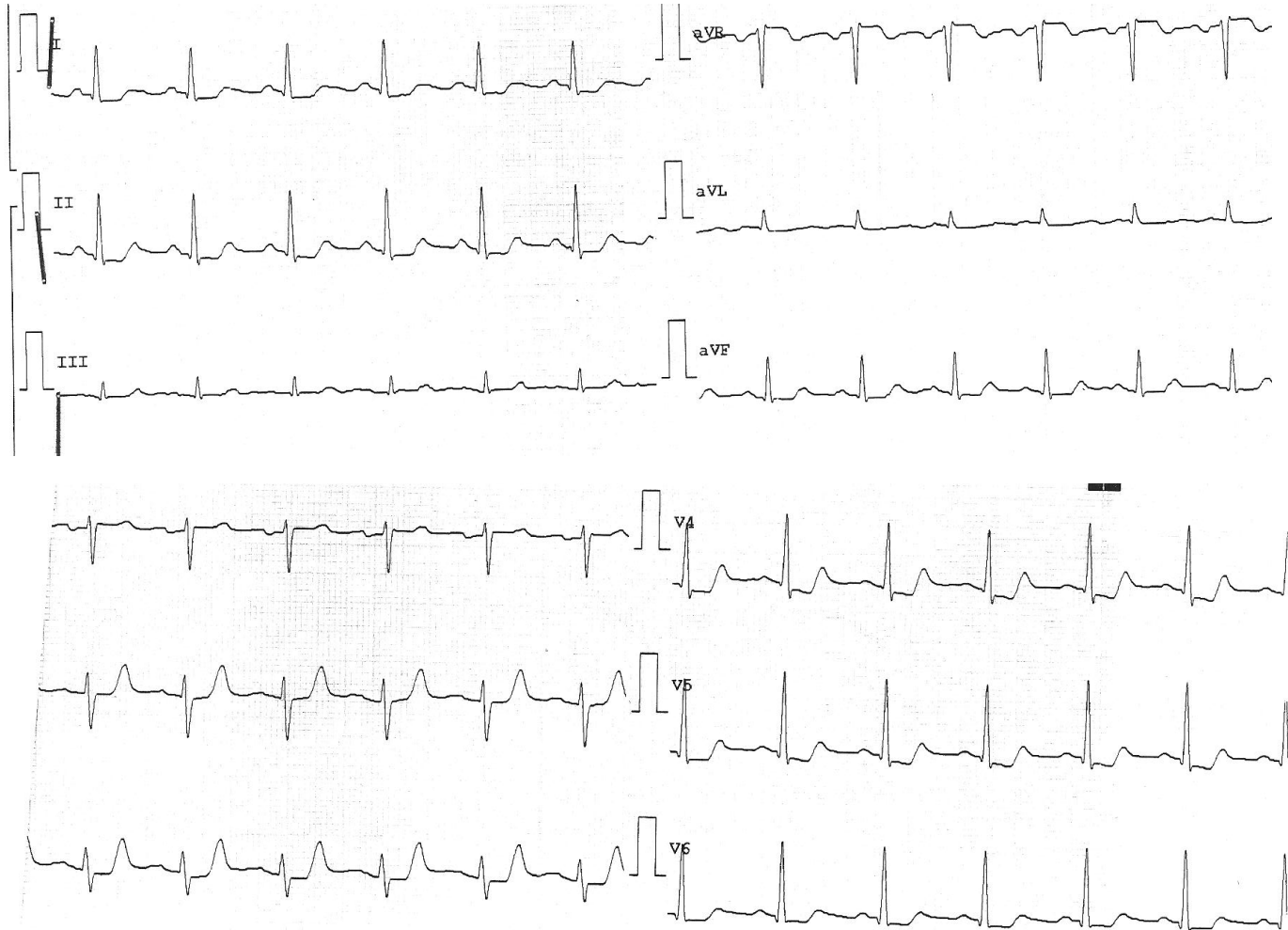


Without pain

Regional involvement: ST depression in 4 leads in this case with STE in VR.
Culprit vessel RCA proximal portion.



This example is a case of regional ischemia with more than 6 leads involved, the culprit artery was LCX

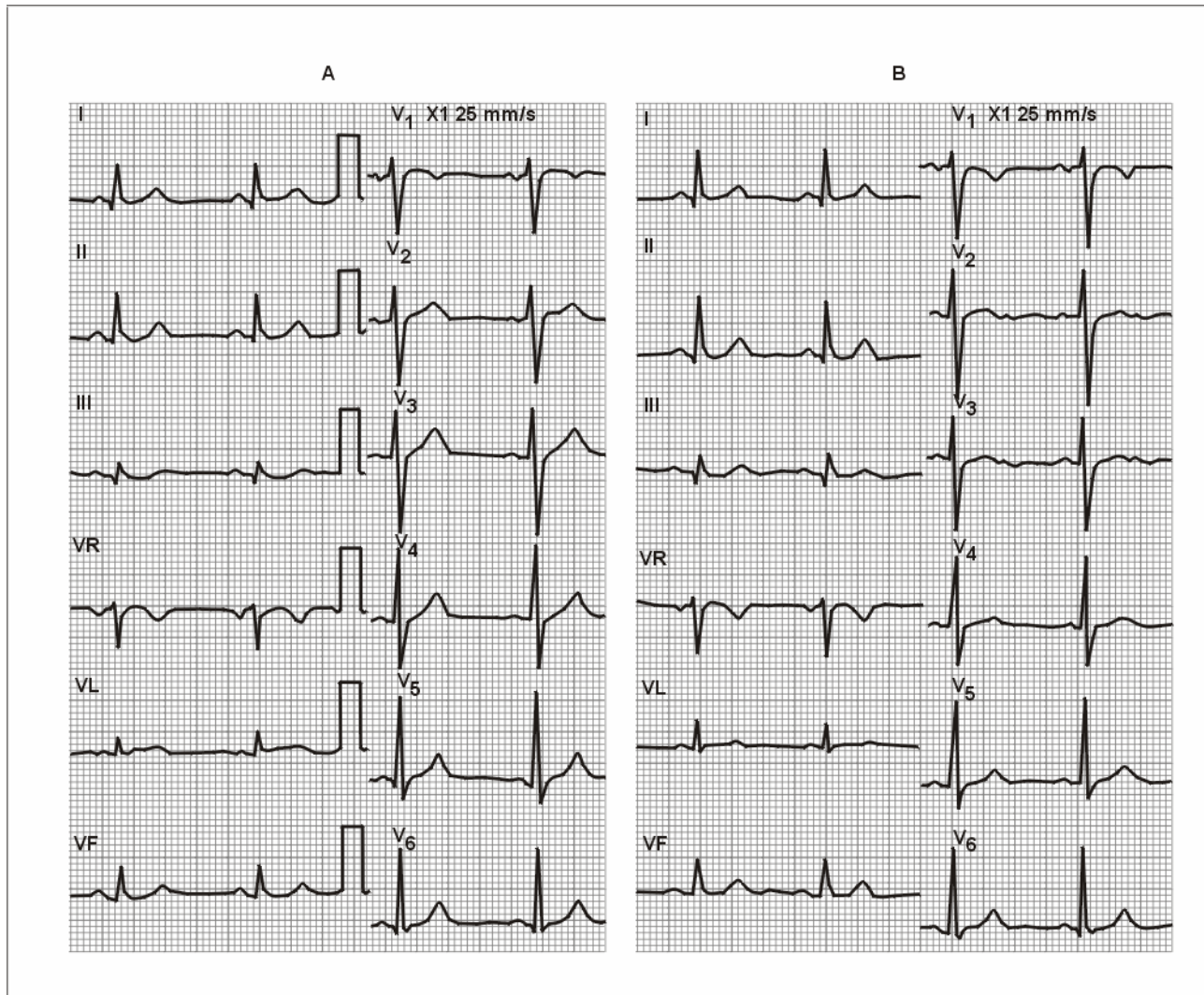


Flat or negative T wave

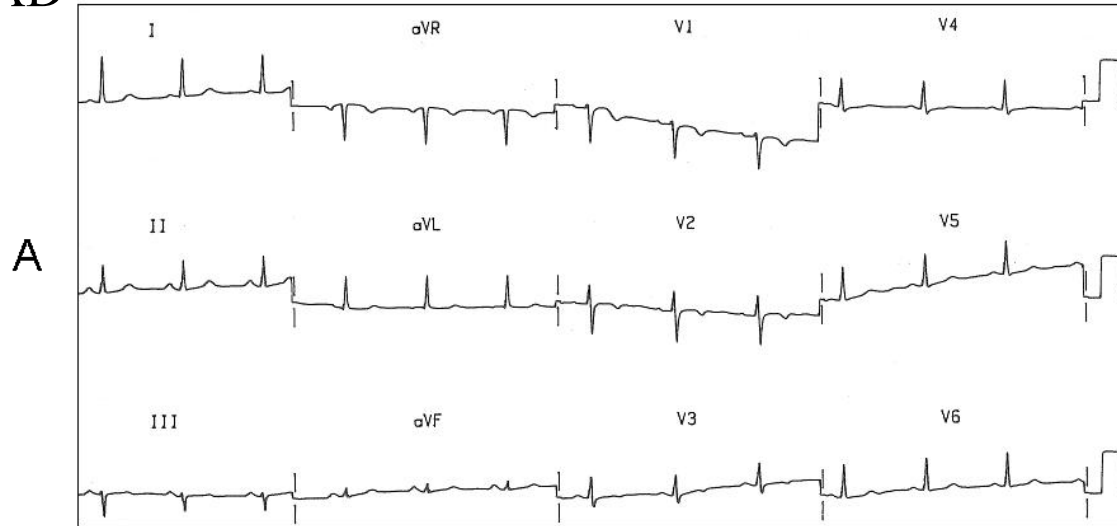
- Sometimes patients with NSTEMI-ACS may present flattened or negative T wave as the only abnormality.
- This pattern is more probably related to partial or total reperfusion than to “active ischemia” and has better prognosis than changes of ST segment.
- The occlusion may be in any artery, usually at non proximal level and is difficult to know which is the culprit vessel.
- In some cases these changes are the only sign of critical coronary subocclusion (see figure next)

In A: ECG of a patient taken 6 months before. In B: Patient with previous chest pain 3 days ago and now, without pain. There are very small changes in the T wave and U wave compared with the ECG taken 6 months before.

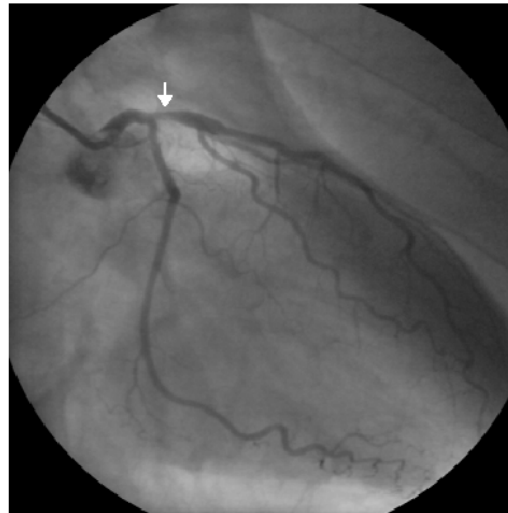
The coronariography shows proximal LAD stenosis resolved by PCI.



ECG of NSTEMI ACS without pain with symmetric and mild negative T wave in V1-V3. The coronariography shows a critical subocclusion of proximal LAD



B





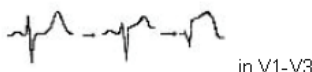




Normal or unchanged ECG

- 15 – 20 % of ACS present normal or unchanged ECG
- If ACS is confirmed, the prognosis is good in cases with normal ECG.
- The absence of ECG changes in case of ACS may be explained by a cancellation of vectors.
- Frequently the cases of ACS with normal ECG correspond to LCX subocclusion.

Confounding Factors

- Bundle branch block, left ventricular hypertrophy or paced rhythm originate changes in the repolarization that makes difficult the interpretation in case of ACS
 - In this cases is very important the clinical criteria
 - The invasive strategy is more beneficial in this cases
 - The prognosis of this patients is usually worst
- (see lectures of A. Perez Riera and Baranowski)

Table 1. ECG patterns of ACS seen in emergency services at admission

A. ECG PATTERNS IN STE-ACS AS THE MOST PREDOMINANT PATTERN	
<p>1) Typical = ST elevation in frontal or horizontal planes with often mirror image of ST depression in other leads</p> <p>2) Atypical:</p> <ul style="list-style-type: none"> - Equivalent = ST depression in V1-V3 with often smaller ST elevation in II, III, VF / V5-V6 - Patterns without ST elevation during some period of the evolving process <ul style="list-style-type: none"> • Hyperacute phase. Tall T wave with rectified or even small ST depression • Deep negative T wave in V1-V4-5 (reperfusion pattern) 	   <p>in V1-V3</p>  <p>With pain No pain Pain again</p>
B. ECG PATTERNS IN NON STE-ACS	
<p>1) ST depression as the most predominant pattern</p> <ul style="list-style-type: none"> - In >7 leads (<u>circumferential involvement</u>) with ST elevation in lead aVR (LMT/equivalent) - Typically < 6 leads ST depression, often the leads with ST depression are >7 (<u>regional involvement</u>) (more difficult to locate) <p>2) Flat or negative T wave as the most predominant pattern Sometimes a negative U wave may be seen.</p> <p>3) Normal ECG, nearly normal or unchanged during ACS</p>	  
C. ECG PATTERNS IN PRESENCE OF CONFOUNDING FACTORS = LVH, LBBB, PM, WPW	

We did a prospective study with 200 consecutive patients who consult to emergency room of the Hospital Sant Pau with diagnosis of ACS to evaluate the incidence of the ECG patterns described previously (see next figure).

The patients with negative T wave (3) was the group with best prognosis in the group of STE-ACS.

We doesn't find any patient with hyperacute pattern (4) probably because this pattern is present in the initial minutes of the STE-ACS and we cannot see it at the admittance.

On the other hand patients with extensive ischemia (5) were the patients with worst prognosis in the group of NSTEMI-ACS.

We can see a big number of patients with normal ECG (8) and confounding factors (9). (see next slide).

However we need more number of patients to take definitive conclusions about prognosis and clinical events.

Pilot study with the incidence of the different ECG patterns

