

# Acute anterior ST segment elevation myocardial infarction complicated with transient intraventricular conduction disturbance



<https://ekgvcg.wordpress.com/>

Raimundo **Barbosa-Barros M.D.<sup>1</sup>**; Andrés Ricardo **Pérez-Riera M.D.Ph.D.<sup>2</sup>**; Luiz Carlos **de Abreu P.h.D.<sup>3</sup>**

1. Chief of the Coronary Center of the Hospital de Messejana Dr. Carlos Alberto Studart Gomes. Fortaleza –CE- Brazil
2. Post-Graduates Advisor at Design of Studies and Scientific Writing Laboratory in the ABC Faculty of Medicine - ABC Foundation - Santo André – São Paulo – Brazil
3. Visiting Scientist at Program in Molecular and Integrative Physiological Sciences (MIPS), Department of Environmental Health | Harvard T.H. Chan School of Public Health.

## Case report

A 58-year-old Caucasian man was admitted to our emergency department due to prolonged oppressive retrosternal chest pain for 3 hours associated with shortness of breath and cold diaphoresis.

He had several risk factors: hypertension, low-density lipoprotein cholesterol elevated levels, central obesity (waist circumference = 112 cm and body mass index (BMI) =34), diabetic intolerance, and addiction to tobacco.

On physical examination, the jugular veins were noted 3 cm above the clavicles with the patient in a 45° semirecumbent position.

Absence of hepatojugular reflux (the height of the neck veins increases only 2 cm with moderate pressure applied over the middle of the abdomen for 30 seconds).

His blood pressure was 95/80 mm Hg (pulse pressure/systolic pressure ratio > 0.25) and alternating discrete irregular heart rate 107-111 bpm.

The point of maximal impulse was located in the midclavicular line at the left fifth intercostal space and it is covered by the tip of one index finger.

A third protodiastolic gallop or ventricular gallop (S<sub>3</sub>) was heard without murmurs with gallop cadence.

Absence of rales in both pulmonary bases.

The liver edge was palpable smooth, uniform, non-tender and non-painful at 1 cm of costal border.

Absence of lower extremity edema.

The electrocardiograms are shown in the next slides.

### Question

What are the diagnoses of both electrocardiograms?

## Português reporte de caso

Homem caucasiano de 58 anos, admitido em nosso departamento de emergência por dor retroesternal típica opressiva prolongada que havia iniciado há 3 horas associada a falta de ar e sudorese fria.

Vários fatores de risco para doença arterial coronariana estavam presentes: hipertensão arterial, níveis LDL-C elevado, obesidade centrípeta (circunferência da cintura = 112 cm e índice de massa corporal (IMC) = 34), intolerância a glicose e tabagista.

Ao exame físico, jugulares a 3 cm acima da clavícula com o paciente em uma posição reclinada a 45°. Ausência de refluxo hepatojugular.

Pressão arterial 95/80 mm de Hg (relação da pressão do pulso / pressão sistólica > 0,25) ritmo cardíaco irregular com discreta variação da FC 107-111 bpm.

Choque da ponta foi localizado na linha médio clavicular no quinto espaço intercostal esquerdo e é coberto com um dedo indicador.

Presença de terceira bulha (S<sub>3</sub>) protossistólica com cadencia de galope. Ausência de sopros.

Ausência de estertores em ambas as bases pulmonares.

Fígado liso, uniforme, não doloroso e palpável a 1 cm da borda costal direita.

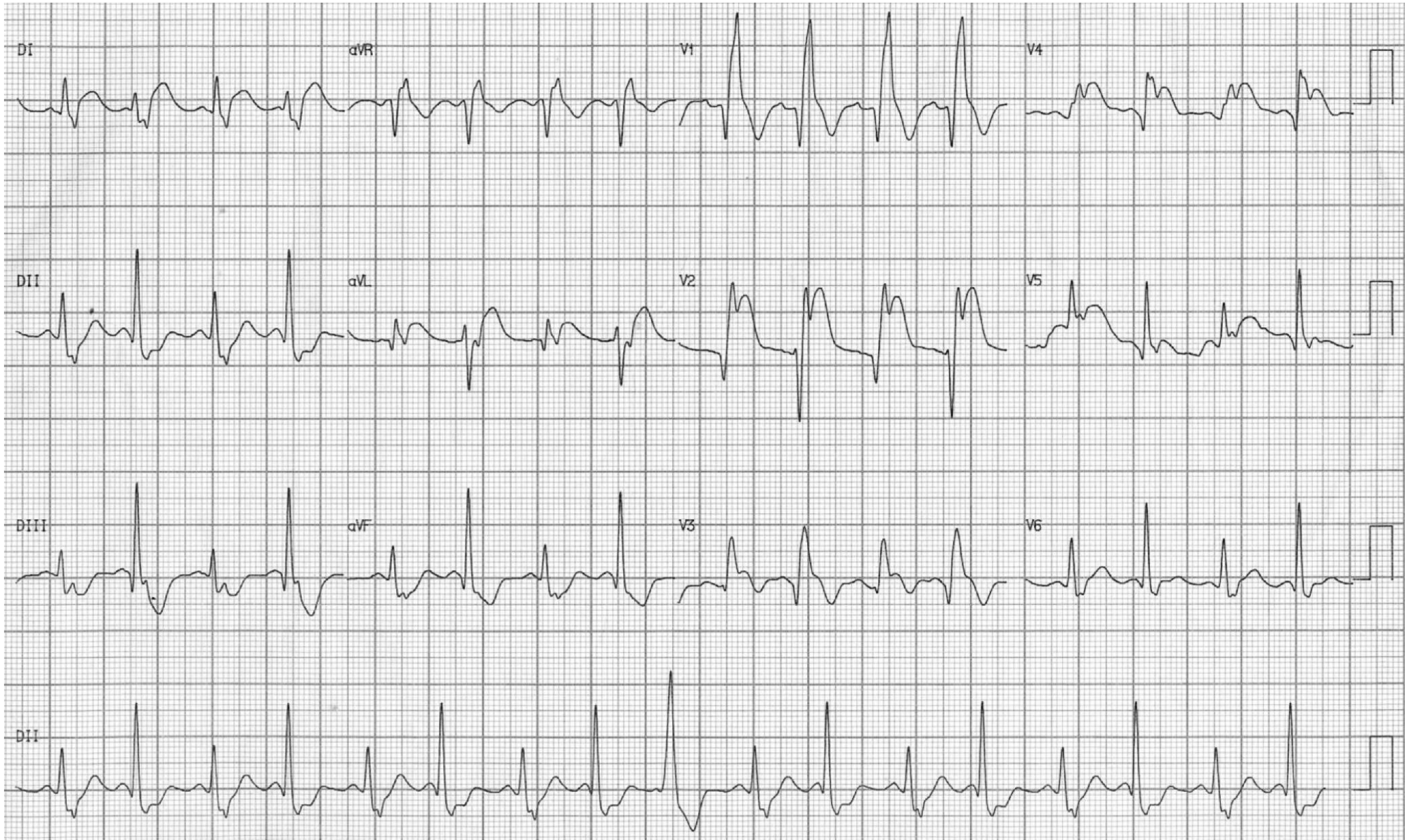Ausência de edema de membros inferiores.

Os eletrocardiogramas são mostrados nos próximos slides.

Pergunta

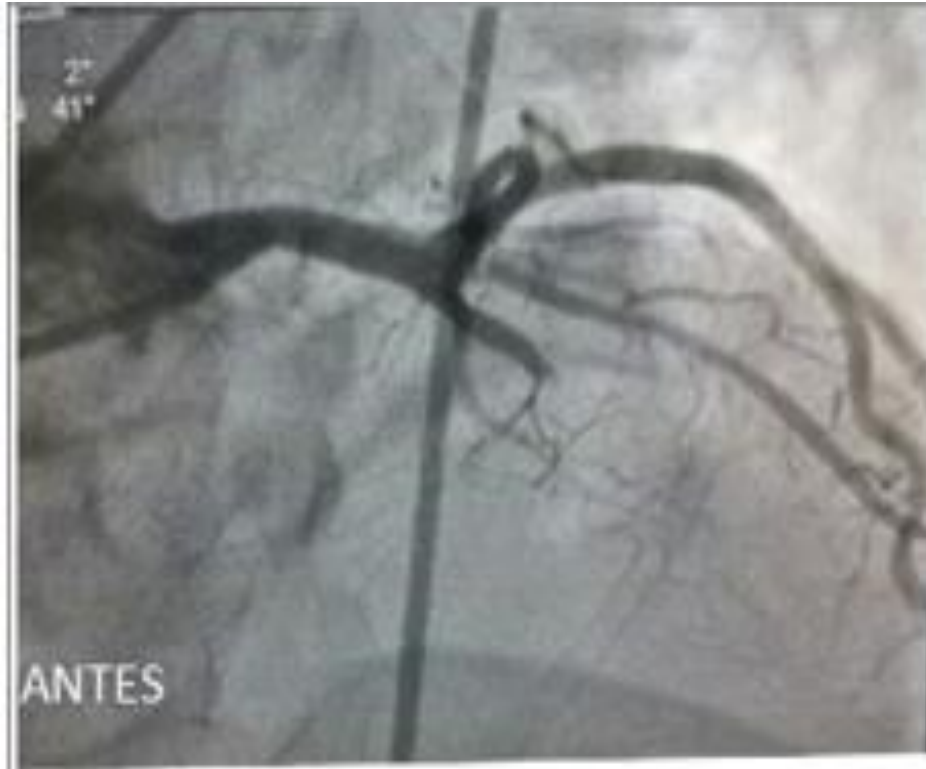Quais os diagnósticos de ambos os eletrocardiogramas?

# ECG performed at admission

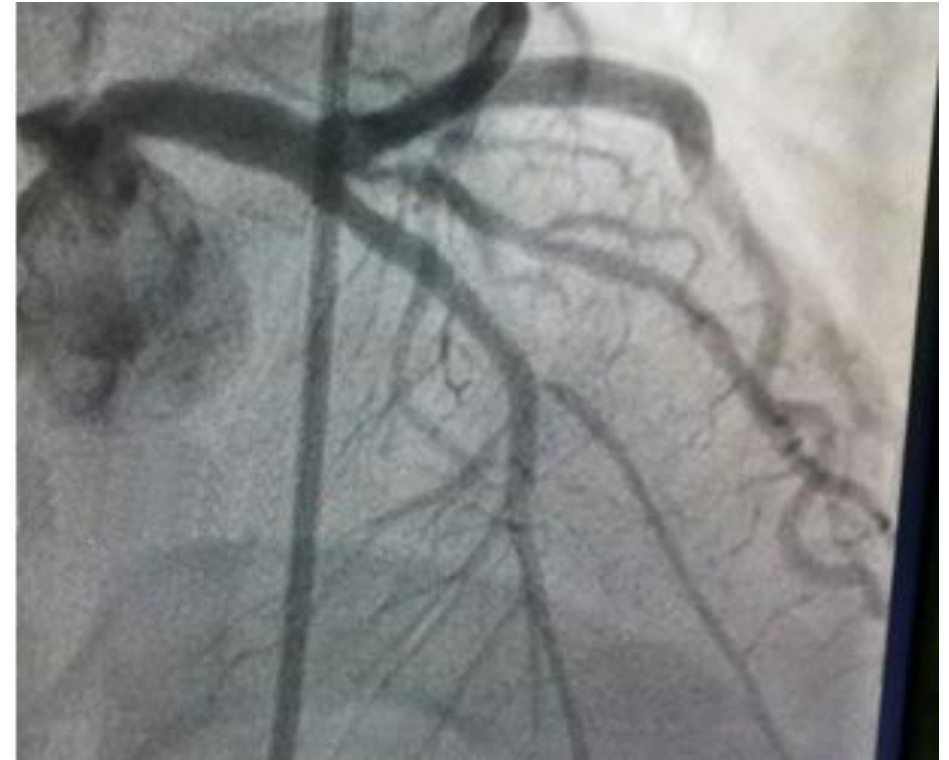

# Primary percutaneous coronary intervention with stent implantation in LAD in the AP cranial view

Before procedure

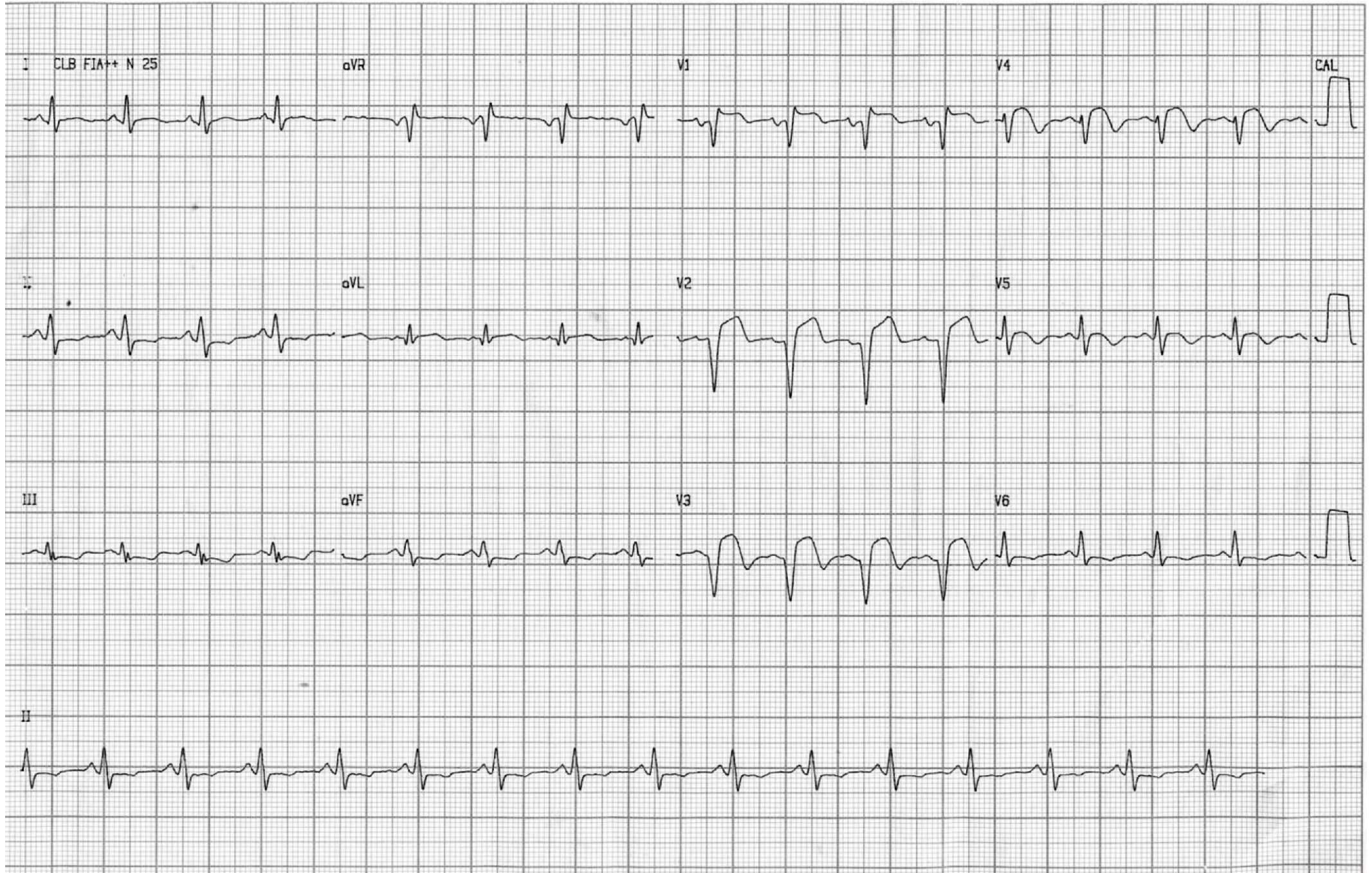


After stent implantation in LAD





# ECG performed immediately after stent implantation



## Colleagues opinions

The ECG shows an acute anteroseptal MI with rate alternate left posterior hemiblock pattern. This resolves after PCI of LAD and shows resolving anteroseptal MI. Of interest is the RBBB and 2:1 block in the Posterior fascicle which is associated with a decrease in the anterior q waves, probably because the initial forces are oriented left and superior

**Melvin M Sheinman**

Department of Cardiac Electrophysiology, University of California San Francisco, San Francisco, California, USA. [scheinman@medicine.ucsf.edu](mailto:scheinman@medicine.ucsf.edu)

Professor of Medicine



Dear friends, Professor Andrés Ricardo, Raimundo, and Luiz Carlos,

The **first ECG** shows proximal anteroseptal infarction, involving the long diagonal artery by causing ST segment elevation in aVL and I and concomitant ST depression in III and aVF (longitudinal remodeling of the base of the heart and the inferior wall, which always go together with rare exceptions).

ST segment elevation in V1 and right bundle branch block suggest that the second septal perforator artery (S<sub>2</sub>) irrigates only the right septum. This leads us to conclude that this artery is small, not dominant, because it does not irrigate the inferior wall. ST segment elevation in lead V1 in the admission ECG of patients with anterior wall AMI is strongly related to ST segment elevation in lead V3R and is associated with a small conal branch. Lead V1 reflects the right paraseptal area supplied by the septal branches of the LAD, alone or together with the conal branch. The absence of ST segment elevation in lead V1 during anterior AMI suggests that the IVS is protected by a large conal branch in addition to the septal branches of the LAD (double circulation)(**Ben-Gal 1997; Sclarovsky book**). Usually, anterior infarctions that irrigate the mid anteroseptal wall, present with right bundle branch block and left anterior fascicular block, which did not happen in this case.

There is intermittent deviation of the QRS frontal axis to the right (intermittent left posterior fascicular block), which could lead us to think of some anatomical anomaly.

We could theorize that the RCA/PDA system does not irrigate the posteroinferior fascicle, and it is the left anterior descending artery(LAD) that does so. These blocks that I have called ischemic blocks, disappear with reperfusion, but when they persist, they evolve with complete AV block, and a more ominous prognosis. ST segment elevation in V1 and V2 suggests biseptal ischemia. This scenario fosters a tendency to high septal rupture. V5 and V6 are less involved in the process by the anterolateral protection exercised by developed LCX artery and concomitant short RCA.

The **second ECG** shows a complicated evolution of the procedure, because there was no myocardial reperfusion, which is called coronary reperfusion without muscle reperfusion. This phenomenon suggest microcirculation destruction, no wash out, therefore the Ph is very low(tissue acidosis). The hydrogen, calcium, potassium, and detritus are accumulated in this area. But the inverted T waves



in V5-V6 the inferior lateral wall are reperfused, and V4 is the ischemic border area. The upper area of the lateral wall is not reperfused.

There is inferior anteroseptal aneurysmatic dilatation. This is very important and should be taken into account, because after 48 hours, intracavitary thrombi frequently appear, with a high risk of embolism (**Sagie 1991: Sclarovsky book**).

The cases of stroke that appear during the evolution of infarctions, are due to this cause. The hope in this case is that from V5, V6, lateral hypertrophic remodeling develops, helping to maintain LV ejection fraction.

Warm regards and congratulations to this fantastic Brazilian trio.

1. Ben-Gal T, Sclarovsky S, Herz I, Strasberg B, Zlotikamien B, Sulkes J, Birnbaum Y, Wagner GS, Sagie A. Importance of the conal branch of the right coronary artery in patients with acute anterior wall myocardial infarction: electrocardiographic and angiographic correlation. J Am Coll Cardiol. 1997;29(3):506-1.
2. Sagie A, Strasberg B, Imbar S, Rechavia E, Sclarovsky S. Value of the electrocardiogram for prediction of left ventricular mural thrombus in anterior wall acute myocardial infarction. Am J Cardiol. 1991;68(9):957-9.
3. Sclarovsky S. Electrocardiography of Acute Myocardial Ischemia and Infarction 1st Edition: Chapter 4, 5 and 7 **ISBN-13:** 978-1853173806; **ISBN-10:** 1853173800.



**Samuel Sclarovsky MD Israel**

- Professor Emeritus - Tel Aviv University  
- Director of Telemedicine, Procardia Medical Center  
. samuel\_s@netvision.net.il

## Spanish

Queridos amigos Profesor, Andrés Ricardo , Raimundo y Luiz Carlos

El primer ECG muestra un infarto antero-septal proximal que involucra la arteria diagonal larga por ocasionar elevación del segmento ST en aVL y I y concomitante depresión del ST en III y aVF(remodelado longitudinal de la base cardíaca y de la pared inferior las cuales siempre van juntas con raras excepciones).

La elevación del segmento ST en V1 y el bloqueo de rama derecha sugiere que la segunda perforante septal irriga apenas el septo derecho. Esto también hace pensar que esta arteria es pequeña no dominante porque no irriga la pared inferior. Habitualmente, los infartos anteriores que irrigan la pared media antero-septal , se presentan con bloqueo rama derecha y hemibloqueo antero-superior izquierdo, lo que no ha ocurrido en este caso Hay desviación intermitente del eje frontal hacia la derecha, (hemibloqueo posterior intermitente), lo que podría hacer pensar en alguna anomalía anatómica. Se podría especular que el Sistema de la coronaria derecha/ descendente posterior no irriga al fascículo pósteroinferior y si la descendente anterior, Estos bloqueos que yo he denominado bloqueos isquémicos desaparecen con la reperfusión, más cuando persisten desarrollan un bloqueo completo de pronóstico mas sombrío.

La elevación del segmento ST en V1 y V2 sugiere una isquemia biseptal. Este escenario propicia una tendencia a ruptura septal alta

V5 y V6, están menos involucradas en el proceso por la protección antero-lateral ejercida por una arteria circunfleja izquierda desarrollada y concomitante coronaria derecha corta

El segundo ECG muestra una evolución complicada del procedimiento porque no ocurrió reperfusión miocárdica, lo que se denomina reperfusión coronaria sin reperfusión muscular.

Existe una dilatación aneurismática antero-septal inferior. Esto es muy importante de tener en cuenta porque a las 48 horas frecuentemente aparecen trombos intracavitarios, con alto riesgo de embolia Los casos de CVA , que aparecen durante la evolución del infarto , se deben a esta causa. La esperanza de este caso es que a partir de V5,V6 comiencen a desarrollar una remodelación hipertrófica lateral, que ayude a mantener el la fracción de eyección

Un fraternal abrazo y felicitaciones a este fantástico trío Brasileño

Samuel Sclarovsky

**Português: Achamos que é taquicardia sinusal, BRD + BDPI intermitente no primeiro ECG com desaparecimento do distúrbio de condução intraventricular após o implante do stent em DA.**

---

We think that the first ECG has sinus tachycardia, RBBB and intermittent LPFB  
In the second ECG intraventricular conduction defect disappear after stent implantation.

**Drs José Grindler,**



**Acácio F. Cardoso**



**Alfredo J. Fonseca**



**Diretor de Serviço**

**Serviço: Eletrocardiologia HC Faculdade de Medicina -Universidade de São Paulo-USP**  
**Service: Electrocadiology HC Faculty of Medicine - University of São Paulo-USP**

This is extensive anterior STEMI due to proximal LAD occlusion before the first diagonal branch with ST elevation in I, aVL V<sub>2</sub>-V<sub>4</sub> and reciprocal ST depression in the inferior leads.

The initial ECG shows RBBB that is unclear whether it is new or old.

There is electrical alternans, most probably secondary to extensive ischemia.

You give hints that there is no tamponade.

After stenting QRS width decreases, there are Q waves in aVL, V1-V3

**Dr. Yochai Birnbaum, MD., FAHA, FACC**

The Section of Cardiology, The Department of Medicine, Baylor College of Medicine, Houston, TX, USA.

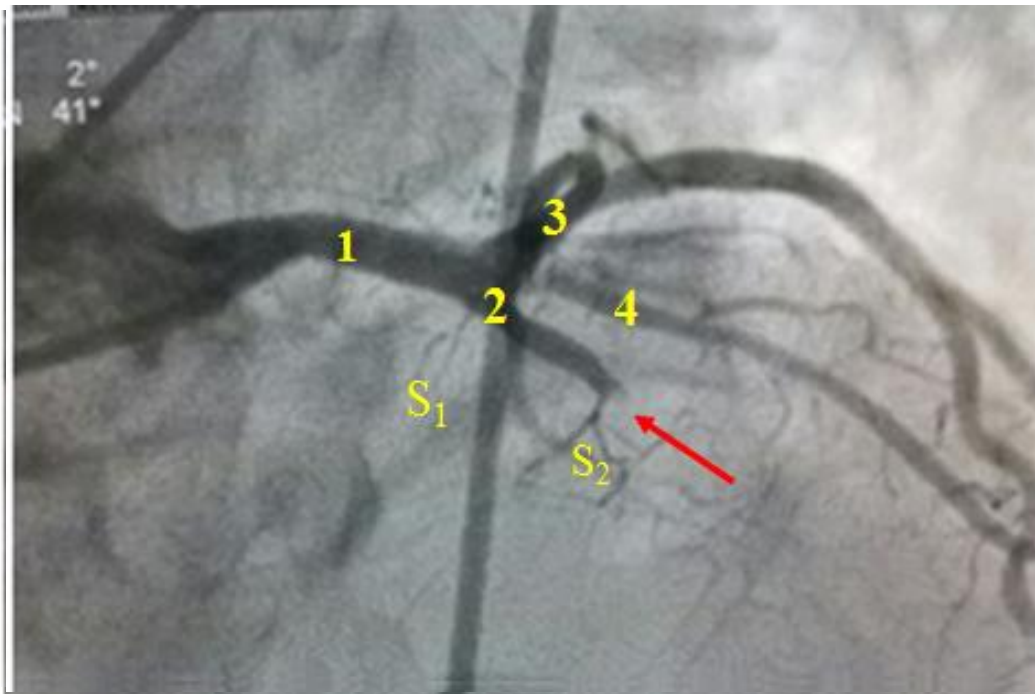




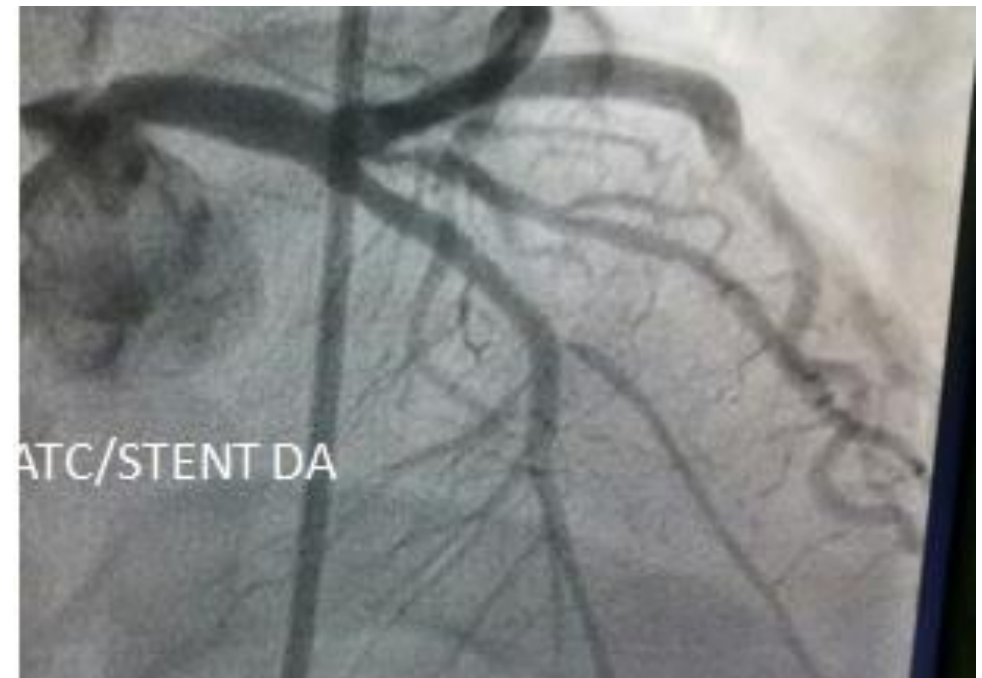**Final comments by Andrés Ricardo Pérez-Riera, Raimundo  
Barbosa-Barros & Luiz Carlos de Abreu**

# Primary percutaneous coronary intervention with stent implantation in LAD in the AP cranial view

Before procedure

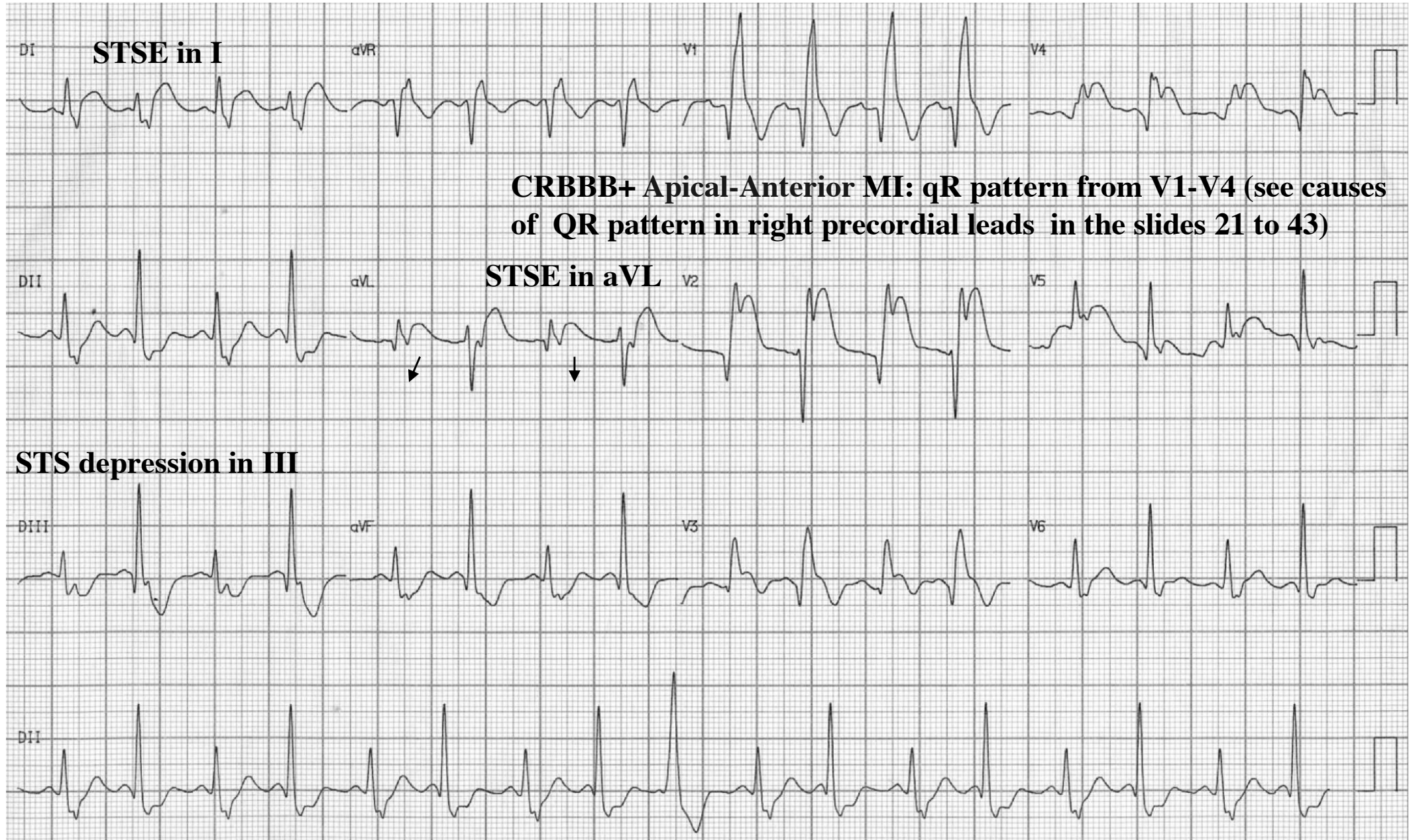


After stent implantation in LAD



1. Left Main Coronary Artery (LMCA) or Left Main Stem coronary artery (LMS)
2. Left Anterior Descending Artery (LAD), or anterior interventricular artery
3. The Left Circumflex Artery (LCX), circumflex artery, or circumflex branch of the left coronary artery
4. Diagonal branch of the left anterior descending artery. anterior descending coronary artery
5. S<sub>1</sub> The first septal branch of the LAD
6. S<sub>2</sub> The second septal branch of the LAD
7. Red Arrow total LAD obstruction

AMI caused by occlusion of LAD after the first septal perforator and before the first diagonal branch of the left anterior descending coronary artery.



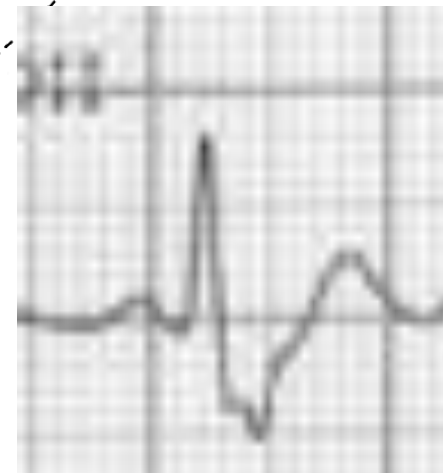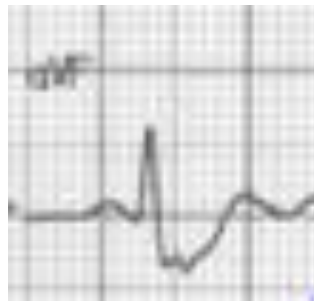
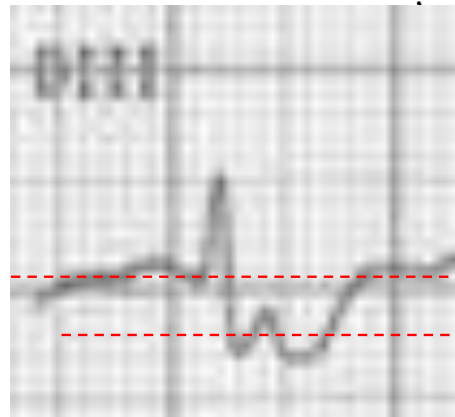
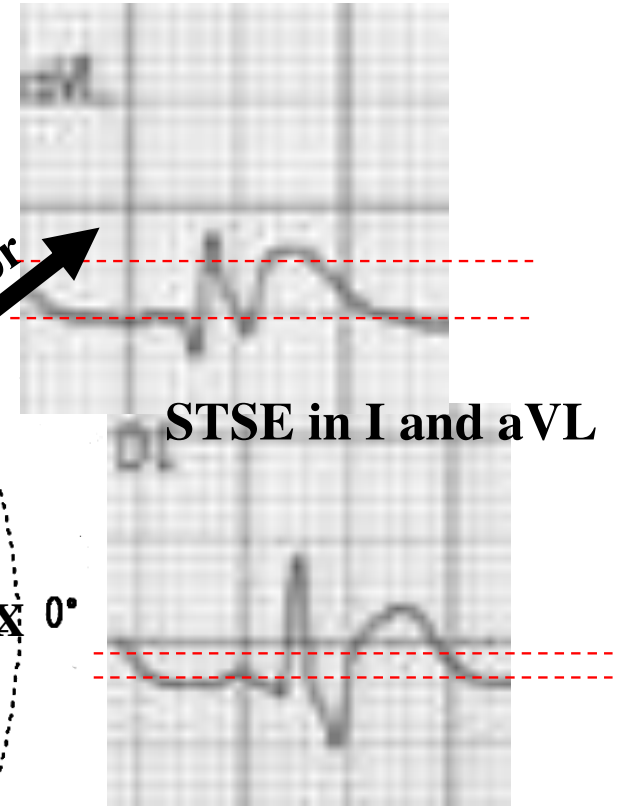
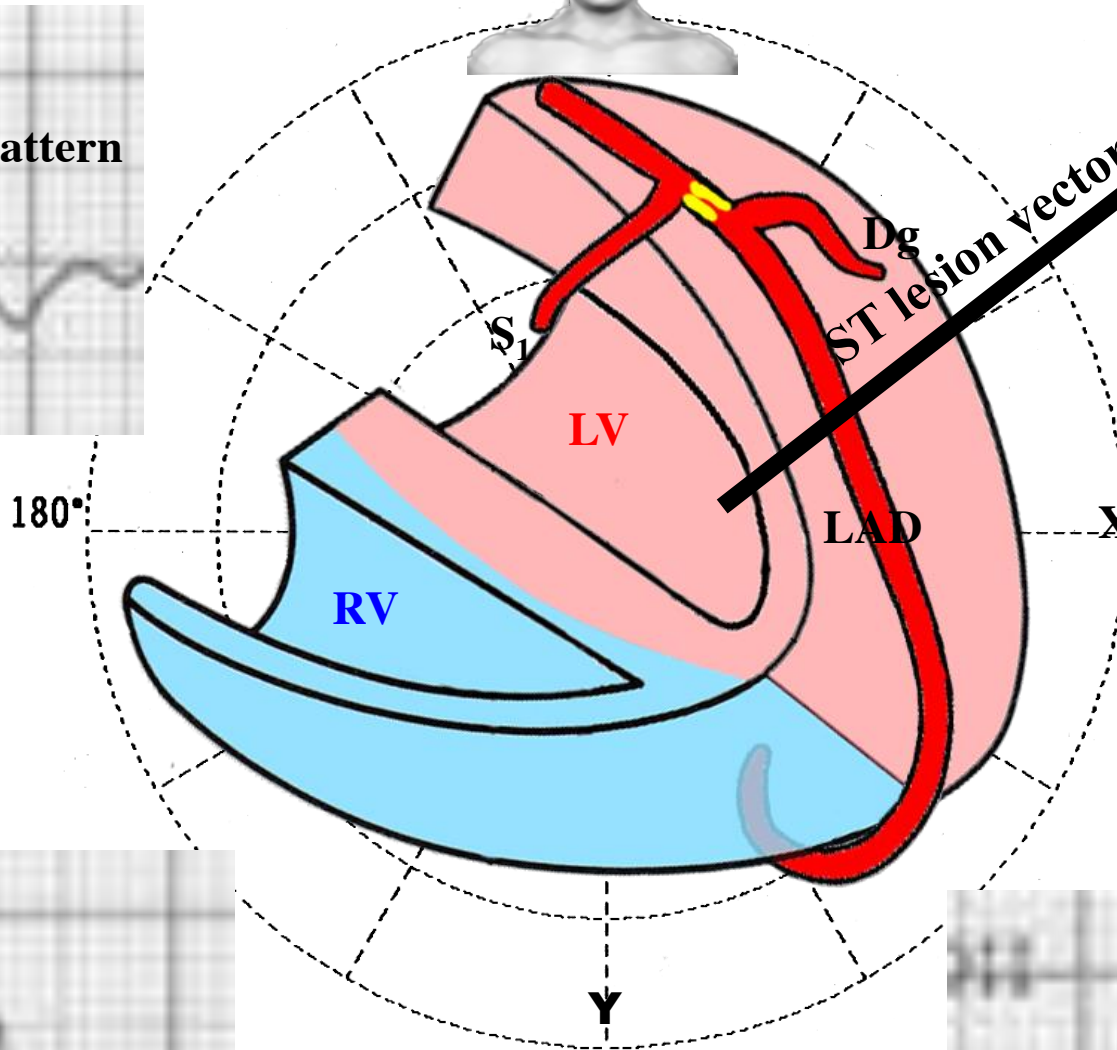
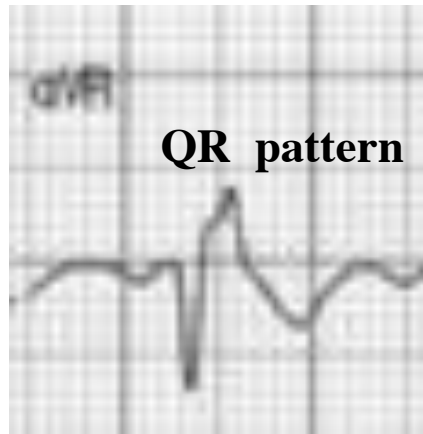
Diagonal branches are branches of the left anterior descending coronary artery. They supply blood flow to the anterior and anterolateral walls of the left ventricle.

**Why this pattern?**

# STSE in I and aVL. ST segment depression in III

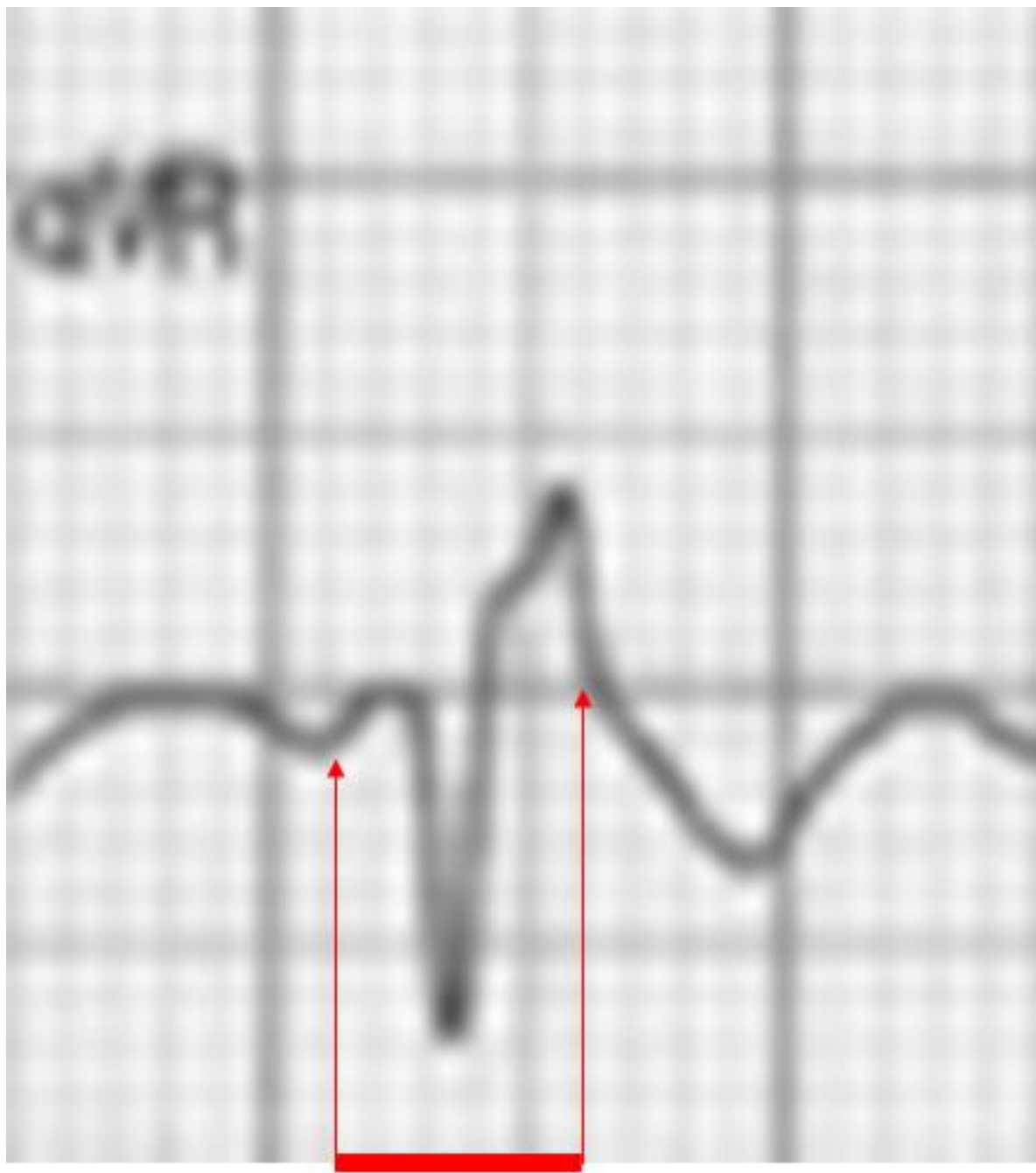The ST lesion vector directed up and leftward

**Frontal**

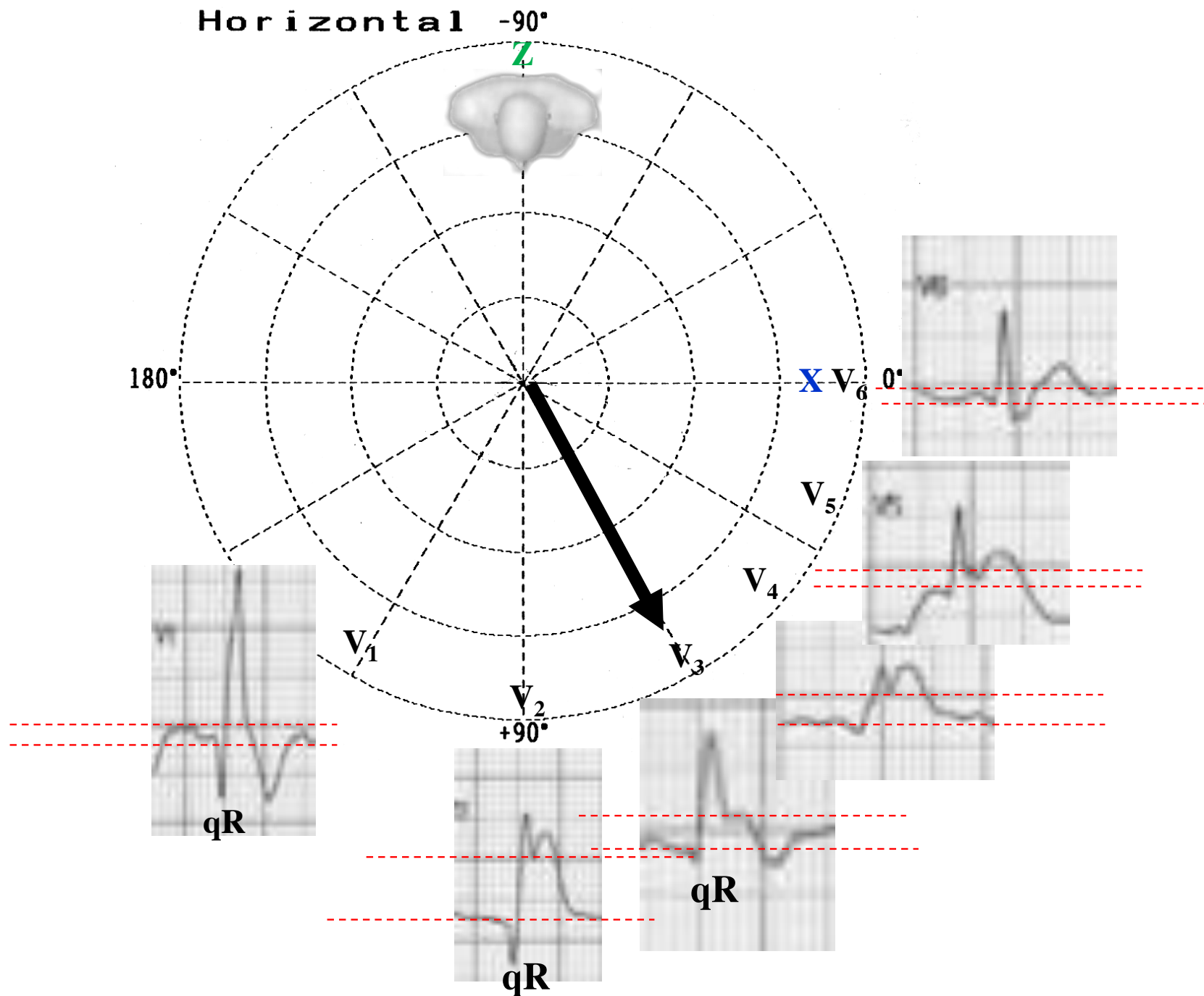


STSD depression in III





**QRS duration = 161 ms.** QR pattern in aVR lead with wide final R wave followed by negative T wave: Complete Right Bundle Branch Block.



The ST injury vector ( black arrow) directed to front and leftward: STSE from V<sub>1</sub> to V<sub>6</sub>.  
 qR pattern from V<sub>2</sub> to V<sub>4</sub>+ QRS duration > 120ms: Acute Apical-Anterior MI of new nomenclature MI + Complete RBBB.

# Limitations of the ST injury vector and the location of myocardial ischemia

Specificity: high

Predictive accuracy: high

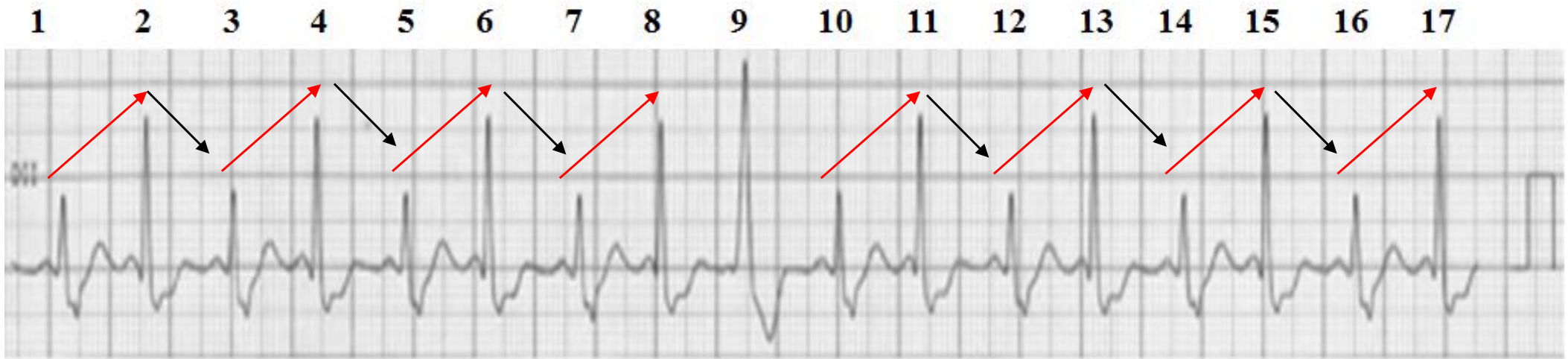
Sensitivity: quite low

## Clinical situations where the deviation of the ST segment is limited

1. Presence of a previous infarction
2. Preexisting abnormalities of the ST segment
3. Left Bundle Branch Block/Right Bundle Branch Block
4. Ventricular Preexcitation
5. Multivessel disease
6. Abnormal site of origin of a coronary artery
7. Dominance or underdevelopment of the coronary arteries.

There is a strong agreement between the direction of the ST injury vector and the location of myocardial ischemia. The ST injury vector may be the key to higher diagnostic accuracy for inferobasal transmural ischemia and may help distinguishing between RCA and LCX occlusions in the acute phase (**Andersen 2010**).

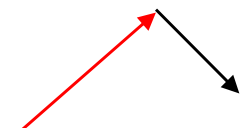
## Long II



Beats 1, 3, 5, 7, 10, 12, 14, 16: have Right Bundle Branch Block pattern; beats 2, 3, 4, 8, 11, 13, 15, 17: have minimal degree of LPFB + RBBB; beat 9 has only major degree of LPFB without RBBB

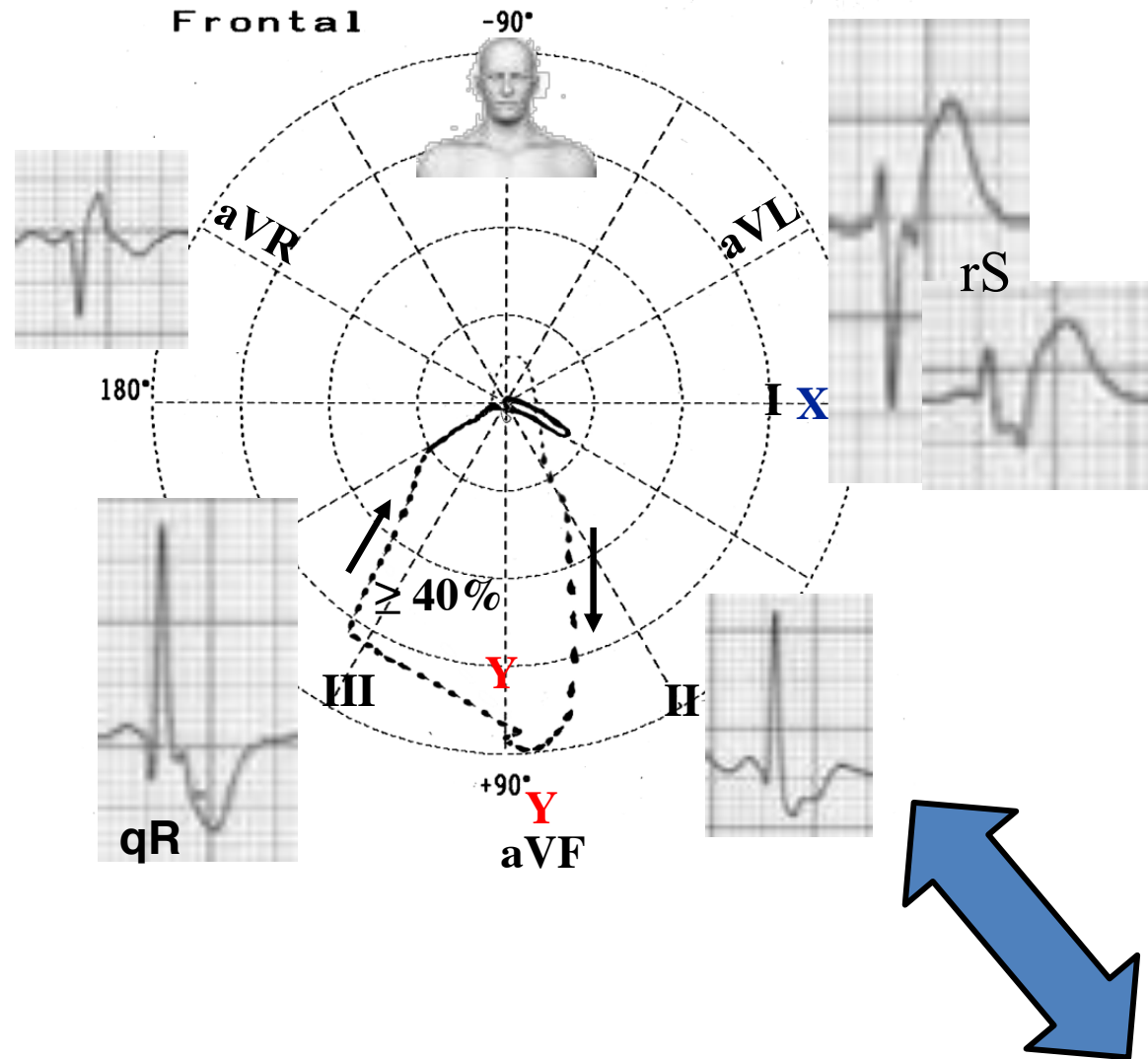
### Conclusion

- 1) **Apical-Anterior Myocardial Infarction of new nomenclature ECG/MCR correlation (Bayés de Luna 2006)**– see slide 45
- 2) **Complete Right Bundle Branch Block**
- 3) **Transient rate alternate variable degree of Left Posterior fascicular block**
- 4) **Bifascicular block**
- 5) **Pseudo electrical QRS alternans** due to a beat-to-beat variation in QRS axis and amplitude consequence of intermittent LPFB in association with RBBB. A typical cause of electrical alternans is a pericardial effusion, and is due to periodic wobbling of the heart in the pericardium “a swinging heart”(Kappor 2009). However, alternating axis shift may be due not to mechanical shifting of the heart, but to alternating conduction disturbance, such as intermittent fascicular block or bundle branch block. Klein, et al (Klein 1978) coined the term ‘pseudoelectrical alternans’ in a case report of intermittent LAFB, in which the axis shifted every other beat due to the development of alternating normal and then leftward axis shift, presumably related to procainamide therapy. Whenever what appears to be electrical





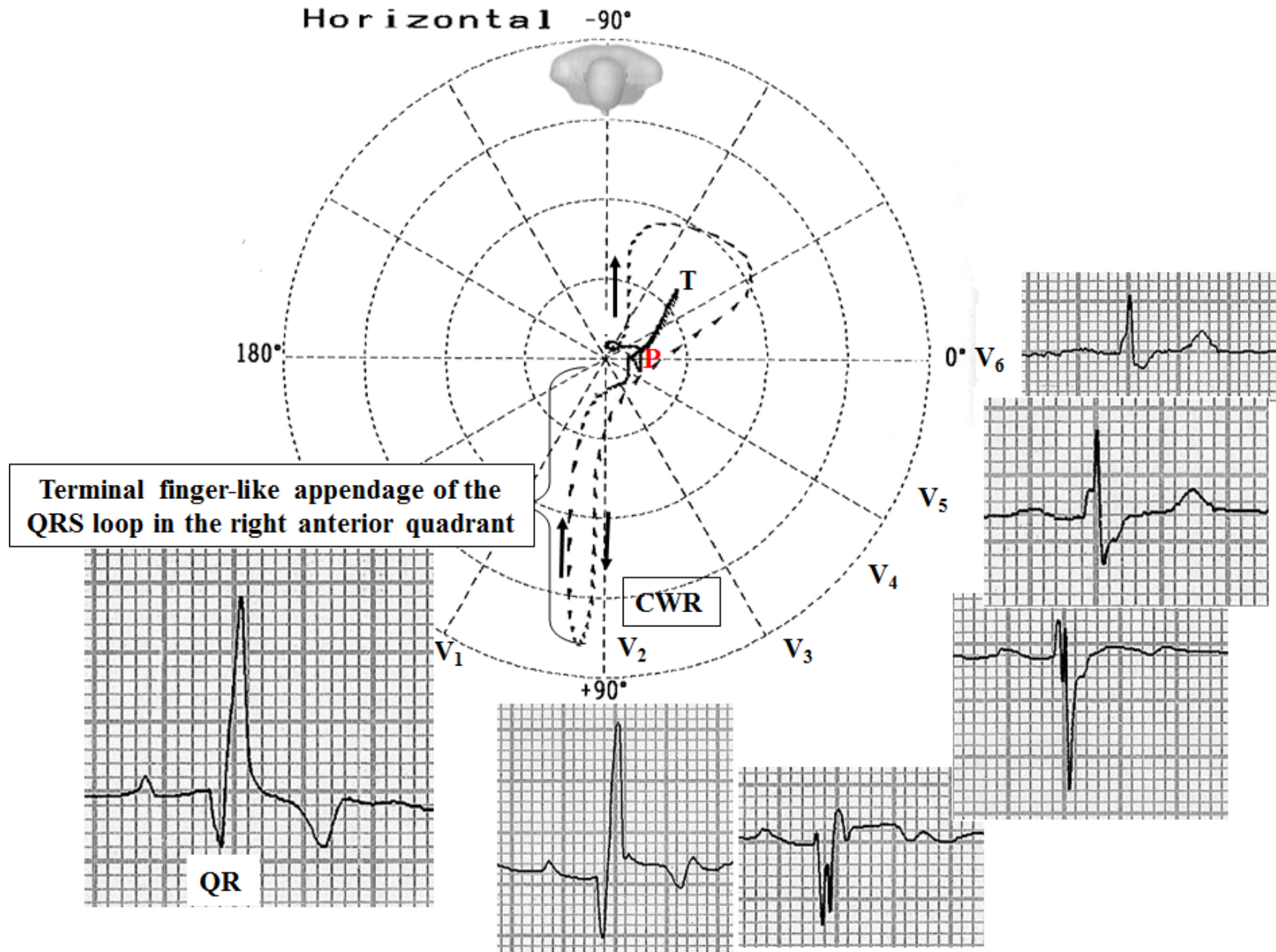
# Hypothetical ECG/VEG correlation in beats 2, 3, 4, 8, 11, 13 15 17 (minimal degree of LPFB + RBBB) in frontal plane



	Isolated LPFB	LPFB + CRBBB
<b>QRS duration</b>	90 to 110 ms	≥120 ms
<b>Location of QRS loop</b>	≥ 40% left of <b>Y</b> line	≥ 40% to the right of the Y line
<b>Vector of final 20 ms</b>	There might be delay, but discrete.	With important delay to the right.

# Possible causes of qR pattern in $V_1$ and $V_3R$ , and /or $V_2 - V_3$ (Sodi-Pallares' sign)

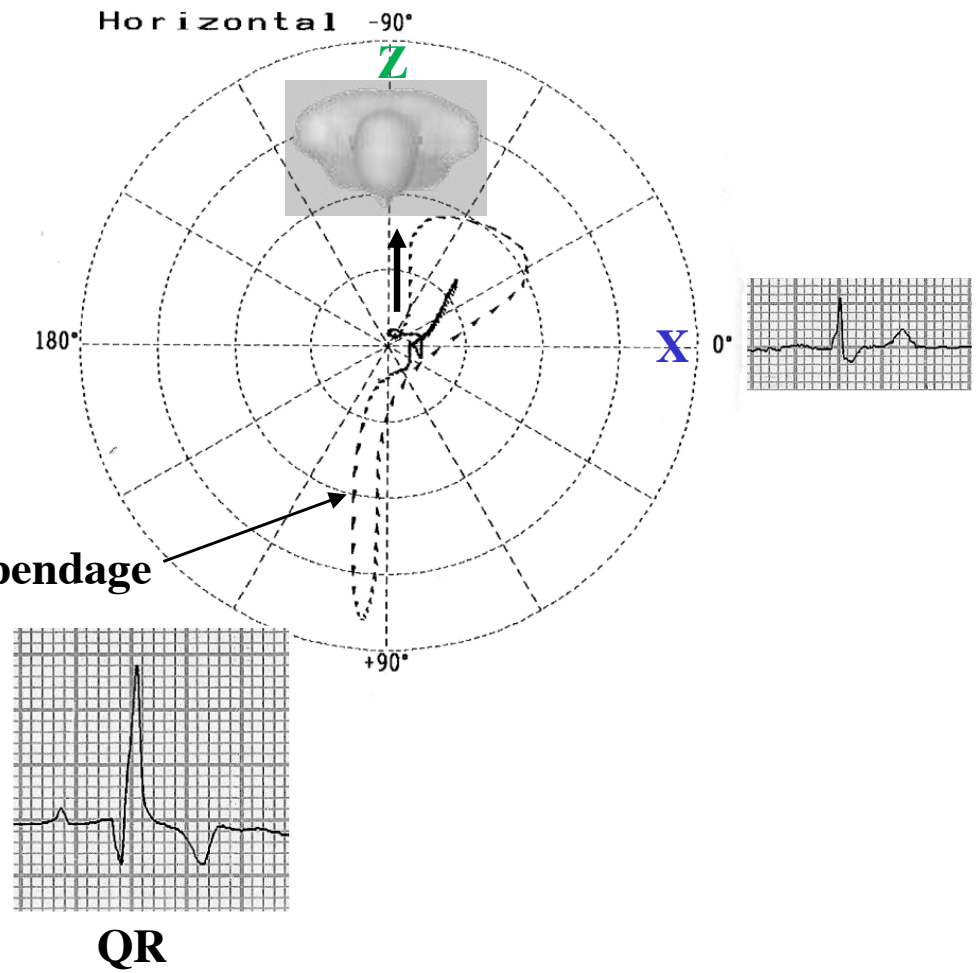
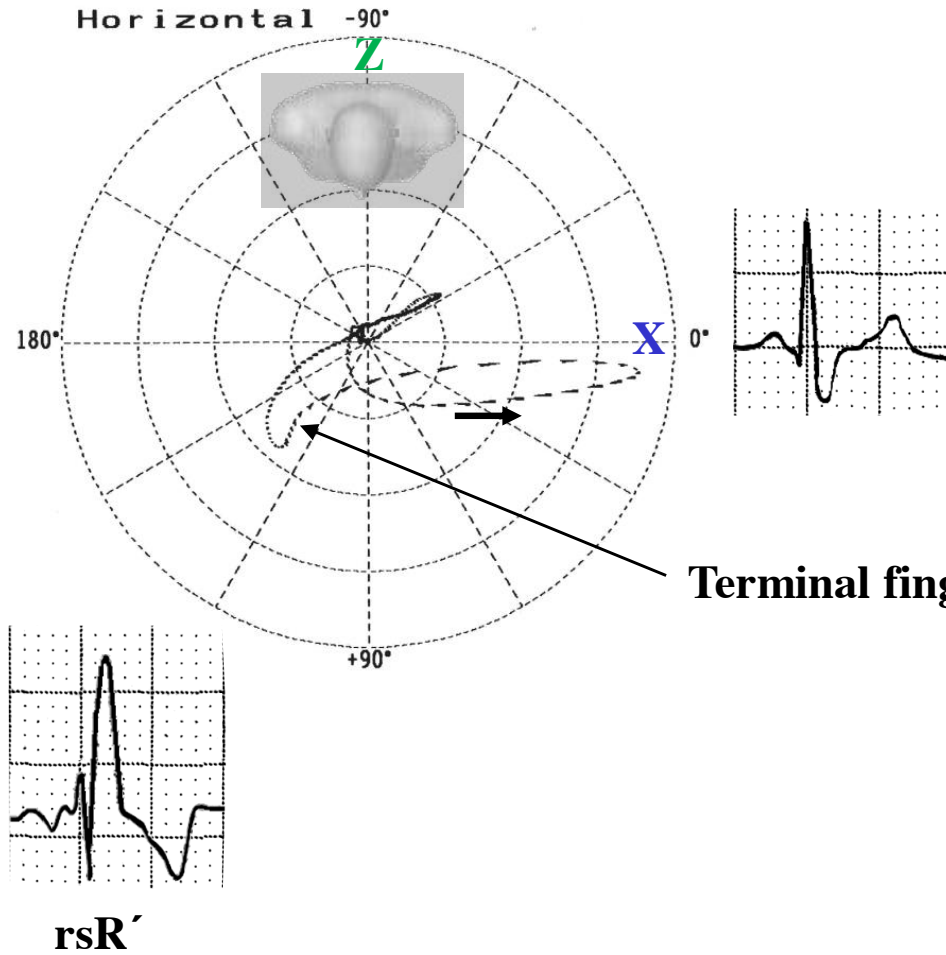
1. Right Bundle Branch Block associated to anterior myocardial infarction (the present case). qR pattern in  $V_1 - V_2$  or  $V_3$  (**Rudiakov 1964**).



	<b>Uncomplicated RBBB</b>	<b>RBBB associated with anterior MI</b>
<b>Initial 40 ms deflection</b>	It is recorded to the right and anteriorly, just as normally.	It is directed to back.
<b>Right precordial leads QRS pattern V2-V3</b>	Triphasic rSR'.	Biphasic QR or qR.
<b>Final 60-80 ms QRS forces</b>	In the right anterior quadrant, these late forces project a prominent wide and slurred terminal R' on leads V <sub>3R</sub> and V1 and a wide, shallow terminal S wave on leads I and V6	In the right anterior quadrant Idem
<b>Terminal VCG forces in the HP</b>	Terminal finger-like appendage of the QRS loop, which is recorded slowly to the right and anteriorly	Idem

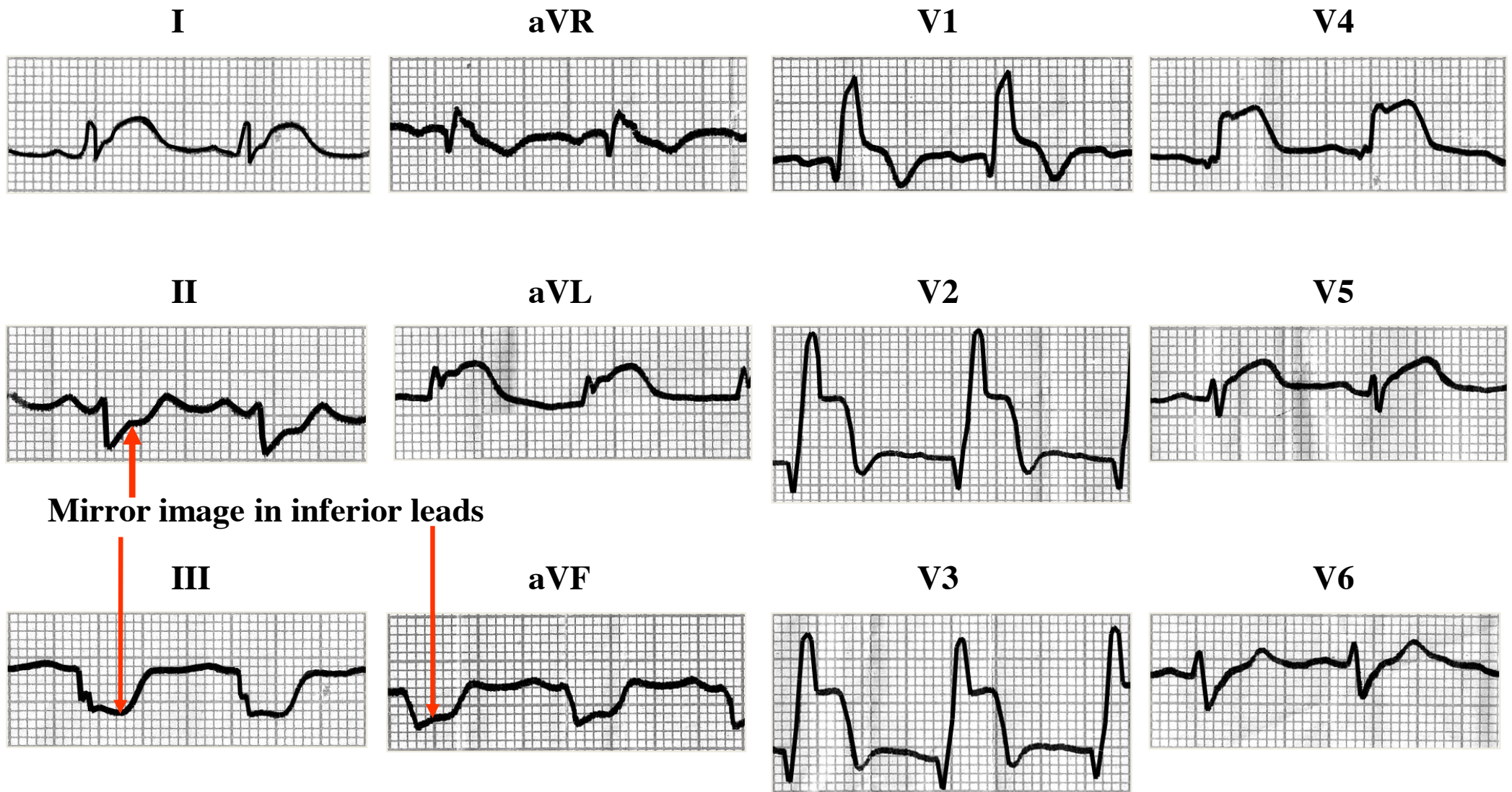
# Uncomplicated RBBB

# RBBB associated with anterior MI





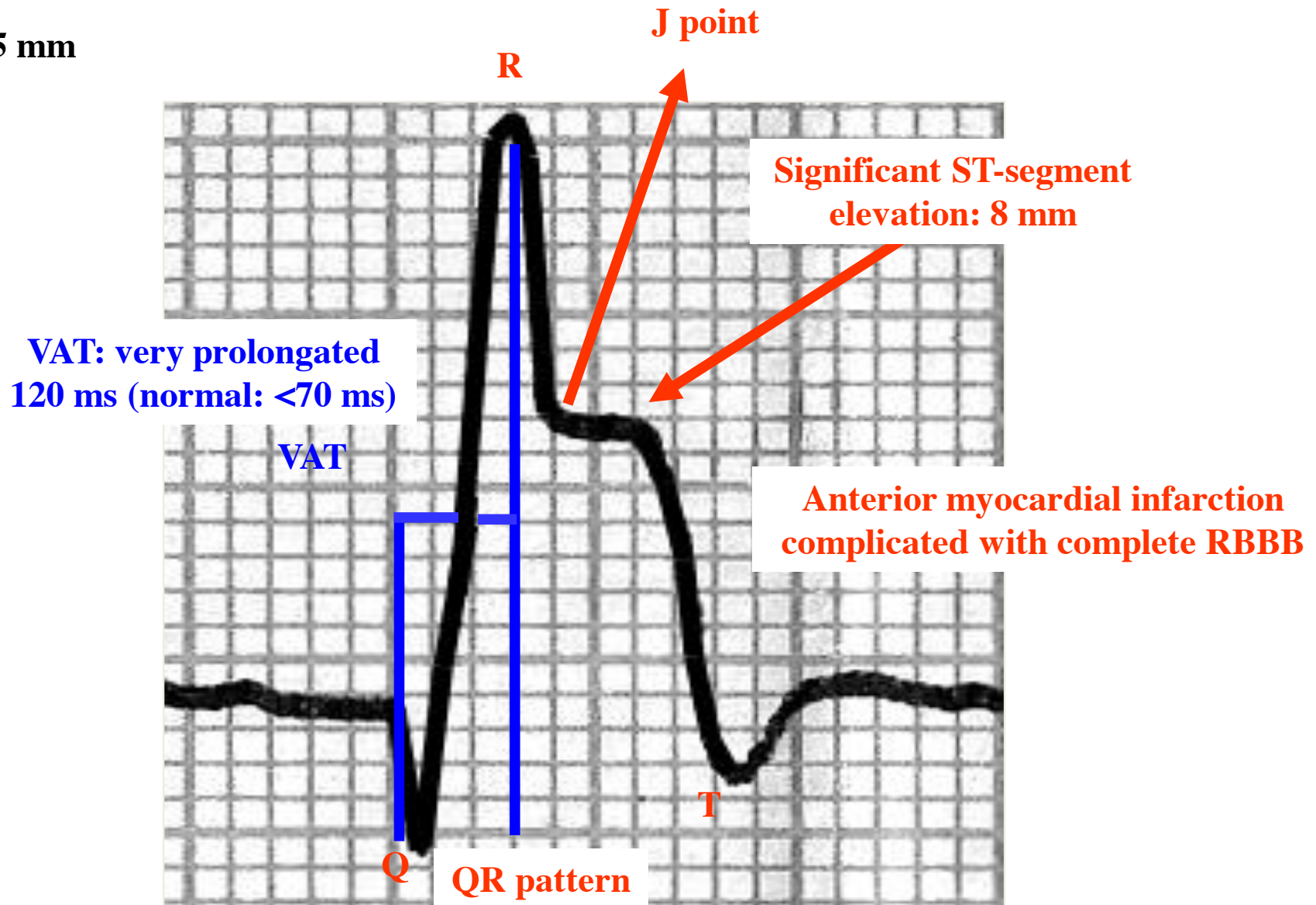
**Name:** FSS; **Sex:** Male; **Age:** 53 y.o.; **Race:** Caucasian; **Weight:** 83 Kg; **Height:** 1.68 m; **Date:** 11/02/2008;  
**Time:** 5:50 PM; chest pain with onset 3 hours ago



Extensive transmural anterior myocardial infarction (V1 to V6 + I and aVL) complicated with CRBBB.  
Treatment: Streptokinase intravenously within 4 hours 1,500,000 IU within 60 min. Very similar of the present case.

**Name:** FSS; **Sex:** Male; **Age:** 53 y.o.; **Race:** Caucasian; **Weight:** 83Kg; **Height:** 1.68 m; **Date:** 11/02/2008;  
Time: 5:50 PM; chest pain started 3 hours ago

**R = 15 mm**



**VAT: Ventricular Activation Time**

**Name:** FSS

**Sex:** M

**Age:** 53 y.o.

**Race:** Caucasian

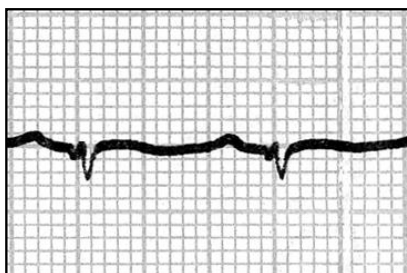**Weight:** 83 Kg

**Height:** 1.68 m

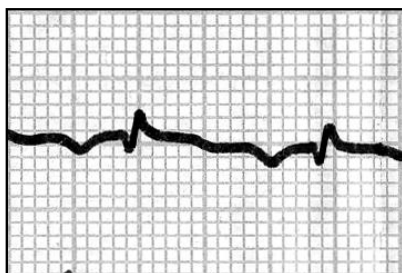
**Date:** 12/02/2008

**Time:** 11:20 AM

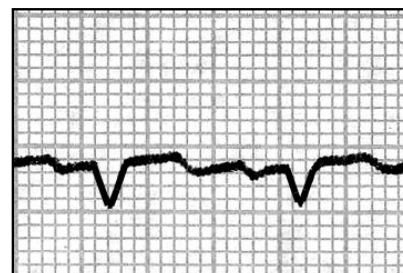
**I**



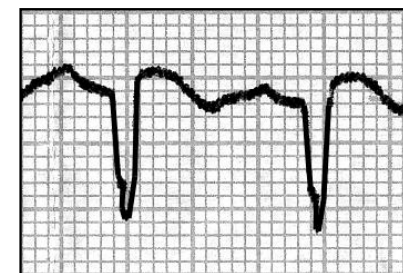
**aVR**



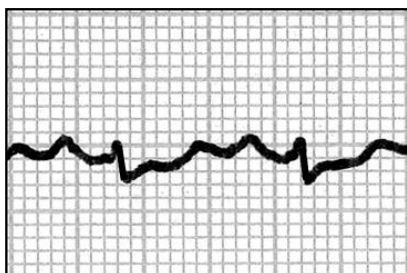
**V1**



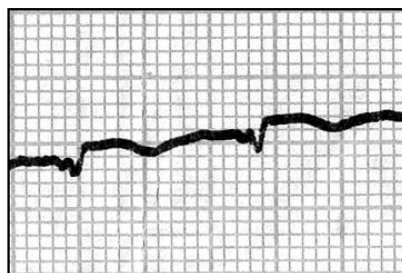
**V4**



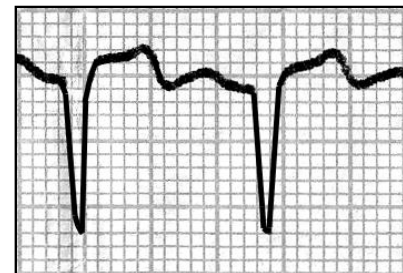**II**



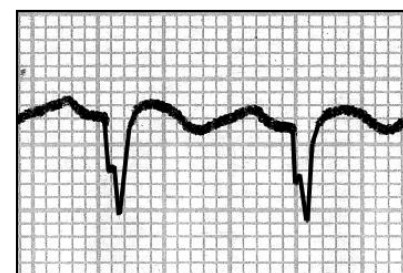**aVL**



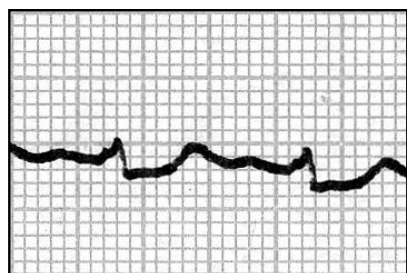
**V2**



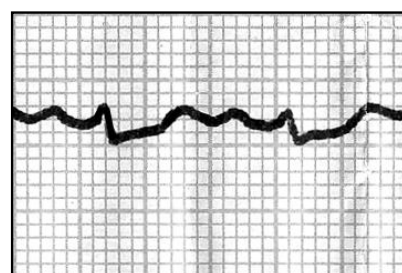
**V5**



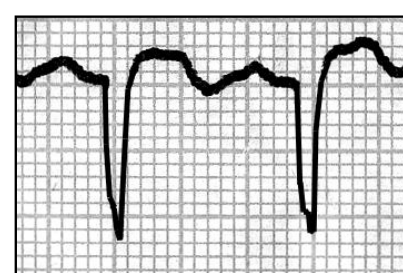**III**



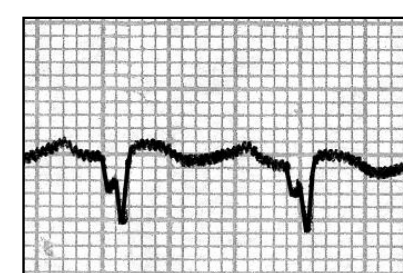
**aVF**



**V3**



**V6**



**ECG 18 hours later:** Thrombolytic therapy without success. Extensive transmural anterior myocardial infarction ( $V_1$  to  $V_6$  + I and aVL). Low QRS voltage in the frontal plane. Absence of complete RBBB pattern or another dromotropic disorder.



**Name:** FSS

**Sex:** M

**Age:** 53 y.o.

**Race:** Caucasian

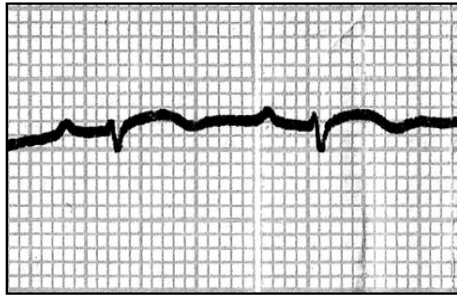
**Weight:** 83 Kg

**Height:** 1.68 m

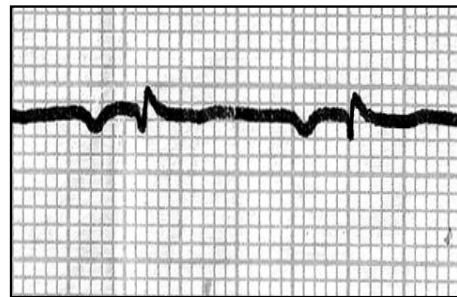
**Date:** 22/02/2008

**Time:** 02:40 PM

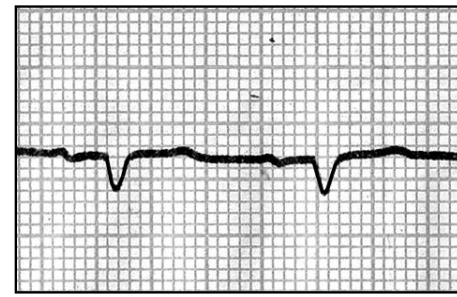
**I**



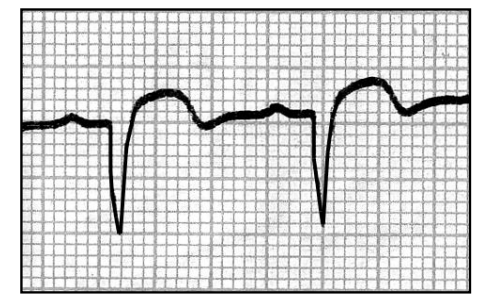
**aVR**



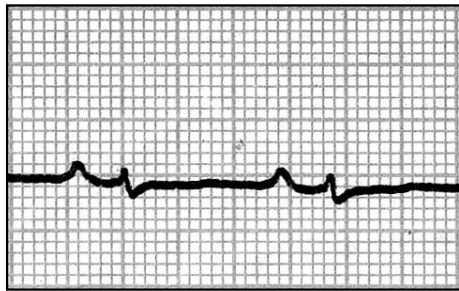
**V1**



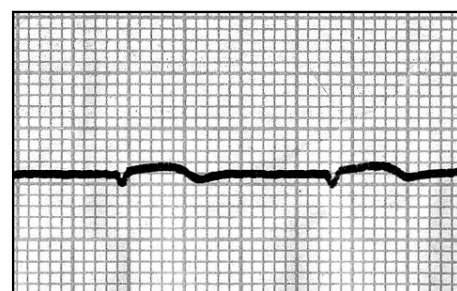
**V4**



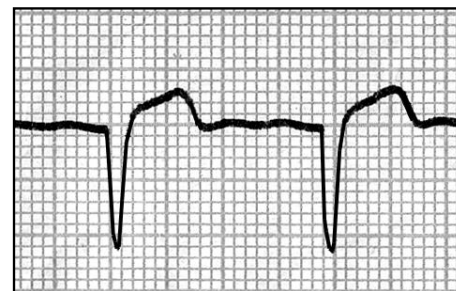
**II**



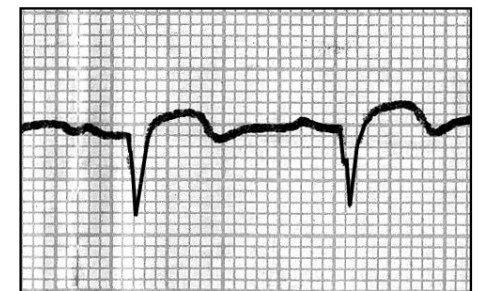
**aVL**



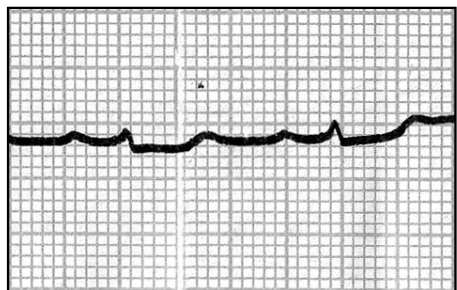
**V2**



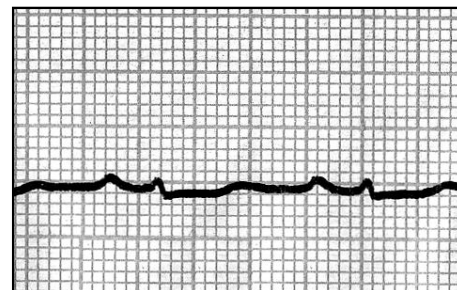
**V5**



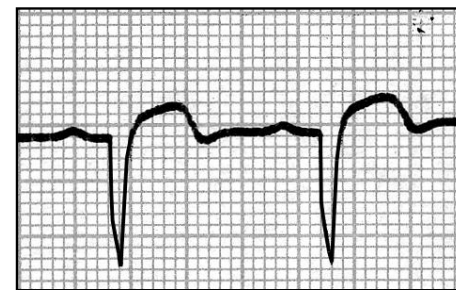
**III**



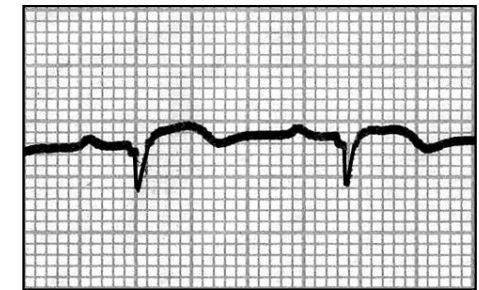
**aVF**



**V3**

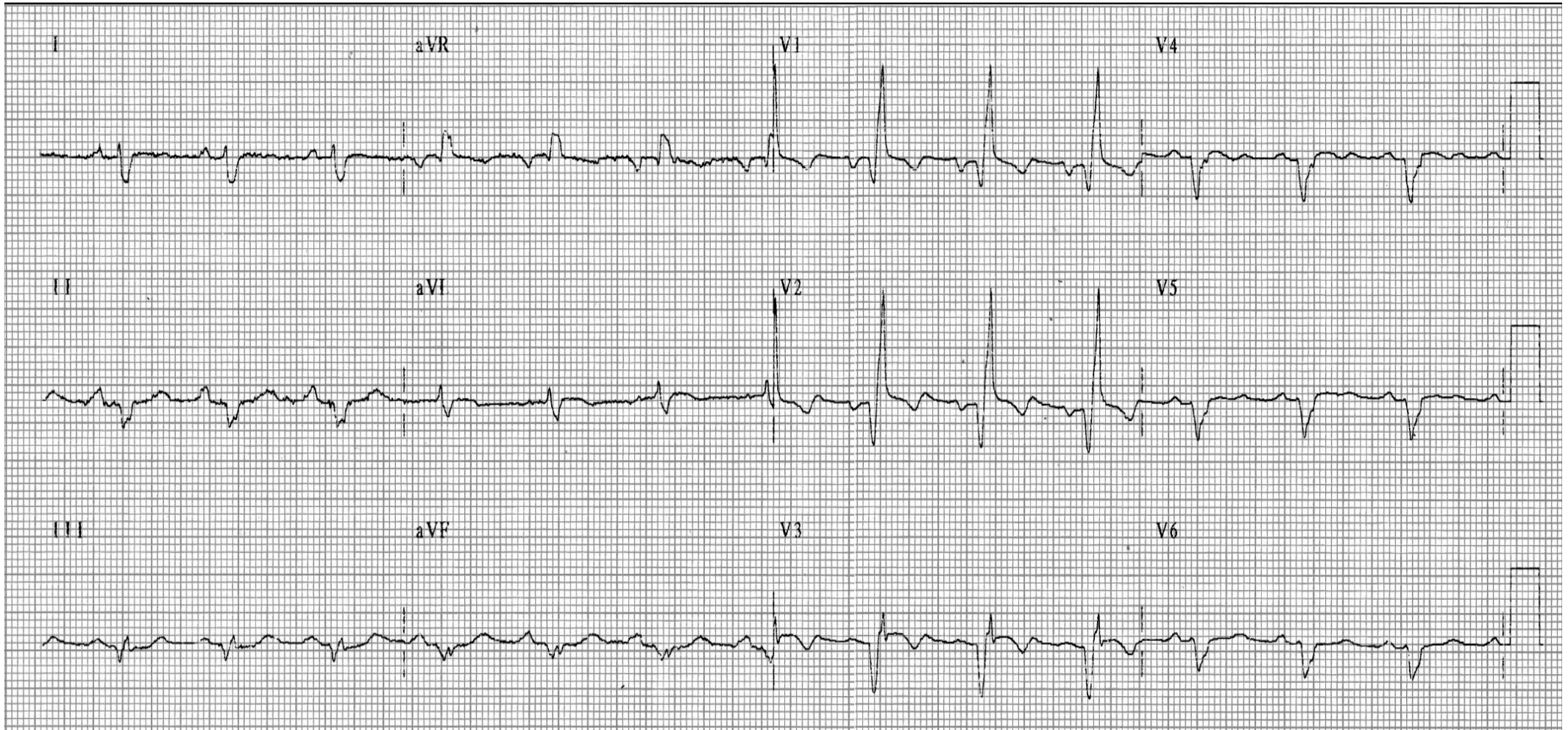


**V6**



**ECG 10 days later:** Thrombolytic therapy. Extensive transmural anterior myocardial infarction. Low QRS voltage in all of the frontal plane ( $\leq 5$  mm or 0.5 mV).

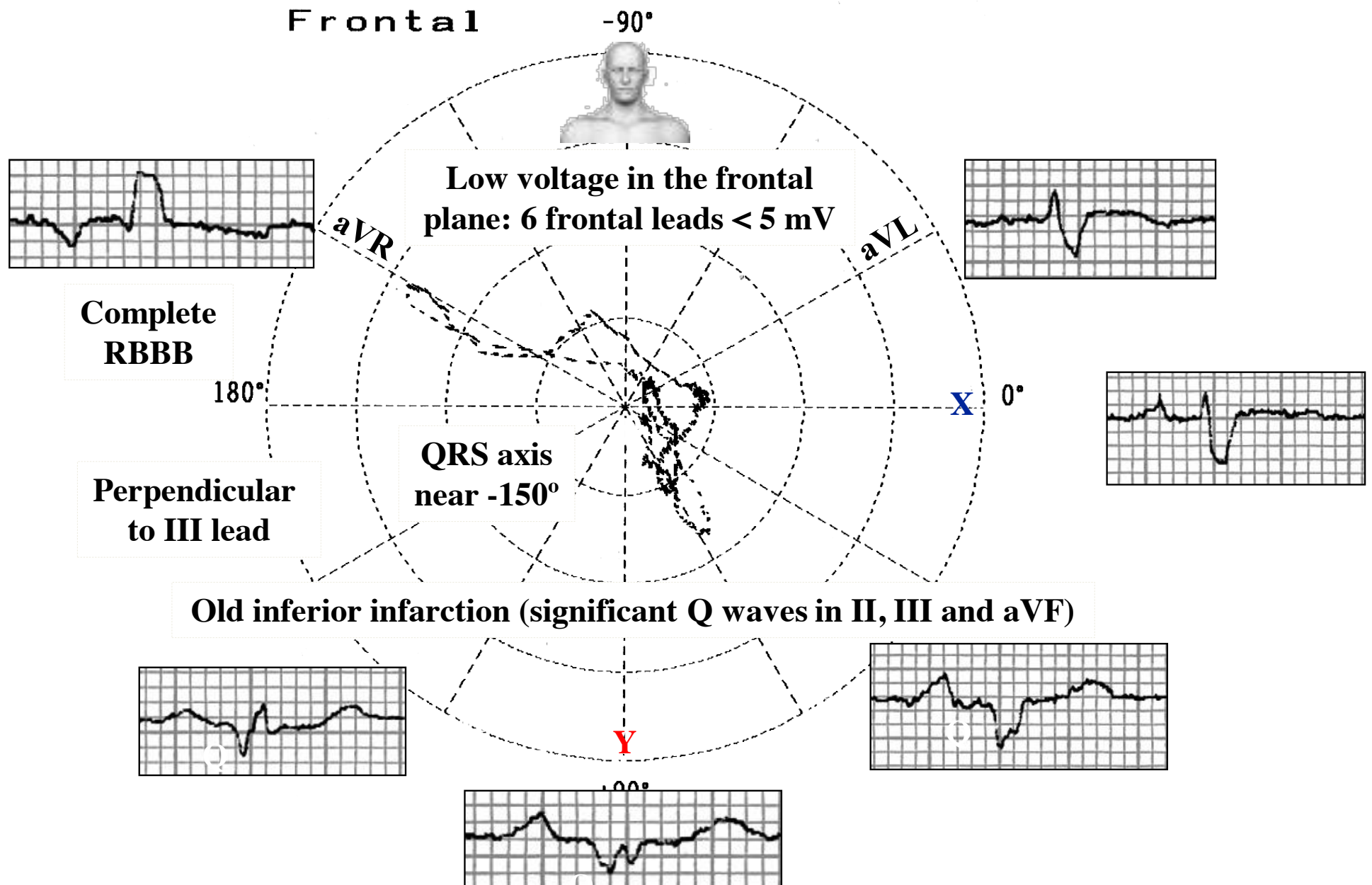
**Name:** FSS; **Sex:** M; **Age:** 53 y.o.; **Race:** Caucasian; **Weight:** 83 Kg; **Height:** 1.68 m; **Date:** 16/04/2008; **Time:** 08:16; **Medications in use:** Carvedilol 25 mg 2 times/day + Enalapril 20 mg + Furosemide 40 mg + Spironolactone 25 mg + Simvastatin 20 mg + Aspirin 100 mg.



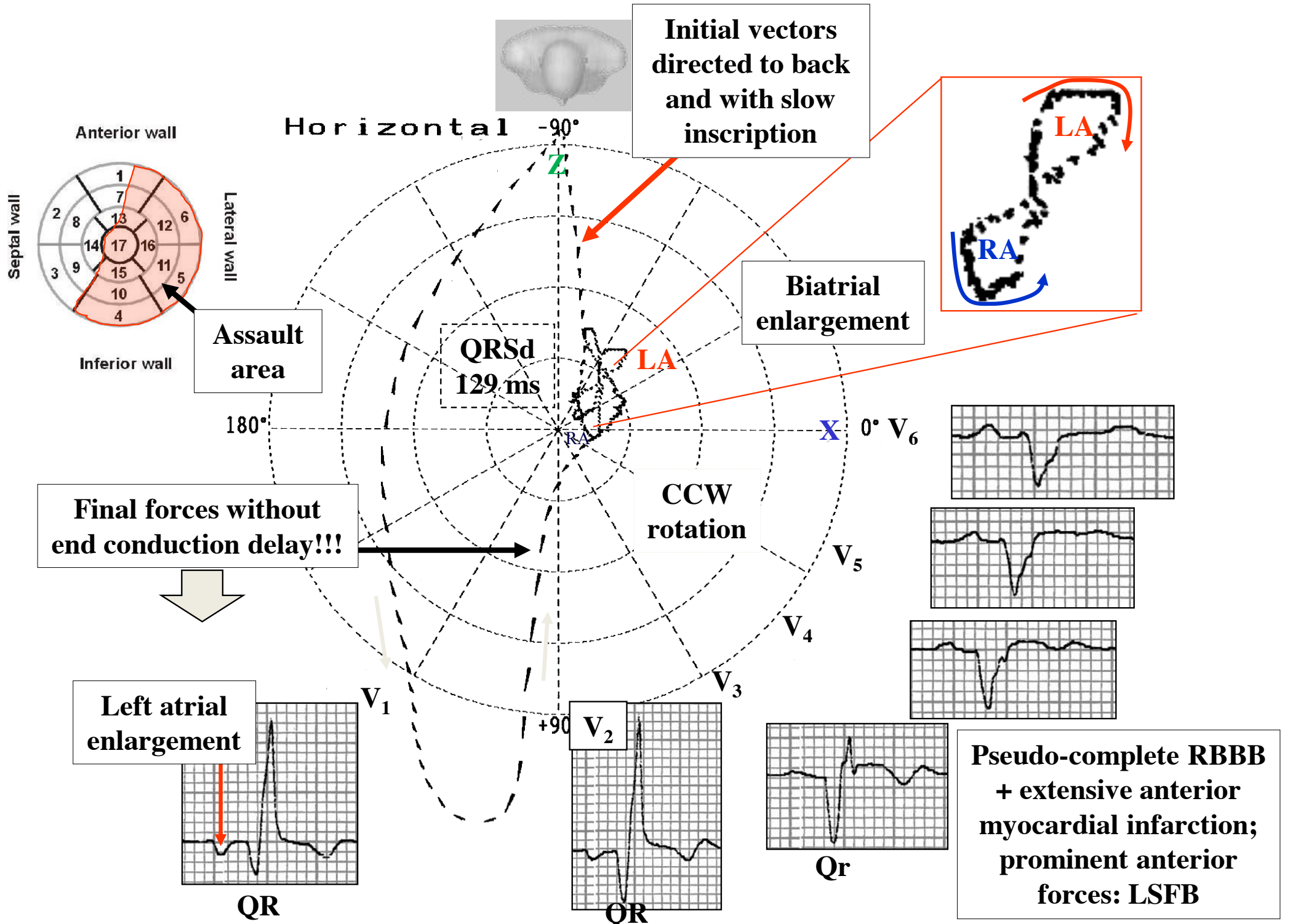
**ECG diagnosis:** Sinus rhythm, HR: 81 bpm, P axis  $+60^\circ$ , P wave: duration 120 ms, prominent negative final component in lead  $V_1$ : Left Atrial Enlargement (LAE). PR interval: Normal 181 ms. QRS axis in  $-150^\circ$  (right axis deviation), QRSd: 129 ms, low voltage in frontal leads, old inferior myocardial infarction (significant Q waves in II, III and aVF), extensive anterior myocardial infarct associated with complete RBBB? (qR pattern from  $V_1$  to  $V_3$ ), QTc: 491 ms. Prominent Anterior Forces (PAF): R waves with great voltage and sharp-pointed in  $V_2$ , progressive decrease of R wave voltage from  $V_4$  to  $V_6$ , absence of initial q wave in  $V_5$ - $V_6$ : Left Septal Fascicular Block (LSFB), probably associated with some degree of RBBB.



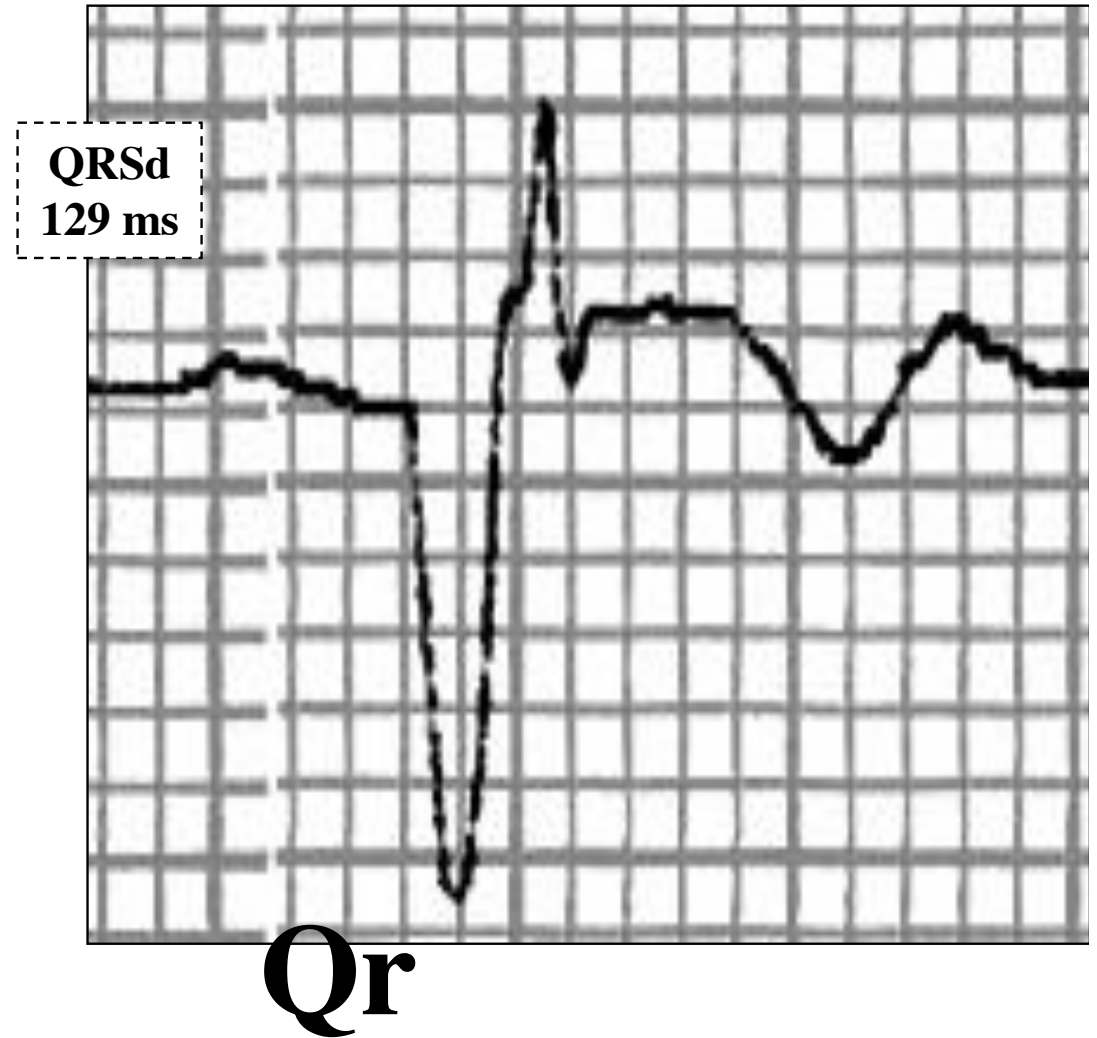
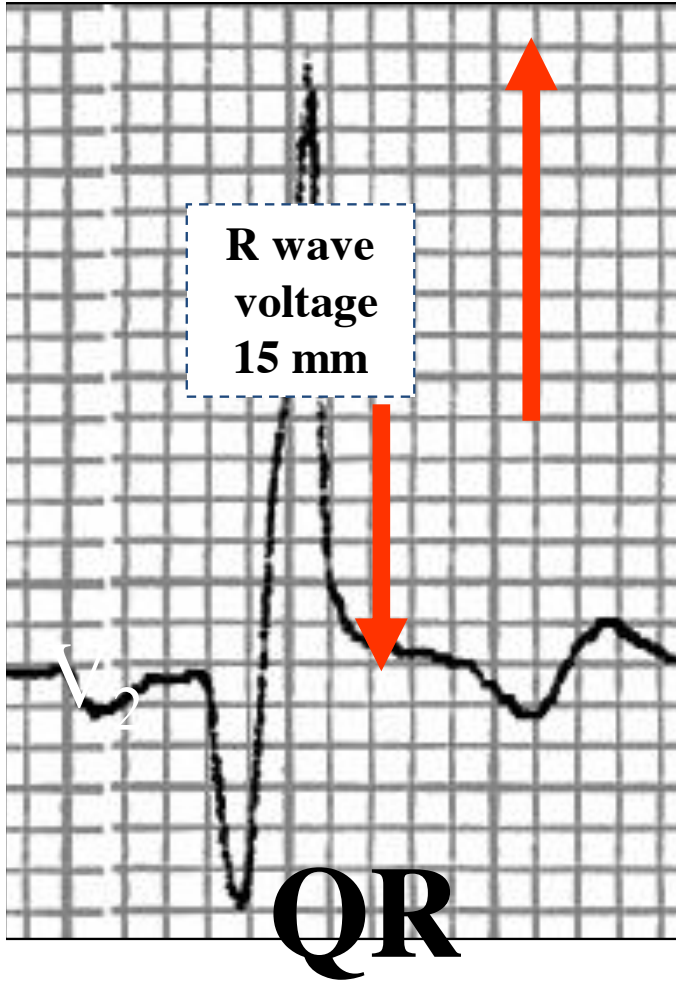
# ECG/VCG correlation in the Frontal Plane



# ECG/VCG correlation in the Horizontal Plane



$$R-V_2 > R V_3$$



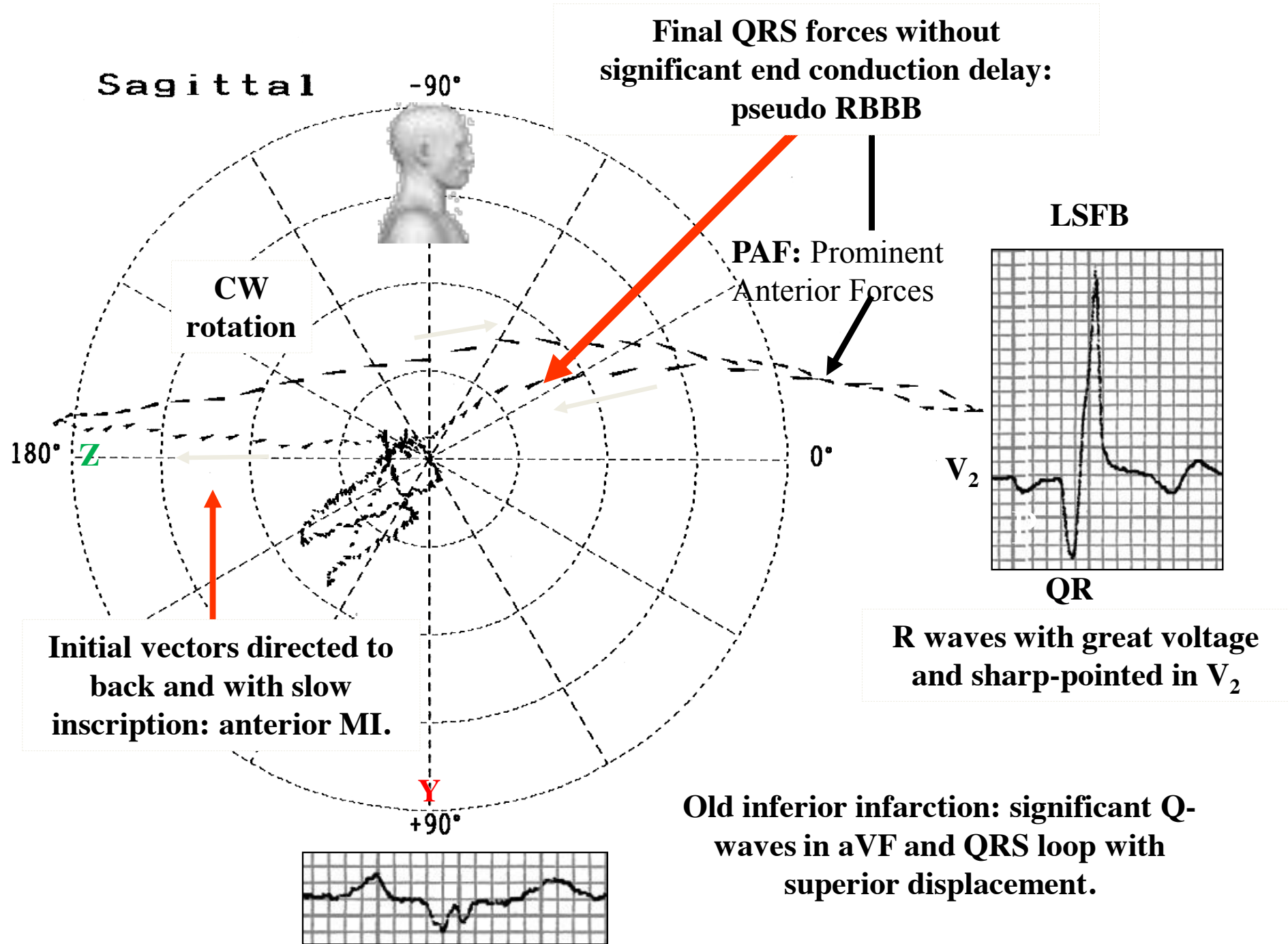
R waves with great voltage and sharp-pointed in  $V_2$  (PAF).

Intrinsicoid deflection in  $V_2 > 50\%$  of total QRSd and final forces without delay: Pseudo Complete RBBB.

Progressive decrease of R wave voltage from  $V_4$  to  $V_6$ .

Absence of initial q wave in  $V_5$ - $V_6$ : Left Septal Fascicular Block.

# ECG/VCG correlation in the Right Sagittal Plane



# Conclusions

- Biatrial enlargement: only VCG
- Extensive anterior myocardial infarction
- Old inferior myocardial infarction
- PAF: secondary to LSFB without complete RBBB: only VCG
- Absence of complete RBBB: only VCG.

**Comments:** in this case VCG is superior to ECG for the appropriate diagnose.

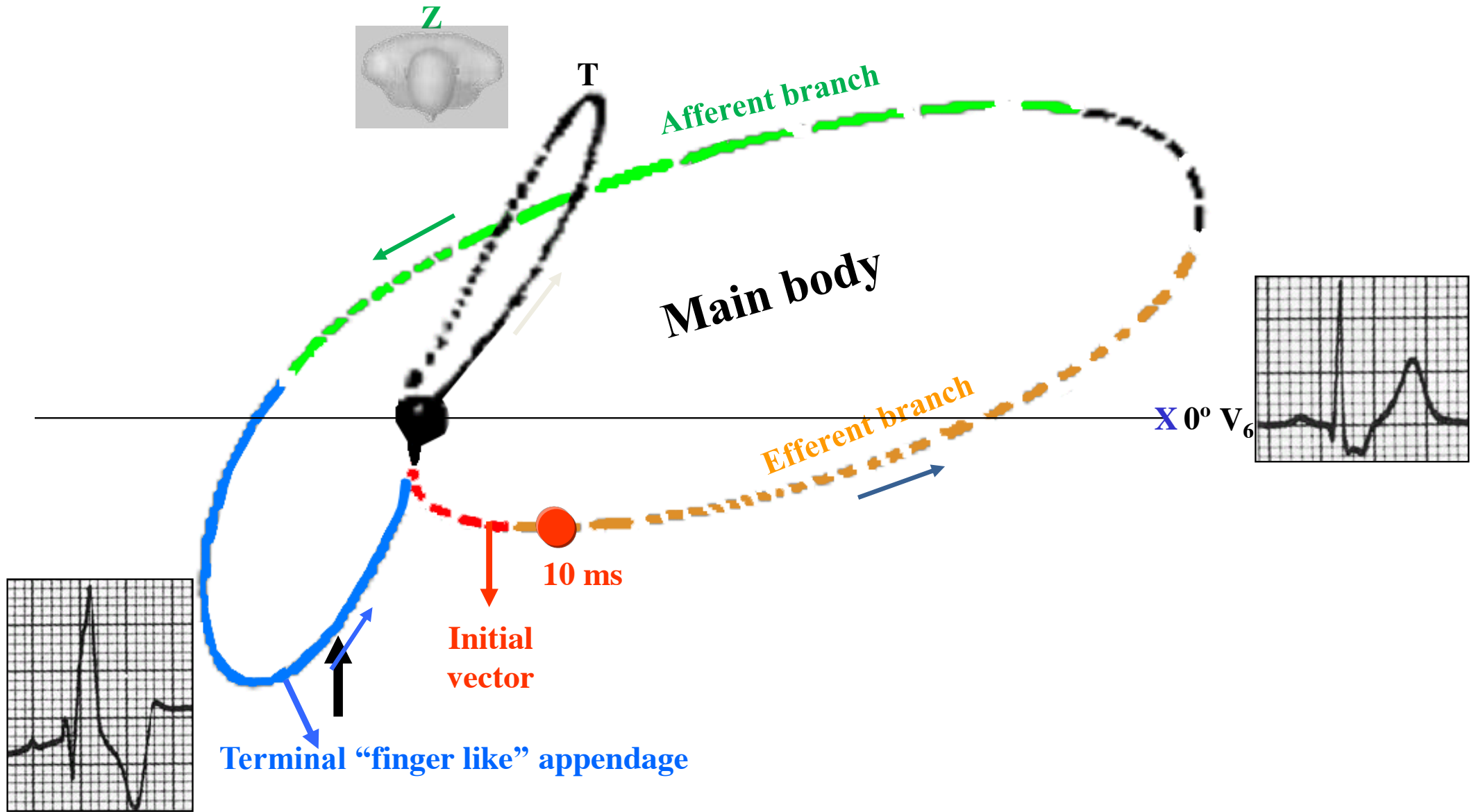
## Theoretical explanations

The coexisting RBBB and MI are individually recognizable in the VCG and ECG because the electrical effects of two conditions appear at different times in the QRS interval. The vector loop of RBBB, therefore, can be divided into an initial portion representing the activation of the left ventricle (LV) and a terminal portion representing activation the right ventricle (RV). Since most infarctions involve the LV and produce changes during the initial portion of the QRS complex/loop, their recognition is not hampered (with exception of lateral infarction, in the near past named strictly dorsal).

In truly complete RBBB associated with anterior MI the terminal late forces of the horizontal plane are directed to the right and anteriorly with characteristic terminal “finger like” appendage of the QRS loop, whose average orientation is along the  $+120^\circ$  (between  $+140^\circ$  to  $+100^\circ$ ) axis of the horizontal reference frame which is recorded slowly: ***A conduction delay represented by the close spacing of the time dashes in the terminal part of the QRS loop.*** This late final forces correspond to the activation of basal wall of RV and /or septum.



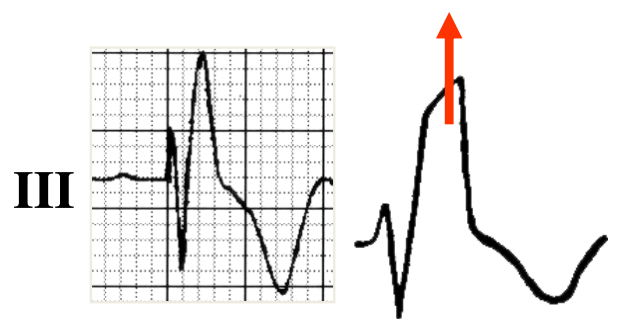
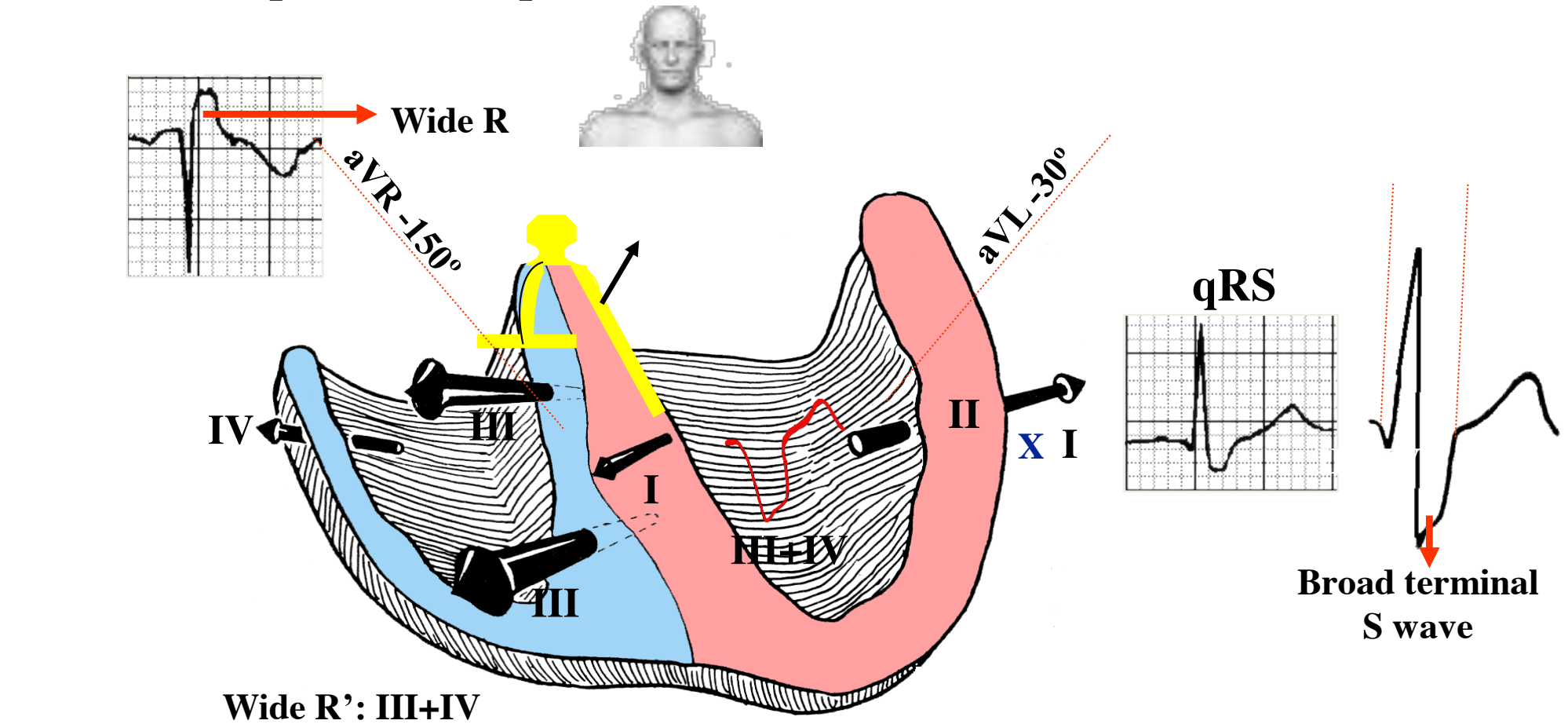
# ECG/VCG criteria of uncomplicated complete RBBB in the HP



QRS loop in the HP formed by: **initial vector**, **efferent branch**, **afferent branch**, main body and terminal appendage with delay.

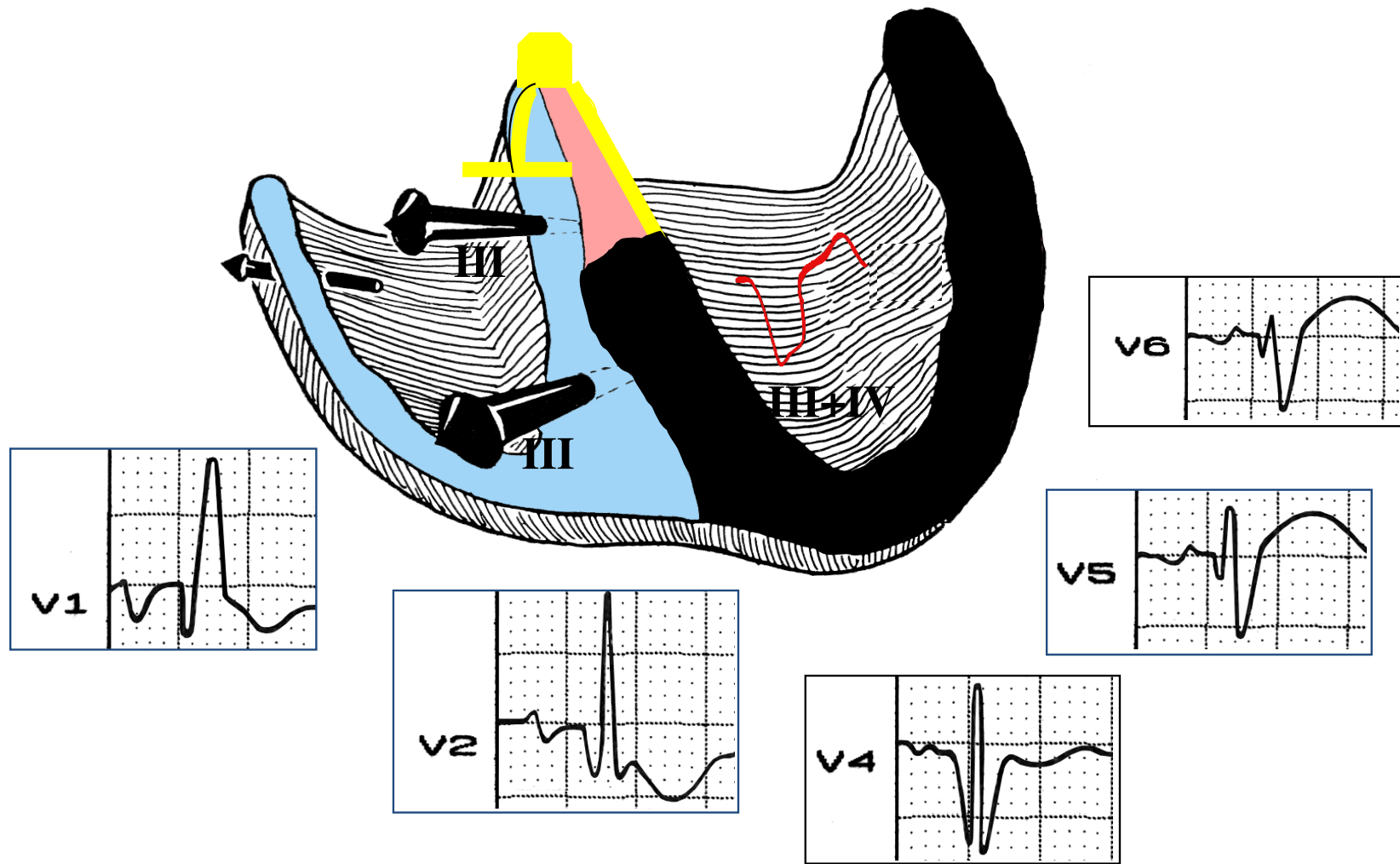
The terminal late forces of the horizontal plane are directed to the right and anteriorly with characteristic terminal "finger like" appendage of the QRS loop.

# Uncomplicated complete RBBB ventricular activation in the FP

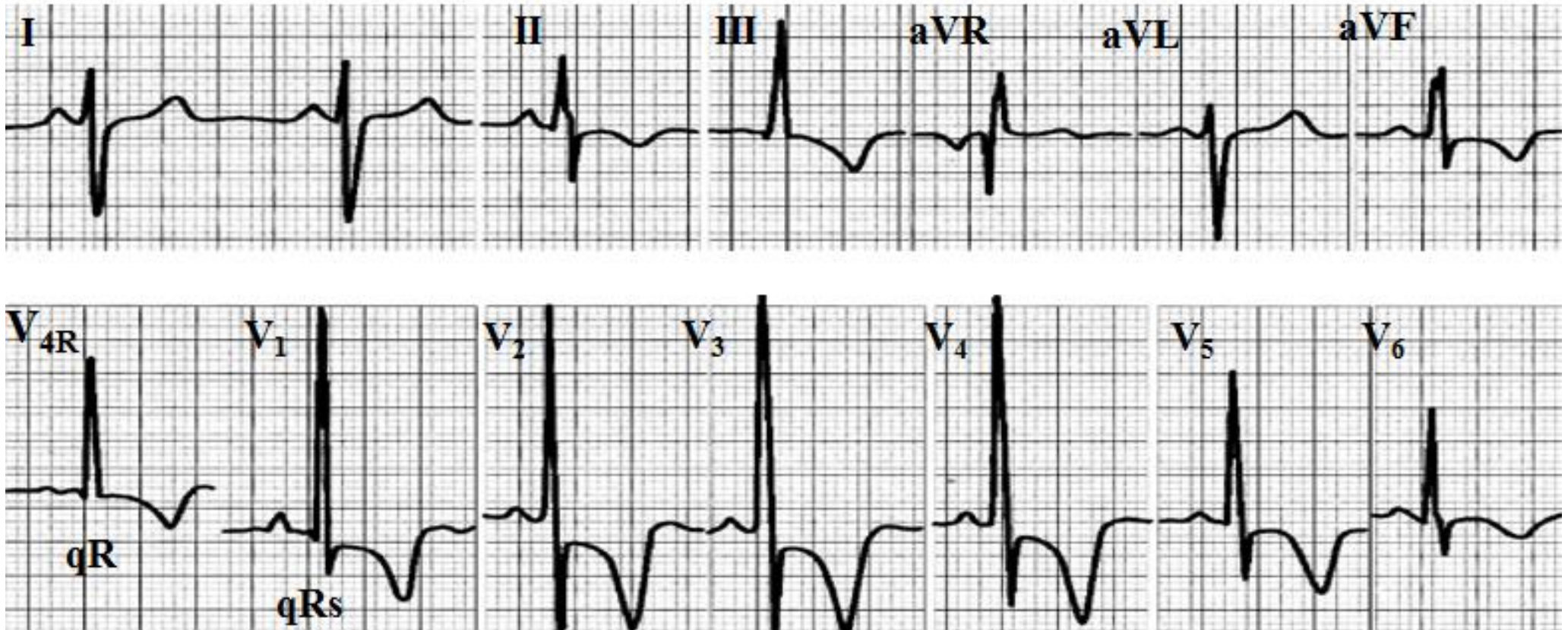


- I. Initial activation of middle third of left septal surface and activation of muscle mass of left septum and of apico-anterior LV free wall;
- II. Activation of anterolateral wall of LV free wall from endo to epicardium;
  - Activation of basal LV wall; continued left-to-right septal activation and apicoanterior activation of RV;
- III. Completion of septal activation (slow trans-septal vectors) and continued activation of RV free wall;
- IV. Activation of basal wall of RV (RVOT) and/or septum.

# Complete RBBB complicated with extensive anterior myocardial infarction

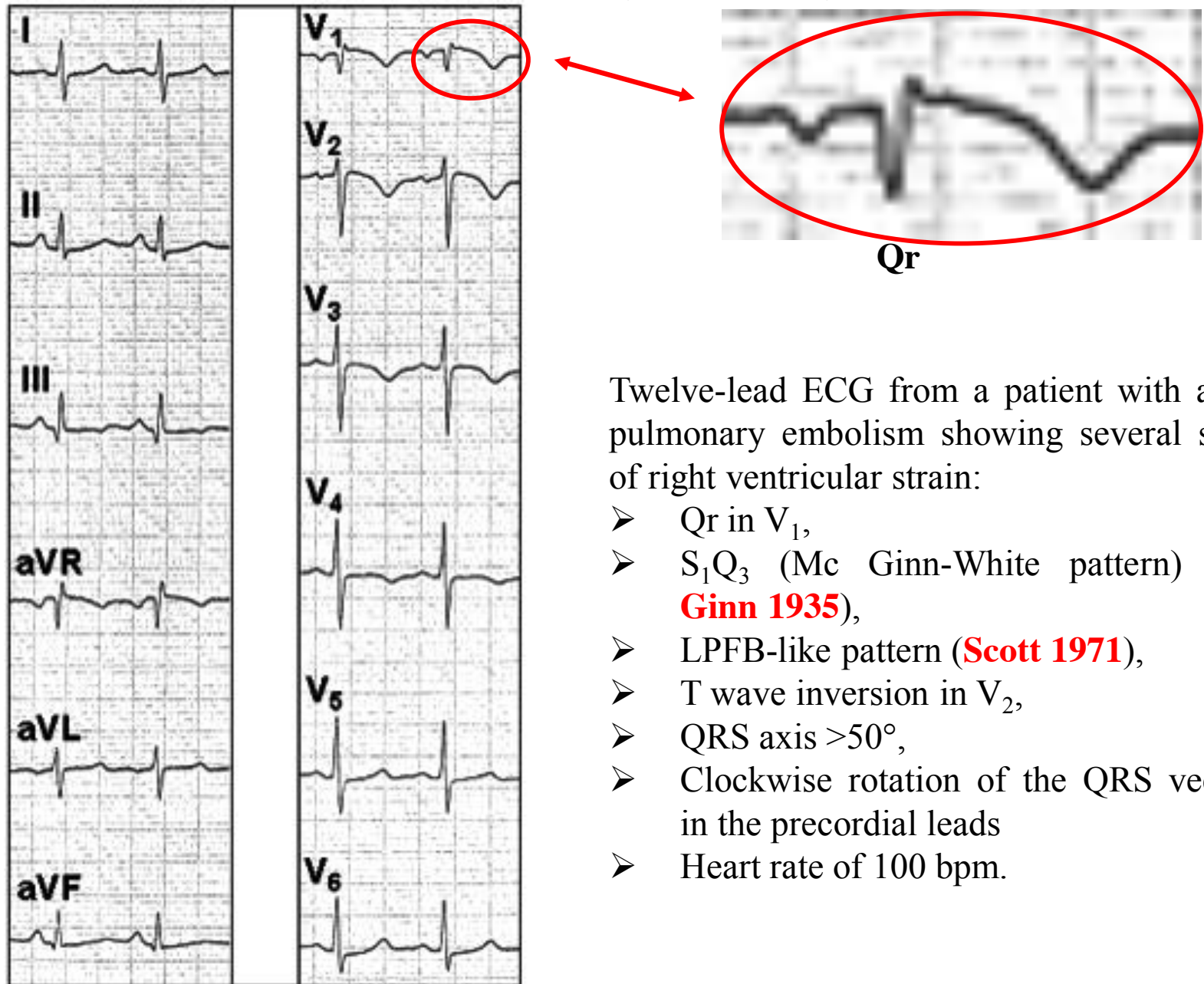


2. Systolic right ventricular hypertrophy with strain pattern: supra-systemic right intraventricular pressure. E.g.: severe or extreme pulmonary stenosis. pulmonary stenosis qR or qRs in  $V_4R$  and  $V_1$ ; inversion of septal activation. Supra-systemic right intraventricular pressure. Negative “primary” T waves in inferior precordial leads (**Gandhi 1962**).





3. **Acute pulmonary embolism:** QR/Qr pattern in V1 is an ECG sign associated with right ventricular strain and adverse clinical outcome in pulmonary embolism. Among the ECG signs seen in patients with acute pulmonary embolism, Qr in V1 is closely related to the presence of right ventricular dysfunction, and is an independent predictor of adverse clinical outcome (**Kucher 2003**)

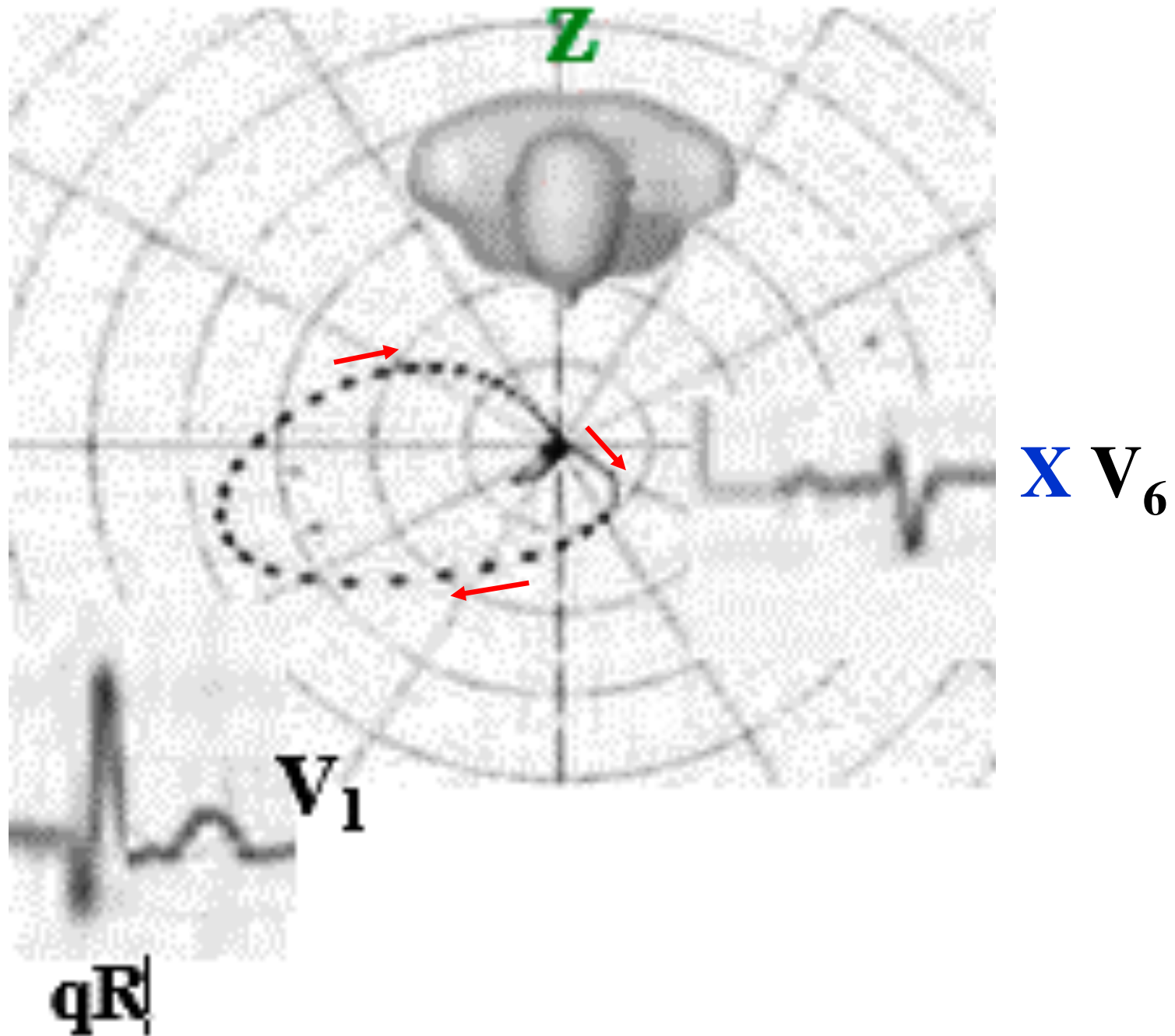


Twelve-lead ECG from a patient with acute pulmonary embolism showing several signs of right ventricular strain:

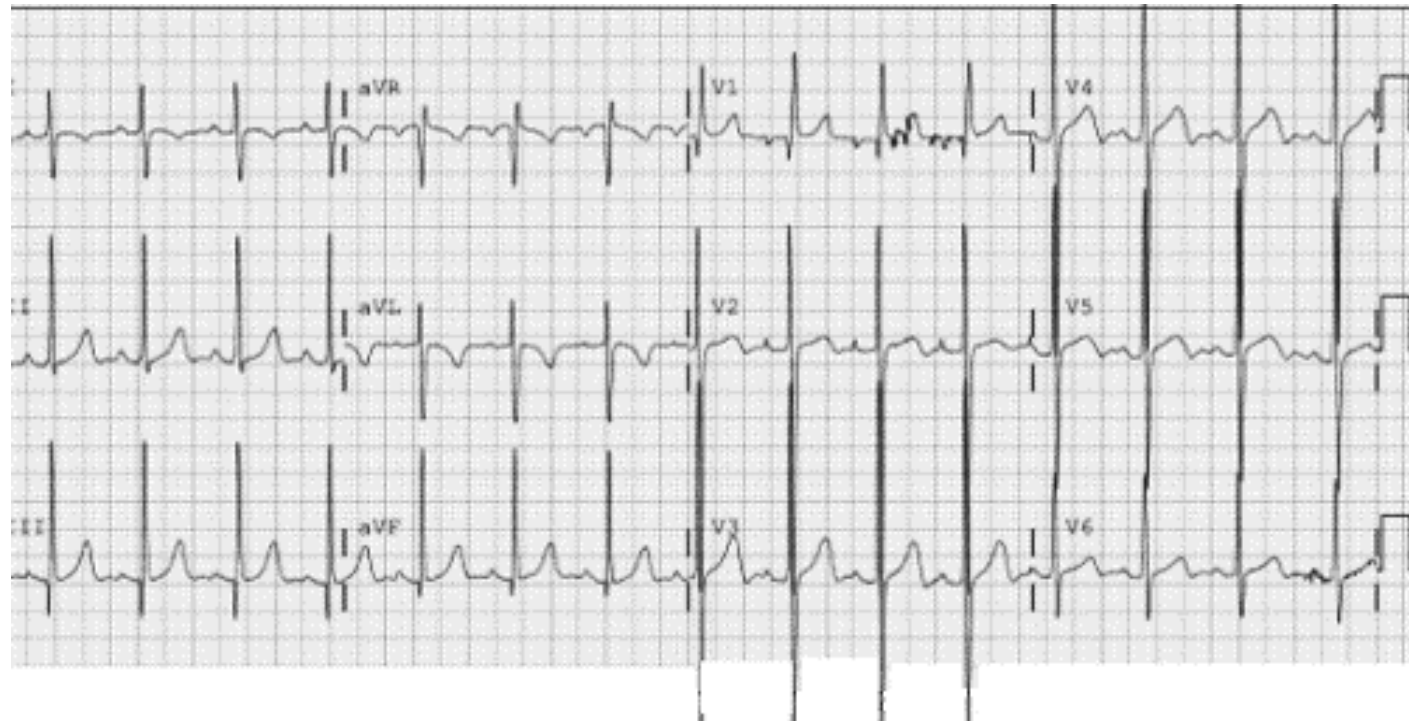- Qr in V<sub>1</sub>,
- S<sub>1</sub>Q<sub>3</sub> (Mc Ginn-White pattern) (**Mc Ginn 1935**),
- LPFB-like pattern (**Scott 1971**),
- T wave inversion in V<sub>2</sub>,
- QRS axis >50°,
- Clockwise rotation of the QRS vectors in the precordial leads
- Heart rate of 100 bpm.



4. Right Bundle Branch Block with isoelectric initial r wave in  $V_1$
5. **Situs inversus (ventricular inversion):** inverted septal activation.


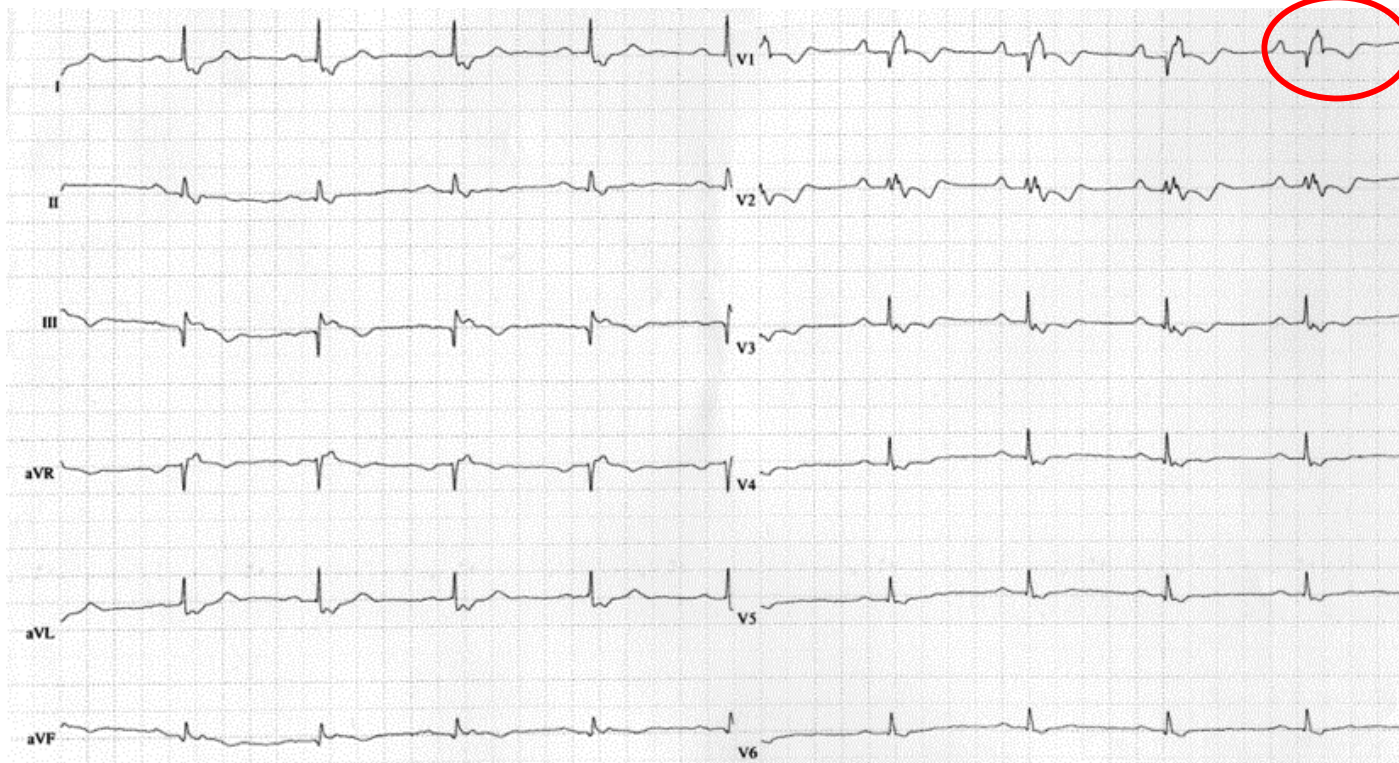


6. **Congenitally corrected transposition of the Great Arteries (CCTGA)** is a rare cardiac malformation characterized by the combination of discordant atrioventricular and ventriculo-arterial connections, usually accompanied by other cardiovascular malformations. Incidence: around 1/33,000 live births, accounting for approximately 0.05% of congenital heart diseases. Associated malformations may include interventricular communications, obstructions of the outlet from the morphologically left ventricle, and anomalies of the tricuspid valve. The clinical picture and age of onset depend on the associated malformations, with bradycardia, a single loud second heart sound and a heart murmur being the most common manifestations. In the rare cases where there are no associated malformations, can lead to progressive atrioventricular valvar regurgitation and failure of the systemic ventricle. The diagnosis can also be made late in life when the patient presents with complete AV block or cardiac failure. Diagnosis can be made by fetal echocardiography, but is more commonly made postnatally with a combination of clinical signs and echocardiography, magnetic resonance imaging and catheterization (**Warnes 2006; Ruttenberg 1966**).



The electrocardiogram shows a qR pattern in lead V<sub>1</sub>, with absence of Q waves in leads V<sub>5</sub> and V<sub>6</sub>, demonstrating abnormal ventricular depolarization.

7. Endomyocardiofibrosis (**Tobias 1992**).
8. Pectus excavatum
9. Indirect ECG criteria of right atrial enlargement (RAE) Sodi Pallares sign (**Sodi-Pallares 1952**): qR, QR or qRs in V<sub>1</sub> and V<sub>2</sub> The volumetric increase of the right atrium (RA), gets closer to the exploring electrode V<sub>1</sub>, recording initial QRS negativity in this lead, because this electrode records the epicardial morphology of the RA. Important dilatation of the right atrium: E.g.: Ebstein's anomaly: mega right atrium, bizarre QRS with CRBBB of low voltage and initial small q wave in V1 (**Lowe 1968**), tricuspid insufficiency. See figure in next slide.



**Clinical diagnosis:** Ebstein's anomaly (**Kumar 1971**).

**EEC diagnosis** HR 59bpm, broad and tall P waves ("Himalayan" P waves), P axis +18°, right atrial enlargement,, first degree AV block (PR= 224ms) due to intra-atrial conduction delay., bizarre and low voltage QRS RBBB pattern with initial Q wave and T wave inversion in V1-4 and a marked Q wave in III, QT/QTc= 458/453

# ECG in Ebstein's anomaly

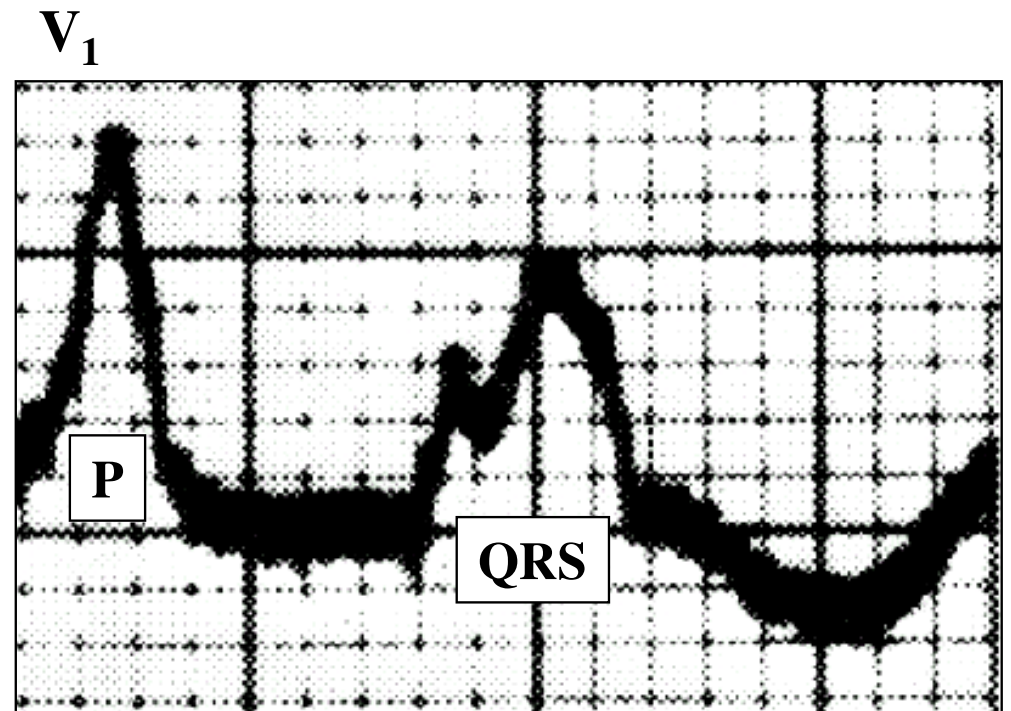
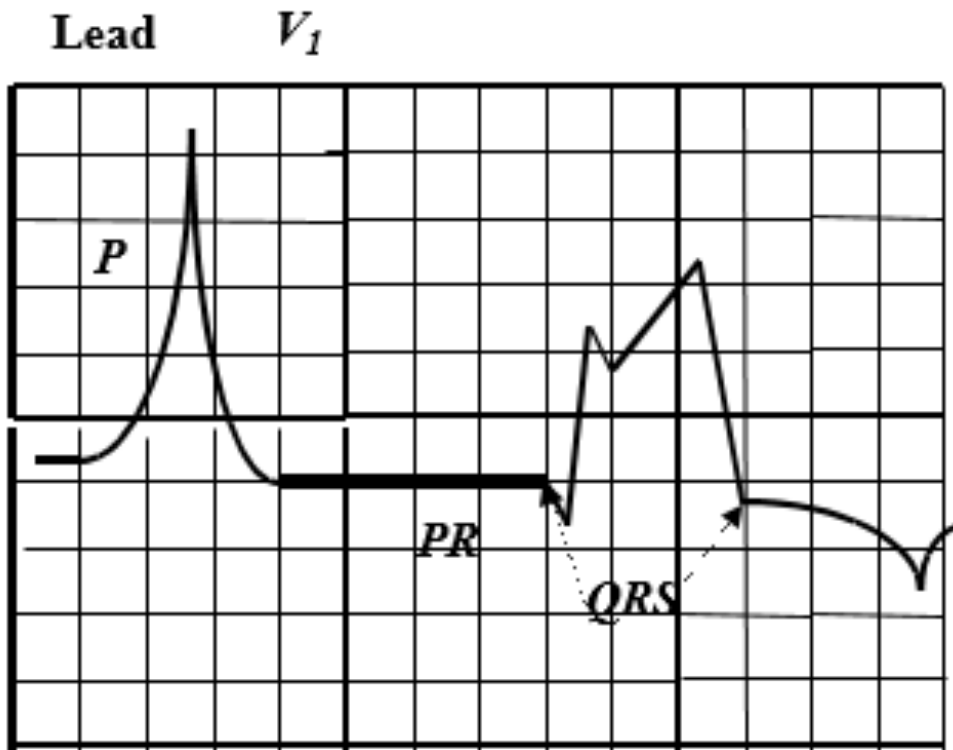
In 30% of the cases, atrial fibrillation, flutter, supraventricular and ventricular paroxysmal tachycardia.

AQRS: generally inferior and to the right between  $+90^\circ$  and  $+130^\circ$ .

Giant P waves of right atrial enlargement: "Himalayan" P waves, PR interval frequently prolonged: 20%.

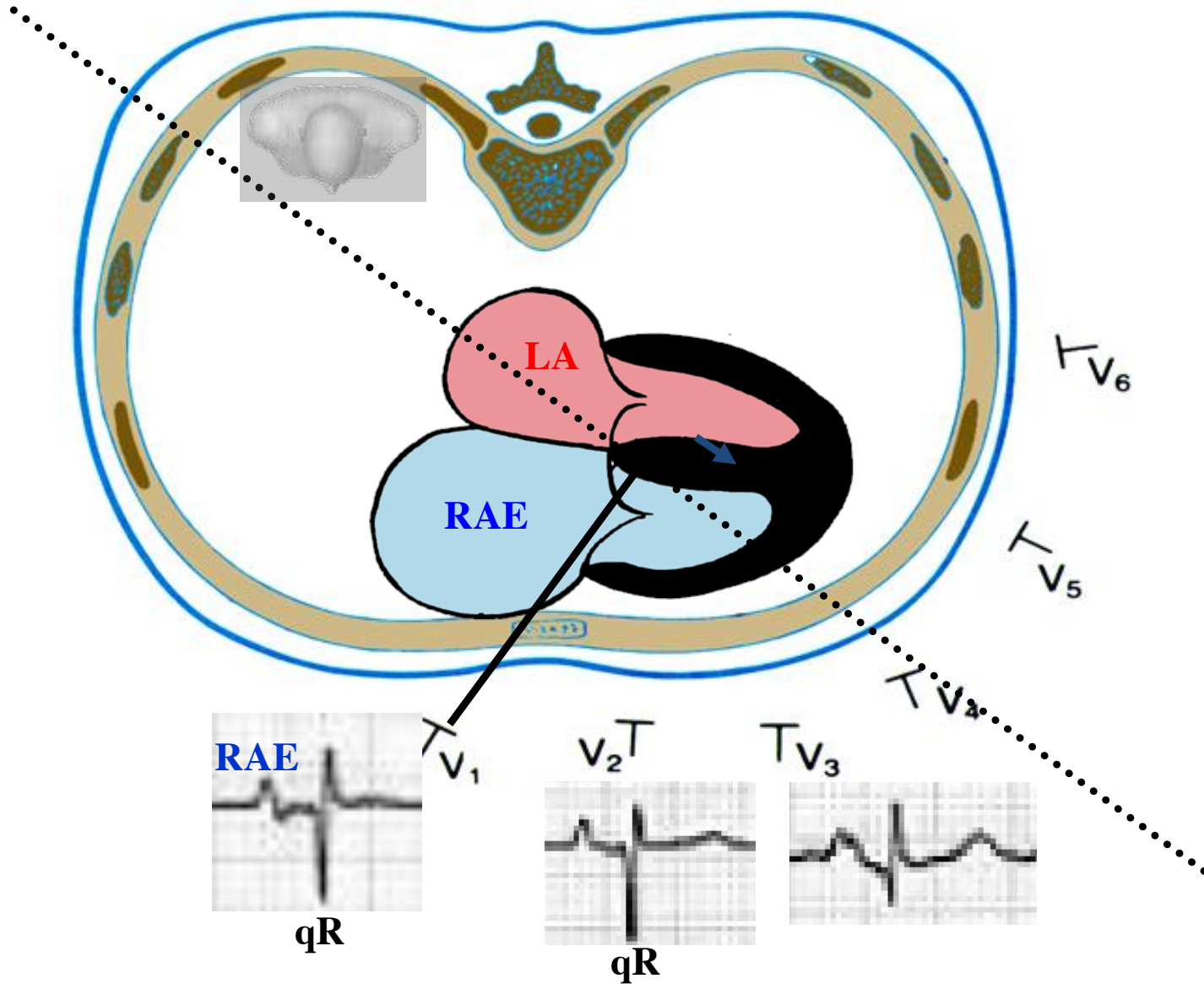
IRBBB or CRBBB of low voltage, bizarre aspect, initial Q wave in right and middle precordial leads (from  $V_1$  to  $V_4$ ) are recorded in 50% of the cases in  $V_1$  to  $V_3$ . It is frequent to record tri or tetraphasic patterns.

Possible type B WPW with anomalous bundle located in the RV free wall (anomalous bundle between the RA and the RV).





# Significant dilatation of Right Atrium: Indirect sign of **RAE** conditioning qR pattern in $V_1$ and $V_3R$ (Sodi-Pallares' sign) (**Sodi-Pallares 1952**)



Outline that explains the indirect sign of RAE: qR in  $V_1$  (Sodi-Pallares' sign). The volumetric increase of the RA, gets closer to the exploring electrode  $V_1$ , recording initial QRS negativity in this lead, because this electrode records the epicardial morphology of the right atrium.



Question: Is the first ECG an acute anterior or anteroseptal or it is an anterolateral MI? Answer: It is an Apical-Anterior MI because the event involve also V5-V6, and there are no abnormal Q waves in aVL and I. In anterior or anteroseptal myocardial infarction the ECG changes are confined to the chest leads (V<sub>1</sub>-V<sub>4</sub>).

### **New classification of Q wave MI following correlation with MRI**

**Septal Myocardial Infarction:** Q waves in V<sub>1</sub>-V<sub>2</sub>. The CMR reveals involvement of the septal wall and often a small part of the adjacent anterior wall. The infarct is caused either by occlusion of septal branches or LAD distal to origins of the diagonal branches.

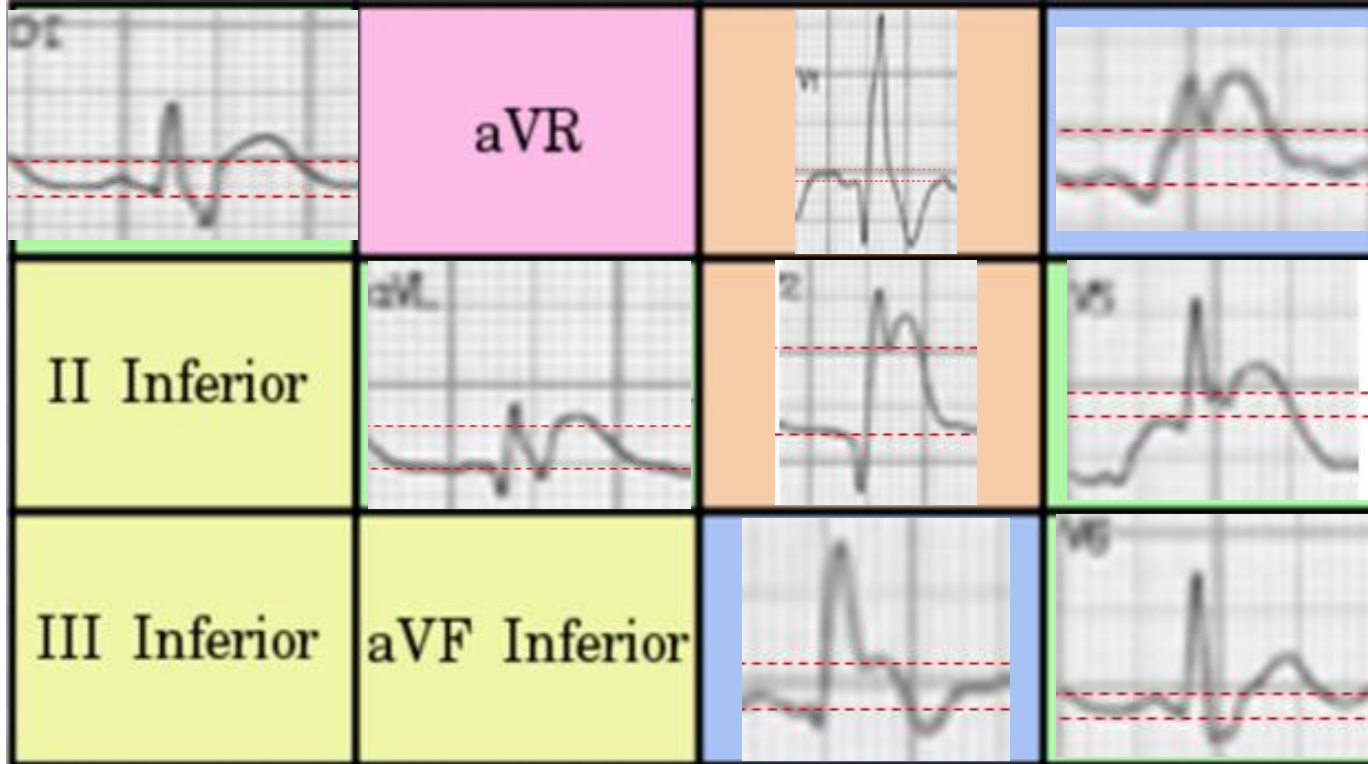
**Mid-Anterior Myocardial Infarction:** abnormal Q waves in aVL and sometimes I but not in V<sub>5</sub>-V<sub>6</sub>. A Q wave in V<sub>2</sub>-V<sub>3</sub> may be present. CMR shows that the infarction encompasses especially the mid-low segments (7 and 13) of the anterior wall. Cause: occlusion of the first Dg of the LAD (**Sclarovsky 1994**).

**Apical-Anterior Myocardial Infarction:** V<sub>1</sub>-V<sub>4</sub> and sometimes V<sub>5</sub>-V<sub>6</sub>. There are no abnormal Q waves in leads aVL and I. The CMR documents MI in the LV apex, often with extension into both the anterior and septal walls but not into the lateral wall. "Culprit artery": mid-LAD occlusion.

**Extensive Anterior Myocardial Infarction:** It is a combination of types a, b, and c. Abnormal Q waves in the precordial leads, aVL and sometimes I. The CMR documents that the infarct extensively involves the anterior, septal, and mid-low lateral walls. Cause: occlusion of the LAD proximal to both the initial septal and diagonal branches.

**Lateral Myocardial Infarction:** Q-wave equivalents of abnormally prominent R waves in V<sub>1</sub>-V<sub>2</sub>. Abnormal Q waves in I, aVL, and/or V<sub>5</sub>-V<sub>6</sub>. CMR: infarction in the lateral walls. Cause: occlusion of a nondominant LCX or of its marginal branch.

**Inferior Infarction:** Q waves in II, III, and VF but without increased R waves in V<sub>1</sub>-V<sub>2</sub>. The CMR shows involvement of the inferior wall, very often including the basal segment. It may be involved by the inferior part of the septal wall because the PDA has "perforating" branches that supply part of the inferior portion of the septum. Cause: occlusion of the dominant coronary artery that supplies the PDA. This is the RCA in ≈90% and the LCX in ≈10%. When the RCA or LCX is very dominant and the occlusion is proximal, the infarction encompasses both the inferior and the lateral wall, and then the ECG pattern is the association of criteria of inferior and lateral MI (inferolateral MI).



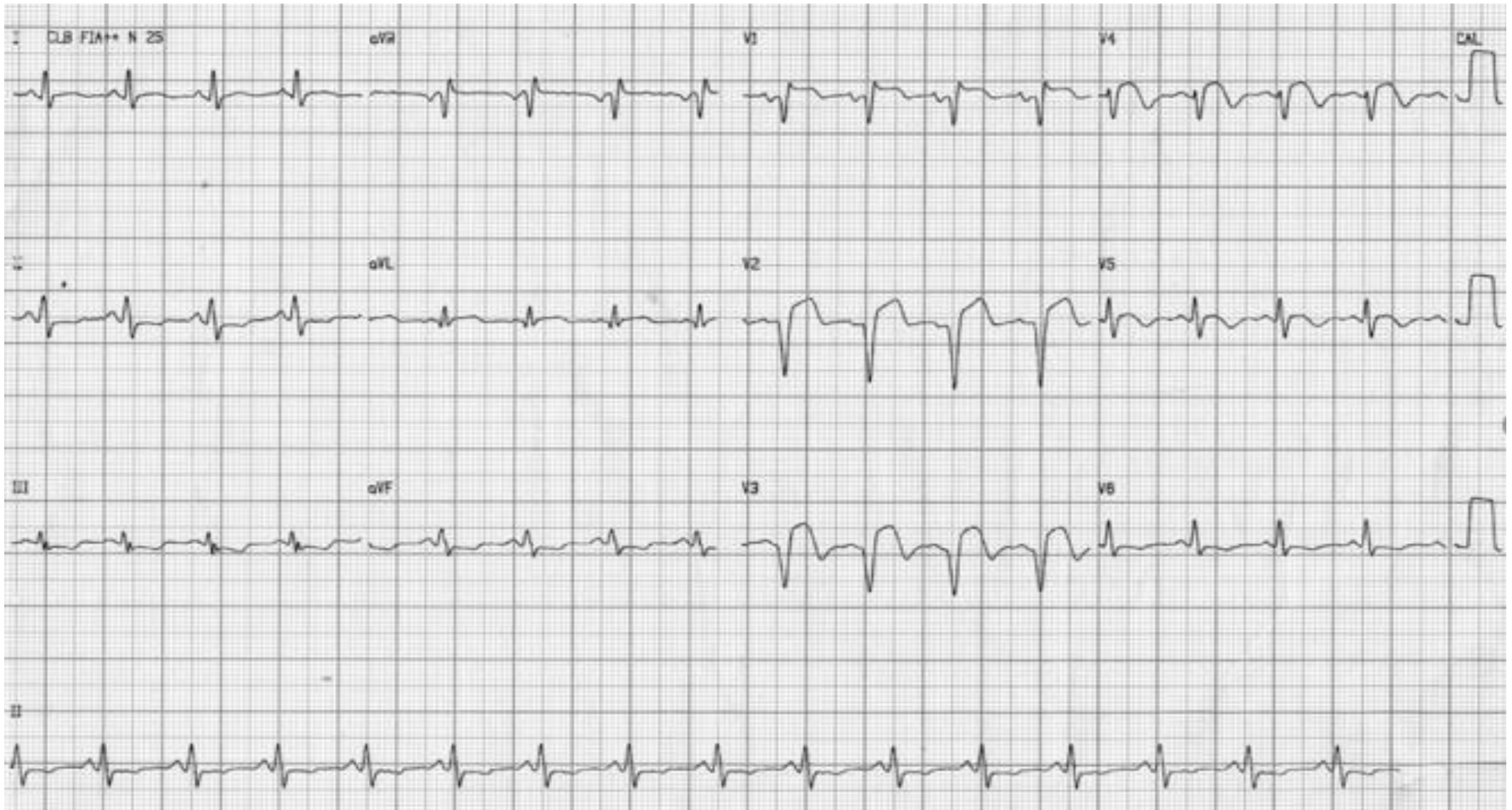
The terms posterior and high lateral MI are incorrect (**Bayés de Luna 2006**)

I Lateral	aVR	V1 Septal	V4 Anterior
II Inferior	aVL Lateral	V2 Septal	V5 Lateral
III Inferior	aVF Inferior	V3 Anterior	V6 Lateral

# Causes of greater vulnerability of the LAF in comparison to the LPF

- 1. Anatomical:** (**Rosenbaum 1970a,b**) a) Less diameter (LAF: 3 mm; LPF: 6 mm).; b) Greater extension (LAF: 35 mm; LPF: 30 mm).
- 2. Electrophysiological:** As a consequence of its greater extension and less diameter, the depolarization and repolarization of LAF is slower than LPF, i.e. the “QT of LAF” is greater than the one of LPF, a fact that makes it more vulnerable.
- 3. Vascular:** LPF is always irrigated by the two systems of the LAD and RCA. The proximal part of the LPF is supplied by the AV nodal branch and, at times, by septal branches of the LAD artery. The distal portion has a dual blood supply from both anterior and posterior septal perforating arteries. The AV nodal branch is a cardiac artery that is crucial because it feeds the AV node, necessary for the excitation and contraction of the ventricles. In over 80% of humans it arises as a distal branch from the RCA near the crux of the heart. In  $\approx 18\%$ , the AV node instead receives blood from the LCX, In  $\approx 2\%$  of people, the vascular supply to the AV node arises from both the RCA and the LCX (**Sow 1996**). The broad nature of the LPI, its protected location in the left ventricular inflow tract as well as its dual blood supply (**James 1965**) makes isolated left posterior fascicular block (LPFB) very rare (**Rokey 1984**). The posteromedial papillary muscle where LPF ends is supplied by those arteries that terminate on the diaphragmatic surface of the LV, and most commonly by a junction of terminal branches of the LCX and of the RCA. When the LCX supplies nearly all the diaphragmatic surface of the LV (10% of human hearts), its branches provide the entire blood supply for the posteromedial papillary muscle. The LPF is irrigated in 10% of cases by LAD only, in 40% of cases by LAD and RCA and in 50% of cases by RCA only.
- 4. Topographic:** The LPF runs through a more protected area, with less pressure mechanic impact. The LAF runs diagonally through the Left Ventricle Outflow Tract (LVOT) by the subendocardium. This region is subject to a great turbulence and high pressure, which justifies the greater vulnerability of the LAF when compared to the LPF, which runs through an area in the LV Inflow Tract (LVIT), which is much less exposed to turbulence, which explains the rarity of the LPFB.

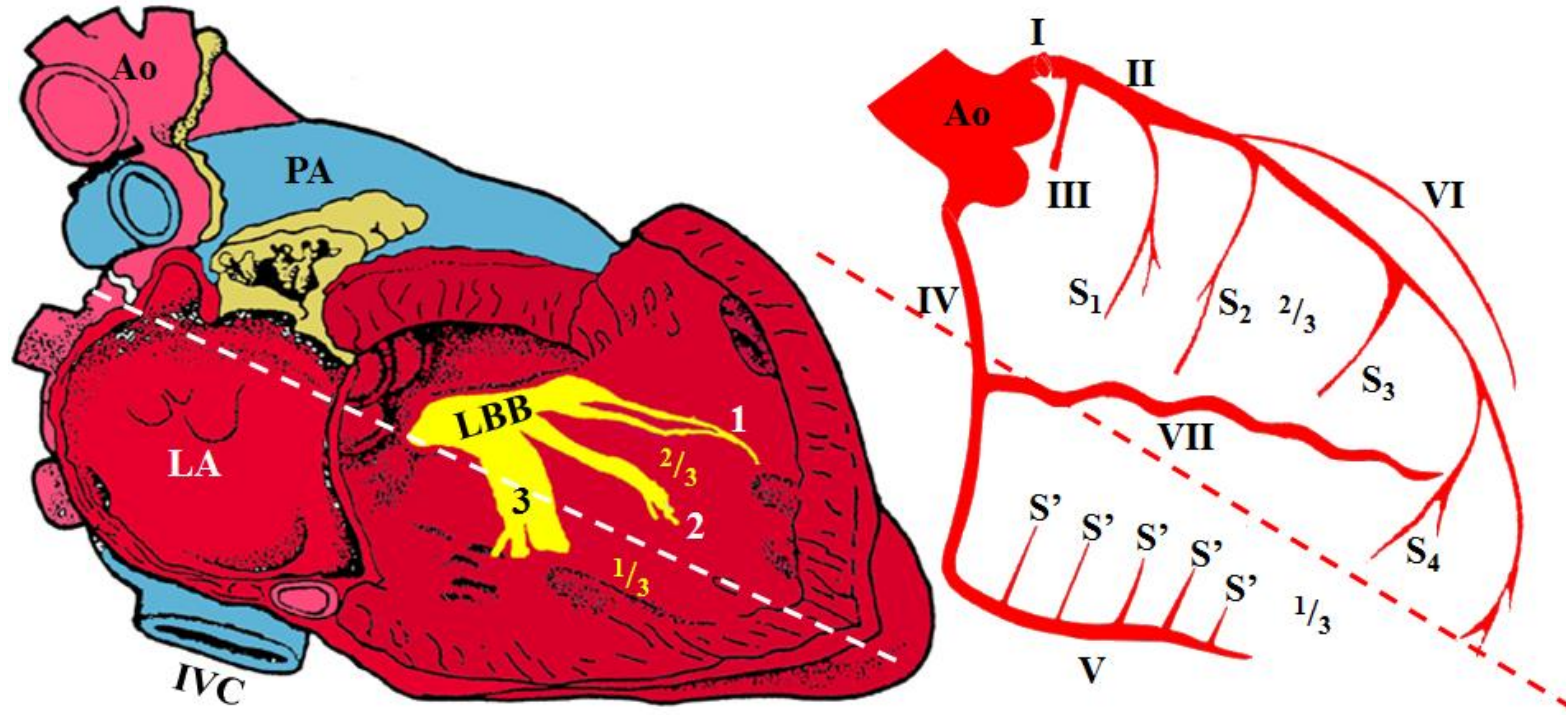
# ECG performed after stent implantation



**ECG diagnosis:** Sinus tachycardia, QRS voltage is low in the limb leads (The amplitudes of all the QRS complexes in the limb leads are  $< 5$  mm) and V5-V6, but normal in precordial leads V1. to V4. only the QRS complexes in V5-V6 precordial leads have  $< 10$  mm. Transmural anterior myocardial infarction with persistent ST segment elevation from V1 to V4.



# Schematic diagram of blood supply to the cardiac conduction system



LBB: Left Bundle Branch  
 LA: Left Atrium  
 IVC: Inferior Vena Cava  
 PA: Pulmonary Artery  
 Ao: Aorta

1. Left Anterior Fascicle (LAF)
2. Left Septal Fascicle (LSF)
3. Left Posterior Fascicle (LPF)

- I. Left Main Coronary Artery (LMCA)
- II. Left Anterior Descending Artery (LAD)
- III. Left Circumflex Coronary Artery (LCX)
- IV. Right Coronary Artery (RCA)
- V. Posterior Descending Artery (PDA). In this case is supplied by the RCA, then coronary circulation can be classified as "right-dominant"
- VI. First Diagonal (Dg)
- VII. Acute Marginal (A. Mg)
- S<sub>1</sub>, S<sub>2</sub>, S<sub>3</sub>, S<sub>4</sub>: Septal Perforator Branches of the LAD
- S': Posterior Septal Perforator Branches of the PDA

The septal branches of the LAD supply two-thirds of the anterior portion of the IVS, while the inferior portion of the septum is supplied by septal branches of the PDA, which usually arises from the RCA and infrequently from the LCX.

# Blood supply of the Right Bundle Branch (RBB)

1) His Right Penetrating Portion of His Bundle

2) His Right Branching Portion of His Bundle

## Right Bundle Branch (RBB)

3) Proximal or membranous portion of RBB

It is irrigated by the AV node artery of the RCA and the first septal perforator artery ( $S_1$ ) of the LAD.

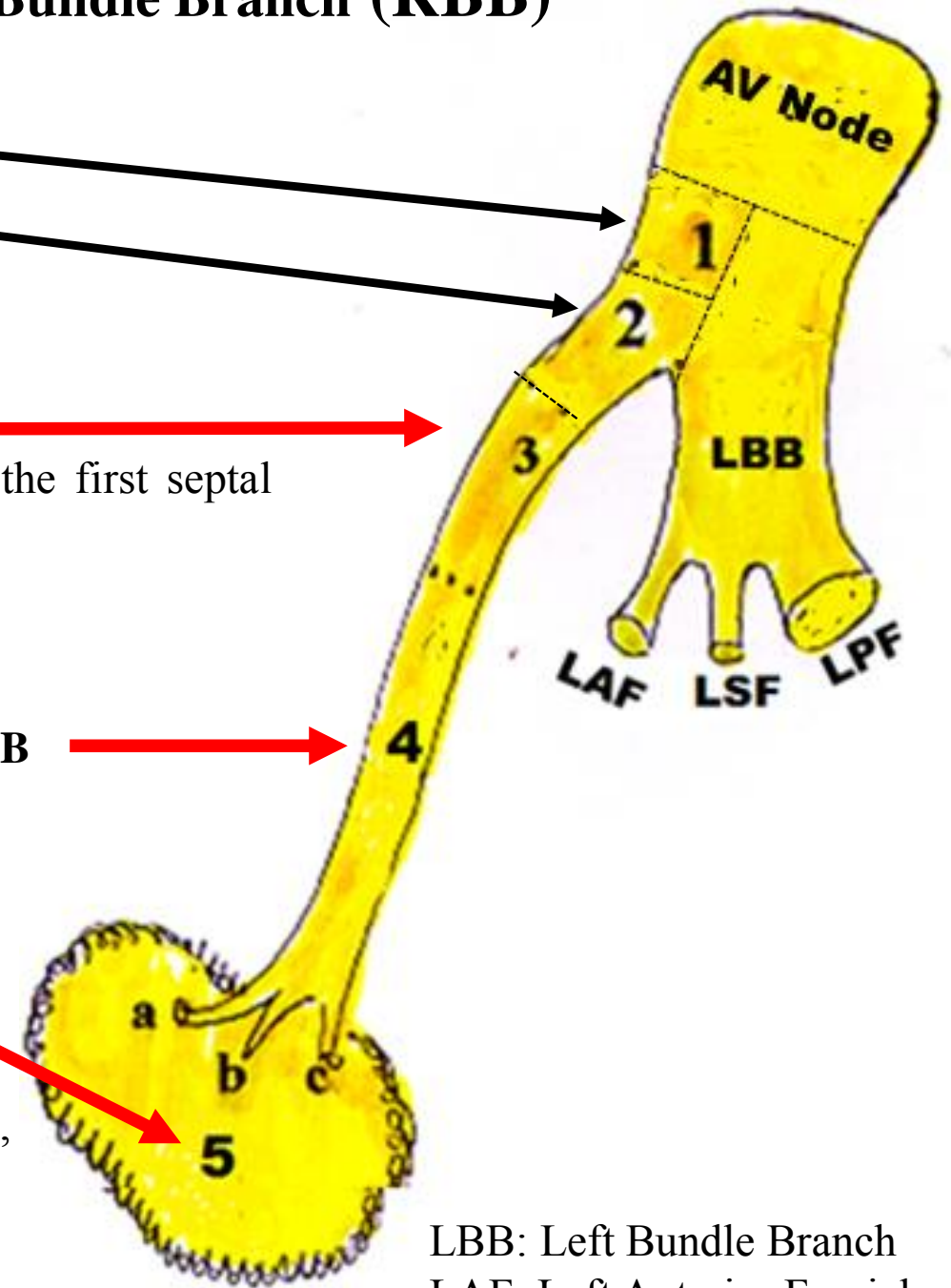
4) Middle, intra-myocardial or mimetic portion of RBB

is irrigated by: Posterior Septal perforators of the PDA  
Second septal perforator artery ( $S_2$ ) of the LAD  
Kugel's artery, branch of the LCX.

5) Distal, inferior or intra-moderator band of RBB

Portions 4 and 5 are irrigated by the "ramus limbi dextri", branch of the  $S_2$  of the LAD.

a, b, c: divisions of the RBB in the free wall



LBB: Left Bundle Branch  
LAF: Left Anterior Fascicle  
LSF: Left Septal Fascicle  
LPF: Left Posterior Fascicle



## Right lateral view

SA-Node

Ao

AV-Node

Right His Bundle

PA

Right Bundle Branch

SVC

RA

TV

IVC

Coronary sinus

Intra-moderator band

- A) **Right His Bundle:** 1) His right penetrating portion; 2) His right branching portion of His bundle.
- B) **Right Bundle Branch:** 3) Proximal or membranous of RBB; 4) Middle, intramyocardial or mimetic portion of RBB; and 5) Inferior, distal or intra-moderator band.

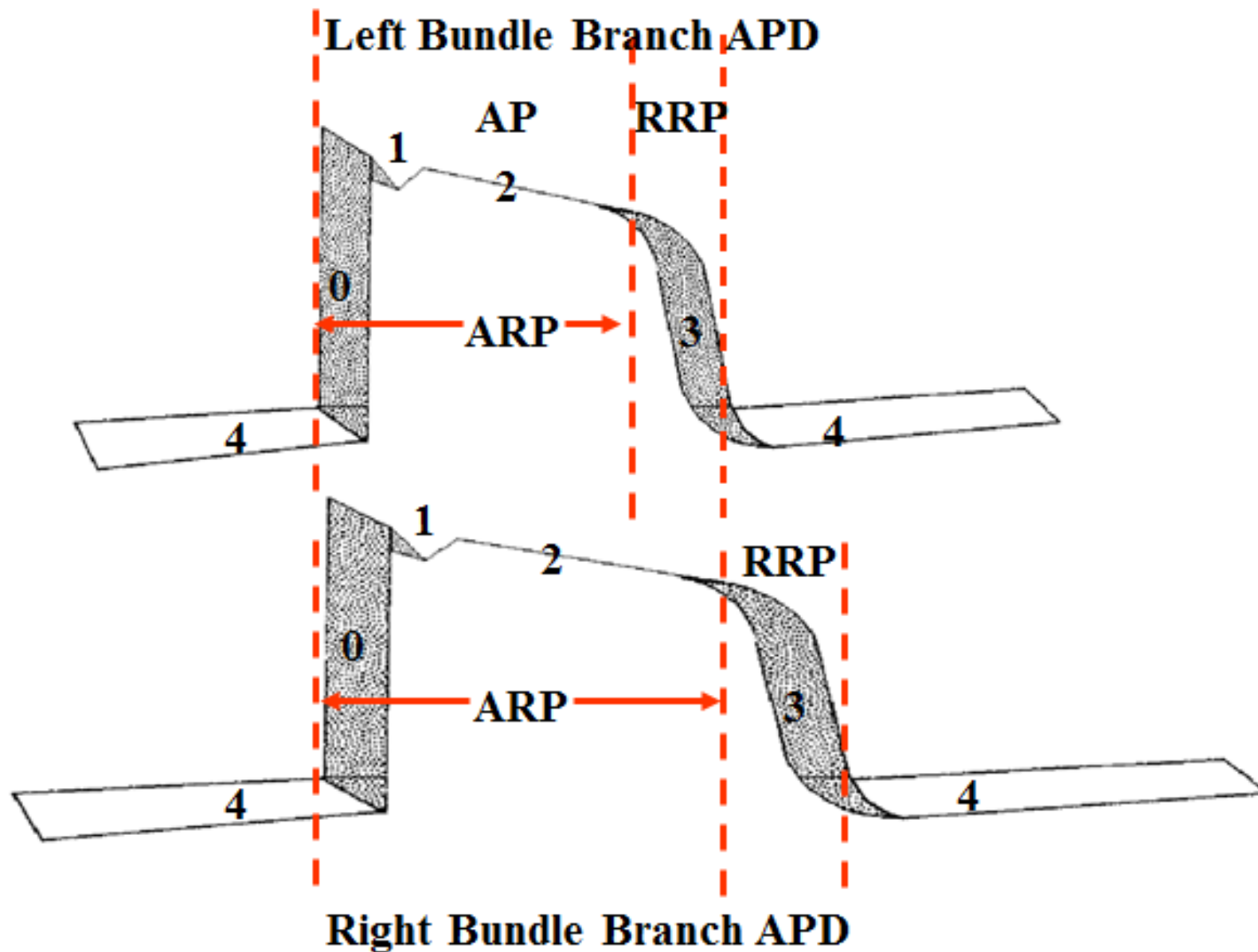
## **A) Right His system**

- 1. His right penetrating portion:** It is inserted in the central fibrous body. This is the strongest part of the fibrous cardiac skeleton. It is a high density single structure of connective tissue that forms and anchors the valves and influences the forces exerted through them. The cardiac skeleton separates and partitions the atria (the smaller, upper two chambers) from the ventricles (the larger, lower two chambers). This is important because it forms the primary channel that electrical energy follows from the top to the bottom of the heart.
- 2. Right branching portion of the His bundle:** It stretches from the origin of the LPF of the LBB until the origin of the right bundle branch (RBB) and the left anterior fascicle (LAF) of the LBB. This portion is closely related with the interventricular membranous septum and with the non-coronary and right coronary cuspid of the aortic valve. Its lesion causes Complete Right Bundle Branch Block (CRBBB) almost constantly, in association with Left Anterior Fascicular Block (LAFB) by the close neighboring relationship between the right branch and the Left Anterior Fascicle (LAF).

## **B) Right Bundle Branch**

- I. Anatomical characteristics:** Length: 45 to 60 mm; Diameter: 1.5 to 2 mm; Color: whitish.
- II. Cellular type:** Purkinje cells;
- III. Conduction velocity:** 5m/s (fast fibers);
- IV. Action Potential (AP) characteristic:** Fast response type, Na<sup>+</sup> dependent, phase 4 with automatism (diastolic depolarization) and refractory period longer than the left branch: slower depolarization and repolarization. See next slide.





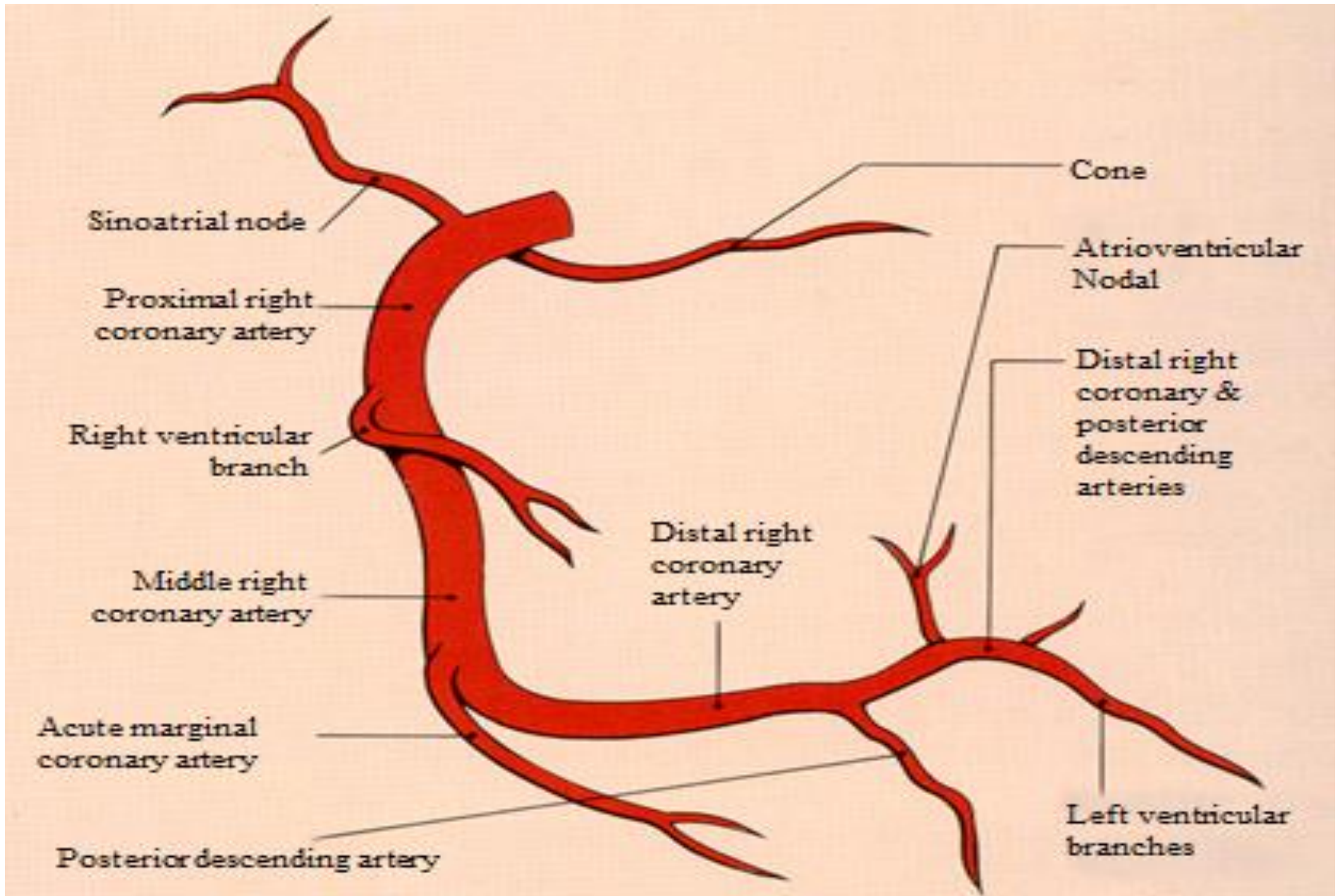
**RRP:** Relative Refractory Period  
**ARP:** Absolute Refractory Period  
**APD:** Action Potential Duration

## **V. Portions of the Right Bundle Branch:**

- 1) **Proximal or membranous:** It is 15 to 20 mm long and it is related to the following structures: septal fascicle of the tricuspid valve, right coronary valve and non-coronary valve of the aortic valve, anterior fascicle of the left branch, fibrous trigone and membranous septum.
- 2) **Middle, intramyocardial or mimetic;**
- 3) **Inferior, distal or intra-moderator band:** From 30 mm to 40 mm long, with an initial portion of 20 mm to 25 mm called, middle, intramyocardial or mimetic, which begins in the apex of the muscular septum and ends where the moderator band begins, and it continues with the distal or subendocardial portion from 10 to 15 mm, which runs inside the moderator band, ending in the base of the papillary muscle of the tricuspid valve, where it splits in three into its superior, middle and inferior divisions.

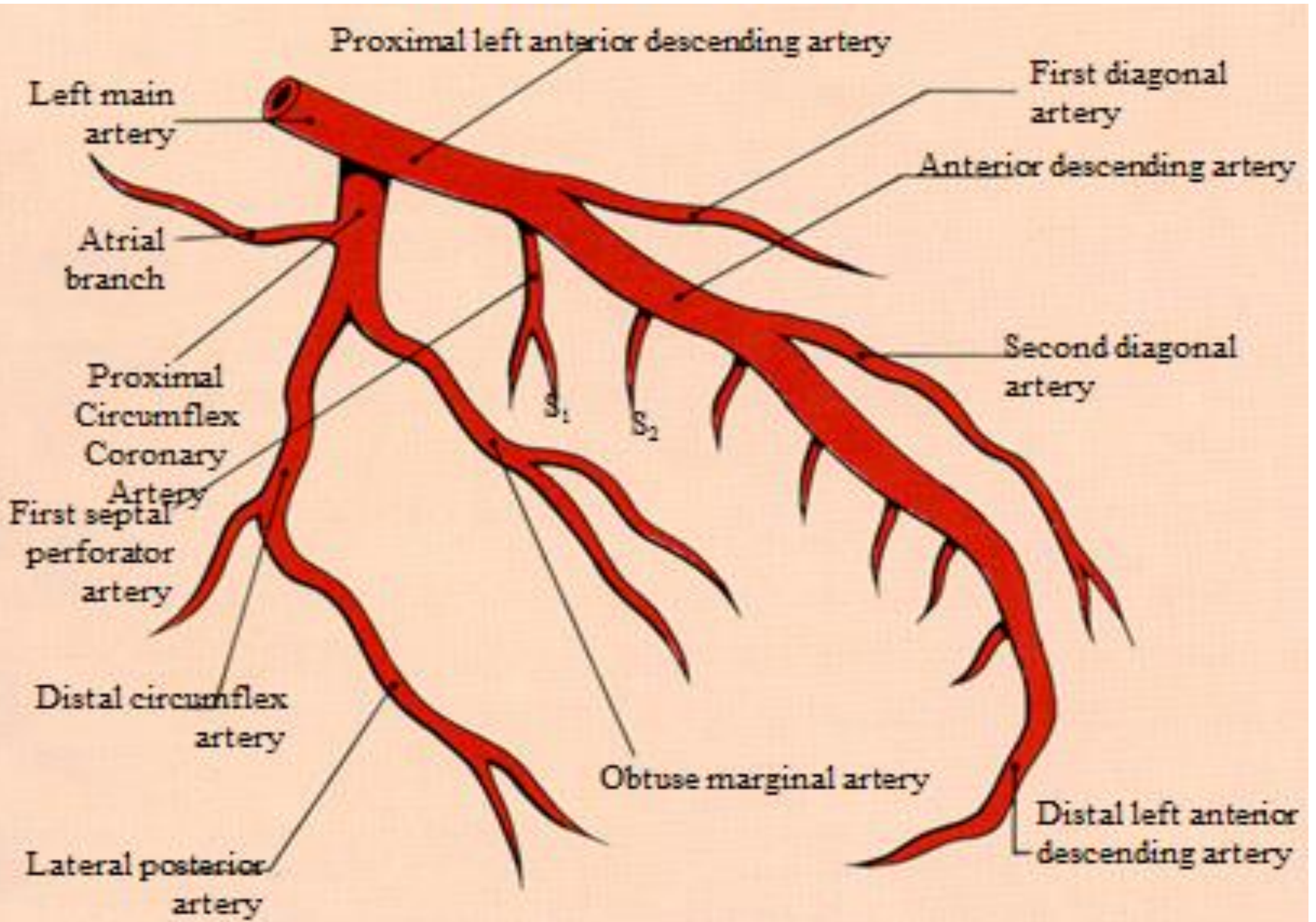
**VI. Irrigation of the Right His System (RHS):** The proximal portion of the right bundle branch and the His bundle is irrigated by the AV node artery of the right coronary artery (RCA) and the first septal perforator artery of the left anterior descending artery (LAD). Possibly, the right branch in its middle portion is irrigated by: septal branches of the posterior descending artery (PDA), of the second septal perforator artery of the LAD, and Kugel's artery, branch of the left circumflex artery (LCA). The middle and distal portion of the right branch are irrigated by the "ramus limbi dextri," branch of the second septal perforator of the LAD.

# Right coronary artery





# Left coronary artery





## Blood supply of the left fascicles of left bundle branch

- 1. Left Anterior Fascicle (LAF)** Is supplied either by septal branches of the LAD or by the AV nodal artery.
- 2. Left Posterior Fascicle (LPF):** The proximal part of LPF is supplied by the artery to the AV Nodal branch and, at times, by septal branches of the LAD artery. The distal portion has a dual blood supply from both anterior (S) and posterior (S') Septal Perforator Arteries. The broad nature of the LPI, its protected location in the left ventricular inflow tract as well as its dual blood supply (**James 1965**) makes isolated left posterior fascicular block (LPFB) very rare (**Rokey 1984**). The posteromedial papillary muscle where LPF ends is supplied by those arteries that terminate on the diaphragmatic surface of the LV, and most commonly by a junction of terminal branches of the LCX and of the RCA. When the LCX supplies nearly all the diaphragmatic surface of the LV (10% of human hearts), its branches provide the entire blood supply for the posteromedial papillary muscle. The LPF is irrigated in 10% of cases by LAD only, in 40% of cases by LAD and RCA and in 50% of cases by RCA only **LCX**.
- 3. Left Septal Fascicle (LSF) or Left Median Fascicle:** It is supplied exclusively by septal branches of the LAD. Critical lesions of the LAD before the first septal perforator, constitute the main cause of LSF in the first world.

### Responsible artery for the irrigation of the three fascicles of the LBB

Blood supply of the left fascicles or divisions			
Responsible system	LAF	LPF	LSF
LAD only	40%	10%	100%
Both LAD & RCA	50%	40%	0%
RCA only	10%	50%	0%

LAD – Left Anterior Descending Artery; RCA – Right Coronary Artery; LAF – Left Anterior Fascicle; LPF – Left Posterior Fascicle; LSF – Left Superior Fascicle.

## References

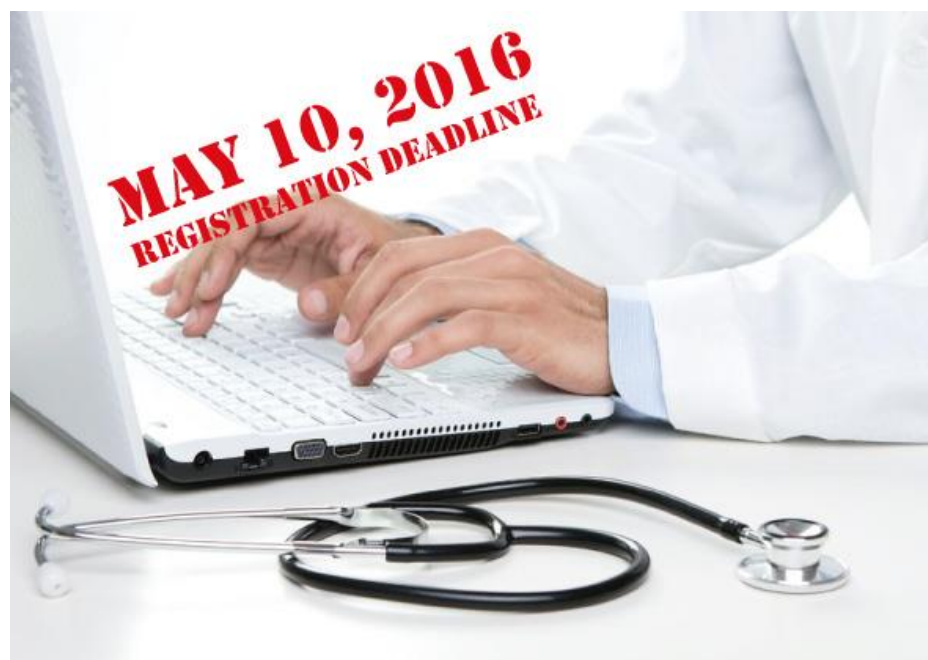
1. Andersen MP, Terkelsen CJ, Sørensen JT, et al. The ST injury vector: electrocardiogram-based estimation of location and extent of myocardial ischemia. *J Electrocardiol.* 2010;43(2):121-31.
2. Basualdo CA, Haraphongse M, Rossall RE. Intraventricular blocks in acute myocardial infarction. *Chest.* 1975; 67(1):75-8.
3. Bayés de Luna A, Wagner G, Birnbaum Y, et al. A new terminology for left ventricular walls and location of myocardial infarcts that present Q wave based on the standard of cardiac magnetic resonance imaging: a statement for healthcare professionals from a committee appointed by the International Society for Holter and Noninvasive Electrocardiography. *Circulation.* 2006;114(16):1755-60.
4. Botvinick EH, Perez-Gonzalez JF, Dunn R, Ports T, Chatterjee K, Parmley W. Late prognostic value of scintigraphic parameters of acute myocardial infarction size in complicated myocardial infarction without heart failure. *Am J Cardiol.* 1983;51(7):1045-51.
5. Elizari MV, Acunzo RS, Ferreiro M. Hemiblocks revisited. *Circulation.* 2007;115(9):1154-63.
6. Gandhi MJ, Dattey KK, Kulkarni TP, Hansoti RC. Genesis of qR pattern in right precordial leads in right ventricular overload. *J Assoc Physicians India.* 1962;10:217-23.
7. James TN. Anatomy of the coronary arteries in health and disease. *Circulation.* 1965;32(6):1020-33.
8. Kapoor J, McConnell M. A swinging heart. *N Engl J Med.* 2009;361(18):e 37.
9. Klein H, Di Segni E, Kaplinsky E. Procainamide-induced left anterior hemiblock of the 2:1 type (pseudoelectrical alternans). *Chest.* 1978;74(2):230-3.
10. Kucher N, Walpoth N, Wustmann K, Noveanu M, Gertsch M. QR in V1--an ECG sign associated with right ventricular strain and adverse clinical outcome in pulmonary embolism. *Eur Heart J.* 2003;24(12):1113-9.
11. Kumar AE, Fyler DC, Miettinen OS, Nadas AS. Ebstein's anomaly. Clinical profile and natural history. *Am J Cardiol.* 1971;28(1):84-95.
12. Lowe KG, Emslie-Smith D, Robertson PG, et al. Scalar, Vector, and Intracardiac Electrocardiograms in Ebstein's Anomaly. *Br Heart J.* 1968;30(5):617-29.

13. Marriott HJ, Hogan P. Hemiblock in acute myocardial infarction. *Chest*. 1970;58(4):342-4.
14. McGinn S, White PD. Acute cor pulmonale resulting from pulmonary embolism: its clinical recognition. *JAMA* 1935;114:1473.
15. Rathore SS, Gersh BJ, Berger PB, et al. Acute myocardial infarction complicated by heart block in the elderly: prevalence and outcomes. *Am Heart J*. 2001;141(1):47-54.
16. Rokey R, Chahine RA. Isolated left posterior fascicular block associated with acquired ventricular septal defect. *Clin Cardiol*. 1984;7(6):364-9.
17. Rosenbaum, MB. The Hemiblocks: Diagnostic criteria and clinical significance. *Mod. Concepts Cardiovasc. Dis.*1970;39(12):141-6.
18. Rosenbaum, MB, Elizari MV, Lazzari JO. The Hemiblocks. *New Concepts of intraventricular Conduction Based on Human Anatomical Physiological, and Clinical Studies*. Oldsmar, Florida: Tampa Tracings, 1970.
19. Rudiakov LaI. On The Diagnostic Significance Of The qR Type QRS Complex In Right Electrocardiographic Leads. *Kardiologia*. 1964;18:72-3.
20. Ruttenberg HD, Elliott LP, Anderson RC, Adams P Jr, Tuna N. Congenital corrected transposition of the great vessels. Correlation of electrocardiograms and vector cardiograms with associated cardiac malformations and hemodynamic states. *Am J Cardiol*. 1966; 17(3):339-54.
21. Sclarovsky S, Birnbaum Y, Solodky A, Zafrir N, Wurzel M, Rechavia E. Isolated mid-anterior myocardial infarction: a special electrocardiographic sub-type of acute myocardial infarction consisting of ST-elevation in non-consecutive leads and two different morphologic types of ST-depression. *Int J Cardiol*. 1994; 46: 37-47.
22. Scott RC. The S1-Q3 (Mc Ginn-White) pattern in acute cor pulmonale: A form of transient left posterior hemiblock? *Am Heart J*. 1971;82(1):135-7.
23. Sodi Pallares D, Bisteni A, Hermann GR. Some views on the significance of qR and QR type complexes in right precordial leads in the absence of myocardial infarction. *Am Heart J*. 1952;43(5):716-34.
24. Sow ML, Ndoeye JM, Lo EA. The artery of the atrioventricular node: an anatomic study based on 38 injection-dissections. *Surg Radiol Anat* 1996;18(3):183-7.

25. Tobias NM, Moffa PJ, Pastore CA, et al. The electrocardiogram in endomyocardial fibrosis. *Arq Bras Cardiol.* 1992;59(4):249-53.
26. Warnes CA. Transposition of the great arteries. *Circulation* 2006;114(24):2699-709.



# 43rd International Congress on Electrocardiology Palma, Balearic Island, Spain - June, 4-6 2016



The registration process for the **ICE2016** is actually running. Hurry up and register now, don't miss this opportunity to join this World class event.

**Registration Deadline** is just a few days away, by **May 10th** the process will be over.

The full set of activities programmed for this event, the scientific committee, speakers and guidelines are available at the [official ICE2016 website](#). Don't hesitate to check it all ! Where? The ICE 2016 will take place in **Palma de Mallorca, Balearic Islands, Spain**.

Mallorca is well known for its beaches and coves, but is also a perfect destination to enjoy countryside, golf, culture, water sports, and entertainment... Registration process is very simple, and there are special fees for students, SEC Members or visitors. **For further info:** **AGA TRAVEL** Paseo mallorca, 11 07011, Palma de Mallorca, Spain +34 971 222 292 [info@agatravel.com](mailto:info@agatravel.com)

