

# **Elderly woman with unusual intraventricular conduction defect**

Case by

Andrés Ricardo **Pérez-Riera M.D.Ph.D.**

Raimundo Barbosa-Barros M.D.

And

Professor Frank Yanowitz M.D.

Faculdade de Medicina do ABC- Disciplina de Cardiologia –

Santo André –São Paulo Brasil

[riera@uol.com.br](mailto:riera@uol.com.br)

## Portuguese

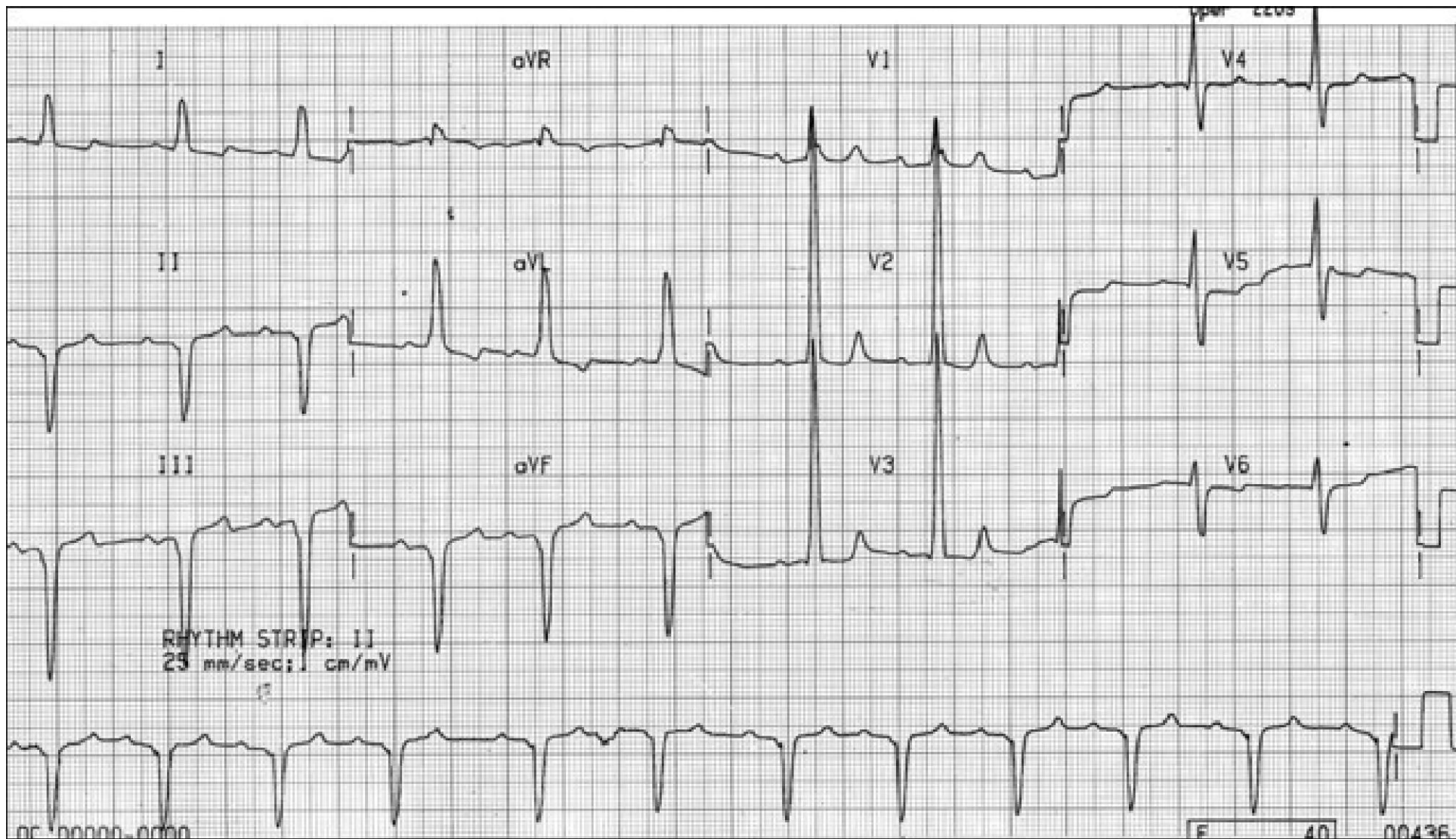
Este ECG pertence a uma idosa de 84 anos branca com história de IM no passado. Pago 1.000.000 de dólares americanos ao colega que faça o diagnóstico correto. Necessito explicações por favor!

## English

This ECG belongs to an elderly Caucasian 84 y.o. woman with a history of IM for a long time. I pay 1.000.000 American dollars to the colleague that makes the correct diagnosis. I need explanations please!!!!

We are waiting for your valuable opinions,

Andrés Ricardo Pérez-Riera M.D.Ph.D.; Raimundo Barbosa-Barros M.D and Frank Yanovitz.



Colleagues opinions

Dear Dr. Pérez Riera,

Your challenge is very tempting!

My diagnosis

1. Sinus rhythm
2. First degree AV block (at the level of the AV node or inside of left posterior fascicle of the left bundle branch).
3. Right bundle branch block and left anterior hemi block simulating left bundle branch block. Rosenbaum described this atypical pattern as "masked"; in the present case "Standard Masquerading RBB".

Could you to deposit the money in a numbered account?

If you cannot, your greetings will suffice.

A hug,

Benjamin Elencwajg M.D Argentina

[belencwajg@YAHOO.COM](mailto:belencwajg@YAHOO.COM)

## Spanish

Estimado Dr. Pérez Riera,  
Su desafío es muy tentador!

1. Ritmo sinusal.
2. Bloqueo AV de 1º grado (a nivel del nódulo AV o del fascículo posterior de la rama izquierda).
3. Bloqueo de rama derecha y hemibloqueo izquierdo anterior simulando un bloqueo de rama izquierda. Rosenbaum describió este patrón atípico como bloqueo "enmascarados".

Al cheque me lo podría depositar en una cuenta numerada?  
Si no se puede, un saludo suyo será más que suficiente.

Un abrazo

Benjamín Elencwajg

[belencwajg@YAHOO.COM](mailto:belencwajg@YAHOO.COM)

[belencwajg@YAHOO.COM](mailto:belencwajg@YAHOO.COM)

Greetings Maestro Andrés Ricardo and other forum members

My interpretation of this ECG

Sinus rhythm, HR 60, the QRS electrical axis presents extreme left shift at  $-45^\circ$ , QS pattern in inferior leads (II, III and aVF). QRS duration minimally greater than  $>120$  ms, QRS complex in V1 seems slurred R (RBBB?), and followed by a very high R wave in V2 and V3. Abnormal progression of precordial R wave. It seems a left septal fascicular block of the left bundle branch, as a cause of this blockage is myocardial infarction, and I also believe in Latin America Chagas disease in its chronic form.

Conclusion: IM + Left Septal Fascicular Block (LSFB) or in anteromedial division of the left bundle branch.

Regards,

Jesus Antonio Campuzano Chacon

[tonoczno@HOTMAIL.COM](mailto:tonoczno@HOTMAIL.COM)>

## Spanish

**Saludos Maestro Andrés Ricardo y resto de los foristas**

**Mi interpretación de este electrocardiograma:**

**Ritmo sinusal, FC 60, eje eléctrico del QRS desviado a la izquierda localizado en  $-45^\circ$ , IPR 160 ms, patrón QS en cara inferior (II, III y aVF), QRS ancho ligeramente mayor de 120 ms, QRS de V1 parece una onda R empastada, (BRDHH??), y una gran onda R en V2 y V3, progresión anormal de las R en precordiales. Me parece un bloqueo de la división media de la rama izquierda del haz de His, ya que una de las causas de de este bloqueo es el infarto al miocardio, y en latinoamerica creo también la enfermedad de Chagas en su forma crónica.**

**Conclusión: IM de cara inferior + Bloqueo de la división anteromedial de la rama izquierda del haz de His.**

**Saludos**

**Jesus Antonio Campuzano Chacon**

**[tonoczno@HOTMAIL.COM](mailto:tonoczno@HOTMAIL.COM)>**



**OK, “por la plata baila el mono” (the monkey dances for money, meaning people will do everything for money)**

**LAFB, LSFB and I think that IRBB in association**

**My account is: [DamelamoscaPotroquetecague1234](#) Banco HSBC  
Geneva Switzerland**

**A hug friend**

**Adrian Baranchuk**

Associate Professor, Program Director, Electrophysiology  
Medicine FAPC 3, Kingston General Hospital.

Telephone: (613) 549-6666 x3801

E-Mail: [barancha@kgh.kari.net](mailto:barancha@kgh.kari.net)

English

Dear friend, Professor Andrés Pérez Riera, M.D. Ph.D.

ECG analysis of the case of this adult woman. Anterosuperior hemiblock in the presence of basal hypertrophy (deep S in II, III with high R in aVL).

Positive T waves in III and negative in aVL may be due to 2 possibilities, 1) the hemiblock, 2) basal fibrosis. The absence of r waves in I, II, III, aVF is not due to inferior infarction but to hypertrophies that in adults progressively erases them in long-standing hypertrophies. Very high R waves in V2-V3 suggest high and medium septal hypertrophy. Basal and high septal hypertrophies usually appear together because they belong to the same area, but are expressed in different planes; in the anteroposterior and the frontal one. The R/S pattern from V4 to V6 is due to counterclockwise rotation observed in anterosuperior hemiblocks. By recording these leads 3 cm above the classical ones, R grow and S decrease until disappearing similarly to aVL.

aVR suggests a bifascicular block that would explain the wide, frontal and lateral S and as the PR interval is 220 ms, I could admit a trifascicular block. In brief, ECG compatible with hypertensive hypertrophic myocardial, but it could also be calcified aortic valve in a post-menopausal woman. Basal and high septal hypertrophy with basal and posterior apical fibrotic signs. There is no diastolic failure, but stress dyspnea is frequent in basal hypertrophies. Warm regards, and the discussion is open.

The only method to corroborate the ECG diagnosis is MRI.

Samuel Sclarovsky M.D. Israel

Spanish: Querido amigo Profesor Andrés Pérez Riera M.D. Ph.D.

Análisis electrocardiográfica del caso de esta mujer adulta hemibloqueo anterosuperior en presencia de una hipertrofia basal (S profundas en II, III con R altas en aVL).

Las ondas T positivas en III y negativas en aVL pueden obedecer a 2 posibilidades 1) por el hemibloqueo 2) por fibrosis basal. La falta de ondas r en I, II, III, aVF no obedece a infarto inferior sino a la hipertrofias que en personas adultas se van borrando progresivamente con hipertensión de larga data. Las ondas R muy altas en V2-V3 sugieren una hipertrofia septal alta y media. Las hipertrofias basales y septales altas vienen muy frecuentemente juntas porque pertenecen al mismo area pero se expresan en diferentes planos en anteroposterior y el frontal El patrón R/S de V4 a V6 se deben a la rotacion antihoraria que se observa en los hemibloqueos anterosuperiores Registrando estas derivaciones 3 cm por encima de las clasica las R crecen y las S disminuye hasta desaparecer similar a aVL.

aVR sugiere un bloqueo bifascicular que vendria explicar las S anchas frontales y laterales y como el intervalo PR es de 220 ms podria admitir un bloqueo trifascicular.

En resumen ECG compatible con una miocardiaca hipertensiva hipertrofica mas tambien, podria ser una valvular aórtica calcificada en una mujer post menopáusica Hipertrofia basal y septal alta con signos fibroticos basales y apicales posteriores No existe insuficiencia diastólica, pero la disnea de esfuerzo es frecuente en las hipertrofias basales Un fraternal abrazo , LA DISCUSION ESTA ABIERTA

El único método para corroborar el diagnóstico electrocardiografico es la MRI

Samuel Sclarovsky M.D. Israel

Dear Andrés my ECG analysis:

1. Sinus rhythm
2. 1<sup>st</sup> degree AV block (nodal?-infracis?)
3. Left anterior fascicular block (axis at the left in the frontal plane)
4. Prominent anterior forces (PAF) by His bundle septal fascicular block
5. Inferolateral necrosis suggestive of ischemic heart disease, proximal ADA + Cx ischemic involvement  
High risk of complete AV block!  
A big, big hug!!!

Juan Jose Sirena M.D. Santiago del Estero Argentina.

[<jjsirena@GMAIL.COM>](mailto:jjsirena@GMAIL.COM)

Estimado potro, mi impresion del ECG:

1. Ritmo sinusal
2. bloqueo AV de 1er grado(nodal ?-infracis?)
3. bloqueo division anterior izquierdo (eje a izq. en plano frontal )
4. Fuerzas anteriores prominentes (FAP) por bloqueo de la division septal del haz de His
5. necrosis inferolateral  
sugestivo de cardiopatia isquemica compromiso DA proximal +Cx  
Alto riesgo de BAVC !  
Un abrazonoonon !!!

Juan Jose Sirena [<jjsirena@GMAIL.COM>](mailto:jjsirena@GMAIL.COM)

The ECG presents sinus rhythm with LA enlargement and/or interatrial conduction disorders. The maximal PR interval that I find is around 230 ms, and by the age of the patient according to some authors is normal. The QRS complex reaches 120 ms (if you widen the image). Q wave is not observed in I with virtually QS wave in II, III and aVF, with initial blurring and axis extremely shifted at the left. I think that these findings are due to left anterior fascicular block + septal block. If there is a low degree block in the right branch, we cannot know it because these forces will be offset by the septal forces. The voltage of R waves in V2 and V3 are very enhanced and the ST-T observed cannot be justified by this conduction disorder. These two facts lead me to assume that there is a great septal hypertrophy; on the other hand the ST segment and the wave morphology seem at first, mitral valve prolapse.

Cordially,

Julia Pons M.D. Buenos Aires/Argentina.

## Spanish

El ECG presenta ritmo sinusal con agrandamiento de AI y/o trastornos de conducción intraauricular. El intervalo PR máximo que yo encuentro es de 230 mseg, que por la edad de la paciente según algunos autores es considerado como normal. El complejo QRS llega a medir 120 mseg (si uno amplía la imagen). No se observa onda Q en I con onda prácticamente QS en II, III y aVF, con empastamiento iniciales y eje desviado a extrema izquierda. Yo considero que estos hallazgos se deben a un bloqueo del fascículo anterior izquierdo + un bloqueo septal. Si existe un bloqueo de bajo grado de la rama derecha no lo vamos a saber porque estas fuerzas van a ser contrarrestadas por las fuerzas septales. El voltaje de las ondas R en V2 y V3 están muy aumentadas y el STT observado no lo puedo justificar por este trastorno de conducción. Estos dos hechos me hacen suponer que existe una gran hipertrofia septal, por otra parte el segmento ST y la morfología de la onda me impresiona en primera instancia como de prolapso de válvula mitral.

Cordialmente

Julia Pons M.D.

**Dear Andrés:**

**I will suggest a single diagnosis - free of charge -- since I am not sure you will be able to confirm or to infirm it in this old patient.**

**A left posteroseptal accessory pathway with a long conduction time.**

**If the patient has been asymptomatic during 84 years I would assume that this pathway is conducting only antegradely.**

**A simple recording of the His bundle activity may allow you to infirm or confirm my speculation.**

**For the money let us see later since I have been told that Brazil is presently facing some problems @@@@**

**Warmest regards**

**NB. We are celebrating a new month in Israel called ADAR during which our tradition asks us to be happy !!**

**So I am happy to suggest you this nice diagnosis @@@**

***Prof., Bernard Belhassen ( nickname BB) Israel***

***Director, Cardiac Electrophysiology Laboratory***

***Tel-Aviv Sourasky Medical Center***

***Tel-Aviv 64239, Israel***

***Tel/Fax: 00.972.3.697.4418***

***[bblhass@gmail.com](mailto:bblhass@gmail.com); 'Bernard Belhassen, Prof'; 'bblhass@tasmc.health.gov.il***

**Caros Andres:**

**Vou sugerir um único diagnóstico - de forma gratuita - já que eu não tenho certeza que você será capaz de confirmar ou descartar este diagnóstico nesta paciente de idade. Uma via acessória pósteroseptal com um tempo de condução muito lento.**

**Se o paciente tiver sido assintomática durante 84 anos, eu diria que esta via conduz apenas em forma anterógrada.**

**A simples gravação da atividade do hisograma intracavitário poderia permitir afirmar o negar a minha especulação diagnóstica.**

**Para o dinheiro vamos ver mais tarde desde que eu tenho dito que o Brasil está atualmente enfrentando alguns problemas @ @ @ @**

**Saudações**

**Bernard**

**NB. Estamos celebrando um novo mês em Israel chamado ADAR durante a qual a nossa tradição nos pede para ser felizes!**

**Então, eu estou feliz em sugerir-lhe este diagnóstico bom @ @ @**



**This s a peculiar ECG with left axis deviation and the "strain pattern" in the extremity leads, very high R waves in the right precordial leads, but low R waves in V5-V6. It even looks like a delta wave in the extremity leads, but the PQ interval is normal. To me the ECG is not typical for electrode displacement, cor pulmonale or septal hypertrophy. The extremity leads seem to indicate structural heart disease of the left ventricle. Lead I is not at all typical for dextrocardia. Maybe it is dextroposition of the heart (not dextrocardia) or some strange electrode displacement of the precordial leads?**

**Thank you for sending the case!**

**Kjell Nikus M.D.**

**Tampere, Finland**

Dear Andres,

I'm so grateful to you for being one of your ECG pupils. I have learned so much from you over the years. Keep learning is the only thing I and I believe everyone else wanted to gain here.

Here are my impressions:

- 1. Old inferior MI**
- 2. Complete LAFB**
- 3. Complete LSFB**
- 4. First degree LPFB+RBBB**

Thanks much and I look forward to hearing the correct answer from you!

**Zhang, Li MD**

**[ldlzhang@gmail.com](mailto:ldlzhang@gmail.com)**

Director, Cardiovascular Outcomes Research. Main Line Health Heart Center. Lankenau Hospital

Associate Professor

Lankenau Institute for Medical Research 558 MOB East 100 Lancaster Avenue Wynnewood, PA 19096 U.S.A.

**Ritmo sinusal, BDAS, AEI inferior, SVE e, o mais importante: CABOS INVERTIDOS no plano horizontal!!!!!!**

**O V1 esta como V6, o V2 como V5, o V3 como V2. O que esta marcado como V1 seria o V4, o que esta marcado como V2 é o V5 e o que esta como V3 é, na verdade, o V1.**

**Este disturbio de condução intraventricular se deve apenas ao SVE.  
Elisabeth Kaiser M.D. São Paulo Brazil.**

---

***English: Sinus rhythm, LAFB, inferior MI, LVH, and the more important feature: inversion of electrodes on horizontal plane!!!!***

***V1 is V6***

***V2 os V5***

***Or***

***V3 is V2***

***This intraventricular conduction disturbance is consequence of only a LVH.***

***Elisabeth Kaiser M.D. São Paulo Brazil.***

## Portuguese

**ECG com padrões de área inativa latero-dorsal e inferior (consequência do Infarto do miocárdio prévio), além de BDAS.**

**Att.**

**Dr. Severiano Atanes Netto M.D. Brazil**

**ECG with pattern of myocardial infarction inferior lateral dorsal (consequence of previous MI) and Left Anterior Fascicular Block(LAFB)**

---

**Prezado Andrés e queridos colegas. ECG Trata-se de ritmo sinusal ,com FC 70 bpm,com area inativa inferior , provavelmente 2aria a IAM ANT . INFERIOR,COM BIRD,com BDASE,com BAV 1 Grau,PR=0,28SEG, com significante SVE ,  $V3 + aVL > 56\text{mm}$ (indice Cornel),Hipertrofia VE ,provavelmente com componente septal e finalmente ,alt dif da rep ventricular.**

**Podera estar associado a paciente com síndrome coronariana aguda ,que se infartar a regio antero-septal leva a alta incidencia de letalidade.**

**Abraço a todos.**

**falaremos.**

**Lourival de Campos MD São Paulo Brazil.**

---

**Dear Andrés and dear colleagues:**

- 1. Sinus rhythm**
- 2. Heart rate 70 bpm**
- 3. First degree AV block: PR interval 280 ms.**
- 4. Incomplete Right Bundle Branch Block**
- 5. Left Anterior Fascicular Block**
- 6. Inferior MI**
- 7. Severe LVH with septal component: positive Cornell index(  $V3+ aVL > 56\text{ mm}$ ), diffuse alterations of repolarization,**

Spanish

Uff.

Ritmo regular sinusal bloqueo av primer grado(PR220 ms), eje a izquierda bloqueo del fasciculo anterior de la rama izq., necrosis de cara inferior, sobregarga ventricular derecha, , hipertrofia o dilatacion ventricular izq.(I y aVL).

*Gracias*

Atentamente y saludos

**Claudio Santibáñez Catalan**

Sinus rhythm, first -degree AV block(PR 220 ms), QRS axis with extreme shift to left: LAFB, Inferior myocardial infarction, right ventricular enlargement/hypertrophy (RVH), and left ventricular enlargement/hypertrophy or dilatation (I and aVL).

**Final Commentaries by Andrés Ricardo Pérez-Riera M.D.Ph.D.**

In this interesting discussion five thinking currents were established, attempting to explain the atypical electrocardiographic alterations of the elderly lady with history of infarction:

Dr. Samuel Sclarovsky from Israel, and Dr Elisabet Kaiser thinks that this prominent anterior forces (PAF) are due to **a mere high and medium LV septal hypertrophy phenomenon**; however, later the great master indicated that it could be a bi or even a trifascicular block. Additionally, Dr Julia Ponds from Buenos Aires think that PAF are consequence of a **great septal hypertrophy**;

A second hypothesis supports that this is a typical case of the so-called standard masquerading bundle branch block; i.e. CRBBB + LAFB in which a significant degree of LSFB associated to LVH/LVE and ventricular wall fibrosis may conceal the final S of I and aVL, resembling CLBBB in the limb leads and in the precordial leads, it would clearly be RBBB by the prominent anterior forces and the final S in the left leads V5-V6.



A third and apparently “wild” hypothesis supports that this would be a ventricular pre-excitation of the WPW type with anomalous parallel bundle of posteroseptal location and of extremely slow and anterograde conduction.

This anomalous pathway of right posterior location would be responsible for the QRS prominent anterior forces (PAF) and of extremely slow and anterograde conduction.

This anomalous Kent pathway of septal posterior location would be responsible for the prominent anterior forces in V2-V3.

This hypothesis is supported by the hint of a delta wave in some leads besides the secondary repolarization alterations.

The justification of short PR interval absence and even its prolongation could be due to extremely slow anterograde conduction by the Kent bundle.

Against this line of thinking, we argue: if the anomalous pathway is conducting anterogradely in an extremely slow way, why the conduction by the normal intraventricular conduction system does not manifest?

Dr Nikus from Finland, and Dr Kaiser speculated dextroposition or a mistake in precordial electrodes.

Finally, the hypothesis that we support consists of the presence of electrically inactive area in the inferior wall, associated to LAFB, which would justify the counterclockwise QRS loop rotation and the extreme QRS axis shift in the FP toward the left superior quadrant (LSFB + inferior infarction). The upward rotation of the initial 30 ms, with upper convexity and with dashes very close to each other would be explained by the slow conduction within the necrotic area.(See VCG in nexts slides) Additionally, in the HP, the “in crescendo” prominent anterior forces from V1 to V2 and decreasing in V5-V6, as well as the absence of q in V6 and small q in V2-V3 indicate the initial exit of the forces to the back and from the right to the left by the non-blocked posterior-inferior fascicle. With the antero-superior or antero-medial fascicle blocked, the stimulus of the initial moments follows the activation of the only non-blocked branch: the posterior-inferior fascicle that is heading backward and from right to left.

In brief,

Left atrial enlargement and/or intraatrial conduction disorder;

Doubtful borderline PR interval prolongation;

LAFB;

LSFB?

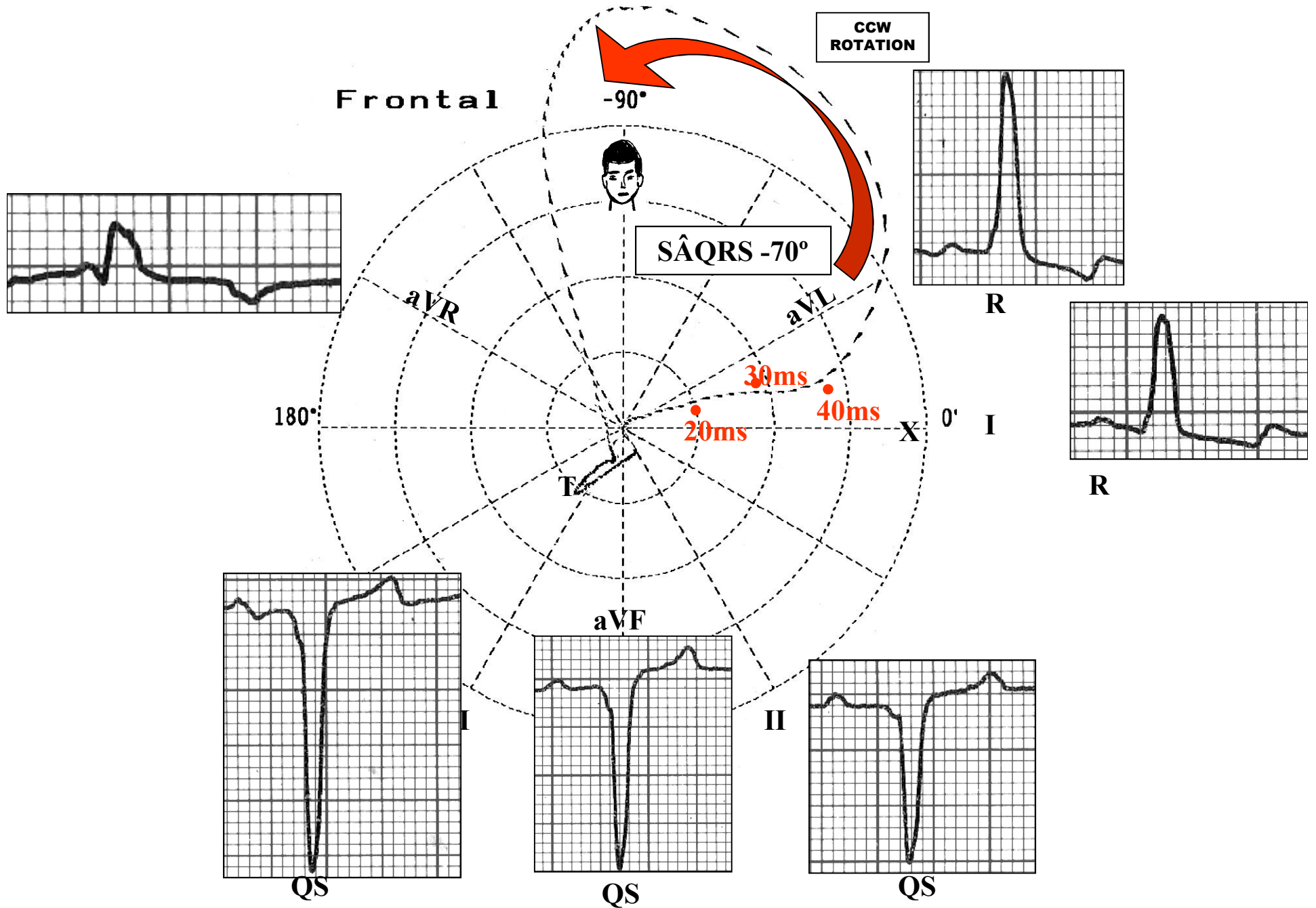
Left bifascicular block?

**Inferolateral Myocardial Infarction:** inferior MI with extension to lateral wall, because QS in inferior leads and PAF in V2-V3(new nomenclature on cardiac walls of Professor Bayes)

Possible anterior fibrosis.

Let see in next slides ludically this hypothesis.....

# ECG/VCG correlation on Frontal Plane



## 1. First question:

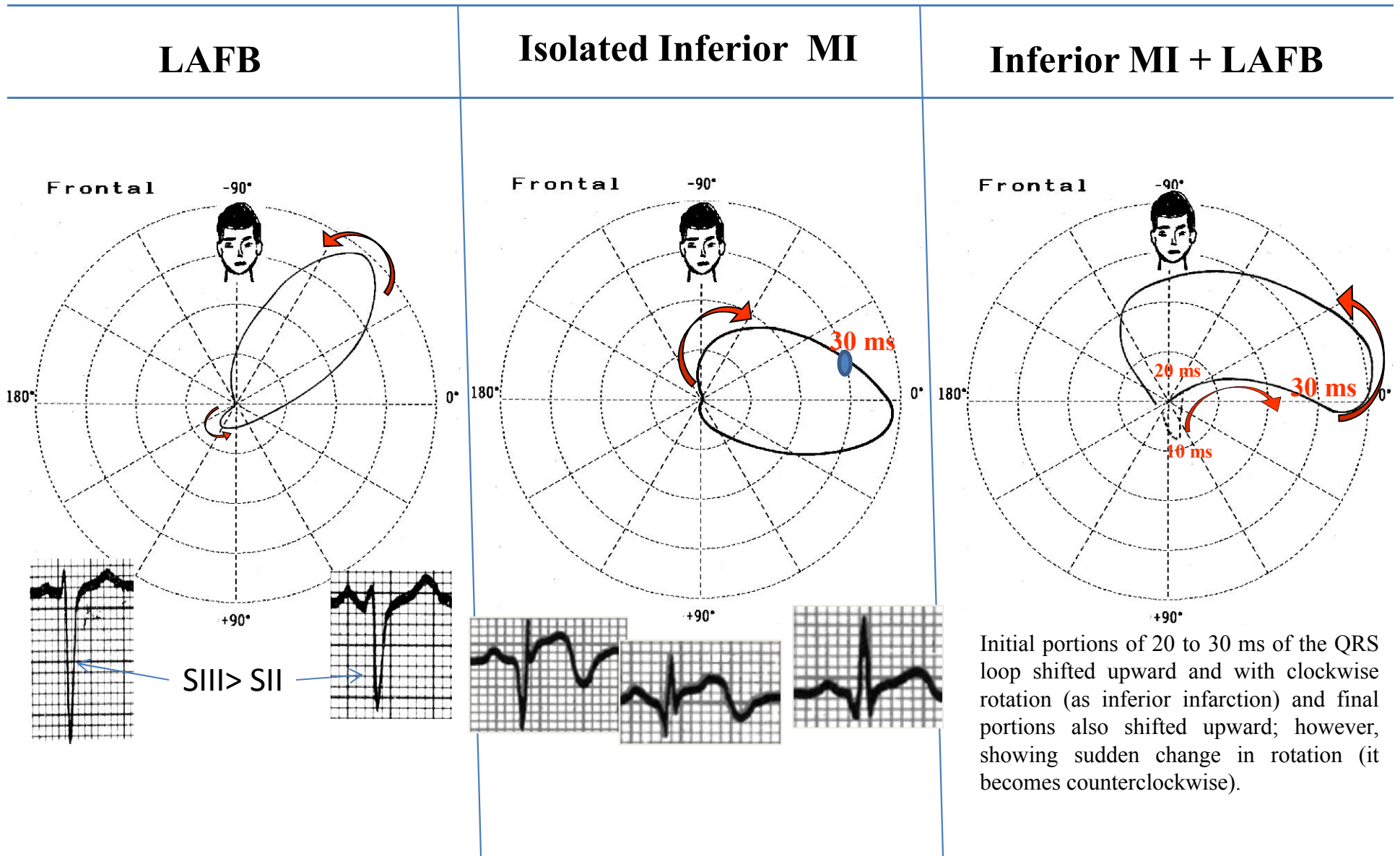
**Hypothesis A:** Is this ECG/VCG correlation pattern in frontal plane compatible with left anterior fascicular block (LAFB) associated with inferior myocardial infarction?

Or

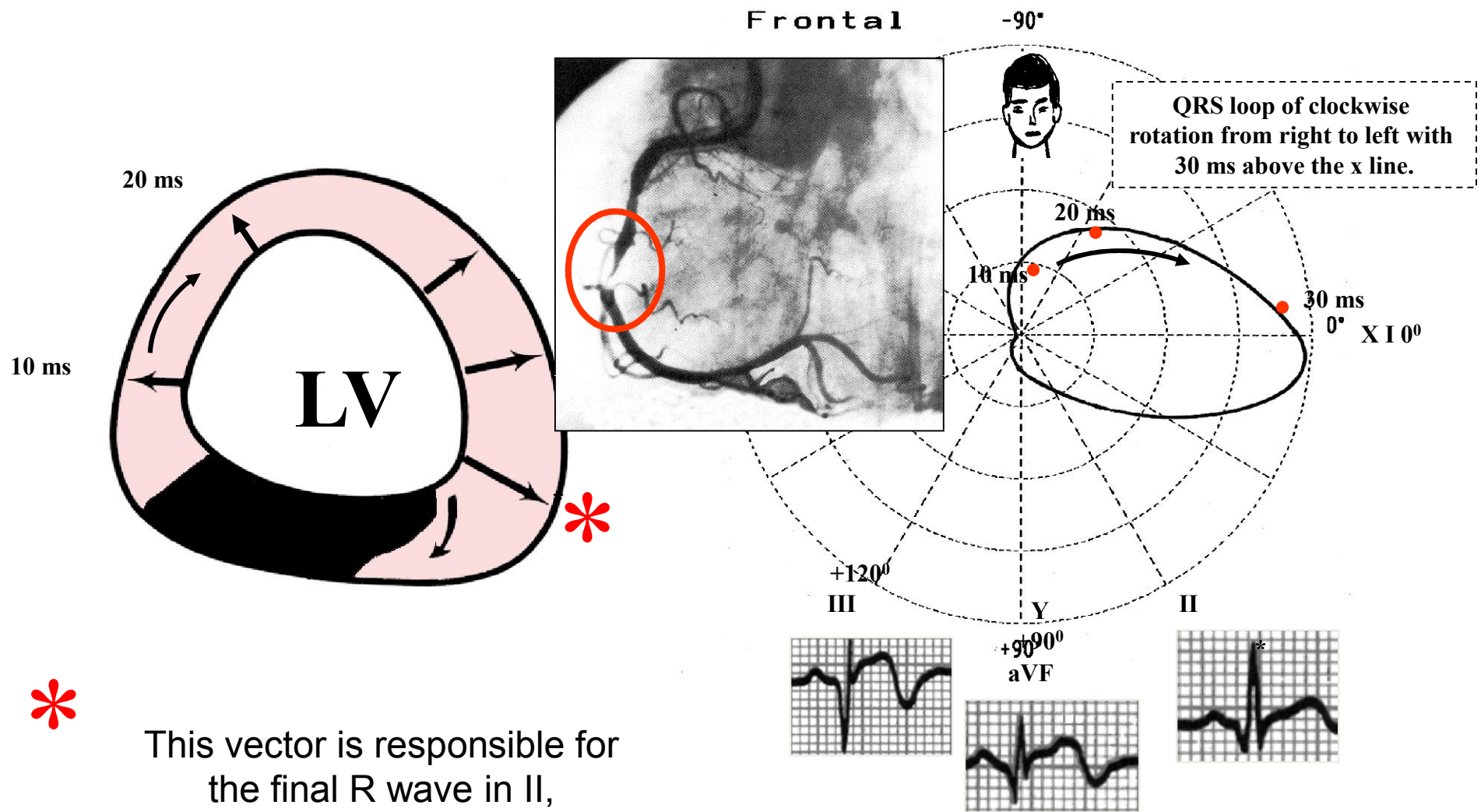
**Hypothesis B:** Is this ECG/VCG correlation pattern compatible with pre-excitation Wolff-Parkinson White Syndrome with posteroseptal pathway resembling LAFB+ inferior MI?

## Hypothesis A Explanation

Comparative frontal plane QRS VCG loops in case of left anterior fascicular block (LAFB), inferior MI and the association of both



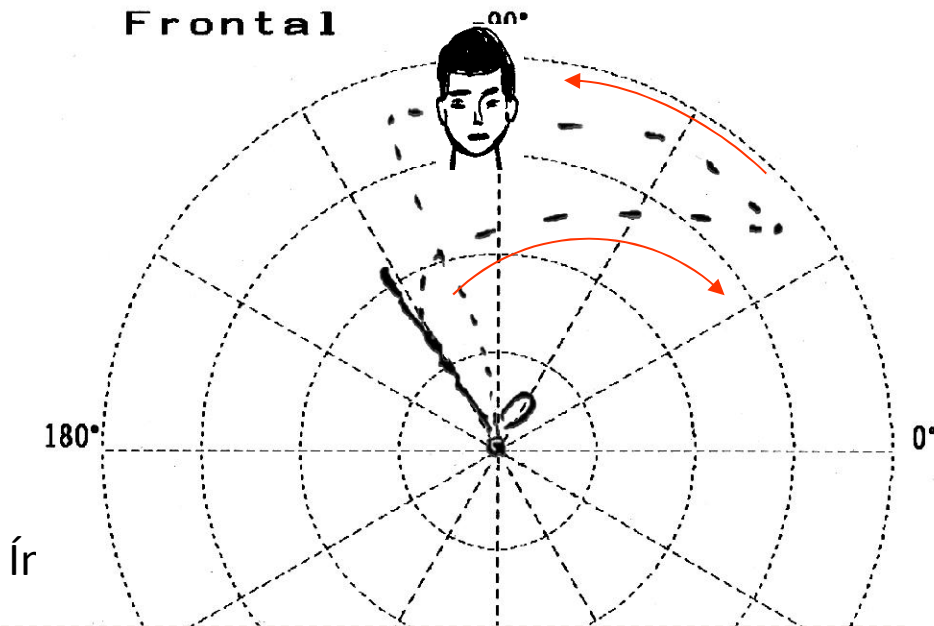
# Inferior Myocardial Infarction



This vector is responsible for the final R wave in II, since the left part of the inferior wall was not affected.

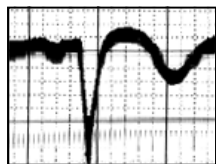
# Inferolateral Myocardial Infarction

Frontal



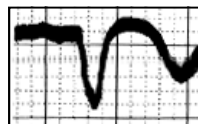
Inferior infarction is extensive, and it compromises the whole inferior wall, thus explaining the absence of final r or R wave in II, III and VF.

DIII

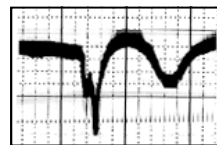


+90°

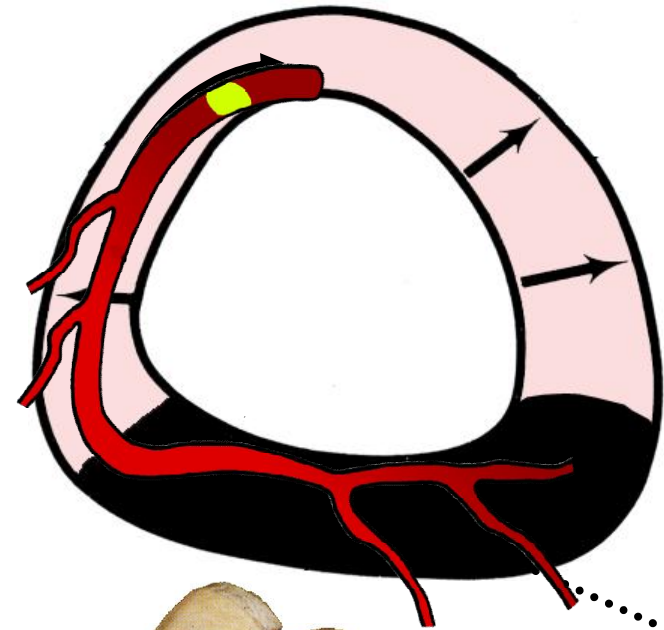
Y



DII

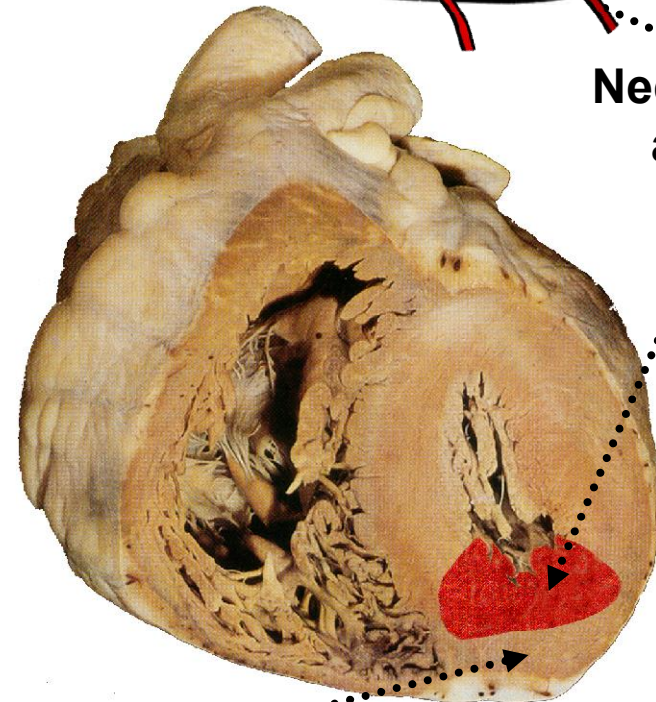


QS in the three inferior leads



X DI 0°

Necrosis area



Apical region



## **New ECG terminology for Q-wave MI based on the correlation with CE-CMR**

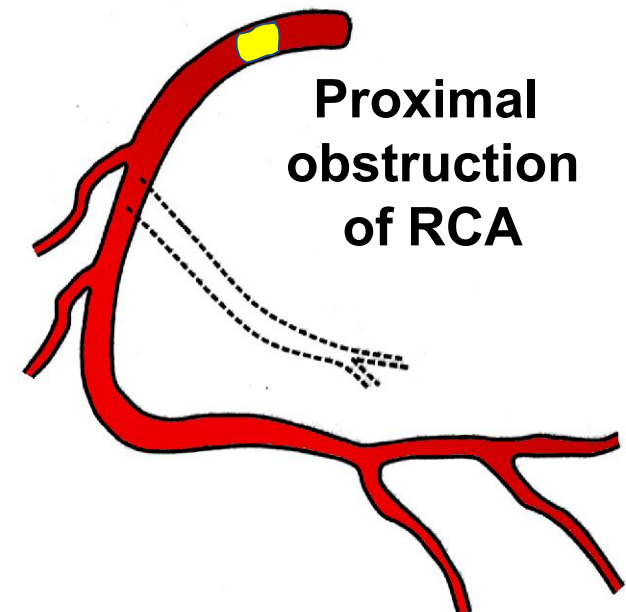
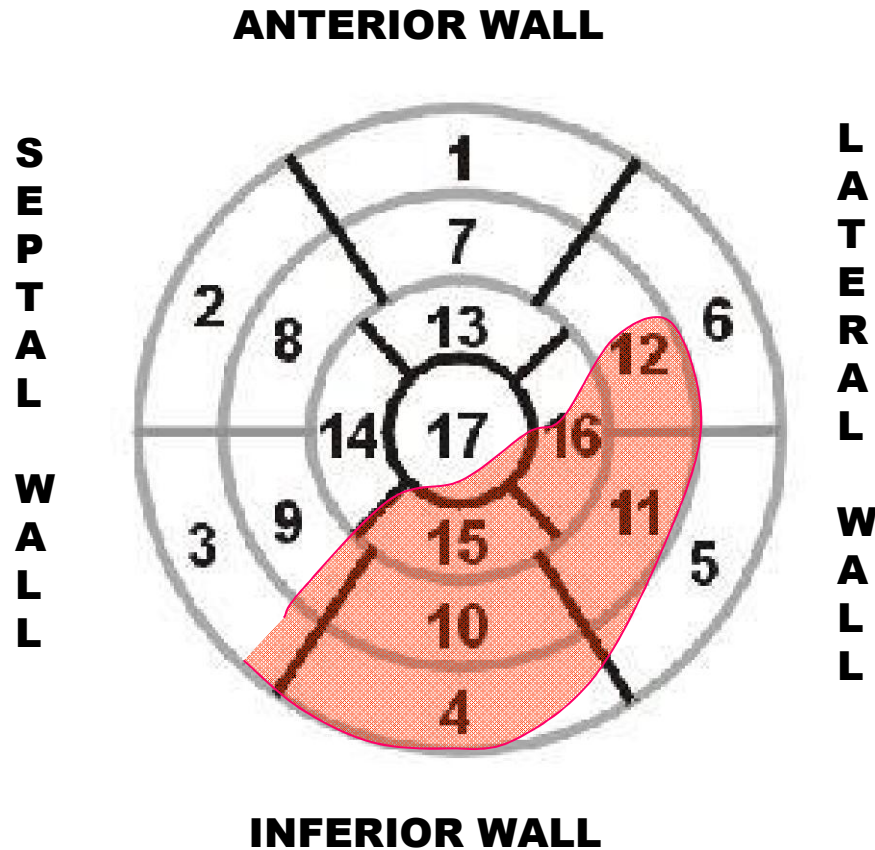
### **2) Inferolateral Zone**

- **Inferolateral**
- **Type: B-3**
- **Most likely site of occlusion: RCA or dominant LCx**
- **ECG pattern: signs of inferior (QS in II, III, aVF: B2) and/or lateral infarction (RS in V<sub>1</sub>).**
- **Segments compromised by infarction in CE-CMR: image in the next slide.**
- **Sensitivity: 73%.**
- **Specificity: 98%.**

- 1) Bayés de Luna A, et al. *Am J Cardiol.* 2006;97:443-451.
- 2) Bayés de Luna A, et al. *Circulation* 2006; 114:1755-1760.
- 3) Bayés de Luna A, et al. *J Electrocardiol.* 2006; 39 (4 Suppl):S79-81.
- 4) Bayés de Luna A, et al. *J Electrocardiol.* 2007;40:69-71.
- 5) Bayés de Luna A, et al. *Ann Noninvasive Electrocardiol.* 2007; 12:1-4.
- 6) Bayés de Luna A, et al. *Cardiology Journal* 2007;14 : 417-419.
- 7) Cino JM, et al. *J Cardiovasc Magn Reson.* 2006;8:335-44.
- 8) Pons-Lladó G, et al. *J Cardiovasc Magn Reson.* 2006;8:325-6.

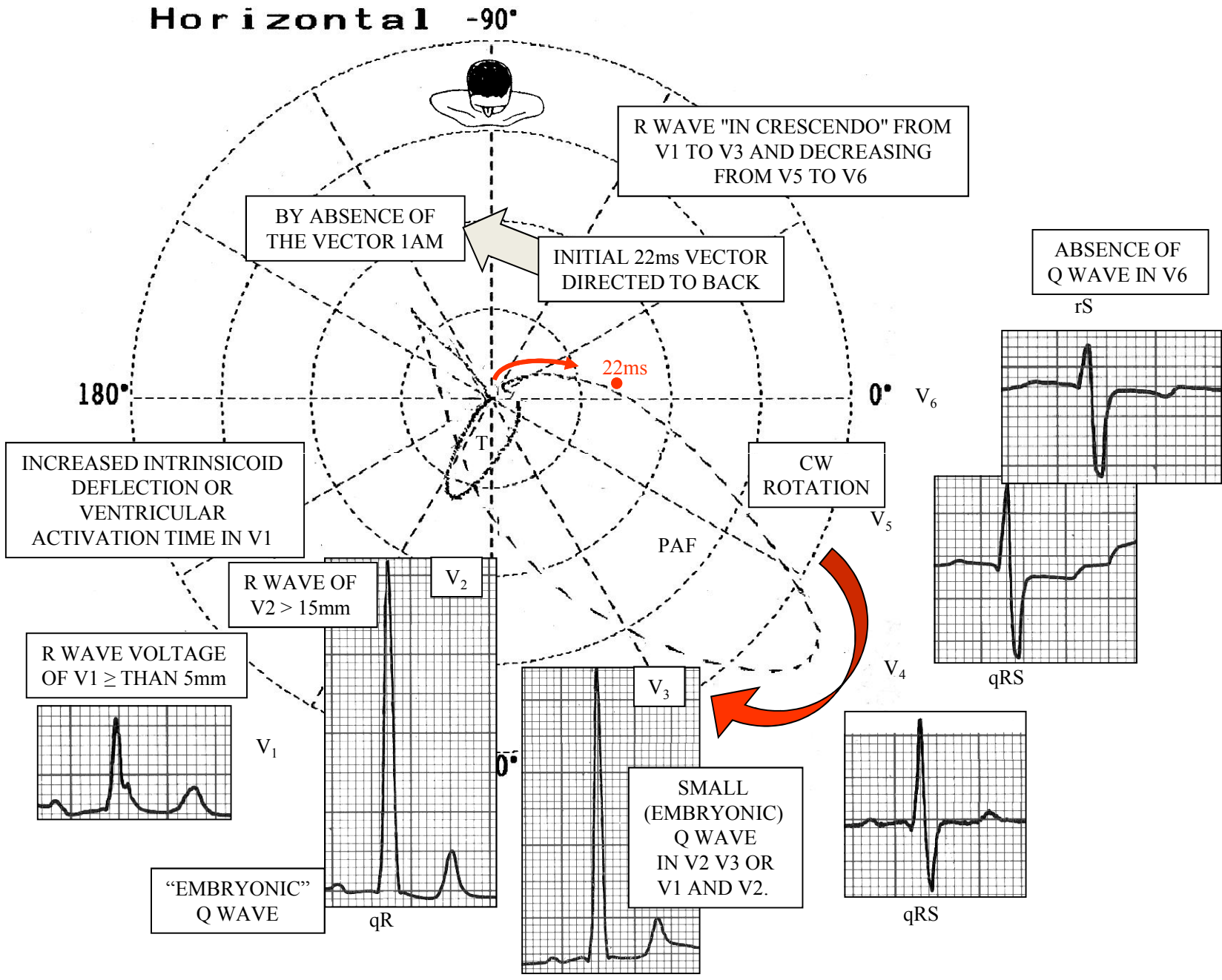
# LATERAL INFARCTION

## B-3



**ECG pattern:** signs of inferior (Q in II, III, VF: B2) and/or lateral infarction (RS in V1). PAF in V2-V3

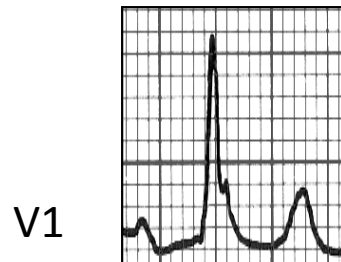
# ECG/VCG Horizontal Plane Correlation



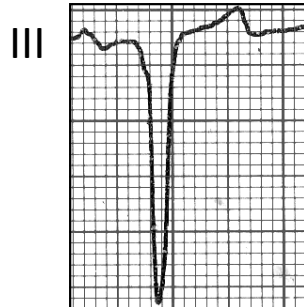**Hypothesis B Is this ECG/VCG correlation pattern compatible with pre-excitation Wolff-Parkinson White Syndrome with right posteroseptal pathway resembling LAFB+ inferior MI?**

**d'ÁVILA'S algorithm to locate accessory pathway on the basis of QRS complex polarity**

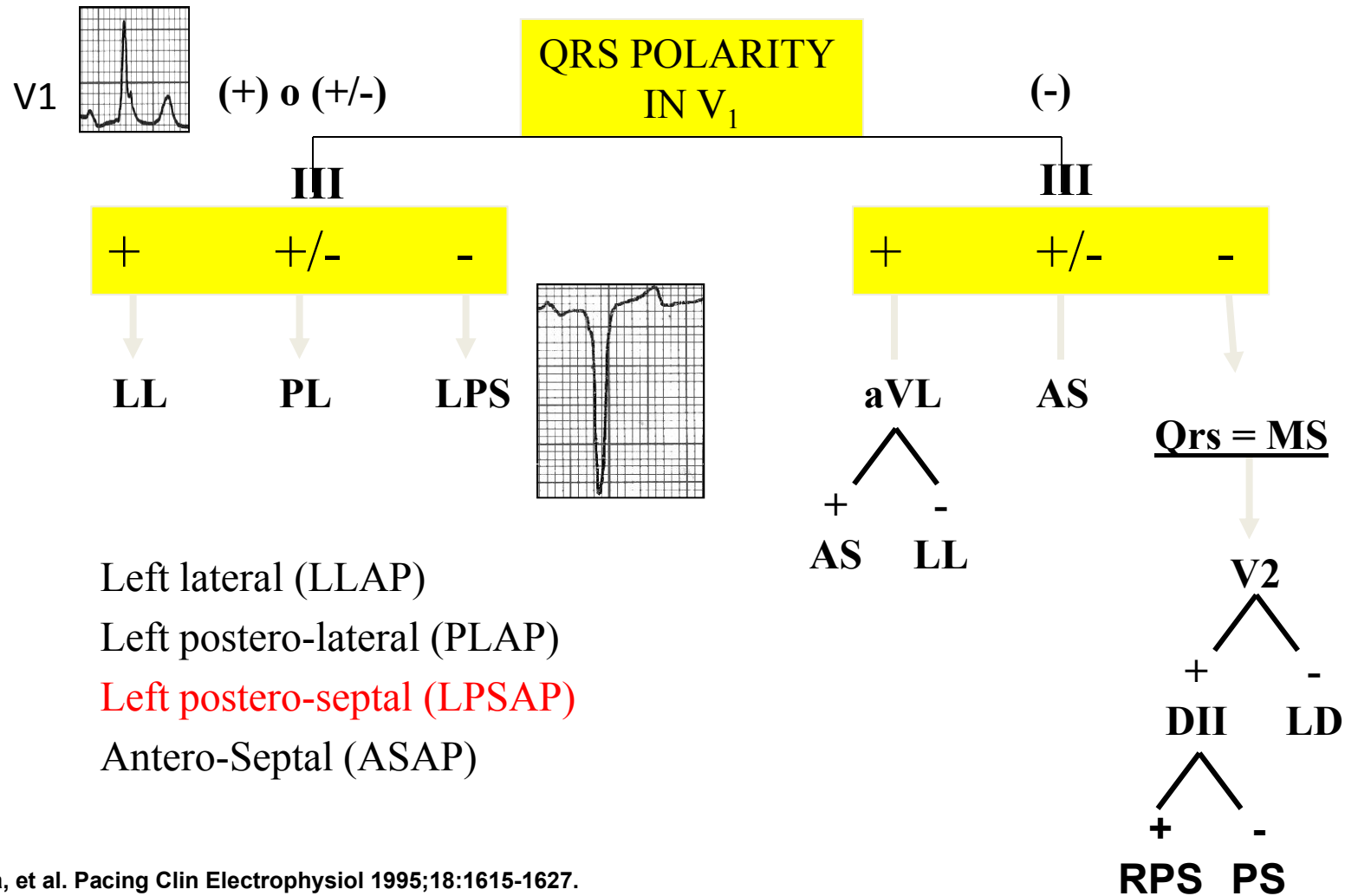
- 1. 1° STEP:** to define QRS complex polarity in V1. Two possibilities: positive or plus-minus or negative;



- 2° STEP:** in case of being positive or plus-minus in V1, the III lead should be checked next. If it is positive, this is a left lateral accessory pathway (LLAP). If it is isodiphasic plus-minus, this is a left postero-lateral pathway (PLAP). Finally, if III is negative, the AP will be **left postero-septal (LPSAP)**.

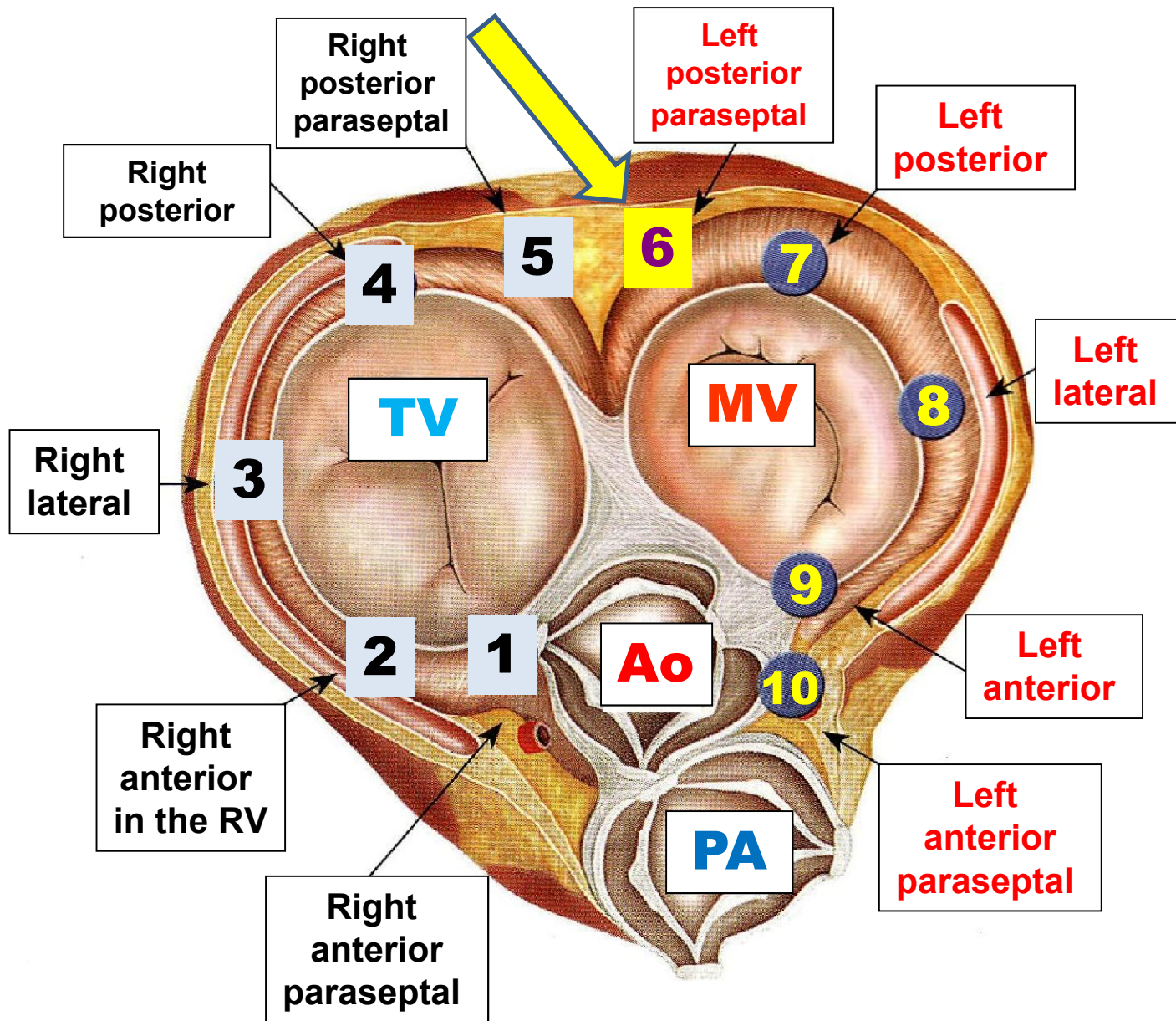
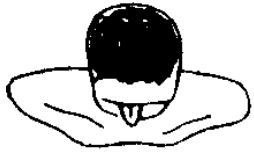

# d'ÁVILA'S algorithm to locate accessory pathway on the basis of QRS complex polarity



d'Ávila, et al. Pacing Clin Electrophysiol 1995;18:1615-1627.

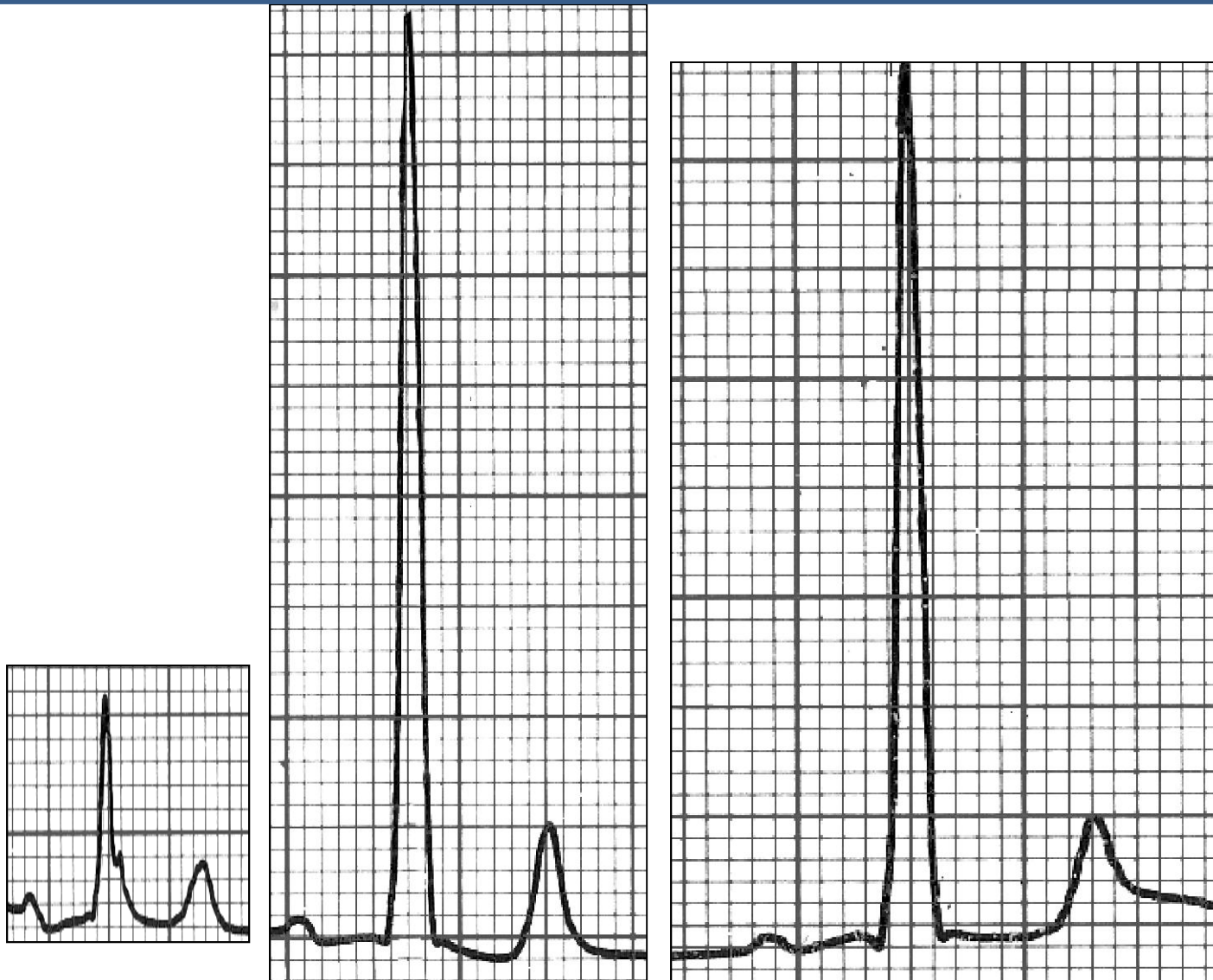Algorithm by d'Ávila to locate QRS-complex polarity in V5.



TV = Tricúspid valve; MV = Mitral valve; PA = Pulmonary artery; Ao = Aorta

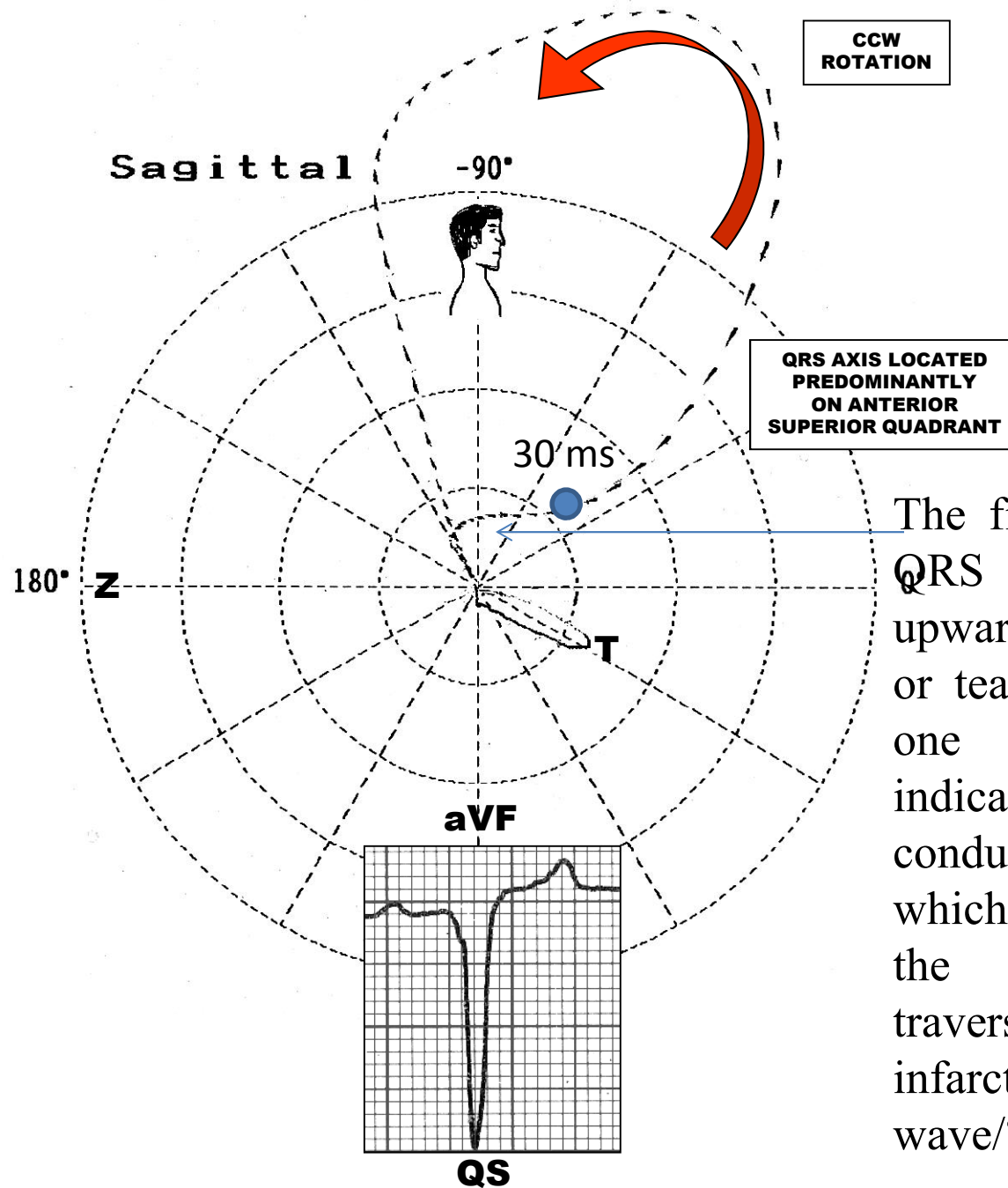
Possible locations of anomalous pathways in WPW

# Right Precordial Leads Pattern from V1 to V3



**This pattern definitely has nothing to do with a right bundle branch block**

# ECG/VCG RIGHT SAGITTAL PLANE CORRELATION



The first 30 ms of the QRS loop are directed upwards and its comets or tears are very next one to another indicating slow conduction in this area which may mean that the stimulus is traversing an area with infarction or it is a delta wave/?/?



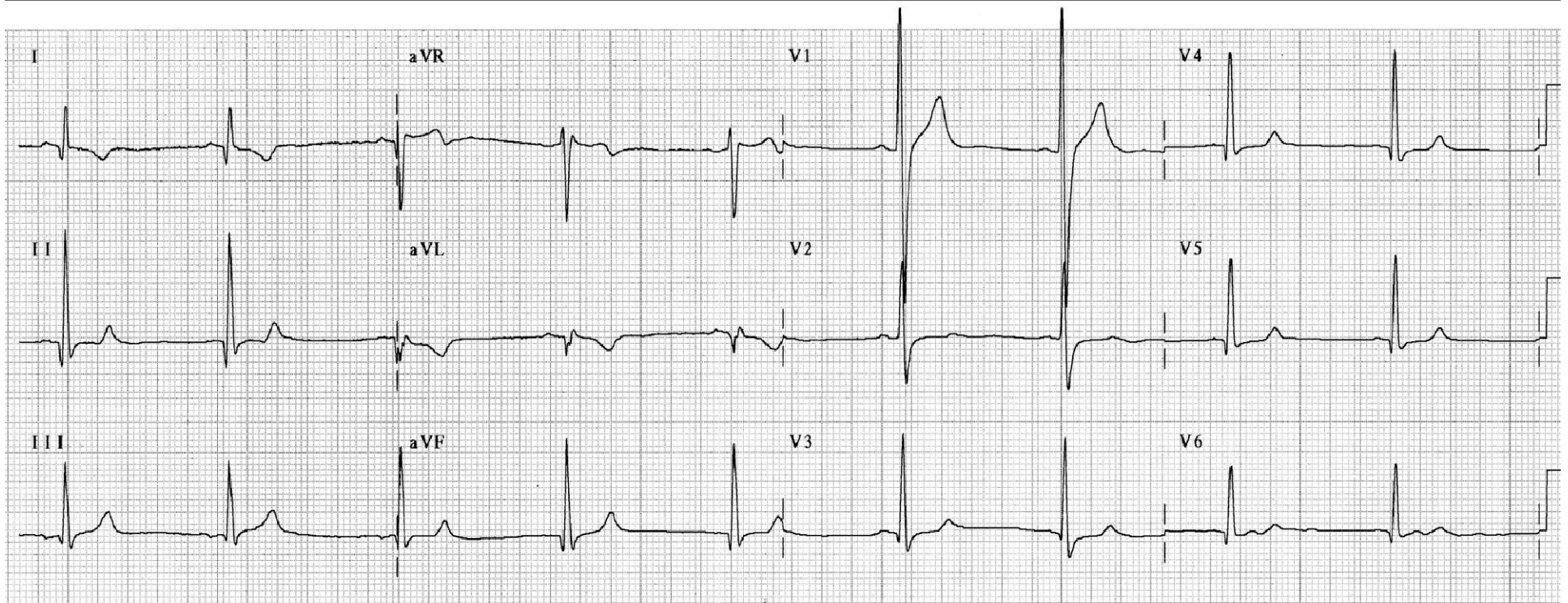
# POSSIBLE CAUSES OF PROMINENT ANTERIOR QRS FORCES (PAF)

- 1) Normal variant: counterclockwise rotation in the longitudinal axis.
- 2) Athlete Heart
- 3) **Electrocardiographic Precordial Electrode Misplacement**
- 4) Right Ventricular Enlargement (RVE)/ Right Ventricular Hypertrophy (RVH) types A and B Vectorcardiographic.
- 5) Left Ventricular Enlargement (LVE) or Left Ventricular Hypertrophy (LVH) of the diastolic or volumetric type.
- 6) **Lateral MI** . Dorsal MI not exist!!!!!!!!!!!!!!!!!!!!!!!!!!!!!!
- 7) Complete or incomplete Right Bundle Branch Block.
- 8) **Wolff-Parkinson-White with anomalous pathway of posterior location: Type A**
- 9) Hypertrophic cardiomyopathy: obstructive and non-obstructive forms.

- 10) Duchenne-Erb disease, pseudo hypertrophic muscular dystrophy linked to sex or infantile malignant (DMD).
- 11) Endomyocardial fibrosis (EMF)
- 12) Left Septal Fascicular Block (LSFB).
- 13) **Dextroposition of the heart pseudo dextrocardia**
- 14) **Associations of the previous ones:** E.g.: RVE + CRBBB.

**Dextroposition or pseudo dextrocardia  
Nikus hypothesis.**

Name: NS .; Sex: Male.; Age: 33 y.o. ; Ethnic group: White.; Weight: 77Kg.; Height: 1.72 m.;  
Biotype: Normoline.; Date: 03/30/2004.; Medication in use: nothing stated.



**Clinical diagnosis:** heart in dextroposition. Chest with discrete bulging of the right hemithorax. Normal noises in intensity; nevertheless, auscultated in the right hemithorax. Dextroposition should not be confused with **true dextrocardia** or with **dextroversion or pseudo-dextrocardia** (only the tip rotates to the right, with chambers and viscera in a normal position). Dextrocardia and dextroversion are characterized by reverse or mirror image in limb leads. In precordial leads in dextrocardia, QRS complexes are negative from V1 to V6 and in dextroversion broad R wave is observed in all precordial leads. Dextroposition, extrinsic or secondary dextrocardia: the heart is shifted to the right by external factors. E.g.: agenesis of the right lung. This is a problem with little relevance.

1. Cihalik C. Evaluation of the ECG recording in abnormal positions of the heart in the thorax. *Vnitr Lek.* 2002;48:90-94.

## DEXTROPOSITION OR PSEUDO-DEXTROCARDIA

### ECG CRITERIA

- 1) Possible negative P waves or minus-plus in I
- 2) Deep Q waves in I and aVL: QR complexes
- 3) qR or qRs type complexes from  $V_1$  to  $V_6$
- 4) Proeminent Anterior Forces (PAF)

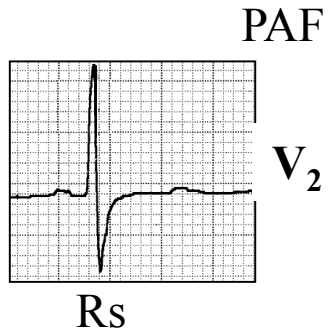
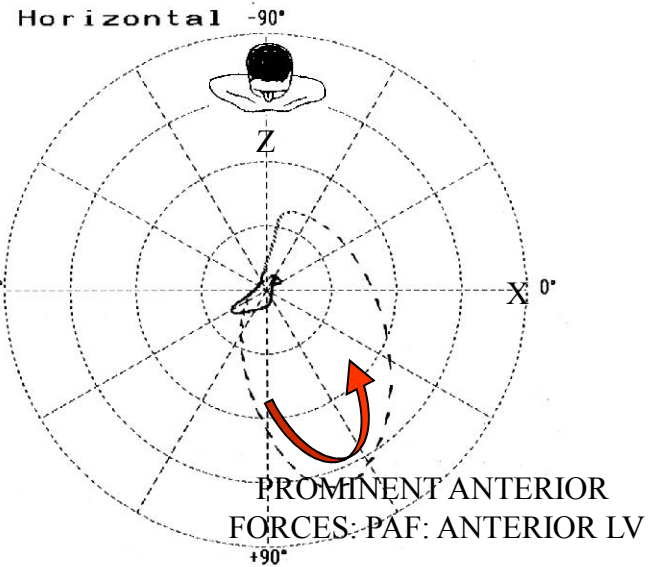
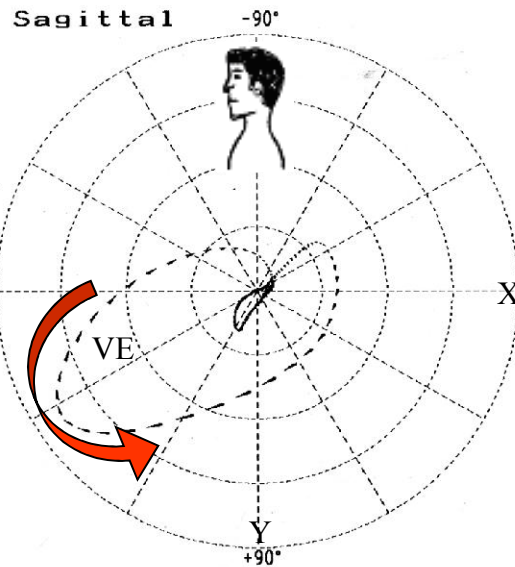
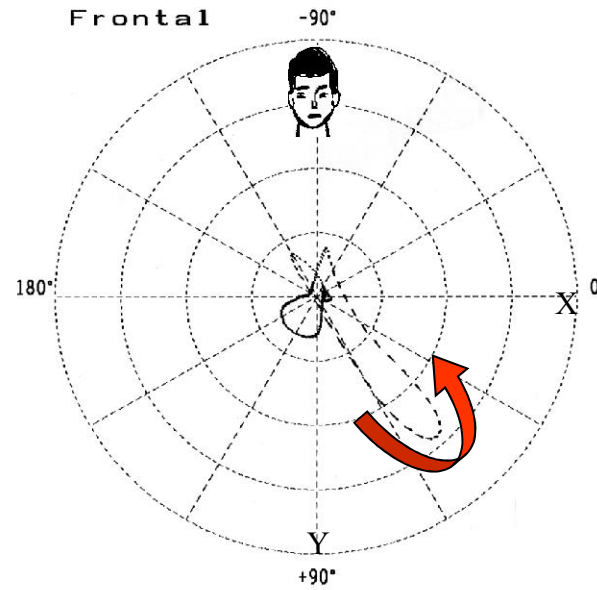
### VCG CRITERIA

1. Initial 10 ms vector heading backward and to the right
2. Narrow QRS loop and with counterclockwise rotation in the horizontal plane
3. Prominent Anterior Forces (PAF).

Electrocardiographic and Vectorcardiographic criteria of dextroposition.

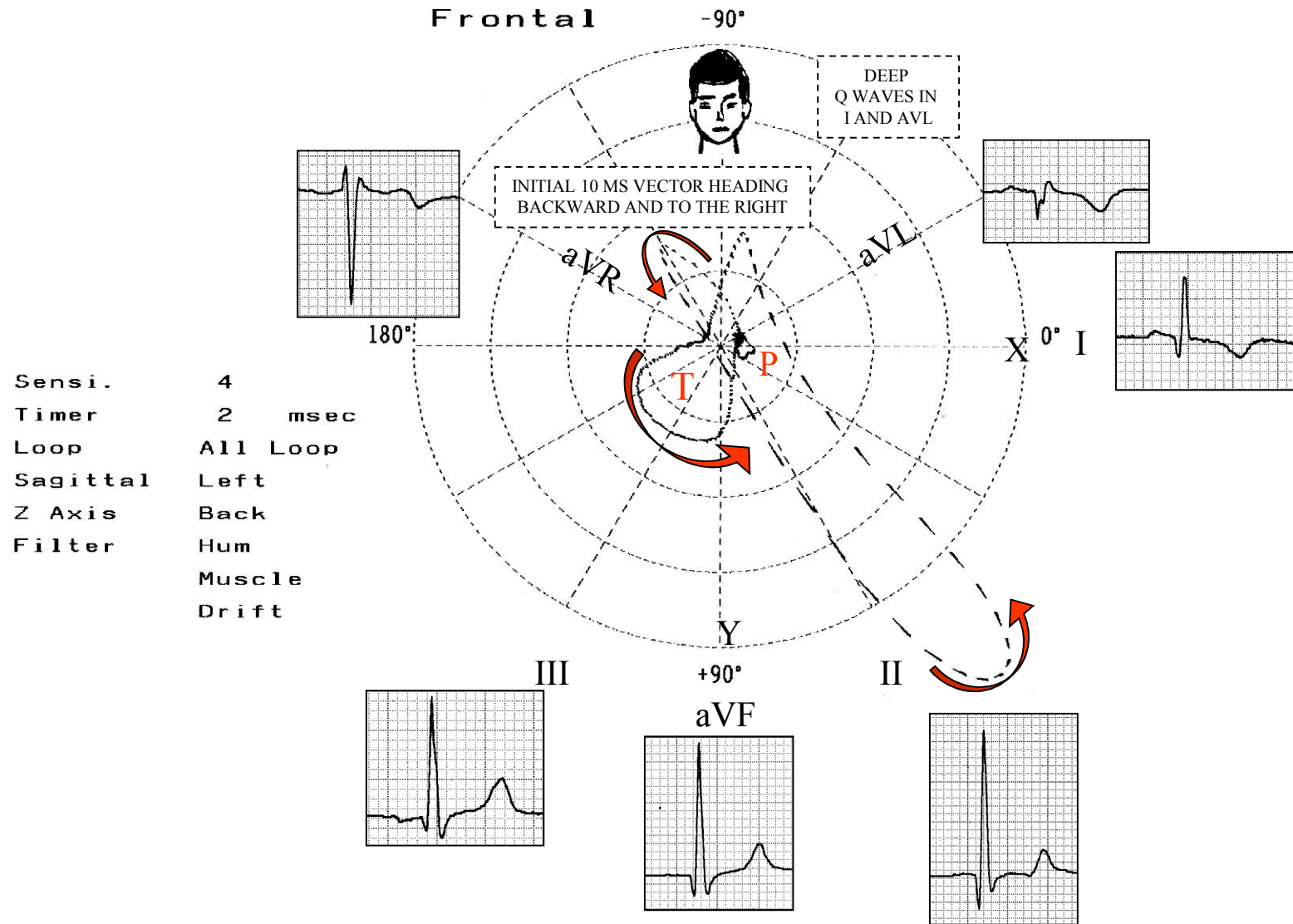
# VECTOCARDIOGRAM

**Sensi.** 2  
**Timer** 2 msec  
**Loop** All Loop  
**Sagittal** Left  
**Z Axis** Back  
**Filter** Hum  
**Muscle**  
**Drift**



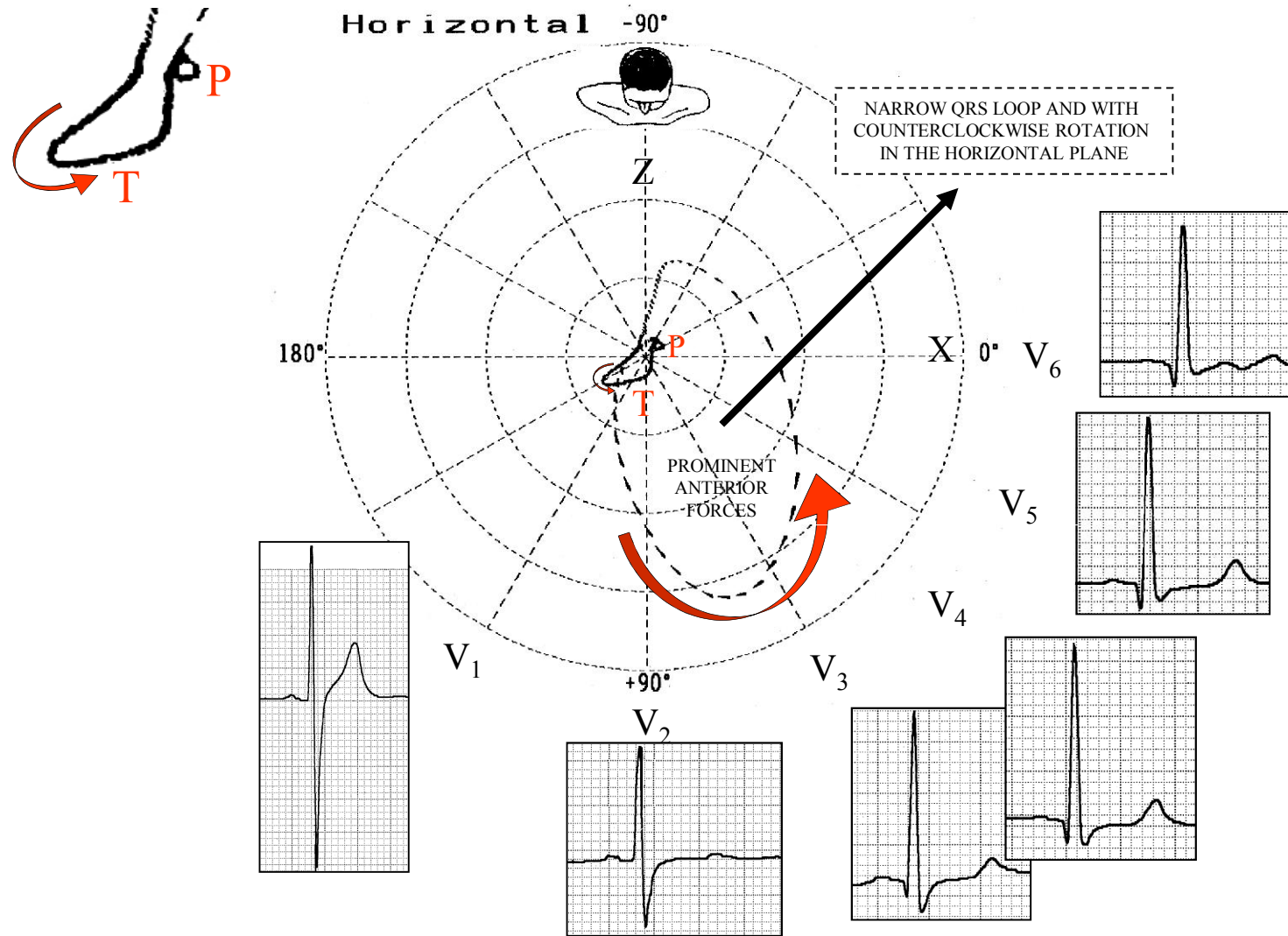
Vectocardiogram of the same case of dextroposition.

# ECG/VCG CORRELATION FRONTAL PLANE



ECG/VCG correlation in the frontal plane in dextroposition or pseudo-dextrocardia.

# ECG/VCG CORRELATION HORIZONTAL PLANE



qR or qRs type QRS complexes from  $V_3$  to  $V_6$

ECG/VCG correlation in the horizontal plane in dextroposition.