

Ventricular arrhythmia post-concealed myocarditis

Arritmia ventricular pós-miocardite oculta



Raimundo Barbosa-Barros, MD

Chief of Coronary Center of the Messejana Hospital Dr. Carlos Alberto Studart Gomes, Fortaleza, Ceará, Brazil.

English: Case report

Male, 67 y/o, Caucasian, hypertensive, with history of long-standing ventricular arrhythmia (20 years).

Family background irrelevant. Negative Chagas disease serology.

He described that it all started more or less 20 years ago, in a trip to São Paulo. On the occasion, after being exposed to cold weather, he presented symptoms of flu with palpitations after some days. He requested help from the *Beneficência Portuguesa* hospital where he was asked to do periodical consultations with a cardiologist. For a while he just presented a single symptom, i.e. intense night sweating. The symptom disappeared during evolution. Currently asymptomatic and taking ramipril 5 mg daily, carvedilol 25 mg 2x/day, spironolactone 25 mg daily.

Physical examination: unremarkable.

We also performed VCG, Holter monitoring, transthoracic echocardiography(September 2017), CMRI (September 2017), and coronary angiography with ventriculography(September 2016).

Questions:

1. Which is the ECG and VCG diagnosis?
2. What is the appropriate approach?

Português: Relato de caso

Homem, 67anos, raça branca, hipertenso, com história de arritmia ventricular de longa data (20 anos) .

História familiar negativa

Sorologia para Chagas negativo

Informa que tudo começou há mais ou menos 20 anos após uma viagem para São Paulo. Nesta ocasião após exposição ao frio apresentou quadro gripal com palpitações após alguns dias. Procurou o hospital Beneficência Portuguesa onde foi orientado a realizar consultas periódicas com cardiologista. Durante algum tem po só apresentava 1 sintoma que consistia de sudorese noturna intensa. Tal quadro desapareceu ao longo da evolução. Atualmente assintomático em uso de ramipril 5 mg/dia, carvedilol 25 mg 2x/dia, spironolactona 25 mg/dia.

Exame físico: NDN.

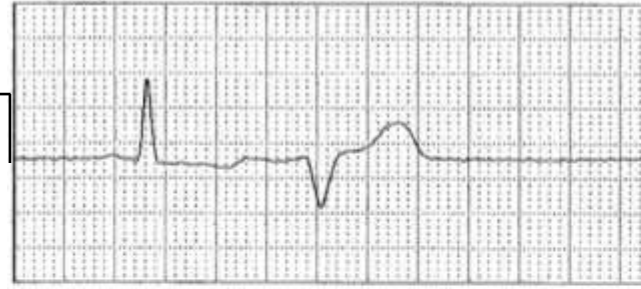
Realizamos VCG, Holter 24h, Eco transtorácico, ressonância nuclear magnética cardíaca e coronário angiografia com ventriculografia.

Perguntas:

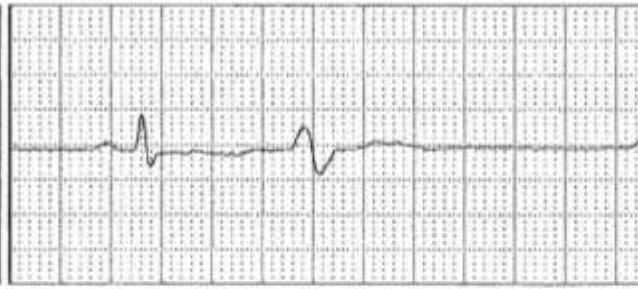1. Qual o diagnóstico ECG e VCG?
2. Qual a abordagem adequada?

12-lead ECG

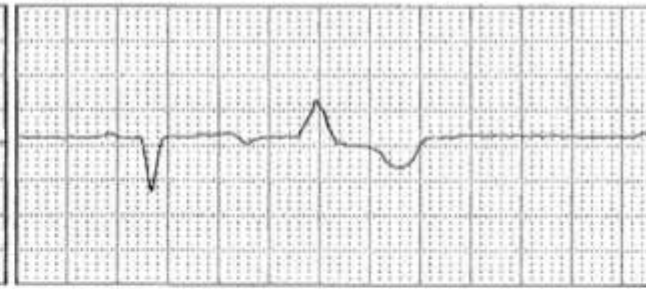
D1 N



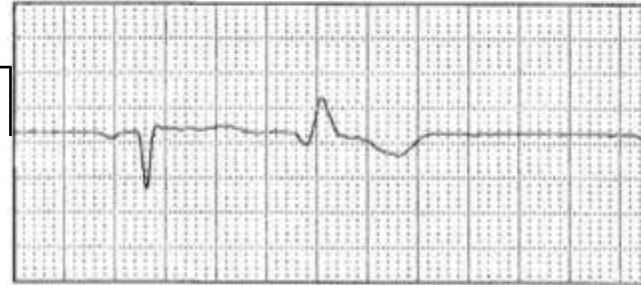
D2 N



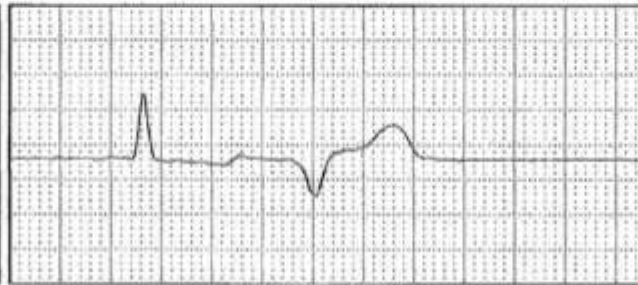D3 N



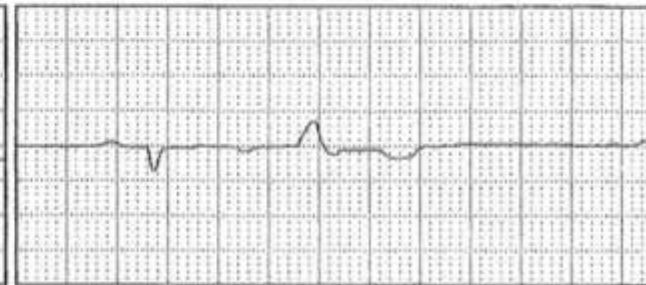aVR N



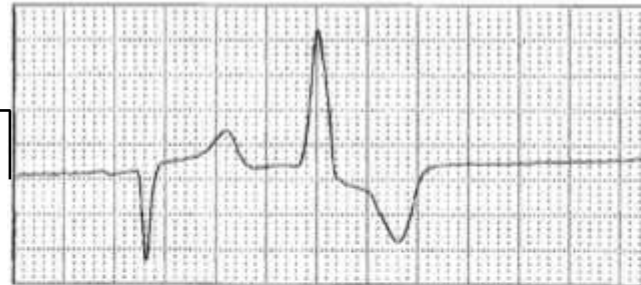aVL N



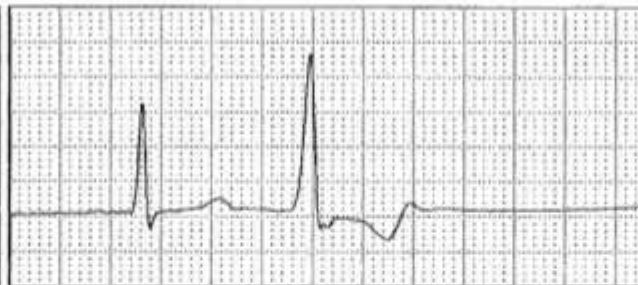aVF N



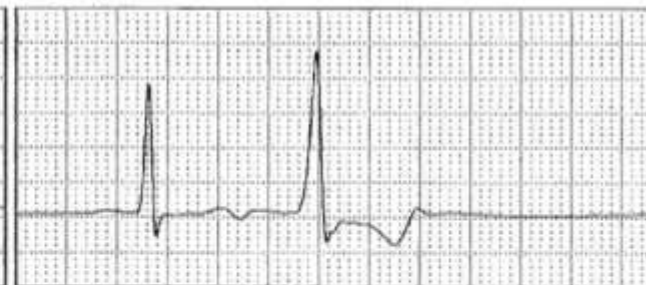V1 N



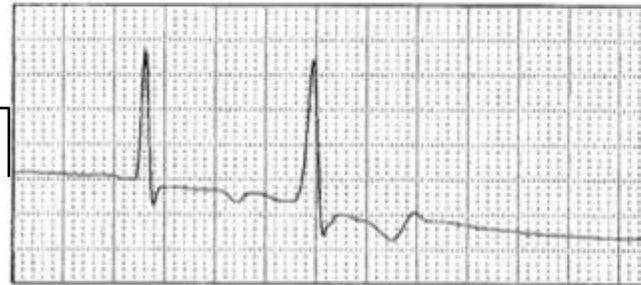V2 N



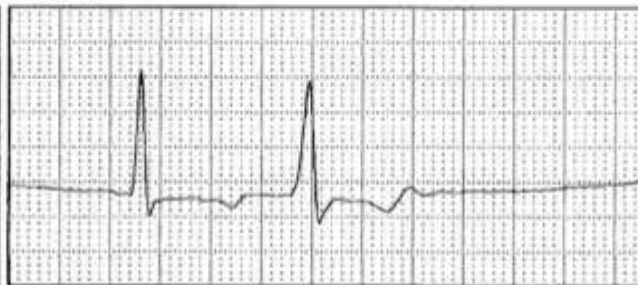V3 N



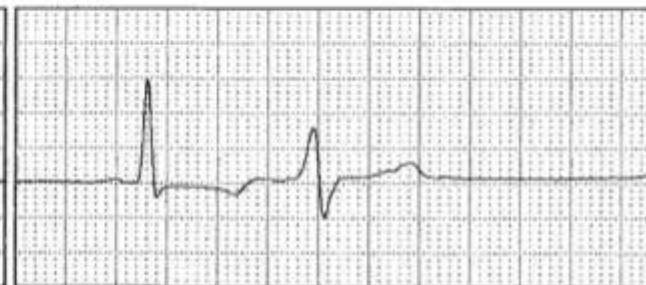V4 N



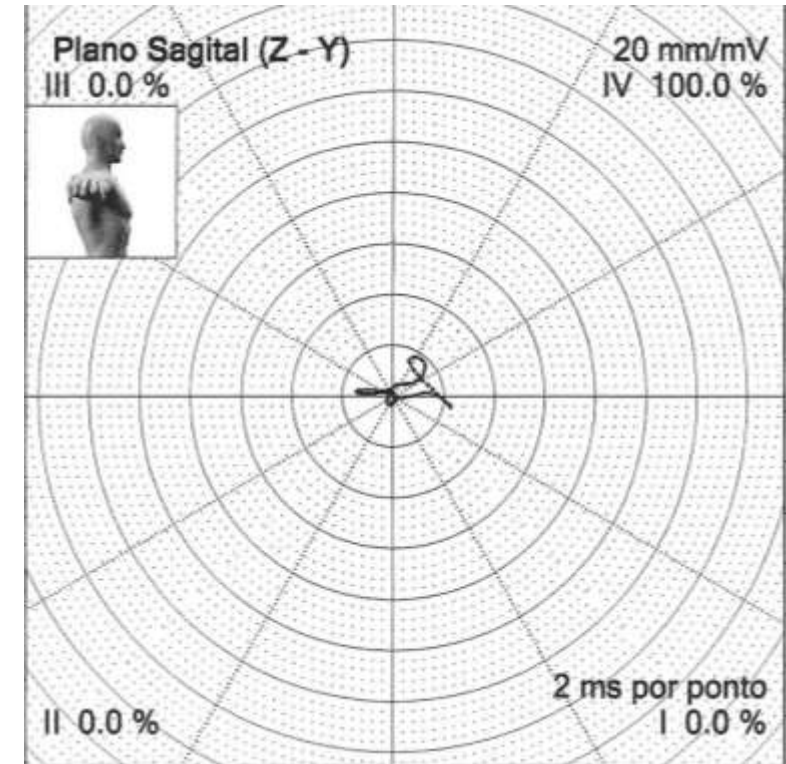
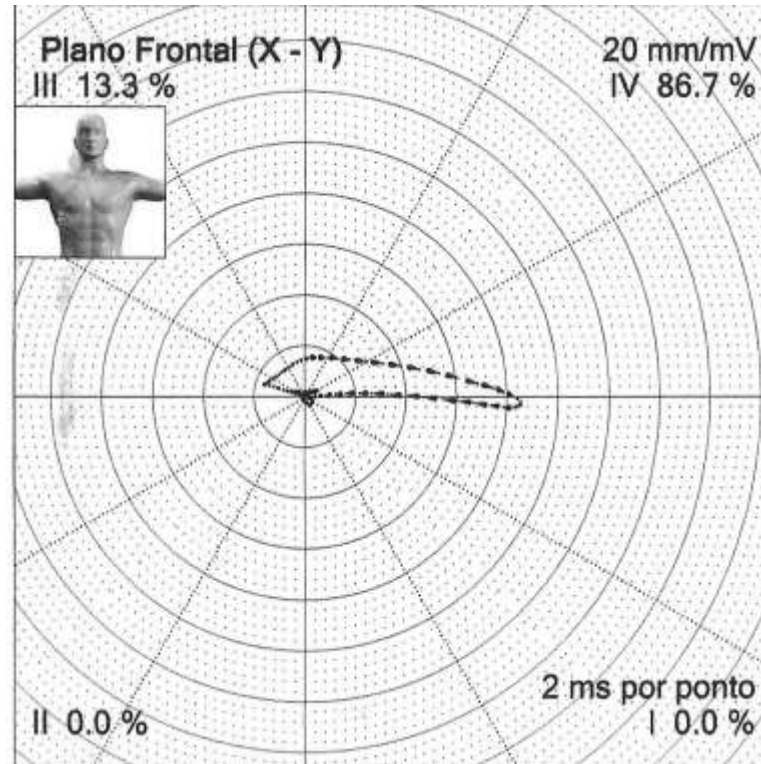
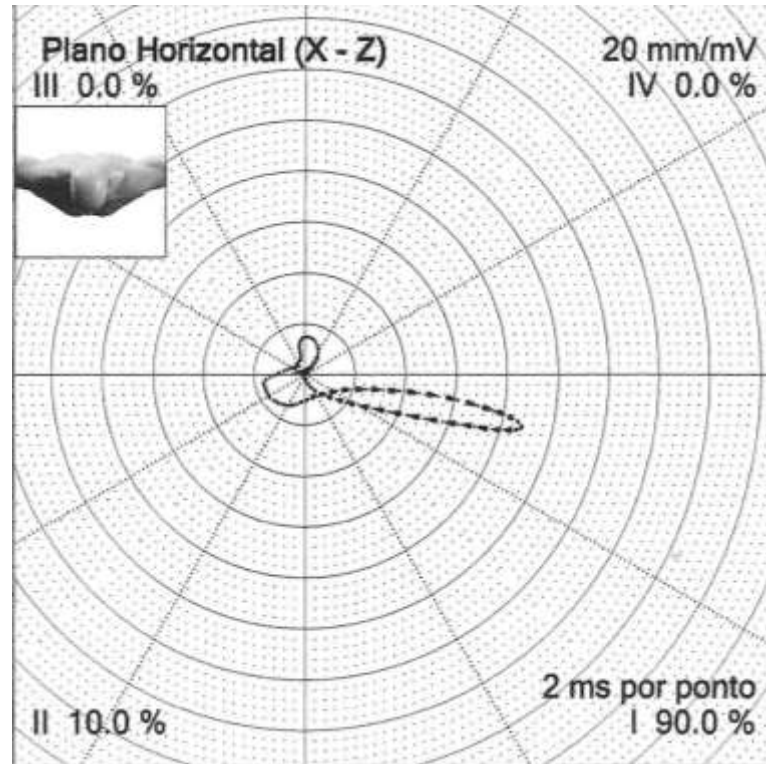
V5 N



V6 N



Vectorcardiogram in the three planes



Holter monitoring analysis

Statistical summary

Totals:

Duration (h): 23:23
Total N° of QRSs: 90,548
Ventricular ectopic beats: 7,930 (9%)
Supraventricular ectopic beats: 1,111 (1%)
Artifacts (%): <1

Ventricular arrhythmias:

7,899 isolated, from which
33 in 11 episodes of bigeminy
14 episodes in couples
1 tachycardia
Largest: 3 beats; 113 bpm at 22:47:28
Fastest: 3 beats; 113 bpm at 22:47:28
Slowest: 3 beats; 113 bpm at 22:47:28

Supraventricular arrhythmias:

1,074 isolated
10 coupled
4 tachycardias
Largest: 6 beats, 102 bpm at 00:25:48
Fastest: 4 beats, 126 bpm at 17:49:12
Slowest: 3 beats; 96 bpm at 03:54:12

Heart rate:

Min: 50 bpm at 05:02:15
Mean: 65 bpm
Max: 111 bpm at 00:25:58
HR ≥ 120 bpm not shown
HR ≤ 50 bpm not shown

Pauses

0 pauses (≥ 2.0 sec)

ST depression

C1: 0 episodes
C2: 0 episodes
C3: 0 episodes

ST elevation

C1: 0 episodes
C2: 0 episodes
C3: 0 episodes

Transthoracic 2D Echo Color Doppler analysis

Pericardium with normal appearance, no effusion.
2nd degree LV diastolic dysfunction with increased LA pressure.
Test easily obtained technically.
Color Doppler echo showed:
Mild increase in LV, LA and ascending aorta, the rest of the chambers with normal size.
Preserved global and LV segmental contractility.
Normal LV and RV systolic function (EF by Simpson 56%).
2nd degree LV diastolic dysfunction with increased LA pressure.

Measurement		Normal values
RV diameter	22	
Septal diastolic thickness	10	6-10 mm
LV diastolic diameter	61	35-36 mm
LV systolic diameter	42	
LV posterior wall diastolic thickness	10	6-10 mm
Aortic diameter	39	20-37 mm
LA diameter	39	19-40 mm
LV ejection fraction	56	52.0-75.0
% of contractility	30	>26%
Circumferential fiber shortening velocity	-	>0.9 cir/s
Mitral valve-septum distance	0	<10 mm

Cardiac Magnetic Resonance Imaging Analysis:

Situs solitus and levocardia.

Venoatrial, atrioventricular connections and ventriculoarterial concordance.

Whole interatrial and interventricular septa.

Discrete dilatation of the left ventricle (LVEDV = 93 ml/m2; LVESV = 40 ml/m2; LVEDD = 5.9 cm; LVESD = 4.9 cm).

The rest of the cardiac chambers with preserved dimensions (LVEDV = 59 ml/m2; LVESD = 19 ml/m2).

Preserved global and segmental biventricular function (RVEF = 68%; LVEF = 56%).

Properly visualized pericardium in the sequences Double IR T1 with no signs of irregularities or thickening.

Absence of myocardial hypersignal at Triple IR T2.

Absence of signs suggesting tapering or fibrofatty infiltration in the right ventricle.

Absence of dyskinetic areas or desynchrony in the right ventricle.

Presence of late gadolinium enhancement in the mesocardium, basal and inferoseptal segment, compatible with fibrosis.

No intracavitary thrombi were observed.

Lumen diameters of the aorta:

-Aortic root: 3.4 x 3.5 cm;

-Ascending aorta: 3.4 x 3.4 cm;

-Descending thoracic aorta: 2.7 x 2.8 cm.

Diagnostic hypothesis:

Discrete dilatation in the left ventricle.

The rest of the cardiac chambers with preserved dimensions.

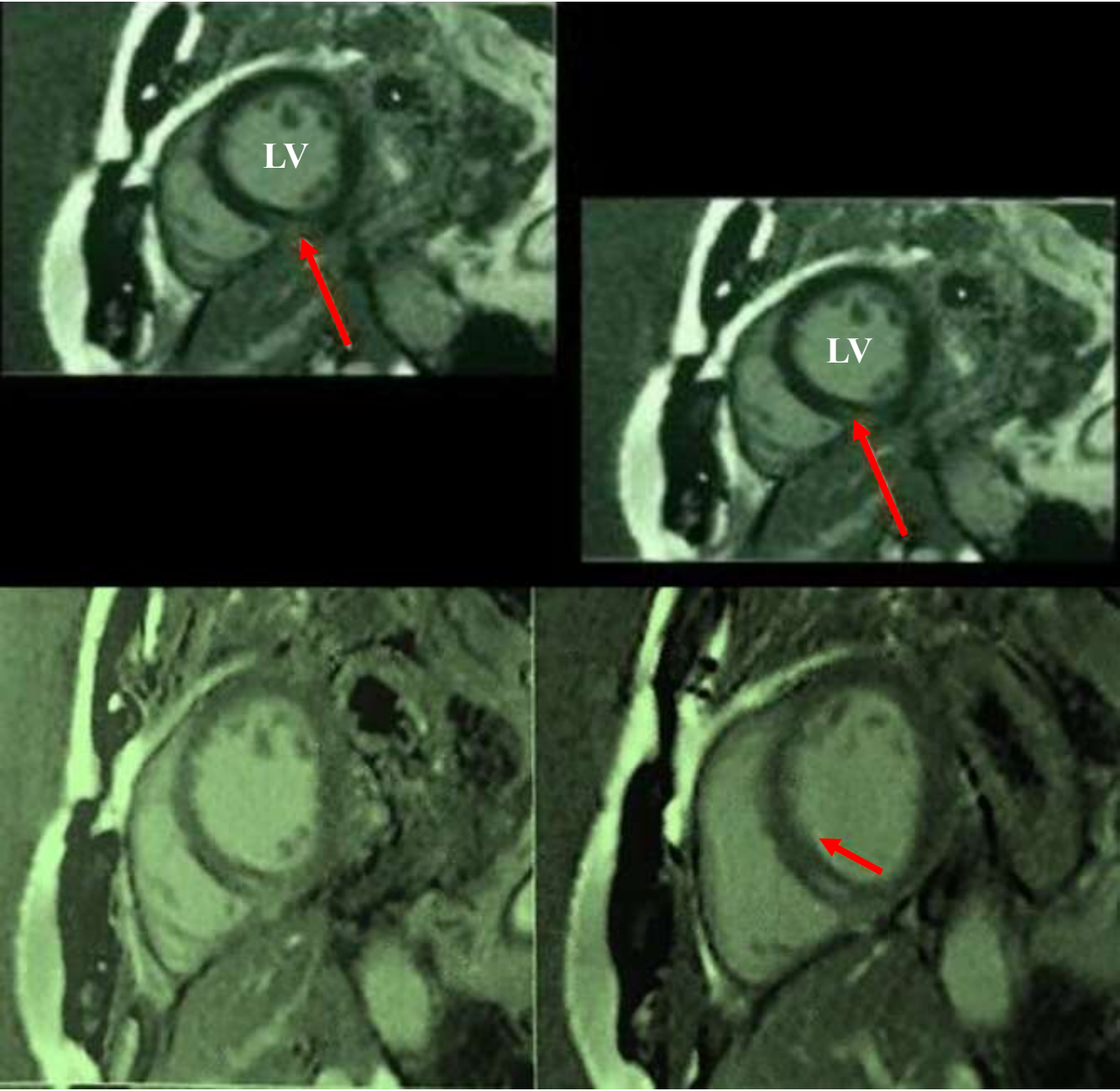
Preserved global and segmental biventricular function (RVEF = 68%; LVEF = 56%).

Absence of myocardial edema.

Presence of inferobasal, inferoseptal and mesocardial fibrotic area, compatible with the diagnosis of inflammatory cardiomyopathy (myocarditis sequelae?)

Cardiac Magnetic Resonance Imaging

Myocardial fibrosis (arrows)



CMRI analysis		
Left ventricle		
Septum	0.9	(0.7 – 1.2 cm)
Lateral Wall	0.8	(0.7 – 1.2 cm)
EDD	5.9	(3.7 – 5.3 cm)
ESD	4.9	(cm)
EDV	181	(ml)
ESV	79	(ml)
Ejection fraction	56	(50 – 70%)
Right ventricle		
RV major axis	6.6	(6.5 – 9.5 cm)
RV minor axis	4.0	(2.2 – 4.4 cm)
EDV	115	(ml)
ESV	37	(ml)
Ejection fraction	68	(40 – 60%)
Aorta to lung		
Aortic root	3.5	(2.0 – 3.5 cm)
Ascending aorta	3.4	(2.0 – 3.5 cm)
Descending aorta	2.8	(cm)
Pulmonary trunk	2.7	(cm)
Others		
Left atrium	-	(1.9 – 4.0 cm)

Colleagues opinions

Spanish

Estimado Andrés: ECG basal muestra um ritmo sinusal con QS en III y aVF, resalto de R de V1 a V2 y trastornos de la repolarización (onda T negativa asimétrica en derivaciones de los miembros y de V3 a V6) probablemente consecuencia de su miocarditis pasada.

En cara inferior hay una cicatriz, lo que confirma la RNM con la presencia de fibrosis.

Las extrasístoles ventriculares presentan imagen de BRD con eje a la derecha, lo que sugiere que son originadas de la base del VI (inferiores).

Además presenta una fracción de eyección del ventrículo izquierdo limítrofe (56%) lo que me sugiere no ser por secuela de su miocardiopatía sino por taquicardiomiopatía asociada.

Creo que respondería bien a la ablación del foco extra sistólico, previo a la decisión de indicación de CDI ya que la encuentro relacionada con el fibrosis miocárdica.

Un cordial saludo

Martín Ibarrola

English

Dear Andrés: Baseline ECG shows a sinus rhythm with QS in III and aVF, R relief from V1 -V2 and repolarization disturbance (asymmetric negative T wave in limb leads and from V3 to V6 probably due to its past myocarditis .

In the inferior wall there is a scar, which confirms the MRI with the presence of fibrosis.

Ventricular premature contractions(PVCs) present a RBBB pattern with right QRS axis, suggesting that they originate from the base of the LV (inferior). In addition, he has a left ventricular ejection fraction border line (56%), which suggests that it is not due to the sequelae of myocardiopathy but to associated tachycardiomyopathy.

I think it would respond well with ablation of the PVC focus, prior to the decision to indicate ICD since the encounter related to myocardial fibrosis.

Kind regards

Martín Ibarrola MD Provincia de Buenos Aires Argentina



Estimados Andrés y Raimundo: Paciente masculino de 60 años, hipertenso e con historia de una probable miocarditis viral desde hace 20 años.
ECG: ritmo sinusal, PR 200 mseg, QRSd 90 mseg, fibrosis inferior, ondas T negativas asimétricas en paredes anterolateral e inferior, probable rotación anti-horaria. (transición antes de V₂). Extrasístoles ventriculares monomórficas de ligadura fija, e tardía, con eje a la derecha, (+160°), imagen de “BRD like”, positivos en aVF y III, lo que indica probable origen en el tracto de salida del ventrículo izquierdo (TSVI).

Holter: severa densidad horaria de extrasístoles ventriculares, un episodio de TVNS y extrasístoles supra-ventriculares (ESV) escasas.

Ecocardiograma: ventrículo izquierdo (VI) levemente dilatado con fracción de eyección del ventrículo izquierdo (Fey) en el límite inferior, sin trastornos segmentarios de motilidad, dilatación leve de aorta ascendente.

RMN: ídem FEy que Eco, fibrosis ínfero-septal, ínfero-basal (segmentos 3 y 4) y mesocárdica muy probablemente secuela de miocarditis viral. Si el origen de las extrasístoles ventriculares fuese éste último, el ECG registrarían complejos QRS negativos en cara inferior.

Sugeriría descartar isquemia por cámara gama, (aunque se efectuó CCG-VG, que se supone normal), Si esta fuese negativa, debería hacer diagnóstico de miocardiopatía discretamente dilatada, que se presume viral.

Anticuerpos virales? Biopsia Endo miocárdica?

Optimizar tratamiento farmacológico y estudio electrofisiológico(EEF) + ablación del foco arritmogénico.

CDI si hubiera taquicardia ventricular sostenida o síncope.

Me despido cordialmente.

Dr Juan Carlos Manzardo

Dear Andrés and Raimundo: A 60-year-old male patient, hypertensive and with a history of a probable viral myocarditis for 20 years.

ECG: sinus rhythm, PR 200 ms, QRSd 90 ms, inferior fibrosis, asymmetric negative T waves in anterolateral and inferior walls, probable CCWR. (transition before V₂). (+ 160 °), “RBBB like“ pattern, positive in aVF and III, indicating probable origen in the LVOT.

Holter: severe hourly density of PVCs, an episode of NSVT and rare supraventricular PACs spares.

Echocardiogram: slightly dilated LV, LVEF at lower limit, without segmental motility disorders, mild ascending aortic dilatation.

MRI: similar to Echo, inferoseptal, inferobasal (segments 3 and 4) and mesocardial fibrosis most likely sequelae of viral myocarditis.

If the origin of the PVCs was in the latter wall the ECG would register negative QRS complexes on the underside.

It would suggest that gamma chamber ischemia was ruled out (although CCG-VG was assumed to be normal). If this was negative, it should be diagnosed for mildly dilated cardiomyopathy, which is presumed to be viral. Viral antibodies? Endomyocardial biopsy?

Optimize pharmacological treatment and EPS + RFCA. ICD if there was Sustained VT or syncope.

I say goodbye cordially. Dr Juan Carlos Manzardo MD Mendoza Argentina.



Spanish

El ECG muestra un ritmo sinusal. La onda P en el VCG no la puedo definir bien. El VCG muestra una necrosis ínfero-septal, HBAI (las primeras fuerzas se dirigen hacia arriba y a la izquierda incialmente con rotación horaria para luego cambia a anti-horaria) y BRD de bajo grado (fuerzas finales hacia adelante y a la derecha en el plano horizontal y sagital). La duración del complejo QRS es de 114 mseg (según las comas que puedo contar), con un vector espacial máximo a los 40 mseg con un voltaje de 1,55 mV. A pesar de que este vector está en límite inferior de lo normal; estas fuerzas pueden estar contrarrestadas por las del trastorno de conducción derecho. El vector del ST se dirige hacia atrás a la derecha y arriba de muy bajo voltaje. La onda T se visualiza mejor en el plano horizontal, elíptica se dirige hacia atrás con rotación horaria, con un componente hacia la derecha y otro hacia la izquierda por lo cual I es -/+ y sobre la línea Z (ni arriba ni abajo). Impresiona como secundaria al BRD + agrandamiento VI. Con respecto a la arritmia presenta una morfología de BRD + HBPI por lo tanto nace en la pared anterosuperior del VI. Independientemente de que el paciente hace 20 años presento una miocarditis, tiene 67 años y es hipertenso.

Me gustaría ver la cineangiocoronariografía que se le realizó.

Afectuosamente

Isabel Konopka

English

The ECG shows a sinus rhythm, the VCG P-loop I can't define well. The VCG QRS-loop shows an inferoseptal necrosis, LAFB (the first forces are directed upwards and to the left initially with CWR and then it changes to CCWR) and minimal RBBB degree (forward and right end QRS forces in the HP and RSP). The QRSd =114 ms (according to the comets that I can count), with a maximum spatial vector at 40 ms with a voltage of 1.55 mV. Although this vector is at lower limit than normal; these forces may be counteracted by those of the right conduction disorder. The ST vector is directed back to the right and above very low voltage. The T-loop is best seen in the HP, and it has elliptical shape, and is directed backwards with CWR, with one component to the right and one to the left, whereby I lead is down-up minus-plus (- / +) and on the Z line (neither above nor below) . Impresses as secondary to incomplete RBBB + LVH.

Regarding the arrhythmia presented a morphology of RBBB + LPFB pattern therefore it is originate from the anterosuperior wall of the LV? Irrespective of the patient 20 years ago he had a myocarditis, he is 67 years old and is a hypertensive patient.

I would like to see the cineangiocoronariography that was performed.

Affectionately

Isabel Konopka, MD, Buenos Aires, Argentina



Dear Andrés and Raimundo,
Although the overall presentation favors VPB coming from a clearly identified substrate, I would suspect atypical ARVD despite the normal repolarization in precordial leads. Two hints: Enlargement of the RV (115 ml) and fixed coupling interval of the VPB. Many ARVD cases are first masquerading as myocarditis.
What about the family? Holter recordings? Exercise test? Any late potentials?

Kind regards,

Philippe Chevalier, MD PhD

Louis Pradel Cardiology Hospital of Lyon, France. Head of the Rhythmology unit of HCL and the coordinator of the National Reference Center for inherited arrhythmia



El ECG tiene varias características de alto riesgo de muerte súbita como son: Q inferiores sugestivas de necrosis, Infradesnivel del segmento ST e inversión de la onda T en caras lateral alta y baja, el AQRS-T desviado al CSD, con éstos hallazgos me parece que también se deberá descartar la presencia de cardiopatía isquémica. Es probable que la coronariografía fuera negativa, pero me parece necesario conocer los resultados. La extrasístole ventricular se origina en la pared lateral del VI, los hallazgos del Holter con frecuentes Extrasístoles ventriculares y un episodio de TVNS asociados con la presencia de realce tardío con gadolinio en un paciente con probable miocardiopatía dilatada o antecedentes de miocarditis, nos orientan a la coloración de un DAI por el alto riesgo de MSC asociada a las zonas de necrosis.

Saludos

Dr. Humberto Rodriguez Reyes (FACC, FHRS y AHA Member)

Cardiología, Electrofisiología (Arritmias), Medicina Interna

Instructor BLS, ACLS y ACLS-EP de la AHA

Sociedad Cardiovascular y Arritmias, SC. Aguascalientes, México



English

The ECG has several high-risk characteristics of sudden death(SD), such as: Q waves in inferior leads suggestive of necrosis, ST segment depression and inversion of the T wave in high and low lateral faces, the AQRS-T diverted to the CSD, with these findings it seems to me that the presence of ischemic heart disease should also be ruled out. It is probable that the coronary angiography was negative, but I think it is necessary to know the results.

PVCs originate in the lateral wall of the LV, Holter findings with frequent PVCs and an episode of NSVT associated with the presence of late enhancement with gadolinium in a patient with probable DCM or a history of myocarditis, orient us to the coloration of an ICD due to the high risk of MSC associated with necrosis zones.

Dr. Humberto Rodriguez Reyes (FACC, FHRS y AHA Member)

Final comments by



Andrés Ricardo Pérez-Riera, M.D. Ph.D.

Laboratorio de Escrita Científica da Faculdade de Medicina do ABC,
Santo André, São Paulo, Brazil

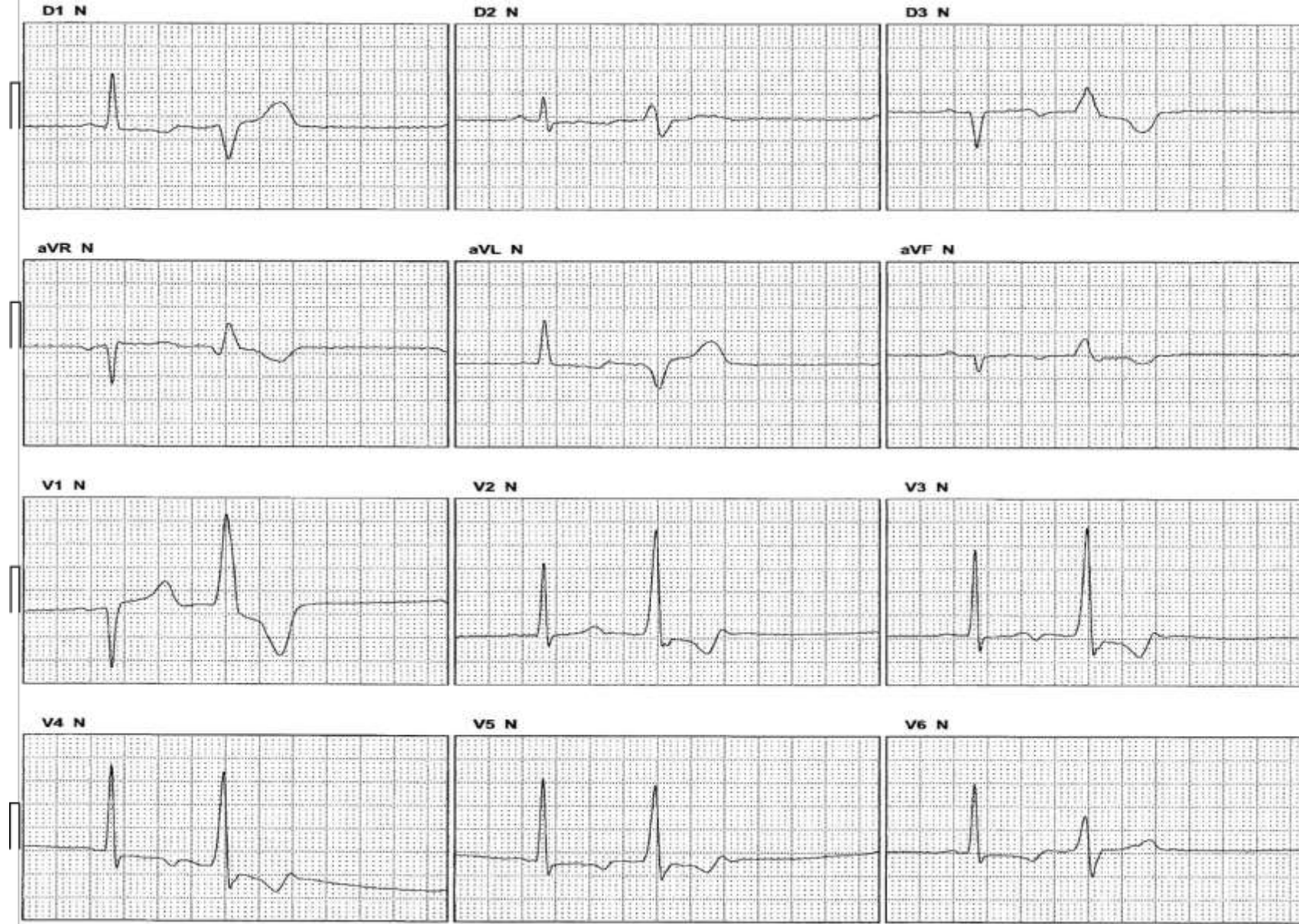Vectorcardiography section editor at Journal of Electrocardiology

<https://ekgvcg.wordpress.com>



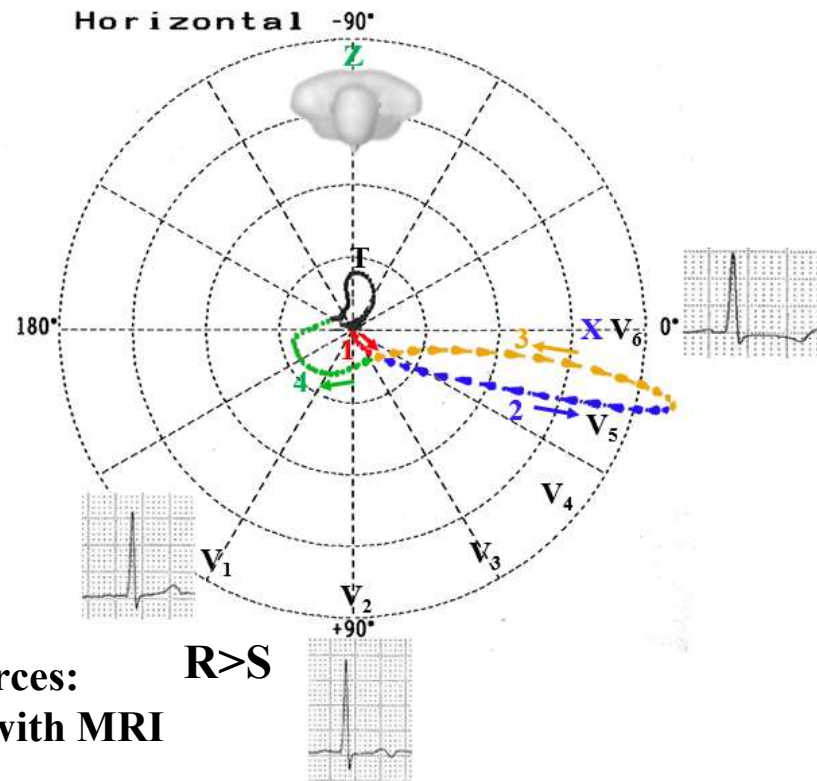
Raimundo Barbosa-Barros, MD

Centro Coronariano do Hospital de Messejana Dr.
Carlos Alberto Studart Gomes, Fortaleza – CE- Brazil



Electrically inactive inferobasal (old dorsal) area: QS in III and aVF + prominent anterior QRS forces (Rs in V2-V3) indicating basal lateral and inferior fibrosis. Bigeminal monomorphic premature ventricular contractions (PVCs) with RBBB + LPFB pattern (focus in anterosuperior LV wall). Asymmetrical T-wave in lateral leads. **Conclusion:** Electrically inactive inferolateral area (indeed, according to the CMRI specialist, the fibrosis is basal inferoseptal); monomorphic bigeminal PVCs with focus in the left ventricle.

ECG/VCG correlation in the horizontal plane

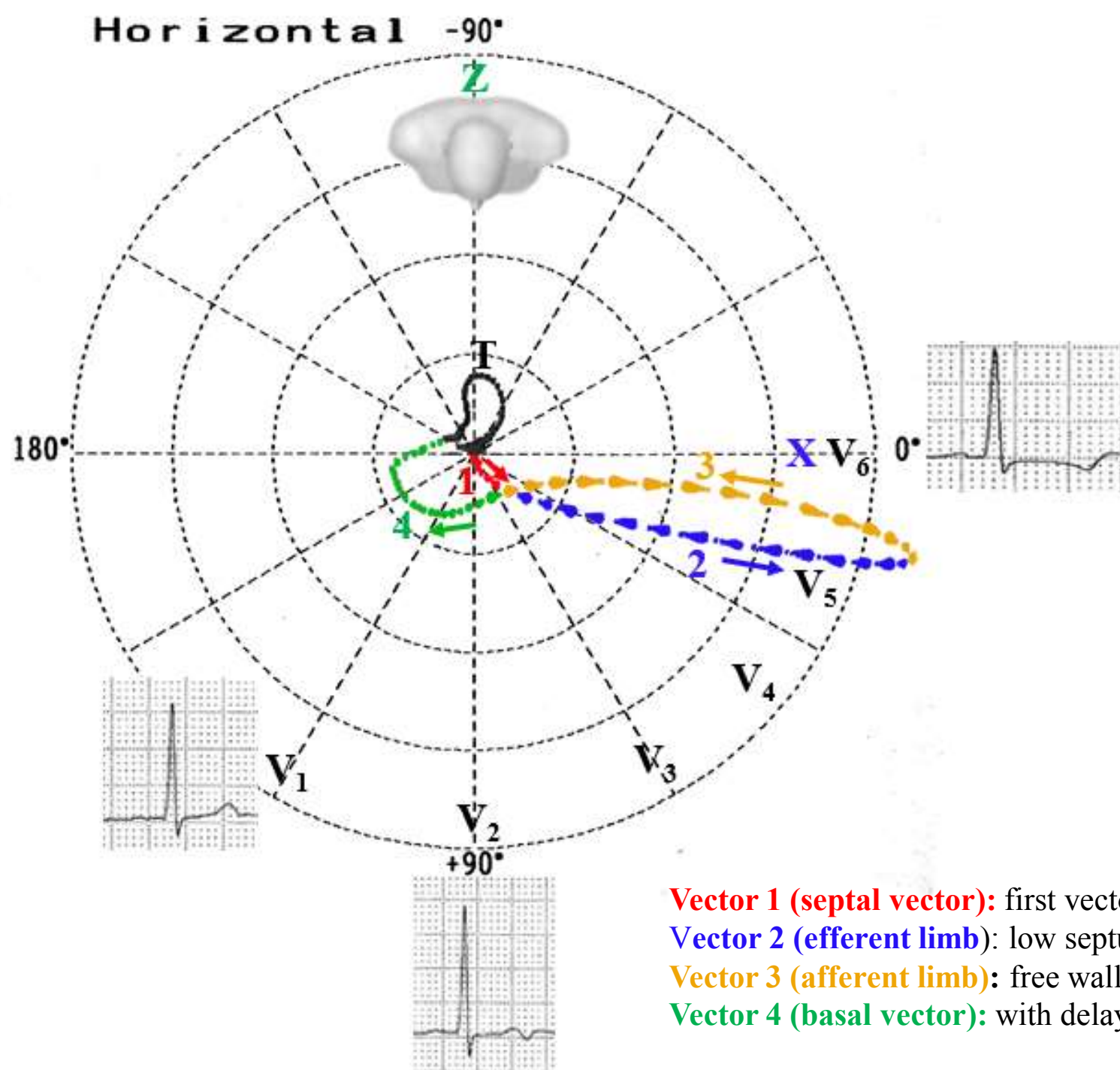


PAF: Prominent Anterior QRS Forces:
suggest lateral LV fibrosis discordant with MRI

R>S

There is initial (**10ms**) and **final** delay (comets closest to each other see magnificent figure in next slide). The initial vector (**septal vector (1)**) heading to the front and left (it may normally occur in 20% of cases). **Vector 2 (efferent limb)** of the low portion of the interventricular septum with mild anterior shift. **Vector 3 (afferent limb)** of the free walls of both ventricles very shifted to the front, and finally, the **basal vector (4)** located in the right anterior quadrant and delayed. The area of inferobasal fibrosis mainly affects the middle and final portions (vectors **3** and **4**) of the QRS loop between 30 and 100 ms; i.e. the second half of QRS shifts the afferent limb to the front, which ends with end conduction delay on the anterior right quadrant. T-loop: small, elliptical 20% to the right and 80% to the left and heading backward.

Conclusion: electrically inactive area in the basal and lateral region of the LV (lateral and inferobasal fibrosis). The end conduction delay (**vector 4**) may suggest the erroneous diagnosis of incomplete RBBB of the VCG Cabrera type, not detectable in ECG; however, it is due to **inferior LV fibrosis** wall and the final one to **lateral fibrosis** (see explanation next slide). Prominent anterior QRS forces are due to loss of lateral basal region of the LV. R/s ratio in V₁ ≥ 0.5 (**de Luna 2008**). The presence of prominent the R wave in V1 (R>S) such as the present case is due to the **lateral MI/fibrosis** and not to the involvement of inferobasal segment of inferior wall (old posterior wall) (**Goldwasser 2015; Bayés de Luna 2015**).

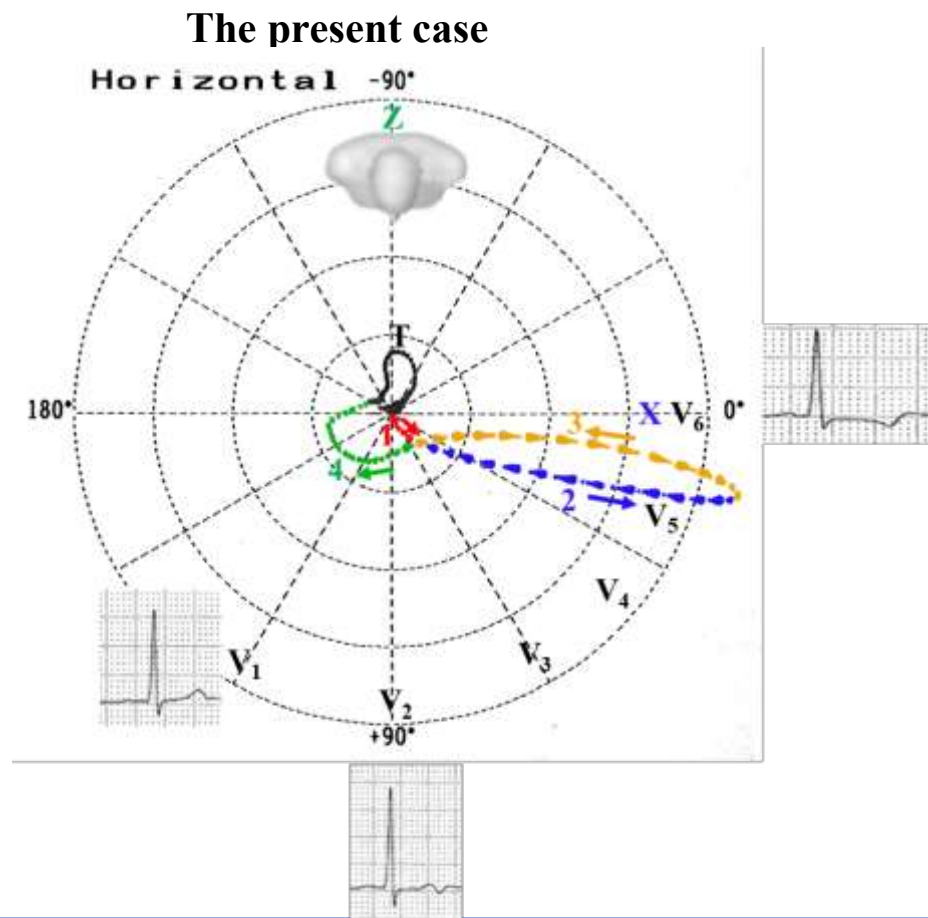


Vector 1 (septal vector): first vector with delay (inferior MF)

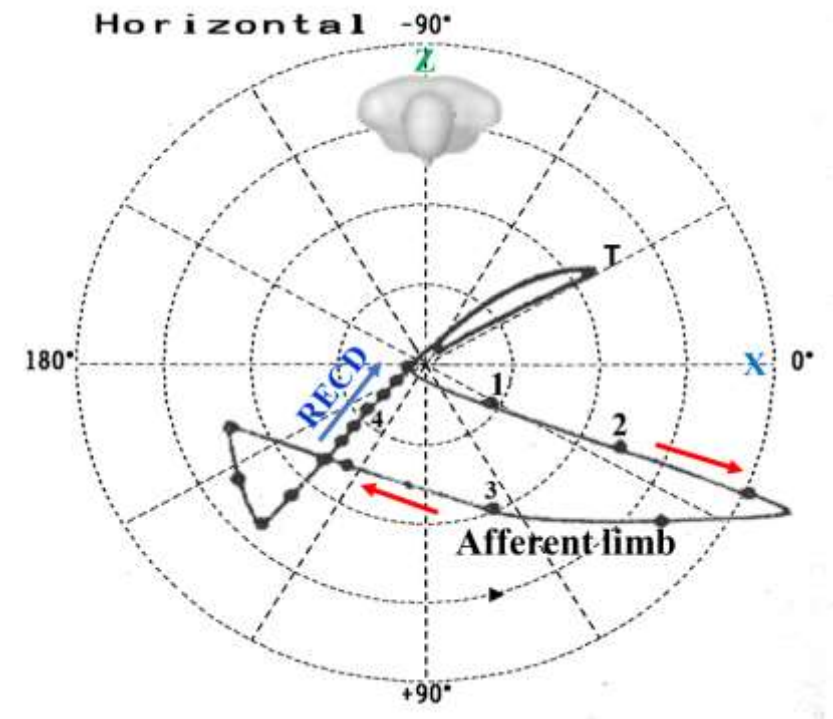
Vector 2 (efferent limb): low septum

Vector 3 (afferent limb): free walls of both ventricles

Vector 4 (basal vector): with delay (basal lateral MF)

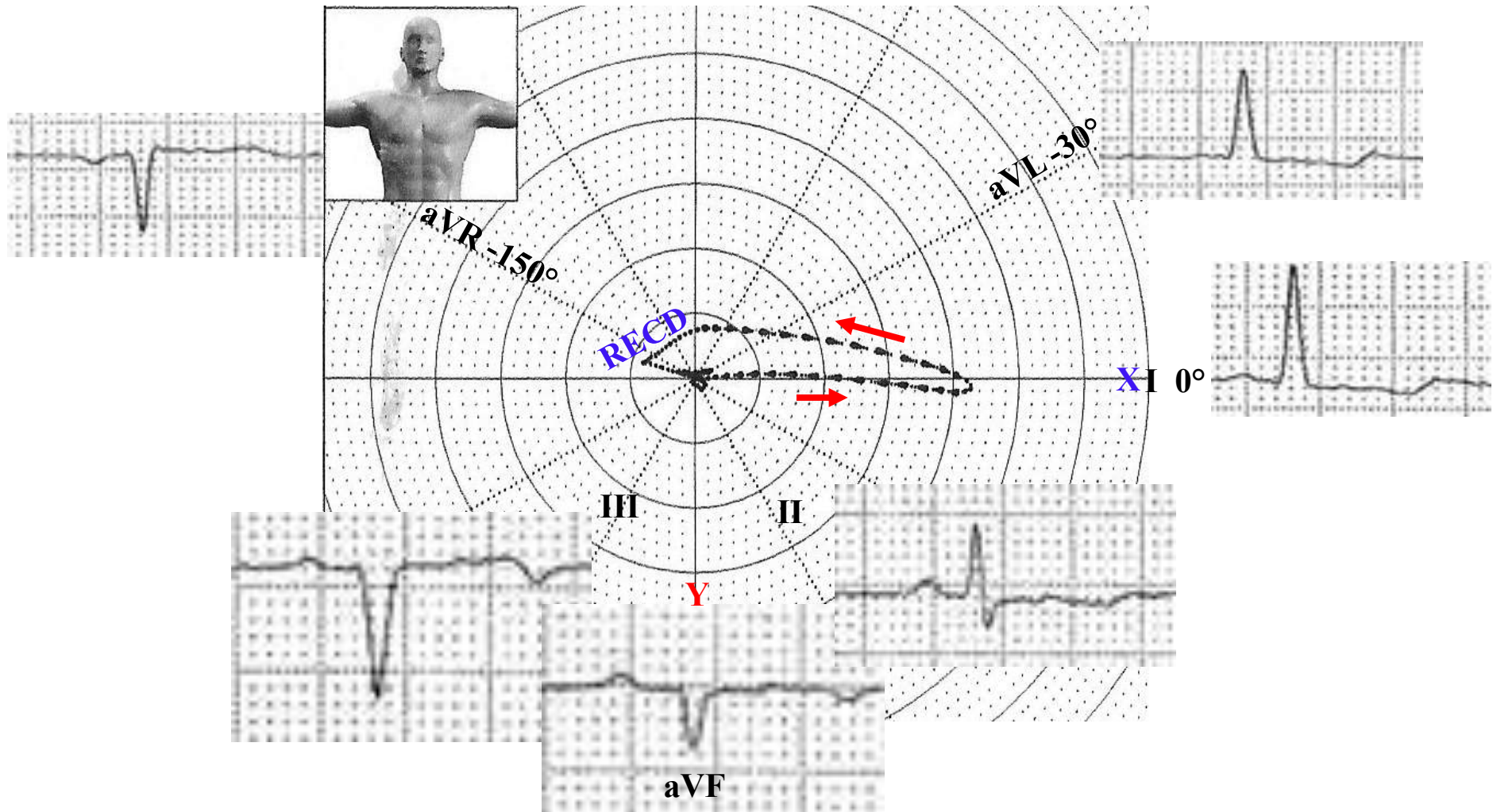


RBBB Cabrera type or Kennedy type II



r	The present case	RBBB of the Cabrera type
Initial delay (1)	Yes (inferior fibrosis)	No. Absent.
Efferent limb (2)	Anterior in relation to orthogonal X	Anterior in relation to orthogonal X
Afferent limb (3)	Anterior in relation to orthogonal X	Anterior in relation to orthogonal X
Final vector (4)	With delay due to basal infarction in late activated region	With final delay by RBBB.
T loop	Primary small, elliptic, and heading backward	Secondary, heading opposite to depolarization

ECG/VCG correlation in the frontal plane

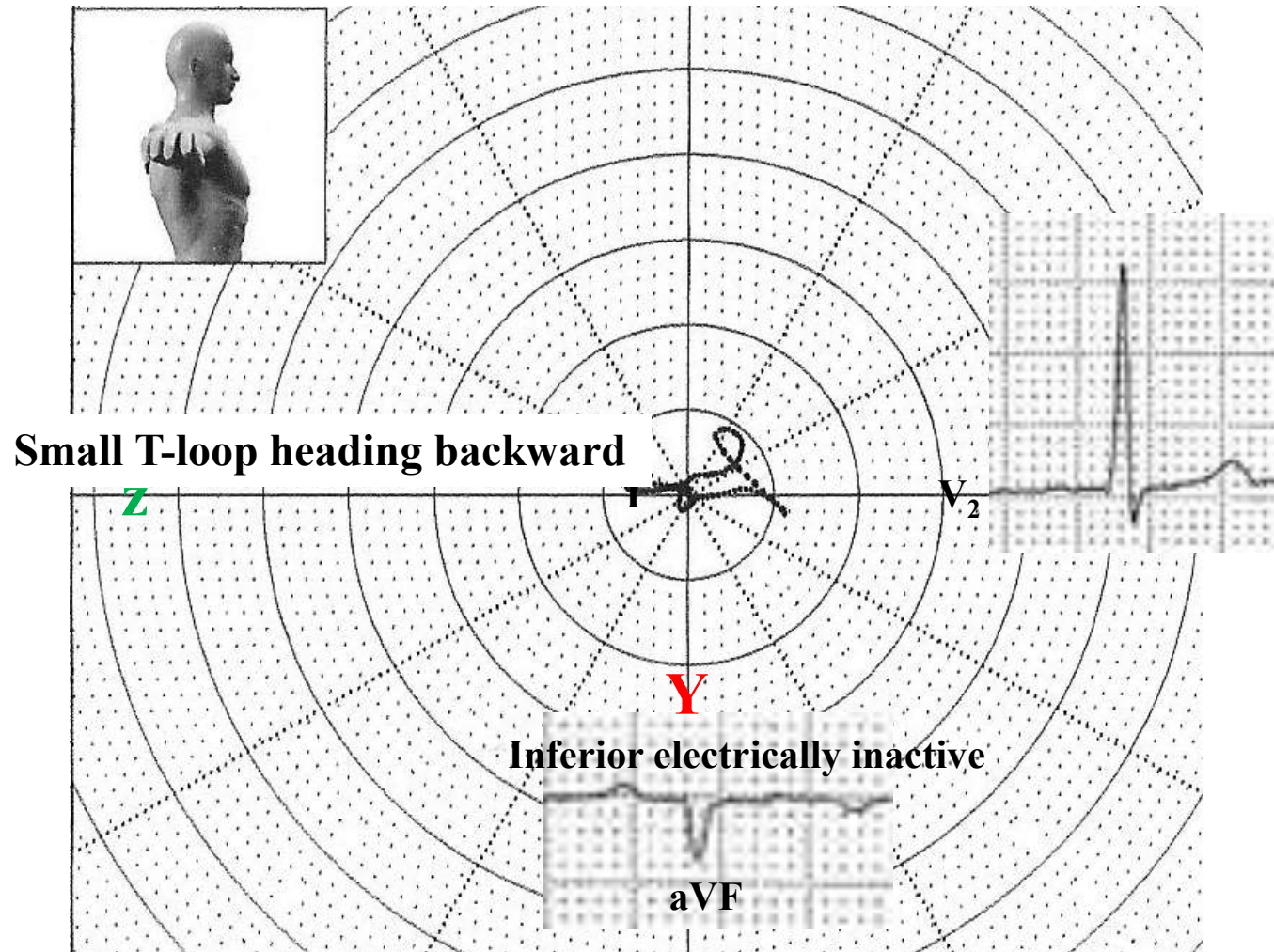


Electrically inactive inferior area that is not extensive (because II is preserved).

Right end conduction delay (**RECD**) (due to LV basal infarction).

Repolarization difficult to analyze (primary).

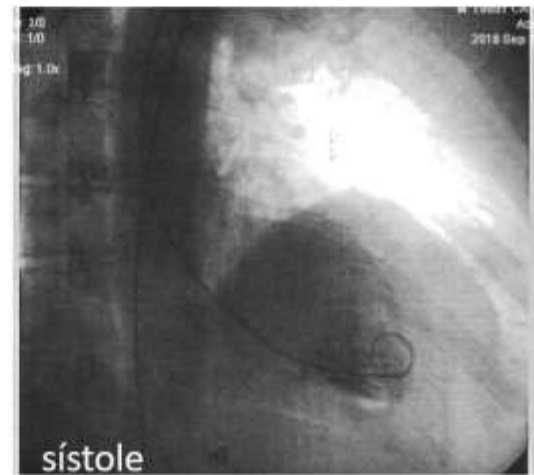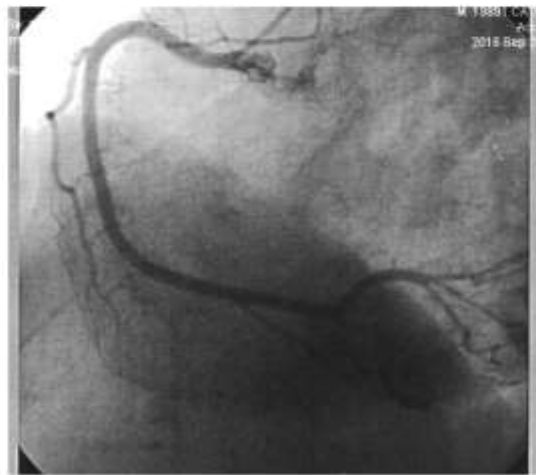
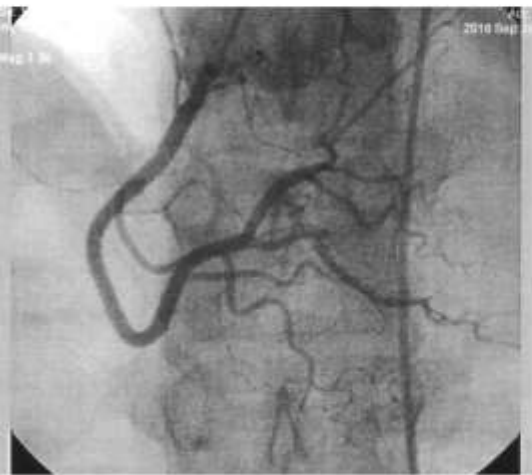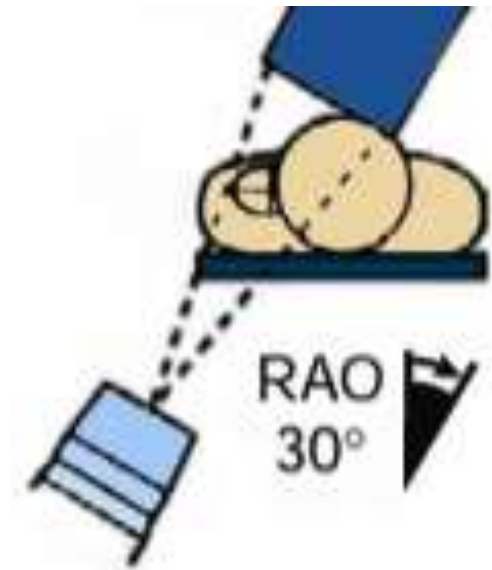
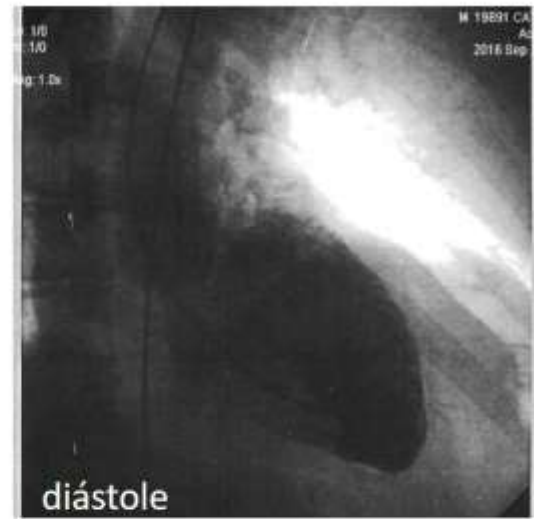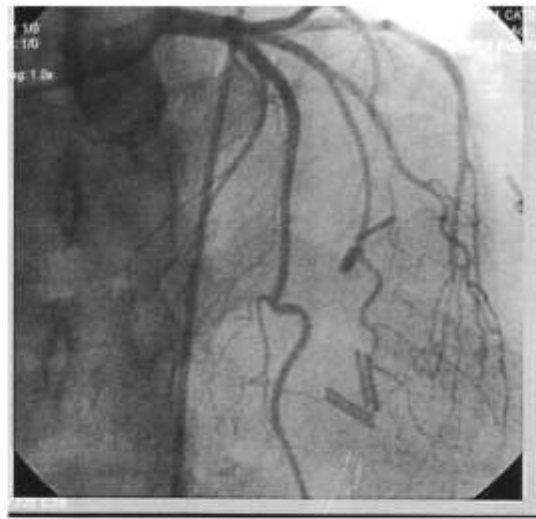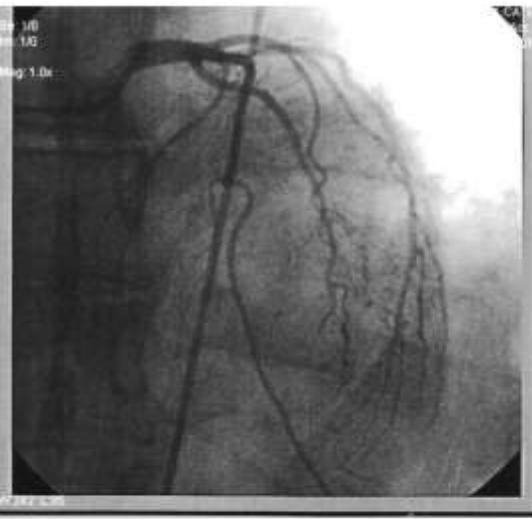
ECG/VCG correlation in the right sagittal plane



PAF: Prominent Anterior QRS Forces: consequence of lateral LV electrically inactive area (fibrosis): $R_s V_1-V_2$

QRS loop totally shifted to the front and above, pointing to inferobasal and lateral electrically inactive area fibrosis in the LV.
Repolarization small, heading backward (primary T-loop) opposite to QRS-loop.

Coronary angiography right anterior oblique projection (30°) made by the JUDKINS technique



Note: ECO and CMR data regarding LV performance are different from those of ventriculography because the latter was performed 20 months later which indicates a poor outcome.

Answer to Dr Martin Ibarrola

Left coronary artery: normal left main coronary artery (LMCA); left anterior descending (LAD) coronary artery: somewhat tortuous in the middle third, but with no signs of obstruction angiographically; left circumflex (LCx) artery: with marginal branch of moderate significance, but with no signs of obstruction angiographically. **Right coronary artery (RCA):** dominant and angiographically normal. **LV:** moderately dilated cardiac chamber with diffuse hypocontractility in a moderate to severe degree; competent mitral valve and whole septum. **Conclusions:** LV systolic dysfunction in a moderate to severe degree; normal coronary arteries.

Approach

In patients with myocarditis, early diagnosis and appropriate therapy are mandatory, as well as close clinical follow-up with particular regard to progression of disease and ventricular arrhythmia recurrences. The management of ventricular arrhythmias should follow current guidelines for ICD implantation, but new therapeutic options could be evaluated in these patients, such as combined epicardial/endocardial ablation and external wearable defibrillator. Particularly, depressed LVEF represents the only risk marker for SD currently used in myocarditis, although the use of a single risk factor has limited utility.

1. **Diet and lifestyle:** restrict salt intake to 2-3g of sodium per day, exercise especially during the acute phase of virus myocarditis enhances viral replication rate, enhances immune mechanisms and increases inflammatory lesions and necrosis. Resumption of physical activity can take place within 2 month of the acute disease.
2. **Pharmacologic** (treatment of heart failure (HF) and arrhythmias): Angiotensin-converting enzyme (ACE) inhibitor or angiotensin II receptor blockers + β -blockers (carvedilol, metoprolol or bisoprolol). These drugs reduce the risk of arrhythmias and lessen chance of SD. β -blockers may reduce signs and symptoms of HF + furosemide + aldosterone antagonists. The use of oral anticoagulant (ACO) is indicated in cases of myocarditis associated with paroxysmal or permanent atrial fibrillation (AF), intracavitary thrombi or previous thromboembolic phenomena.
3. **RFCA:** Endocardial RFCA with an irrigated catheter, using contact electroanatomic mapping of LV focus in biopsy-proven viral myocarditis and drug-refractory or electrical storm. Recurrence of sustained VT after endocardial RFCA must be treated with additional epicardial RFCA. Endocardial RFCA is useful in $\approx 70\%$ of cases while in the remaining $\approx 30\%$ VT is successfully ablated by epicardial approach RFCA. Hemodynamic instability requires sometimes an intra-aortic balloon pump to complete RFCA. $\approx 90\%$ remained free of sustained VT. Patients with LVEF $\leq 35\%$ frequently died for acute HF unrelated to ventricular arrhythmias. In patients with myocarditis, RFCA of drug-refractory VT is feasible, safe, and effective. Epicardial RFCA should be considered as an important therapeutic option to increase success rate (**Dello Russo 2012**).
4. The *Wearable cardioverter-defibrillator (WCD)* can be used to protect against SCA during the bridging period. WEARIT-II Registry demonstrates a high rate of Sustained VTs at 3 months in at-risk patients who are not eligible for an ICD, and suggests that the WCD can be safely used to protect patients during this period of risk assessment. Fulminant myocarditis is a distinct clinical entity with an adverse short-term but a relatively good long-term prognosis. Refractory SVTs are typical for the fulminant form of myocarditis. According to a Japanese registry, the short-term survival rate of patients with fulminant myocarditis is only 58% (**Aoyama 2002; Kohno 2000**).
5. ICD: only to the failure of the pharmacological approach and RFCA. See indications in this reference (**Russo 2013**)

Myocarditis a poorly understood disease with many faces

Myocarditis is an underdiagnosed cause of acute HF, SD, and chronic DCM. In developed countries, viral infections are the main cause of myocarditis; on the other hand, in the developing world, rheumatic carditis, *Trypanosoma cruzi*, and bacterial infections such as diphtheria still contribute to the global burden of the disease. The short-term prognosis of acute myocarditis is usually good, but varies widely by cause. Those patients who initially recover might develop recurrent DCM and HF, sometimes years later. Because myocarditis presents with non-specific symptoms (**Sagar 2012**). Myocarditis is the pathological result of myocardial infection and/or autoimmunity that causes active inflammatory destruction of myocytes. Giant cell myocarditis or eosinophilic necrotizing myocarditis, it is an autoimmune process. Several factors predispose the development of autoimmune myocarditis such as systemic/local primary autoimmunity, viral infection, HLA and gender bias, exposure of cryptic antigens, mimicry, and deficient thymic training/Treg induction (**Bracamonte-Baran 2017**). Etiologically, a wide spectrum of infectious agents, including viruses, bacteria, chlamydia, rickettsia, fungi and protozoans, as well as toxic and hypersensitivity reactions might be involved (**Sagar 2012**). Enteroviruses (Coxsackie B), adenoviruses, parvovirus B19 and human herpes virus type 6 are among the most common causal agents. Myocarditis can occur also in patients with advanced HIV infections due to cardiotoxicity with cellular apoptosis induced by viral glycoprotein, opportunistic infections, autoimmune response, drug-related cardiac toxicity and possibly nutritional deficiencies (**Sagar 2012; Liu 2001**). The typical microscopic image required for the diagnosis of myocarditis consists of the presence of inflammatory cells together with necrotic myocytes. The World Health Organization defines myocarditis as an inflammatory disease of the myocardium diagnosed by established histological, immunological and immunohistochemical criteria (**Richardson 1996**). In the same document, myocarditis associated with cardiac dysfunction is referred to as inflammatory cardiomyopathy, and both definitions are recommended for use by the relevant ESC recommendations (**Caforio 2013**). Thus endomyocardial biopsy (EMB) remains the gold standard for the definite diagnosis and should be performed especially in patients with a life-threatening events. CMR is becoming routine and is a sensitive, non-invasive test for confirmation of acute myocarditis even before EMB. Essential first-line tests to confirm the diagnosis in patients with a clinical presentation consistent with myocarditis should include ECG, transthoracic echo and assessment of biomarker concentrations (including troponins), erythrocyte sedimentation rate and C-reactive protein. The diagnosis criteria summarized by Caforio et al. (**Caforio 2013**). In the acute stage, may be asymptomatic or present with an unrecognized non-specific course. Considering malignant arrhythmias associated with myocarditis, two distinct clinical settings have to be distinguished: 1) acute fulminant: With sudden onset with refractory malignant VTs in the context of severe acute HF or cardiogenic shock usually following a flu-like illness with adverse short-term prognosis and early death due to multisystem failure (**Hékimian 2017**); long-term evolution to inflammatory cardiomyopathy with LV dysfunction resulting in a high risk of SD similar to that for DCM.

Myocarditis is histologically defined by the presence of an inflammatory infiltrate in the myocardium in conjunction with degenerative and/or necrotic changes of adjacent cardiomyocytes not typical of ischemic damage associated with myocardial infarction(**Sagar 2012**).

Myocarditis may be asymptomatic or have very different clinical presentations, ranging from sudden or rapidly evolving signs or symptoms of acute cardiac disease to slowly and inadvertently progressing to cardiac dysfunction, so that patients may come to medical attention when advanced and sometimes irreversible cardiovascular disease is established (**Anzini 2013**). The clinical presentation and prognosis will depend on etiology, pathogenic mechanisms and therapeutic strategies (**Lurz 2012**). However, studies aimed at identifying correlations between clinical phenotypes, imaging features and pathological or molecular substrates have produced no uniform conclusions, essentially due to the low use of histological ascertainment by EMB (**Mahrholdt 2006**). Therefore, in the clinical arena, most myocarditis patients undergo unpredictable evolution of their hemodynamic and clinical phenotype and require long-term strict follow-up to detect cardiac dysfunction. In this review diagnostic and therapeutic management issues will be examined in detail.

Causes of sudden cardiac death in different age groups: Cardiac diseases associated with SD differ in young vs. older individuals. In the young there is a predominance of channelopathies and cardiomyopathies (**Eckart 2011**), myocarditis and drugs abuse, while in older populations, chronic degenerative diseases predominate (CAD, valvular heart diseases and HF). Several challenges undermine identification of the cause of SD in both age groups: older victims, for instance, may suffer from multiple chronic cardiovascular conditions so that it becomes difficult to determine which contributed most to SCD. In younger persons, the cause of SD may be elusive even after autopsy, because conditions such as inherited channelopathies or drug-induced arrhythmias that are devoid of structural abnormalities are epidemiologically relevant in this age group. Rapidly expanding evidence suggests that myocardial inflammation is frequently underdiagnosed or overlooked in clinical practice, although new therapeutic options have been validated. Moreover, the available evidence suggests that subclinical cardiac involvement has negative prognostic impact on morbidity and mortality and should be actively investigated and adequately treated.

Summary

Myocarditis represents a growing challenge for physicians, due to increased referral of patients for EMB or CMR, and requires a highly integrated management by a team of caring physicians.

Epidemiology

Due to heterogeneity of clinical presentation and diagnostic work-up, myocarditis epidemiology is poorly documented. The high rate of ECG changes and elevation of biomarkers of myocardial necrosis during viral influenza epidemics, for example, may suggest myocarditis in a variable percentage of infected patients but this has not been prospectively validated by EMB nor by noninvasive cardiac imaging (**Ison 2005; Greaves 2003**). Autopsy studies reported a high incidence of myocarditis in SD patients but, these are not representative of the whole spectrum of disease manifestations (**Greaves 2003**). Some information has been provided by CMR imaging studies but this technique has been seldom correlated with EMB results and suffers from heterogeneity in myocarditis definition as well as CMR protocols (**Lurz 2012**).

Etiology and pathogenesis

A complex interplay of environmental and genetic factors causes inflammatory myocardial injury. Exogenous physical, chemical and microbiological agents may directly damage the myocardium, inducing inflammatory reactions (**Lumsden 2016**). The myocardium can also be exposed to endogenous biochemical compounds that may damage the cardiomyocytes, activate danger-related inflammatory pathways, as seen in catecholamine-induced cardiomyopathy/myocarditis, or in thyrotoxicosis (**Zhang 2015**). By modulating inflammatory and immune reactivity and cardiac susceptibility to damaging agents, genetic and epigenetic factors have been widely implicated in myocarditis as well (**Campuzano 2015**). The inflammatory response may be inappropriate as a response to the initial myocardial insult, because of hypersensitivity reactions or loss of self-tolerance (autoimmune post-injury reactions) (**Rose 2009**). When the myocardium is the primary target of immune-mediated diseases, cardiac involvement may be isolated or take place in the context of systemic immunemediated diseases (SIDs) (**Birnie 2016**). In these cases, the heart may host self-antigens or neoantigens against which specific autoreactive clones are expanded and directed (**Johnson 2016**). Alternatively, the myocardium may be passively infiltrated and damaged in the course of localized or generalized proliferation of immunocompetent cells or during systemic hyper-inflammatory reactions. This mechanism may be involved in eosinophilic myocarditis in the setting of drug-induced reaction with eosinophilia and systemic symptoms (DRESS) syndrome, in particular minocycline-related DRESS syndrome, as well as in hypereosinophilic syndromes, autoinflammatory diseases (e.g. adult-onset Still's disease, AOSD), septic shock and macrophage activation syndrome (**Mankad 2016; Bourgeois 2012; Savage 2014**). Whatever the operating mechanisms, inflammation supervenes and contributes to a wide range of biological events: healing and recovery with or without residual scar, ongoing cardiac damage with cardiomyocyte necrosis, stunning or apoptosis and finally interstitial or substitutive fibrosis (**Aretz 1987**). It is likely that cardiac clinical phenotype in myocarditis patients is influenced by concomitant functional autoantibodies or toxic compounds that directly impair metabolic and mechanical functions of the cardiomyocytes (**Nagamoto 2014**). A paradigmatic example is given by congenital heart block from transplacental passage of anti-SSA/anti-SSB autoantibodies (**Doti 2016**).

Etiology of myocarditis	
Infectious agents	Bacterial: Haemophilus influenzae, mycobacterium (tuberculosis), mycoplasma pneumoniae, others (rare); Spirochetal: Borrelia (Lyme disease), leptospira (Weil disease); Fungal: uncommon, mainly immunocompromised patients; Protozoal: trypanosoma cruzi (common in South America), others (rare); Parasitic: Chagasic myocarditis(endemic in rural area of South and Central America. Chronic form lead to conduction intraventricular system, AF, VT, SD, dilated, tromboembolism); Rickettsial: rare; Viral (common) - RNA viruses: coxsackievirus A and B, echovirus, influenza A and B virus, respiratory syncytial virus, humanimmunodeficiency virus-1, others (rare). DNA viruses: parvovirus B19 (most common in recent German series), adenovirus (mainly pediatric cases, Adenoviral infections can be much more virulent than coxsackievirus and can cause extensive cell that without comparable inflammatory response, cytomegalovirus (immunocompromised patients), herpes simplex virus, human herpes virus-6 (common in German patients, often in association with parvovirus B19), Epstein-Barr virus, others (rare).
Drugs and toxics	Drugs: amphetamines, anthracyclines, cocaine, cyclophosphamide, ethanol, fluorouracil, lithium, catecholamines, hemetine, interleukin-2, trastuzumab, clozapine; Heavy Metals: copper, iron, lead; Miscellaneous: scorpion sting, snake, and spider bites, bee and wasp stings, carbon monoxide, inhalants, phosphorus, arsenic, sodium azide; Hormones: Pheochromocytoma; Vitamins: ↓B ₁ (beri-beri); Physical agents: Radiation, electric shock.
Immune-mediated	Autoimmune organ-specific (primary or post-infectious): lymphocytic (common), giant cell (rare); Autoimmune associated with extra-cardiac autoimmune or immune-oriented disorders: systemic lupus erythematosus, rheumatoid arthritis, Churg-Strauss syndrome, Kawasaki’s disease, inflammatory bowel disease, scleroderma, polymyositis, myasthenia gravis, insulin-dependent diabetes mellitus, thyrotoxicosis, Granulomatous: sarcoidosis(rapid onset, HF, VTs, conduction block), Giant cells Myocarditis (rapidlly progressive HF, TVs. EMB: diffuse granulomatosis lesions surrounded by extensive inflammatory infiltrate), Wegener’s granulomatosis; Allergic - Miscellaneous: tetanus toxoid, vaccines, serum sickness; Drugs: penicillin, cefaclor, colchicine, furosemide, isoniazid, lidocaine, tetracycline, sulfonamides, phenytoin, phenylbutazone, methyldopa, thiazide diuretics, amitriptyline; Alloantigenic: heart transplant rejection.

Acute myocarditis

Viral infection

Myocyte necrosis

**Macrophage
activation**

Cytokine expression

- Interleukin-1
- Interleukin-2
- Tumor necrosis factor
- Interferon- γ

Subacute myocarditis

**Infiltrating
mononuclear cells**

**Natural
killer cells**

Perforin

Nitric oxide

**Cytotoxic
T lymphocytes
B lymphocytes**

**Neutralizing
antibodies**

Chronic myocarditis

**Fibrosis
Cardiac dilatation
Heart failure**

Viremia

4 days

Viral clearing

14 days

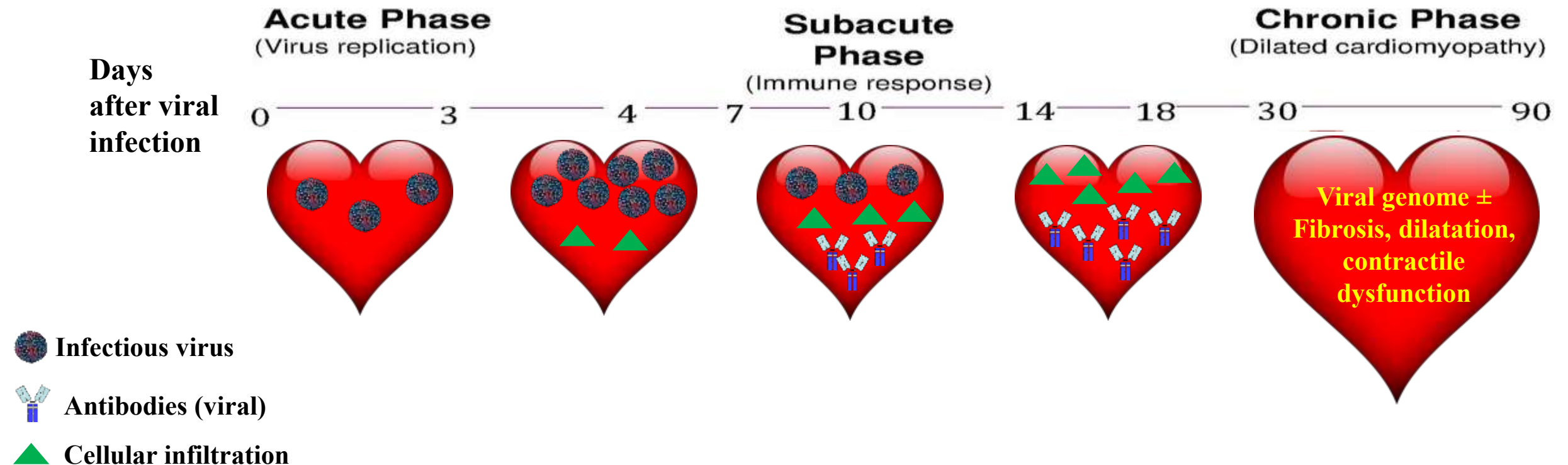
Absence of virus

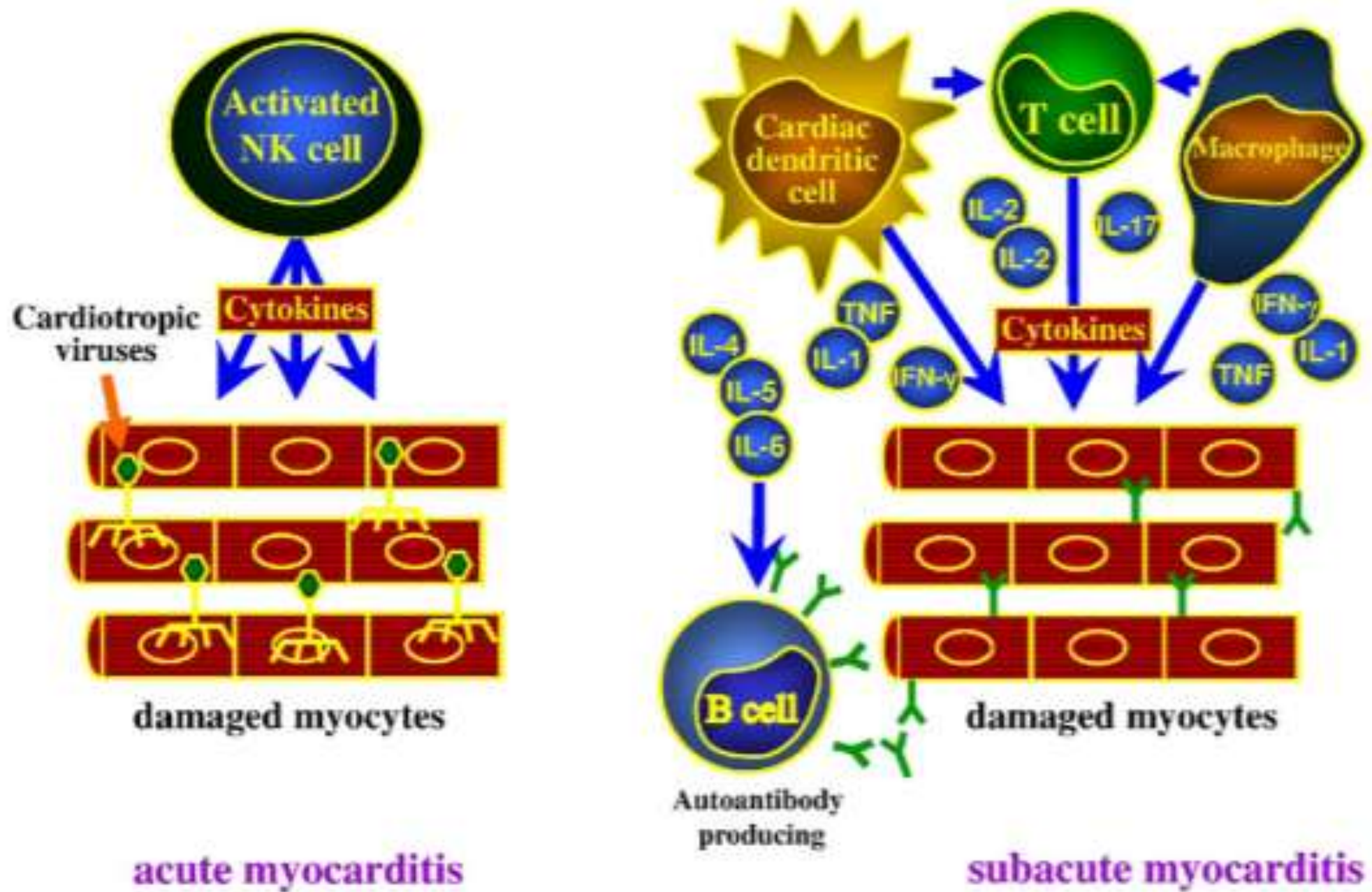
90 days

Clinical presentation

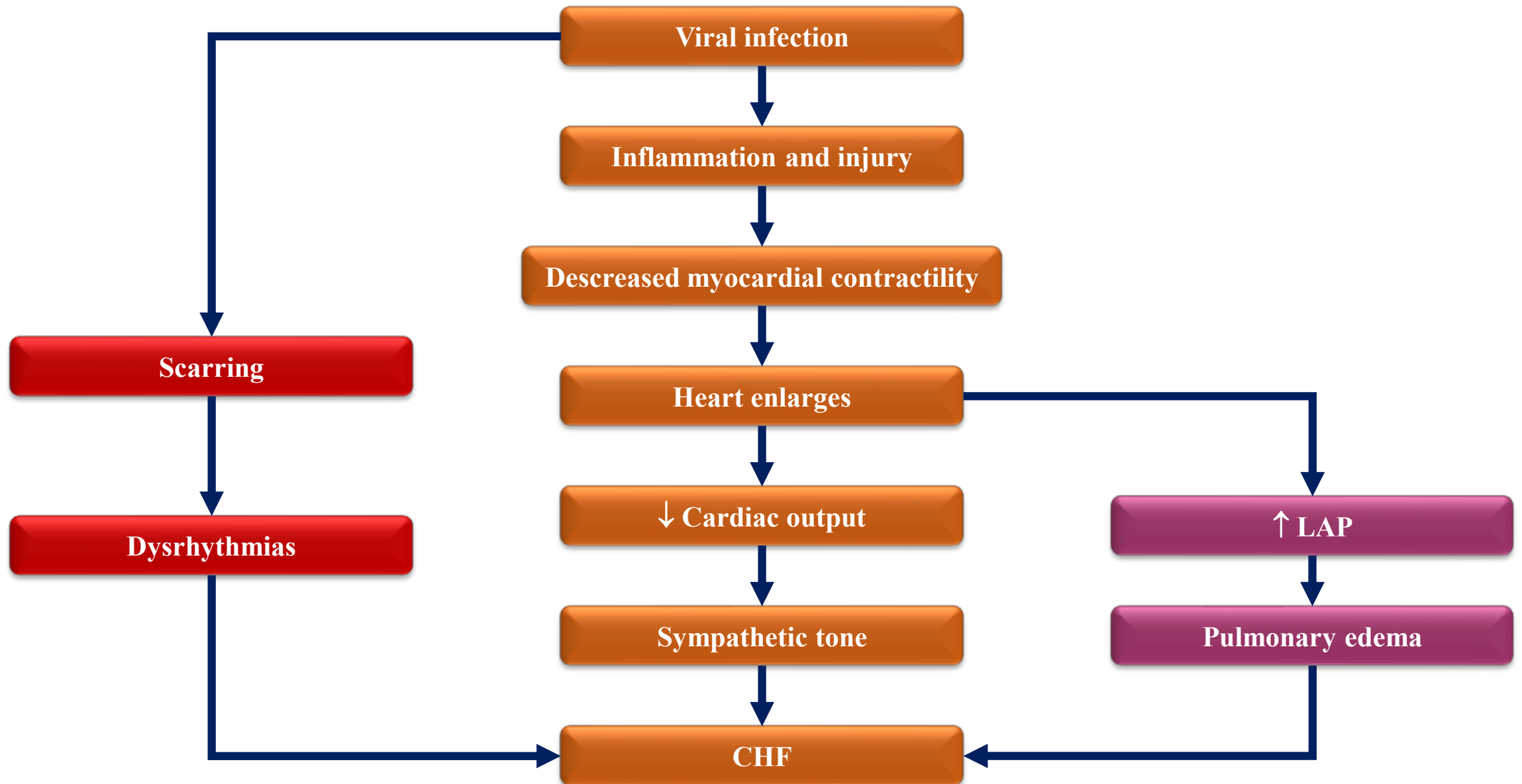
Acute	Fulminant	Chronic
Nonspecific cardiac symptoms	Cardiogenic shock	Subtle, insidious onset
Heart failure, acute MI, or SD	± acute heart failure	Already have DCM - HF symptoms
More common in children/teenagers	Biopsy doesn't march the clinical severity	Biopsy with fibrosis usually
± viral prodrome	High levels of cytokines – reversible cardiac depression - better prognosis	

Clinical phases (Kindermann 2012)





Pathophysiology of viral myocarditis: after viral entry, virus replication leads to acute injury of the myocytes (acute myocarditis) and to activation of the host's immune system (subacute myocarditis). IFN interferon; IL interleukin; TNF tumor necrosis factor.



Clinical presentation, laboratory diagnostics and imaging: Myocarditis presentation is heterogeneous and more than one sign or symptom of cardiac disease can be present at disease onset (**Caforio 2015**). The patient may come to medical attention reporting one of more of the following symptoms: chest pain and discomfort, which may be ischemic-like or pleuritic-like (if myocarditis is accompanied by pericarditis), palpitations, syncope, dyspnea and easy fatigability. Cardiogenic shock, requiring admission to intensive care unit for pharmacological and/or mechanical hemodynamic support, may be the presenting modality in severe disease (i.e. fulminant myocarditis) (**McCarthy 2000**). Ancillary findings may be asthenia, fever, lack of appetite and abdominal pain. Myocarditis usually manifests in an otherwise healthy person and can result in rapidly progressive (and often fatal) HF and arrhythmia. Patients with myocarditis have a clinical history of acute decompensation of HF, but they have no other underlying cardiac dysfunction or have low cardiac risk.

Signs and symptoms: mild symptoms: chest pain (in concurrent pericarditis), fever, sweats, chills, dyspnea; in viral myocarditis: Recent history (≤ 1 -2 wk) of flulike symptoms of fevers, arthralgias, and malaise or pharyngitis, tonsillitis, or upper respiratory tract infection; palpitations; syncope; SD due to underlying ventricular arrhythmias or atrioventricular block (especially in giant cell myocarditis); HF: adults may present with HF years after an initial index event of myocarditis (as many as 12.8% of patients with idiopathic DCM had presumed prior myocarditis in one case series).

Clinical presentations include ≥ 1 of the following: ACS-like, with or without normal global or regional LV and/or RV dysfunction on echo or CMRI, with or without increased troponin (Tn)T/TnI (that may have a time course similar to acute myocardial infarction or a prolonged and sustained release over several weeks or months); new onset or worsening HF in the absence of CAD and known causes of HF; chronic HF, with HF symptoms (with recurrent exacerbations) of >3 months in the absence of CAD and known causes of HF; life-threatening condition (including life threatening arrhythmias and aborted SD, cardiogenic shock, severely impaired LV function), in the absence of CAD and known causes of HF.

Clinically suspected myocarditis: defined by the presence of ≥ 1 clinical presentation (with or without ancillary findings) and ≥ 1 diagnostic criteria from different categories, in the absence of: angiographically detectable CAD (coronary stenosis $\geq 50\%$); known pre-existing cardiovascular disease or extra-cardiac causes that could explain the syndrome (e.g. valve disease, congenital heart disease, etc.). Suspicion is higher with higher number of fulfilled criteria; if the patient is asymptomatic ≥ 2 diagnostic criteria should be met.

Physical Examination: Usually present with signs and symptoms of acute HF (eg, tachycardia, gallop, mitral regurgitation, edema) and, in those with concomitant pericarditis, with pericardial friction rub. Specific findings in special cases are as follows: sarcoid myocarditis - Lymphadenopathy, also with arrhythmias, sarcoid involvement in other organs (up to 70%); acute rheumatic fever - Usually affects heart in 50-90%; associated signs, such as erythema marginatum, polyarthralgia, chorea, subcutaneous nodules (Jones criteria); hypersensitive/eosinophilic myocarditis - Pruritic maculopapular rash and history of using offending drug; giant cell myocarditis - Sustained VT (SVT) in rapidly progressive HF (**Rosenstein 2000**); peripartum cardiomyopathy – HF developing in the last month of pregnancy or within 5 months following delivery

Signs and symptoms

Chest pain (often described as “stabbing” in character)

CHF (leading to edema, breathlessness and hepatic congestion)

Palpitations (due to arrhythmias)

SD (in young adults, myocarditis causes up to 20% of all cases of SD)

Fever (especially when infectious)

Since myocarditis is often due to a viral illness, many patients give a history of symptoms consistent with a recent viral infection, including fever, diarrhea, joint pains, and easy fatigueability

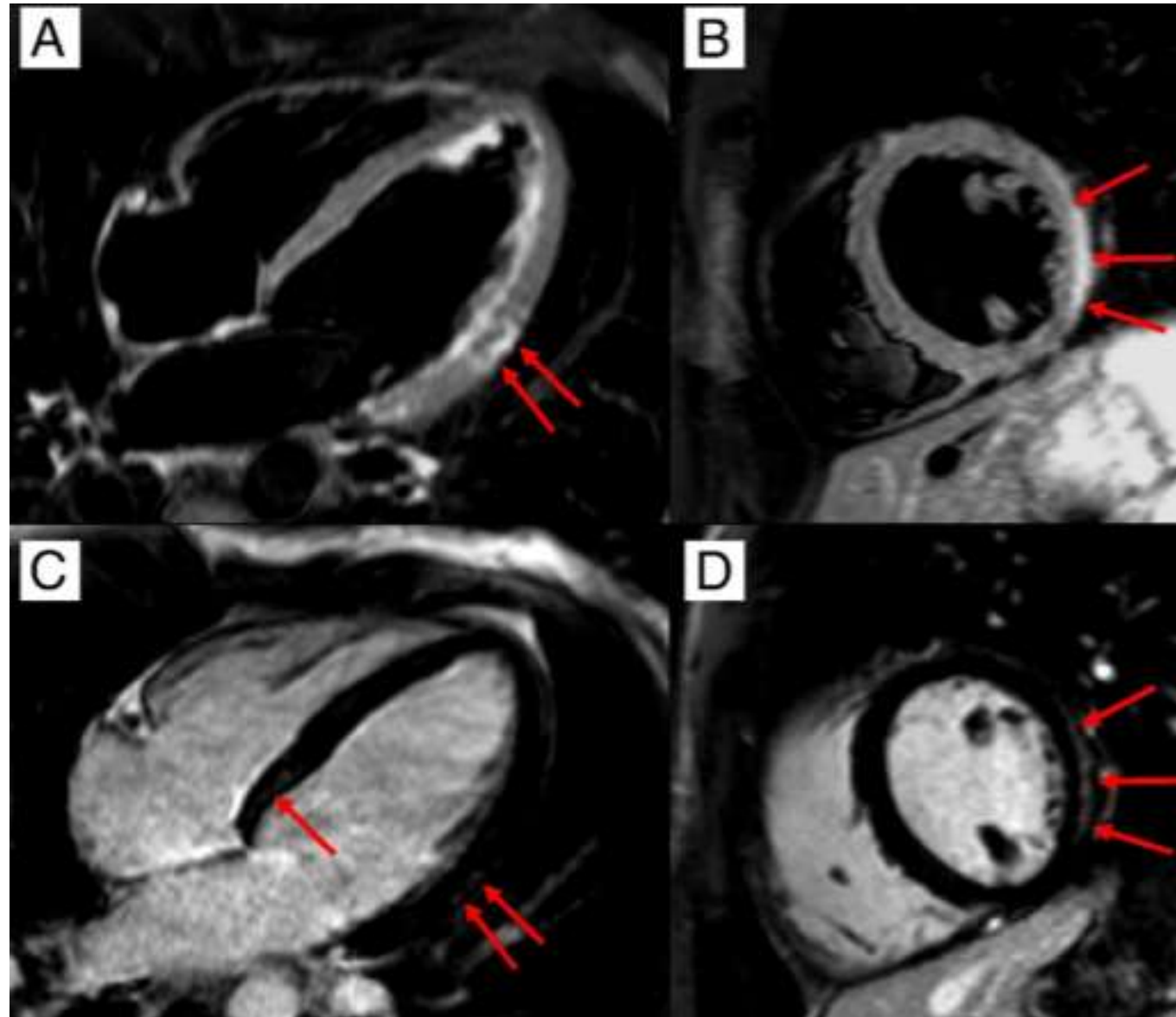
Myocarditis is often associated with pericarditis, and many patients present with signs and symptoms that suggest concurrent myocarditis and pericarditis

- I. **ECG findings** may include sinus tachycardia, low QRS voltage if pericardial effusion present. Concomitant pericardial involvement may be suspected by the finding of diffuse non-specific ST segment or T-waves changes elevation on precordial leads, PR-segment depression with concurrent ST segment elevation if pericardium involved, tachy- brady-arrhythmia, conduction abnormalities. Newly abnormal 12 lead ECG and/or Holter and/or stress testing, any of the following: I to III degree AV block, or bundle branch block, ST/T wave change (ST elevation or non ST elevation, T wave inversion), sinus arrest, ventricular tachycardia or fibrillation and asystole, atrial fibrillation, reduced R wave height, nonspecific intraventricular conduction delay (widened QRS complex), abnormal Q waves, low voltage, frequent PVCs, supraventricular tachycardia.
- II. **A 24h-ECG-Holter** can be used for quantification of the arrhythmic burden and selection of the appropriate anti-arrhythmic therapeutic strategy.
- III. **Lab:** Cardiac damage laboratory markers Troponin I and T cannot distinguish between myocarditis and other causes of acute cardiac necrosis and do not correlate with the degree of myocardial necrosis; in addition, lack of troponin rise does not rule out biopsy-proven myocarditis (**Lauer 1997**). Markers of increased ventricular filling pressures, e.g. natriuretic peptides, are neither sensitive nor specific. It could be said that both myocardial damage and dysfunction biomarkers, if abnormal at baseline, may be useful in documenting the clinical evolution of myocarditis and its response to therapy but, when negative at baseline, should not be read as proof of immunohistological absence of myocarditis. In the appropriate clinical setting, laboratory investigation can be particularly helpful to confirm or exclude specific disease states associated with cardiac involvement, such as hypereosinophilic syndromes, ANCA-associated vasculitis (AAV), sarcoidosis, systemic lupus erythematosus (SLE), idiopathic inflammatory myopathies, infections. An indirect immunofluorescent assay is also available for the detection of circulating anti-heart autoantibodies (AHA): the presence of these AHA in a patient serum supports an autoimmune etiology for myocarditis (**Caforio 1997**).
- IV. **Transthoracic echocardiography** represents the first line imaging technique by providing essential information for differential diagnosis (ischemic cardiomyopathy, valvular disease) and quantification of the degree of systolic and diastolic ventricular dysfunction and hemodynamic impairment. In this regard a wide spectrum of ventricular morpho-functional abnormalities may be detected, ranging from regional wall motion abnormalities with a non coronary artery distribution, or diffusely hypokinetic non-dilated cardiomyopathy to a dilated hypokinetic cardiomyopathy (recent onset dilated cardiomyopathy) (**Caforio 2015; Pinto 2016**). In the acute clinical setting, myocardial inflammatory edema, leading to an increase in wall thickness, may mimic hypertrophy (**Felker 2000**). Transthoracic echo may also provide useful information regarding concomitant pericardial or endocardial disease and additional findings suggesting a specific diagnosis (for example, Libman-Sacks endocarditis in the setting of lupus myocarditis (**Mohammed 2017**) or endomyocardial fibrosis changes or

endocavitary thrombus in the setting of acute eosinophilic myocarditis); nonetheless it does not provide detailed tissue characterization. In suspected myocarditis with infarct-like presentation, it is necessary to exclude CAD by coronary angiography or noninvasive computer tomographic coronary angiography (**Pinto 2016; Agewall 2017**). Routine coronary angiography should also be pursued in the work-up of a new onset dilated cardiomyopathy.


V. Chest X, Ray: reveal cardiomegaly, pulmonary vascular prominence, pulmonary edema or pleural effusions;.

VI. CMRI is a valid non-invasive option to better characterize the inflamed myocardium by identifying edema, early and late gadolinium enhancement (LGE). Lake Louise Criteria have been proposed in a consensus to get a diagnosis of myocarditis (**Friedrich 2009**). Similar to the Dallas Criteria for EMB, it is now clear that also the Lake Louise Criteria suffer from major limitations and new emerging CMR techniques are under intense research (T1- and T2-tissue mapping) (**Bohnen 2015; Ferreira 2013**). When the patient suffers from a multisystem infective or inflammatory disease, signs of cardiac disease may herald the syndrome or appear in association with the signs and symptoms of extra-cardiac disease (e.g. nephritic syndrome, skin rash, etc.) (**Escher 2015; Lumsden 2016; Mankad 2016; Birnie 2016, Dieval 2015; Thomas 2017; Bourgeois 2012; Antonarakis 2006**). In these cases the clinician should try to recognize etiological- or disease-specific patterns (e.g. DRESS syndrome, sarcoidosis, flu, etc.) to provide the best therapeutic approach. It should be remembered that multisystem inflammatory diseases may not be limited to the myocardium and the full cardiological clinical phenotype may result from the involvement of more than one cardiac structure (pericardium, endocardium and valves, coronary vessels) (**Prasad 2015**). In a described cohort of lupus myocarditis patients, for example, concomitant pericardial effusion and valvular dysfunction, as detected by CMR and echocardiography, was present in 69% and 41% of patients respectively (**Thomas 2017**).

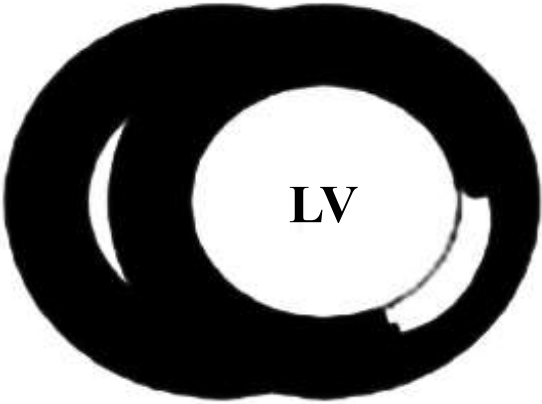


CMRI of a young patient presenting with acute chest pain syndrome due to acute myocarditis (A). Long-axis and (B) short-axis T2-weighted edema images demonstrating focal myocardial edema in the subepicardium of the left midventricular lateral wall (red arrows). Corresponding (C) long-axis and (D) short-axis T1-weighted late gadolinium enhancement images demonstrate presence of typical late gadolinium enhancement in the subepicardium of the left midventricular lateral wall and the basal septum (red arrows).


The short axis view shows cross-sections of the LV and RV that are useful for volumetric measurements using Simpson's rule. The short axis view is chosen such that a series of slices are perpendicular to the long axis of the LV.



Normal myocardium



Myocardial infarction



Myocarditis

MRI can also play a role in discriminating myocarditis from myocardial infarction, which can help in the evaluation of acute chest pain. In myocarditis the infiltrates are characteristically located in the mid-wall and tend to spare the sub endocardium, whereas in infarction, the sub endocardium is involved first.

EMB-proven (definite) myocarditis: the diagnosis of “Definite myocarditis” is based upon EMB confirmation of clinically suspected myocarditis, including conventional histology (Dallas criteria Dallas Hum Pathol. 1987. 18:619-24.), as well as immunohistochemistry and polymerase chain reaction (PCR) detection of infectious agents; histological definition (Dallas criteria): “histological evidence of inflammatory infiltrates within the myocardium associated with myocyte degeneration and necrosis of non-ischaemic origin”; immunohistochemical criteria, abnormal inflammatory infiltrate defined as follows: “ ≥ 14 leucocytes/mm² including up to 4 monocytes/mm² with the presence of CD 3 positive T-lymphocytes ≥ 7 cells/mm²”. Immunological criteria and myocarditis etiology defined as follows: viral: histology (Hx) and immunoHx positive (pos), PCR pos for \geq virus (recommended viral screen: Enterovirus, influenza virus, adenovirus, cytomegalovirus, Epstein-Barr virus, parvovirus B19, human herpes virus 6); autoimmune: Hx and immunoHx pos; viral PCR negative (neg); with or without pos cardiac autoantibodies (aabs); exclusion of other known inflammatory causes; viral and immune: Hx and immunoHx pos; viral PCR pos; cardiac aabs pos N.B. a follow-up EMB may identify persistent viral myocarditis, resolved myocarditis (Hx and virological), or persistent virus-negative myocarditis, e.g. post-infectious autoimmune; absence of infectious agents identifies immune-mediated myocarditis and is the basis for safe (infection negative) immunosuppression; EMB is essential to identify specific myocarditis types (e.g. giant cell, eosinophilic, sarcoidosis) which imply different treatments and prognosis; EMB provides differential diagnosis from diseases that may mimic myocarditis (arrhythmogenic right ventricular cardiomyopathy, Takotsubo cardiomyopathy, peri-partum cardiomyopathy, infiltrative/storage disorders, cardiac masses). According Dallas Criteria (1986), myocarditis is defined by the presence of an inflammatory infiltrate in the myocardium accompanied by degenerative and/or necrotic changes of adjacent cardiomyocytes not typical of ischemic damage associated with MI (**Aretz 1987**). A wide variety of histological myocarditis patterns have been described according to the diverse etiologies and to the stage of the disease at the time of EMB ascertainment. Although the Dallas criteria represent an important first attempt to standardize histological diagnosis, in the subsequent decades several limitations have been pinpointed: inflammatory cell characterization by immunohistochemistry and fibrosis amount are not considered; the type and extent of myocyte damage are not specified; fibrosis amount are not considered; the type and extent of myocyte damage are not specified; the term borderline myocarditis, including also chronic forms, remains equivocal and does not help in the clinical setting; any reference to etiological agents is lacking (**Baughman 2006**). For these reasons an international Task Force of the Association for European Cardiovascular Pathology and the Society for Cardiovascular Pathology published a position paper concerning the current role of EMB for the diagnosis of cardiac diseases, mainly focusing on pathological issues (**Leone 2012**). At least three or four EMB fragments, each 1–2 mm in size, should be fixed in 10% buffered formalin at room temperature for light microscopic examination. When myocardial lesions are focal or patchy additional sampling is encouraged. Moreover, one or two specimens should be snap-frozen in liquid nitrogen and stored at -80°C for possible molecular tests or be stored in RNA-later (a solution preventing RNA degradation). Application of these recommendations and of new immunohistochemical and virological techniques allowed a dramatic improvement in both sensitivity and specificity of EMB analysis and led to the conclusion that myocarditis

diagnosis had probably been underestimated previously (**Wojnicz 1998**). Viral genome could be detected in a relevant, although varying, percentage of patients, mostly human herpes virus 6 (HHV6), parvovirus B19 (PVB19), adenovirus, reflecting the viral epidemiology of specific geographic areas and ethnic groups (**Schultz. 2009**). These findings also raised new hope for the possibility to predict prognosis and/or response to etiology-directed therapies in homogeneously selected cohorts of patients.

Pathologic classification is complicated, however, because EMBs often are not obtained, and a presumptive clinical diagnosis must sometimes be confirmed by means of indirect methods such as serology (**Biesbroek 2015**).

Histologic patterns: lymphocytic (including viral and autoimmune forms); eosinophilic (of which hypersensitivity myocarditis is the most common type, followed by hypereosinophilic syndrome); granulomatous (cardiac sarcoidosis and giant-cell myocarditis); neutrophilic (bacterial, fungal, and early forms of viral myocarditis); reperfusion type/contraction band necrosis (present in catecholamine-induced injury and reperfusion injury).

WHO Marburg Criteria (1996)

Acute (active) myocarditis: A clear-cut infiltrate (diffuse, focal or confluent) of >14 leukocytes/mm (preferably activated T-cells).

The amount of the infiltrate should be quantitated by immunohistochemistry. Necrosis or degeneration are compulsory, fibrosis may be absent or present and should be graded.

Chronic myocarditis: An infiltrate of >14 leukocytes/mm (diffuse, focal or confluent, preferably activated T-cells).

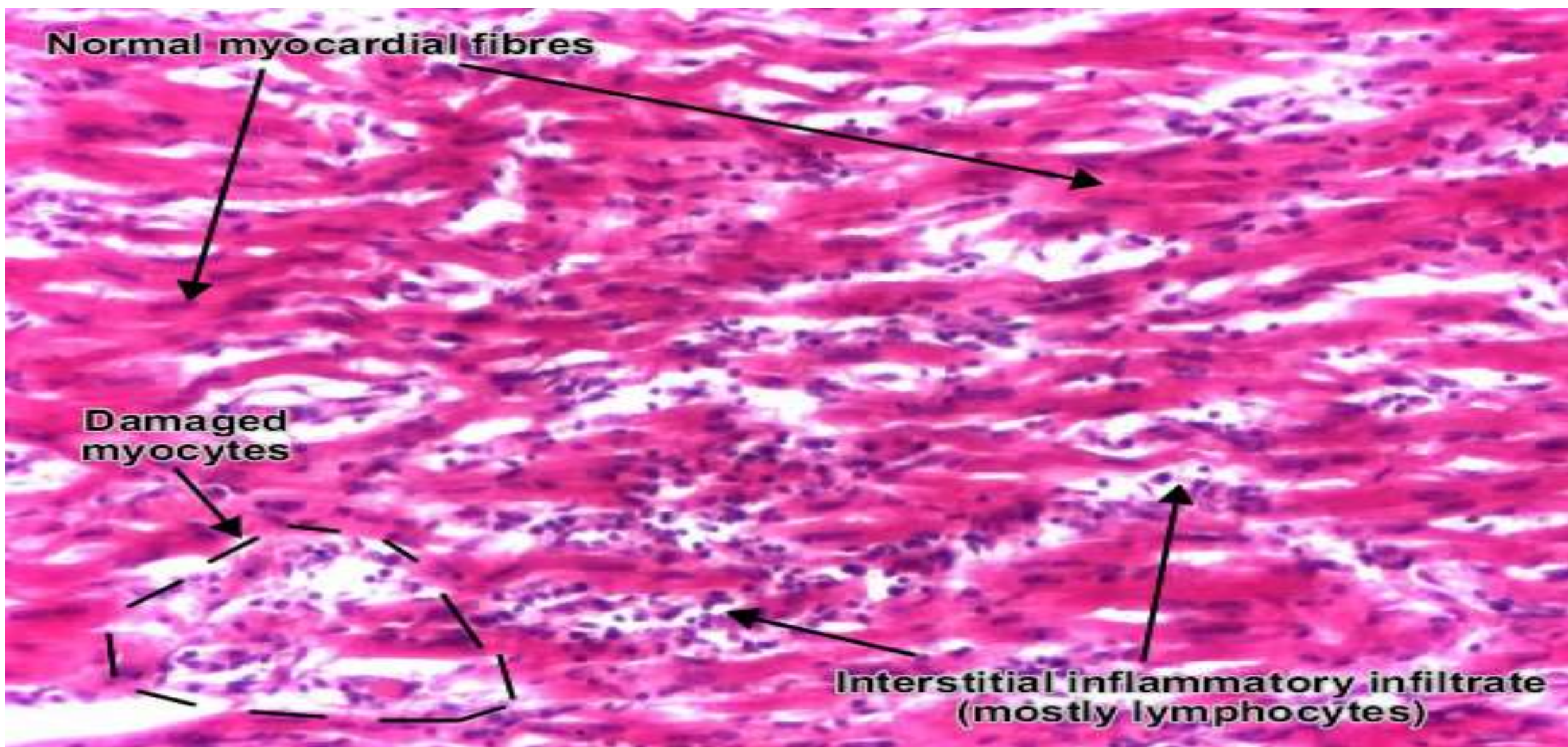
Quantification should be made by immunohistochemistry.

Necrosis or degeneration are usually not evident, fibrosis may be absent or present and should be graded.

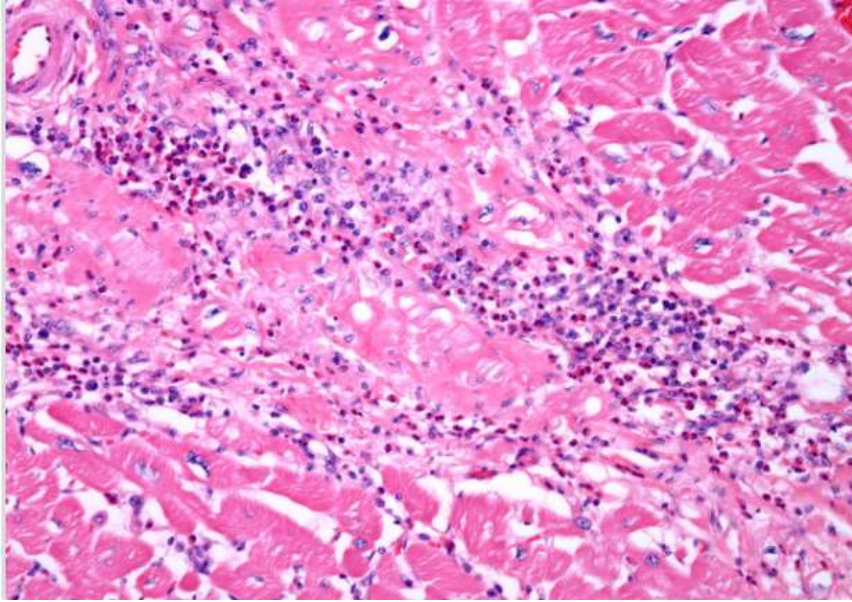
No myocarditis: No infiltrating cells or <14 leukocytes/mm .

When to consider biopsy?

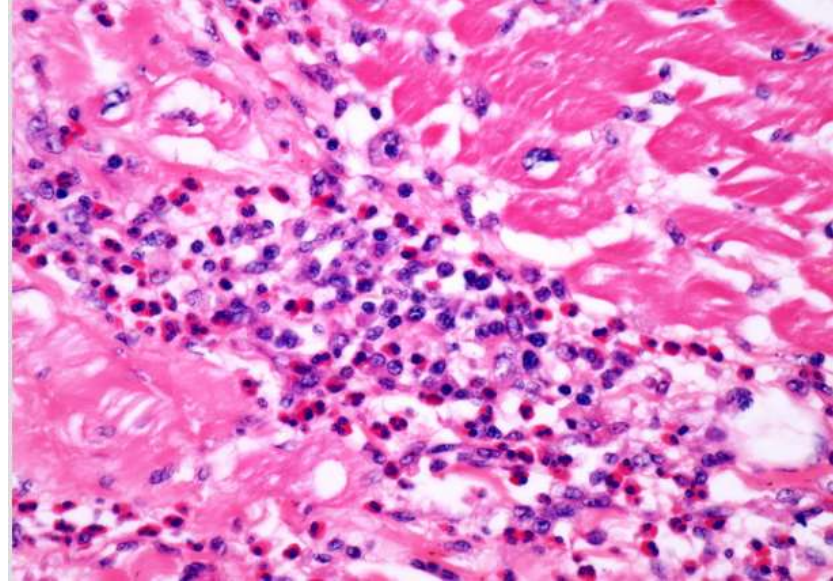
- 1) Acute heart failure with symptoms refractory to current medical management
- 2) Rapidly decreasing LVEF with no clear etiology despite conventional therapy of the HF
- 3) HF with acutely worsening rhythmic disturbance, particularly VT
- 4) HF in the setting of peripheral eosinophilia, rash, and fever
- 5) HF in the setting of clinical history and/or features of secondary causes where endomyocardial biopsy may change or modify therapy
- 6) Collagen vascular diseases: systemic lupus erythematosus, scleroderma, Marfan syndrome, polyarthritis nodosum, dermatomyositis, polymyositis
- 7) Infiltrative and storage disease (amyloid, sarcoid, hemochromatosis, Giant cell myocarditis, neoplasias,



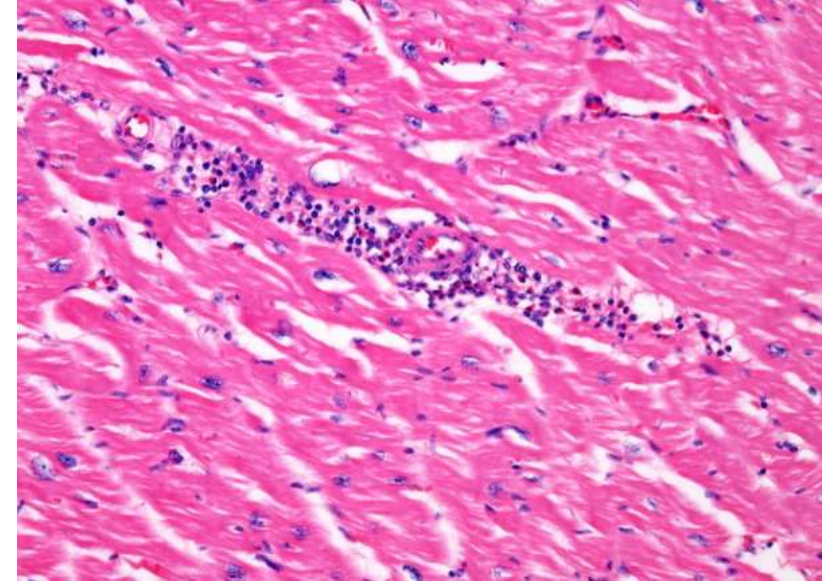
Myocarditis is an inflammation of the myocardium. Acute viral myocarditis is produced most often by *Coxsackie B virus* and *echoviruses*. Myocardial interstitium presents an abundant edema and inflammatory infiltrate, mainly with lymphocytes and macrophages. Focal destruction of myocytes may be present, generating loss of contractile function of the myocardium. (H&E, ob. x10)



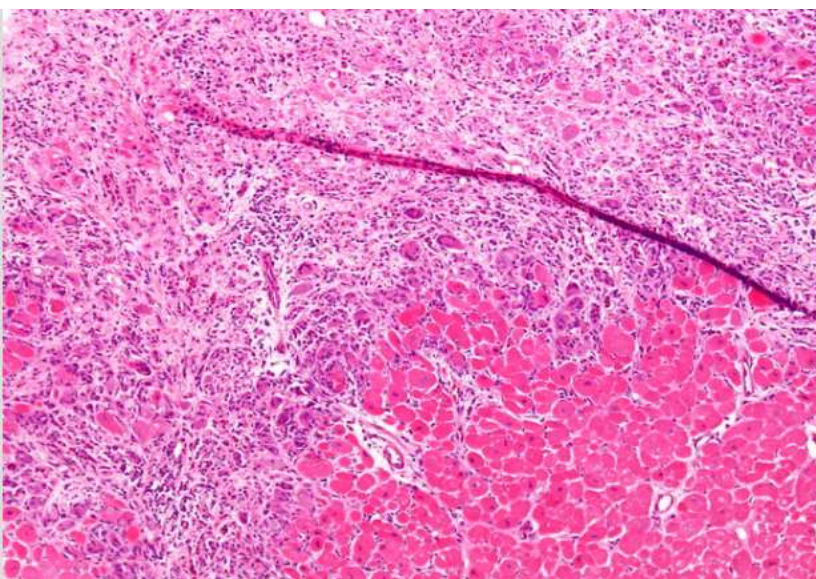
Eosinophils predominate in the inflammatory infiltrate in this image. Myocyte destruction is not prominent. Eosinophilic myocarditis is often drug-induced and may also be seen in up to 20% of explanted heart of cardiac transplant patients.



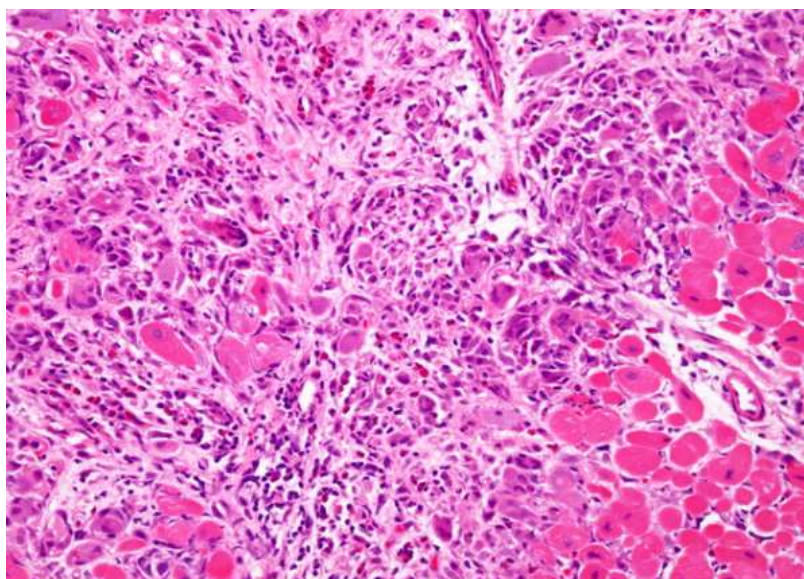
Higher magnification shows numerous eosinophils admixed with a few lymphocytes and histiocytes. Myocytes appear to have minimal damage.



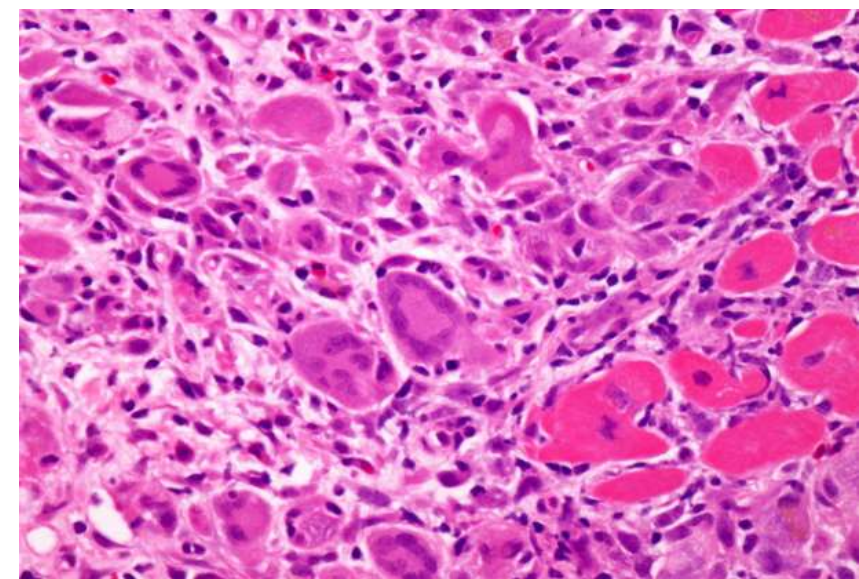
Eosinophilic myocarditis shows predominantly perivascular infiltrate (as seen here) rich in eosinophils. There is minimal damage to the myocytes. The pathogenesis of eosinophilic myocarditis includes both immediate and delayed hypersensitivity reactions. The diagnosis requires the presence of histopathologic changes on EMB biopsy. Treatment usually consists of removing the offending drug/agent, immunosuppression with steroids, and treatment of heart failure, if present.



Idiopathic Giant Cell Myocarditis) characterized by cytotoxic T-cell mediated destruction of cardiac myocytes. The disease often pursues a fulminant course and can cause death within months of diagnosis unless the patient receives heart transplantation. Extensive destruction of myocytes and an inflammatory infiltrate rich in multinucleated giant cells, lymphocytes, eosinophils, and histiocytes.



Multinucleated giant cells, lymphocytes, eosinophils, and histiocytes along with loss of myocardial fibers.



Multinucleated giant cells can be better appreciated in this high magnification view. The diagnosis requires an EMB. There is no cure. Treatment usually consists of immunosuppressive therapy whose aim is to delay the eventual need for cardiac transplantation. Giant cell myocarditis recurs in the transplanted heart in about 25% of cases.

Stages of diagnostic evaluation

Clinical suspicion of myocarditis



ECG, ECO, RMC, Biomarkers of inflammation, necrosis, infectious and autoimmune diseases



EMB



Cardiac catheterization with negative coronary artery disease: coronary stenosis $\geq 50\%$)



RV=EMB



Histological analysis + immunohistochemistry + viral research

Prognosis

The clinical manifestations of myocarditis include a wide spectrum of conditions, ranging from asymptomatic (subclinical) forms to fulminant cases leading to intractable cardiogenic shock requiring heart transplantation, or death (**Magnani 2006**). Myocarditis development and course in the context of an infection depends on the cardiotropism and cardiotoxicity of the infective agent (most often virus), environmental factors and the genetic predisposition of the host (**Feldman 2000**). The outcome of acute myocarditis is influenced by several factors including etiology clinical presentation, laboratory, electrocardiographic and imaging study findings, as well as EMB findings. Lymphocytic myocarditis are frequently subclinical. The condition resolves spontaneously with no known sequelae. In a small percentage, mostly children and young adults, the myocarditis presents as acute-onset fulminant disease and may progress rapidly to SD. In these cases, the infiltrates are usually diffuse. Another subset of patients who develop CHF may have late morbidity related to the degree of LV dysfunction. Cases of giant-cell myocarditis are usually severe, with a higher death within a short time. Heart transplantation in association with immunosuppressive therapy is one of the only ways of saving most of these patients. Hypersensitivity myocarditis and HF can improve and heal if the offending drug is discontinued, but some patients may require heart transplantation. More frequently, the pathologist sees incidental hypersensitivity myocarditis at autopsy or in an explant from an asymptomatic patient. In heart transplant patients, who are often on multiple medications, the incidence of this condition is 7% as diagnosed histologically in the explanted heart (**Gravanis 1991**).

The prognosis of pericarditis with concomitant myocarditis, especially in the setting of troponin elevation, is a reason for concern because it could imply an adverse outcome. Myopericarditis has a good overall prognosis. Troponin elevation in this setting does not predict an adverse outcome in most cases. Thus it is important to reassure the patients on their prognosis, explaining the nature of the disease and the likely course. Diagnostic and therapeutic choices should take into account the overall good outcome of these patients, including less invasive diagnostic tools and toxic drugs (**Imazio 2014**).

Management of HF and potentially fatal arrhythmias is the main clinical challenge in acute and fulminant myocarditis.

LBBB in NYHA classes II–IV (**McMurray 2012**). As LV function may improve over time in patients with inflammatory cardiomyopathy due to the natural course of the disease and/or appropriate HF therapy, implantation of an ICD/CRT-D should not be indicated prematurely.

Patients with fulminant myocarditis have a high acute mortality and a severe risk of life-threatening refractory ventricular tachyarrhythmias. In patients who initially present with an HF syndrome suggestive of first DCM manifestation and in whom possible or probable acute myocarditis is suspected, supportive measures with a recommendation to avoid exercise and use of pharmaceutical treatment with neurohormonal blockade with ACE inhibitors and beta-blockers is recommended. Progressive wall motion abnormalities with deteriorating LV function on echocardiography, persistent or fluctuating cardiac troponin concentrations, widening of the QRS complex and frequent non-SVT may precede a SVT in the setting of acute myocarditis (**JCS Joint Working Group 2011; Ukena 2011**). Patients with VA or heart block in the setting of acute myocarditis need prolonged ECG monitoring and must be admitted to hospital. Lyme's disease and diphtheria myocarditis are frequently associated with various degrees of heart block, which can also trigger VTs. Thus temporary pacemaker insertion is recommended in patients with acute myocarditis who present with symptomatic heart block (as with other causes of acute symptomatic heart block). Pacing is recommended in patients with symptomatic sinus node dysfunction or AV block following myocarditis (as with other causes of sinus or AV node dysfunction). Ventricular tachyarrhythmias triggered by high-degree AV block require temporary pacemaker insertion. If persistent AV blocks develop, permanent pacing is recommended. However, device selection should reflect the presence, extent and prognosis (progression or regression) of LV dysfunction in order to appropriately choose a pacemaker or ICD with or without cardiac resynchronization capability. Owing to the adverse prognosis of patients with giant cell myocarditis or sarcoidosis, the implantation of an impulse generator may be considered earlier in these patients (**Liberian 2014**). Fulminant myocarditis is a distinct clinical entity with an adverse short-term but a relatively good long-term prognosis. Refractory SVTs are typical for the fulminant form of myocarditis. According to a Japanese registry, the short-term survival rate of patients with fulminant myocarditis is only 58% (**Aoyama 2002; Kohno 2000**). VTs were the most common SVTs in 2148 children with acute myocarditis, accounting for 76% of 314 cases with arrhythmias during the course of the disease. Patients with SVTs had a very high risk of cardiac arrest, need for mechanical circulatory support and/or death compared with patients without arrhythmias (**Liberian 2014**). Giant cell myocarditis is a severe form of myocarditis with a dramatic clinical course, frequently affecting young patients. The diagnosis is confirmed by EMB showing the presence of typical multinucleated giant cells in inflammatory lesions. Patients may develop heart AV block, requiring placement of temporary or permanent pacemakers. However, refractory electrical storms with incessant VT or VF have a particularly adverse prognosis despite the use of aggressive anti-arrhythmic drug therapy. Surprisingly, in a retrospective study among adult patients after acute myocarditis, those with the fulminant form had a better long-term prognosis than patients with non-fulminant. After 11 years, 93% of patients with fulminant myocarditis were alive without heart transplantation

compared with only 45% with the non-fulminant type (**McCarthy 2000**). Aggressive hemodynamic support using percutaneous cardiopulmonary support or an intra-aortic balloon pump in addition to drug therapy is recommended for patients with fulminant myocarditis to bridge the dramatic but often curable acute stage of the disease. Percutaneous cardiopulmonary support should be initiated if refractory VT/VF does not respond to three to five defibrillation attempts (**JCS Joint Working Group 2011**). The association between undiagnosed myocarditis and SD is emphasized by post-mortem data, which have implicated myocarditis in SD of young adults at rates of 8.6–44% (**Fabre 2006**). Data on the causative agents are rare. Chlamydia myocarditis was implicated in the SD of 5 of 15 young Swedish elite athletes following the identification of chlamydial RNA in their hearts (**Wesslen 1996**). During the acute phase, ICD should be deferred until resolution of the acute phase. Because myocarditis may heal completely, the indication for ICD implantation and its timing remain controversial even beyond the acute stage. Bridging the critical period to full recovery by a wearable cardioverter-defibrillator (WCD) vest in patients with myocarditis and VT/VF is a promising therapeutic option (**Chung 2014**). The presence of malignant AV block in giant cell myocarditis or cardiac sarcoidosis might warrant earlier consideration of an ICD due to the known high risk of arrhythmic death or need for transplantation (**Kandolin 2013**).

Myocarditis leading to inflammatory cardiomyopathy: Myocarditis has been identified as a cause of DCM in up to 10% of cases in large prospective series. Inflammatory cardiomyopathy is involved in the pathogenesis of DCM, with a poor prognosis. In long-term follow-up studies after acute myocarditis, DCM developed in 21% (**D'Ambrosio 2001**). On the other hand, a viral genome was identified in the myocardium of 65% of patients with ‘idiopathic’ LV dysfunction. Persisting cardiac viral infections may constitute a major cause of progressive LV HF in patients with DCM and with a suspicion of prior myocarditis (**Kuhl 2005**). However, these observations were not confirmed by Kindermann et al. (**Kindermann 2008**), who identified immunohistological evidence of inflammatory infiltrates in the myocardium as the primary factor associated with a three-fold or greater increase in risk of cardiac death or heart transplantation. Over 5 years of follow-up, 61% of patients in NYHA class III or IV with positive immunohistology and not receiving β -blocker therapy died or underwent heart transplantation (**Kindermann 2008**). In patients with documented symptomatic SVT of unclear etiology, myocarditis should also be suspected and a CMR scan may reveal abnormal fibrotic myocardial tissue, frequently located in subepicardial and intramural regions. In a cohort of 405 patients with suspected myocarditis, all of the patients who died suddenly or experienced aborted SD or ICD discharge had abnormal CMR scans (**Schumm 2014**). Successful RFCA of epicardial arrhythmogenic foci in myocarditis has been described recently (**Mazzone 2013**). Drug treatment of arrhythmias in patients with inflammatory heart disease does not differ from generally principles. Arrhythmia management outside the acute phase should be in line with current ESC guidelines on arrhythmia and device implantation in chronic HF management (**McMurray 2012**). The indications for an ICD in inflammatory cardiomyopathy are the same as for non-ischemic DCM. As in secondary prevention of SD, an ICD in patients with myocarditis is recommended after cardiac arrest due to VF or after symptomatic VT. CRT-D is recommended as primary prevention in patients with LVEF <35%

References

1. Agewall S, Beltrame JF, Reynolds HR, et al. ESC working group position paper on myocardial infarction with non-obstructive coronary arteries. *Eur Heart J*. 2017;38:143–53.
2. Antonarakis ES, Wung PK, Durand DJ, Leyngold I, Meyerson DA. An atypical complication of atypical pneumonia. *Am J Med*. 2006;119:824–7.
3. Anzini M, Merlo M, Sabbadini G, et al. Long-term evolution and prognostic stratification of biopsy-proven active myocarditis. *Circulation*. 2013;128(22):2384-94.
4. Aoyama N, Izumi T, Hiramori K, et al. National survey of fulminant myocarditis in Japan: therapeutic guidelines and long-term prognosis of using percutaneous cardiopulmonary support for fulminant myocarditis (special report from a scientific committee). *Circ J* 2002;66:133–144.
5. Aretz HT, Billingham ME, Edwards WD, et al. Myocarditis. a histopathologic definition and classification. *Am J Cardiovasc Pathol*. 1987;1(1):3–14.
6. Bayés de Luna A, Rovai D, Pons Llado G, et al. The end of an electrocardiographic dogma: a prominent R wave in V1 is caused by a lateral not posterior myocardial infarction-new evidence based on contrast-enhanced cardiac magnetic resonance-electrocardiogram correlations. *Eur Heart J*. 2015;36(16):959-64.
7. Baughman KL. Diagnosis of myocarditis: death of Dallas criteria. *Circulation*. 2006; 113(4):593-5.
8. Biesbroek PS, Beek AM, Germans T, Niessen HW, van Rossum AC. Diagnosis of myocarditis: Current state and future perspectives. *Int J Cardiol*. 2015;191:211-9.
9. Birnie DH, Nery PB, Ha AC, et al. Cardiac sarcoidosis. *J Am Coll Cardiol*. 2016;68(4):411-21.
10. Bourgeois GP, Cafardi JA, Groysman V, Hughey LC. A review of DRESS-associated myocarditis. *J Am Acad Dermatol*. 2012;66(6):e229-36.
11. Bracamonte-Baran W, Čiháková D. Cardiac Autoimmunity: Myocarditis. *Adv Exp Med Biol*. 2017;1003:187-221.
12. Caforio AL, Goldman JH, Haven AJ, Baig KM, Libera LD, McKenna WJ. Circulating cardiac-specific autoantibodies as markers of autoimmunity in clinical and biopsy-proven myocarditis. The Myocarditis Treatment Trial Investigators. *Eur Heart J*. 1997;18:270–5.
13. Caforio AL, Pankuweit S, Arbustini E, et al. Current state of knowledge on aetiology, diagnosis, management, and therapy of myocarditis: a position statement of the European Society of Cardiology Working Group on Myocardial and Pericardial Diseases. *Eur Heart J*. 2013;34:2636–2648.
14. Caforio AL, Marcolongo R, Basso C, Iliceto S. Clinical presentation and diagnosis of myocarditis. *Heart*. 2015;101:1332–44.

15. Campuzano O, Fernández-Falgueras A, Sarquella-Brugada G, et al. A genetically vulnerable myocardium may predispose to myocarditis. *J Am Coll Cardiol*. 2015; 66(25):2913-4.
16. Chung MK. The role of the wearable cardioverter defibrillator in clinical practice. *Cardiol Clin*. 2014;32:253–270.
17. D'Ambrosio A, Patti G, Manzoli A, et al. The fate of acute myocarditis between spontaneous improvement and evolution to dilated cardiomyopathy: a review. *Heart*. 2001;85:499–504.
18. Dello Russo A, Casella M, Pieroni M, et al. Drug-refractory ventricular tachycardias after myocarditis: endocardial and epicardial radiofrequency catheter ablation. *Circ Arrhythm Electrophysiol*. 2012 ;5(3):492-8.
19. de Luna AB, Cino J, Goldwasser D, et al. New electrocardiographic diagnostic criteria for the pathologic R waves in leads V1 and V2 of anatomically lateral myocardial infarction. *J Electrocardiol*. 2008;41(5):413-418.
20. Dieval C, Deligny C, Meyer A, et al. Myocarditis in patients with antisynthetase syndrome: prevalence, presentation, and outcomes. *Medicine (Baltimore)*. 2015;94:e798.
21. Doti PI, Escoda O, Cesar-Díaz S, et al. Congenital heart block related to maternal autoantibodies: descriptive analysis of a series of 18 cases from a single center. *Clin Rheumatol*. 2016;35(2):351-6.
22. Eckart RE, Shry EA, Burke AP, et al. Sudden death in young adults: an autopsy-based series of a population undergoing active surveillance. *J Am Coll Cardiol* 2011;58:1254–1261.
23. Escher F, Kühl U, Gross U, et al. Aggravation of left ventricular dysfunction in patients with biopsy-proven cardiac human herpesvirus A and B infection. *J Clin Virol*. 2015;63:1–5.
24. Fabre A, Sheppard MN. Sudden adult death syndrome and other non-ischaemic causes of sudden cardiac death. *Heart*. 2006;92:316–320.
25. Feldman AM, McNamara D. Myocarditis. *N Engl J Med*. 2000;343:1388-1398.
26. Felker GM, Boehmer JP, Hruban RH, et al. Echocardiographic findings in fulminant and acute myocarditis. *J Am Coll Cardiol*. 2000;36:227–32.
27. Ferreira VM, Piechnik SK, Dall'Armellina E, et al. T(1) mapping for the diagnosis of acute myocarditis using CMR: comparison to T2-weighted and late gadolinium enhanced imaging. *JACC Cardiovasc Imag*. 2013;6:1048–58.
28. Friedrich MG, Sechtem U, Schulz-Menger J, et al. Cardiovascular magnetic resonance in myocarditis: A JACC White Paper. *J Am Coll Cardiol*. 2009;53:1475–87.
29. Gravanis MB, Hertzler GL, Franch RH, et al. Hypersensitivity myocarditis in heart transplant candidates. *J Heart Lung Transplant*. 1991;10(5 Pt 1):688-97.

30. Greaves K, Oxford JS, Price CP, et al. The prevalence of myocarditis and skeletal muscle injury during acute viral infection in adults: measurement of cardiac troponins I and T in 152 patients with acute influenza infection. *Arch Intern Med.* 2003;163:163(2):165-8.
31. Goldwasser D, Senthilkumar A, Bayés de Luna A, et al. Lateral MI Explains the Presence of Prominent R Wave ($R \geq S$) in V1. *Ann Noninvasive Electrocardiol.* 2015;20(6):570-577.
32. Hékimian G, Combes A. Myocarditis. *Rev Med Interne.* 2017;38(8):531-538.
33. Imazio M, Brucato A, Spodick DH, Adler Y. Prognosis of myopericarditis as determined from previously published reports. *J Cardiovasc Med (Hagerstown).* 2014;15(12):835-9.
34. Ison MG, Campbell V, Rembold C, et al. Cardiac findings during uncomplicated acute influenza in ambulatory adults. *Clin Infect Dis.* 2005;40(3):415-22.
35. JCS Joint Working Group. Guidelines for diagnosis and treatment of myocarditis (JCS 2009): digest version. *Circ J* 2011;75:734–743.
36. Johnson DB, Balko JM, Compton ML, et al. Fulminant myocarditis with combination immune checkpoint blockade. *N Engl J Med.* 2016;375(18):1749-55.
37. Kandolin R, Lehtonen J, Salmenkivi K, Raisanen-Sokolowski A, Lommi J, Kupari M. Diagnosis, treatment, and outcome of giant-cell myocarditis in the era of combined immunosuppression. *Circ Heart Fail.* 2013;6:15–22.
38. Kindermann I, Kindermann M, Kandolf R, et al. Predictors of outcome in patients with suspected myocarditis. *Circulation* 2008;118:639–648.
39. Kindermann I, Barth C, Mahfoud F, .Update on myocarditis. *J Am Coll Cardiol.* 2012;59(9):779-92.
40. Kohno K, Aoyama N, Shimohama T, et al. Resuscitation from fulminant myocarditis associated with refractory ventricular fibrillation. *Jpn Circ J.* 2000;64:139–143.
41. Kuhl U, Pauschinger M, Seeberg B, et al. Viral persistence in the myocardium is associated with progressive cardiac dysfunction. *Circulation.* 2005;112:1965–1970.
42. Lauer B, Niederau C, Kühl U, et al. Cardiac troponin T in patients with clinically suspected myocarditis. *J Am Coll Cardiol.* 1997;30:1354–9.
43. Leone O, Veinot JP, Angelini A, et al. 2011 consensus statement on endomyocardial biopsy from the Association for European Cardiovascular Pathology and the Society for Cardiovascular Pathology. *Cardiovasc Pathol.* 2012;21: (4):245-74,
44. Liberman L, Anderson B, Silver ES, Singh R, Richmond ME. Incidence and characteristics of arrhythmias in pediatric patients with myocarditis: a multicenter study. *J Am Coll Cardiol.* 2014;63:A483.
45. Liu QN, Reddy S, Sayre JW, Pop V, Graves MC, Fiala M. Essential role of HIV type 1-infected and cyclooxygenase 2-activated macrophages and T cells in HIV type 1 myocarditis. *AIDS Res Hum Retroviruses.* 2001;17:1423–1433.

46. Lumsden RH, Bloomfield GS. The causes of HIV-associated cardiomyopathy: a tale of two worlds. *Biomed Res Int.*;2016;8196560.
47. Lurz P, Eitel I, Adam J, et al. Diagnostic Performance of CMR Imaging Compared With EMB in Patients With Suspected Myocarditis. *Jacc-Cardiovascular Imaging* 2012;5(5):513-24.
48. Magnani J, Dec W. Myocarditis: Current Trends in Diagnosis and Treatment. *Circulation*. 2006;113(6):876-890.
49. Mankad R, Bonnicksen C, Mankad S. Hypereosinophilic syndrome: cardiac diagnosis and management. *Heart*. 2016;102:100–6.
50. Mazzone P, Tsiachris D, Della Bella P. Epicardial management of myocarditis-related ventricular tachycardia. *Eur Heart J*. 2013;34:244.
51. McCarthy RE3rd, Boehmer JP, Hruban RH, et al. Long-term outcome of fulminant myocarditis as compared with acute (nonfulminant) myocarditis. *N Engl J Med*. 2000;342:690–695.
52. McMurray JJ, Adamopoulos S, Anker SD, et al. ESC Guidelines for the diagnosis and treatment of acute and chronic heart failure 2012: The Task Force for the Diagnosis and Treatment of Acute and Chronic Heart Failure 2012 of the European Society of Cardiology. Developed in collaboration with the Heart Failure Association (HFA) of the ESC. *Eur Heart J*. 2012;33:1787–1847.
53. Mohammed AG, Alghamdi AA, ALjahlan MA, Al-Homood IA. Echocardiographic findings in asymptomatic systemic lupus erythematosus patients. *Clin Rheumatol*. 2017;36(3):563-568.
54. Nagatomo Y, TangWH. Autoantibodies and cardiovascular dysfunction: cause or consequence? *Curr Heart Fail Rep*. 2014; 11(4):500-8.
- Richardson P, McKenna W, Bristow M, et al. Report of the 1995 World Health Organization/International Society and Federation of Cardiology Task Force on the Definition and Classification of Cardiomyopathies. *Circulation*. 1996;93:841–842.
55. Pinto YM, Elliott PM, Arbustini E, et al. Proposal for a revised definition of dilated cardiomyopathy and its implications for clinical practice: a position statement of the ESC Working Group on myocardial and pericardial diseases. *Eur Heart J*. 2016;37:1850–8.
56. Prasad M, Hermann J, Gabriel SE, et al. Cardiorheumatology: cardiac involvement in systemic rheumatic disease. *Nat Rev Cardiol*. 2015;12:168–76.
57. Rose NR. Myocarditis: infection versus autoimmunity. *J Clin Immunol*. 2009;29(6):730-7.
58. Rosenstein ED, Zucker MJ, Kramer N. Giant cell myocarditis: most fatal of autoimmune diseases. *Semin Arthritis Rheum*. 2000;30(1):1-16.
59. Russo Andrea M, Stainback Raymond F, et al. ACCF/HRS/AHA/ASE/HFSA/SCAI/SCCT/SCMR 2013 appropriate use criteria for implantable cardioverter-defibrillators and cardiac resynchronization therapy: a report of the American College of Cardiology Foundation appropriate use criteria task force, Heart Rhythm Society, American Heart Association, American Society of Echocardiography, Heart Failure Society of America, Society for Cardiovascular Angiography and Interventions, Society of Cardiovascular Computed Tomography, and Society for Cardiovascular Magnetic Resonance. *J. Am. Coll. Cardiol*. 2013;61 (12):1318–68.

60. Sagar S Liu PP Cooper LTJr. Myocarditis. *Lancet*. 2012;379(9817):738-47.
61. Savage E, Wazir T, Drake M, et al. Fulminant myocarditis and macrophage activation syndrome secondary to adult-onset Still's disease successfully treated with tocilizumab. *Rheumatology (Oxford)*. 2014; 53(7):1352-3
62. Schultz JC, Hilliard AA, Cooper Jr LT, Rihal CS. Diagnosis and treatment of viral myocarditis. *Mayo Clin Proc*. 2009;84(11):1001-9.
63. Schumm J, Greulich S, Wagner A, et al. Cardiovascular magnetic resonance risk stratification in patients with clinically suspected myocarditis. *J Cardiovasc Magn Reson*. 2014;16:14.
64. Thomas G, Cohen Aubart F, Chiche L, et al. Lupus myocarditis: initial presentation and long-term outcomes in a multicentric series of 29 patients. *J Rheumatol*. 2017;44:24–32.
65. Ukena C, Mahfoud F, Kindermann I, Kandolf R, Kindermann M, Bohm M. Prognostic electrocardiographic parameters in patients with suspected myocarditis. *Eur J Heart Fail*. 2011;13:398–405.
66. Wesslen L, Pahlson C, Lindquist O, et al. An increase in sudden unexpected cardiac deaths among young Swedish orienteers during 1979–1992. *Eur Heart J*. 1996;17:902–910.
67. Wojnicz R, Nowalany-Kozielska E, Wodniecki J, et al. Immunohistological diagnosis of myocarditis. potential role of sarcolemmal induction of the MHC and ICAM-1 in the detection of autoimmune mediated myocyte injury. *Eur Heart J*. 1998;19: (10):1564-72.
68. Zhang W, Lavine KJ, Epelman S, et al. Necrotic myocardial cells release damage-associated molecular patterns that provoke fibroblast activation in vitro and trigger myocardial inflammation and fibrosis in vivo. *J Am Heart Assoc*. 2015; 4(6):e001993.