

An unusual ECG behavior in the Acute Coronary Syndrome scenario



<https://ekgvcg.wordpress.com/>

- Raimundo **Barbosa-Barros M.D**¹; Andrés Ricardo **Pérez-Riera M.D.Ph.D.**²; Luiz Carlos **de Abreu P.h.D.**³
1. Chief of the Coronary Center of the Hospital de Messejana Dr. Carlos Alberto Studart Gomes. Fortaleza –CE- Brazil
 2. Post-Graduates Advisor at Design of Studies and Scientific Writing Laboratory in the ABC Faculty of Medicine - ABC Foundation - Santo André – São Paulo – Brazil
 3. Visiting Scientist at Program in Molecular and Integrative Physiological Sciences (MIPS), Department of Environmental Health | Harvard T.H. Chan School of Public Health.

English: Case report

A 57-year-old man was admitted to the Emergency Room with history of typical constricting retrosternal chest pain of 60 minutes duration. Significant past history was positive for dyslipidemia.

The admission ECG (**Figure 1**) is showed in the next slide. The first troponin level was increased. This electrocardiographic pattern remained the same over the next 5 hours (**Figure 2**).

The patient was classified as a Non-ST Elevation acute Myocardial Infarction (NSTEMI) and treated with morphine (2mg IV), oxygen therapy, nitrates (isosorbide mononitrate 5mg), aspirin (325mg), clopidogrel (300mg), β -blocker atenolol (25mg) and enoxaparin (30mg IV). During this time he was hemodynamically stable but with persistent precordial discomfort. He was admitted to a tertiary care unit with a plan for cardiac catheterization after 24 hours.

After 13 hours the ECG (**Figure 3**) shows another pattern.

While waiting for the catheterization he developed a new episode of chest pain at which time the ECG (**Figure 4**) with new changes.

Coronary angiography is showed in the **Figure 5**. He was treated with 2 conventional coronary stents (**Figure 6**).

An echocardiogram performed later revealed the left ventricular ejection fraction of 37%.

Questions:

1. Which is the diagnosis of ECG-1 and ECG-2?
2. Which is the diagnosis of ECG-3?
3. Which is the diagnosis of ECG-4?
4. How is called this type of initial presentation without changes and its prevalence in the context of acute coronary syndrome (ACS)?
5. Was it correct our approach and why?

Português: Reporte de caso

Um homem de 57 anos foi admitido na unidade de pronto-atendimento (UPA) com historia de dor retroesternal típica de caráter constritivo, iniciada ha 60 minutos. Como fator de risco para doença arterial coronariana (DAC) referia dislipidemia.

Na admissão, realizou um eletrocardiograma (ECG-1). A primeira amostra de troponina mostrava uma discreta elevação. Esse padrão eletrocardiográfico permaneceu inalterado no ECG subsequente, realizado 5 horas mais tarde (ECG-2).

O paciente foi classificado como portador de uma síndrome coronariana aguda sem elevação do segmento ST e tratado com morfina (2mg IV), oxigênio, nitrato (mononitrato de isosorbide 5mg), aspirina (325mg), clopidogrel (300mg), β -bloqueador atenolol (25mg) e enoxaparina (30mg IV). Encontrava-se neste momento hemodinamicamente estável, porem com discreto desconforto precordial. Optou-se então por transferi-lo para uma unidade terciaria para que se pudesse realizar estudo hemodinâmico apos 24 horas.

O ECG realizado apos 13 horas (ECG-3) mostrou drástica mudança no padrão.

Enquanto aguardava a realização do cateterismo, apresentou novo episodio de dor e o ECG desta ocasião (ECG-4) com novas mudanças.

A angiografia coronariana mostrou oclusão total da artéria descendente anterior com presença de circulação colateral (Figura 5). Foi tratado com implante de dois *stents* convencionais (Figura 6). Um ecocardiograma realizado posteriormente revelou fração de ejeção do ventrículo esquerdo de 37%.

Perguntas:

1. Qual o diagnóstico dos ECG-1 e ECG-2?
2. Qual o diagnóstico do ECG-3?
3. Qual o diagnóstico do ECG-4?
4. Como se denomina este tipo de apresentação inicial sem mudanças e qual a sua prevalência no contexto da síndrome coronariana aguda?
5. Foi correta a nossa abordagem e por quê?

Figure 1 (ECG-1) - At admission

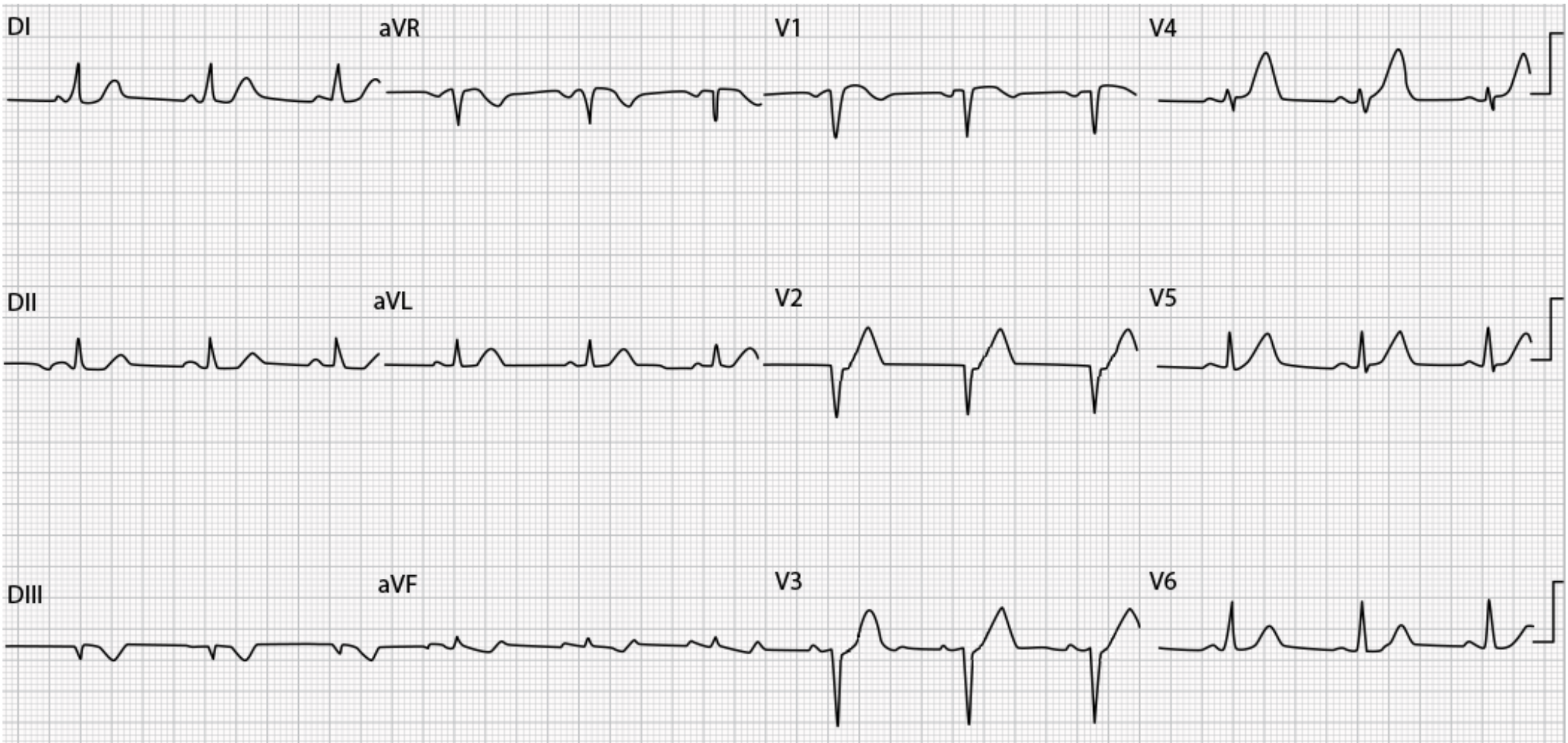


Figure 2 (ECG-2) - Performed 5 hours later

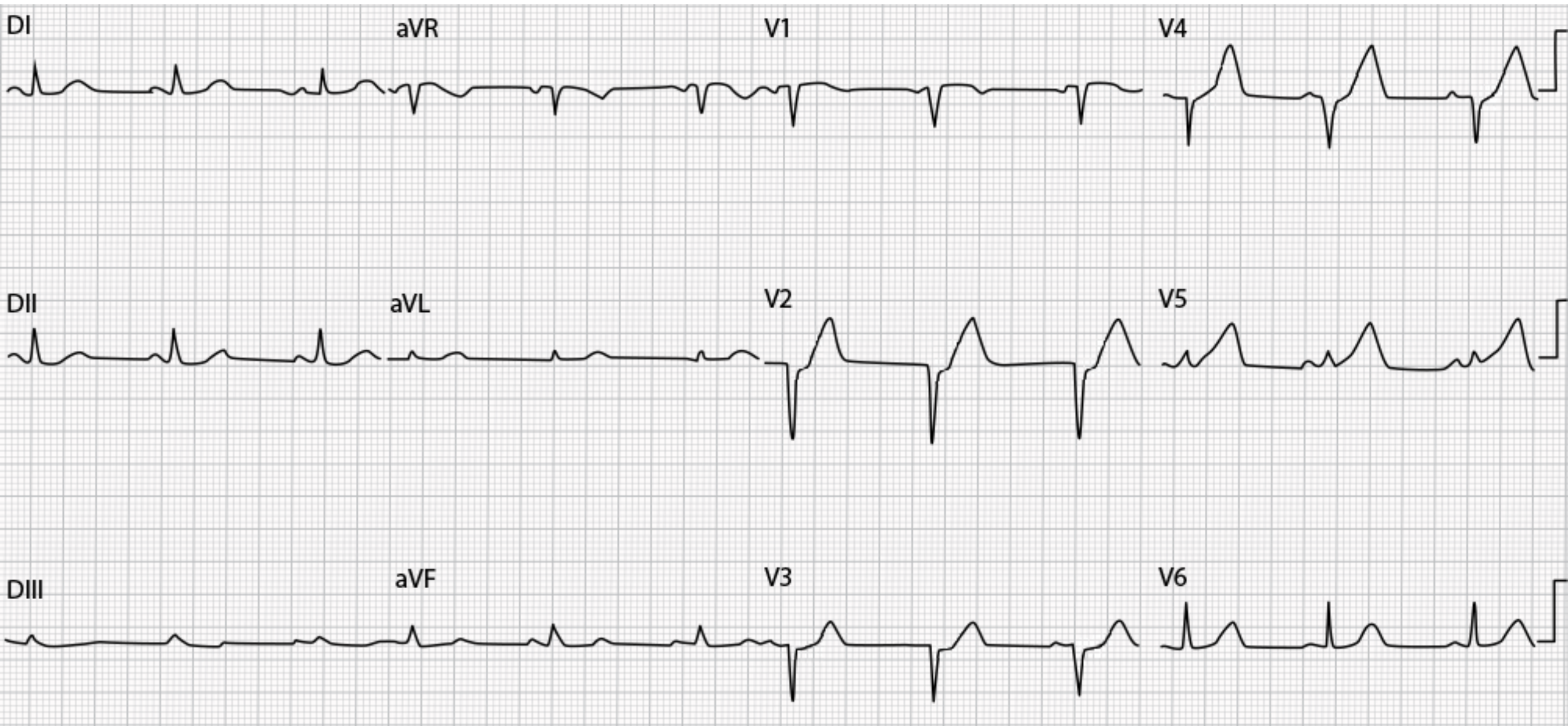


Figure 3 (ECG-3) - Performed 13 hours later

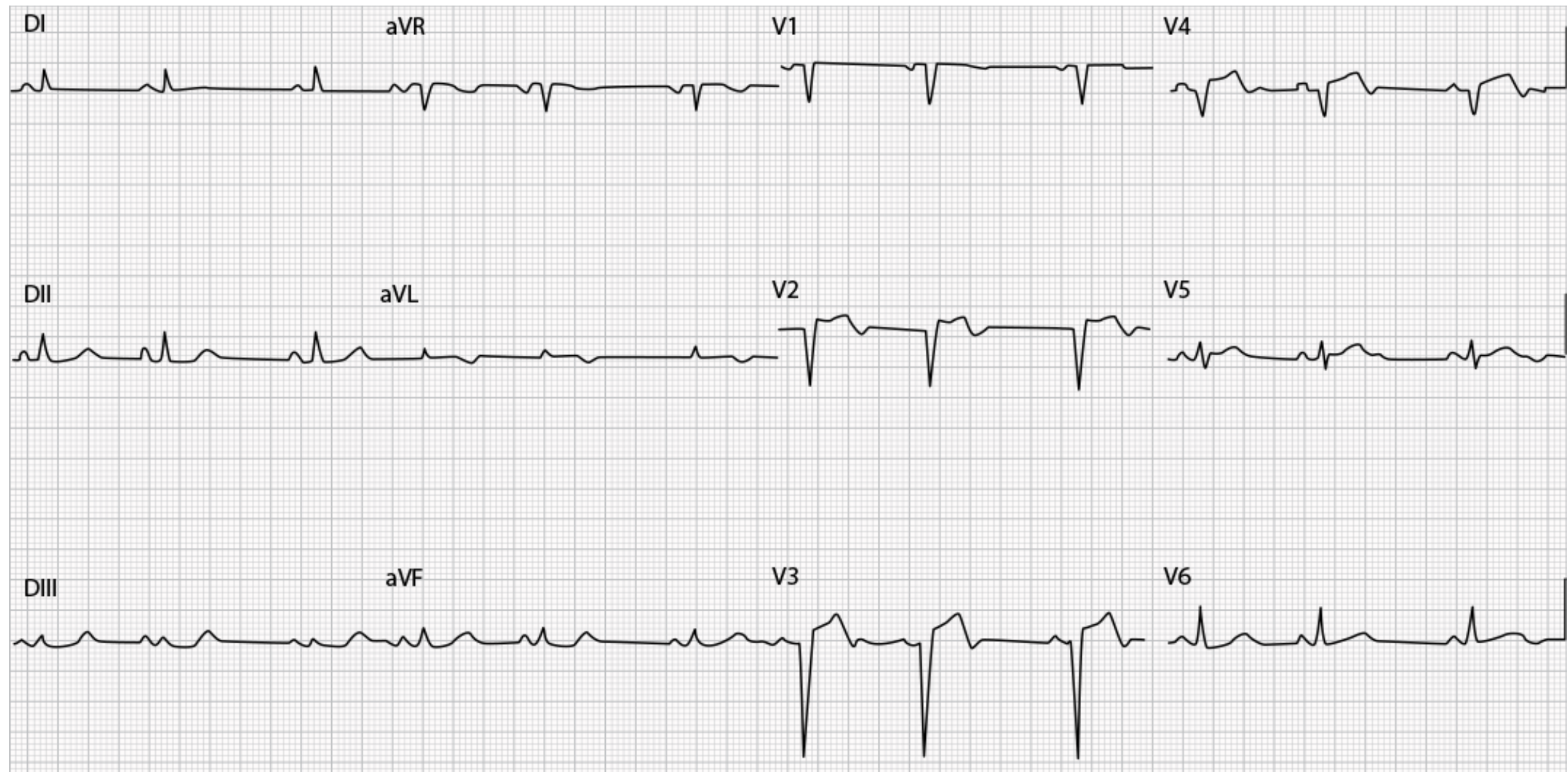


Figure 4 (ECG-4) - Performed prior to cardiac catheterization during a new episode of chest pain

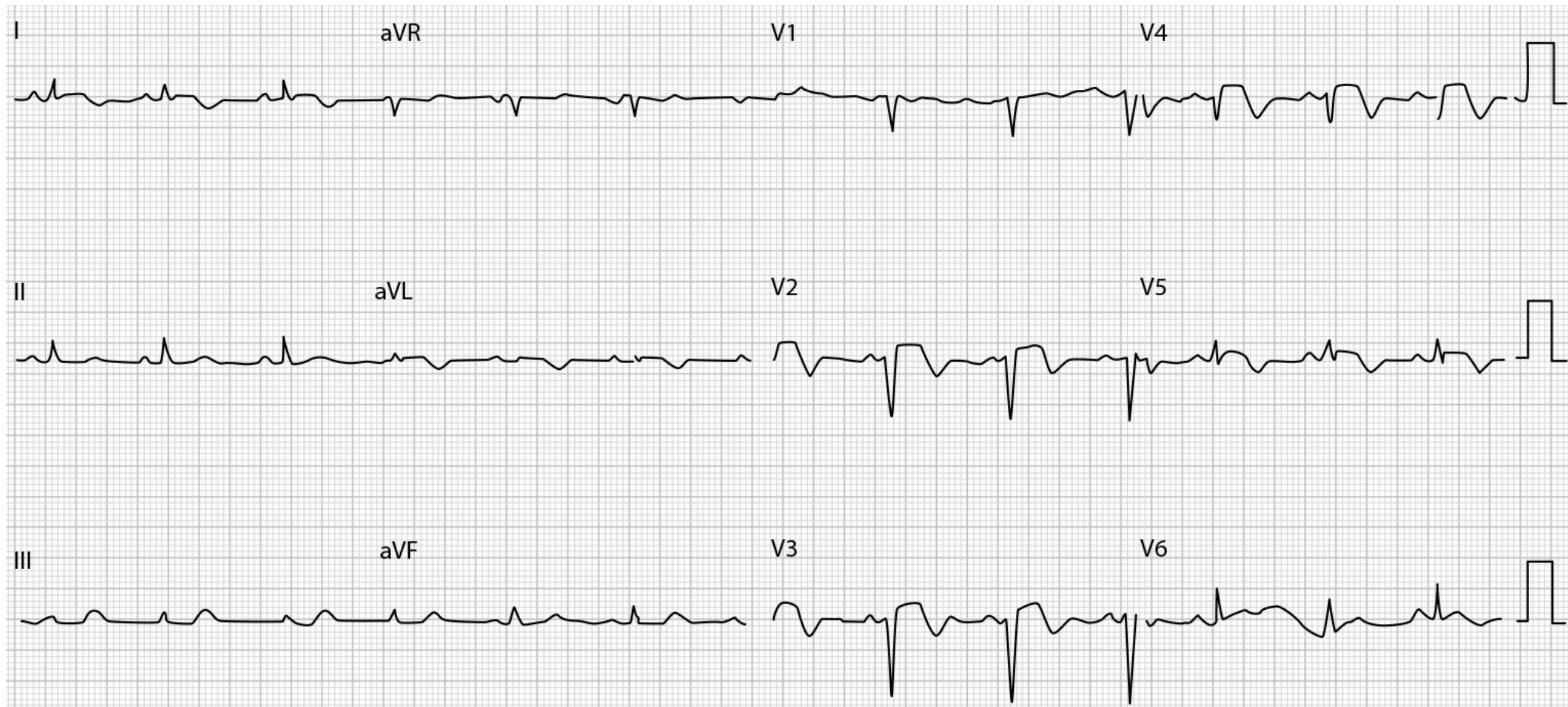
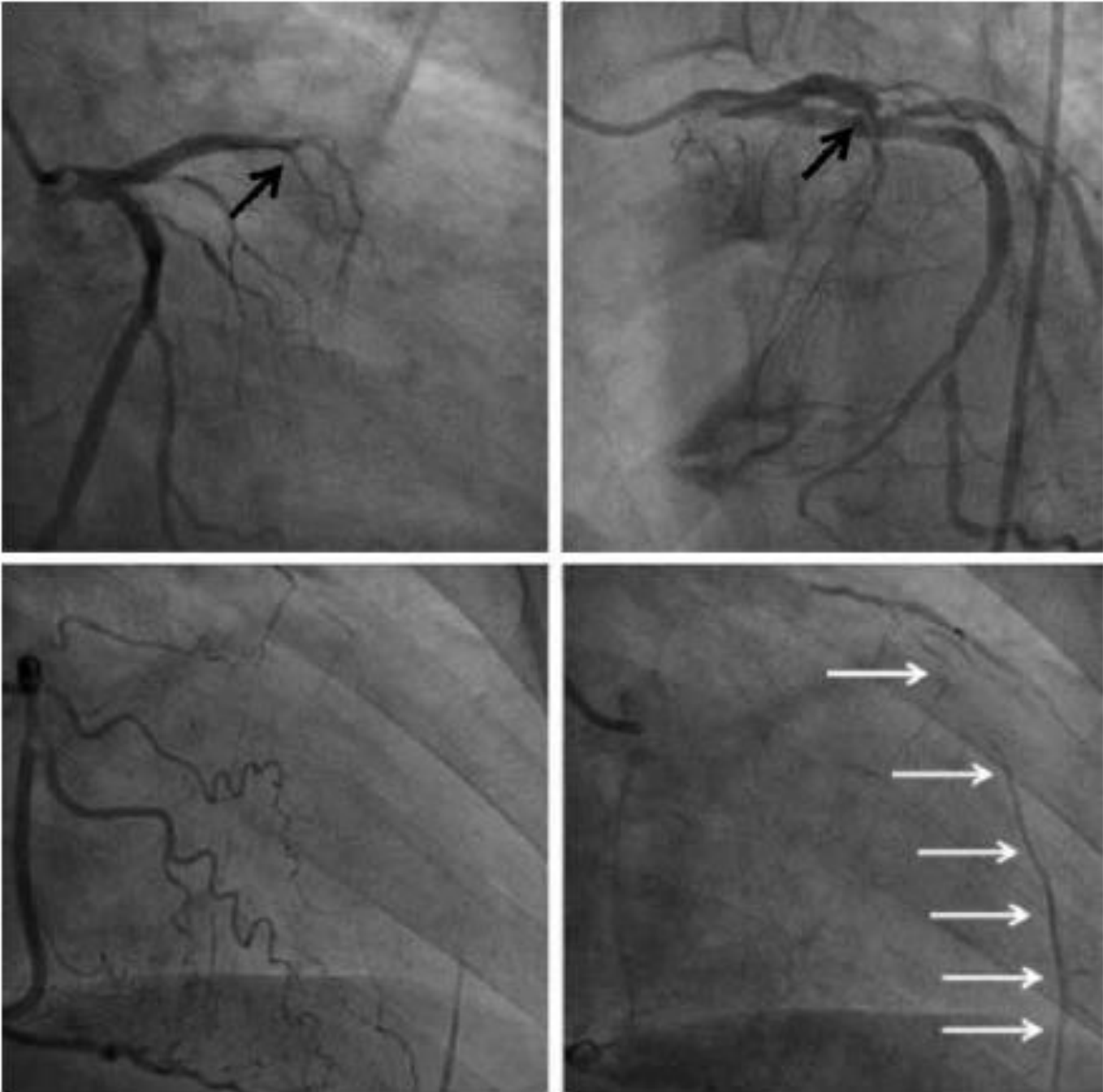
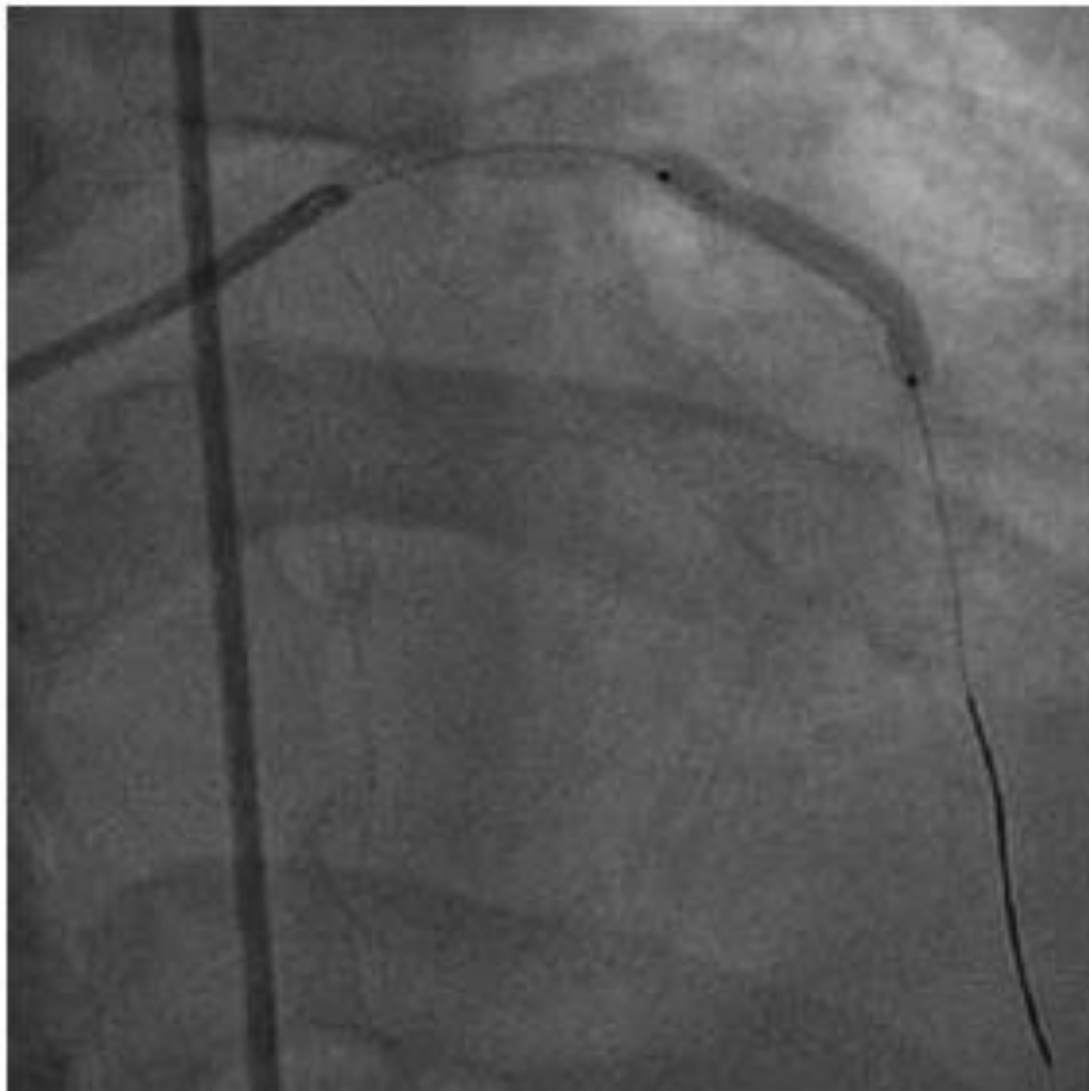

Figure 5 - Coronariography

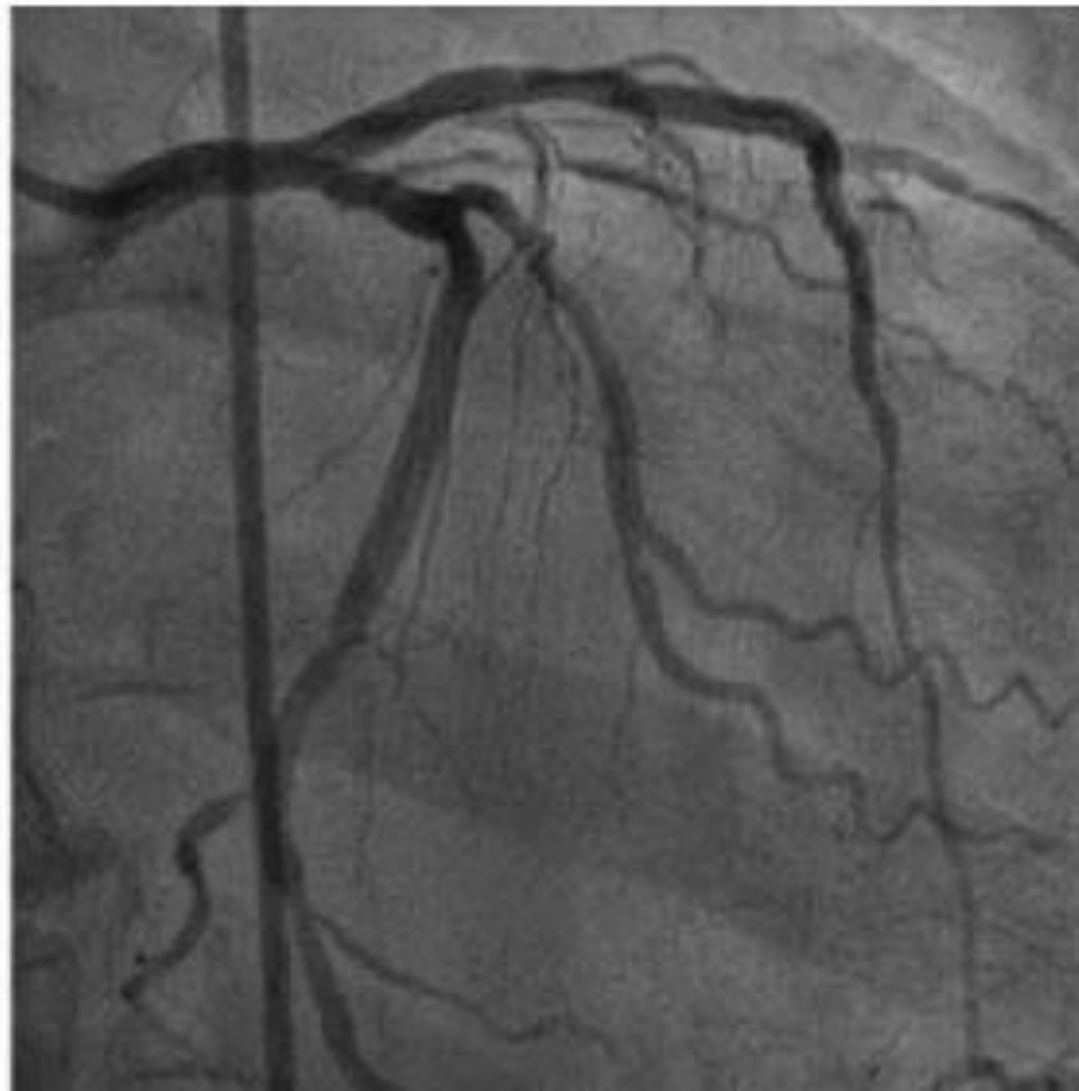

Before (A) and after (B) angioplasty and conventional stent deployment in the LAD

A



B



Colleagues opinions


The first ECG shows sinus rhythm. However, the PR of the first complex in I and V6 is relatively short and there might be a delta wave. This is an incidental finding. The major issue is Q waves in V1-V2 and upsloping ST depression with tall T waves in V2-V5 that is suggestive of acute anterior ischemia. (de Winter sign)

The fact that there is reciprocal T wave inversion in III and aVF suggests ischemia due to proximal LAD right lesion.

The second ECG also shows fluctuations in the PR interval (is the AIVR?). Now there is mild ST elevation in V5 and the T waves are no longer negative in the inferior leads.

Figure 3 and 4 shows the natural evolution of this pattern to STEMI (short LAD occlusion before the first diagonal).

Yochai Birnbaum, MD
Cardiology Houston, TX
Professor, Cardiology, Baylor College of Medicine



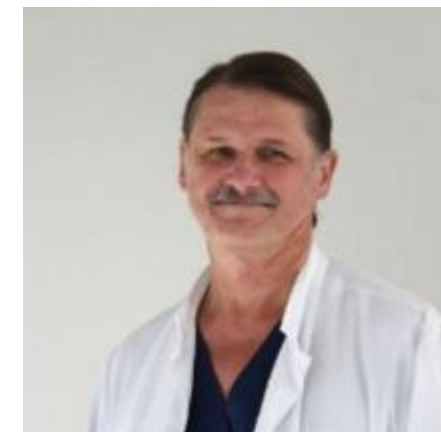My interpretation:

1. As to questions 1, 4 and 5: ECG 1 and 2 show up-sloping ST depression with prominent T waves especially in the precordial leads. There is mild J-point elevation in aVR and V1. I consider this to be the ECG pattern that was described by Pruitt et al in Fig. 7 in their article in Circulation volume 11, number 4, April 1955. A similar ECG pattern was later described by Samuel Sclarovsky in 1988 in the American Heart Journal in 1988 as regional subendocardial ischemia and was associated with a subtotal occlusion of the LAD or a total occlusion of a side branch, typically a diagonal branch. We have considered this a non-ST elevation ACS pattern (Nikus K et al, committee paper, JECG 2010). However, after the papers by Wellens' group (Verouden, de Winter et al), where they found this ECG pattern in 2% of primary PCI patients and almost always with a totally occluded LAD, I would consider this a STEMI equivalent. In our regional network for acute coronary syndromes, we treat these patient according to the STEMI protocol (emergent angiography bypassing the emergency room) if their clinical presentation is compatible with acute coronary syndrome. In case of uncertainty we take the patient to the emergency room and take a control ECG within 30 minutes, and if possible, do an echo to find regional wall motion abnormalities.
2. As to ECG 3: now there is ST elevation with terminal T-wave inversion. I would presume this to represent either a totally occluded LAD with collateral flow to the ischemic region or an open artery with critical stenosis and subnormal epicardial flow. To me the inverted T waves represent some grade of myocardial reperfusion ("evolving MI with incomplete reperfusion"; Eskola MJ et al. Eur Heart J 2007;28:2985).
3. ECG 4: more prominent T-wave inversion – better myocardial reperfusion, the situation is better than in ECG 3 although the ST segments are still elevated. The myocardium is stunned and edematous, but will recover to some part. The EF will improve.
4. Angiography shows a proximal LAD occlusion with collateral flow mainly from the RCA.

Best regards

Kjell Nikus

Tampere, Finland



Spanish

Queridos colegas: Permítanme analizar estos ECGs de dejan gran aprendizaje ya que involucran muchos conceptos de la fisiopatología de las isquemias agudas y que únicamente el método electrocardiográfico puede analizar.

ECG 1: infarto antero-septal por obstrucción de la DA distal a la primera diagonal (Dg_1), El área necrótica compromete el septo anterior alto y medio Parecería que el septo derecho esta irrigado por la coronaria derecha (CD) y la pared antero-lateral por la circunflejo (LCX) sugiriendo que todas las arterias irrigan las áreas a las que habitualmente están destinadas. El grado de isquemia es 2, es decir ST/T elevado, sin distorsión del QRS. Este comportamiento indica que el epicardio esta pre-condicionado y parcialmente protegido. Este fenómeno se observa en pacientes con síndromes anginosos previos o en pacientes bien entrenados. La precordial V_4 presenta una isquemia de grado 1, es decir ondas T altas sin desviación del segmento ST por lo que podría representar la zona limítrofe del IM o que haya una circulación superpuesta, de la segunda diagonal (Dg_2) de AD y la segunda marginal de la LCX que pueden irrigar el mismo segmento septal inferior. Lo mismo ocurre en la bipolar I, que muestra isquemia grado 1, con remodelación recíproca longitudinal por la presencia de ondas T negativas en III,(no se trata de isquemia inferior).

ECG 2 se observa una evolución dramática de la extensión del infarto. Este concepto fue introducido en la literatura al comienzo de la década del 80 en el siglo XX, cuando se desarrollaron los conceptos de **expansión** y de **extensión**, La primera se expande hacia el epicardio, no ocasiona dolor, aumento de enzimas cardiacas y termina en disquinesia del área afectada. Contrariamente, la extensión va acompañada de angina, aumento de las enzimas y del tamaño del infarto. La Dg_2 se obstruyó, extendiendo el IM al segmento inferior del septo y al ápex (V_5). Además, aVL también disminuyó el voltaje del QRS y la onda T, por lo tanto la T negativa se aplanando sugiriendo que también la Dg_1 forma parte del proceso; es decir que la Dg_2 se obstruyo por completo y la Dg_1 está en vías de hacerlo.

ECG3: Comienza la reperfusión miocárdica en el centro del infarto (V_2 a V_4) caracterizada por ondas Q, segmento ST elevado y ondas T invertidas. Si este patrón persiste tendrá una evolución típica. Al día 4 del infarto las ondas T se positivaron y comienza la expansión hacia el epicardio con riesgo de formar una aneurisma y en los ancianos ruptura tardía con hemopericardio, ya que en la edad avanzada desaparece la cadena biológica que provoca el pre condicionamiento epicárdico. (adenosina, que estimula al canal de K^+ dependiente del ATP, que acorta la fase 2 del potencial de acción del epicardio evitando la entrada del Ca^{2+} permitiendo así la sobrevivida prolongada del miocito del epicardio y evitando la ruptura cardiaca.

ECG 4 Se ve el resultado final del fenómeno de extensión y expansión. El IM involucra todo la pared antero-septal y el segmento izquierdo del músculo basal expresado en aVL y remodelación recíproca longitudinal en III. El problema que la reperfusión miocárdica no es completa. Este patrón se registra generalmente a las 72 horas del infarto, y luego comienza la expansión hacia el epicardio con ondas positiva hasta el noveno día del IM y quedara disquinesia antero-septal. La profundidad del QS en V2,V3 sugieren hiperquinesia póstero-septal que ayuda a mantener el volumen sistólico y la presión arterial

Queridos amigos este caso es el ejemplo más extraordinario de los conceptos de extensión y expansión en el la evolución de un IM agudo. Esto conceptos fueron demostrado únicamente en los laboratorios experimentales, pero vale la pena publicarlo ,no se cuándo se podría encontrar un caso igual

Mis felicitaciones a este fantástico trio Brasileño por tener la capacidad de ver esta evolución no usual del infarto antero-septal. Un abrazo a todos los compañeros y en especial a los clínicos y cardiólogos jóvenes de toda Latinoamérica.

Samuel Sclarovsky Israel

Current director of telemedicine unit at Assuta medical center.



English: Allow me to analyze these ECGs of great learning value, as they involve many pathophysiology concepts on acute ischemias and that only ECG can yield.

ECG1: anteroseptal infarction by LADA obstruction distal to the first diagonal artery (Dg1). The necrotic area is in the high and medium anterior septum. It seems that the right septum is irrigated by the RCA and the anterolateral wall by the LCx, suggesting that all arteries irrigate the usual areas. We can also say that the degree of ischemia is 2; i.e. there is elevated ST/T, with no QRS distortion. This behavior indicates that the epicardium is pre-conditioned and semi-protected. This phenomenon is observed in patients with previous angina syndromes or in well trained patients. V4 presents first-degree ischemia; i.e. high T waves with no ST segment shift, which may be expressing the borderline area of the MI or an overlapping circulation of the second diagonal artery of the ADA, and the second marginal artery of the LCx, that may irrigate the same inferior septal segment. The same happens in I, which shows ischemia in degree 1, with reciprocal longitudinal remodeling by the presence of negative T waves in III (it is not inferior ischemia).

ECG2: Dramatic evolution of the extension of infarction is observed (this concept was introduced in literature at the beginning of the 80s), differentiating extension expansion. The first one expands to the epicardium, without pain, or an increase in cardiac enzymes, ending with dyskinesia, while the extension is accompanied by angina, increase in enzymes and increase in the size of infarction. The second diagonal was obstructed, extending the infarction to the inferior segment of the septum and the cardiac apex (V5). aVL also decreased QRS and T wave voltage, so the negative T flattens, suggesting that also the first diagonal artery became involved in the process; i.e. the second diagonal artery was completely obstructed and the first diagonal artery is on its way to do so.

ECG3: Myocardial reperfusion starts at the center of infarction (V2, V3, V4), characterized by Q waves, elevated ST segment and inverted T waves. If this pattern persists the patient will have a typical evolution. On day 4 of the infarction, T waves will become positive and start expanding toward the epicardium with a danger of forming an aneurysm or in the elderly, a late rupture with hemopericardium, since in those in an advanced age, the biological chain that causes epicardial preconditioning disappears (adenosine, which stimulates the potassium channel dependent on ATP, which shortens phase 2 of the epicardial action potential, preventing calcium inflow, thus allowing for a prolonged survival of the epicardial myocyte and cardiac rupture).

ECG4: The final result of the extension and expansion phenomenon is seen. The MI affects all the antero-septal wall and the right segment of the basal muscle expressed in aVL and reciprocal longitudinal remodeling in III.

The problem is that there is no complete myocardial reperfusion. This pattern is generally recorded after 72 h of the infarction, and later the expansion to the epicardium starts with positive waves until the 9th day of the MI, and anteroseptal dyskinesia will remain.

But the depth of QS in V2, V3 suggest posteroseptal hyperkinesia, helping to keep the systolic volume and blood pressure.

Dear friends, this case is the most extraordinary example of the concepts of extension and expansion in the evolution of acute myocardial infarction. These concepts were proven only in experimental labs, but it is worth publishing them; I cannot imagine finding a case like this elsewhere.

My congratulations to this fantastic Brazilian trio, for having the capacity of seeing this unusual evolution of the antero-septal infarction.

Warm regards to all our colleagues, and especially the young clinicians and cardiologists from all of Latin America.

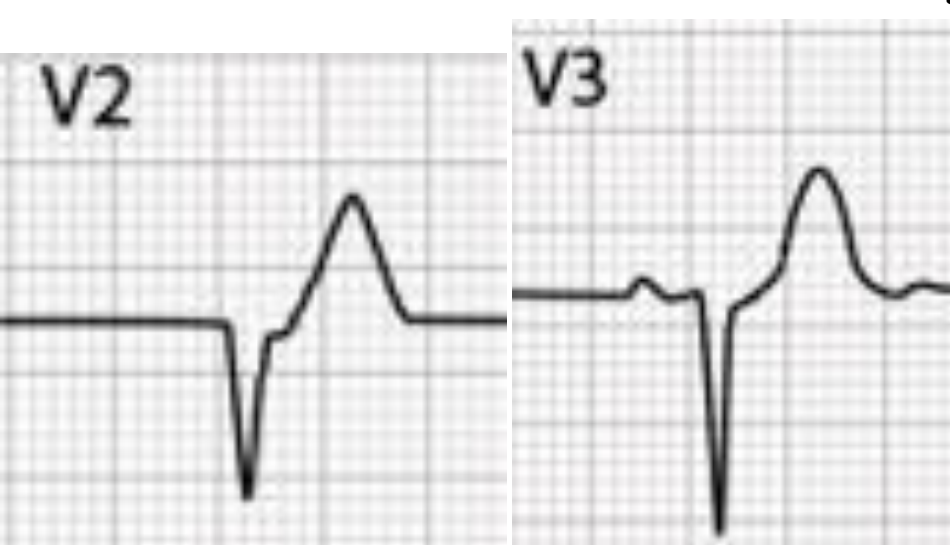Samuel Sclarovsky

Question Dear Samuel: when you analyze the ECG-1 mentions that the ST segment is elevated in antero-septal wall, however, I think it's depressed. What do you have to say?


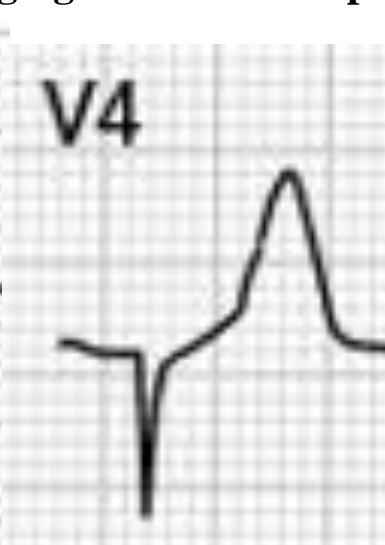
Thank in advance

Andrés.

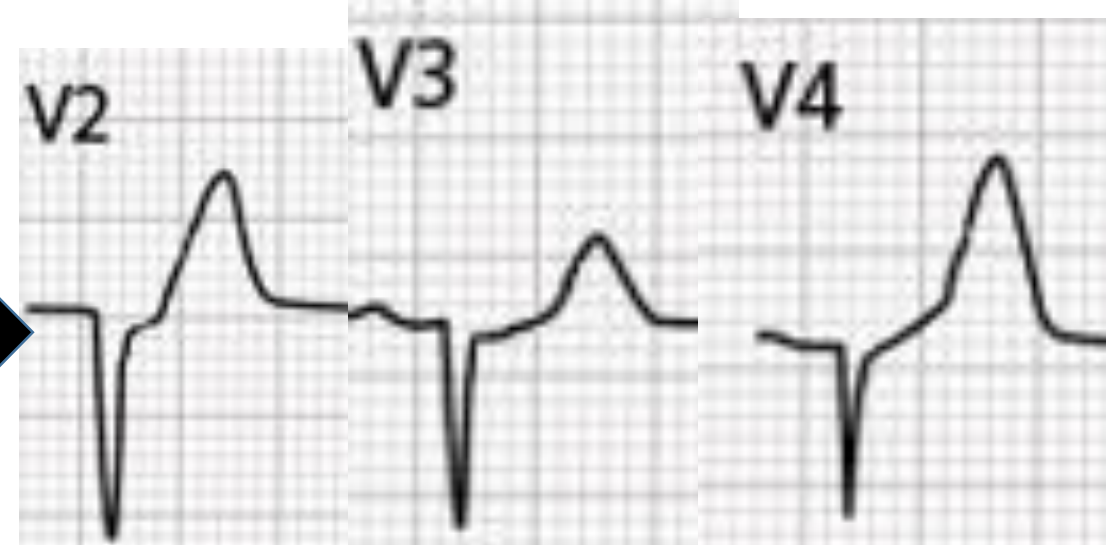
ECG-1- At admission



Unchanging or static ECG pattern



ECG-2 - Performed 5 hours later



Answer: No my dear friend Professor Andrés Ricardo. The ascending limb of the T, shows very small slow and fragmented conduction delay in V2, V3 and V4. After these depolarization of the epicardium, appears signs of a typical elevated ST-T of repolarization with, showing second degree of acute ischemia, due to a sudden total obstruction of the left anterior descending artery(LADA)

I am more than sure, after searching the electrocardiographic evolution of a large number the acute anterior myocardial infarction during consecutive 30 years.

I think that you identified a very unusual case showing simultaneously the electrocardiographic expression of expansion and extension, frequently described in basic science laboratories.

Regarding the evolution of acute anteroseptal myocardial infarction expressed by ST depression with positive T waves, in V2, V3, Non ST elevation could be seen. But inverted T waves, without ST deviation is almost recorded. This inverted T waves express the inversion of the non homogeneous transmural action potential. The shortened AP in the jeopardized sub-endocardial is expressed by the inverted T waves in precordial leads.

By the way, I want remind that the only one artery, that could expresses with acute subendocardial ischemia is the LAD, because the auto regulation phenomenon, that avoid the collapse due to a the reduction of the flow pressure after acute subtotal obstruction.

This is because the adventitia of the artery is surrounded by sympathetic ganglions, which release adrenergic substances, inducing small arteries vasoconstriction

This issue is open for against and pro critics

My best regard

Samuel Sclarovsky

Spanish: Queridos amigos Andrés Ricardo, Raimundo y Luiz Carlos permítanme agregar un elemento electrofisiológico que se observa en este caso tan extraordinario que estamos analizando. El ECG-1 presenta un fenómeno electrocardiográfico, no descrito, pero del cual hay presunción teórica de su existencia. En los infartos transmurales la despolarización del epicardio se procesa longitudinalmente desde el área no afectada a la isquémica. Como la despolarización es longitudinal y paralela al electrodo de registro, este no la registra. No obstante, en el presente caso se pudo obtener en la fase precoz una corriente transversal que despolariza el epicardio que se expresa entre los 50 y 60ms. ¿Como se traduce electrocardiográficamente este fenómeno? En los casos de infartos con perfusión miocárdica completa por patrón QS en V2-V3 con profundidad de 5 a 10mm y QRS fragmentado en la rampa ascendente del complejo alrededor de los 60ms seguido de segmento ST isoelectrico y ondas T negativas profundas de hasta 10mm. Más tarde el IM expande hacia el epicardio y esta despolarización transversal desaparece. En los infartos anteriores transmurales no reperfundidos no se observa esta despolarización epicárdica transversal entonces la profundidad de las S de V2-V3 pueden alcanzar los 20mm, el segmento ST permanece elevado y las ondas T son positivas, es decir, tienen despolarización epicárdica longitudinal y no transversal. En el capítulo 4 de mi libro esto lo explico e ilustro con numerosos ejemplos.

Un fraternal abrazo

Samuel Sclarovsky

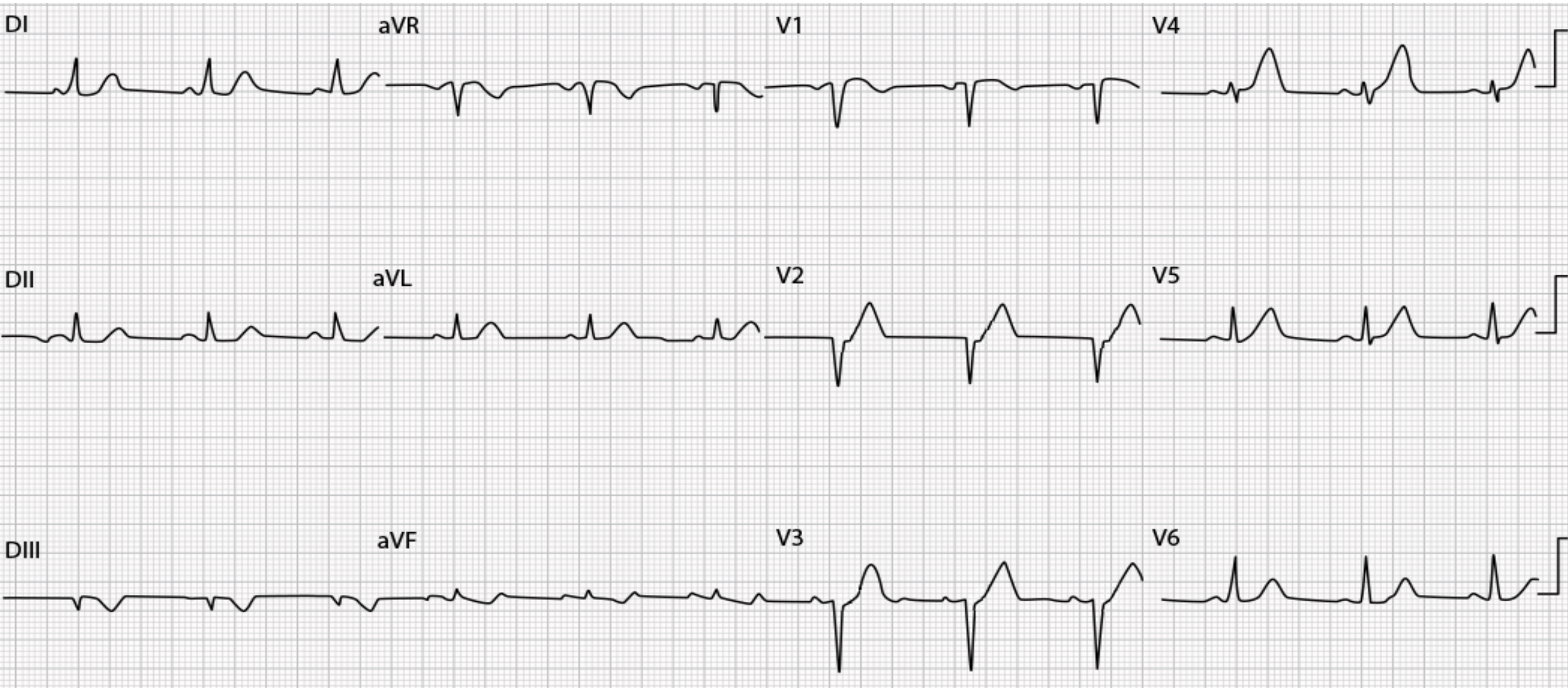
Dear friends, Andrés Ricardo, Raimundo and Luiz Carlos, Allow me to add an electrophysiology element that is observed in this case we are analyzing, that is so extraordinary.

ECG-1 presents an electrocardiographic phenomenon, not described, but about which there is a theoretical assumption regarding its existence. In transmural infarctions, epicardial depolarization is processed longitudinally from the non-affected area to the ischemic one. As depolarization is longitudinal and parallel to the recording lead, the latter does not record it. Nevertheless, in this case it was possible to get a transverse current in the early phase, that depolarizes the epicardium that is expressed between 50 and 60 ms. How is this phenomenon translated electrocardiographically? In the cases of infarctions with complete myocardial reperfusion, it is done by QS pattern in V2-V3 with a 5 to 10 mm depth and fragmented QRS in the ascending ramp of the complex around 60 ms, followed by isoelectric ST segment and deep, negative T waves of up to 10 mm. Later, the MI expands to the epicardium and this transverse depolarization disappears.

In non-reperfused, transmural anterior infarctions, this transverse epicardial depolarization is not observed, so the depth of S from V2 to V3 may reach 20 mm, the ST segment seems elevated and T waves are positive; i.e. epicardial depolarization is longitudinal and not transverse. In Chapter 4 of my book, I explain this and illustrate it with numerous examples.

**Final comments by Raimundo Barbosa-Barros, Andrés
Ricardo Pérez-Riera, & Luiz Carlos de Abreu**

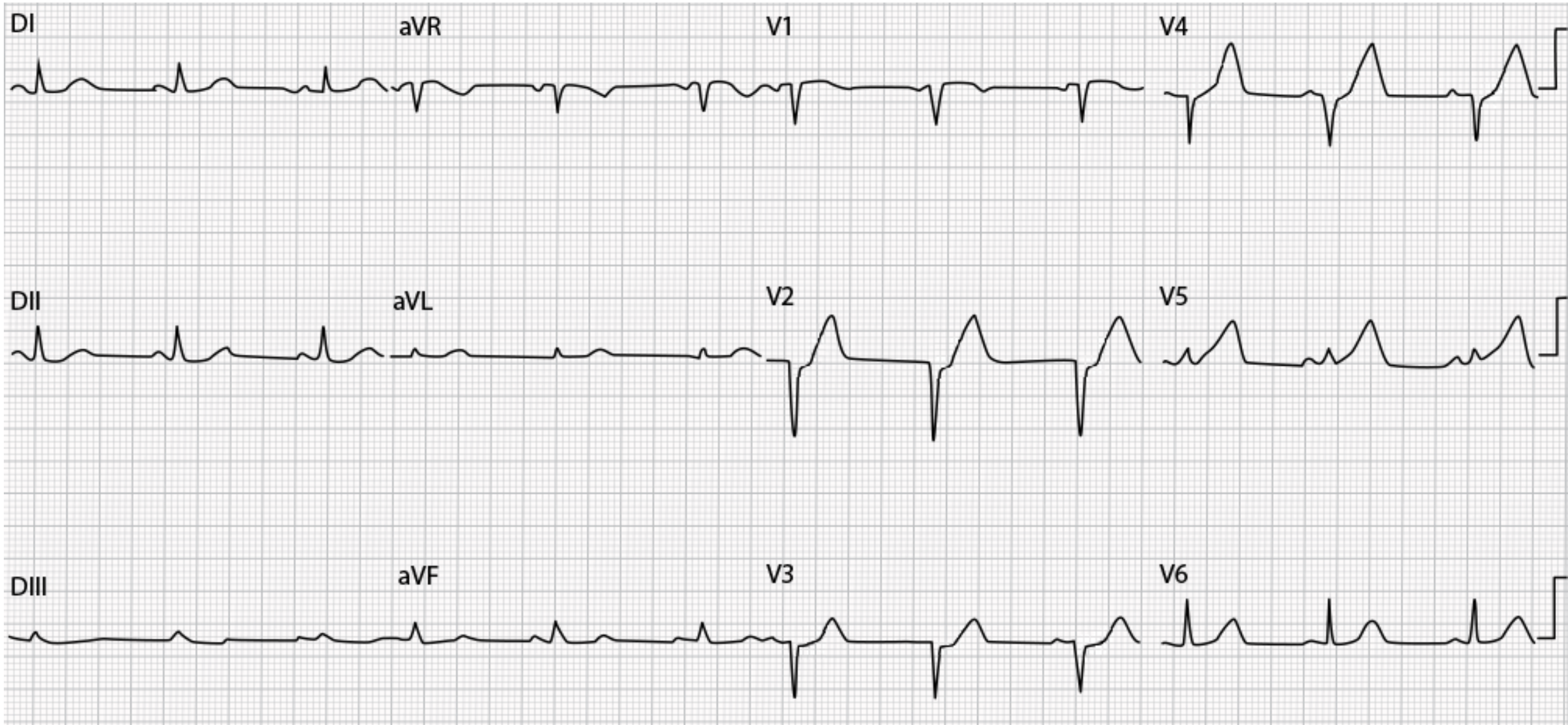
Figure 1 (ECG-1) - At admission



Electrocardiographic diagnosis: High amplitude T waves, with wide base and slight ST segment depression from V2 to V4. Poor R wave progression from V1 to V3 is observed.

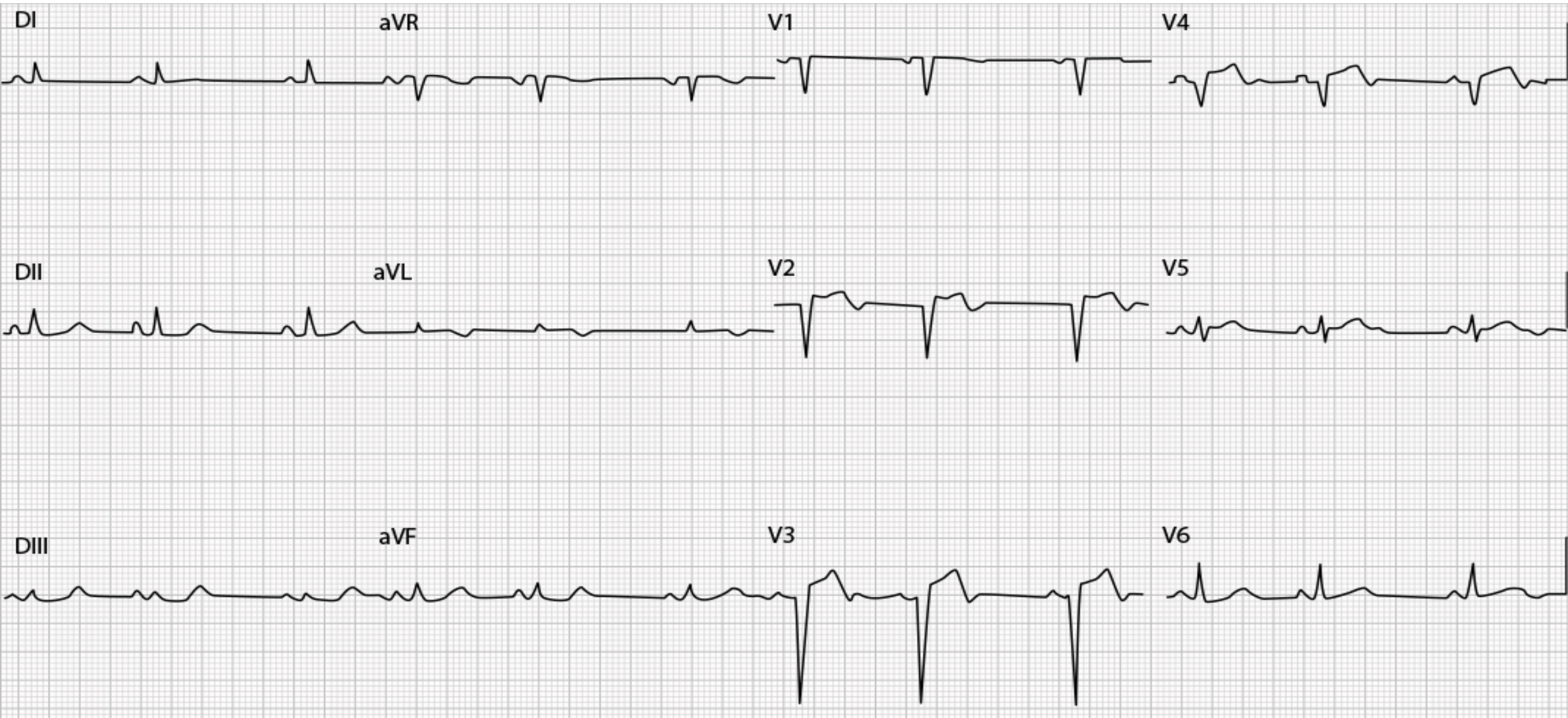
The axis of T wave in the frontal plane was approximately $+5^\circ$ (to the left of $+30^\circ$; negative T wave in III).

Figure 2 (ECG-2) - Performed 5 hours later



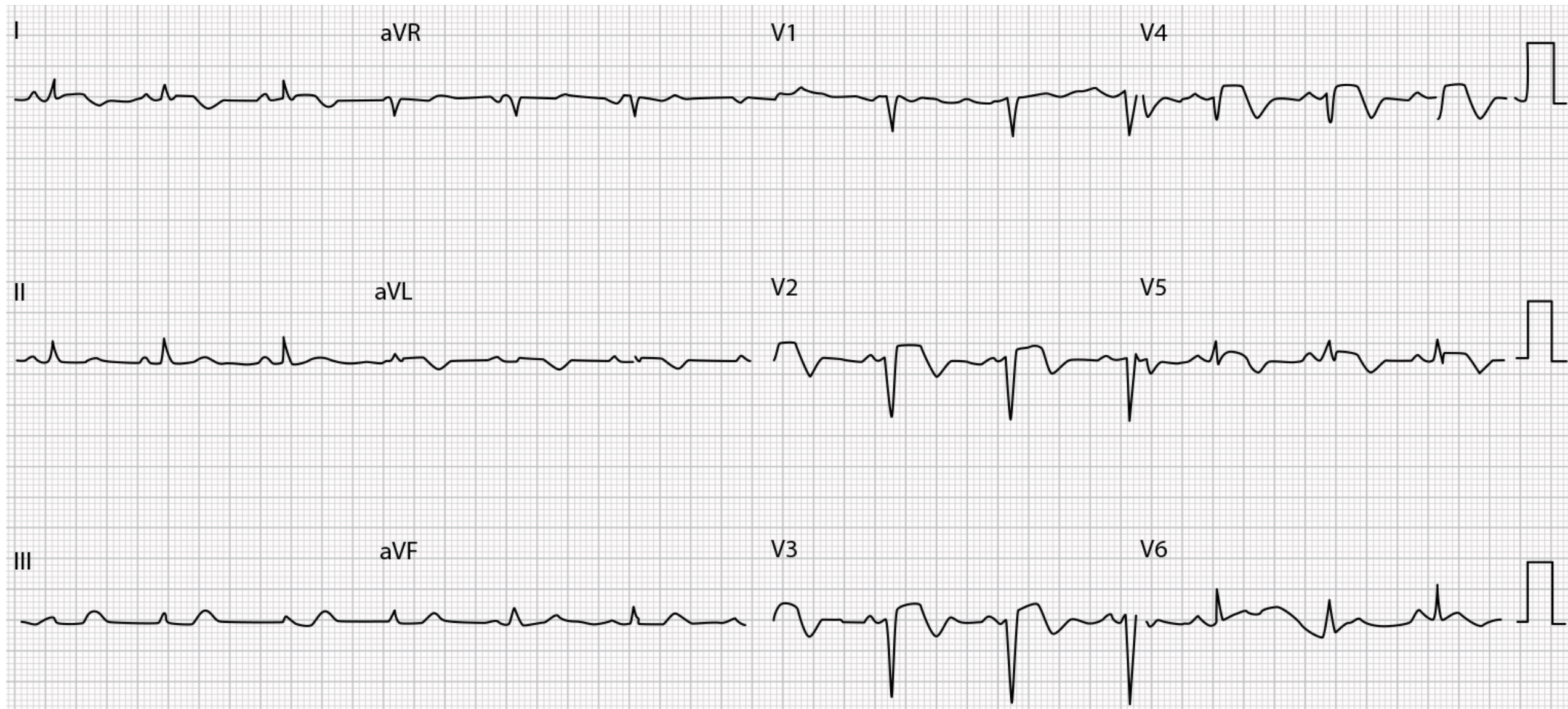
Electrocardiographic diagnosis: The electrocardiographic pattern remained essentially unchanged or “static” in the precordial leads when compared to the admitting ECG. Only the T wave axis had slightly shifted to the left in the frontal plane, at approximately $+30^\circ$ (T wave perpendicular to lead III axis).

Figure 3 (ECG-3) - Performed 13 hours later



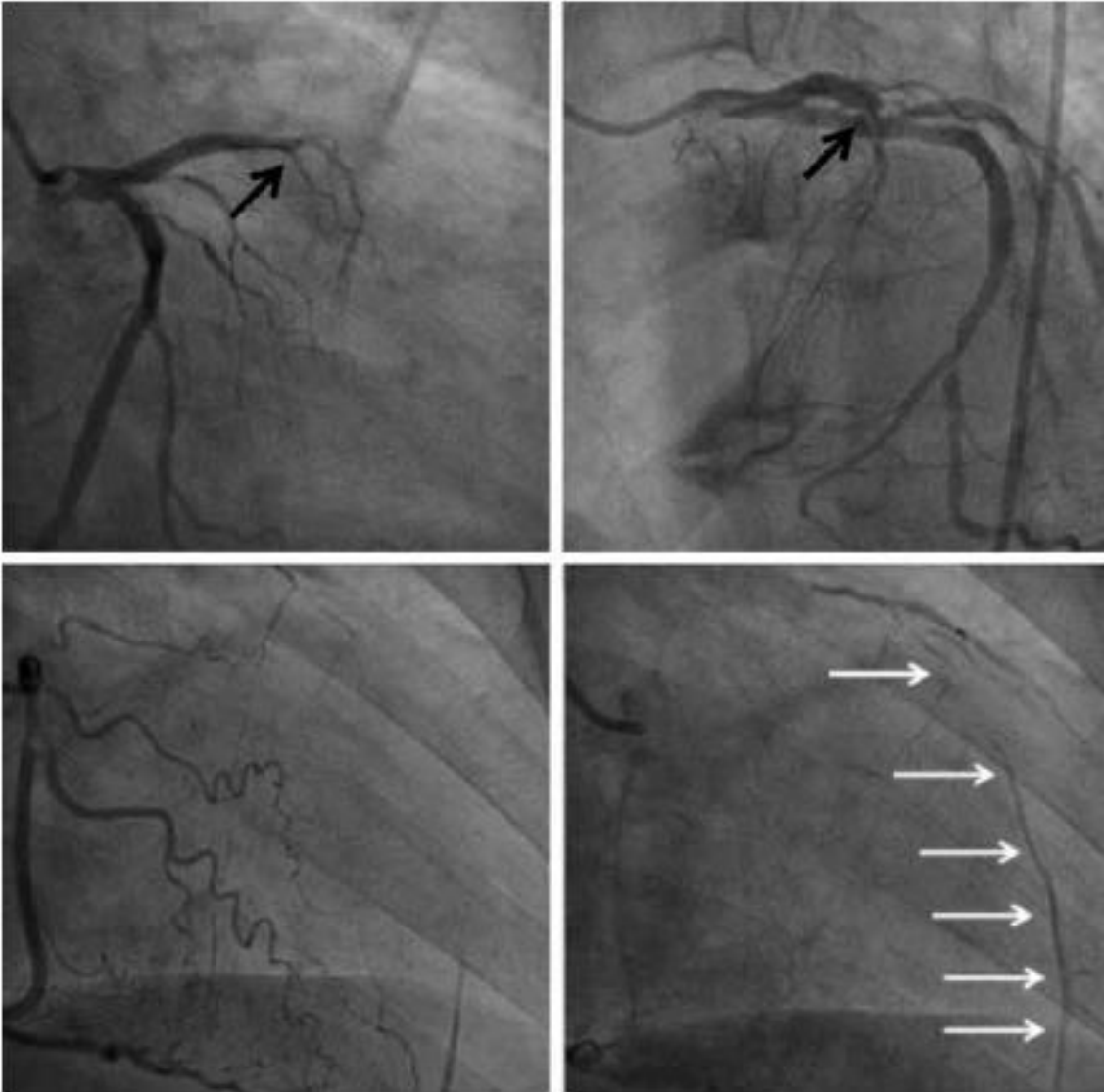
Electrocardiographic diagnosis: Transmural anterior myocardial infarction (transmural because the electrodes that face the infarcted anterior wall record a completely negative QS pattern) in evolution: necrosis, transmural ST segment injury current and plus-minus T-wave from V2 to V4 ischemia in anterior wall leads.

Figure 4 (ECG-4) - Performed prior to cardiac catheterization during a new episode of chest pain



Electrocardiographic diagnosis: Evolving anterior transmural myocardial infarction and ischemia in anterior wall leads. The frontal plane T waves show a major shift to the right with an axis close to +120° (negative in I and positive in III).

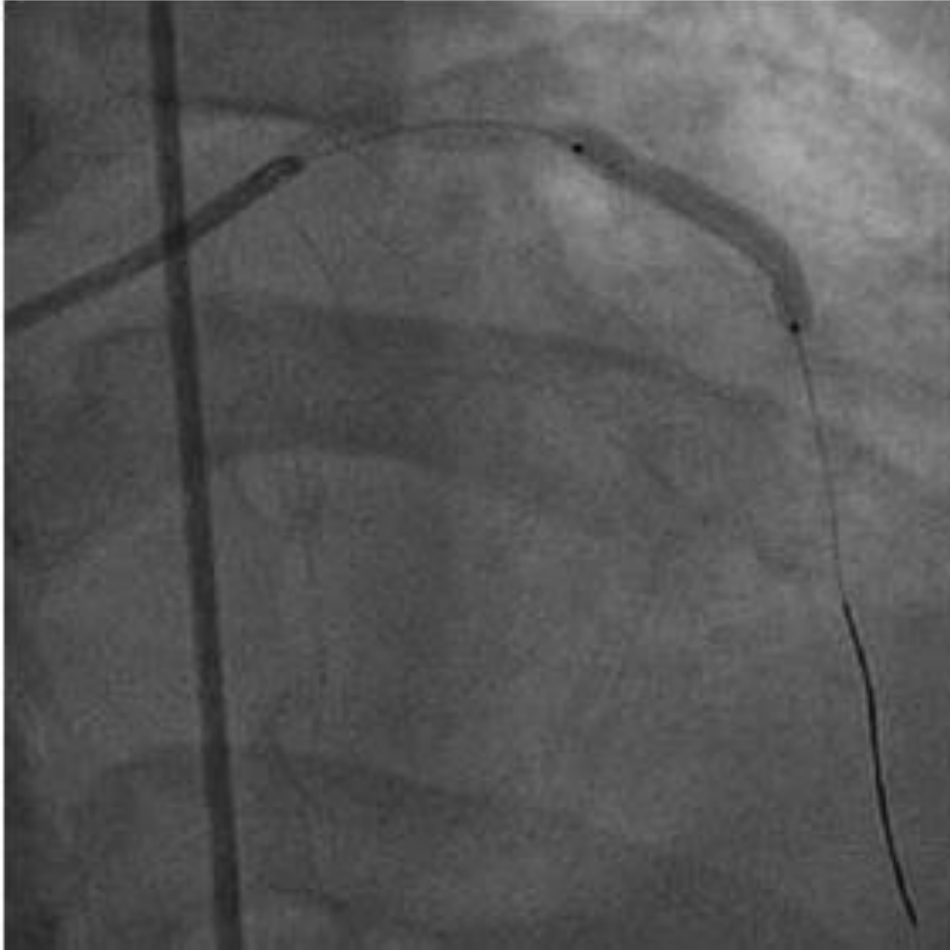Figure 5 - Coronariography



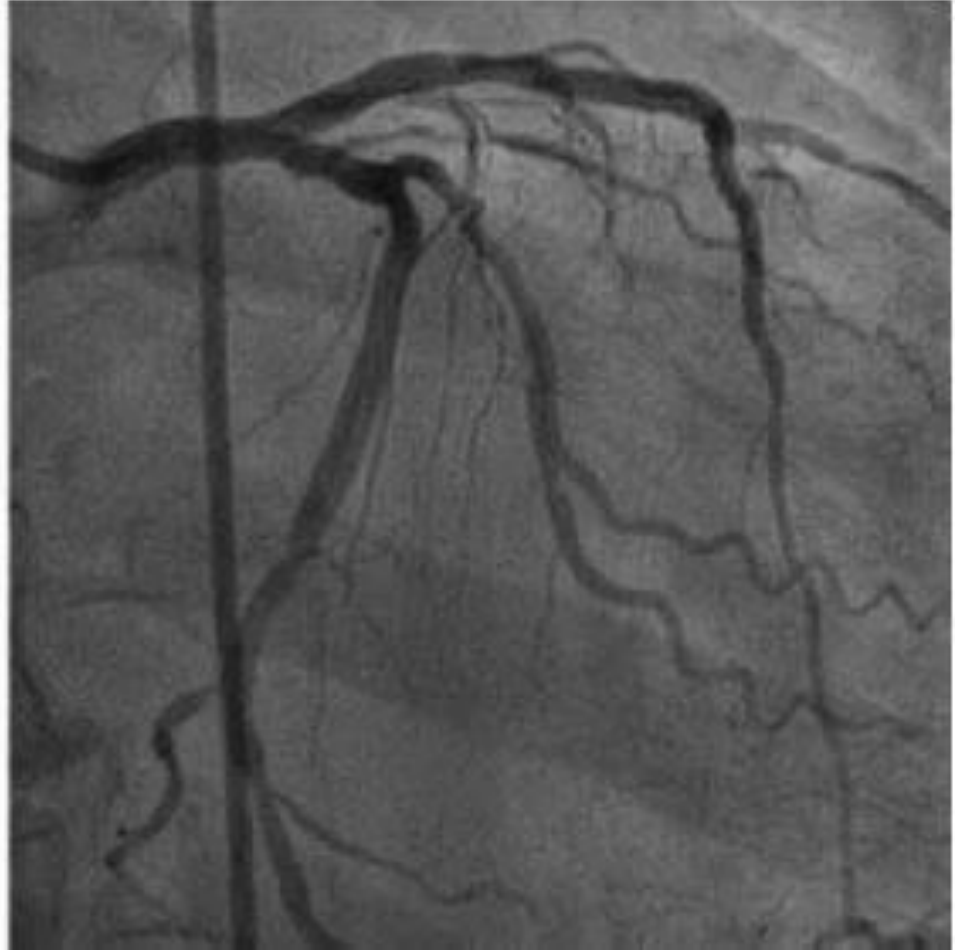Total proximal occlusion of the LAD with collateral circulation from the RCA (white arrows).

Before (A) and after (B) angioplasty and conventional stent deployment in the LAD

A



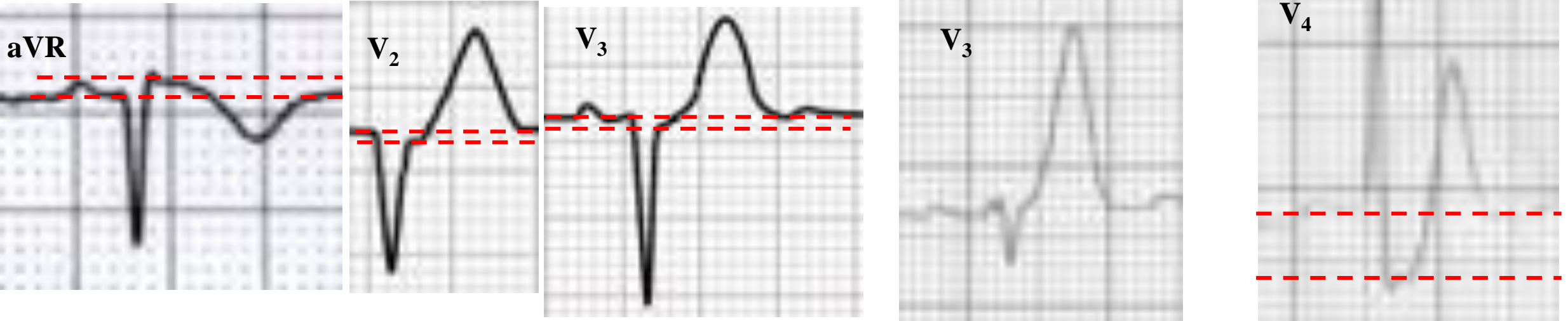
B



Before and after angioplasty and conventional stents in the LAD showing an open artery, however with a thin distal bed.

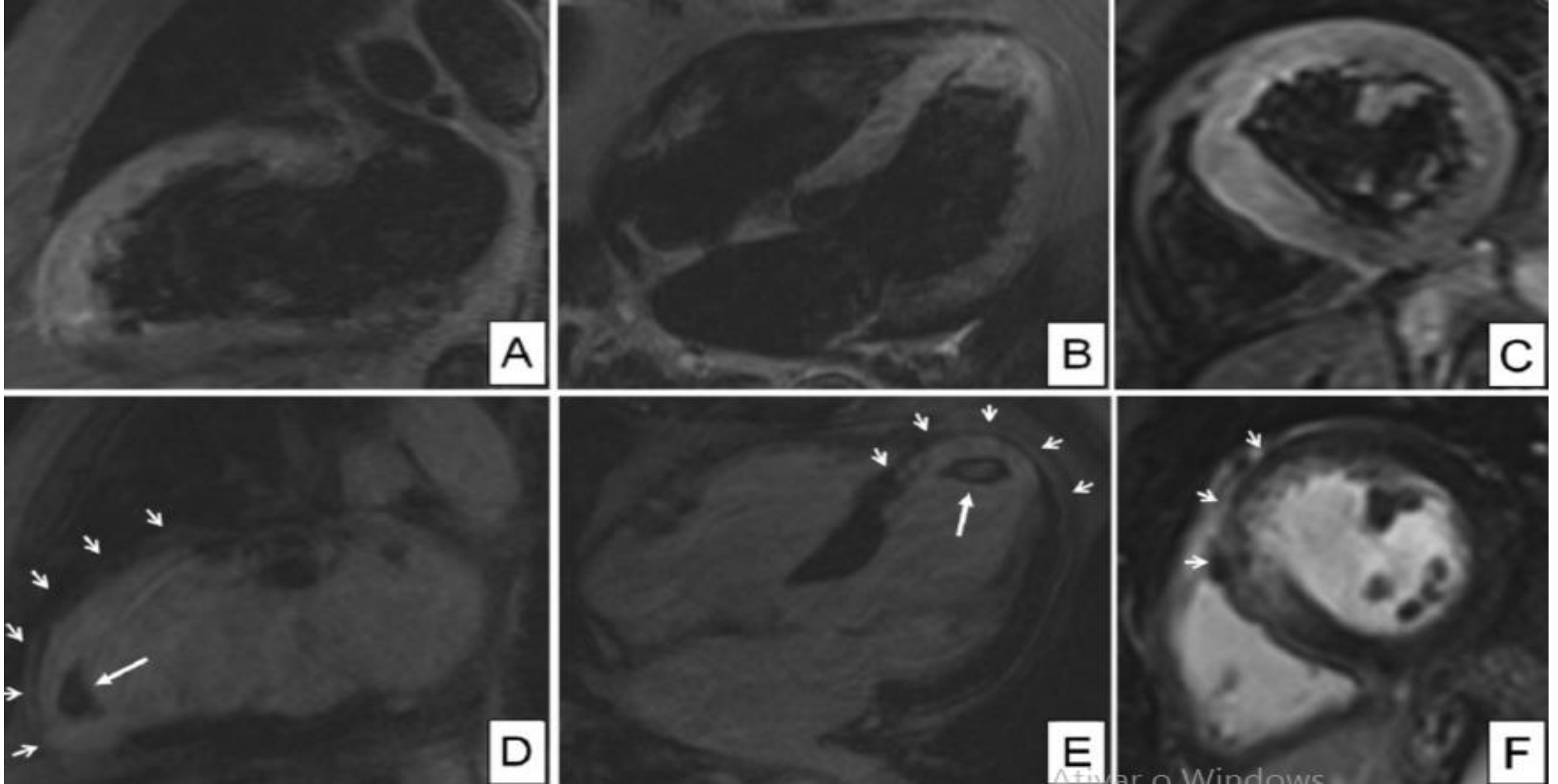
Conclusion: the so called de Winter's T Waves sign/pattern: Upsloping STD followed by persistent precordial "hyperacute" tall symmetrical T waves signify proximal LAD artery occlusion

1mm STSE in aVR



- Upsloping ST segment depression in V2-V6
- Tall, prominent, symmetric and persistent T waves throughout the precordial leads
- Frequent 1mm STSE in aVR
- The de Winter ECG pattern is a recently-described **STEMI equivalent** that emergency physicians and paramedics must be aware of.
- Represents $\approx 2\%$ of LAD occlusions.
- May persist until the culprit artery is opened (making it a STEMI equivalent) or may evolve into an anterior STEMI.
- This patient needs to be managed as a STEMI with emergent PCI or thrombolysis! (our approach was wrong)
- These patients typically have **critical stenosis of the LAD** requiring emergent PCI or thrombolysis.
- Lack of familiarity with these ECG findings may lead to reluctance to activate the cath lab and unacceptable delays in reperfusion.
- in many cases the de Winter pattern/sign persisted until *after* the target artery was opened. Don't wait for serial ECGs to evolve into a more easily-recognizable STEMI pattern (which may never happen): activate the cath lab now!

The use of NMR clearly shows that the myocardial protection is only partial and does not prevent cell damage. This ECG pattern is often associated with the presence of collateral circulation, which may modulate myocyte action potential changes in response to ischemia and prevent the appearance of STSE. Late percutaneous myocardial revascularization made in the present case was not capable of preventing residual LV dysfunction. Therefore, in opposition to the previous evidence, the approach in this subset of patients should be similar to that used for STEAMI. “A new electrocardiographic pattern” was described de Winter et al (**de Winter 2008**) due to proximal occlusion of the LAD characterized by 1-3 mm J point and ST segment depression (STD) with concave upwards ST segments and persistent wide, symmetrically positive T waves from V1 to V6. QRS complexes were generally not wide or only slightly so, and in some cases poor R-wave progression was observed (as in the admittance ECG of the present case). In most of the patients there was 1-2 mm STSE in lead aVR. The authors observed this characteristic ECG pattern in 30 of 1,532 (2.0%) patients with anterior MI. ECGs with this pattern were obtained an average 90 minutes after the onset of symptoms. In spite of having successful percutaneous coronary interventions in all cases, there was a considerable myocardial loss. It is clinically very important to identify this ECG pattern and adopt a more urgent therapeutic intervention. A significant number of patients with large AMI, caused by occlusion of an epicardial coronary artery, do not show STSE. Other ECG abnormalities may be present, the so called STEMI-equivalents. One such STEMI equivalent, junctional STD followed by tall symmetrical T-waves in the precordial leads, often in combination with slight STSE in lead aVR, associated with proximal occlusion of the LAD. In some patients, this classic ECG time sequence does not occur, and the only change is due to subendocardial ischemia resulting in tall, symmetrical and wide-based T waves that remain without modification in sequential ECGs. When this ECG behavior occurs in the anterior wall leads with wide and persistently positive T waves it indicates a high likelihood of total obstruction of the LAD which is filled in a retrograde fashion through collateral circulation variable degree of LV dysfunction. During the period of total obstruction there was preexisting adequate collateral circulation in order to prevent transmural ischemia, which explains the absence of STSE (**Sagie 1989**). The myocardium is partially protected with a lower degree of ventricular dysfunction (**Desch 2010**). This interpretation has led to the practice of an initial conservative treatment in patients that present with an unchanging or static ECG pattern. This approach, however, has recently been questioned in a study published by Verouden et al (**Verouden 2009**). These authors observed that patients with this “static” electrocardiographic pattern without significant STSE who had acute proximal occlusion of the LAD (**Verouden 2009**) were younger and more likely to be men with a history of hyperlipidemia compared to patients with anterior wall STEMI (**Eskola 2009**). Other investigators using nuclear magnetic resonance (NMR) imaging during the acute phase along with ECGs (**Perazzolo Marra 2010; Desch 2010**) showed that in addition to the presence of transmural myocardial edema there is an element of myocardial necrosis in the territory irrigated by the LAD comparable to anterior wall STEMI and associated with significant increases of cardiac enzymes (**Lonborg 2012; Zorzi 2012**).

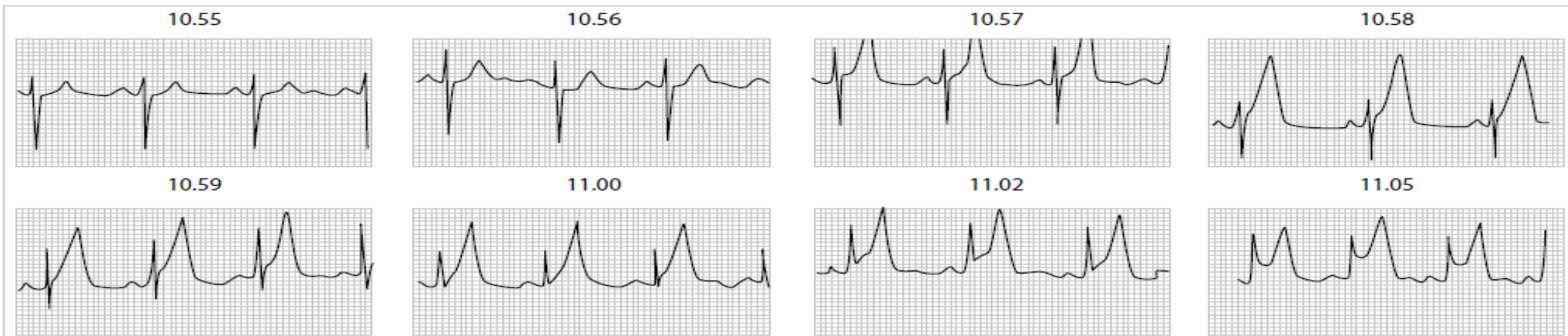


Cardiac magnetic resonance findings. (Top) Increased signal intensity on T2-weighted sequences in the 4-chamber (A), 2-chamber (B) and mid short axis (C) views consistent with transmural myocardial edema of the left ventricular anterior wall, ventricular septum, and apex (area at risk = 37%). (Bottom) T1-weighted inversion recovery post-contrast sequences in the same views (D–F) showing non-transmural late-gadolinium enhancement suggestive of myocardial necrosis (infarct size = 32%) sparing the epicardial layers of the anterior wall and apical segments (arrowheads). Salvaged myocardium was 5%. An apical thrombosis is also evident (arrow).

Discussion

In the presence of a classic scenario of ST elevation MI (STEMI) or ACS due to LAD occlusion the ECG evolves in a classic time sequence of modifications leads facing the ischemic zone (anterior or anterolateral precordial leads) that affect first the T wave become tall, symmetrical and peaked (**grade 1 ischemia**), second, there is STSE without distortion of the terminal portion of QRS complex (**grade 2 ischemia**) and finally those with terminal QRS distortion resulting in loss of the S wave and an increase of R wave amplitude explained by prolongation of electrical conduction of the Purkinje arborizations (**grade 3 ischemia**) (David 1982; Sagie 1989; Sclarovsky 1990; Sclarovsky 1999; Birnbaum Y 1999; Birnbaum Y2003; Birnbaum GD 2014).

In the figure below a continuous recording over 10 minutes (lead V2) the mentioned changes are seen: increase in the width and amplitude of the T wave (**degree I of ischemia**) followed by ST segment elevation (STSE) (**degree II of ischemia**).



A Grade III "Terminal QRS distortion" is indicative of most severe ischemia and associated with cardiovascular magnetic resonance imaging (CMR) markers of myocardial damage in the subacute phase. Additionally, associated with a trend towards a lower LVEF (Hassell 2016). Distortion in the terminal portion of the QRS complex on pre-reperfusion ECG in two or more leads is independently associated with larger myocardium at risk and infarct size in the setting of primary angioplasty-reperfused anterior STEMI. QRS terminal distortion in only one lead is independently associated with larger infarct size in this setting. These findings suggest that terminal QRS distortion analysis could be included in risk-stratification of patients presenting with anterior STEMI (Valle-Caballero 2016)

There are two distinct definitions of terminal QRS distortion depending on the presumed waveforms of the pre-ischemic ECG recording. One of these (disappearance of S waves) is indeed a manifestation of slowed ventricular depolarization. However, the other (J point/R wave > 0.5) is not such a clear manifestation hereof.

The Grade 3 criterion 'absence of S-wave' is more closely associated with changes of QRS-complex indices as well as with myocardial hypoperfusion, than the criterion 'J point/R-wave > 0.5 ' both used to define terminal QRS distortion in the Sclarovsky and Birnbaum ischemia grading.

The Sclarovsky-Birnbaum ischemia grading system, which considers T wave, ST and QRS complex changes, correlates with final infarct size, failure of ST segment resolution and mortality. However, the pathophysiologic basis for the distinction between the grades of ischemia is not fully understood.

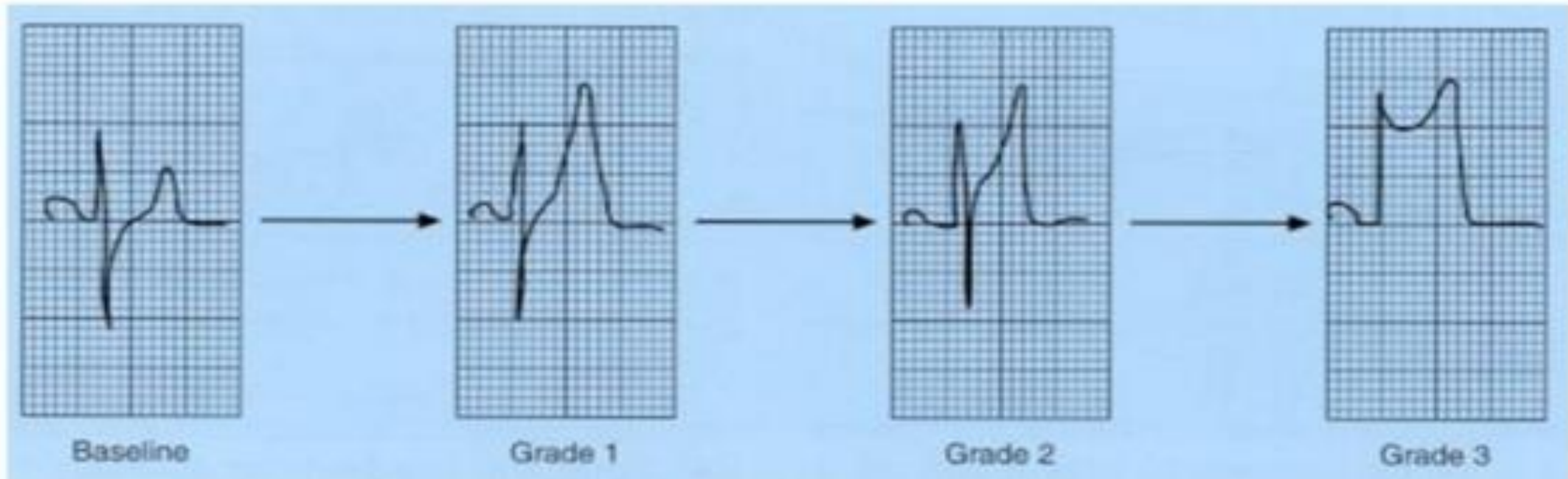
The refined Sclarovsky-Birnbaum Ischemia Grading System can be performed manually with low interobserver variability. It has potential for support of the AMI triage decision as an electrocardiographic method for evaluating the level of ischemic protection at the time of either pre-hospital or emergency-department presentation (**Billgren 2004**).

Sclarovsky and Birnbaum detects a parallel between the ancient manuscript of Miron Prinzmetal et al (**Prinzmetal 1959**), in their approach to research, which is based on systemization and utilization of electrocardiographic knowledge (**Madias 2009**).

The ECG based Sclarovsky-Birnbaum Ischemia Grade may be used to determine the prognosis of patients with STEMI. However, application of the method is based on assumption of the baseline QRS morphology. Thus, Carlsen et al (**Carlsen 2014**) studied if the baseline QRS morphology was correctly assumed based on an ECG recorded during induced ischemia, and if reference to the baseline ECG altered the designated Ischemia Grade. The authors studied 63 patients with chronic ischemic heart disease that underwent elective percutaneous transluminal coronary angioplasty were included. Baseline ECG and ECG during the procedure were recorded. In the latter, Ischemia Grade was classified according to assumed baseline QRS morphology. Then the baseline ECG was used as reference and Ischemia Grade was determined based on change from the baseline ECG. In 66.6% of patients the criteria for STEMI were fulfilled; the incidence was similar between LAD and RCA occlusion. In LAD patients who fulfilled STEMI criteria, assumption of baseline QRS morphology in involved leads was accurate in only 35% and this altered the Ischemia Grade in 10% (2/20) of patients. In RCA patients who fulfilled STEMI criteria, assumption of baseline QRS morphology in involved leads was accurate in 77.3% and this altered the Ischemia Grade in 9.1% of patients. The authors concluded that application of the Sclarovsky-Birnbaum Ischemia Grade with reference to a baseline ECG altered Ischemia Grade in $\approx 10\%$ of patients. All patients that were reclassified were assigned a higher Ischemia Grade. Future research is needed to determine the impact of availability of the baseline ECG on the clinical diagnostic and prognostic performances of the Sclarovsky-Birnbaum Ischemia Grade.

Scalarovsky-Birnbaum grade of ischemia

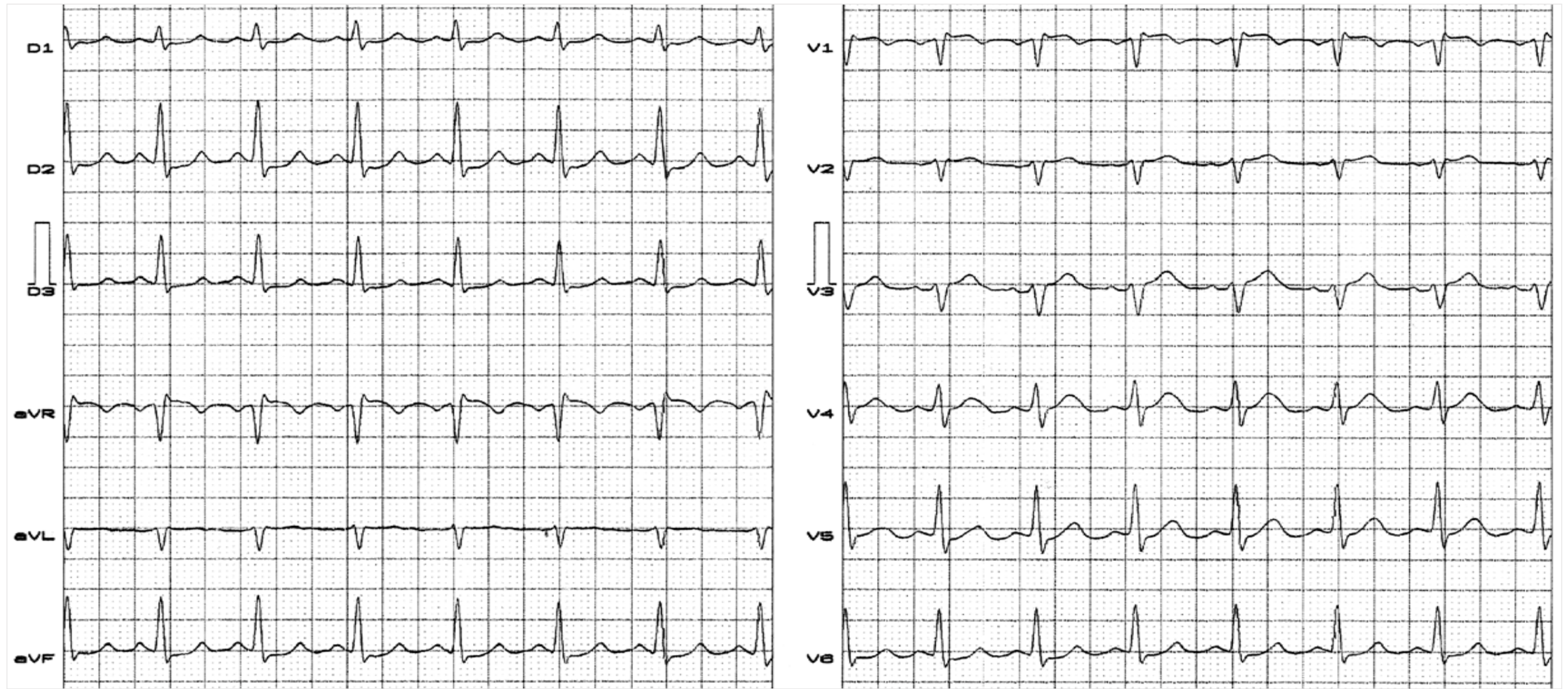
Scalarovsky-Birnbaum Ischemia Severity Grading System



Scalarovsky-Birnbaum Ischemia Severity Grading System ischemia on admission is the strongest independent predictor of failure to achieve myocardial reperfusion after thrombolysis. This association may underlie the larger infarcts associated with grade 3 ischemia. Other predictors of reperfusion failure are the extent of STSE, prior use of aspirin and no prior use of β -blockers (**Buber 2005**). Critical proximal obstruction in LAD artery before first septal perforator (S_1) is the main cause of Prominent QRS Anterior Forces (PAF) (grade 3 ischemia) by prolongation of electrical conduction of the Purkinje arborizations in the ischemic zone reflecting severe ischemia due to lack of protection by preconditioning or collateral circulation (**Birnbaum 2014**) and located in the middle of left septum and apical portion where left septal fascicle or middle fibers runs and thus can cause an Left Septal Fascicular Block (LSFB) (**Pérez-Riera 2016**) Let's see a demonstrative example in the following ECG sequence.

Ergometer stress test – Stage 1 – onset of strain

Name: PRT; **Date:** 11/04/2002; **Age:** 48 y/o; **Gender:** M; **Race:** Mixed; **Weight:** 82 Kg; **Height:** 1.84 m; **Biotype:** Mesomorph

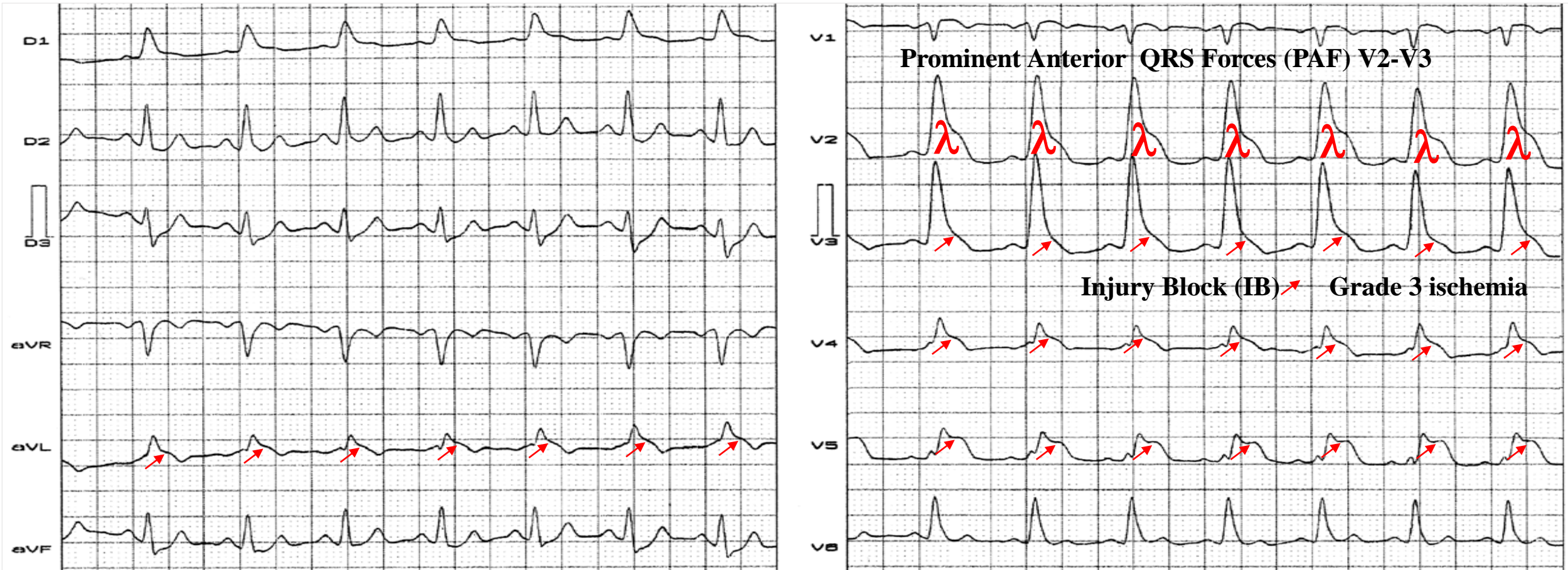


Clinical diagnosis: stress angina pectoris, long-standing smoker (30 cigarettes/day), stress. Absence of diabetes, hypertension, dyslipidemia, or others.

ECG diagnosis: tracing of onset of strain, HR 109 bpm, discrete right end conduction delay by one of the right branch divisions: aVR and V₁ Qr.

Ergometer stress test – Stage 2– during strain

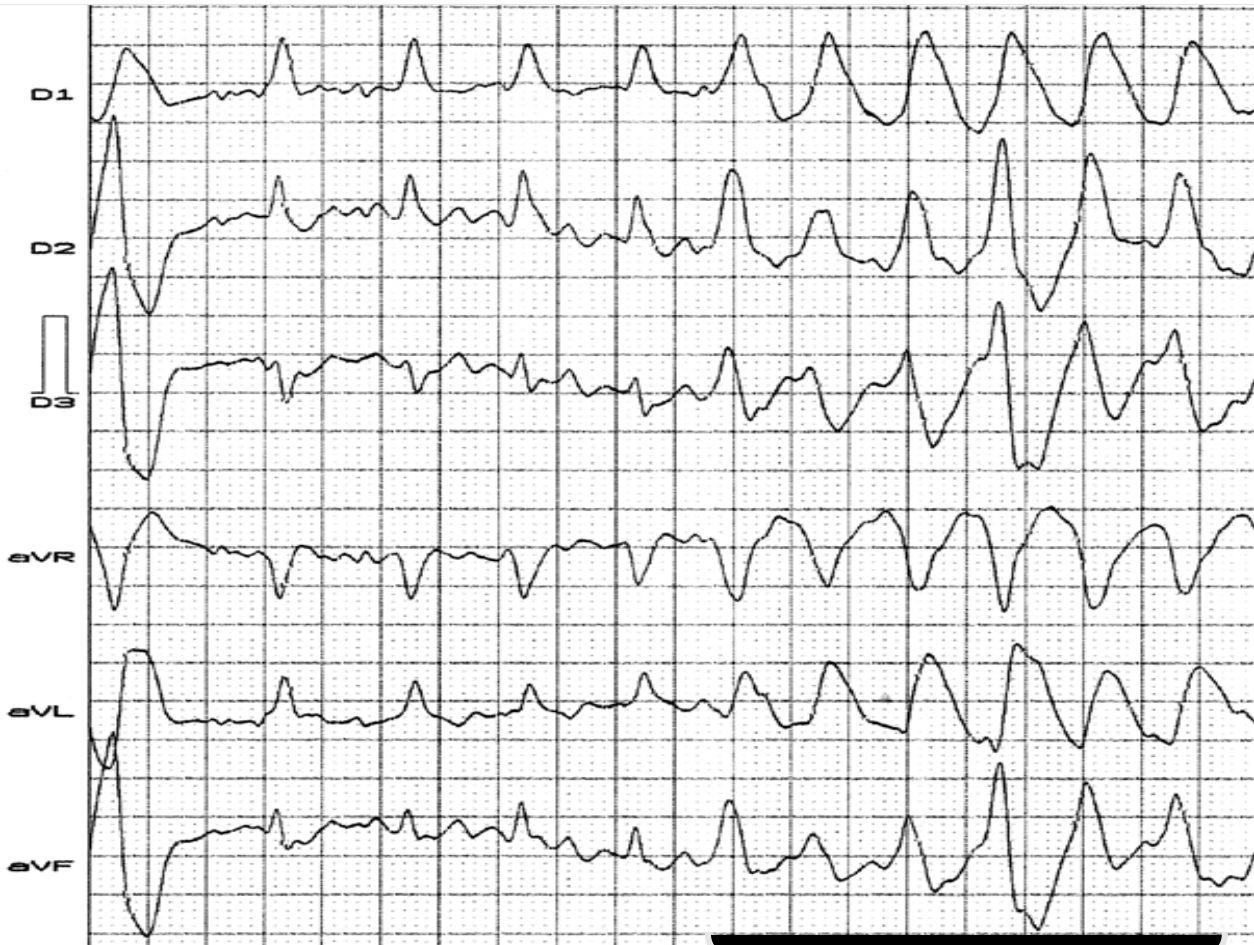Name: PRT; Date: 11/04/2002; Age: 48 y/o; Gender: M; Race: Mixed; Weight: 82 Kg; Height: 1.84 m; Biotype: Mesomorph



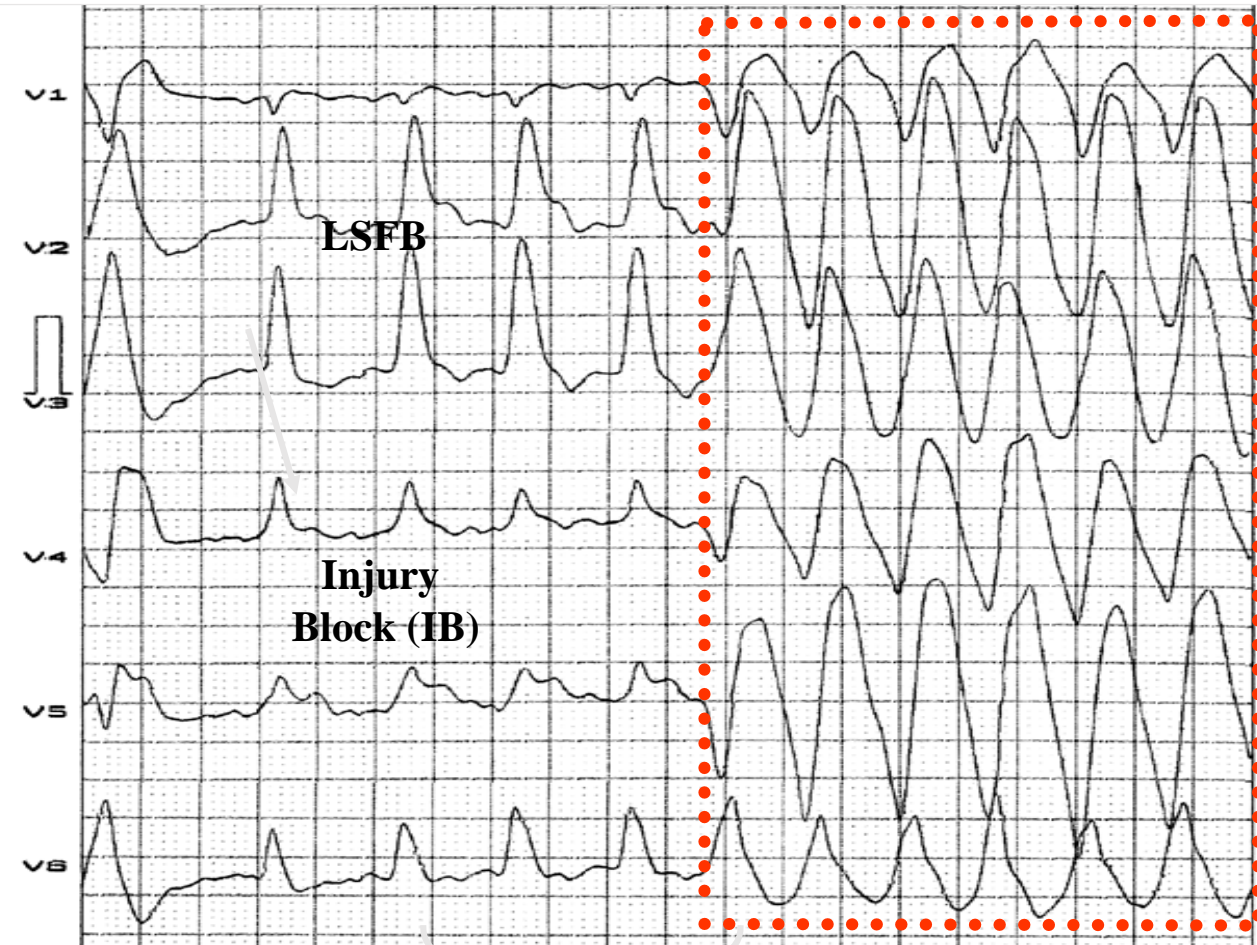
In the second stage of the stress test, a typical pattern appeared in the anterior wall, known as injury block (IB), characterized by terminal portion distortion of the QRS complex (lambda wave or Gussak wave ([Gussak 2004](#))). Grade 3 ischemia. This IB is characterized by the emergence of the J point above the lower half of the R wave, and disappearance of S wave in leads with rS configuration, as in this case in v₂ & v₃. Additionally, a significant increase in R wave voltage is observed in v₂ & v₃. Prominent anterior QRS forces (PAF), indicating the appearance of Left Septal Fascicular Block (LSFB). The hemodynamic study revealed critical proximal lesion in the LAD artery before the first septal perforator branch. Tracing performed during stage 2 stress test, which shows in the sequence, LSFB with prominent anterior QRS forces and injury block.

Ergometer stress test – Stage 3–of strain : LSFb + injury block + VT

Name: PRT; Date: 11/04/2002; Age: 48 y/o; Gender: M; Race: Mixed; Weight: 82 Kg; Height: 1.84 m; Biotype: Mesomorph



Ventricular Tachycardia (VT)

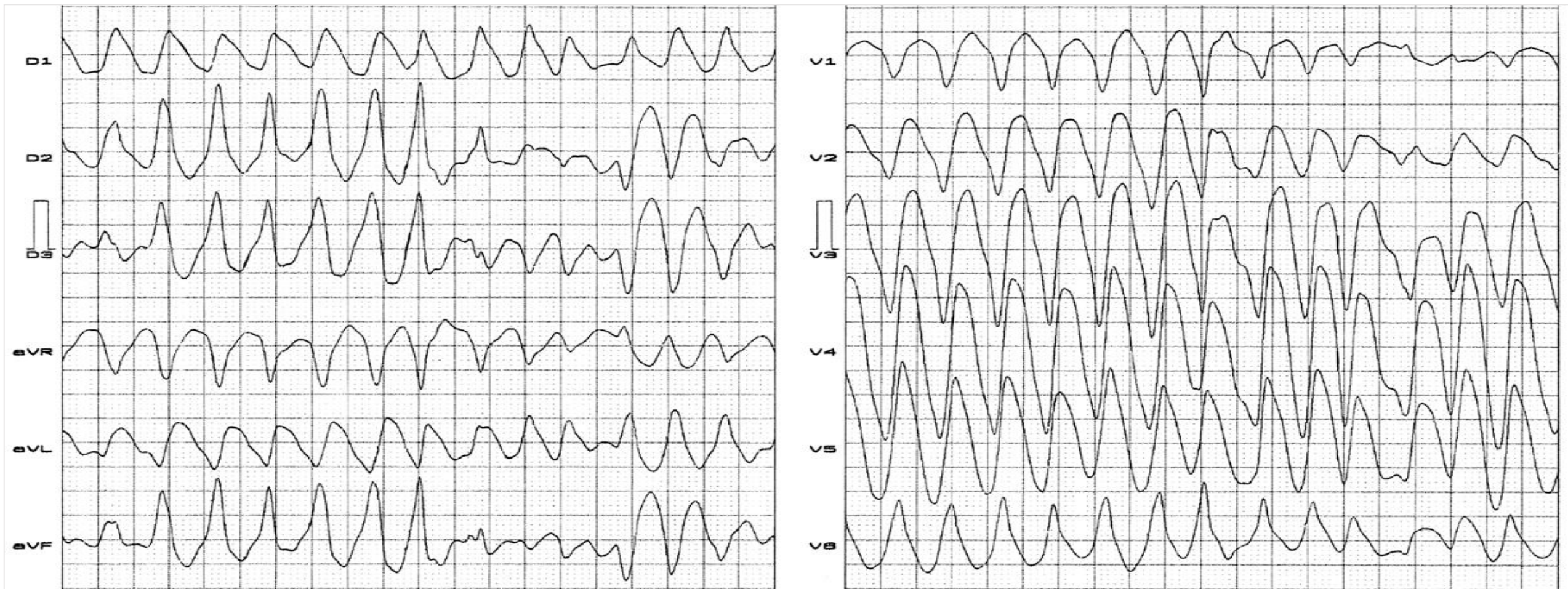


Ventricular Tachycardia (VT)

Tracing of a patient during stress test, showing in the sequence, LSFb with prominent anterior QRS forces and injury block followed by sustained monomorphic ventricular tachycardia run, that disappeared during the recovery stage.

Ergometer stress test – Stage 4 SVT

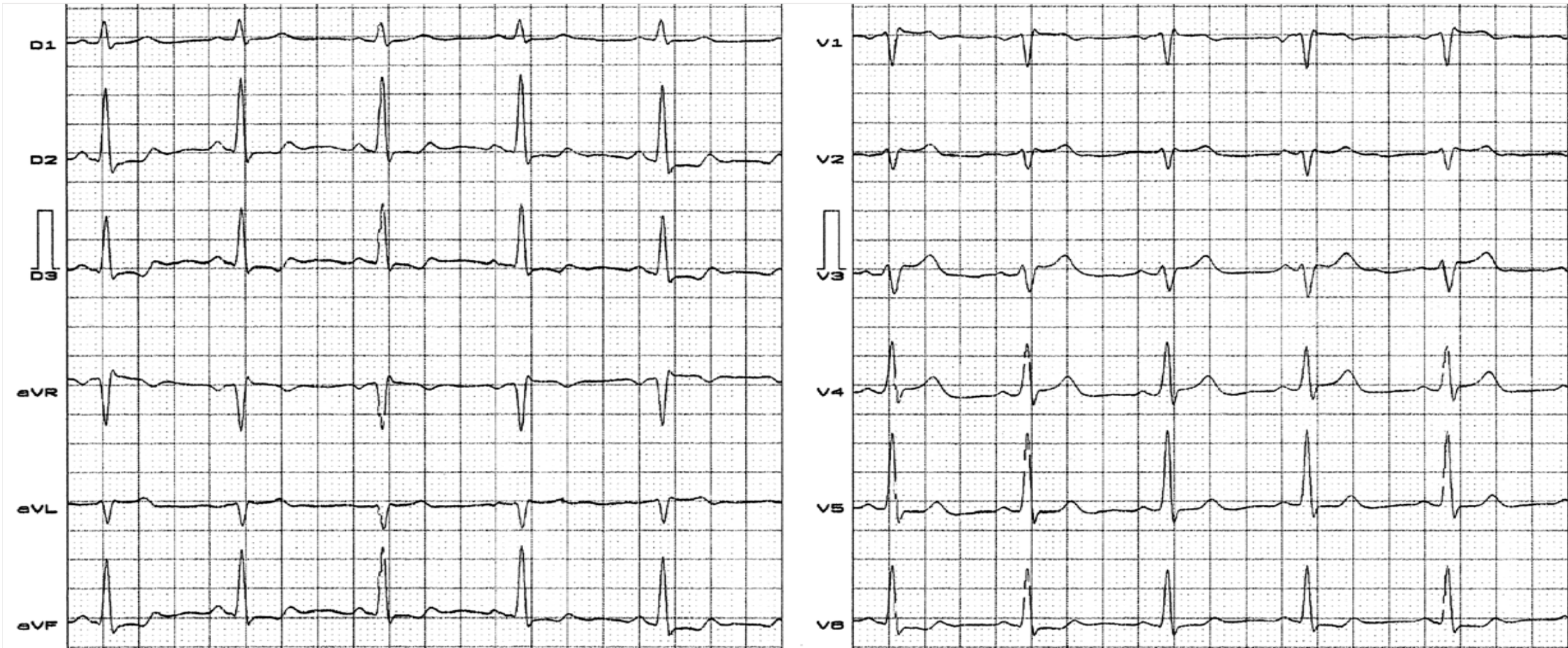
Name: PRT; **Date:** 11/04/2002; **Age:** 48 y/o; **Gender:** M; **Race:** Mixed; **Weight:** 82 Kg; **Height:** 1.84 m; **Biotype:** Mesomorph



Tracing of a patient during stage 4 stress test, showing sustained monomorphic ventricular tachycardia run, which disappears during the recovery stage.

Ergometer stress test stage 5, recovery in 2 minutes: normalization with PAF by LSFb and VT disappearing

Name: PRT; Date: 11/04/2002; Age: 48 y/o; Gender: M; Race: Mixed; Weight: 82 Kg; Height: 1.84 m; Biotype: Mesomorph



Conclusions: after 2 minutes of interrupting the strain, the VT run disappears (NS-VT), as well as injury block (IB) and prominent anterior forces (PAF) secondary to left septal fascicular block (LSFB). This case reveals irrefutably the intermittent form of LSFb. The intermittence phenomenon has a great diagnostic value since it rules out the possibility of other causes of PAF.

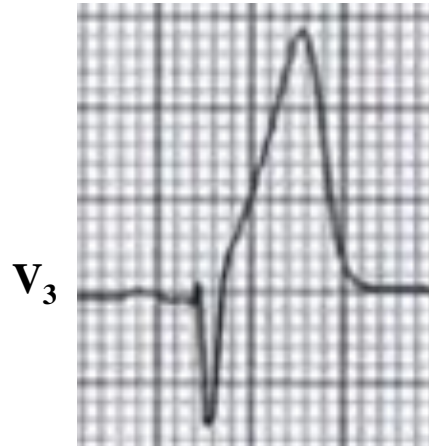
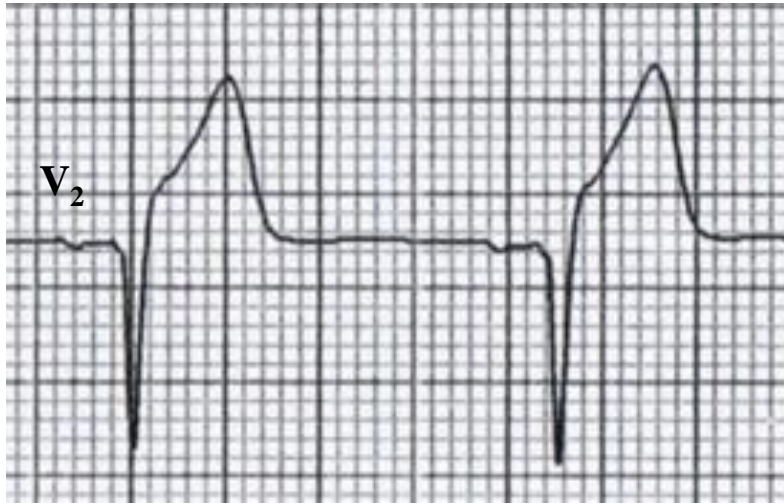
Emergency physicians and interventional cardiologists involved in STEMI networks, is important to ensure timely reperfusion therapy in these patients (**de Winter 2016**). Up-sloping STD followed by a positive T waves is a sign of regional subendocardial ischemia associated with severe obstruction of the LAD. Additionally, widespread STD, often associated with inverted T waves and STSE in lead aVR during precordial pain, may represent diffuse subendocardial ischemia caused by severe CAD. In case of hemodynamic compromise, urgent coronary angiography is recommended (**Birnbaum 2014**).

Non-STEMI or non-STEACS is approached by less invasive and frequently delayed treatment strategies. Because also non-STEACS comprises severe and/or extensive CAD under treatment may occur of these patient categories. Therefore better identification of those patients is needed. In the current guidelines the ischemic ECG changes are incompletely described. Improved description and understanding of the ECG in ACS will lead to better recognition of the patient at risk by emergency physicians and cardiologists (**Gorgels 2013**).

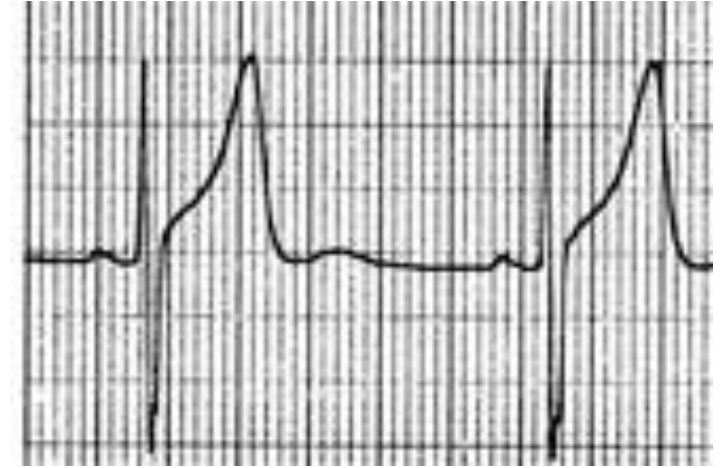Currently is not well known are which subgroups of MI patients with STD on the ECG may benefit from emergent reperfusion therapy. Current clinical guidelines recommend against administering emergent reperfusion therapy to MI patients with STD on the ECG unless a true posterior MI is suspected. Overlooked subgroups of patients with STD on the initial ECG who may potentially benefit from emergent reperfusion therapy are patients with multilead STD with coexistent STSE in lead aVR. This finding has been reported in MI patients with occlusion of the left main artery, occlusion of the proximal LDA, and MI in the presence of severe multivessel coronary artery disease. Because these patients have a higher mortality in the setting of MI, we believe that this ECG finding be considered a STEMI equivalent and that patients with this finding receive consideration for emergent reperfusion therapy preferably at a center with both primary percutaneous coronary intervention and coronary artery bypass grafting capability (**Hennings 2012**).

Other ECG patterns in acute coronary syndrome scenario and their differential diagnosis

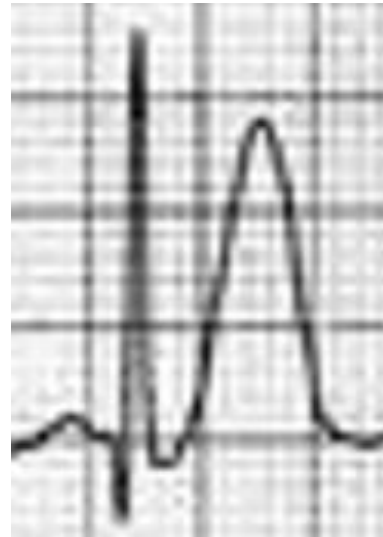
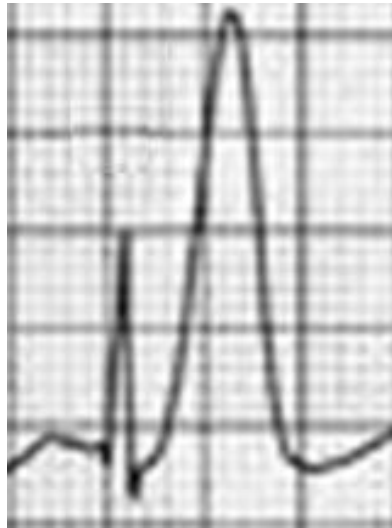
Hyperacute T waves due to anterior STEMI



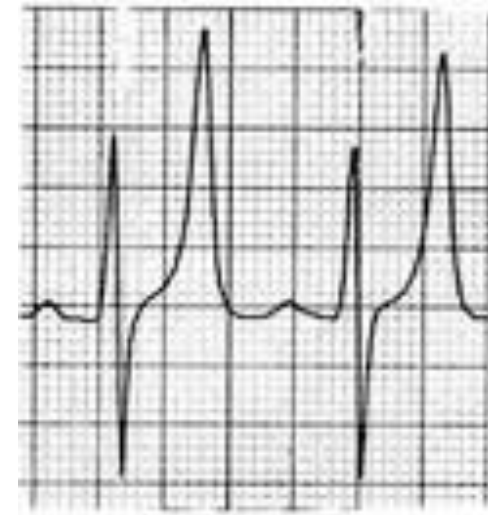
Normal variant



Hyperacute T waves



Hyperkalemic T waves



In some patients with acute STSEMI, the T wave is initially tall and is called hyperacute T wave changes -- "more acute than acute." In such a case, the T wave is symmetric but not narrow, not pointed, and not tented.

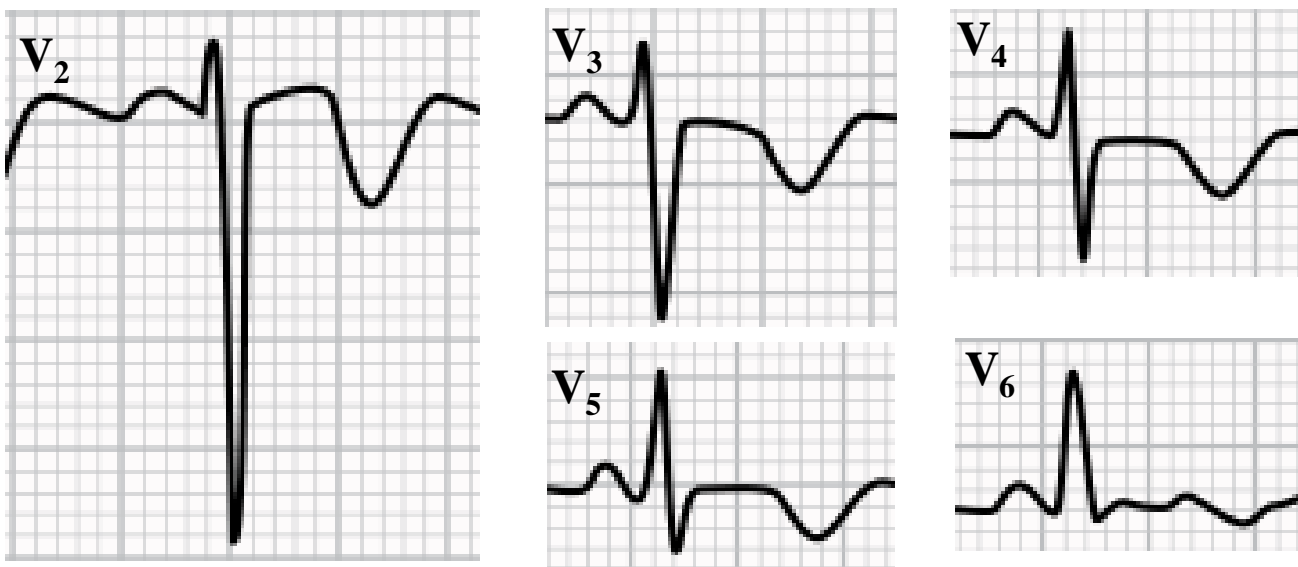
Tall, symmetric, narrow base and pointed: "Eiffel tower" pattern

Broad, asymmetrically peaked or 'hyperacute' T-waves are seen in the early stages of ST-elevation MI (STEMI) and often precede the appearance of ST elevation and Q waves. They are also seen with Prinzmetal angina. T-wave inversions due to myocardial ischaemia or infarction occur in contiguous leads based on the anatomical location of the area of ischemia/infarction: Inferior = II, III, aVF.; Lateral = I, aVL, V5-6.; Anterior = V2-6.

Wellens' syndrome is a pattern of inverted or biphasic T waves in V2-V3 (in patients presenting with ischemic chest pain) that is highly specific for critical stenosis of the LAD. There are two patterns in Wellens' syndrome: Type 1 Wellens' T-waves are deeply and symmetrically inverted. Type 2 Wellens' T-waves are biphasic, with the initial deflection positive and the terminal deflection negative.

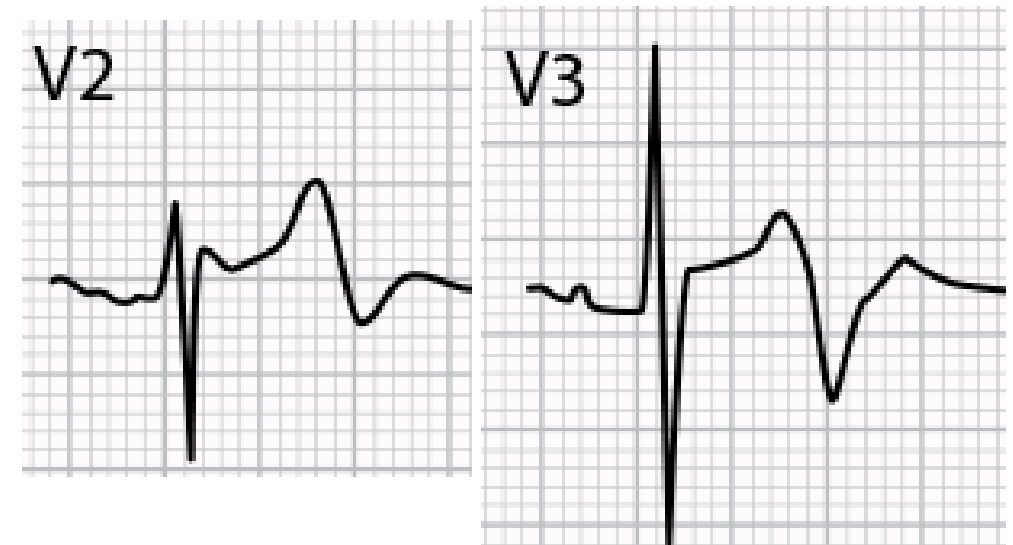
Wellens' Syndrome or de Zwan's syndrome (**de Zwan 1982**): Acute Coronary T-wave Syndrome Due To Proximal Obstruction of the LAD

Type 1 Wellens' T-waves



Negative and symmetrical T waves

Type 2 Wellens' T-waves



Biphasic plus-minus T wave

Wellens' syndrome is a clinic-electrocardiographic entity defined as a set of signs and symptoms occurring in the setting of unstable angina with normal or minimally increased necrosis biomarkers and associated with a characteristic ECG pattern recorded often in the absence of ischemic pain. These findings suggest a proximal high-grade lesion of the anterior descending artery and a need for invasive management to minimize the threat of evolving into an extensive anterior infarction or sudden cardiac death.

The electrocardiographic pattern is characterized by:

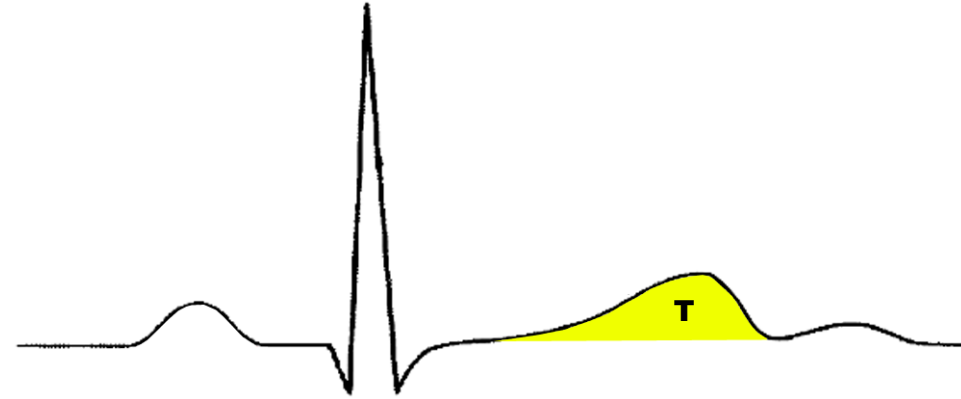
1. T waves indicative of ischemia characterized by deep, symmetrical negative waves (>2 mm) with a wide base resembling “seagull wings” in precordial leads V2, V3 or from V1 to V4 (Type 1 or A). In one study the sensitivity of these ECG findings for a significant LAD lesion was 69%, the specificity was 89%, and the positive predictive value was 86% (**Haines 1983**). This pattern of dynamic T wave inversion in the anterior leads is observed in reversible left ventricular dysfunction (stunned myocardium), whether ischemic or non-ischemic. Although the pathophysiology remains uncertain researches suggest that it is the consequence of myocardial edema (**Migliore 2011**). The Wellens' ECG pattern has also been described in the settings of a myocardial bridge, coronary artery dissection, cholecystitis and Takotsubo syndrome (**Migliore 2011**). Inverted T waves in the right precordial leads have also been observed as a normal finding in children and in some older subjects (so-called persistence of the juvenile T wave pattern). Symmetrical, inverted T waves in the precordial leads occur in many other clinical conditions including complete and incomplete right bundle branch block, acute pulmonary embolism, hypertrophic cardiomyopathy of the apical or Japanese variety, sudden increase in intracranial pressure (e.g., subarachnoid hemorrhage with bizarre, deeply inverted T waves), and myocardial ischemia or infarction. Inverted T waves in lead III is often a normal variant. New inverted T waves compared with a prior ECG are always considered to be abnormal. Pathological inverted T waves are usually symmetrical, deep (>3 mm), and have a wide base looking like “seagull wings”. There is usually QTc interval prolongation as well.
2. Biphasic T waves of the plus-minus type in V2-3 (or from V1 through V4) are called type 2 or B of Wellens' syndrome.
3. Occasionally both T wave patterns are seen as in the present case
4. Non-elevated or only slightly elevated ST segments.
5. Normal R wave progression in the precordial leads (**Rinehardt 2002**).
6. Riera et al (**Riera 2008**) described a variant of this syndrome characterized by transient increase in R voltage in V2-V3 (prominent anterior QRS forces) thought to be due to left septal fascicular block, left-middle fibers/septal fascicule block or antero-medial divisional block. This type of fascicular block is mainly caused by a critical proximal lesion of the LAD (**Pérez-Riera 2016**).
7. Constant transient QT/QTc interval prolongation (**Migliore 2011**).

The T wave abnormalities in this syndrome are persistent and may remain for hours, days or weeks in the absence of angina pain. After anti-ischemic treatment or revascularization the T waves normalize (**Rinehardt 2002**).

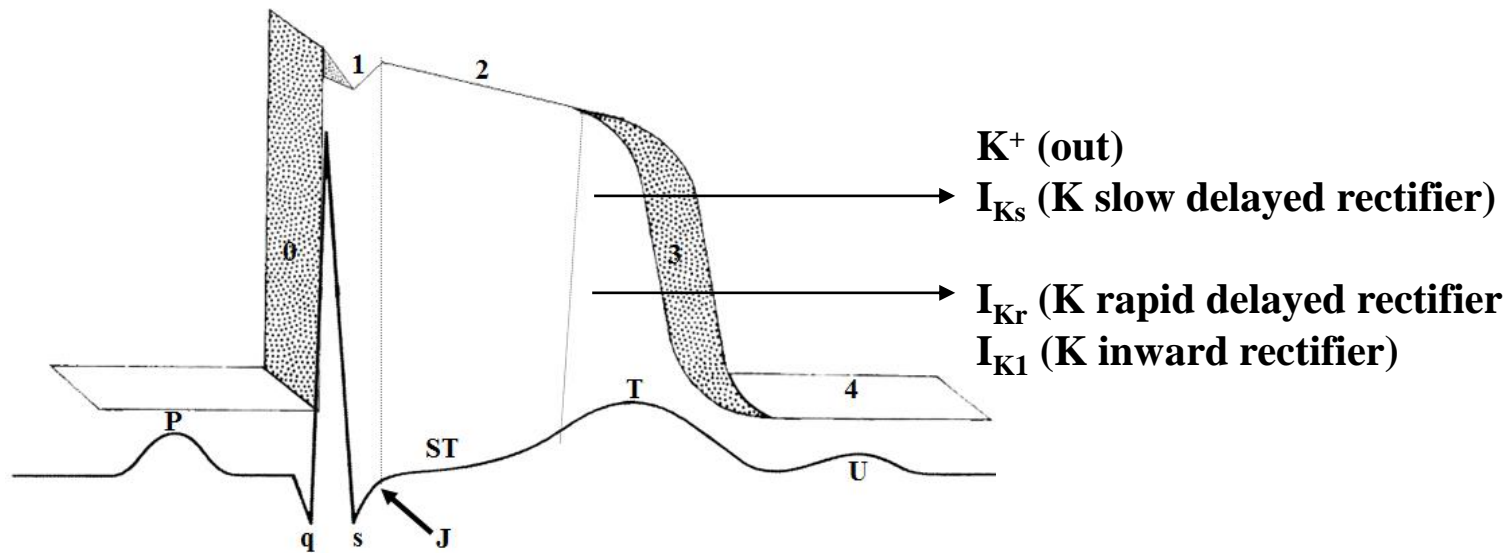
Normal T wave

Definition: First upward deflection after QRS complex. Represents: ventricular repolarization.

- Shape:** asymmetric with slow ascendant ramp and faster descendent. The normal T wave is *asymmetric* with the first portion(ascendent ramp) moving more slowly than the final portion(descendent ramp).



- Relationship between monophasic action potential and T wave in surface ECG:** it is coincident with phase 3 of AP.

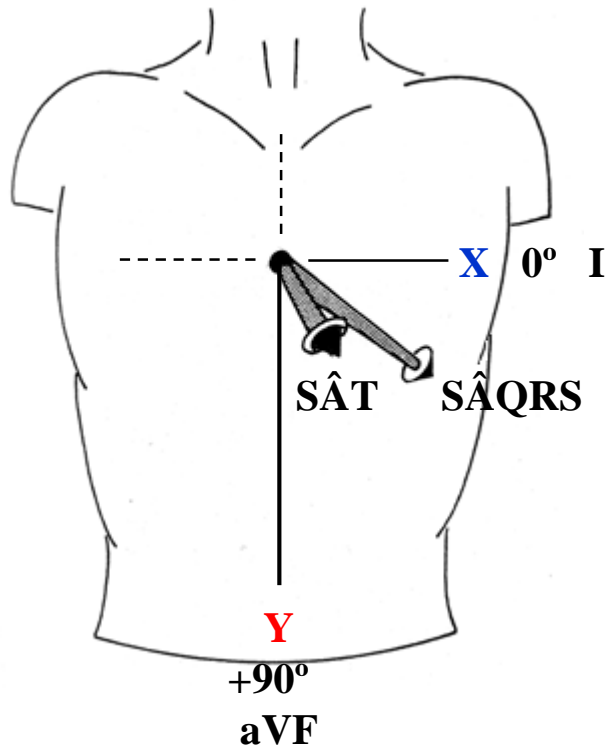


During phase 3 coincident with T wave Ca^{+2} channels close and delayed rectifier K^+ channels open to effect normal repolarization.

Normal voltage of T wave: 1/8 size of the preceding R wave; $< 2/3$ size of the preceding R wave; Height ≤ 10 mm. The maximal normal limit of T wave in the FP is 5 mm or 6 mm and for the HP 10 mm. About precordial leads, V_2 and V_3 have a greater voltage and the left ones, (V_5 - V_6) have lower voltage. Low T voltage changes may occur in the absence of any heart disease at all.

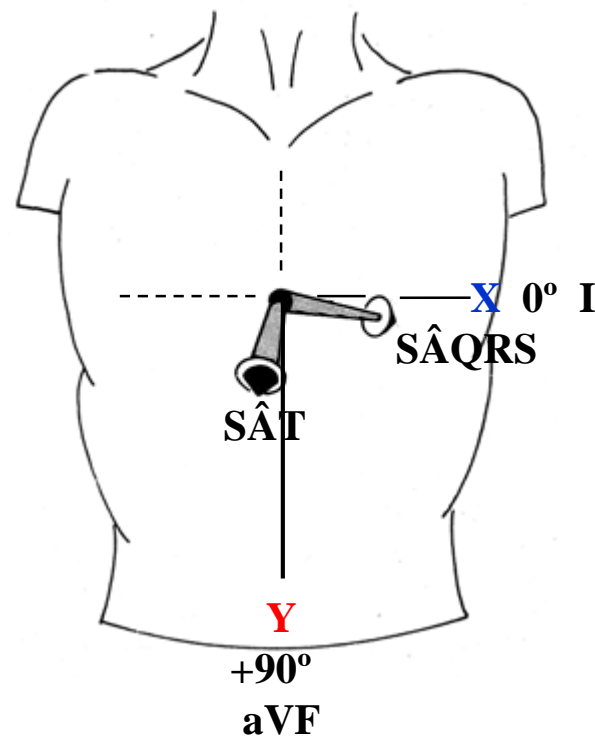
4. Normal T axis in the frontal plane and QRS-T angle in adults, elderly and children

In adults



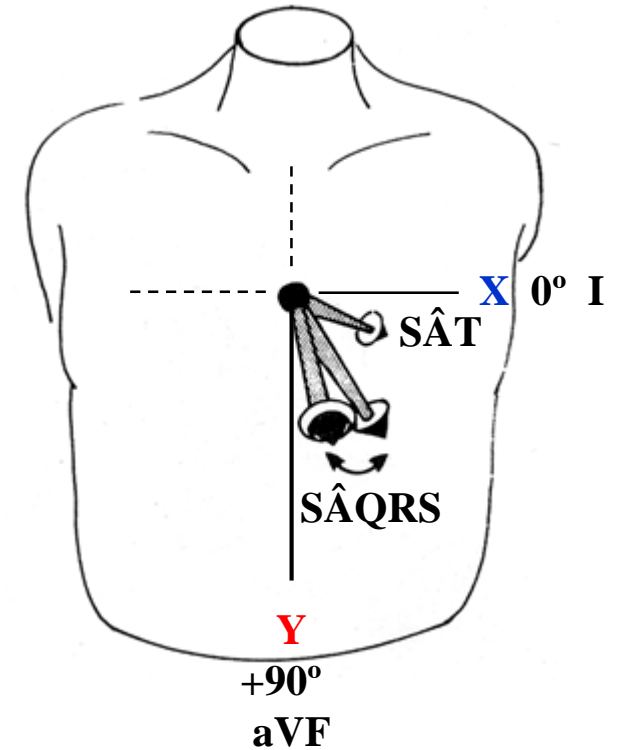
The angle between the SÂT & the SÂQRS is always $< 60^\circ$.

In elderly people



The angle between the SÂT and the SÂQRS is always wider: close to 90° .

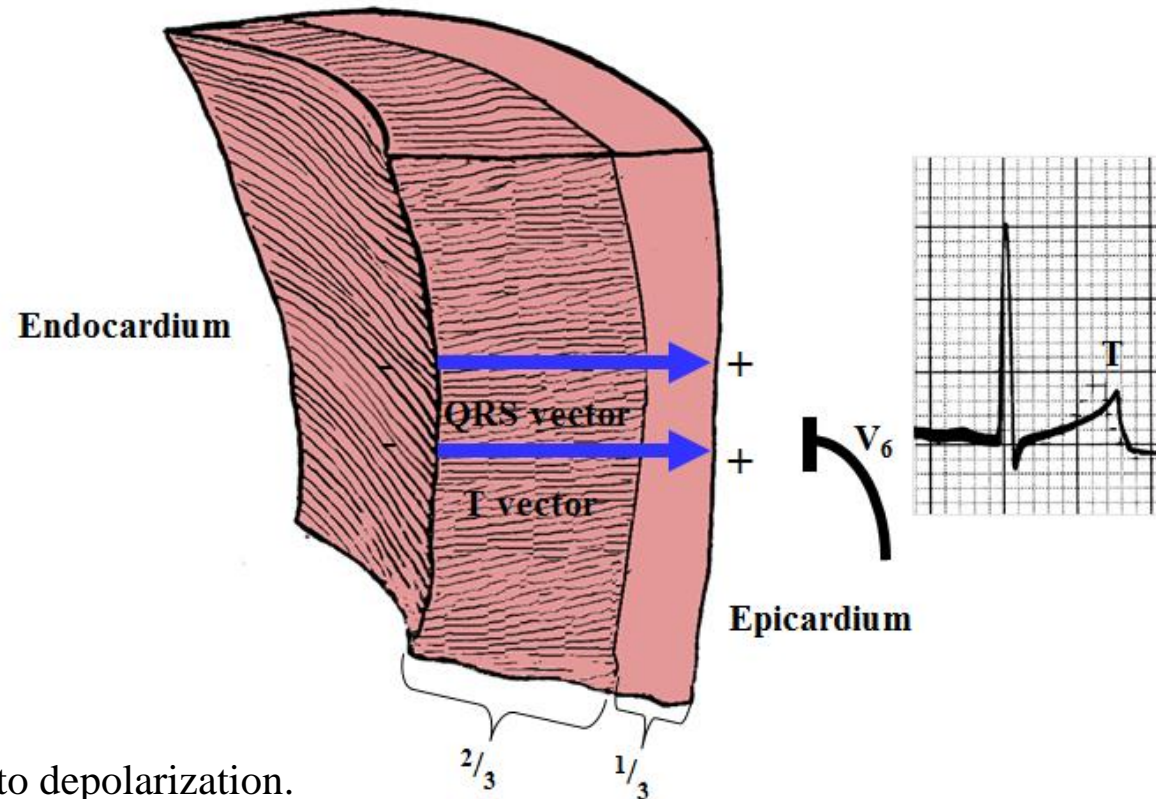
In normal children



The SÂQRS is more anterior and the SÂT more posterior: the angle could be wide.

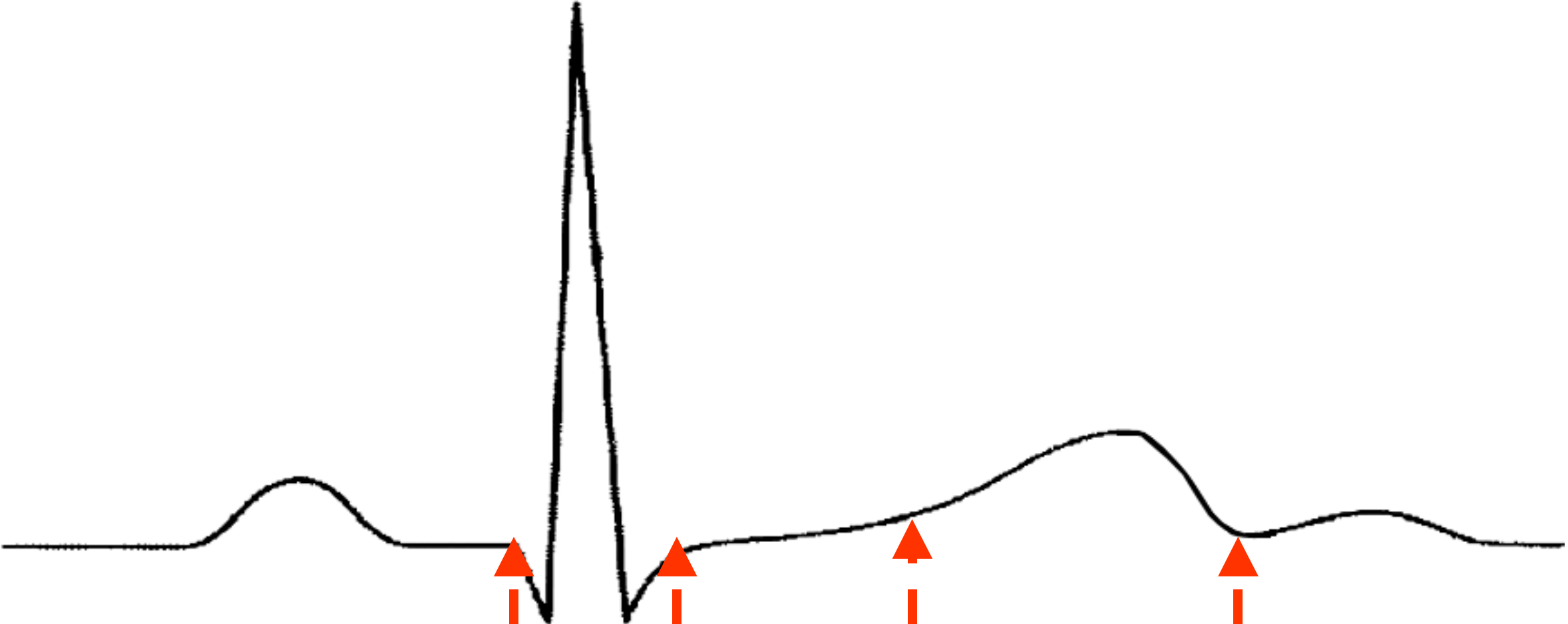
SÂT: it means axis of T wave for the ECG or T loop for the VCG. The acronym SÂ comes from English, and means S = spatial and Â = angle.
SÂQRS: it means axis of the QRS complex for the ECG or the QRS loop for VCG.

5. **T- polarity:** In general, T waves are in the same direction as the largest deflection of the QRS (normally the R wave). Negative in aVR. Inverted T waves in precordial leads V1, V2, V3 can be seen in normal, young athletes. Depolarization vectors (QRS) and ventricular repolarization (T wave) have similar directions, because in normal conditions, repolarization begins in the epicardium, while depolarization does it in the endocardium. As both phenomena are opposite, the polarities of the waves they represent are similar. The normal T wave is usually in the same direction as the QRS except in the right precordial leads. In the normal ECG, the T wave is always upright in leads I, II, V3-6, and always inverted in lead aVR. The other leads are variable depending on the direction of the QRS and the age of the patient. The T wave is the most labile wave in the ECG.



- Repolarization is an electrical phenomenon opposite to depolarization.
- In the ventricles, repolarization starts in the epicardium towards the endocardium and from the base to the point.
- It occurs during mechanical systole, a fact that explains the inversion of the sequence regarding depolarization.
- Repolarization (vector T), is electrically inverse to depolarization.
- The vector that is represented begins in the epicardium and it moves backwards, pointing its positive end (+) towards this region and thus, it gains positive charges towards the endocardium, where the origin (-) of the vector is located.

6) Normal T- wave duration: 100ms to 250ms (up to five times more than the ventricular depolarization).



QRS duration complex in frontal plane:

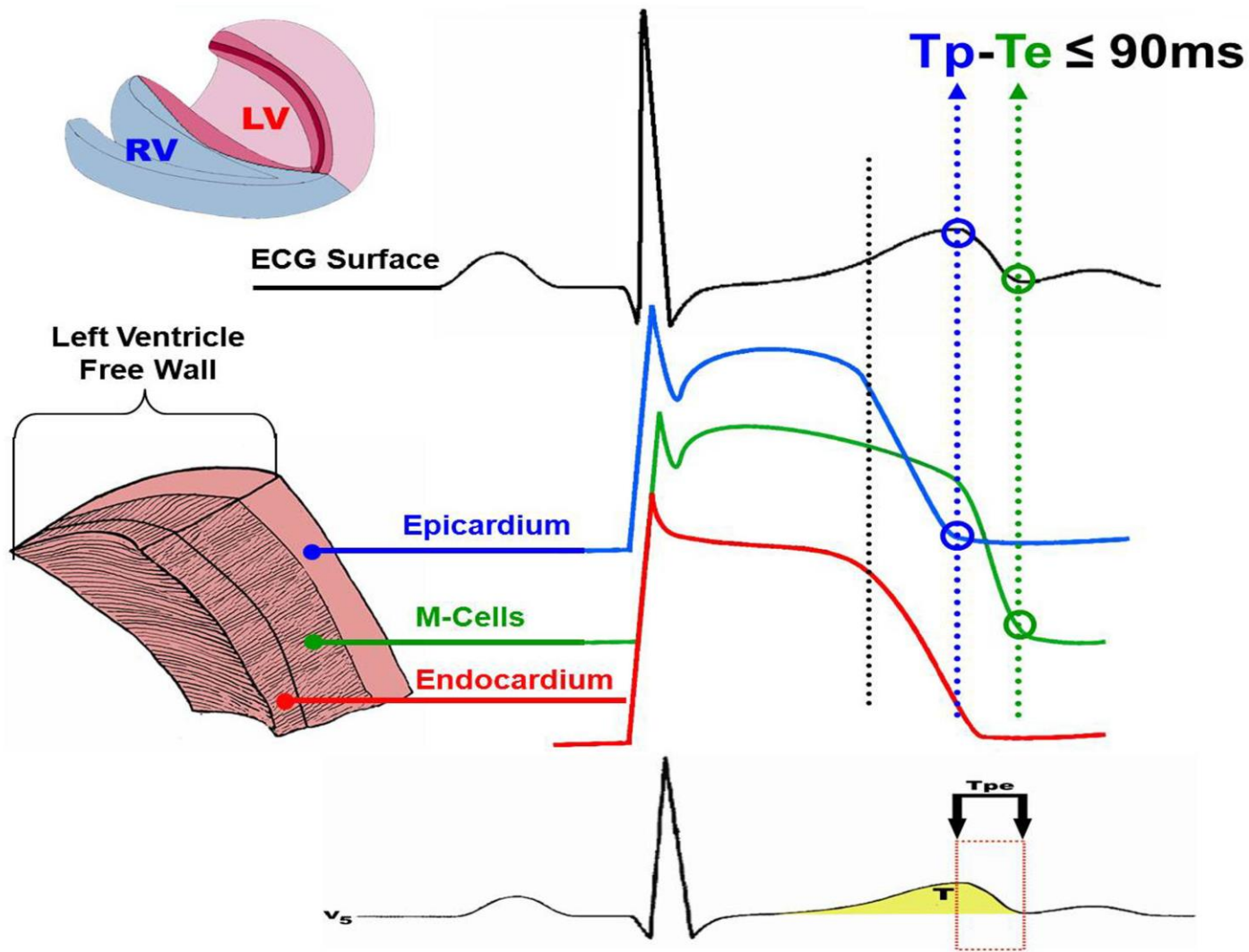
- Normal: 60 - 100ms
- Prolonged QRS duration (> 100ms):

≤ 100 ms

100 to 250 ms

7) **The normal *Tpeak/Tend interval (Tpe)*:** Representation of the Tpeak/Tend interval (Tpe). This is the interval elapsed from the apex to the end of T wave (Tpeak-Tend interval or Tpe)..

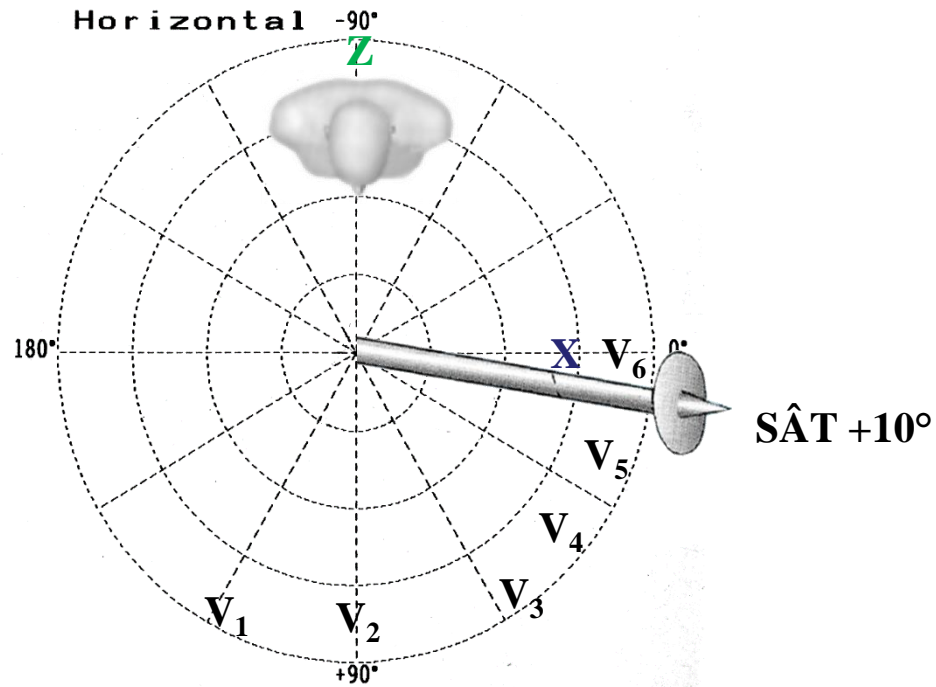
Outline of action potential in ventricular wall thickness. Differences in epi, meso and endocardium action potential profile of ventricular contractile cells in wall thickness: epicardium, mesocardium and endocardium: heterogeneity. The heterogeneous character of action potentials is clearly observed in the 3 areas.



Tpe may correspond to transmural dispersion of repolarization and consequently, the amplification of this interval is associated to malignant ventricular arrhythmias. The normal value of Tpeak/Tend interval (Tpe) is 94 ms in men and 92 in women when measured in the V5 lead. In congenital SQTS this parameter is $> 92\text{ms}$ in women and $> 94\text{ms}$ in men (measurement in V5).

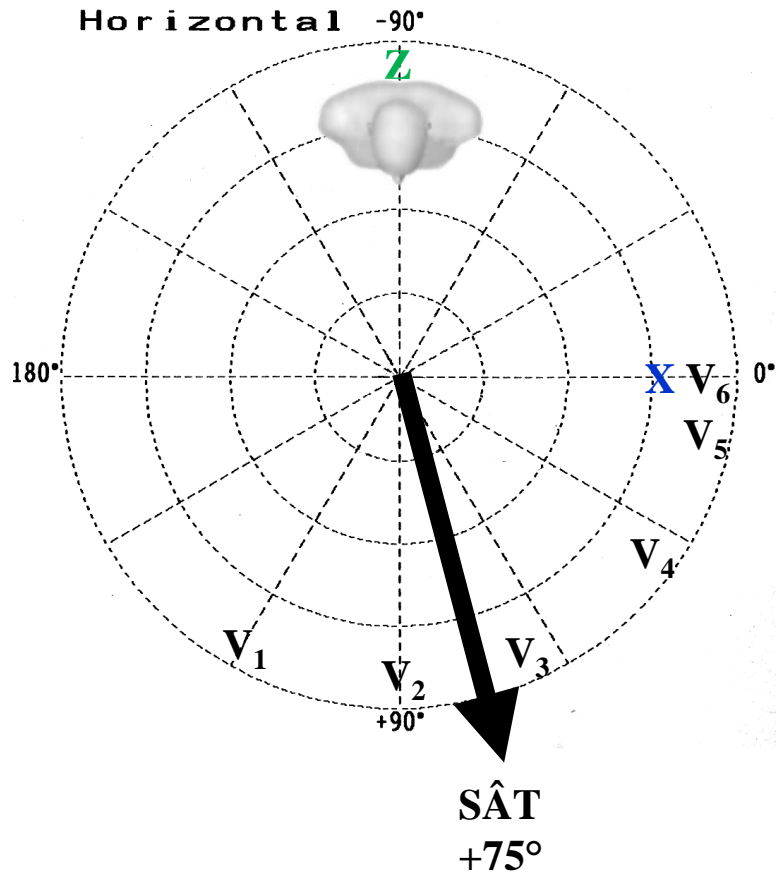
T wave axis or $\hat{S}\hat{A}\hat{T}$ polarity in the HP in normal adults, newborn babies, at the moment of birth, 1 to 6h of life and after 72h of life

$\hat{S}\hat{A}\hat{T}$ in the HP in normal adults it is heading to the left and slightly to the front and is very close to V_6 (0°).



T wave is always positive from V_3 to V_6 ; generally positive in V_2 and frequently negative in V_1 . In normal adults, invariably the ventricular repolarization vector (T vector) is heading to the left and usually discretely to the front near the $+10^\circ$.

SÂT in the HP at the moment of birth

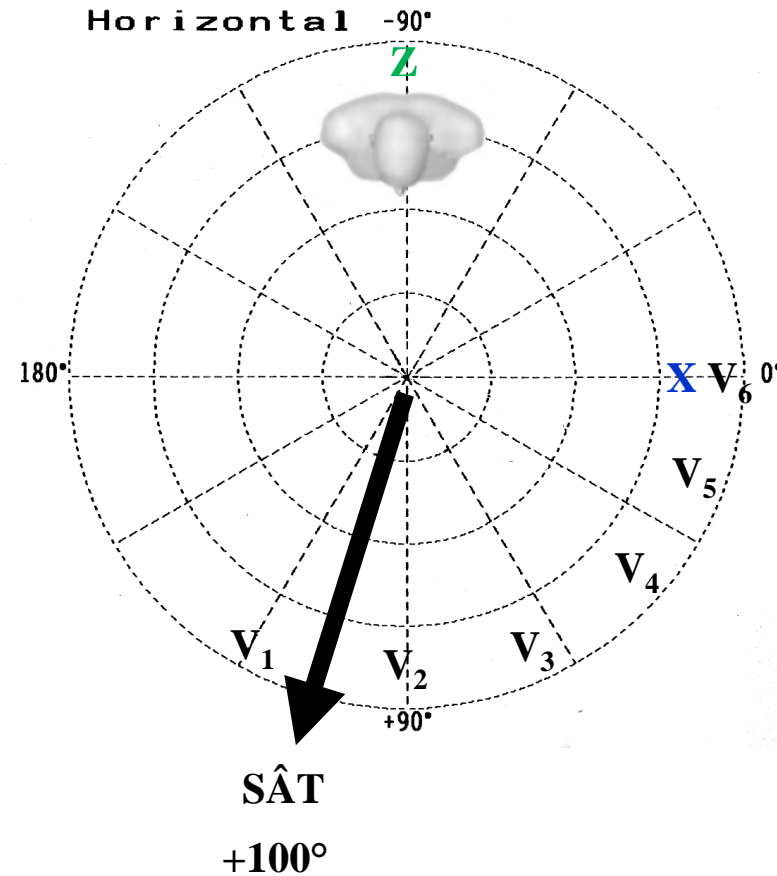


SAT in the HP at the moment of birth points to the front and to the left, near the V_3 lead: $+75^\circ$.

Observation: In premature babies, T loop in the HP is heading backwards and to the left.

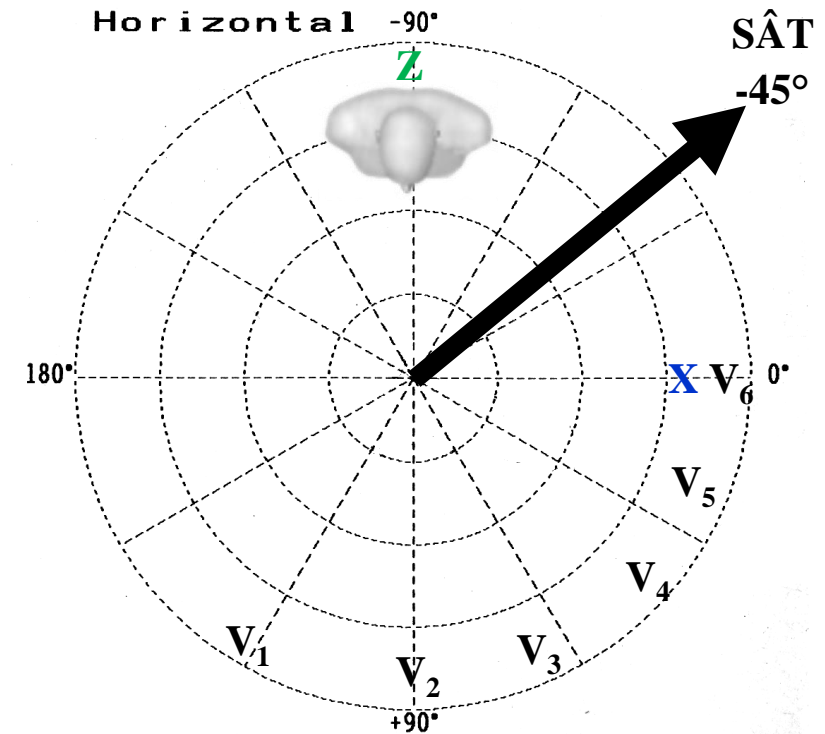
Positive T wave in V_1 after three days of life and up to 6 years, when the R/S ratio in this lead is greater than 1, constitutes an important sign of RVH.

SÂT in the HP between 1h to 6h of life



Between 1h and 6h of life, SÂT dislocates even more to the right, close to $+100^\circ$. Therefore, occasionally the T wave may be negative in V_6 . (SÂT in $+100^\circ$).

SÂT in the HP after 72h of life



After 72h of life, it heads backward and to the left, and SÂT is around -45° . From this location, SÂT dislocates progressively to the front.

- In infants from one to six months, T wave: negative T wave in V_1 . QRS/T angle: greater than 60° .
- In children from six months to three years old, T wave has posterior and left direction. QRS/T angle: it may be normal up to 90° in the both planes frontal and horizontal planes.
- In children from three to eight years old, the ST segment is isoelectric and horizontal at the same level as the PR and TP intervals. An elevation of 1 mm may be admitted in the limb leads and 2 mm in left precordial leads.

The voltage of the maximal T wave in V_5 is 14 mm and in V_6 of 9 mm.

In the FP, SAT is between 0° and 90° .

In the HP, SAT may be both posterior and anterior, and after 10 years of age, it progressively becomes more anterior. QRS/T angle is smaller than 60° .

- In elderly, QRS/T angle progressively longer both in the frontal plane and in the horizontal plane due to aging.

Voltage of the maximal vector of T even more reduced;

Spatial orientation of the maximal vector of T more to the front;

The angle between $\hat{S}AT$ and $\hat{S}AQRS$ is always wider than in adults: near 90° .

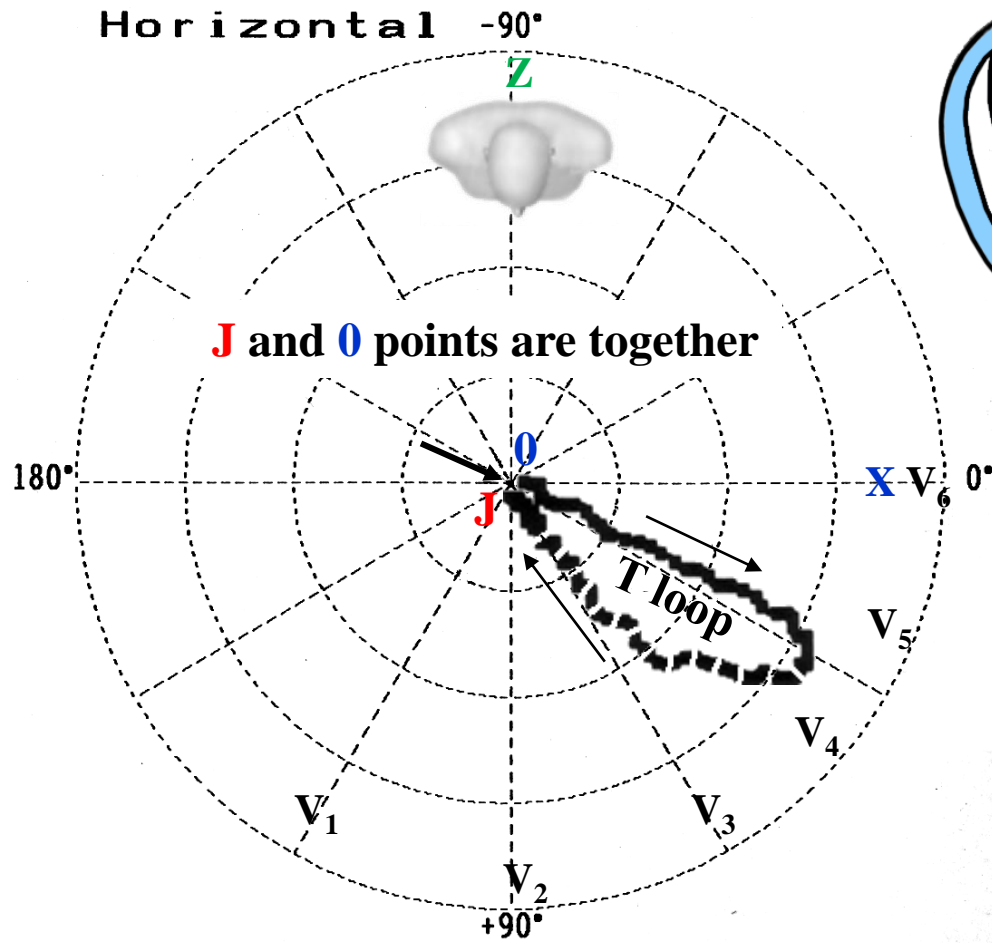
In non-elderly adults, the angle between $\hat{S}AT$ and $\hat{S}AQRS$ is always $< 60^\circ$ in the frontal plane.

T-loop characteristics regarding morphology, magnitude of maximal vector, rotation, recording velocity of efferent and afferent limbs, location and QRS/T angle

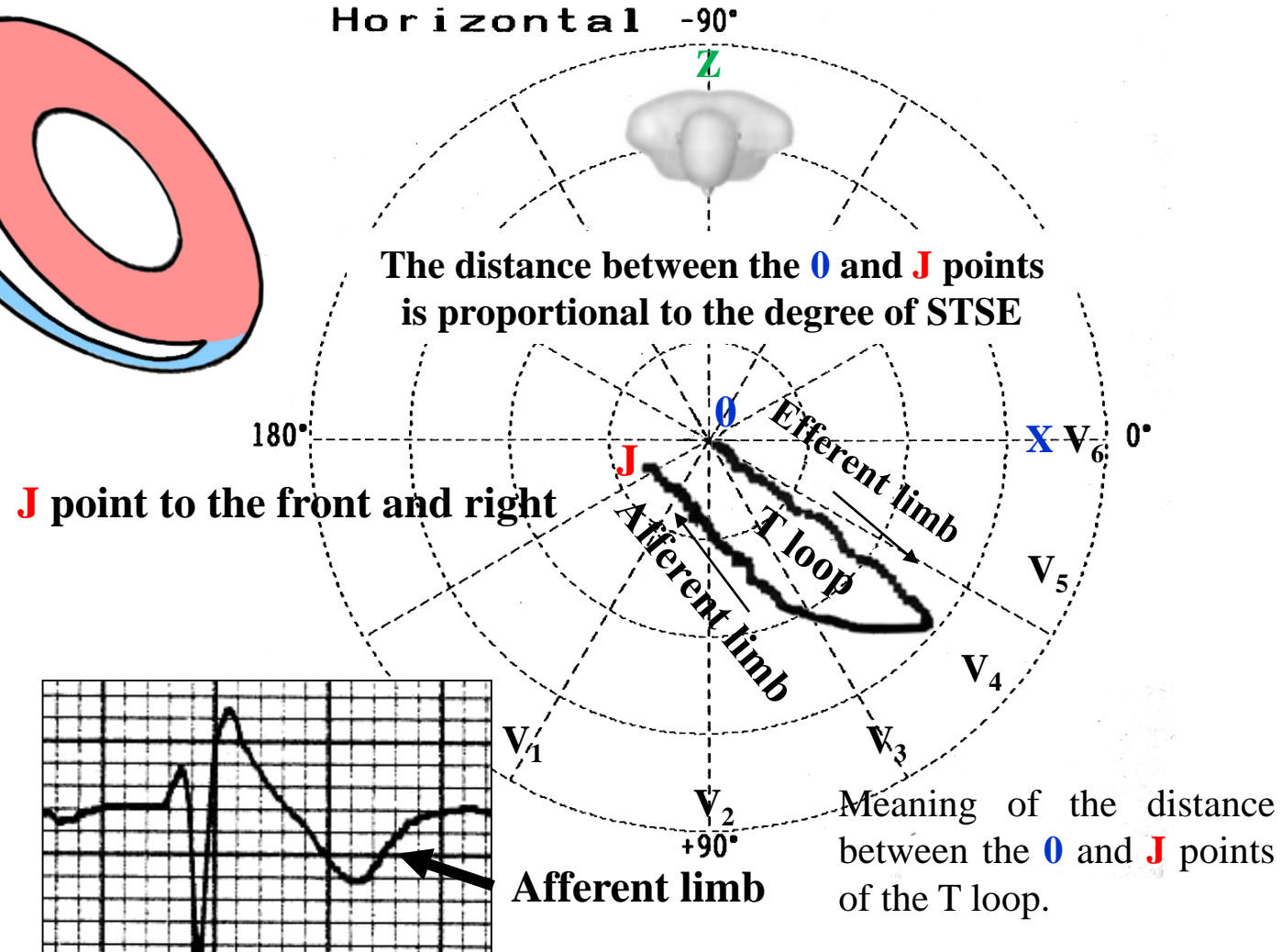
- 1) **Morphology:** it tends to be elliptic;
- 2) **Magnitude of maximal t vector:** this is obtained from the 0 point up to the farthest point of the T loop. The maximal normal magnitudes in the three planes are:
 - FP:** 0.75 mV.
 - HP:** 0.75 mV.
 - RSP:** 0.70 mV.
- 3) **Rotation:**
 - FP:** variable: clockwise or counterclockwise.
 - HP:** counterclockwise exclusively. Clockwise rotation in this plane indicates heart disease.
 - RSP:** clockwise. **LSP:** counterclockwise.
- 4) **Velocity of recording of its efferent and afferent limbs:** the efferent limb is always recorded more slowly than the afferent one;
- 5) **Location:** usually, left and inferior, and to the front in adults.
 - FP:** in left inferior quadrant.
 - HP:** in left anterior quadrant.
 - RSP:** in anteroinferior quadrant.
- 6) **QRS/T angle:** $< 75^{\circ}$. Usually smaller in the FP than in the HP

Characteristics of **0** and **J** points with the ST segment either normal or presenting elevation or depression

When ST segment is not elevated or depressed



When ST is elevated, the J and 0 points do not coincide



Conclusion: the greater the distance between the two points (**0** and **J**), the greater the elevation or depression of the ST segment.

Abnormal T wave changes

It can be primary or secondary. Primary T wave change refers to abnormal repolarization.

Secondary T wave changes are caused by QRS changes. T wave changes caused by bundle branch block or ventricular hypertrophy are secondary. The association of inverted T waves with increased work of the LV was described for the first time in 1929 (**Barnes 1929**). The term “typical strain” was introduced in 1941 (**Kaplan 1941**) and referred to a specific ST-T abnormality, which was attributed to an increased hemodynamic burden. It consisted of J-point depression, upwardly convex down-sloping depression of the ST segment, followed by asymmetrical inversion of the T wave. It is now appreciated that electrocardiographic LVH with ST-segment and T-wave abnormalities occurs in conditions that are not necessarily caused by increased hemodynamic work, as in patients with dilated or HCM, and that lesser degrees of ST-T abnormalities than the “typical strain” pattern are associated with LVH. Thus, the terms “strain” and “typical strain” are discouraged, and the term “secondary ST-T abnormalities” is preferred. The presence of ST-T-wave abnormalities provides major support to a diagnosis of LVH that would otherwise be based only on increased QRS voltage, and there is evidence to suggest that the presence of ST-T abnormalities are associated with larger values for LV mass and higher risks of cardiovascular complications and mortality than an increase in QRS voltage alone (**Kannel 1970; Okin 2004**). However, the evidence is insufficient to indicate whether the “typical strain” pattern has more significant clinical implications than lesser ST-T abnormalities, whether ST-T abnormalities should be used to diagnose LVH in the absence of any QRS voltage criteria, or whether the presence of ST-T abnormalities should allow modification of QRS voltage criteria.

Tall peaked T waves

Electrolyte imbalance = Hyperkalemia causes tall peaked T waves. overall maximum of 15 mV but this is not sensitive. T wave looks like an isosceles triangle.

Low voltage T waves

Hypokalemia causes low voltage T waves and prominent U waves. T waves less than 1mV in the limb leads and less than 2mV in the precordial leads.

Low T voltage and sagging or flattened ST segments. These changes may occur in the absence of any heart disease at all.

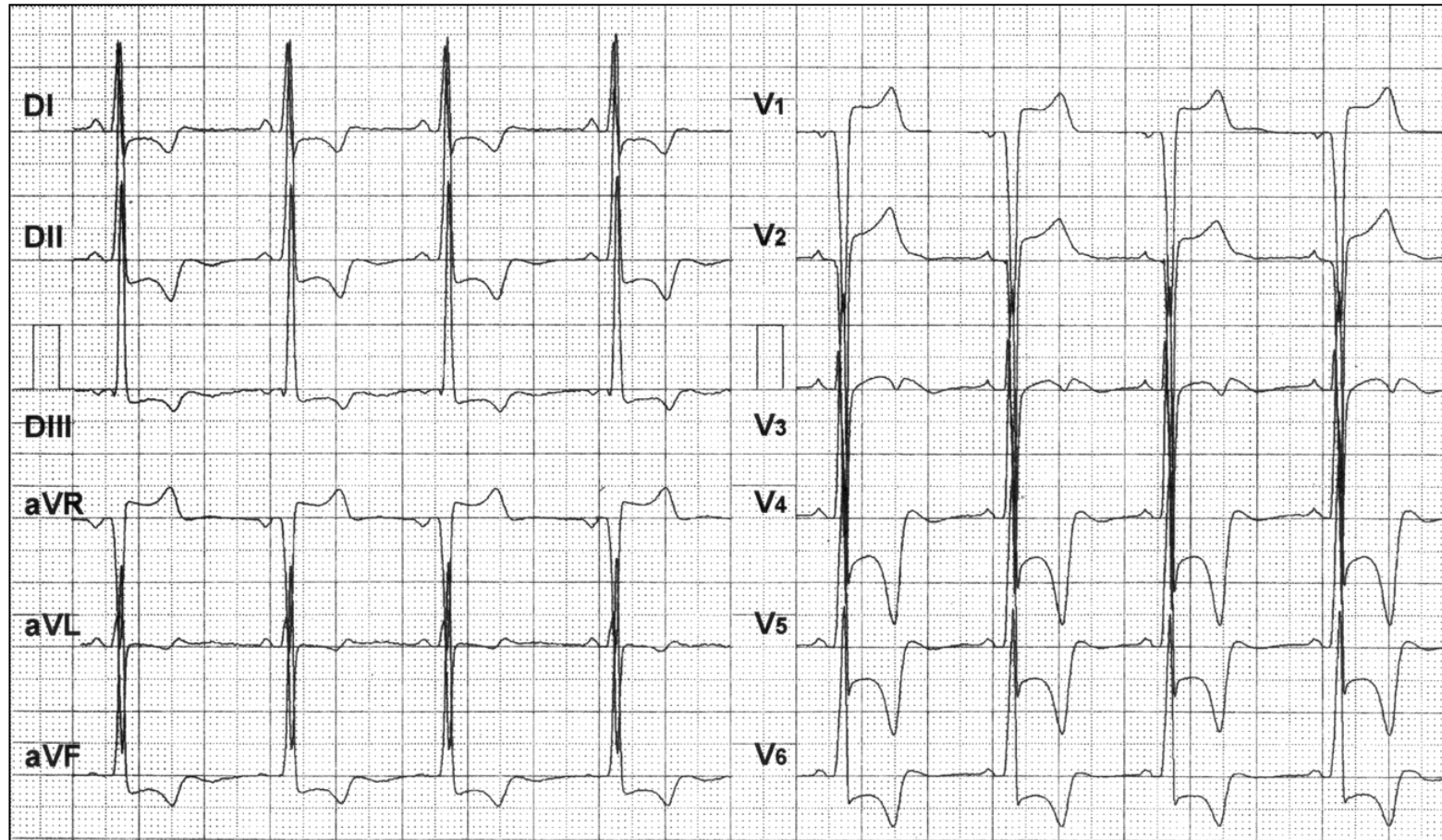
Inverted T waves

Inverted T waves that are symmetrical, "round-shouldered" can be caused by coronary ischemia. especially when it occurs in a pattern as previously described for ST segment changes.

Inverted T waves in precordial leads V1, V2, V3 can be seen in normal, young athletes, as well as CNS diseases.

T waves in Apical hypertrophic cardiomyopathy Yamaguchi syndrome

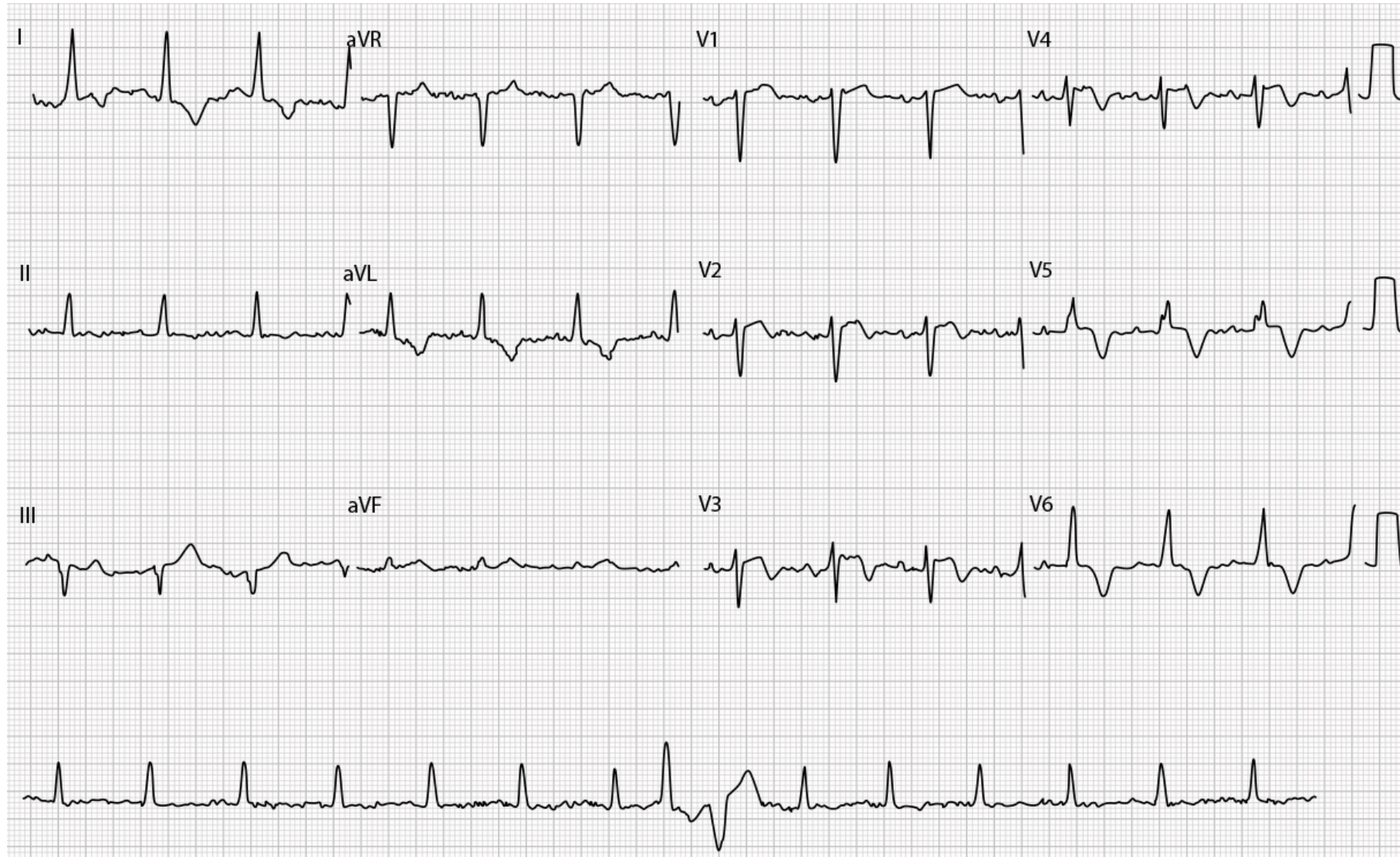
Name: SFS; Age: 15 y/o; Sex: M; Race: W; Weight: 70 Kg; Height: 1.72 m; Date: 03/31/98; Medication in use: β -blockers.



Clinical/echocardiographic diagnosis: Non-obstructive hypertrophic cardiomyopathy. Diastolic thickness of interventricular septum in the apical region greatly increased (32 mm): Ap-HCM.

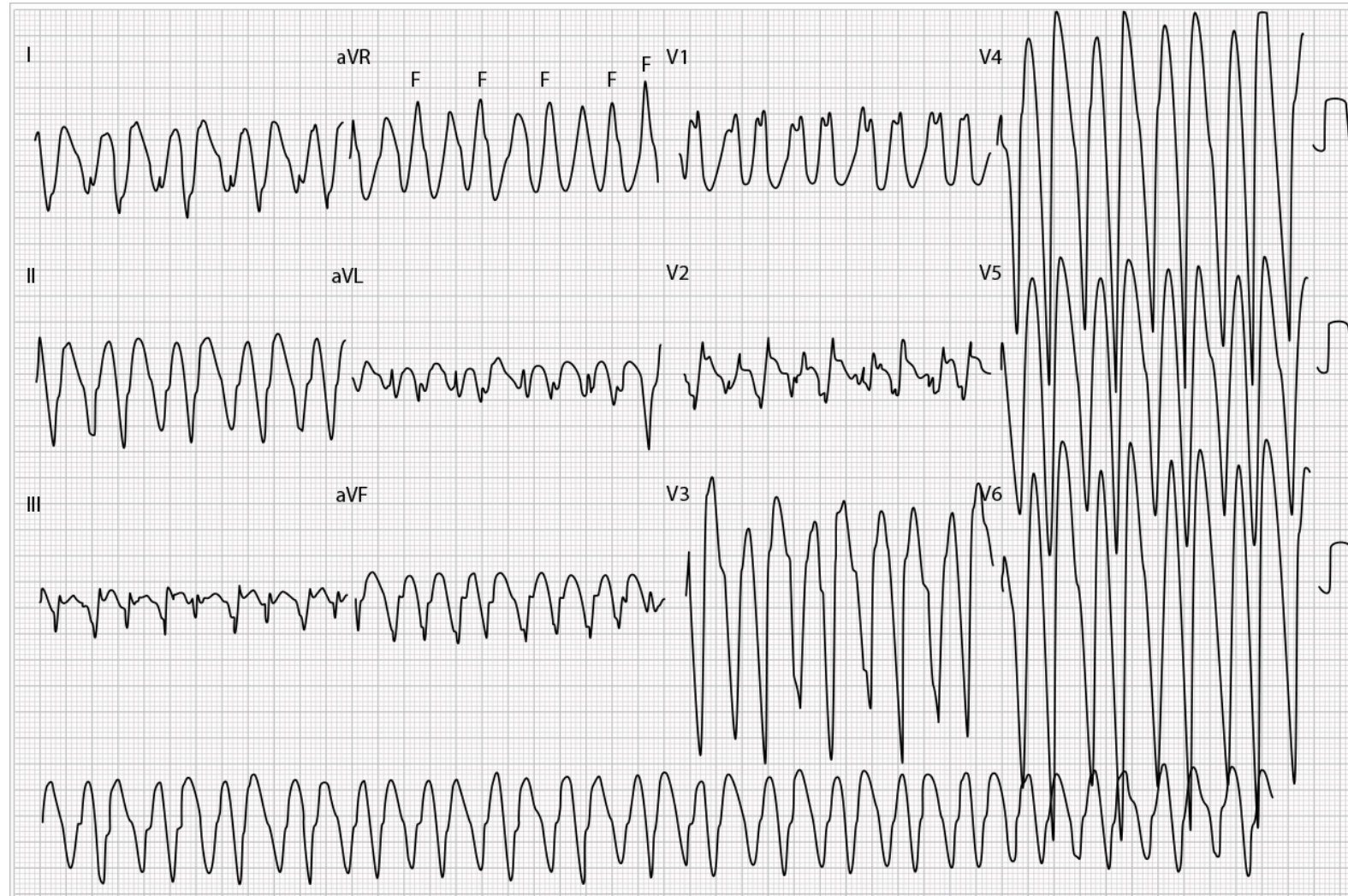
ECG diagnosis: sinus rhythm, LAE, normal QRS axis on FP (+50°), LVH (positive Sokolow-Lyon index: S of V1 + R of V5 \geq 35 mm or 3.5 mV in adults older than 30, 40 mm or 4.0 mV between 20 and 30 years (Sokolow-Rapaport) and > 60 mm between 16 and 20 years and > 65 mm between 11 and 16 years), QS pattern in V1-V2 contrasting with abruptly prominent QRS anterior forces in intermediate leads (V3-V4), R wave of V5 or V6 > 26 mm and strain pattern of ventricular repolarization from V4-V6, high lateral (I aVL), and inferior wall (II-III-aVF) leads (wide QRS/ST/T angle: near 180°).

Hypertrophic Cardiomyopathy mimicking Acute Coronary Syndrome (ACS)



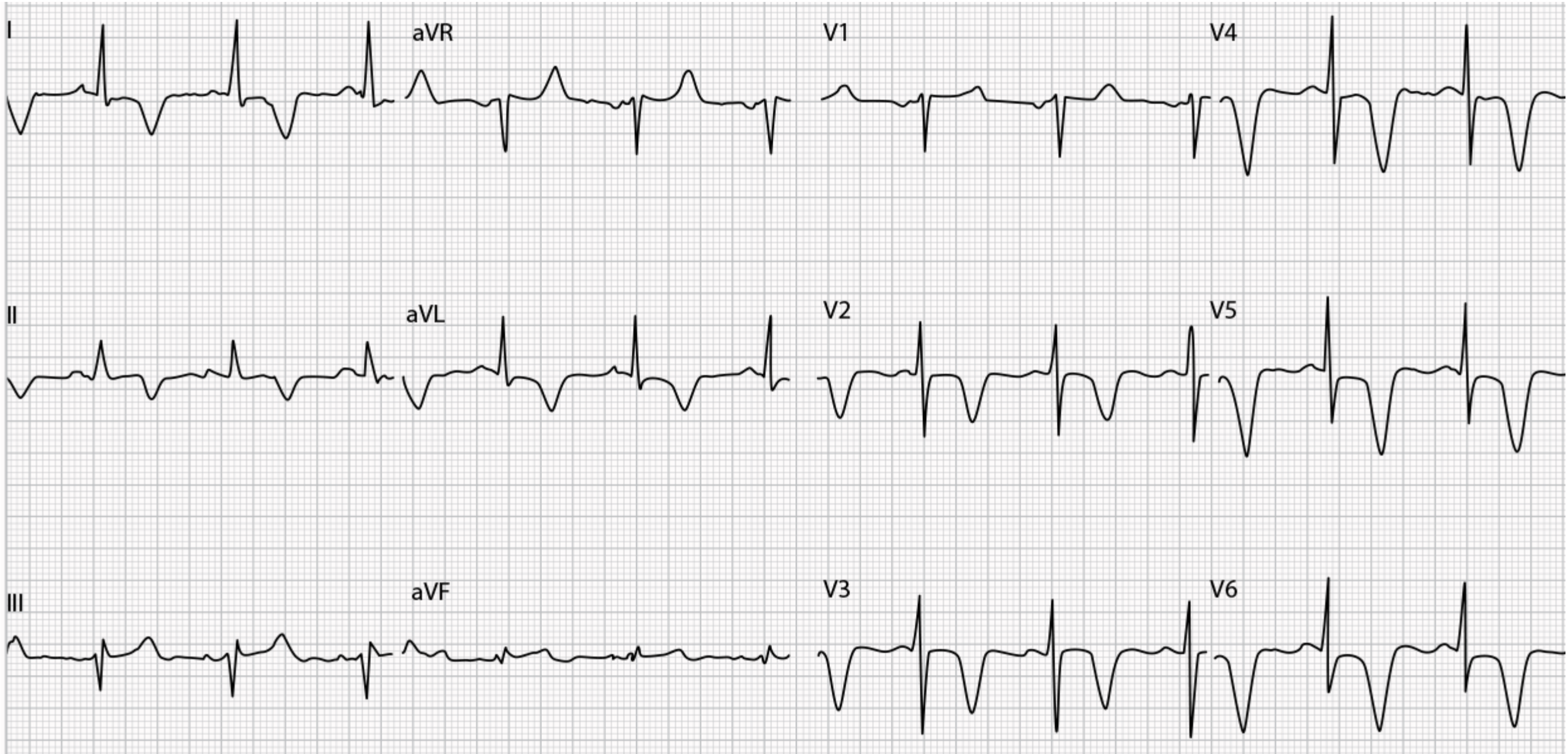
After reversion to sinus rhythm T wave inversion is seen in the anterolateral leads; ST segment elevation is noted in V2-V3 with plus/minus T waves (ECG pattern of Wellens syndrome). The left leads I and V5-V6 show a systolic overload pattern of ventricular repolarization characterized by convex upward ST segment depression and negative asymmetric T waves. Negative T waves with a slower downsloping portion are called the “left ventricular strain pattern”.

Hypertrophic Cardiomyopathy mimicking Acute Coronary Syndrome (ACS)



The ECG shows a fast and irregular wide-QRS tachycardia (beat to beat variation within 188-250 bpm); SAQRS between -90° and $\pm 180^{\circ}$ with positive QRS in lead aVR (“no man’s land” or “northwest quadrant” axis); distance from QRS onset to the nadir of S > 100 ms (Brugada sign); absence of RS pattern in precordial leads; QS complexes in I and V6; notched R wave pattern in V1 (the “bad rabbit ear” type with the first apex \geq voltage of the second) and the presence of clear fusion beats (hybrid QRS complexes) in a variable degree (labeled ‘F’). These findings are all compatible with ventricular tachycardia (VT).

T waves in Takotsubo cardiomyopathy (TCM)



Electrocardiographic diagnosis: Persistent deeply negative T waves in anterolateral wall (V2 to V6, I and aVL) and II (second stage) in spite of the regression of ventricular dysfunction. These ECG findings are very important in differentiating TCM from acute myocardial infarction.

The electrocardiogram in TCM is characterized by circumferential subepicardial ischemia (**Sclarovsky 2010**). These ECG changes are significantly different from those that occur in acute segmental transmural ischemia characteristic of ST segment elevation MI (STEMI). Although some segmental contractile alterations (apical dyskinesis and basal hyperkinesis) occur in TCM, ST segment elevation is more diffuse in comparison to STEMI. This paradox can be explained by considering the electrophysiological and molecular alterations.

The electrocardiographic pattern of TCM has 3 successive stages or phases (**Kosuge 2010; Bybee 2004; Sclarovsky 2010; Tsuchihashi 2001; Bybee 2007; Kurisu 2004**).

- **First stage:** characterized by discrete ST segment elevation, usually in the precordial leads but also sometimes in the lateral and inferior leads. The magnitude of ST elevation is usually less than ST segment elevation in STEMI. T waves are tall but do not exceed 12-15 mm as is sometimes seen in STEMI where they may exceed 18 mm. The maximal ST segment alteration usually occurs in leads V3-5.
- **Second stage:** seen after 2-3 days; ST segment elevation resolves with appearance of diffuse, deep and inverted T waves except in lead aVR where T waves are positive. The presence of positive T waves in aVR is a valuable sign in differentiating TCM from myocardial infarction. The non-segmental distribution of T wave alterations is a characteristic of this syndrome. The QT and QTc intervals may also be prolonged. Pathological Q waves are rarely seen.
- **Third stage:** T wave inversion and QT prolongation typically resolves after 3-4 months, but in some cases these changes may last up to 1 year. Resolution of changes may sometimes occur earlier after 3-4 weeks,

The combination of ST segment depression in aVR along with absent ST segment elevation in V1 has 91% sensitivity, 96% specificity and 95% predictive accuracy for TCM (**Kosuge 2010**).

A summary of the significant electrocardiographic criteria for diagnosis is indicated below (**Omar 2013**).

1. **Absence of ST segment elevation in V1**
2. **Absence of reciprocal changes in inferior leads**
3. **Presence of ST segment elevation in inferior leads, especially in II**
4. **Sum of ST segment elevation in V4-6 ÷ V1-3 ≥1**
5. **ST segment depression in aVR.**
6. **Deep negative T waves associated with prolonged QTc.**

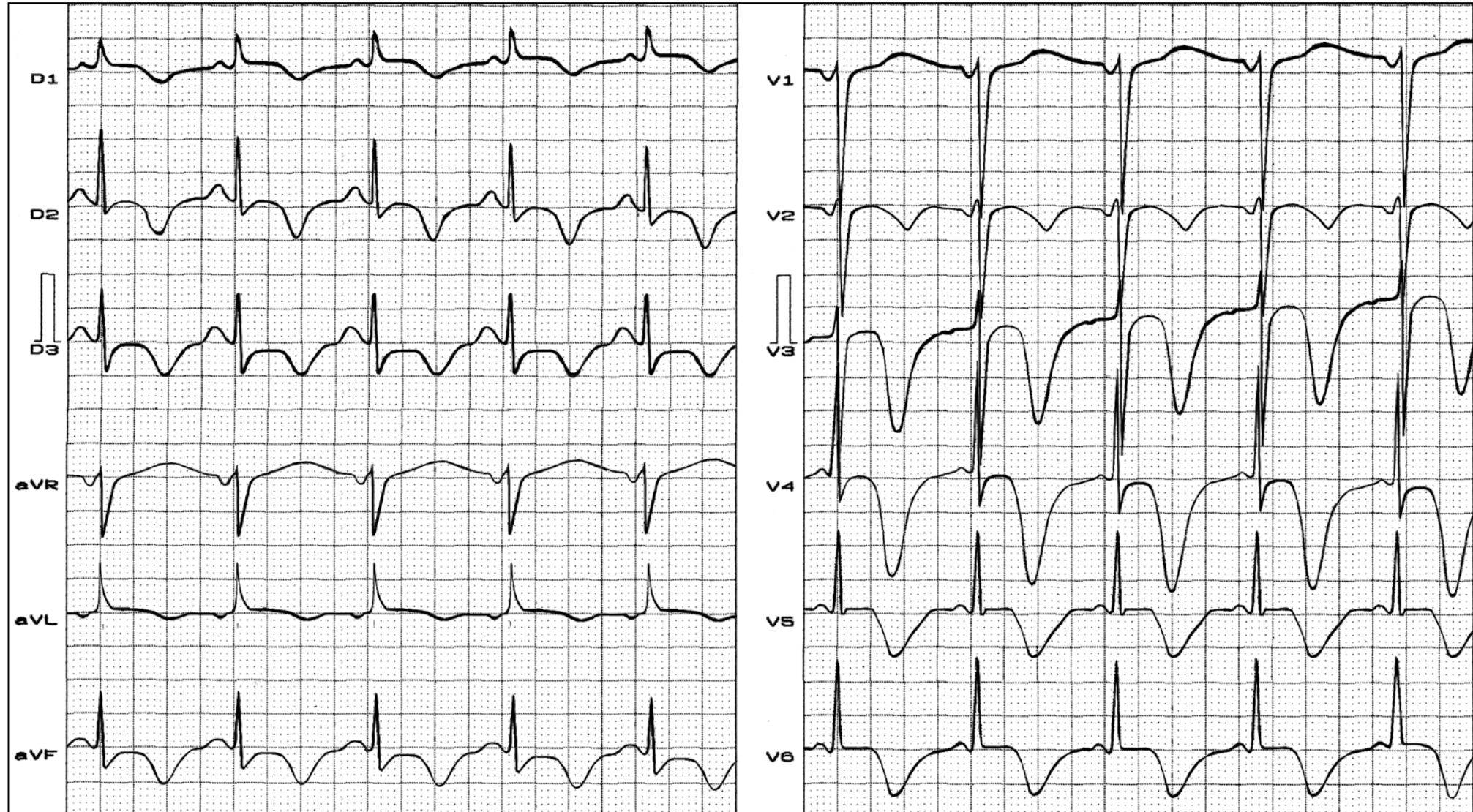
Another characteristic of the negative T waves is that they remain negative in spite of regression of myocardial contractile dysfunction, unlike what happens in segmental ischemia where T waves became positive with the recovery of myocardial contractility. This evolution of ECG changes is illustrated in another case of TCM shown in figures 6A-6D.

Low QRS voltage and shortening of QRS duration are highly prevalent ECG signs in patients with Takotsubo syndrome. This is a reason why these ECG characteristics are useful in differentiating it from ACS during the first contact with the patient in the ED. This sign along with the echocardiogram and coronary angiography could be of great diagnostic importance (**Madias 2014**).

Malignant ventricular arrhythmias, including torsade de pointes (TdP) associated with QT prolongation, may occur in 8% of the cases, especially when $QTc > 500$ ms (**Madias 2011**). ICD implant should be considered in cases of persistent $QTc > 500$ ms with a previous history of syncope or cardiac arrest (**Sclarovsky 2010**). In a systematic review of TCM the incidence of late SCD is 0.5% (**Syed 2011**).

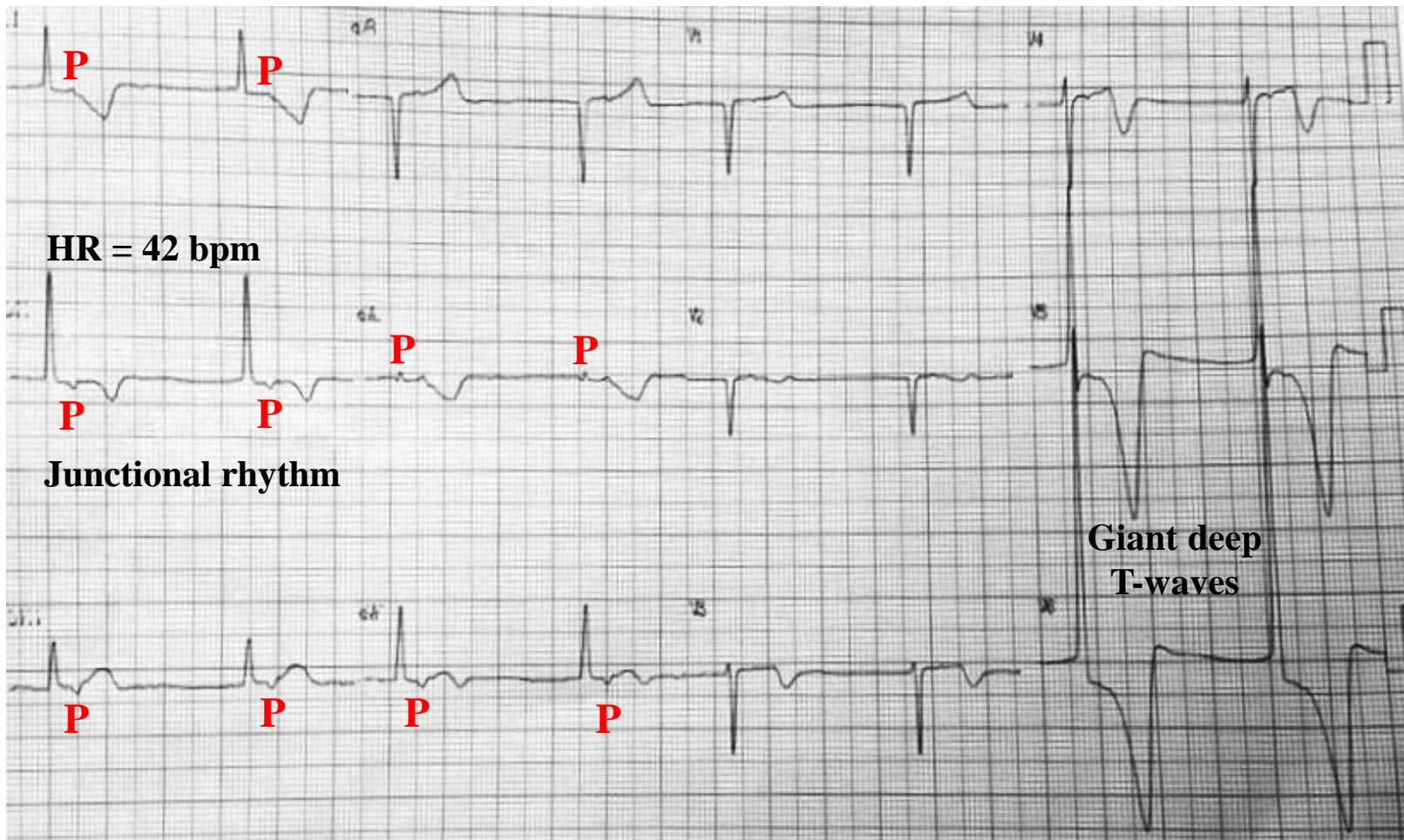
Deep T-waves in Subarachnoid hemorrhage

Name: EAD; **Age:** 68 y/o; **Sex:** F; **Race:** Caucasian; **Date:** 01/21/1999; **Weight:** 65 Kg; **Height:** 1.65 m; **Medication in use:** Enalapril + Hydrochlorothiazide



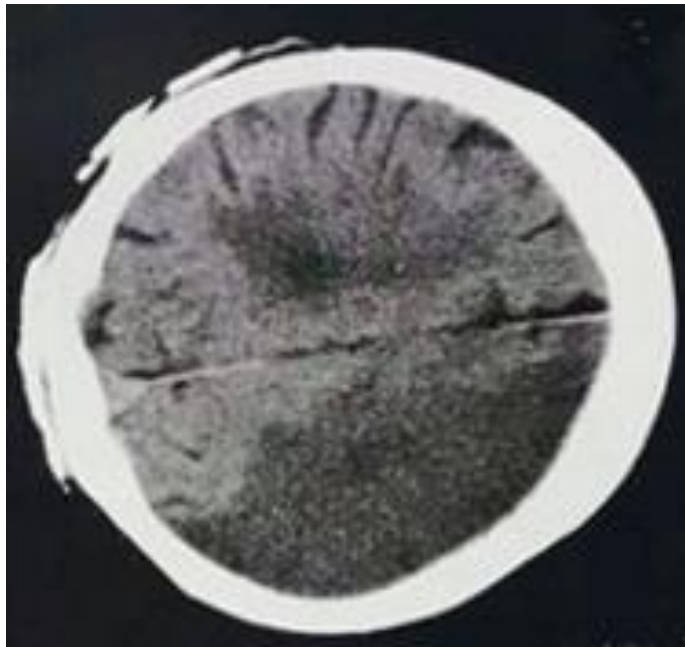
Clinical diagnosis: Subarachnoid bleeding.

ECG diagnosis: long QT interval, largely wide and inverted T waves: “giant T waves”.

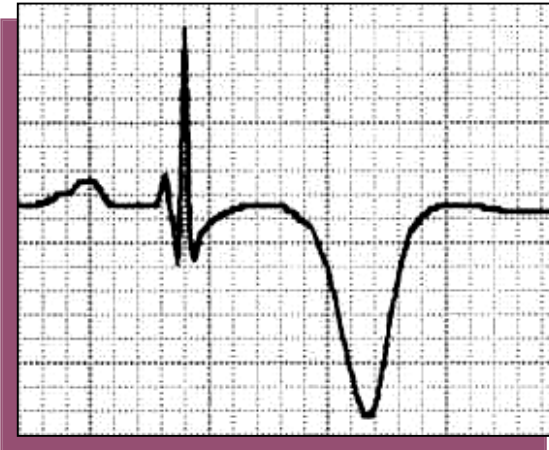


Junctional rhythm, HR=42 bpm, deep inverted T waves with broad base and prolonged QT interval with covering an area many times that of the QRS complex. The possible causes of this pattern are: Stokes-Adams attacks associated with complete AV block, coronary artery disease, extreme bradycardia, right ventricular hypertrophy and RBBB, metabolic disturbances, changes during coronary angiography, carotid artery occlusion, and other cerebrovascular accidents. In 1954, Burch et al (**Burch 1954**) drew attention to the occurrence of negative deep T wave developing during cerebral disorders. The abnormal T waves resemble very closely those occurring after Stokes-Adams attack. They have been encountered in patients suffering from subarachnoid haemorrhage, cerebral tumors, cerebral infarction and after neurological procedures. They can be reproduced in animals by hyperthalamic stimulation and abolished or prevented by nerve or cord section.

The typical T wave encountered in this electrocardiographic syndrome is a large wave with the same general configuration as found in association with myocardial ischemia (ECG below). The T wave is usually negative in the standard and chest leads, although large positive T waves are encountered in the precordial leads recorded from the right of the transition zone in lead V3. Some of the widest and largest T waves seen in clinical electrocardiography are recorded in this syndrome. With improvement of the clinical state, the T waves reverted to a pattern dependent upon the underlying cardiac state, normal or abnormal. In some cases, the T waves are so large that they occupied the entire interval between the R and P complexes; this is not always attributable to tachycardia, with associated shortening of the duration of electrical diastole. Some tracings contained large U waves which are usually located within the T waves and are large and distinct in some instances but discernible with difficulty in others. It is possible, if not usual, that the U wave contributed to the deflections usually interpreted as T waves, but an adequate number of serial tracings is not available to clarify this point. Thus, because of the close association of the U wave with the T wave, the long QT intervals may be QU intervals. It is interesting that the T and U waves often exhibited configurations which resembled those accompanying electrolyte disturbances.



CT scan slice of the brain showing a right-hemispheric ischemic stroke.



Ischemic T wave

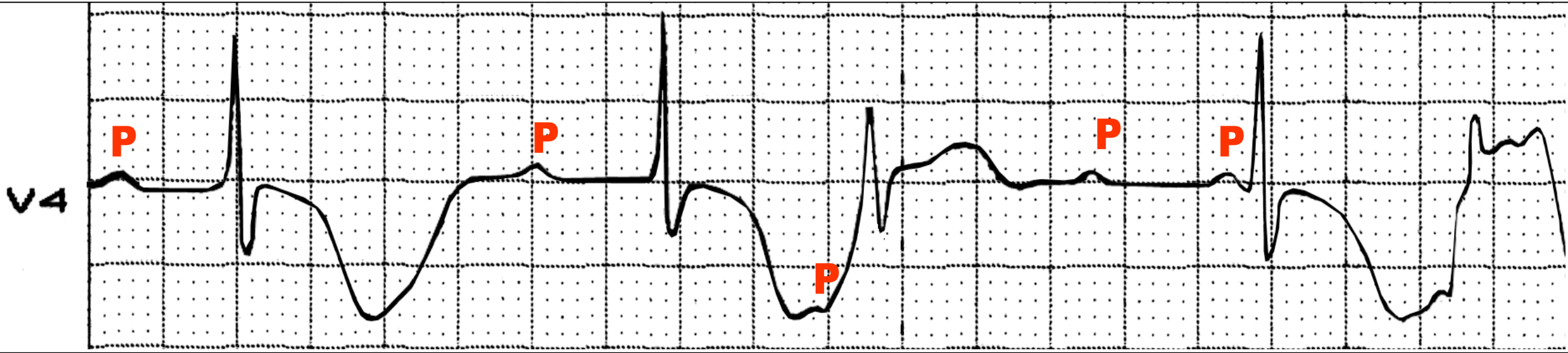Symmetrical, pointy, wide-based and with variable polarity:

Negative: T wave in “seagull”.

Positive: subendocardial ischemia.

Ischemia: negative polarity, wide base, symmetrical limbs and acute nadir. T wave in “seagull wings”.

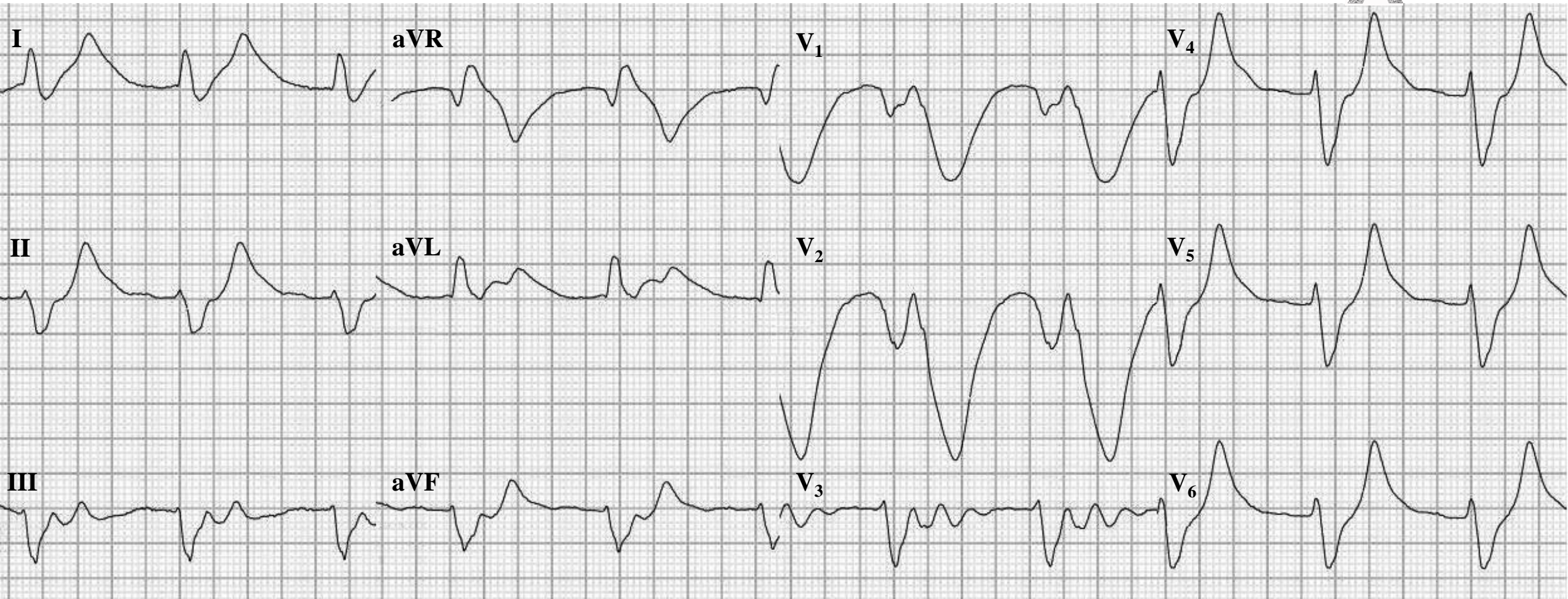
Deep T-waves after Adams–Stokes syndrome (Gerbezius-Morgagni-Adams–Stokes syndrome)



Negative T wave after Adams-Stokes episode in complete AV block.

ECG strip that shows total AV block in a patient that suffered a recent episode of Stokes-Adams: giant T waves, deeply inverted and with prolonged QT interval. This situation causes a tendency to appearance of polymorphic ventricular tachycardia of the torsade des pointes (TdP) type. It is also observed after removing artificial pacemaker

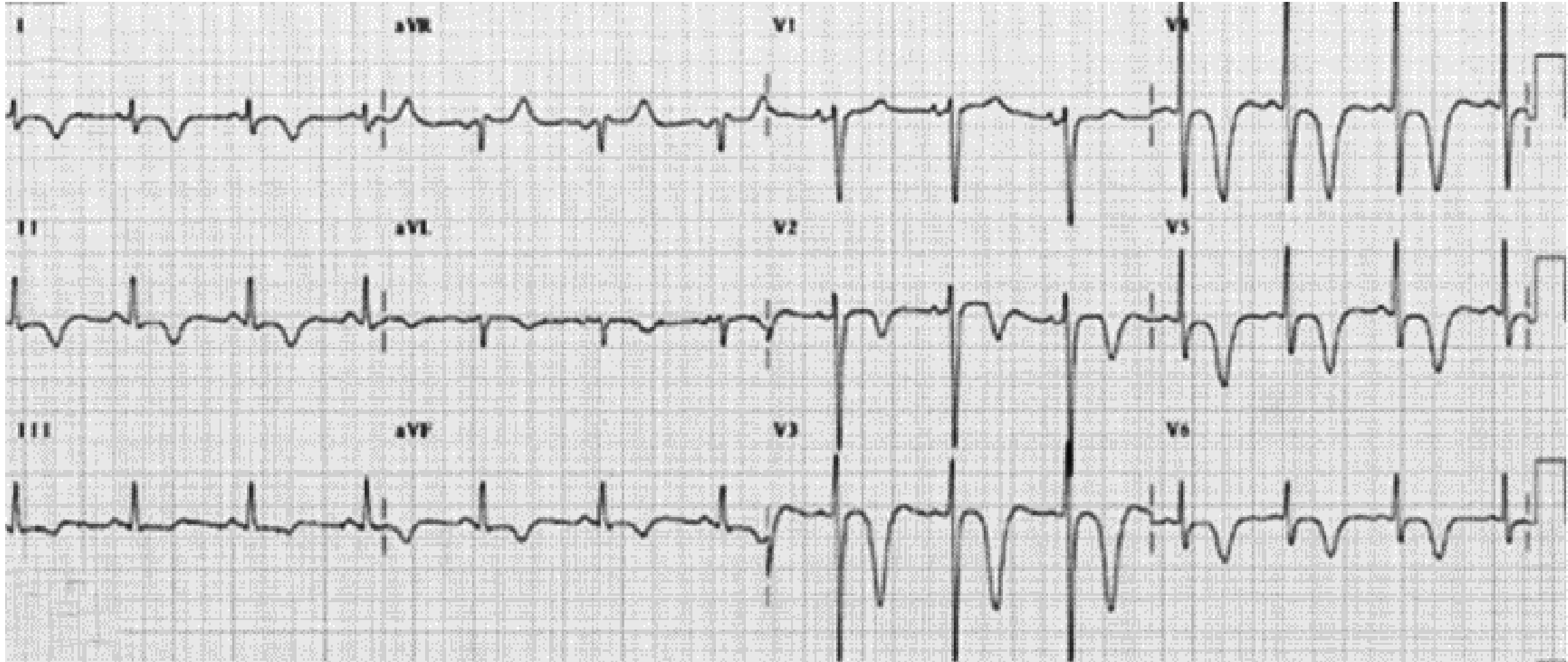
Deep T-waves in severe hyperkalemia



Severe hyperkalemia, long PR interval, with very broad QRS (nonspecific intraventricular conduction defect) and sinusoidal pattern., very deep T-waves in V1-V2, and concomitant “Eiffel tower-like” peaked T-waves in V4-V5 and inferior leads.

Cardiac and not cardiac causes of deep negative T waves

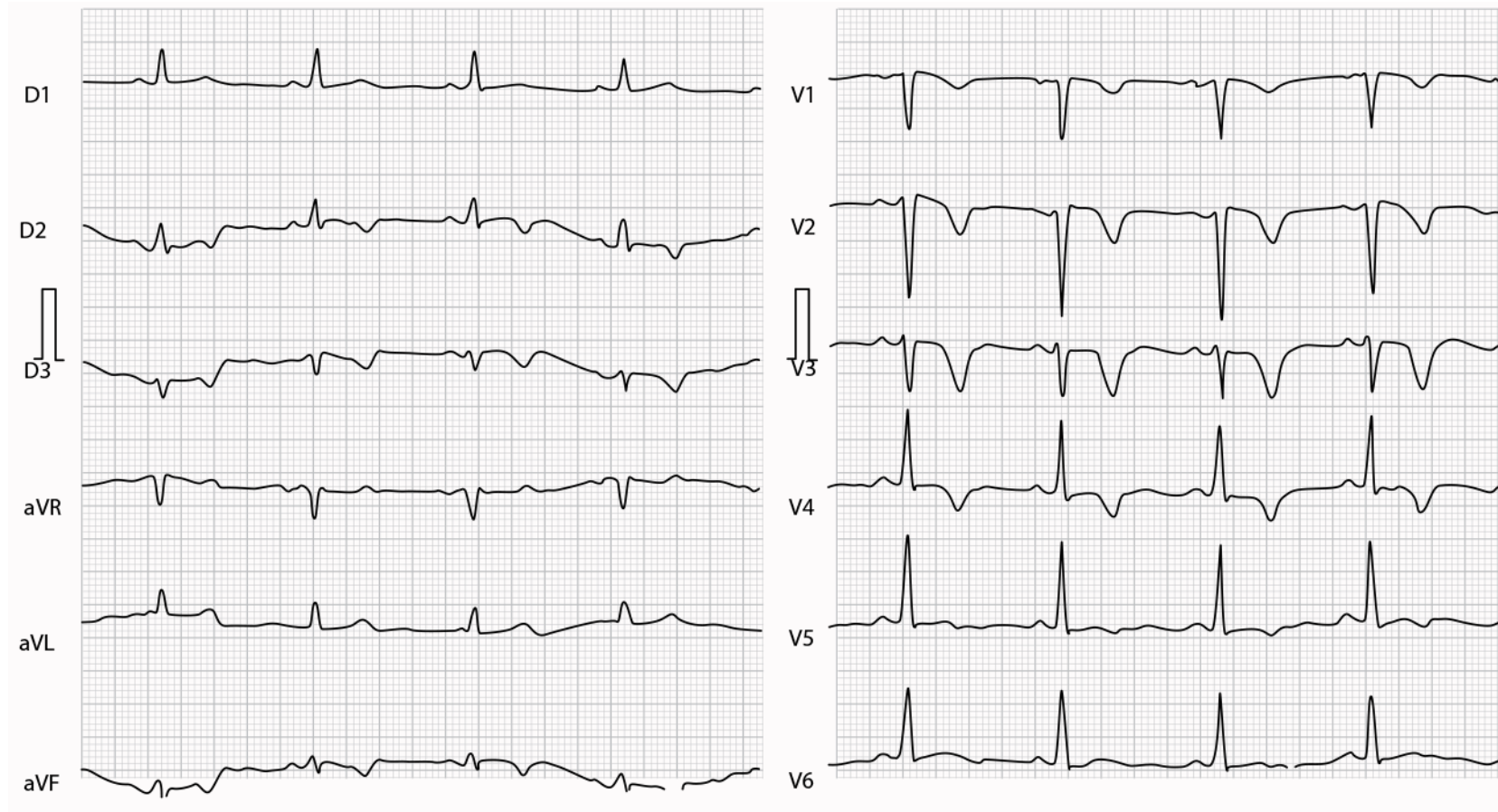
Electroconvulsive therapy-induced ECG diffuse deep T-wave inversions in leads I, II, III, aVF, and V1 to V6 (**Gould 1983**).



ECG illustrating the negative T-wave in the precordial leads V₂₋₆, II, III and aVF of a 51-year-old-female patient presented with palpitation following electroconvulsive therapy for her depression. These patients are asymptomatic with normal serial enzyme, normal brain scan, gated-pool scan, computed tomography scan of the head, and a technetium Tc 99m pyrophosphate. Serial ECGs frequently show a persistence of the deep T-wave inversions without QRS changes, and no evidence of a cerebral vascular accident or pericarditis.

Negative T waves in Cardiac memory pattern

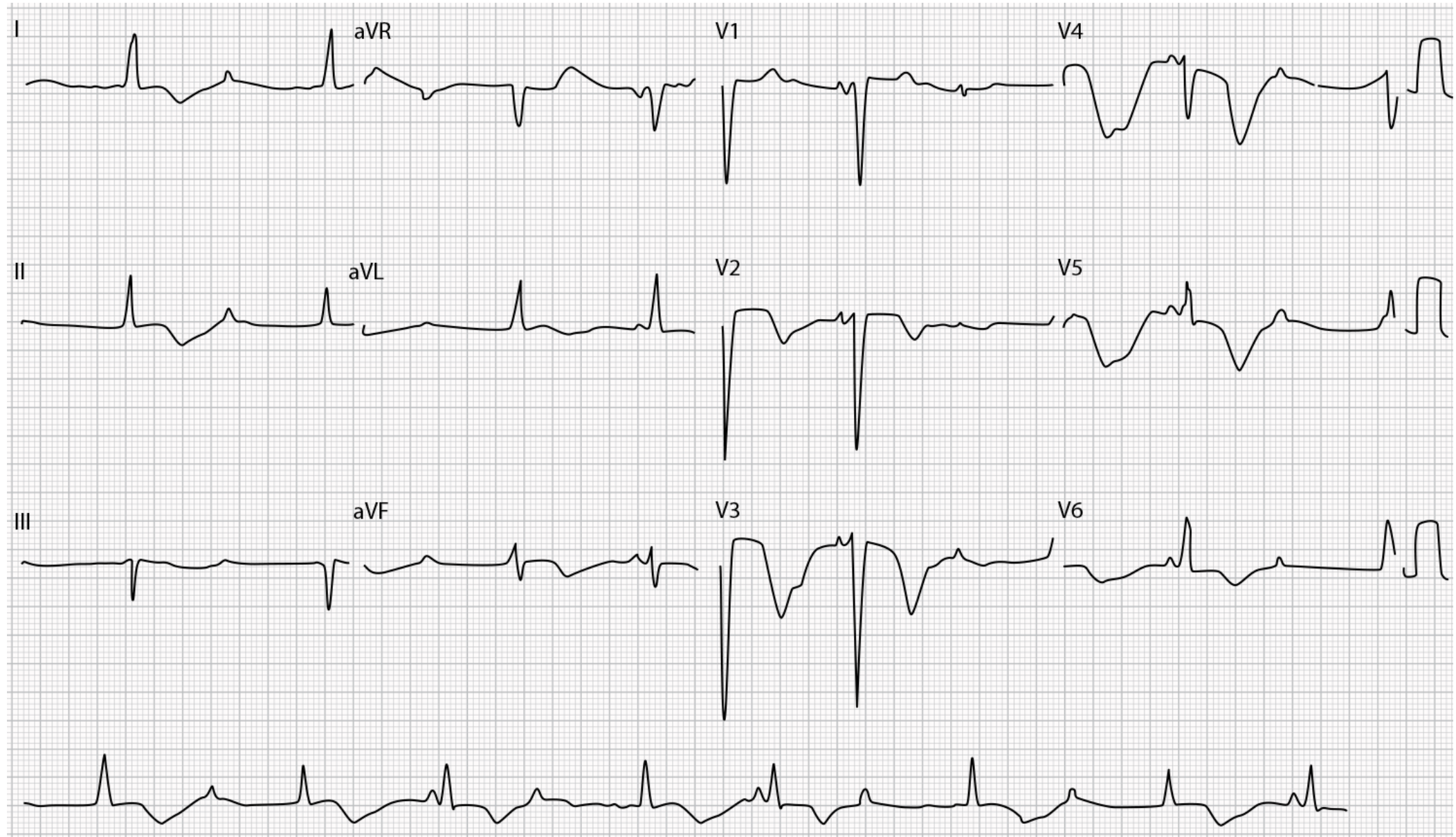
Date: Feb 27, 2013; **Time:** 17 h; **Age:** 38 y/o; **Sex:** Female; **Ethnic group:** Caucasian.



Clinical diagnosis: Cardiac memory.

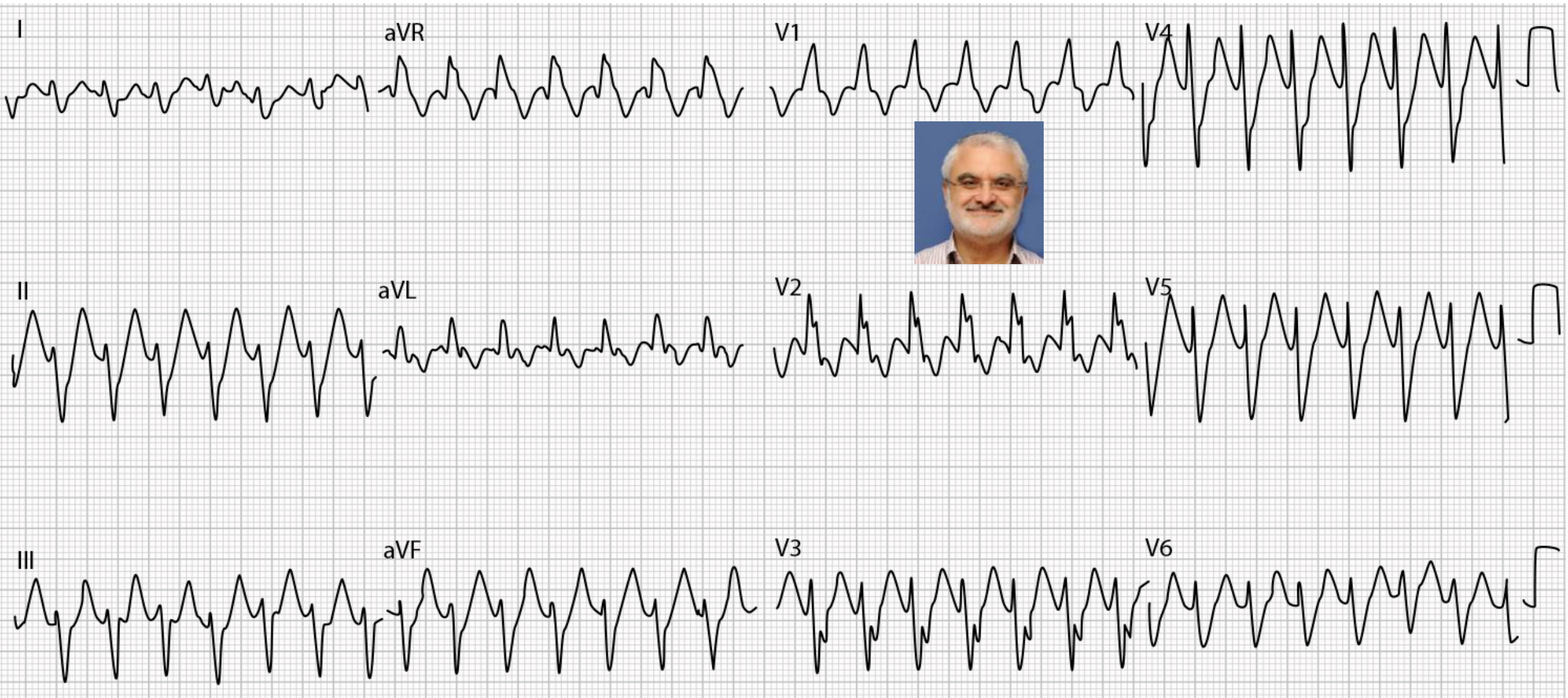
ECG diagnosis: SR, HR 83 bpm; $\hat{S}\hat{A}QRS +15^\circ$, QRS complexes of the QS type in V1 and rS with small initial r in V2-V3 and sudden passage of the transition area in V4, where the QRS complex is of the pure R or Rs type. This sudden passage from complexes of the rS type to complexes of the Rs type from V3 to V4 without recording R/S transition complex, eventually occurs in the presence of LVH by posterior shift of the QRS loop in the horizontal plane. Negative T waves in II, III and aVF and in V1 and deeply negative from V2 though V4, lead to the doubt of anterior and inferior ischemia or a chance of non-obstructive apical hypertrophic cardiomyopathy by the presence of deep, giant, negative T waves from V2 to V4 in a totally asymptomatic person.

Negative T waves in cardiac memory pattern after complete AV block



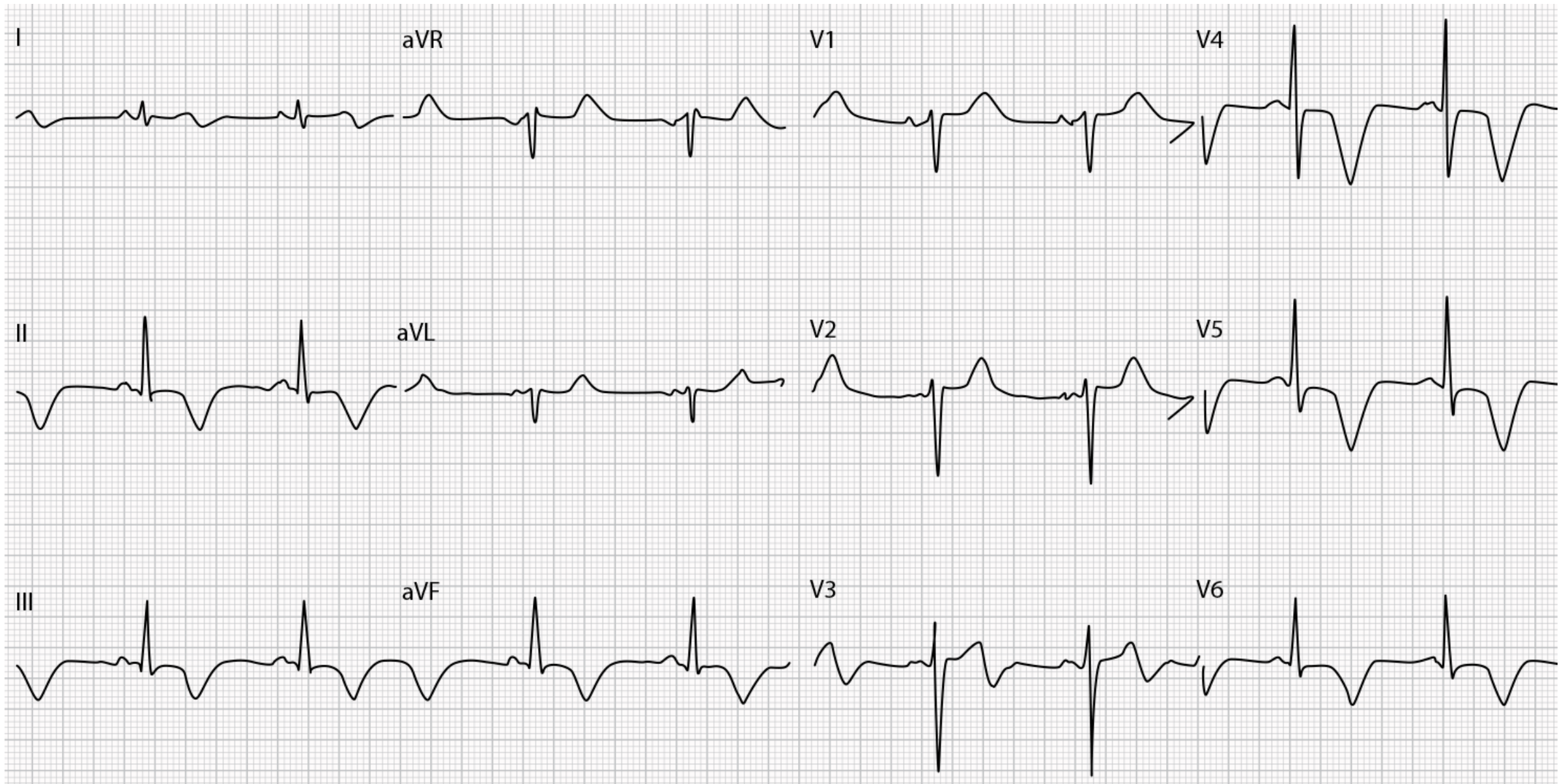
Complete ECG with PM off after 24 hours, showing AV dissociation rhythm with long QT, ventricular repolarization alterations (deep negative T waves) in the same leads where QRS complexes were previously negative (II, III, aVF and V2-V6), configuring the effect of CM.

Admission ECG showing fascicular VT of Belhassen



Cardiac memory phenomena after reversion in the next slide.

Negative T waves in cardiac memory pattern after tachyarrhythmic event



ECG after reversion to sinus rhythm with verapamil, showing deep negative T waves in II, III, aVF and from V4 through V6 and plus-minus in I, typical of CM phenomenon.

The phenomenon of cardiac memory (CM) is characterized by the presence of negative T waves preceded by normal QRS complexes after a conditioning period of abnormal ventricular depolarization in the same ECG leads. The term CM was coined by Mauricio Rosenbaum and his school (**Rosenbaum 1982**) in an experimental fashion in dogs to describe electrocardiographic alterations in ventricular repolarization induced by abnormal ventricular activation by:

1. Intermittent left bundle branch block (**Byrne 2010**).
2. After ventricular pacemaker (**Kolb 2002**). In this case, CM that induces negative T waves, is caused by the presence of transmural gradients of repolarization manifest during atrial pacing, which is maximum near the site of ventricular stimulation (**Coronel 2007**).
3. Following an episode of ventricular tachyarrhythmia (**Omidvar 2013**).
4. After ablation of anomalous pathway in Wolff-Parkinson-White or transitorily in an intermittent fashion. T wave inversion in II, III and aVF associated to delta wave disappearance of delta wave after ablation of anomalous accessory pathway in patients carrier of Wolff-Parkinson-White syndrome, is a powerful marker of success of ablation procedure (**Trajkov 2008**).

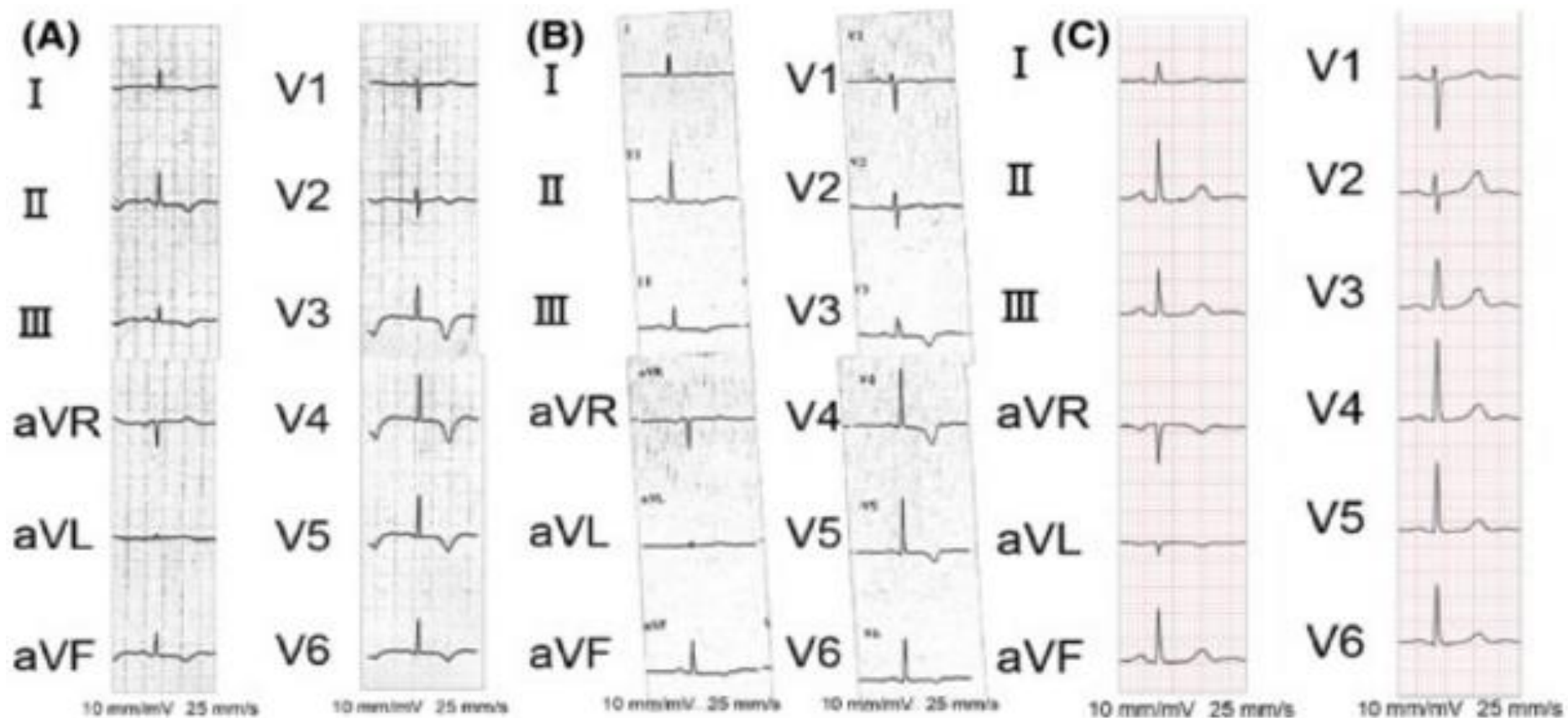
The great interest for investigating this topic is due to the impact that recognizing this phenomenon has when making decisions in cardiological clinical practice, since it manifests with T wave alterations generally interpreted mistakenly as of ischemic origin (**pseudo-primary T waves**) observed in multiple scenarios, mainly in the presence of precordial pain in the ER, as in the first case.

Concept of CM accumulation

Accumulation: duration and frequency of depolarization alteration is a predictor in relation to the time of the phenomenon of CM, which will remain present after the end of ventricular depolarization alteration. Consequently, when CM is observed after a short event of tachyarrhythmia, the phenomenon of CM will last shortly, and on the contrary, when depolarization alteration was prolonged as it happens after preexcitation removed by ablation, T wave changes are observed for a long period of hours or days (**Takada 2002**). Inden et al (**Inden 2001**) found that the prolongation in the duration of action potential of the epicardium was present before, and persisted after preexcitation ablation. Gradual changes on repolarization properties include action potential prolongation that continues after ablation procedure and may be justified by the phenomenon of accumulation proper of CM.

Isolated deep T-wave inversion on an electrocardiogram with normal wall motion

The ECG of a 73-year-old, asymptomatic woman showed deep T-wave inversion. The complete workup was negative. Ten years later, she developed takotsubo cardiomyopathy with abnormal ECG again. Isolated deep T-wave inversion might be an aftereffect of takotsubo cardiomyopathy that does not warrant an invasive workup. Deep T-wave inversion is commonly associated with takotsubo cardiomyopathy or takotsubo-like myocardial dysfunction, but this cannot be diagnosed without wall motion abnormalities. A healthy elderly woman in whom deep T-wave inversion of unknown origin was incidentally found and who developed typical takotsubo cardiomyopathy 10 years later. These findings provide evidence that isolated deep T-wave inversion is an after-effect of takotsubo cardiomyopathy (Aoki 2015).



ECGs during and after the first admission to hospital. (A) ECG on day 1 shows negative T waves in leads II, III, aV_F, and V₂₋₆. Note the deeply inverted T waves (7 mm) in leads V₃₋₄. (B) ECG on day 11. T-wave inversion has become much shallower. (C) ECG 3 months after discharge. T-wave inversion has disappeared.

Miscellaneous entities with possible deep negative T-wave

- Post-Tachycardia T-Wave Syndrome (**Katz 1995**)
- Traumatic head injury (**Najafipour 2014**)
- T wave in pheochromocytomas (**Kimura 2010**)
- Reversible deep T-wave inversion with QT interval prolongation in Acute pulmonary embolism (**Punukollu 2004**)
- Maxillofacial surgery (**Kim 1992**)
- Bilateral carotid endarterectomy (**Baur 1976**)
- After abrupt increases in the sympathetic discharge (**Schwartz 1975**)
- Cocaine abuse (**Ramirez 2012**)
- Flecainide use (**Said 1994**)
- Gastrointestinal emergencies (perforated ulcer, acute pancreatitis and acute cholecystitis) (**Rott 2011**) Induced by cardiac compression from a retrosternal gastric tube used to reconstruct the esophagus after tumor resection (**Takato 2006**)
- Acute adrenal crisis (**Iga 1992**)
- Sodium azide poisonings (**Łopaciński 2007**)

In the emergency setting, ECG is the most important diagnostic test for angina. The ECG is the most important tool in the initial evaluation and triage of patients in whom an ACS, such as MI, is suspected. It is confirmatory of the diagnosis in approximately 80% of cases. ECG changes that may be seen during anginal episodes include transient ST-SE, dynamic T-wave changes (Inversions, normalizations, or hyperacute changes) or ST depressions (junctional, downsloping or horizontal). ACS refers to a spectrum of clinical presentations ranging from those for STEMI to presentations found in NSTEMI or in unstable angina. In terms of pathology, ACS is almost always associated with rupture of an atherosclerotic plaque and partial or complete thrombosis of the infarct-related artery. In some instances, however, stable coronary artery disease (CAD) may result in ACS in the absence of plaque rupture and thrombosis, when physiologic stress (eg, trauma, blood loss, anemia, infection, tachyarrhythmia) increases demands on the heart. The diagnosis of AMI in this setting requires a finding of the typical rise and fall of biochemical markers of myocardial necrosis in addition to at least 1 of the following (**Alpert 2003**): Ischemic symptoms, development of pathologic Q waves and/or ischemic ST-segment changes on ECG or in the setting of a coronary intervention. NSTEMI is distinguished from unstable angina by elevated levels of cardiac enzymes and biomarkers of myocyte necrosis. Differentiation is generally based on 3 sets of biomarkers measured at 6- to 8-hour intervals after the patient's presentation to the ED. The current definition of NSTEMI requires a typical clinical syndrome plus elevated troponin (or creatine kinase isoenzyme MB [CK-MB]) levels to over 99% of the normal reference (with a coefficient of variation of < 10% for the assay). Given this definition, nearly 25% of patients who were previously classified as having unstable angina now fulfill the criteria for NSTEMI. Measure cardiac enzyme levels at regular intervals, starting at admission and continuing until the peak is reached or until 3 sets of results are negative. Biochemical biomarkers (demonstrated in the image below) are useful for diagnosis and prognostication.

The terms transmural and nontransmural (subendocardial) MI are no longer used because ECG findings in patients with this condition are not closely correlated with pathologic changes in the myocardium. Therefore, a transmural infarct may occur in the absence of Q waves on ECGs, and many Q-wave myocardial infarctions may be subendocardial, as noted on pathologic examination. Because elevation of the ST segment during ACS is correlated with coronary occlusion and because it affects the choice of therapy (urgent reperfusion therapy), ACS-related myocardial infarction should be designated STEMI or NSTEMI. Attention to the underlying mechanisms of ischemia is important when managing ACS. A simple predictor of demand is rate-pressure product, which can be lowered by beta blockers (eg, metoprolol or atenolol) and pain/stress relievers (eg, morphine), while supply may be improved by oxygen, adequate hematocrit, blood thinners (eg, heparin, IIb/IIIa agents such as abciximab, eptifibatid, tirofiban, or thrombolytics), and/or vasodilators (eg, nitrates, amlodipine). In 2010, the American Heart Association (AHA) published new guideline recommendations for the diagnosis and treatment of ACS (**O'Connor 2010**). ECGs should be reviewed promptly. Involve a cardiologist when in doubt. Recording an ECG during an episode of the presenting symptoms is valuable. Transient ST-segment changes (>0.05 mV) that develop during a symptomatic period and that resolve when the symptoms do are strongly predictive of underlying CAD and have

prognostic value. Comparison with previous ECGs is often helpful.

Alternative causes of ST-segment and T-wave changes are left ventricular aneurysm, pericarditis, Prinzmetal angina, early repolarization, Wolff-Parkinson-White syndrome, and drug therapy (eg, with tricyclic antidepressants, phenothiazines).

In the emergency setting, ECG is the most important ED diagnostic test for angina. It may show changes during symptoms and in response to treatment, confirm a cardiac basis for symptoms. It also may demonstrate preexisting structural or ischemic heart disease (left ventricular hypertrophy, Q waves). A normal ECG or one that remains unchanged from the baseline does not exclude the possibility that chest pain is ischemic in origin. Changes that may be seen during anginal episodes include the following:

- Transient ST-segment elevations
- Dynamic T-wave changes - Inversions, normalizations, or hyperacute changes
- ST depressions - May be junctional, downsloping, or horizontal

In patients with transient ST-segment elevations, consider LV aneurysm, pericarditis, Prinzmetal angina, early repolarization, and Wolff-Parkinson-White syndrome as possible diagnoses. Fixed changes suggest AMI.

When deep T-wave inversions are present, consider the possibility of central nervous system (CNS) events or drug therapy with tricyclic antidepressants or phenothiazines as the cause.

Diagnostic sensitivity may be increased by performing right-sided leads ($V_4 R$), posterior leads (V_8, V_9), and serial recordings.

References

1. Alpert JS, Thygesen K, Antman E, Bassand JP. Myocardial infarction redefined--a consensus document of The Joint European Society of Cardiology/American College of Cardiology Committee for the redefinition of myocardial infarction. *J Am Coll Cardiol*. 2000;36(3):959-69.
2. Aoki Y, Koder S, Shakya S, Ishiwaki H, Ikeda M, Kanda J. Isolated deep T-wave inversion on an electrocardiogram with normal wall motion. *Clin Case Rep*. 2015;3(7):594-7.
3. Barnes AR, Whitten MB. Study of T-wave negativity in predominant ventricular strain. *Am Heart J*. 1929;5:14-67.
4. Baur HR, Pierach CA. Electrocardiographic changes after surgical manipulation of the carotid arteries. *Dtsch Med Wochenschr*. 1976;101(22):855-6.
5. Billgren T, Birnbaum Y, Sgarbossa EB, Sejersten M, Hill NE, Engblom H, Maynard C, Pahlm O, Wagner GS. Refinement and interobserver agreement for the electrocardiographic Sclarovsky-Birnbaum Ischemia Grading System. *J Electrocardiol*. 2004;37(3):149-56.
6. Birnbaum GD, Birnbaum I, Birnbaum Y. Twenty years of ECG grading of the severity of ischemia. *J Electrocardiol*. 2014;47(4):546-55.
7. Birnbaum Y, Wagner GS. The Initial electrocardiographic pattern in acute myocardial infarction: correlation with infarct size. *J Electrocardiol* 1999;32 (suppl):122-8.
8. Birnbaum Y, Drew BJ. The electrocardiogram in ST elevation acute myocardial infarction: correlation with coronary anatomy and prognosis. *Postgrad Med J*. 2003;79(935):490-504.
9. Birnbaum Y, Wilson JM, Fiol M, de Luna AB, Eskola M, Nikus K. ECG diagnosis and classification of acute coronary syndromes. *Ann Noninvasive Electrocardiol*. 2014;19(1):4-14.
10. Buber J, Gilutz H, Birnbaum Y, Friger M, Ilia R, Zahger D. Grade 3 ischemia on admission and absence of prior beta-blockade predict failure of ST resolution following thrombolysis for anterior myocardial infarction. *Int J Cardiol*. 2005;104(2):131-7.
11. Burch GE, Meyers R, Abildskov JA. A new electrocardiographic pattern observed in cerebrovascular accidents. *Circulation*. 1954;9(5):719-23.
12. Bybee KA, Kara T, Prasad A, et al. Systematic review: transient left ventricular apical ballooning: a syndrome that mimics ST-segment elevation myocardial infarction. *Ann Intern Med*. 2004;141(11):858-65.
13. Bybee KA, Motiei A, Syed IS, et al. Electrocardiography cannot reliably differentiate transient left ventricular apical ballooning syndrome from anterior ST-segment elevation myocardial infarction. *J Electrocardiol*. 2007;40(1):38.e1-6.
14. Byrne R, Filippone L. Benign persistent T-wave inversion mimicking ischemia after left bundle-branch block--cardiac memory. *Am J Emerg Med*. 2010;28(6):747.e5-6.

15. Carlsen EA, Bang LE, Køber L, et al. Availability of a baseline Electrocardiogram changes the application of the Sclarovsky-Birnbaum Myocardial Ischemia Grade. *J Electrocardiol.* 2014;47(4):571-6.
16. Coronel R, Opthof T, Plotnikov AN, et al. Long-term cardiac memory in canine heart is associated with the evolution of a transmural repolarization gradient. *Cardiovasc Res.* 2007;74(3):416-25.
17. David D, Naito M, Michelson E, et al. Intramyocardial conduction: a major determinant of R wave amplitude during acute myocardial ischemia. *Circulation.* 1982;65(1):161-7.
18. Desch S, de Waha S, Eitel I, et al. Effect of coronary collaterals on long-term prognosis in patients undergoing primary angioplasty for acute ST-elevation myocardial infarction. *Am J Cardiol* 2010;106(5):605-11.
19. de Winter RJ, Verouden NJ, Wellens HJ, Wilde AA, Interventional Cardiology Group of the Academic Medical Center. A new ECG sign of proximal LAD occlusion. *N Engl J Med.* 2008;359(19):2071-3.
20. de Winter RW, Adams R, Verouden NJ, de Winter RJ. Precordial junctional ST-segment depression with tall symmetric T-waves signifying proximal LAD occlusion, case reports of STEMI equivalence. *J Electrocardiol.* 2016;49(1):76-80.
21. de Zwan C, Bär FW, Wellens HJ. Characteristic electrocardiographic pattern indicating a critical stenosis high in left anterior descending coronary artery in patients admitted because of impending myocardial infarction. *Am Heart J.* 1982;103(4, Pt 2):730a-736a.
22. Eskola MJ, Nikus KC, Sclarovwky S. Persistent precordial "hyperacute" T waves signify proximal left anterior descending artery occlusion. *Heart.* 2009;95(23):1951-2.
23. Gorgels AP. ST-elevation and non-ST-elevation acute coronary syndromes: should the guidelines be changed? *J Electrocardiol.* 2013;46(4):318-23.
24. Gould L, Gopaldaswamy C, Chandy F, Kim B. Electroconvulsive therapy-induced ECG changes simulating a myocardial infarction. *Arch Intern Med.* 1983;143(9):1786-7.
25. Gussak I. Electrocardiographic "Lambda" wave and primary idiopathic cardiac asystole: a new clinical syndrome? *J Electrocardiol.* 2004;37(2):105-7.
26. Haines DE, Raabe DS, Gundel WD, Wackers FJ. Anatomic and prognosis significance of new T-wave inversion in unstable angina. *Am J Cardiol.* 1983;52(1):14-8.
27. Hassell ME, Delewi R, Lexis CP, et al. The relationship between terminal QRS distortion on initial ECG and final infarct size at 4months in conventional ST- segment elevation myocardial infarct patients. *J Electrocardiol.* 2016;49(3):292-9.
28. Hennings JR, Fesmire FM. A new electrocardiographic criteria for emergent reperfusion therapy. *Am J Emerg Med.* 2012;30(6):994-1000.

29. Iga K, Hori K, Gen H. Deep negative T waves associated with reversible left ventricular dysfunction in acute adrenal crisis. *Heart Vessels*.1992;7(2):107-11.
30. Inagaki N, Gono T, Clement JP 4th, et al. "Reconstitution of IKATP: An inward rectifier subunit plus the sulfonylurea receptor". *Science*. 1995;270(5239):1166–70.
31. Inden Y, Hirai M, Takada Y, et al. Prolongation of activation-recovery interval over a preexcited region before and after catheter ablation in patients with Wolff-Parkinson-White syndrome. *J Cardiovasc Electrophysiol*. 2001;12(8):939-45.
32. Kannel WB, Gordon T, Castelli WP, Margolis JR. Electrocardiographic left ventricular hypertrophy and risk of coronary heart disease: the Framingham study. *Ann Intern Med*. 1970;72(6):813–22.
33. Kaplan LG, Katz LN. The characteristic electrocardiograms in left ventricular strain with and without axis deviation. *Am J Med Sci*. 1941;201:676–93.
34. Katz AM. Images in clinical medicine. Post-tachycardia T-wave syndrome. *N Engl J Med*. 1995;332(3):161.
35. Kim Y, Shibutani T, Hirota Y, Hori T, Matsuura H. Giant negative T waves after maxillofacial surgery. *Anesth Prog*. 1992;39(1-2):28–35.
36. Kimura S, Mitsuma W, Ito M, et al. Inverted Takotsubo contractile pattern caused by pheochromocytoma with tall upright T-waves, but not typical deep T-wave inversion. *Int J Cardiol*. 2010;139(2):e15-7.
37. Kolb JC. Cardiac memory-persistent T wave changes after ventricular pacing. *J Emerg Med*. 2002;23(2):191-7.
38. Kosuge M, Ebina T, Hibi K, et al. Simple and accurate electrocardiographic criteria to differentiate takotsubo cardiomyopathy from anterior acute myocardial infarction. *J Am Coll Cardiol*. 2010;55(22):2514–6.
39. Kurisu S, Inoue I, Kawagoe T, et al. Time course of electrocardiographic changes in patients with tako-tsubo syndrome: comparison with acute myocardial infarction with minimal enzymatic release. *Circ J*. 2004;68(1):77–81.
40. Łopaciński B, Kołacinski Z, Winnicka R. Sodium azide--clinical course of the poisoning and treatment]. *Przegl Lek*. 2007;64(4-5):326-30.
41. Lønborg J1, Kelbæk H, Vejlstrup N, et al. Influence of preinfarction angina, collateral flow, and pre-procedural TIMI flow on myocardial salvage index by cardiac magnetic resonance in patients with ST-segment elevation myocardial infarction. *Eur Heart J Cardiovasc Imaging*. 2012;13(5):433–43.
42. Madias JE. Prinzmetal's work and the "Sclarovsky-Birnbaum ischemia score" for acute myocardial infarction: a parallel in systematizing electrocardiographic knowledge. *J Electrocardiol*. 2009;42(1):27-34.
43. Madias C, Fitzgibbons TP, Alsheikh-Ali AA, Bouchard JL, Kalsmith B, Garlitski AC, et al. Acquired long QT syndrome from stress cardiomyopathy is associated with ventricular arrhythmias and torsades de pointes. *Heart Rhythm* 2011;8(4):555–61.

44. Madias JE. Transient attenuation of the amplitude of the QRS complexes in the diagnosis of Takotsubo syndrome. *Eur Heart J Acute Cardiovasc Care*. 2014;3(1):28-36.
45. Migliore F, Zorzi AM, Marra MP, et al. Myocardial edema underlies dynamic T-wave inversion (Wellens' ECG pattern) in patients with reversible left ventricular dysfunction. *Heart Rhythm*. 2011;8(10):1629-34.
46. Najafipour H, Siahposht Khachaki A, Khaksari M, Shahouzehi B, Joukar S, Poursalehi HR. Traumatic brain injury has not prominent effects on cardiopulmonary indices of rat after 24 hours: hemodynamic, histopathology, and biochemical evidence. *Iran Biomed J*. 2014;18(4):225-31.
47. O'Connor RE, Bossaert L, Arntz HR, et al. Part 9: acute coronary syndromes: 2010 International Consensus on Cardiopulmonary Resuscitation and Emergency Cardiovascular Care Science With Treatment Recommendations. *Circulation*. 2010;122(16 Suppl 2):S422-65.
48. Okin PM, Devereux RB, Nieminen MS, et al. Electrocardiographic strain pattern and prediction of cardiovascular morbidity and mortality in hypertensive patients. *Hypertension*. 2004;44(1):48–54.
49. Omar HR, Faibairn J, Abdelmalak HD, Delibasic M, Camporesi EM. Postoperative takotsubo cardiomyopathy: an illustration of the electrocardiographic features that raise suspicion for takotsubo. *Eur Heart J Acute Cardiovasc Care*. 2013 Oct 21. [Epub ahead of print].
50. Omidvar B, Majidi S, Raadi M, Alasti M. Diffuse inverted T waves in a young man with structurally normal heart: a case report. *Ann Noninvasive Electrocardiol*. 2013;18(4):409-12.
51. Perazzolo Marra M, Lima JA, Iliceto S. MRI in acute myocardial infarction. *Eur Heart J*. 2011;32(3):284–93.
52. Pérez-Riera AR, Barbosa-Barros R, Baranchuk A. In: *Left Septal Fascicular Block: Characterization, Differential Diagnosis and Clinical Significance*. 1st edition. Springer Publishing Company, UK; 2016.
53. Prinzmetal M, Kennamer R, Merliss R, Wada T, Bor N. Angina pectoris. I. A variant form of angina pectoris. *Am J Med*. 1959;27:374.
54. Punukollu G, Gowda RM, Khan IA, Wilbur SL, Vasavada BC, Sacchi TJ. QT interval prolongation with global T-wave inversion: a novel ECG finding in acute pulmonary embolism. *Ann Noninvasive Electrocardiol*. 2004;9(1):94-8.
55. Ramirez FD, Femenía F, Simpson CS, Redfearn DP, Michael KA, Baranchuk A. Electrocardiographic findings associated with cocaine use in humans: a systematic review. *Expert Rev Cardiovasc Ther*. 2012;10(1):105–27.
56. Riera AR, Ferreira C, Ferreira Filho C, et al. Wellens syndrome associated with prominent anterior QRS forces: an expression of left septal fascicular block? *J Electrocardiol*. 2008;41(6):671-4.
57. Rinehardt J, Brady WJ, Perron AD, Mattu A. Electrocardiographic manifestations of Wellens' syndrome. *Am J Emerg Med* 2002;20(7):638-43.

58. Rosenbaum MB, Blanco HH, Elizari MV, Lazzari JO, Davidenko JM. Electrotonic modulation of the T wave and cardiac memory. *Am J Cardiol.* 1982;50(2):213-22.
59. Rott D, Leibowitz D, Weiss AT. Giant precordial T wave inversion in a patient with gastroenteritis. *Case Rep Vasc Med.* 2011;2011:942045.
60. Sagie A, Sclarovsky S, Strasberg B, et al. Acute anterior wall myocardial infarction presenting with positive T waves and without ST segment shift. Electrocardiographic features and angiographic correlation. *Chest.* 1989;95(6):1211-5.
61. Said SA, Somer ST, Oude Luttikhuis HA. Flecainide-induced JT prolongation, T wave inversion and ventricular tachycardia during treatment for symptomatic atrial fibrillation. *Int J Cardiol.* 1994;44(3):285-7.
62. Schwartz PJ, Malliani A. Electrical alternation of the T-wave: clinical and experimental evidence of its relationship with the sympathetic nervous system and with the long Q-T syndrome. *Am Heart J.* 1975;89(1):45-50.
63. Sclarovsky S, Mager A, Kusniec J, et al. Electrocardiographic classification of acute myocardial ischemia. *Isr J Med Sci.* 1990;26(9):525-31.
64. Sclarovsky S. *Electrocardiography of acute myocardial ischaemic syndromes.* London: Martin Dunitz, 1999.
65. Sclarovsky S, Nikus KC. The role of oestrogen in the pathophysiologic process of the Tako-Tsubo cardiomyopathy. *Eur Heart J.* 2010;31(3):377; author reply 377-8.
66. Sclarovsky S, Nikus K. The electrocardiographic paradox of tako-tsubo cardiomyopathy-comparison with acute ischemic syndromes and consideration of molecular biology and electrophysiology to understand the electrical-mechanical mismatching. *J. Electrocardiol.* 2010;43(2):173-6.
67. Syed FF, Asirvatham SJ, Francis J. Arrhythmia occurrence with takotsubo cardiomyopathy: a literature review. *Europace.* 2011;13(6):780-8.
68. Takada Y, Inden Y, Akahoshi M, et al. Changes in repolarization properties with long-term cardiac memory modify dispersion of repolarization in patients with Wolff-Parkinson-White syndrome. *J Cardiovasc Electrophysiol.* 2002;13(4):324-30.
69. Takato T, Ashida T, Sugiyama T, Yoshida Y. Marked reversible ST-T abnormalities induced by cardiac compression from a retrosternal gastric tube used to reconstruct the esophagus after tumor resection. A case of a diabetic patient and mini-review of 7 reported patients *Int Heart J.* 2006;47(3):475-82
70. Trajkov I, Poposka L, Kovacevic D, Dobrkovic L, Georgievska-Ismail Lj, Gjorgov N. Cardiac memory (t-wave memory) after ablation of posteroseptal accessory pathway *Prilozi.* 2008;29(1):167-82.
71. Tsuchihashi K, Ueshima K, Uchida T, et al. Transient left ventricular apical ballooning without coronary artery stenosis: a novel heart syndrome mimicking acute myocardial infarction. *Angina Pectoris-Myocardial Infarction Investigations in Japan. J Am Coll Cardiol.* 2001;38(1):11-8.

72. Valle-Caballero MJ, Fernández-Jiménez R, Díaz-Munoz R, et al. QRS distortion in pre-reperfusion electrocardiogram is a bedside predictor of large myocardium at risk and infarct size (a METOCARD-CNIC trial substudy). *Int J Cardiol.* 2016;202:666-73.
73. Verouden NJ, Koch KT, Peters RJ, et al. Persistent precordial 'hyperacute' T-waves signify proximal left anterior descending artery occlusion. *Heart.* 2009;95(20):1701–6.
74. Zorzi A, Perazzolo-Marra M, Migliore F, Tarantini G, Iliceto S, Corrado D. Interpretation of acute myocardial infarction with persistent 'hyperacute T waves' by cardiac magnetic resonance. *Eur Heart J Acute Cardiovasc Care.* 2012;1(4):344–8.