

Another STSE pattern on right precordial leads with J point elevation 0.2mV in the right precordial leads non type 1 and non type 2 BrP

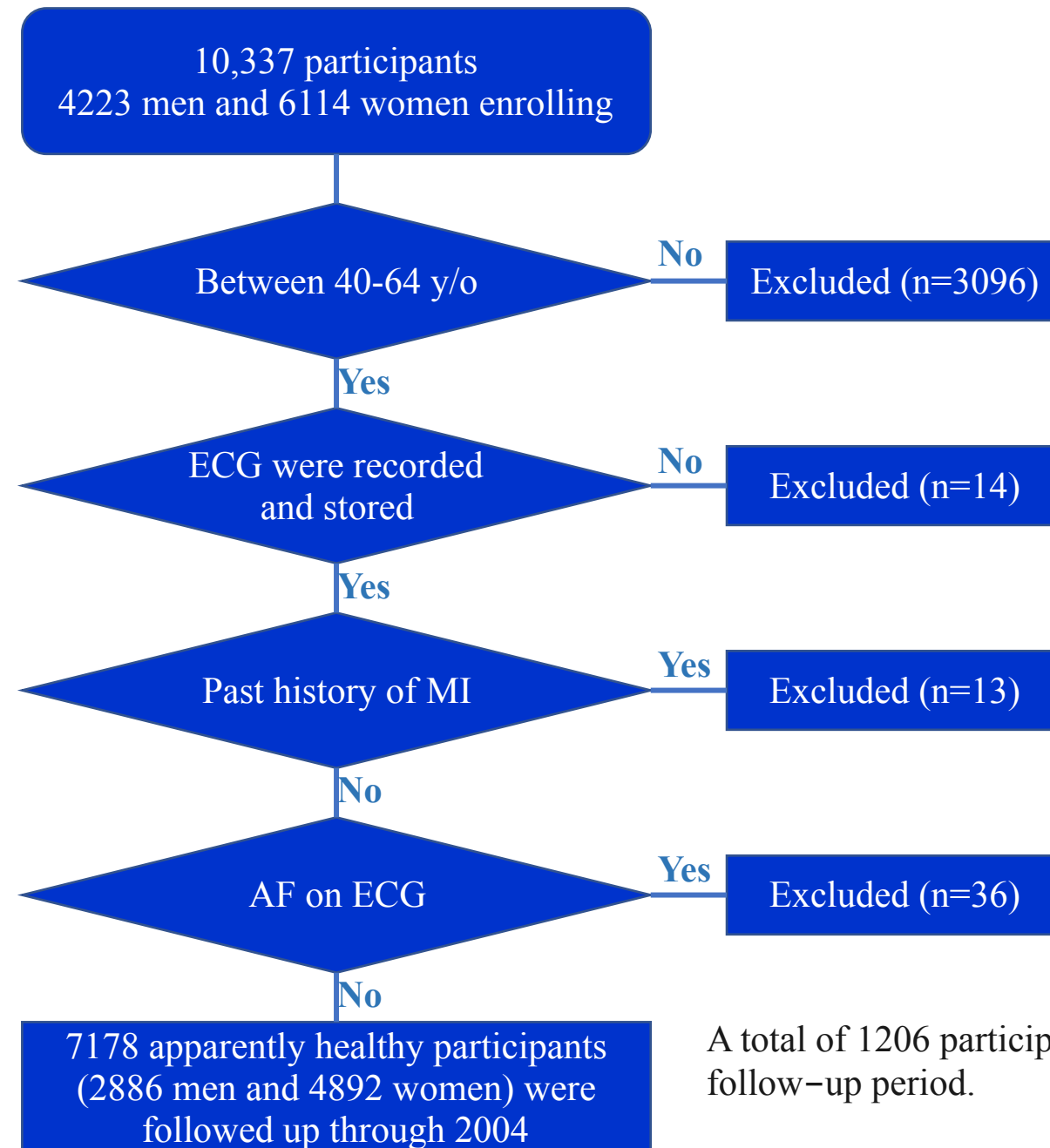
Another STSE pattern on right precordial leads with J point elevation ≥ 0.2 mV in the right precordial leads non type 1 and non type 2 BrP

Tsuneoka et al (**Tsuneoka 2016**) studied a cohort of 7178 people (2886 men, 4292 women) who constituted the participants of this study. The study included community residents aged 40 to 64 years who enrolled in a community-based cohort of the Circulatory Risk in Community Study (CIRCS). CIRCS is a prospective community-based study that was launched to examine risk factors of cardiovascular disease from 1963. The authors recruited 10 337 participants (4223 men, 6114 women) who underwent a health checkup from 1982 to 1986.

Non coved and non saddle back ST-T morphology with J point elevation ≥ 0.2 mV in the right precordial leads. The authors observed an interesting finding in this large-scale and long-term observational study: Participants with: **noncoved (type 1 BrP) and nonsaddleback ST-T morphology (type 2 BrP) with J point elevation ≥ 0.2 mV in the right precordial leads (STERP)** had an excess risk of SCD compared with those in the non-ST group. This study is the first to find that STERP is a distinct clinical entity with a high risk of SCD in the middle-aged Japanese general population. The arrhythmogenic potential of ER in the inferior leads was highlighted by Haïssaguerre et al (**Haïssaguerre 2008**). Nevertheless, in the cohort studies examining ERS, the right precordial leads were not included in the analysis to avoid including BrS or ARVC. Kamakura et al extended the definition of non-type 1 BrS and concluded that the long-term prognosis of probands with non-type 1 BrS was similar to that of probands with type 1 BrS in a hospital-based multicenter study (**Tikkanen 2009**). Moreover, Kamakura et al investigated the significance of non-type 1 anterior ER in patients with idiopathic VF and inferolateral ER in their hospital-based study (**Kamakura 2009**). They concluded that the coexistence of non-type 1 anterior ER was a predictor of poor outcome in patients with inferolateral ER and VF; however, these studies included patients with non-type 1 BrS. Little is known about what ST-T morphology, except for BrS in the right precordial leads, is associated with malignant arrhythmia. Consequently, the authors investigated ECGs with STERP without BrS and analyzed the clinical characteristics and long-term prognosis of participants with STERP. These participants had a markedly elevated risk of SCD compared with those with non-STSE. This report is the first to show a significantly higher risk of SCD in participants with STERP. Additionally, participants with STERP were predominantly male (94.7%) and were significantly younger than participants in the non-STSE group, which is the same as that with BrS and ERS (**Ohira 2012; Tikkanen 2009; Nam 2010**). This suggests a particular young and male background that relates to heredity, hormonal factors, or autonomic nervous function. Haruta et al proposed a hypothesis that testosterone may modulate cardiac mortality in ERS (**Haruta 2011**).

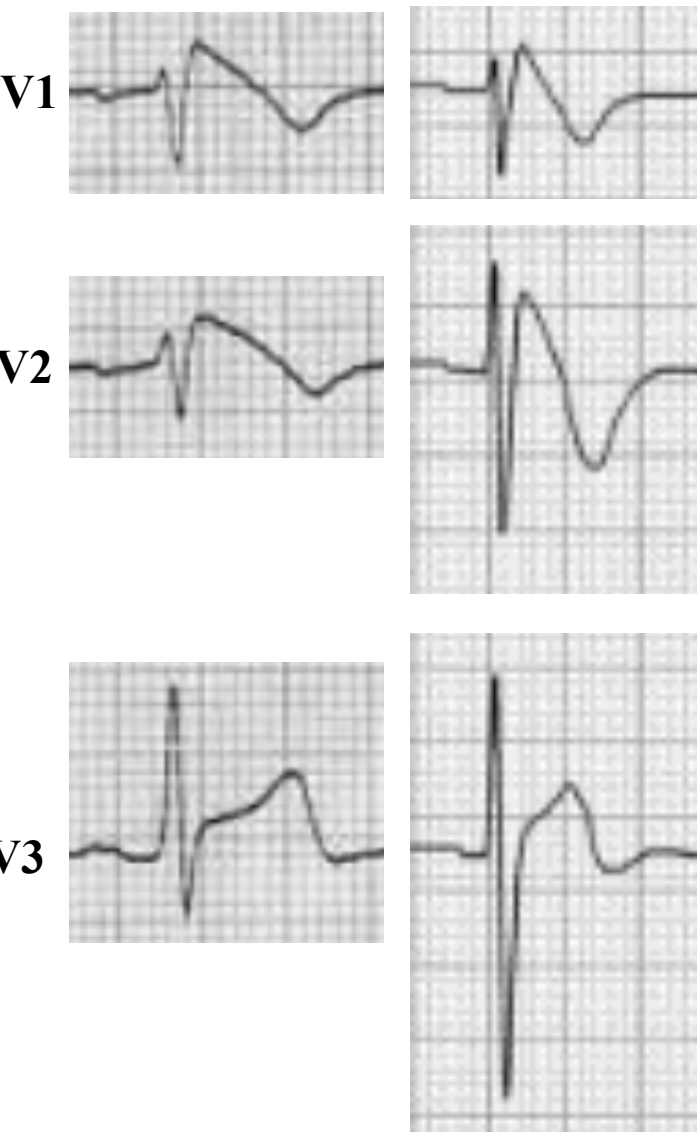Exclusion criteria: 1) Age <40 or >64 years; 2) No previous ECGs on record; Past history of MI; 4) AF. SCD was defined as a sudden unexpected death either within 1 hour of symptom onset (for witnessed events) or within 24 hours of having been observed alive and symptom free.

Flowchart of the entry process for the 7178 participants

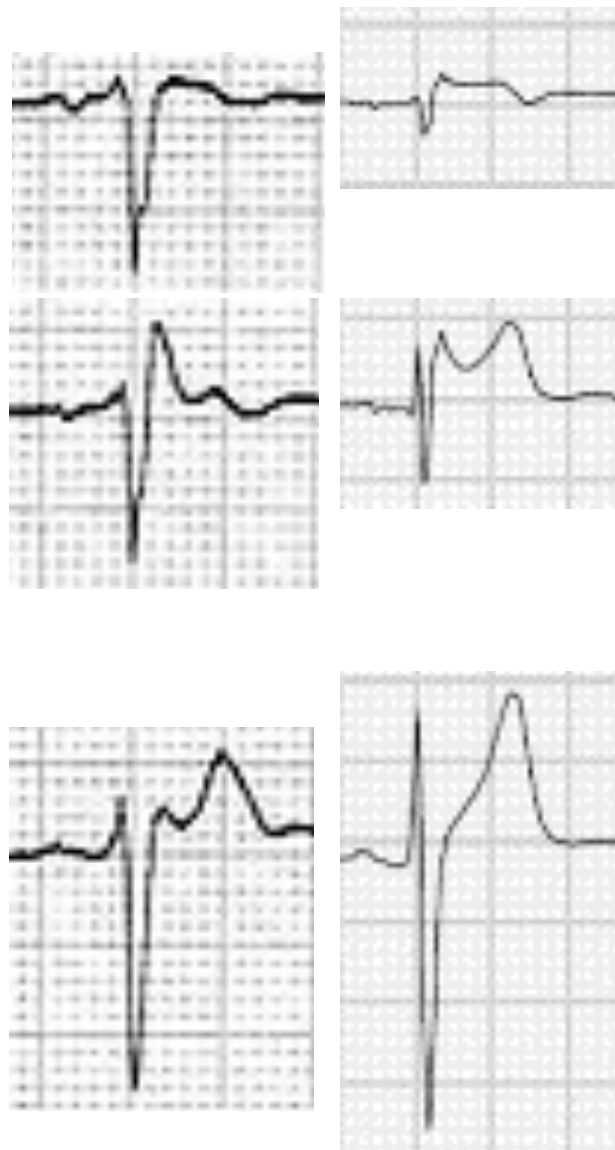

A total of 1206 participants (16.8%) died during the follow-up period.

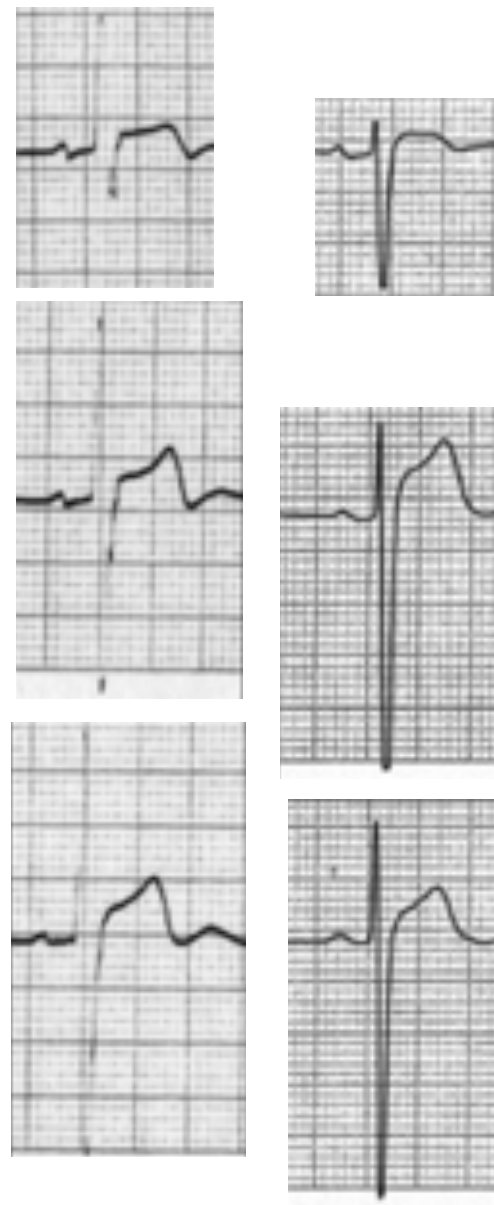Type 1 Brugada pattern



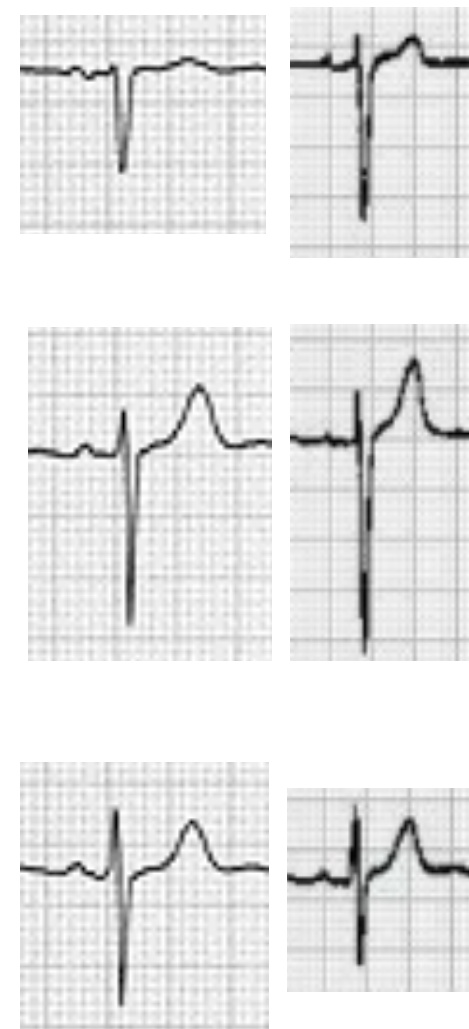
Type 2 Brugada pattern



STSE ≥ 0.2 mV non type 1 and non type 2 BrP



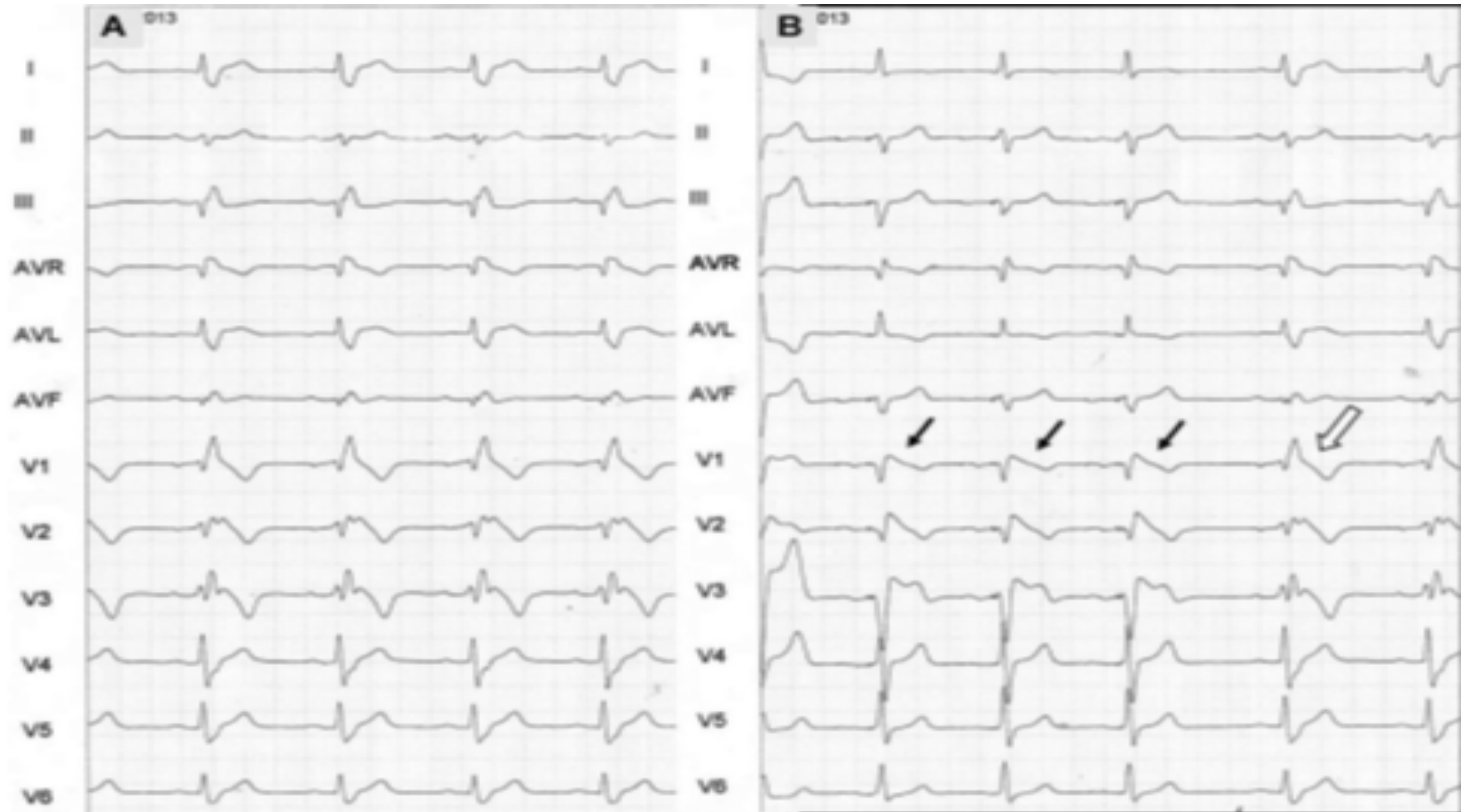
Normal without STSE



The plasma concentration of testosterone is higher in men with BrS than in other age-matched men (**Kamakura 2013**) and was reported to increase net Ito of the epicardium, to aggravate the transmural voltage gradient between the epicardium and endocardium, and to lead to the J point seen in ERS and BrS (**Sekiguchi 2013**). In this study, there was no significant difference in body mass index that would indicate an influence by testosterone between the STERP and non-ST groups, indicating that testosterone may not play a leading role in the prognosis of participants with STERP even if it could influence the J point amplitude. Junttila et al (**Junttila 2013**) reported that testosterone levels were closely associated with not only lateral J point elevation but also with a rapidly ascending ST-segment after J point elevation, which Tikkanen et al (**Tikkanen 2011**) reported as being benign in 3 types of ST-segments (ascending, horizontal, or descending.) The mechanism of the J point in the right precordial leads associated with testosterone would be the same as that in the inferior leads.

In the large number of participants without BrS, the higher amplitude of the J point in the right precordial leads was significantly associated with SCD incidence. A hospital-based study with a small number of participants (n=85) reported that the incidence of SCD of probands with non-type 1 BrP including ECGs with a J point amplitude ≥ 0.1 to < 0.2 mV was similarly as high as those with type 1 BrP (**Kamakura 2013**). In terms of J point amplitude, our result is identical to that of a previous large-scale community-based study that investigated the inferior leads and showed that J point elevation of at least 0.1 mV in the inferior leads was associated with a high risk of cardiac death, and J point elevation of > 0.2 mV in the inferior leads had a higher risk of arrhythmia events and cardiac death (**Nam 2010**). Similarly, the authors focused on the right precordial leads in this middle-aged Japanese general population without BrS and revealed that the amplitude of the J point elevation in the right precordial leads had some prognostic value, and there was a higher risk of SCD among participants with a markedly elevated J point (> 0.2 mV) than among those with more moderate elevation (≥ 0.1 mV).

ECG BrP Obscured by RBBB: How to Resolve the Enigma?; Answer: with Chiale maneuver ([Chiale 2012](#))

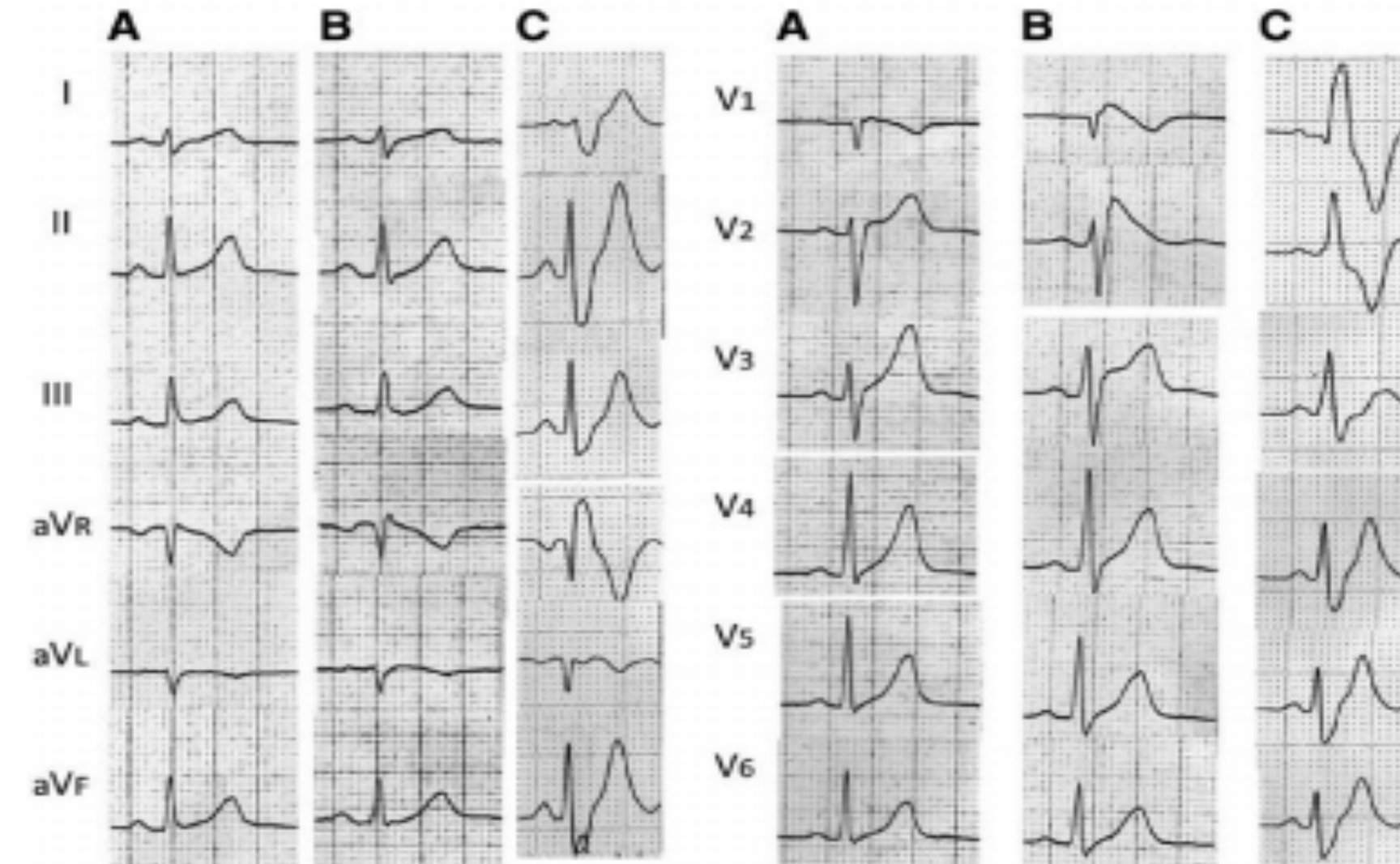


Panel A) 12-lead ECG depicting high degree RBBB.

Panel B) 12-lead ECG depicting the “Chiale” maneuver Right apical ventricular pacing during with timed A-V intervals in the fused QRS complexes.

Black arrows show classic type 1 BrP. Upon cessation of pacing, high-degree RBBB reappears (white arrows) ([Baranchuk 2014](#)).

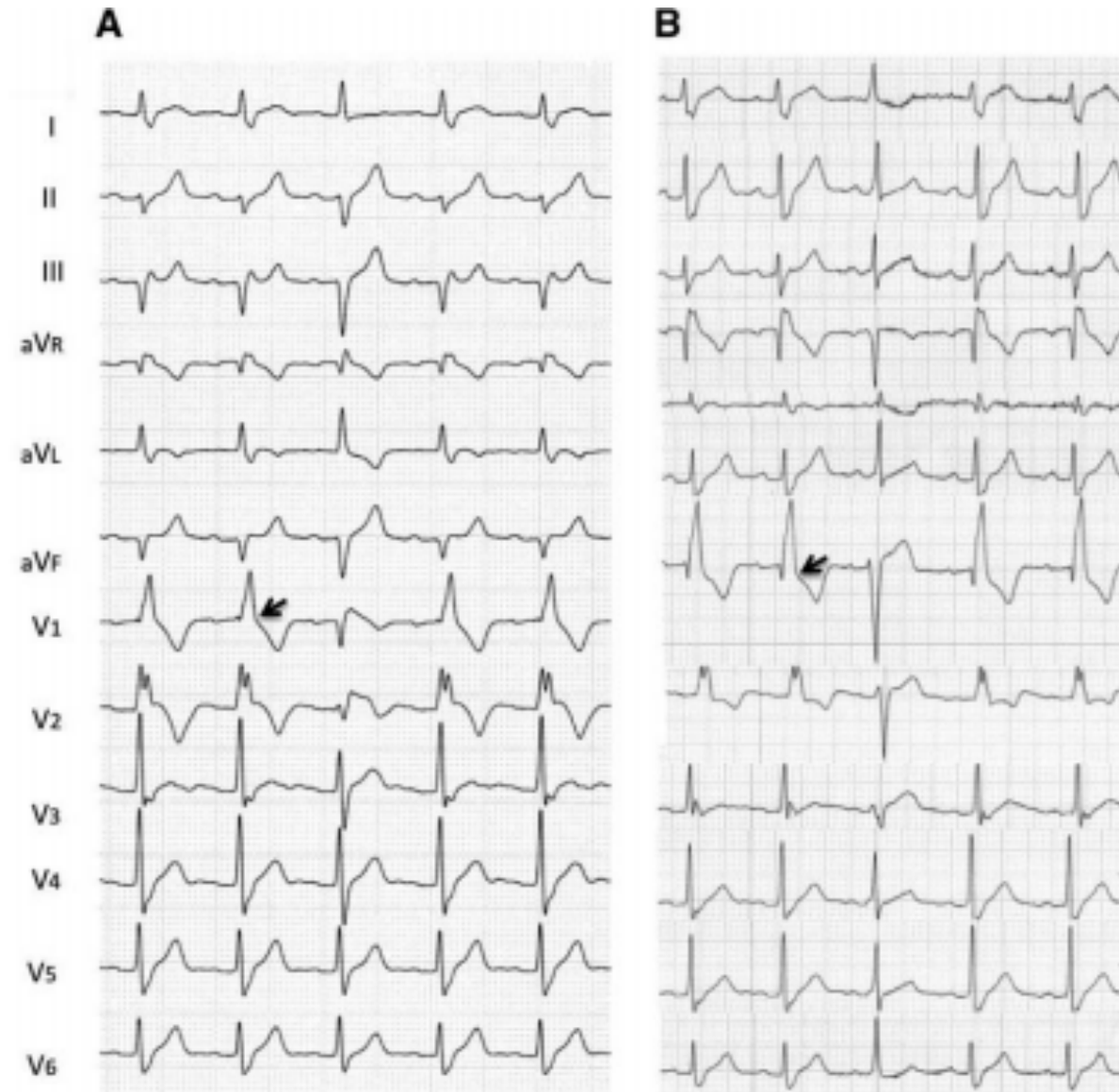
BrS can coexist behind CRBBB, and CRBBB can completely mask BrS. BrS might be demonstrated by relief of CRBBB or by spontaneous or drug-induced ST-SE. The prevalence, mechanism, and clinical significance of a combination of CRBBB and BrS are yet to be determined. Aizawa et al (Aizawa 2013) observed a case in which the characteristic ECG phenotype of BrS was unmasked by relief of complete RBBB; when CRBBB resolved spontaneously, the characteristic ECG pattern of BrS was found to be underlying. (Tomita 2012) A similar case was reported by others (Rolf 2005; Márquez 2005) The goal of this study is to discuss patients with BrS that were complicated by CRBBB and to present evidence for the presence of BrS in CRBBB patients.

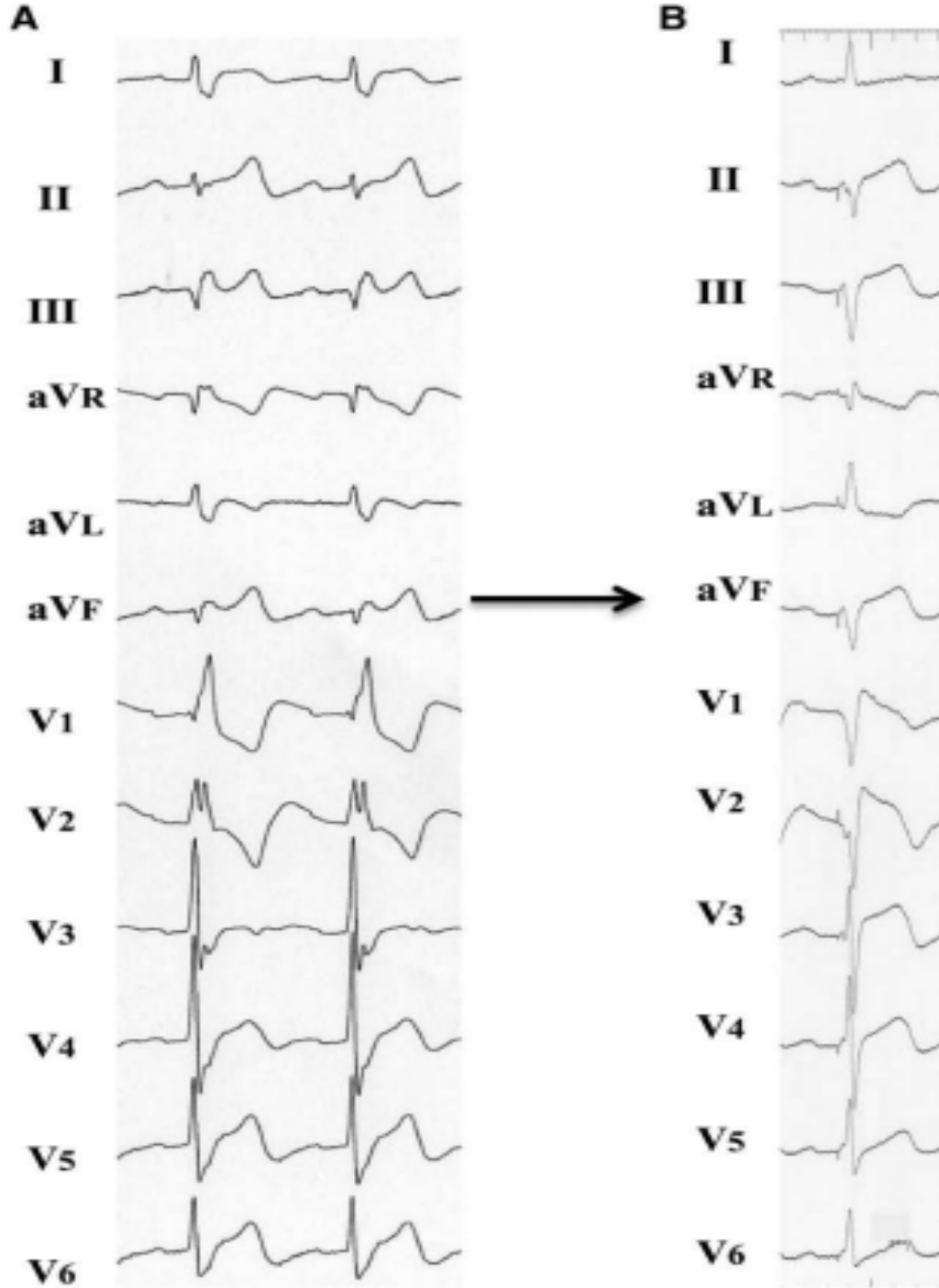


This patient showed variable ECG in the right leads (A and B). During the 2-year follow-up, complete RBBB developed without any precipitating cause (C). The ECG showed a tall R' in V1, and the QRS duration was wide with a slurred, wide S on the left lateral leads (C).

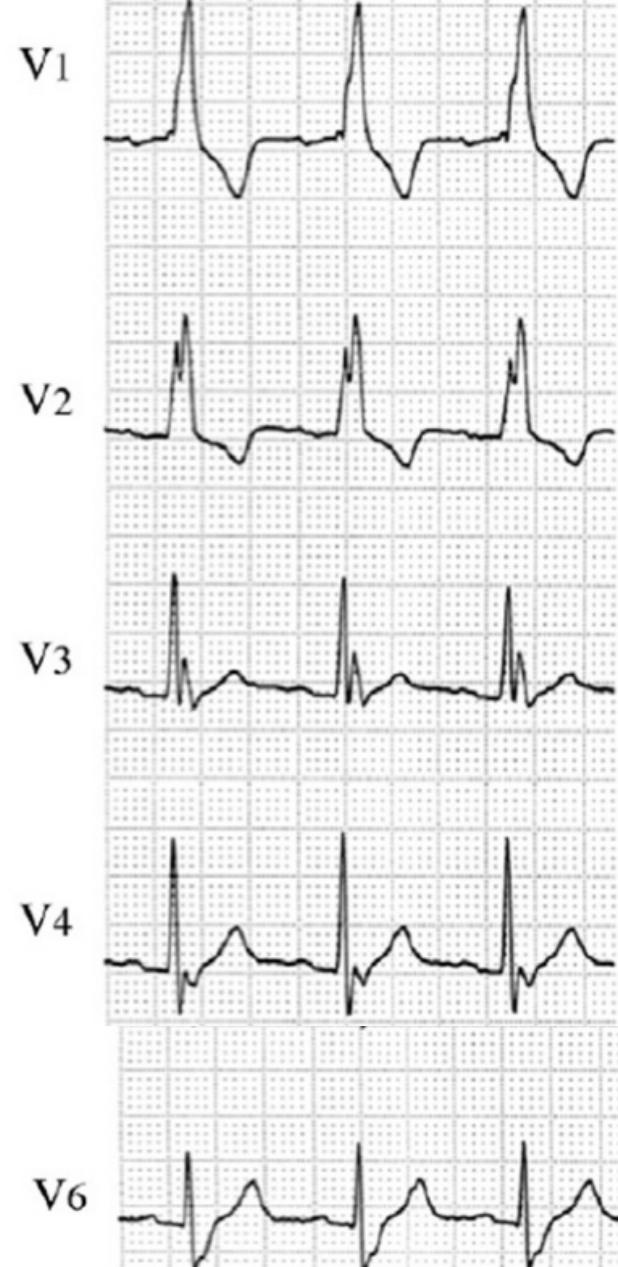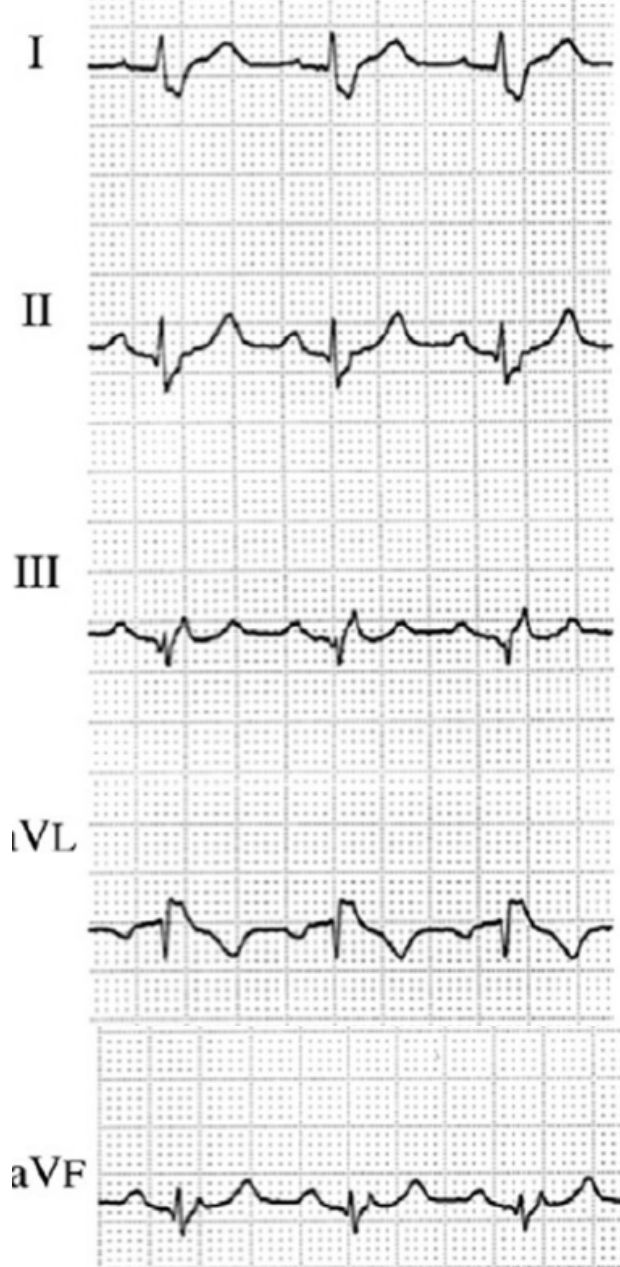
Maury observed RBBB in 28% of cases of BrS from 325 patients with BrS (47 ± 13 years, 258 men) (Maury 2013)

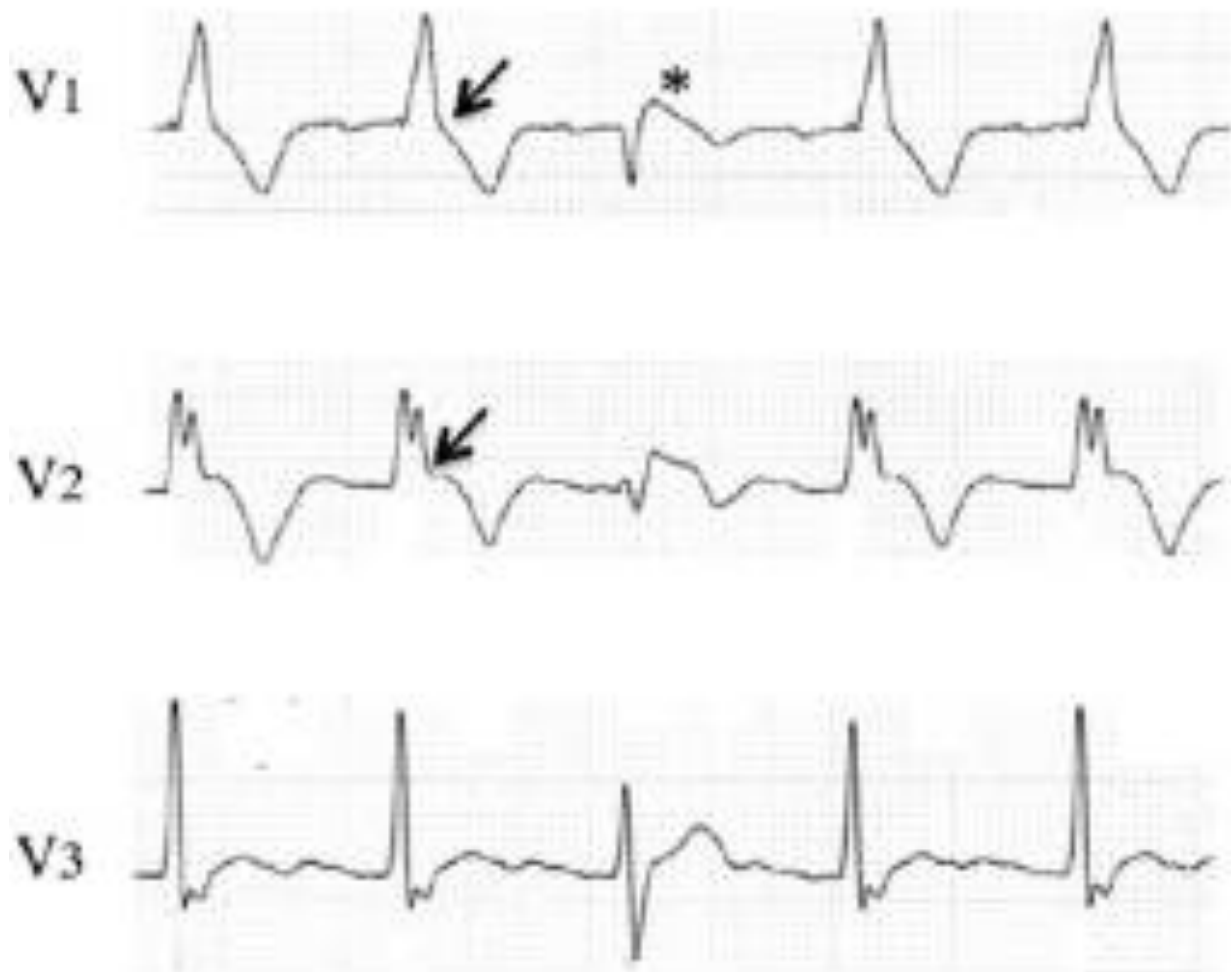
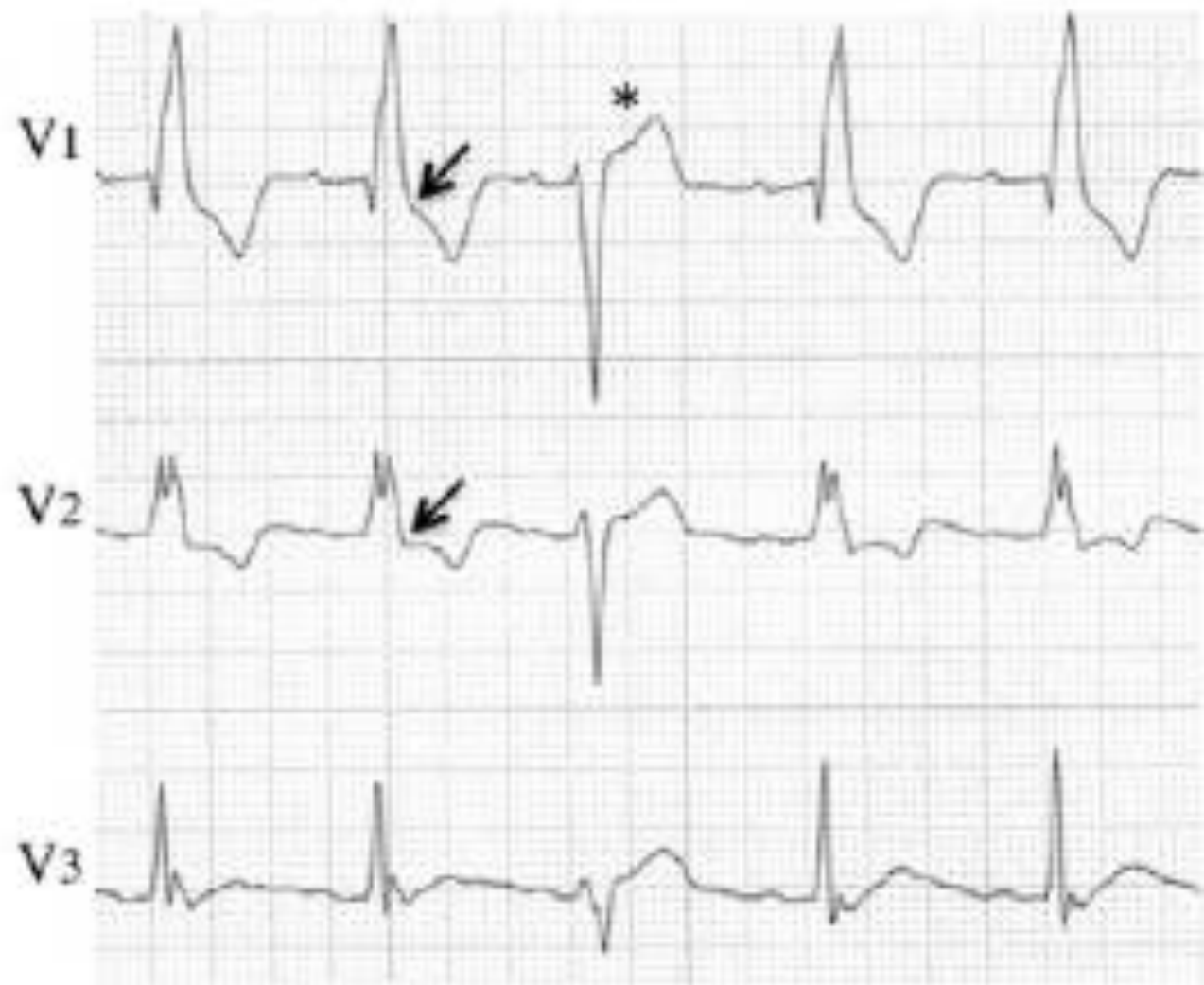
Patient experienced out-of-hospital cardiac arrest and was rescued by emergency personnel. During cardiac catheterization, CRBBB was found to resolve in a single beat, which disclosed type 1 BrP in V1 and V2 (A). Resolution of CRBBB occurred twice without apparent cause with similar findings. After implantation of an ICD, he was monitored by 12-lead Holter, which showed spontaneous resolution of CRBBB twice a day (B). This time, only ST-segment elevation was found in V1 and V2. The different level of the J point suggests that the QRS morphology was affected by the underlying ECG patterns between A and B (arrows)





The atrioventricular sequential pacing was attempted to normalize the QRS complexes in 3 patients. The CRBBB pattern at baseline (A) was normalized by right ventricular pacing (B). The QRS became narrow with left-axis deviation, and leads V1 and V2 showed type 1 BrP (B).



A**B**

The 12-lead ECG with spontaneous normalization of the CRBBB. A, The ECG shows a CRBBB in the first and last 2 beats. The third beat shows a loss of CRBBB and the normalized QRS complex (asterisk), and in this beat, the type 1 BrP. The J point is slightly lowered in V_1 and elevated in V_2 including the initial part of the ST segment (arrows). B, Spontaneous resolution of the CRBBB during the 12-lead Holter recording (asterisk). The normalized QRS complex was associated with a slightly shorter RR and PR interval, and an ST-segment elevation in V_1 and V_2 was evident. The QRS with CRBBB showed distinct downward displacement of the J point and the ST segment (arrows).