

## **THE DIFFERENTIAL DIAGNOSIS OF BRUGADA ECG PATTERN WITH ECG OF PECTUS EXCAVATUM**

**By Andrés Pérez Riera**

Chest wall deformities are the most common congenital chest deformities and are more popularly known as 'funnel chest' or "sunken chest" (pectus excavatum) or "pigeon chest" (pectus carinatum). Pectus deformities occur in 1-8 per 1000 individuals and are more frequent in boys than girls. Pectus excavatum is defined as an abnormal formation of the rib cage where the breastbone caves in, resulting in a sunken chest appearance. Pectus excavatum would therefore seem to be the expression of a minor form of dystrophy of collagen and elastin tissues and a clinical marker of possible mitral valve prolapse<sup>1</sup> Marfan syndrome, Kyphoescoliosis, straight back syndrome and others.

In pectus excavatum (funnel chest) the sternum (breastbone) is depressed in a concave shape and in pectus carinatum (pigeon chest) the sternum protrudes in a convex shape. In pectus excavatum, it is believed that the heart is displaced to the left side of the chest. There is a restriction of movement of the heart and lungs. Patients complain of a decrease in stamina and endurance during strenuous exercise (67%), frequent respiratory infections (32%), chest pain (8%), and asthma (7%).

### **ECG FEATURES IN PECTUS EXCAVATUM AND ITS RELATION WITH BRUGADA SYNDROME**

- 1) Rhythm: sinus rhythm is the rule, but paroxysmal tachycardia has been reported.
- 2) P waves: entirely negative in lead V<sub>1</sub>, because the relation between the atria and the location of lead V<sub>1</sub> electrode is altered: This is explained by atrial activation proceeding in a direction away from the site of the lead V<sub>1</sub> because of leftward displacement of the heart owing to the chest deformity. Become similar to aVR frontal unipolar lead<sup>2</sup>.
- 3) QRS: Occasionally extreme left QRS deviation.
- 4) QRS:  
Sometimes SI-SII-SIII pattern or SI-SII-SIII syndrome: predominantly negative deflection of the S wave type in the standard limb leads, with S wave greater or equal to the R wave in each lead. The SI-SII-SIII syndrome is typical of straight back syndrome<sup>3,4</sup>.  
Occasionally, an r end wave is observed in aVR lead.  
A triphasic rSr' pattern in lead V<sub>1</sub> is one of the characteristics ECG changes: PSEUDO INCOMPLETE RIGHT BUNDLE BRANCH BLOCK PATTERN. The last r' wave is usually small<sup>5</sup>.
- d) Clockwise rotation of the QRS complex in the precordial unipolar leads.
  - > In some patients, a Qr pattern is recorded.

Complete RBBB have been reported.

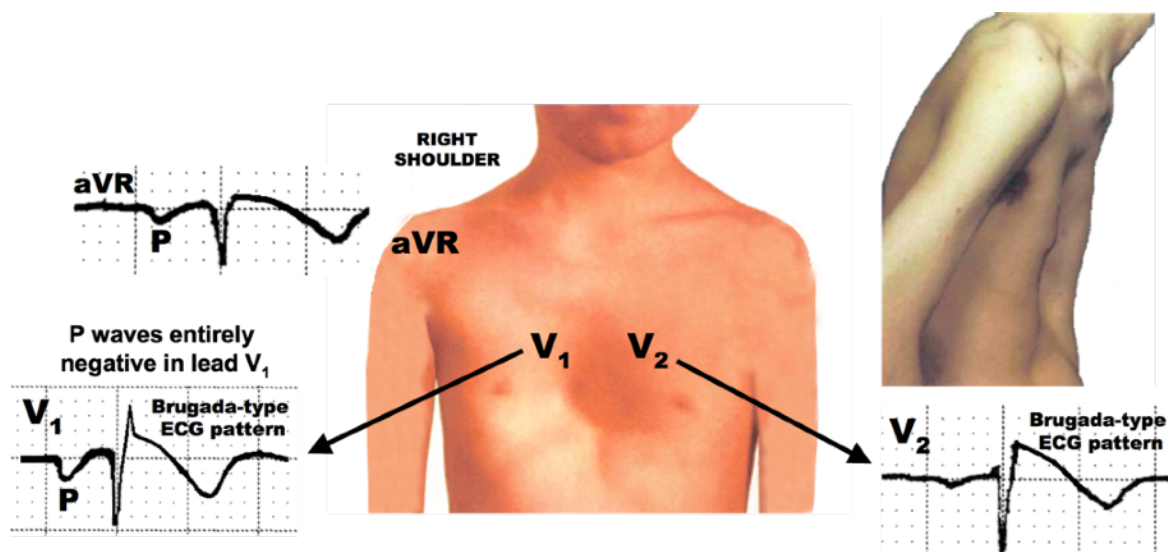
- Abnormal Q waves are seen most often in the right and mild-unipolar precordial leads or in inferior leads (pseudo anteroseptal or inferior infarction)<sup>6</sup>.

1) 5) ST-segment elevation in the right precordias ECG leads.

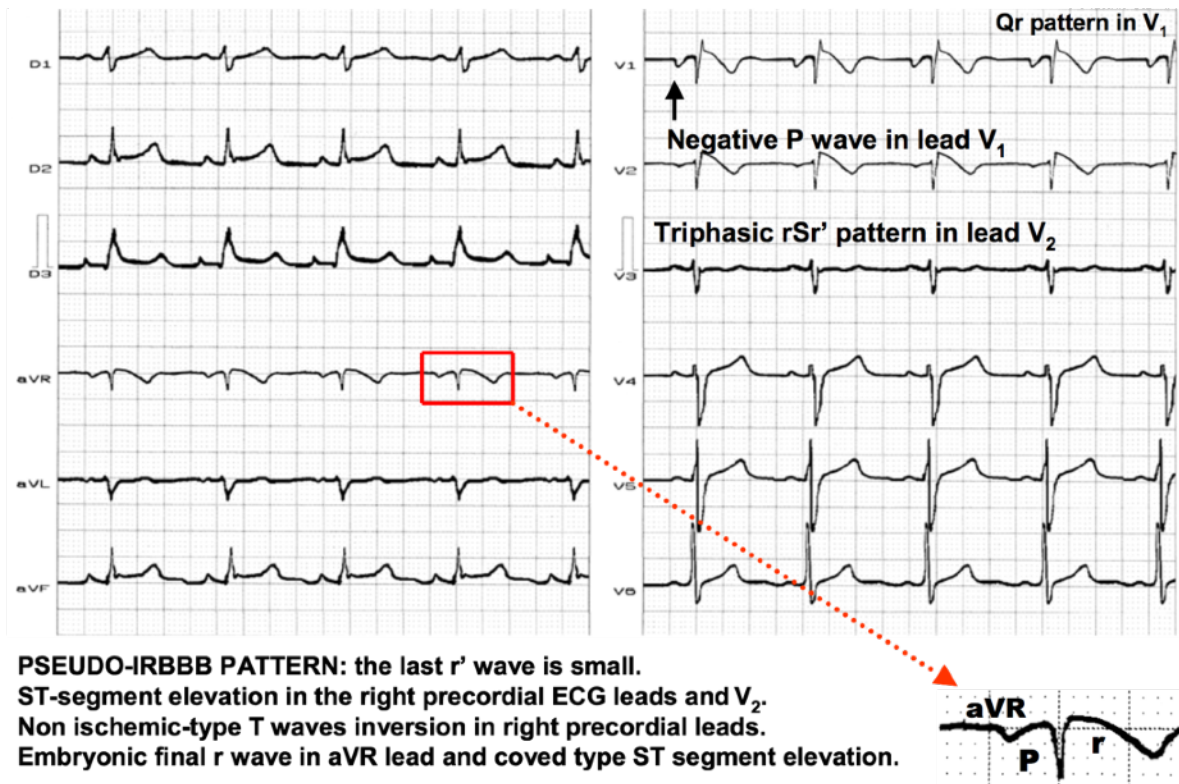
6) Nonischemic-type T wave inversion in right or mild precordial leads<sup>7</sup>.

7) Brugada-type ECG pattern, i.e., RBBB pattern and ST-segment elevation in the right precordial ECG leads have been described<sup>5</sup>. So, a clinically benign Brugada-type ECG pattern may appear in some patients with pectus excavatum<sup>8</sup>.

8) Eventual false positive exercise test.



ECG OF AN 18 YEAR-OLD MALE PATIENT WITH PECTUS EXCAVATUM  
BRUGADA-TYPE 1 ECG PATTERN



References

1. Saint-Mezard G, Chanudet X, Duret JC, et al. Mitral valve prolapse and pectus excavatum. Expressions of connective tissue dystrophy? Arch Mal Coeur Vaiss 1986;79:431-4.
2. De Oliveira JM, Sambhi MP, Zimmerman HA. The electrocardiogram in pectus excavatum. Br. Heart J 1958; 20:495-501 .
3. Pileggi F, Tranchesi J, Grandiski B, Ebaid M, Rodrigues JR, Germiniani H.; Decourt, L.V.: Análise vectocardiográfica da ativação ventricular em indivíduos com electrocardiogramas do tipo S1 S2 S3. Arq. Bras. Cardiol.1961; 14:373.

de Leon, A. C.; Perlof, J. K.; Twigg, H et al.: The Straight back syndrome: Clinical cardiovascular manifestations. Circulation,1965; 32:193-8.

- 1) Camerini, F.; Davies, L. G.: Secondary R waves in right chest leads. Br.Heart J. 1955;17:28.

Dessler W, Roesler H. Electrocardiographic changes in funnel chest. Am Hear J 1950; 4: 877-883.

- 7) Elisberg El.: Electrocardiographic changes associated with pectus excavatum. *Ann. Intern. Med.* 1958; 49:130-141.
5. Kataoka H. Electrocardiographic patterns of the Brugada syndrome in 2 young patients with pectus excavatum. *J Electrocardiol* 2002; 35:169-71.