


To be or not to be-that is the question



Raimundo Barbosa-Barros, MD
Chief of the Coronary Center of the Hospital de
Messejana Dr. Carlos Alberto Studart Gomes.
Fortaleza – CE- Brazil

Case report

Caucasian man, 62 years old, was admitted in the emergency room with a clinical picture of hemodynamic instability (altered level of consciousness, systolic blood pressure < 90 mm Hg, very high rate pulse (\approx 185 bpm) and prolonged capillary refill time (> 6 seconds return of normal coloration after temporary compression); consequence of sustained wide complex QRS tachycardia (Figure 1). This event was immediately reverted with synchronized direct current (DC) cardioversion, at starting energy dose of 100 J. We preformed immediately a new standard 12-lead ECG that showed QRS fragmentation? or epsilon waves? (Figure 2) and in view of the ECG findings we recorded the accessory bipolar precordial Fontaine leads (F-ECG) placing the left arm on the xiphoidal process and the right arm lead on the manubrium sternum, with the left leg in the location of V4 or V5 because these leads provide a better detection of fragmented QRS (fQRS) and epsilon (ϵ)-wave (Figure 3).

Transthoracic echocardiogram: normal. Left Ventricular Ejection Fraction (LVEF): 66%, normal right ventricle.

Computed tomography of the chest was suggestive of cardiac sarcoidosis with probable cardiac involvement.

Questions:

1. Which is the ECG diagnosis of wide QRS tachycardia at admission? **VT or SVT with aberrancy** **That is the questions**
2. Which is the ECG diagnosis of 12-leads basal ECG preformed immediately after reversion? **fQRS? or ϵ -waves?** **That is the question**
3. Which is the most probable subjacent etiology? **Conceaed form of Arrythmogenic Right Ventricular Cardiomyopathy/Dysplasia or sarcoidosis?** **That is the question**
4. Which are the appropriate approach steps?

Figure 1 - At admission with hemodynamic instability

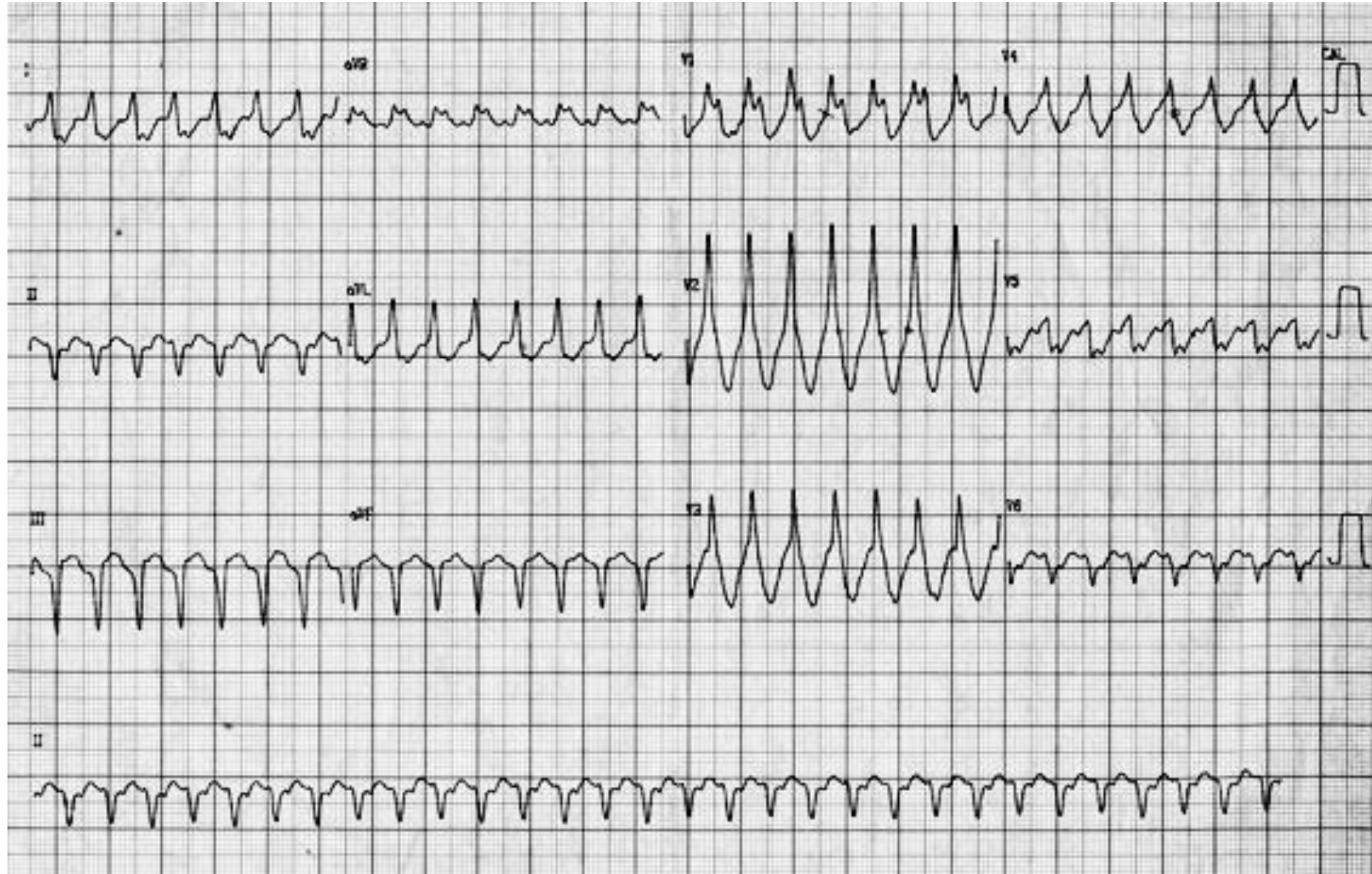


Figure 2 - 12- lead ECG preformed immediately after event reversion

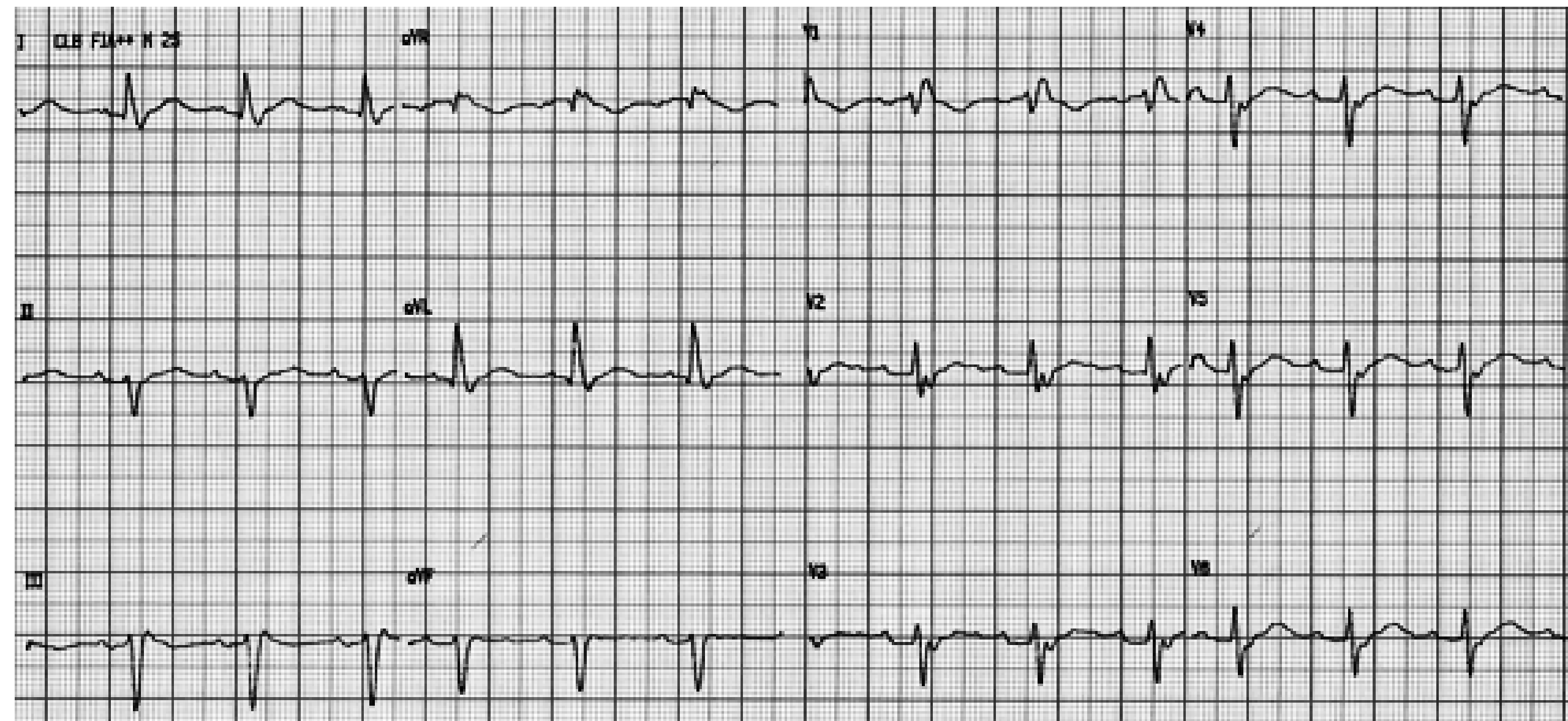
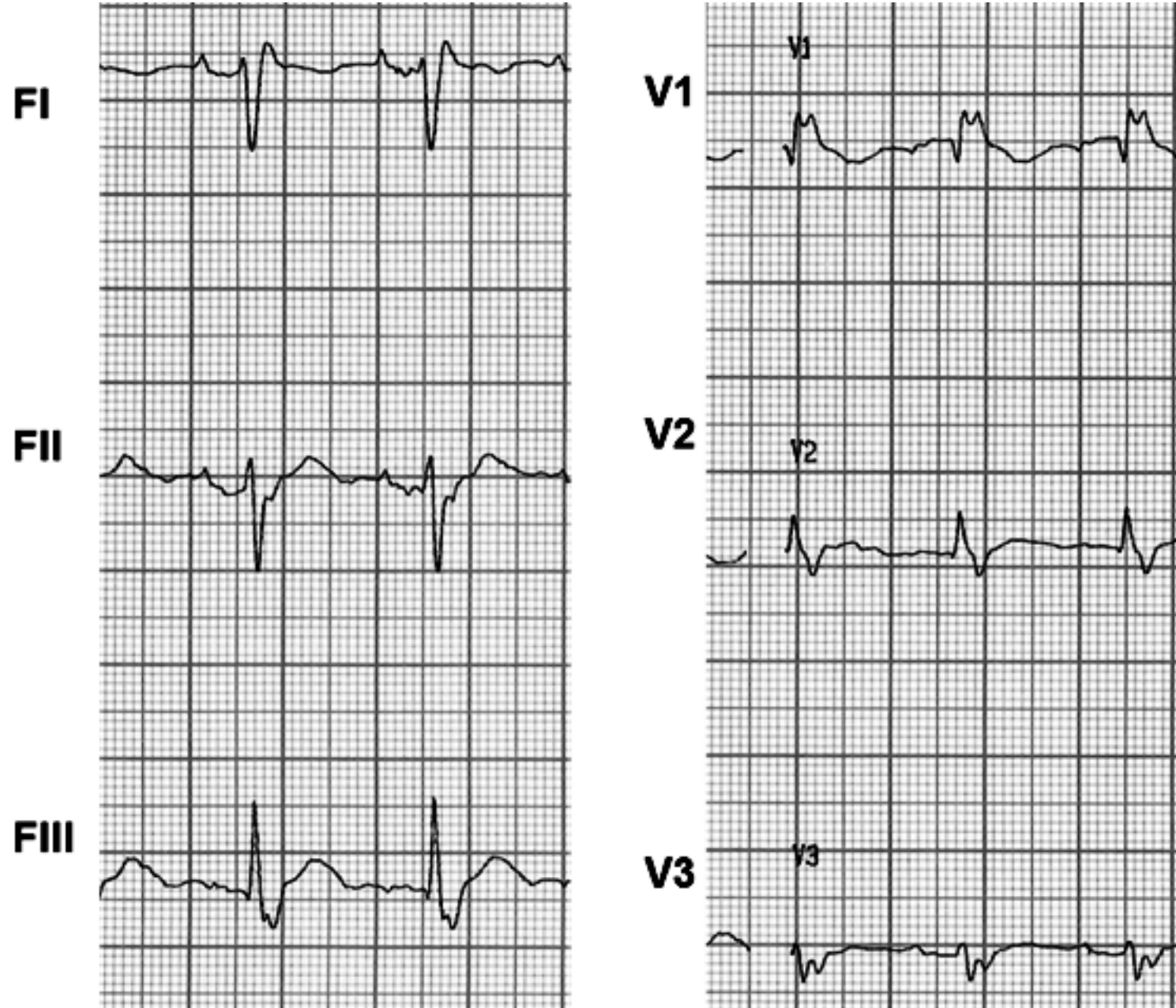
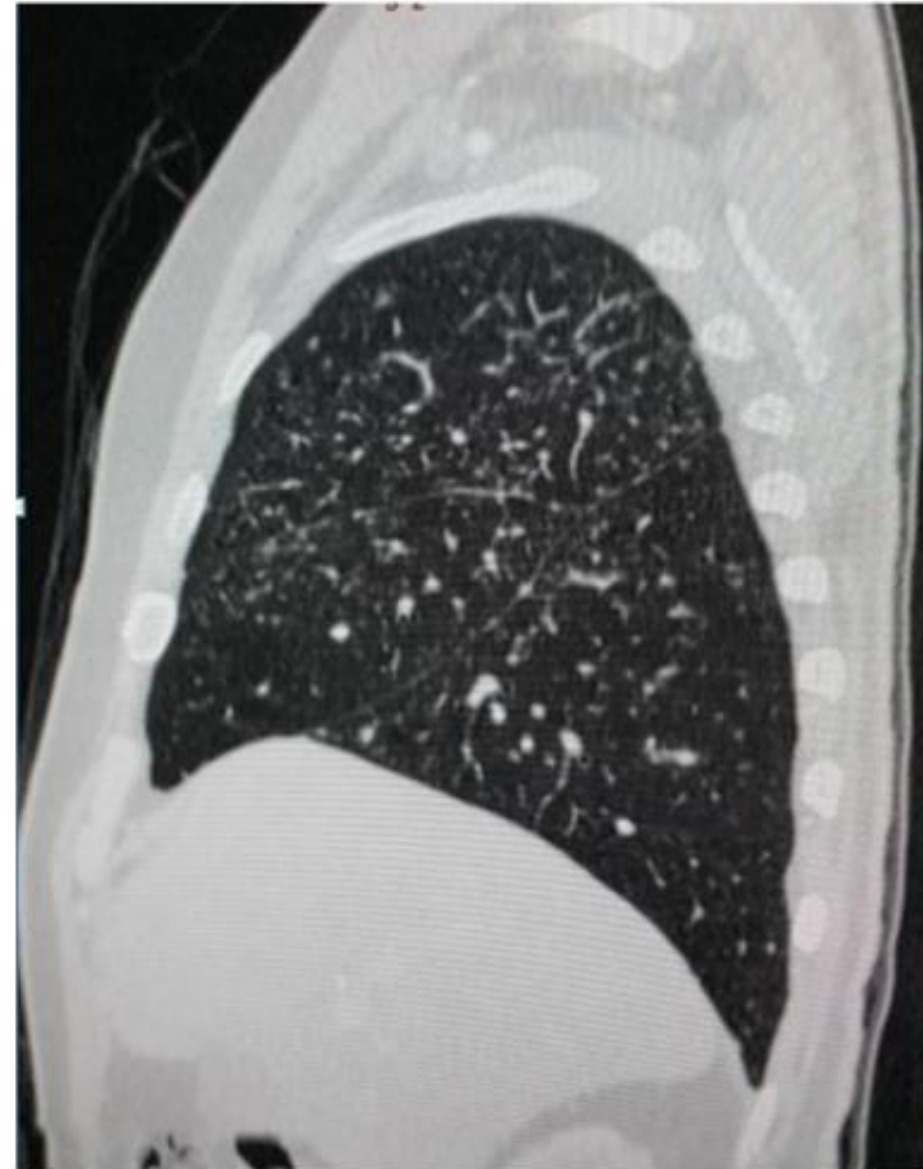
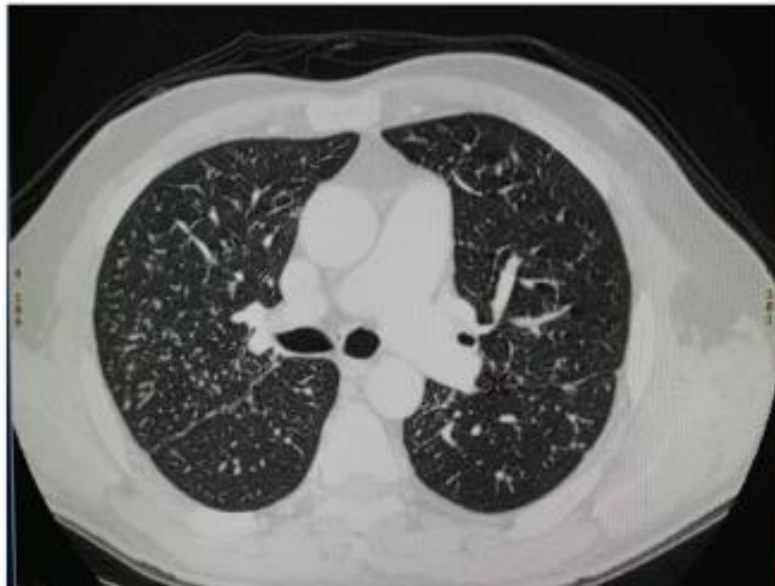
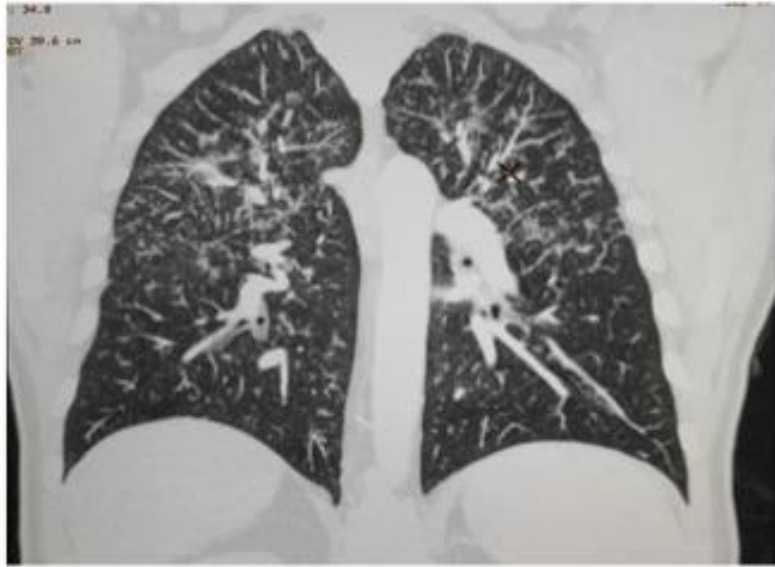
Figure 3 - The accessory bipolar precordial Fontaine leads (F-ECG) Fontaine and right precordial leads



**Thoracic high resolution computed tomography: thickening of the interlobular septa and peribronchovascular.
Presence of nodules in a miliary pattern distributed throughout both lungs**



Spanish

Buenas noches foro. Es un paciente de 62 años que ingresa con descompensación hemodinámica en taquiarritmia.- Creo se trata de una TV monomorfa con probable origen en pared lateral de VI: QRS ancho, eje a la izquierda, R inicial en aVR, Pava positivo en DII, complejo positivo Rr' en V1 y $s/R < 1$ en V6; disociación AV (la veo mejor en DI y aVL), complejos QRS fusionados (diferente voltaje en aVF y V3).

2° ECG ritmo sinusal 68 lpm, PR 200 ms, probable onda P mayor de 120 ms, con componente negativo en cara inferior y V1, BIA avanzado??, eje a la izquierda con trastornos de conducción compatibles con BCRD+HAI.-Impresiona QRS fragmentado más que onda epsilon.- (el QRSf es signo pronóstico de mortalidad y MS). La onda epsilon yo esperaría verla en la DAVD y tiene un ecocardiograma normal, aunque no lo descartaría, Creo es QRS fragmentado por la infiltración granulomatosa de probable sarcoidosis, causando cicatrices por fibrosis y generando circuitos reentrada favoreciendo las TV, también afectaría el sistema de conducción generando trastornos de conducción.-Solicitaría RMN para descartar DAVD, Test de perfusión para descartar defectos segmentarios de perfusión ocasionados por la probable infiltración sarcoidea. Mi diagnostico primario es sarcoidosis, enfermedad granulomatosa multisistémica con afectación predominante en pulmón, que así parece demostrar la TAC. El 2° diagnóstico a descartar DAVD.

Creo que indicaría un CDI, ya que el tratamiento con fármacos a menudo es refractario.

Juan Carlos Manzardo jmanzardo@GMAIL.COM

Good evening Forum. This is a 62-year-old, male patient, admitted because of hemodynamic decompensation in tachyarrhythmia. I think it is monomorphic VT, with a probable origin in the LV lateral wall: wide QRS, axis at the left, initial R in aVR, positive Pava in II, positive Rr' complex in V1 and s/R <1 in V6; AV dissociation (I see it better in DI and aVL), fused QRS complexes (different voltage in aVF and V3).

2nd ECG: sinus rhythm 68 bpm, PR 200 ms, probable P wave > 120 ms, with negative component in inferior side and V1, advanced IAB??, QRS axis at the left with conduction disorders compatible with CRBBB + LAFB. It seems to be fQRS rather than epsilon wave (fQRS is a sign prognostic of mortality and SCD). I would expect to see epsilon wave in ARVC/D and there is normal echocardiogram, but I would not rule it out. I think it is fQRS by granulomatous infiltration by probable sarcoidosis, causing scars by fibrosis and generating reentry circuits fostering VT, also affecting the conduction system, generating conduction disorders. I would request NMR to rule out ARVC/D, perfusion test to rule out segmentary perfusion defects, caused by probable sarcoid infiltration. My primary diagnosis is sarcoidosis, multisystemic granulomatous disease, with predominant lung involvement, that the CT seems to show. The 2nd diagnosis to rule out is ARVC/D.

I think I would indicate ICD, since the treatment with drugs is often refractory.

Juan Carlos Manzardo M.D. From Mendoza Argentina.

jmanzardo@GMAIL.COM



Visit local Mendoza vineyards and discover exactly why Argentina is renowned for its wine!



Estimado maestro por criterios de la TQRS ancho según criterios de Verecke de trata de una TSV

Ricardo Corbalan

ricardo.corbalan@GMAIL.COM

Grupo de Arritmias

Centro Modelo de Cardiología

San Miguel de Tucumán

Tucumán

Argentina

Dear master following Verekei criteria it is a SVT-A



ECG #1 VT from apical crux

ECG #2 RBBB and LAFB

Chest X ray shows military pattern which is an unusual presentation for Sarcoid but has been reported in case reports. Consider PET Scan and Lung biopsy. Likely will need treatment with steroids/methotrexate. If inflammation doesn't resolve consider ICD. Must exclude military TB

Melvin Scheinman, MD

Department of Cardiac Electrophysiology, University of California San Francisco, San Francisco, California, USA.

scheinman@medicine.ucsf.edu

Professor of Medicine

Address:

UCSF

Electrophysiology Service

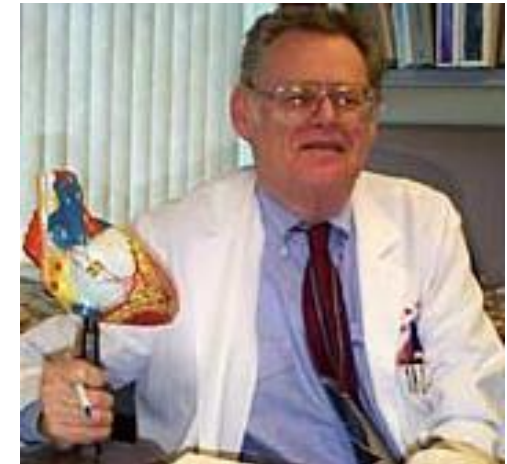500 Parnassus Avenue

San Francisco, CA 94143-1354

Telephone/FAX/E-mail:

Phone: (415) 476-5706

Fax: (415) 476-6260



Even though the QRS during tachycardia is quite similar to the QRS in sinus rhythm, I think this is a ventricular tachycardia. The initial vector corresponding to the left anterior hemiblock (or fascicular block) is missing during tachycardia. Specifically, there are no q waves in lead I and aVL and no r waves in inferior leads. V1 has an initial large R wave that is not consistent with the RBBB morphology observed during sinus rhythm (R prime due to delayed activation of the RV).

The origin of this arrhythmia is the inferior wall of the left ventricle.

In sinus rhythm the late portion of the QRS is consistent with Epsilon waves that are clearly seen in the frontal plane and the Fontaine leads.

The most likely clinical diagnosis is sarcoidosis based on the bilateral and extensive lung nodules.

Some patients with sarcoidosis have an initial clinical presentation mimicking arrhythmogenic right ventricular cardiomyopathy/dysplasia.

Thank you,

Mario González MD

Penn State Hershey Heart and Vascular Institute

500 University Drive

Hershey, PA 17033

Tel: 800-243-1455

Fax: 717-531-4077



Final comments

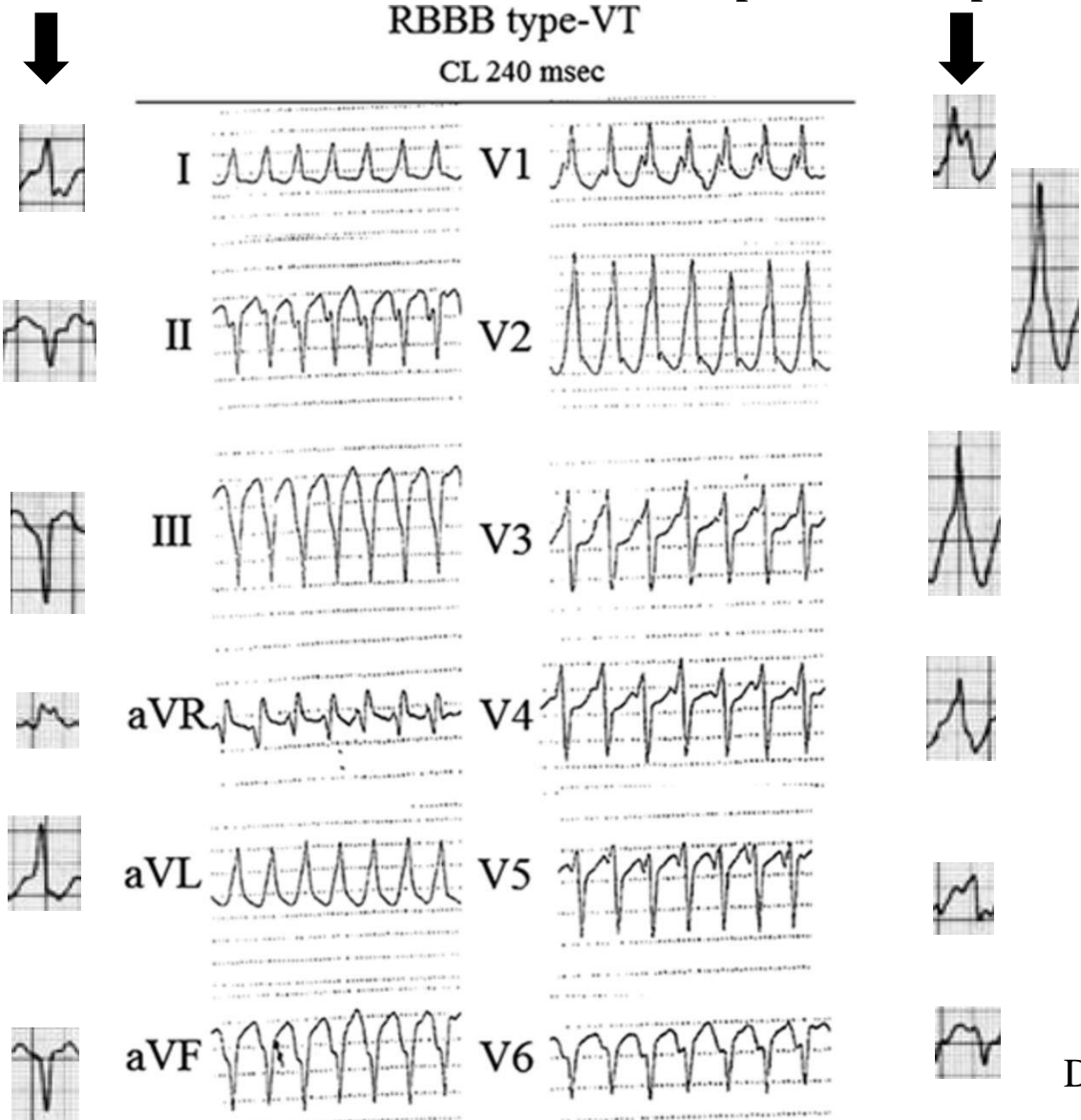
By Andrés Ricardo Pérez-Riera M.D.Ph.D.

<https://ekgvcg.wordpress.com>

Conclusion ECG at admission: This wide QRS complex tachycardia is a Ventricular Tachycardia Arising from Cardiac Crux of the LV with RBB type –VT. It is characterized by negative QS pattern in inferior leads and RBBB pattern V1-V2 as shown in the figure below.

The present case

The present case (precordial leads) QRSd = 160ms



Observation: This type of VA often requires a subxiphoid epicardial approach for RFCA. VT partially may originate from the crux cordis which is accessible for ablation via the middle cardiac vein with good ablation results (**Sultan 2014**). Intracardiac mapping reveals earliest activation in the middle cardiac vein or proximal coronary sinus at the crux. The site of earliest activation is near (5 to 10 mm) of the proximal posterior descending coronary artery. Consequently, requires careful attention to the posterior descending coronary artery during ablation (**Doppalapudi 2009**).

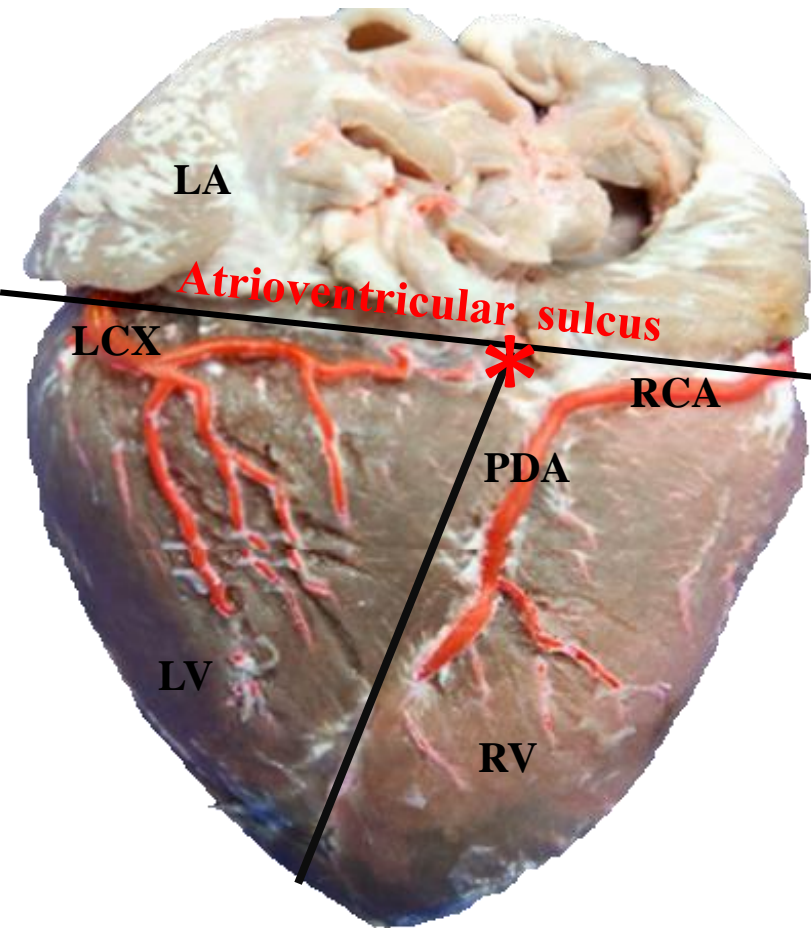
Deep S wave in V6

Patients with crux ventricular arrhythmia (VA) had a wider QRS duration during VA than did those with other form of idiopathic VA (150 ± 27 versus 138 ± 19 ms; $P=0.04$). All patients present with a superior axis and QS pattern in II, III, and aVF (89%) presented with R>S wave in V2 (**Kawamura 2014**).

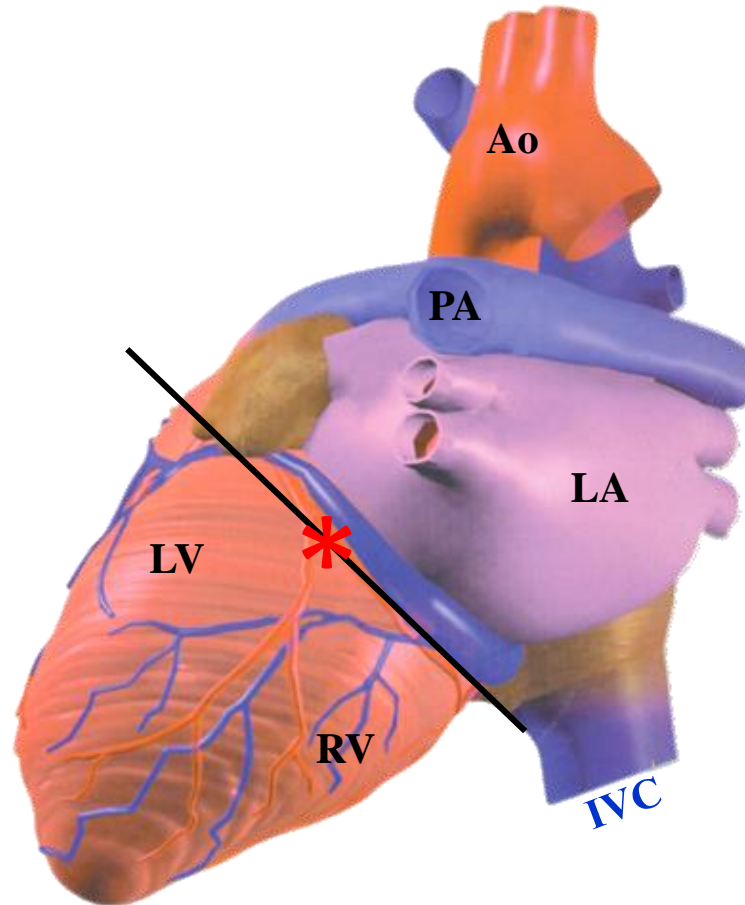
Example of 12-lead ECGs showing typical VT from apical crux cordis area of the LV.
CL: cycle length; RBBB: right bundle-branch block (**Kawamura 2014; Larroussi 2016**).

Cardiac Crux location

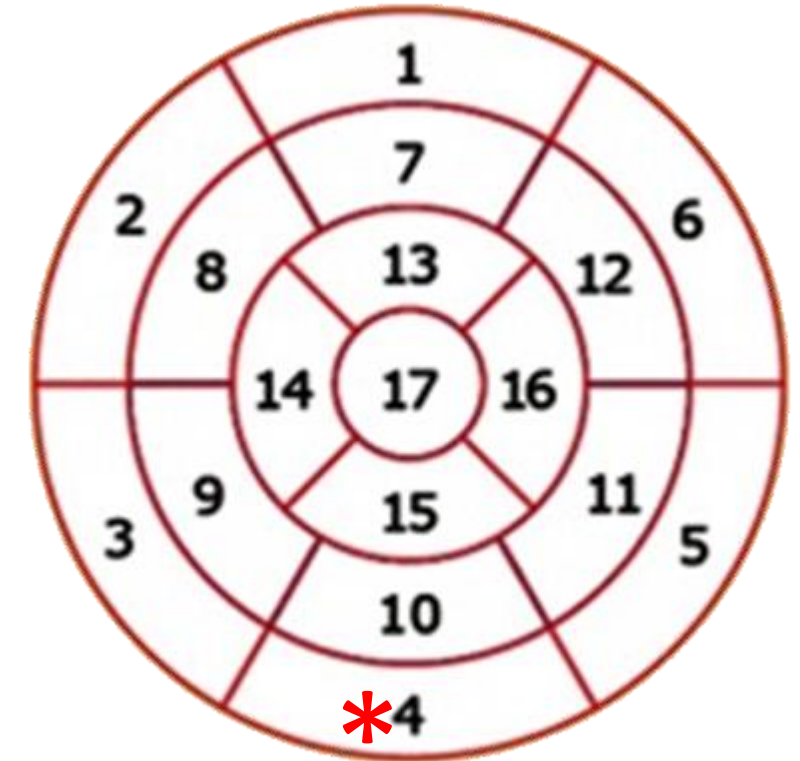
Posterior view of the heart



Left posterior oblique view of the heart



17-segment model: a recommended myocardial segments and their nomenclatures on a circumferential polar display.

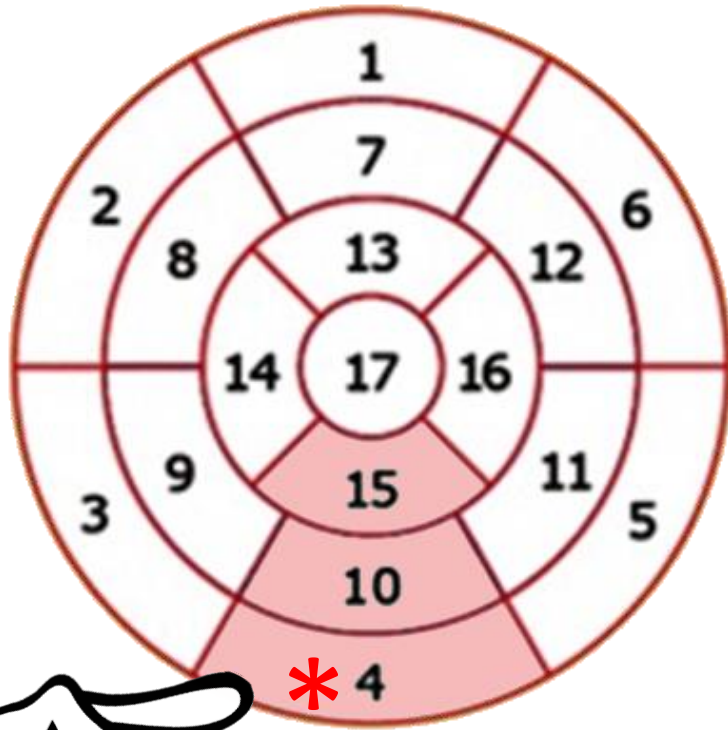


The crux cordis or crux of the heart (from Latin "crux" meaning "cross") is an anatomical landmark formed by the crossing of the atrioventricular sulcus (the groove separating the atria from the ventricles) and the conjunction of the posterior interventricular sulcus (the groove separating the left from the right ventricle) and the interatrial sulcus. *The right coronary artery (RCA), posterolateral artery, and the circumflex artery (LCX) are found in the atrioventricular sulcus. The posterior interventricular artery (PDA) is found in the posterior interventricular sulcus. The AV node artery, which provides blood supply to the AV node usually arises from the PDA, the RCA, or the posterolateral artery at the level of the crux cordis.

ANTERIOR WALL

S
E
P
T
A
L

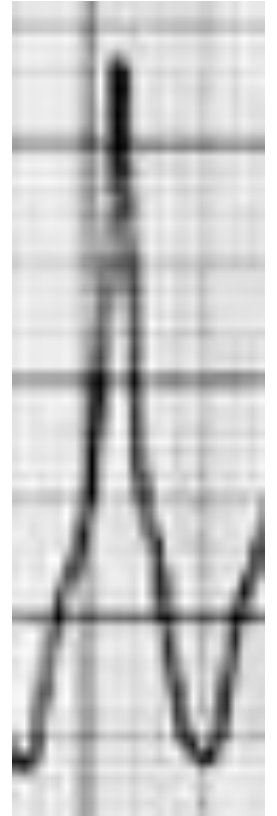
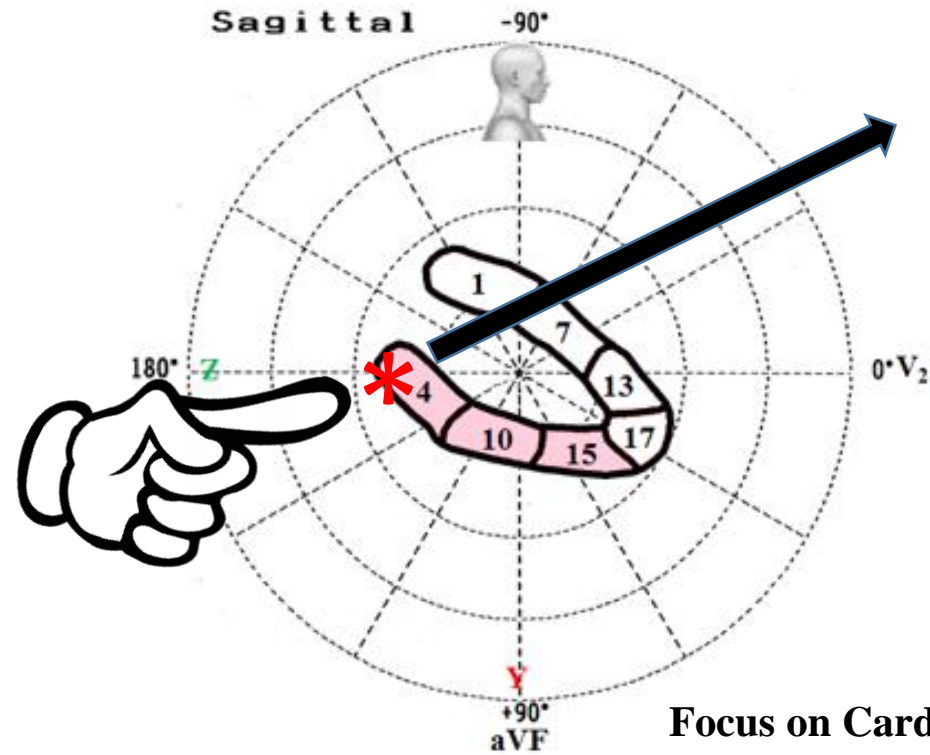
W
A
L
L



INFERIOR WALL

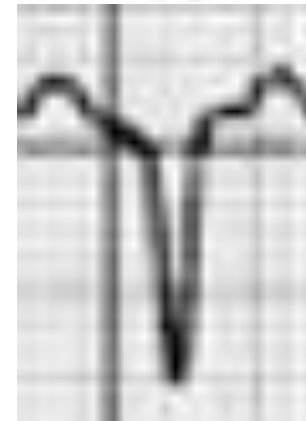
L
A
T
E
R
A
L

W
A
L
L




Focus on Cardiac Crux of the LV with RBB type –VT.

* The focus of VT is in crux cordis or crux of the heart, located in segment 4. Today it is called inferobasal (old dorsal).

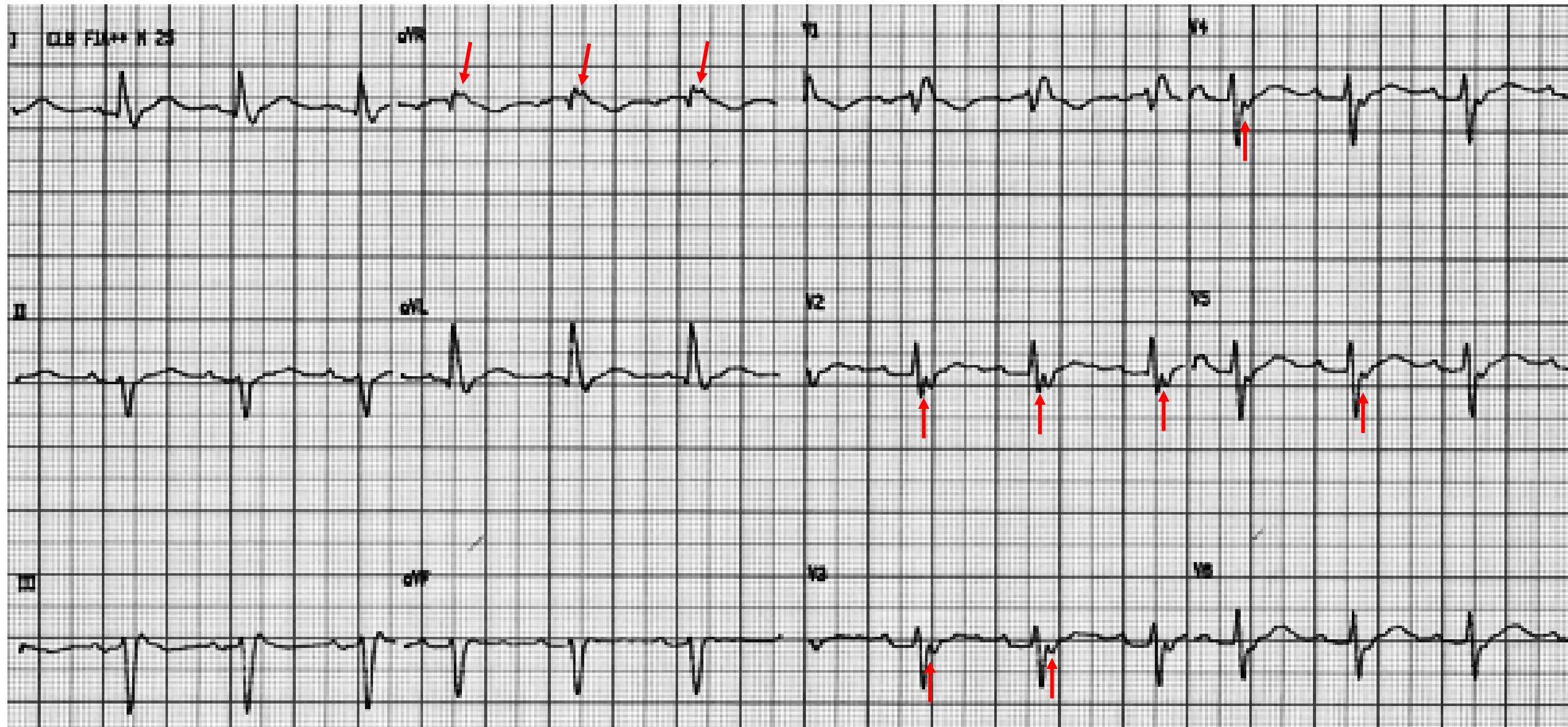


All patients present superior axis and QS pattern in II, III and aVF

QRS morphologies during VT originating from apical crux



ECG-2 after reversion



ECG2 diagnosis: Sinus rhythm, S_{II} < S_{III}, P duration = 90 ms, PR interval = 200 ms, QRS with extreme left axis deviation, S_{III} > S_{II}, qRs I and aVL: LAFB, QRS duration: 160 ms, triphasic pattern in V1 (rsR'), broad final R wave in aVR and wide final S in I: CRBBB.

Conclusion: Bifascicular block (CRBBB + LAFB) + fragmented QRS (fQRS) (red arrows).

Fragmented QRS versus epsilon wave

In approximately 30% of the most severe cases of arrhythmogenic right ventricular cardiomyopathy /dysplasia (ARVC/D), a deflection or small wiggle may be observed in the electrocardiogram (ECG), in most of cases located after the J point at the beginning of the ST segment. They are delayed potentials which appear after the end of ventricular depolarization (recorded after the end of the QRS complex) or post-excitation phenomenon that may be demonstrated by epicardial mapping, intracavitary electrodes, standard ECG(S-ECG), and signal averaged ECG (SAECG) (**Fontaine 1978 Frank 1978**). It was called for the first time by a French pioneer in Electrophysiology Dr. Guy Fontaine (**Marcus 1998**) with the Greek letter epsilon (ϵ) epsilon waves.

I. Others denominations

epsilon potentials (**Peters 2007**), ventricular post-excitation waves (**Maia 1991**), post excitation (epsilon) waves (**Okano 1995**) or with the eponymous Fontaine wave (**Fontaine 1977**). It is a late depolarization of right ventricular fibers of right ventricular free wall (dysplastic triangle) registered mainly in V₁-V₄ leads, these oscillations are best seen in the ST segments of leads V₁ and V₂, different from J wave seen in V₅, V₆ and inferior leads which origin is not so clear. Epsilon waves are not the direct counterpart of late potentials, but reflect the delay peripheral activation in the right ventricular free wall therefore appear to be responsible for much of the genesis of negative T waves (**Okano 1995**).

Semantic discussion: The reason that led this author to choose epsilon name is not clear enough. Could it be because its shape reminded him of the Greek letter Epsilon (ϵ) as suggested by Surawicz e Knilans in their fifth edition of classical book on electrocardiography (**Surawicz 2001**). If this was the case, it should be stated that the epsilon-like wave is in a horizontal position: The tracing shows in the location of the J point and the beginning of the ST segment, an indentation that reminds of the Greek letter epsilon, however, in a horizontal position. Dr. Fontaine could be considered following the Greek alphabet sequence?: α ; β ; δ and ϵ ? If the additional wave observed in ventricular pre-excitation is located at the beginning of QRS complex is called delta wave (δ), the following additional wave in the Greek enumeration should be called with the following letter: epsilon ϵ . Faced with this doubt, I decided to ask the author of this nomenclature, Dr. Fontaine himself, who replied to me thus: *"Dear Dr. Pérez-Riera, Thanks for your documents. The naming of the ECG waves and the reason of their choice is a long story. Dr. Willis Hurst (**Hurst 1998 a**) in Circulation has published a summary of these some years ago. I have strongly contributed to this paper as indicated by Dr. Hurst. Best regards"*. Dr. Hurst wrote: *"Fontaine discovered and named the epsilon waves. He chose the epsilon because it follows delta in the Greek alphabet and is the mathematical symbol for smallness."* The term "epsilon" was nice, because it occurs in the Greek alphabet after delta; thus, delta represents the preexcitation and epsilon the post-excitation phenomenon. In addition, epsilon is also used in mathematics to express a very small phenomenon. It was quite exciting to demonstrate that these late potentials (LPs) located on the free wall of the RV of patients with ARVC/D could be recorded on the surface by SAECG and in some circumstances by increasing the magnification of ECG recording.

To conclude, even with the great respect I feel for Dr. Boris Surawics and Dr. Timothy Knilans, I have to comment that they made a mistake by thinking that the reason of the name was morphological and not the sequence of the Greek alphabet.

II. Origin of the name epsilon

“Fontaine discovered and named the epsilon waves. He chose the epsilon because it follows delta in the Greek alphabet and is the mathematical symbol for smallness” (**Hurst 1998**).

III. Definition

Classical concept: Epsilon waves have been defined as any potential manifested as a distinct waves of post-excitation with small squiggles, small notches or oscillations (**Khaji 2013**) amplitude that occupy mainly the beginning of the ST segment after the end of the QRS complex (J point) (**Wang 2010**). In other words, after the depolarization between the end of the QRS complex and the beginning of the ST segment. Epsilon waves are caused by post excitation of the myocytes in the right ventricle free wall due to myocardial scarring. On ECG, they are small notches, oscillations, wiggles, or smooth potential waves in variable quantities (one single deflection, 2, 3 or more). The Epsilon wave was defined as wiggler, small spike wave and smooth potential located between the end of the QRS complex and the beginning of the ST segment. (**Wang 2009; 2010**):

- Small spike waves: the most common type. They are divided into 2 subtypes, upward and downward
- Wiggle waves
- Smooth potential waves

Epsilon waves are LPs that occur in the RV free wall in patients with ARVC/D and rarely in others physiological and pathological scenarios. As LPs were supposed to be the result of late activation of a limited group of fibers, the term “post-excitation” looked logical, since it was observed after the main excitation of the ventricle, leading to the QRS complex.

The term “epsilon” was nice, because it occurs in the Greek alphabet after delta; thus, delta represents the pre-excitation and epsilon the post-excitation phenomenon. In addition, epsilon is also used in mathematics to express a very small phenomenon.

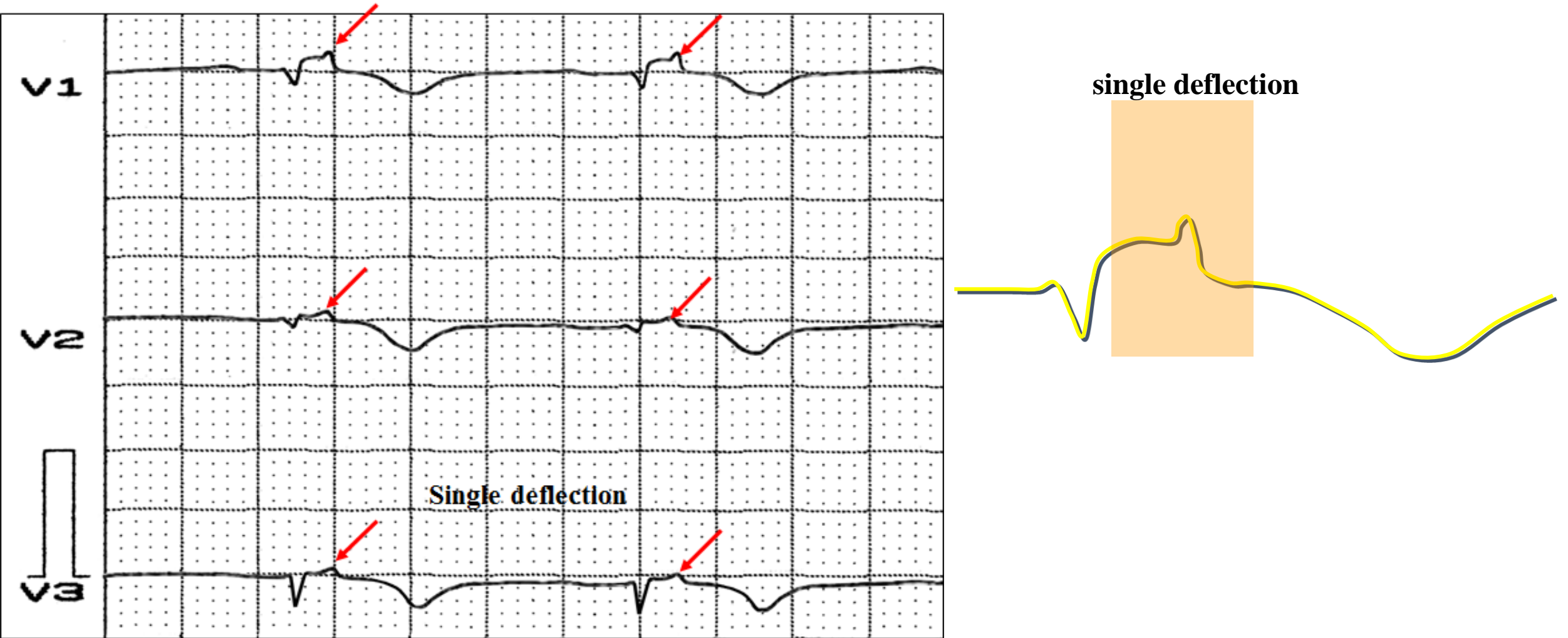
The proximity of the right ventricle (RV) to the anterior precordial leads V1 to V4 explains why the characteristic ECG abnormalities are most prominent in those leads.

The following ECG shows epsilon waves with 1 (single deflection), 2, 3 or multiple waves.

IV. Classification of epsilon wave by the number of deflections

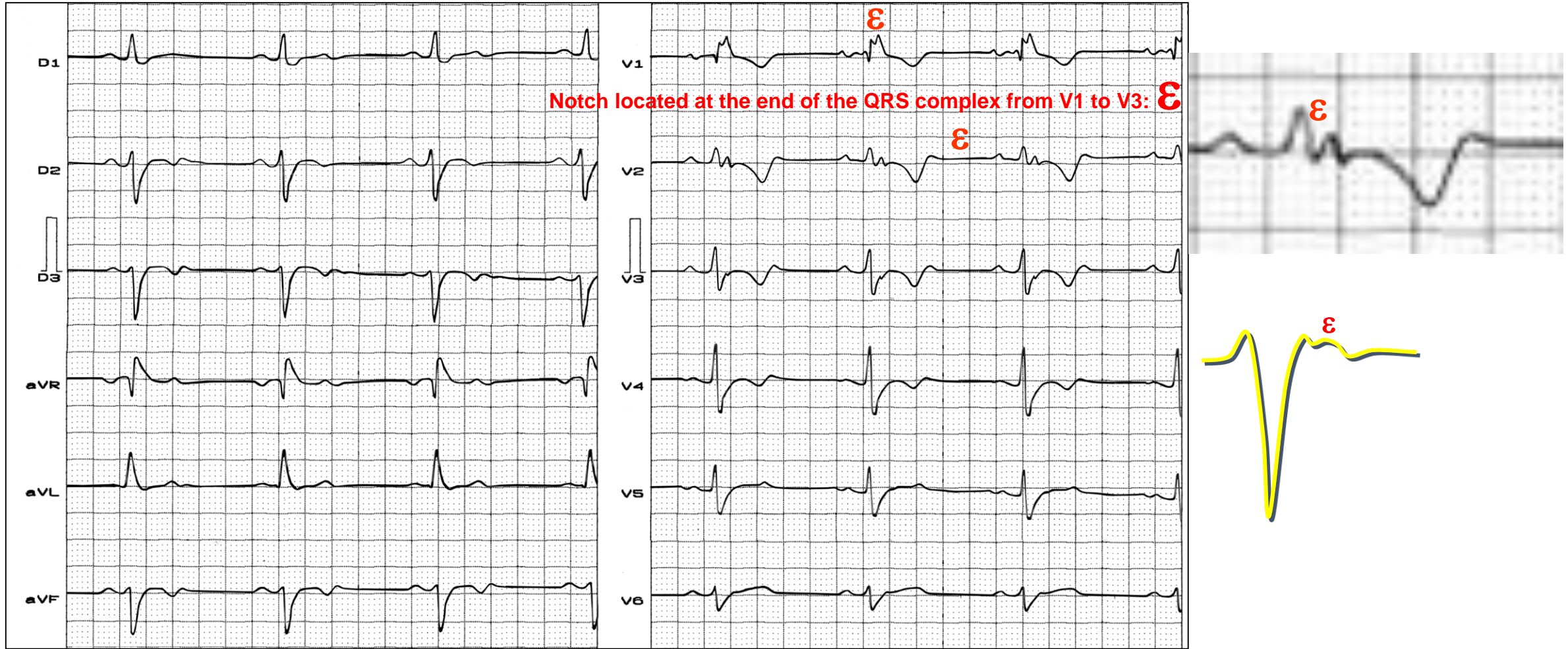
We classified the epsilon waves according to the number of deflections: one, two or multiple deflections.

Example of epsilon wave with single deflection



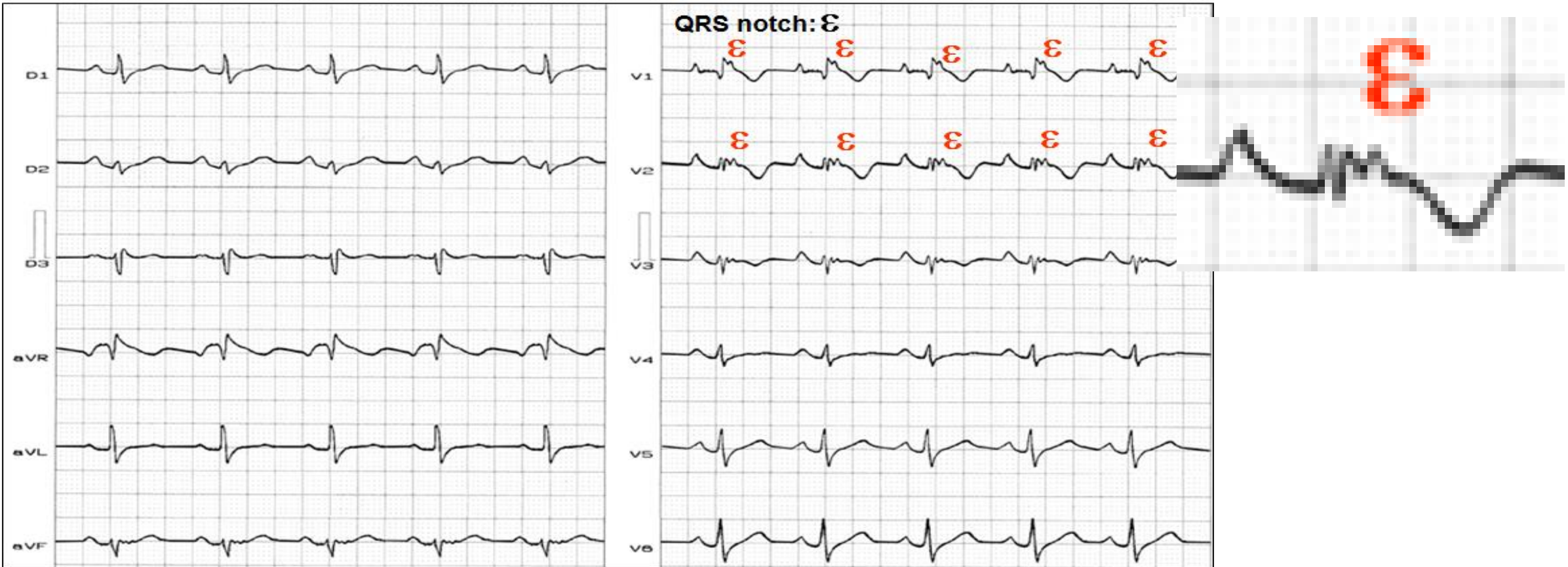
We observe prominent upright deflections (red arrows) after the QRS complex in right precordial leads V1–V3 associated with negative T waves. Epsilon waves are one of the major depolarization diagnostic criteria of ARVC/D following task force. Epsilon waves can be recorded using 12 lead ECG during sinus rhythm, and are useful for establishing a diagnosis of ARVC/D (**Anan 2002**).

Typical ECG of arrhythmogenic right ventricular cardiomyopathy/dysplasia Example of epsilon wave with two deflections



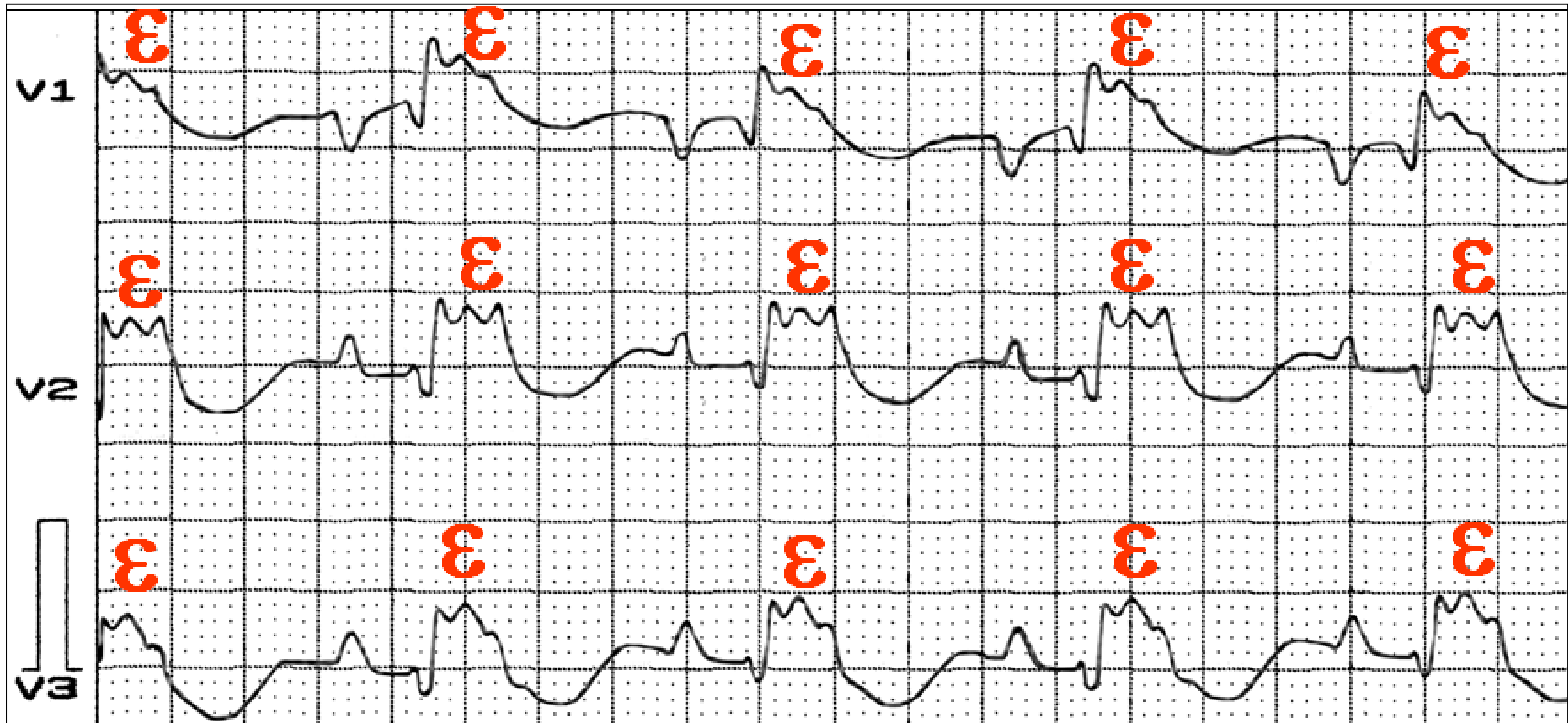
Sinus rhythm, HF: 44 bpm, sinus bradycardia, PR interval: 175 ms, SAQRS: -85°, QRSD: 185 ms, SIII > SDI, LAFB, atypical CRBBB (qR pattern), notch located near the J point (epsilon wave with two deflections) visible from V1 to V3, characteristic of ARVC/D. Negative T wave from V1 to V4.

Example of epsilon wave with deflections located inside of QRS (pre-, top-): fragmented QRS?

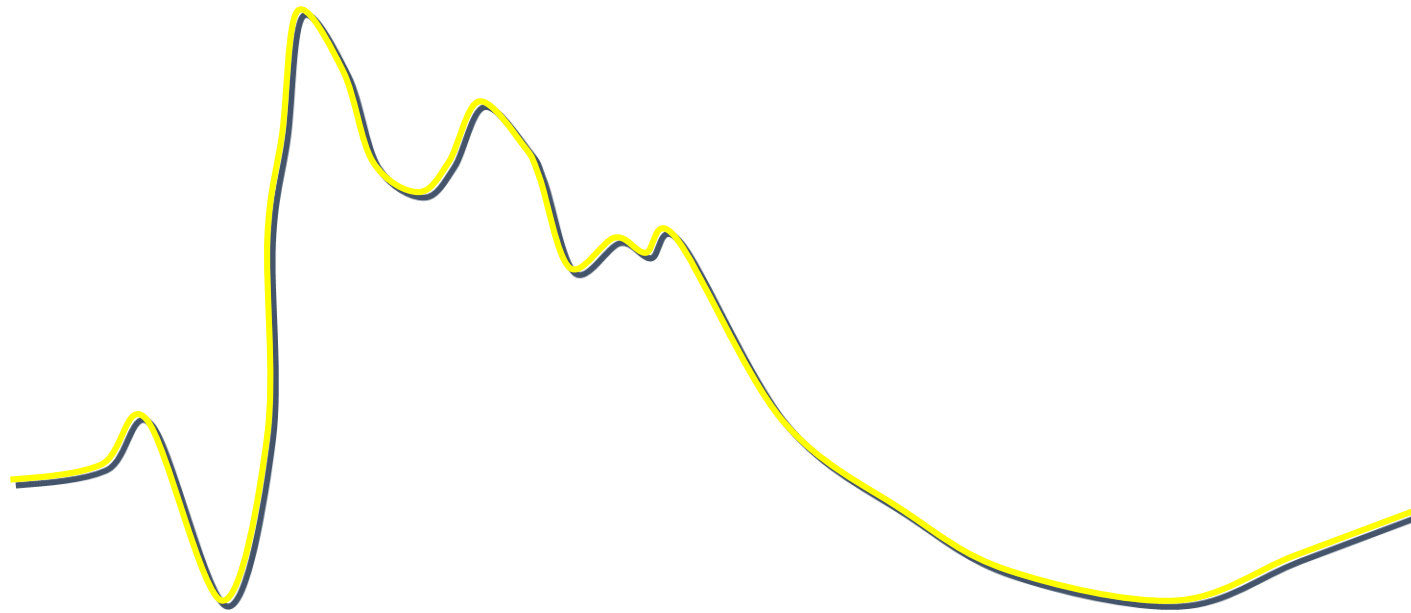



ECG diagnosis: Sinus rhythm, right atrial enlargement(tall P wave in V2), bizarre qR pattern CRBBB, The epsilon wave are visible inside of QRS complexes. Additionally, T wave inversion is observed in V1 to V3, characteristic of ARVC/D. **Observation:** Epsilon waves have been defined as any potential after between the end of the QRS complex and the beginning of the ST segment (**Wang 2010**). Consequently, the phenomena temporarily occur during the repolarization and not during depolarization. The definition of epsilon wave remains difficult because within the QRS complex are inscribed notches or deflections called fragmentation of the QRS complex (f-QRS). The fQRS at the beginning, on the top, and at the end of QRS complex (termed "pre-, top-, and postsilons") was proposed as typical extended definition of epsilon potentials (**Kukla 2012**).

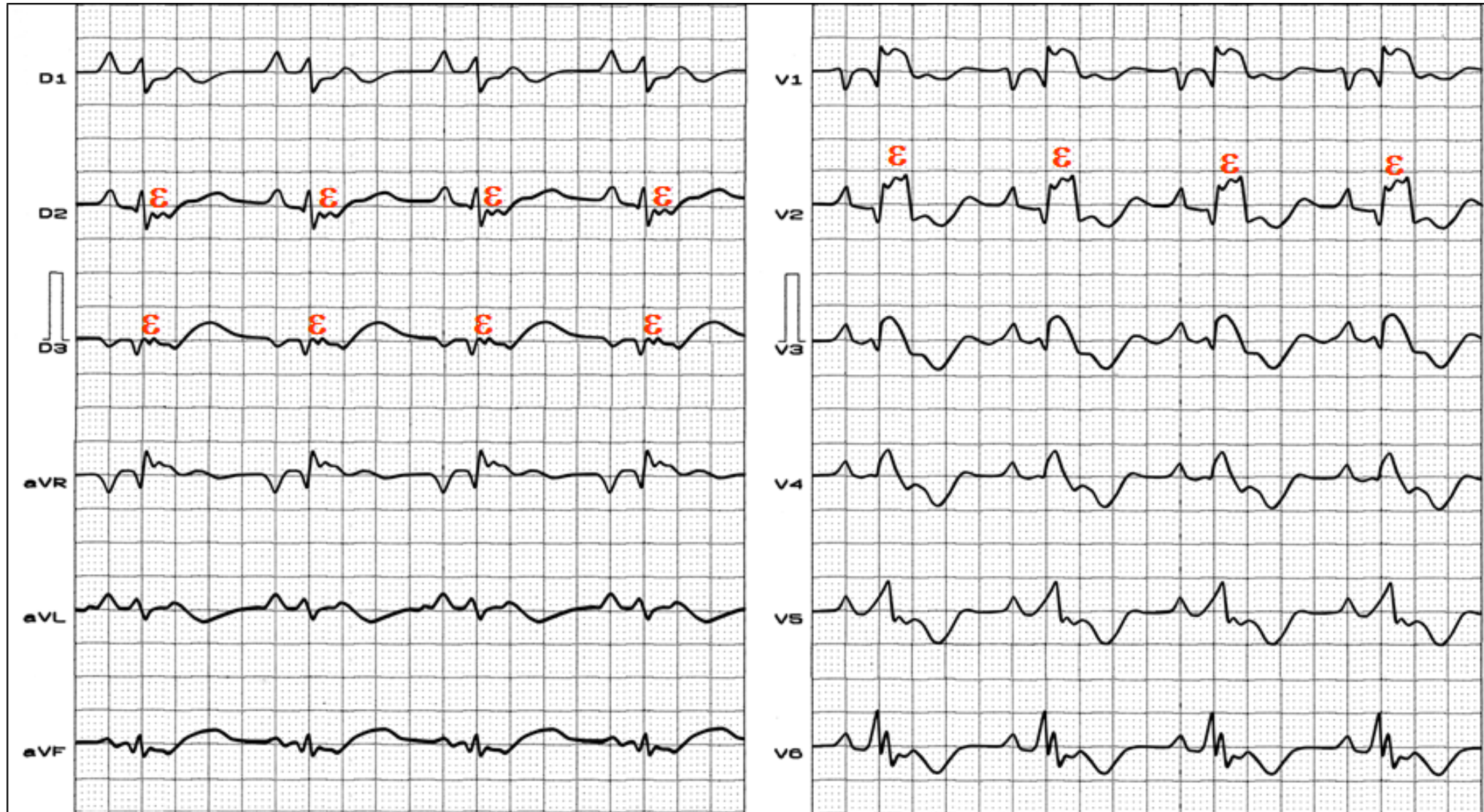
Example of epsilon wave with multiple deflections inside of QRS complex



Epsilon wave with multiple deflections = fQRS?



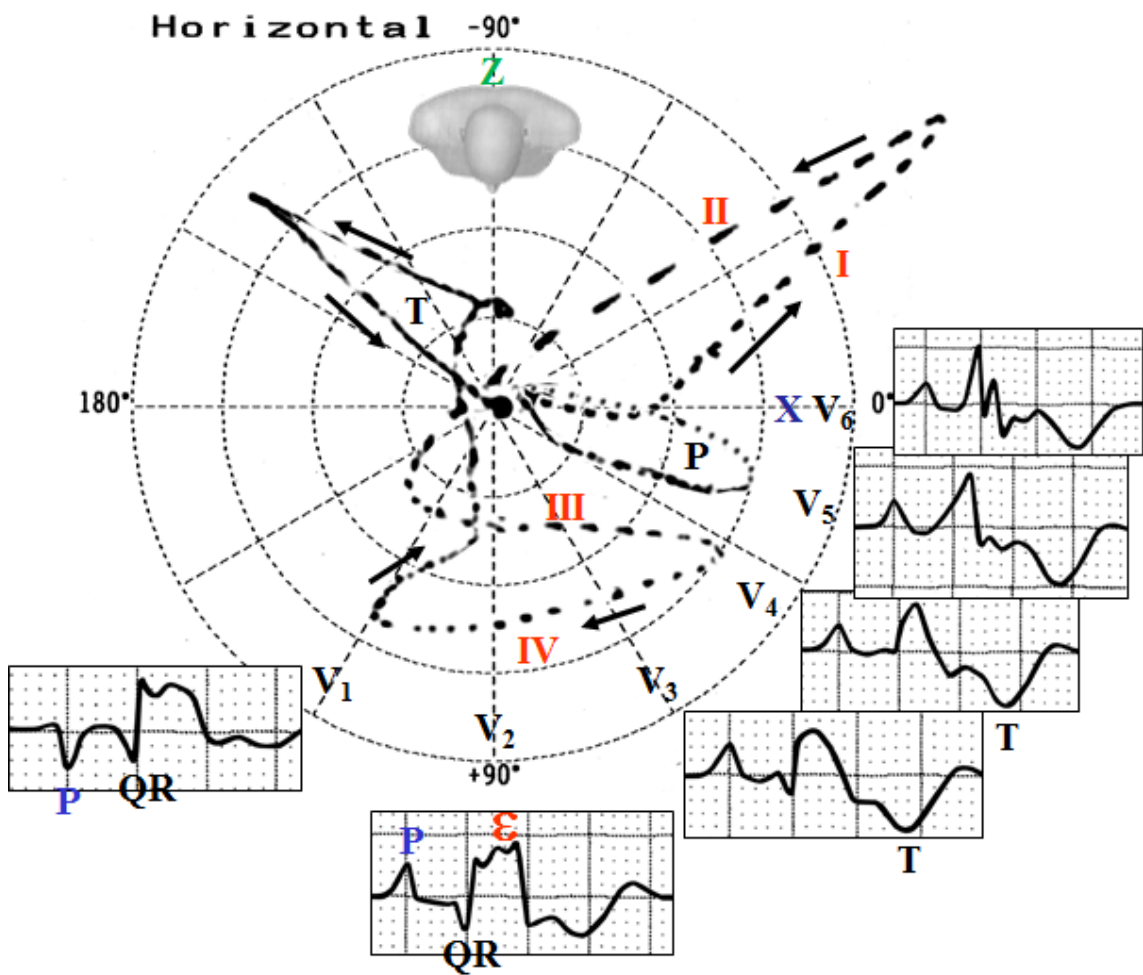
Name: SFD; **Sex:** F; **Age:** 18 y/o; **Race:** Caucasian; **Weight:** 53 Kg; **Height:** 1.52 m; **Biotype:** Normal; **Date:** 05/03/2006



Clinical diagnosis: ARVC/D. Severe right heart failure.

ECG diagnosis: sinus rhythm, HR: 60 bpm; P wave: SÂQRS near 0°, voltage: 3 mm, duration: 130 ms: negative polarity in V1 and positive in V2, q wave in V1 and V2: biatrial enlargement? or right ventricular mega enlargement? QRSd: 230 ms (CRBBB); epsilon waves are observed in numerous leads(across precordial leads and inferior leads) inside and outside of the QRS.

ECG/VCG correlation in the horizontal and frontal planes



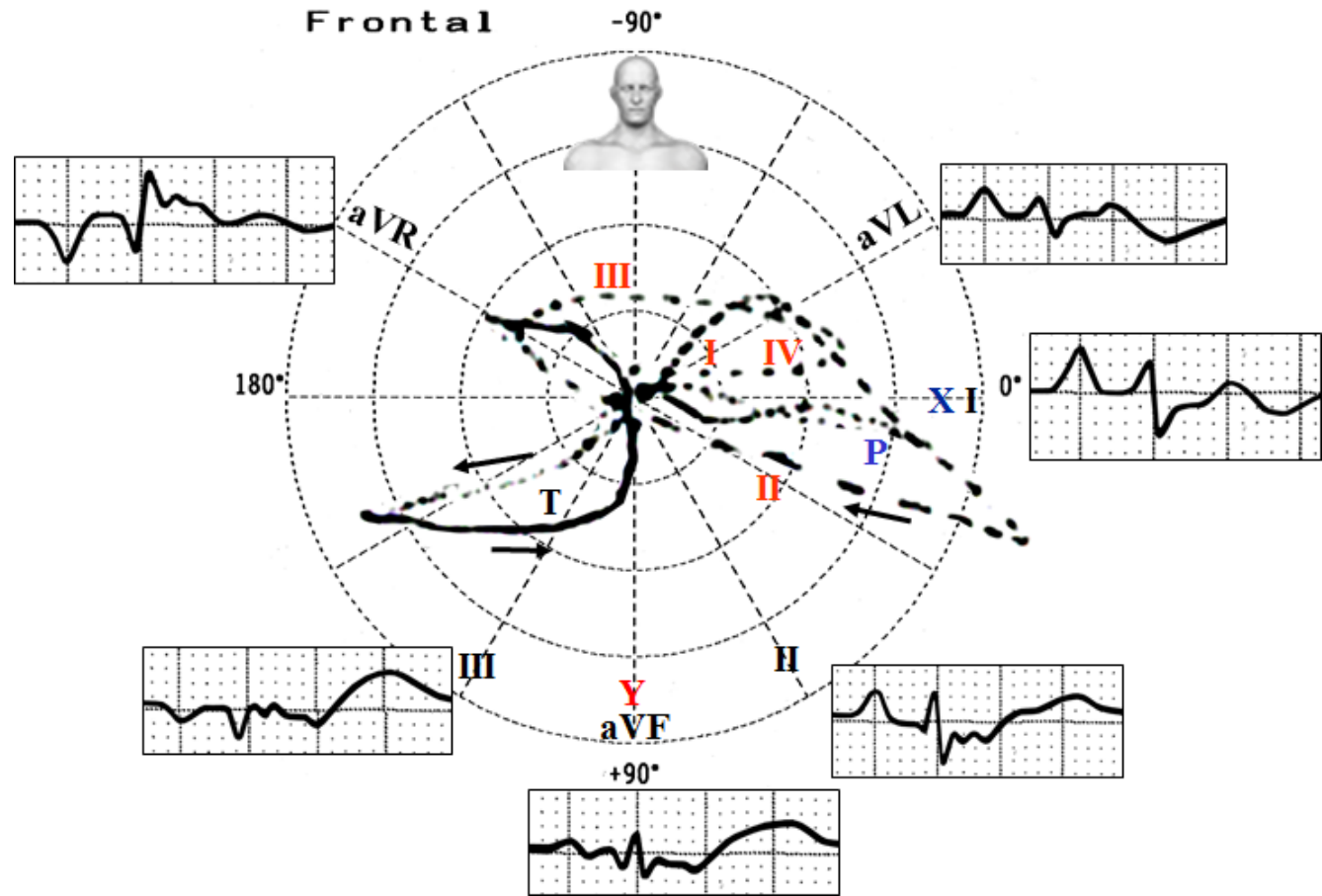
Biatrial enlargement/ Giant P loop. P axis +15°.

QRS loops:

I – Efferent limb;

II – Afferent limb;

III, IV – Late QRS forces appendix located in anterior quadrants. Clear right end conduction delay.

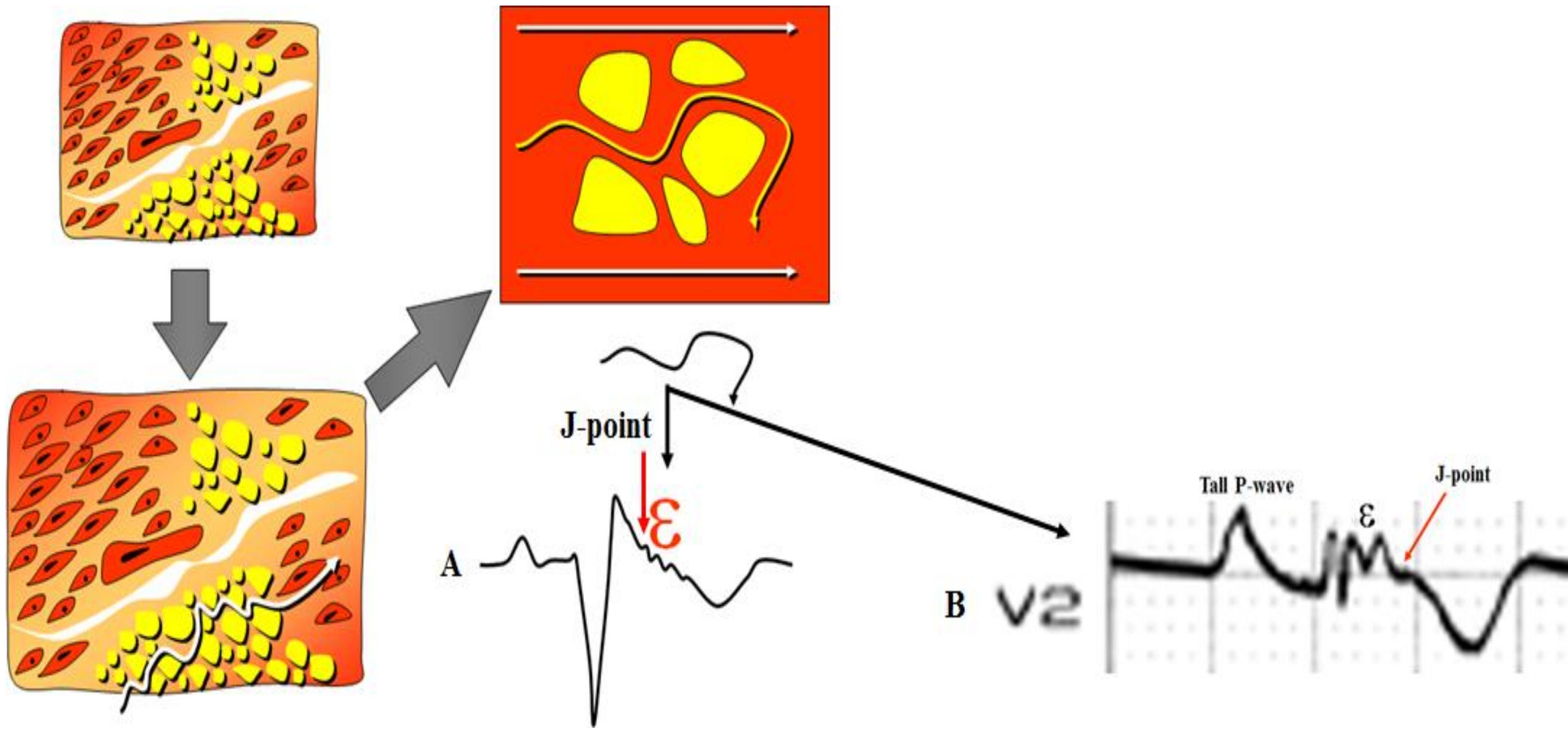


**I – Efferent limb; II – Afferent limb; III, IV – Late forces
append. Epsilon waves in inferior leads and aVR.**

B. New concept: in many cases, the definition of epsilon waves/epsilon potentials remains difficult because some authors consider that these waves may be inside of the QRS complex, manifested as QRS fragmentation or QRS notching (**Hoffmayer 2013**). In ARVC/D fragmented QRS (fQRS) has a high diagnostic value similar to epsilon potentials by a highly amplified and modified recording techniques, such as right precordial leads ECG (R-ECG) and Fontaine leads (F-ECG) (**Peters 2008**). fQRS refers to the ‘slurs or notches’ appeared on the R or S wave or if the total QRS complex had ≥ 4 spikes. fQRS can be registered as a normal variant mainly in seniors endurance athlete heart if it appeared randomly in just a few leads. fQRS presenting in multiple leads is more likely pathologic. The underlying cause is the regional delay in propagation of ventricular depolarization (**Monta 2008**).

fQRS is highly prevalent in ARVC/D patients when applied to amplified and modified ECG recording techniques, including the use of the Fontaine Leads System (**Peters 2008; Hurst 1998**). In real world practice, nevertheless, most ECGs available from ARVC/D patients and family members were obtained by using only the standard ECG recording technique. fQRS is easily recognizable from standard ECGs (S-ECG) and they are much more common in ARVC/D patient when compared with control subjects. Among them a notch before the end of R or S wave is characteristic, seen in 51% of ARVC/D vs 26% in controls. In ARVC/D, fQRS is often seen in multiple leads (**Zhang 2014**). Such changes, however, are common in control subjects as well. In the latter, the QRS complex is wider (**Dechering 2013**). fQRS complex, with various morphology, has been described as a diagnostic criterion of ARVC/D. Since fQRS is also prevalent in other types of cardiomyopathies (both ischemic and non-ischemic) (**Das 2006;2010**).

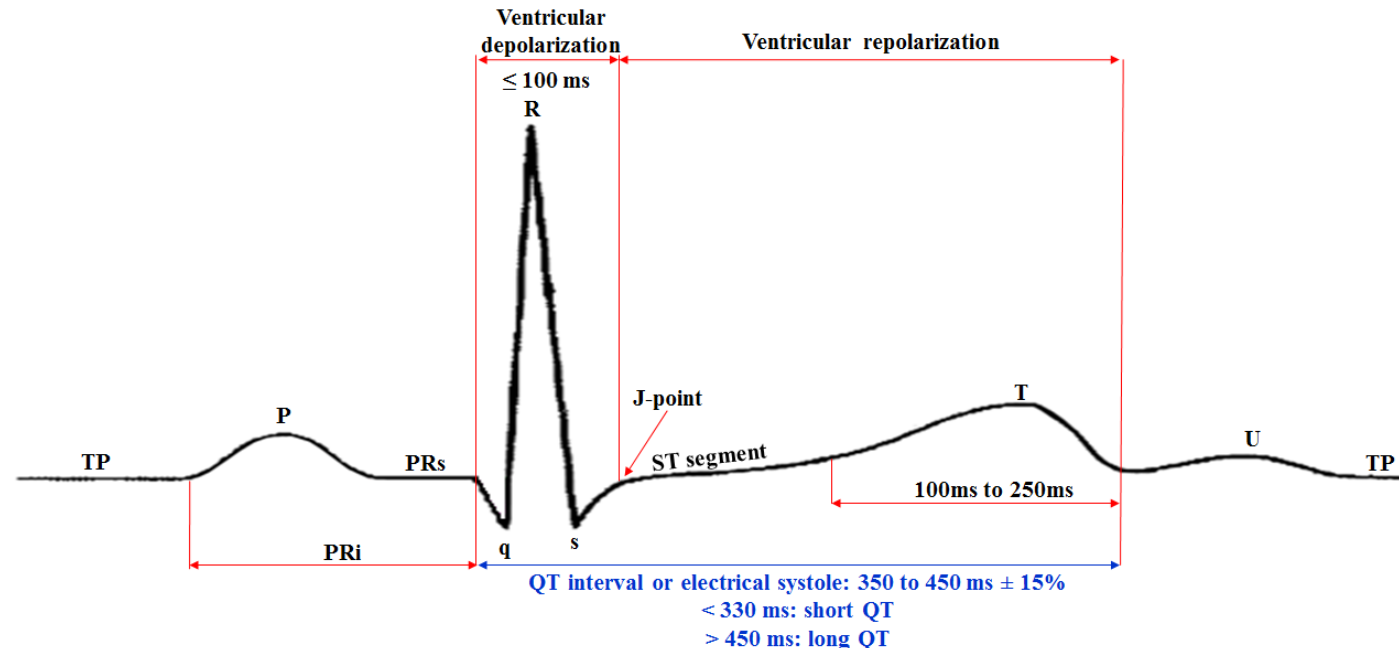
fQRS is induced by radiotherapy in patients with breast cancer (**Adar 2015**), and in normal subjects, its use in ARVC/D diagnosis is limited. The figure shows the two admitted possibilities of epsilon waves.



A. Oscillations registered after J-point at the beginning of ST segment.
B. Oscillations registered inside the QRS complex. In this case, epsilon waves are indistinguishable of fQRS.

Evidence of slow fractionated conduction is present as epsilon waves. The signal averaged ECG may show exceedingly long and low late potentials (**Marcus 2000**). Tanawuttiwat et al (**Tanawuttiwat 2016**) studied 30 ARVC/D patients underwent endo and epicardial electroanatomical activation mapping in sinus rhythm. The ECGs were classified into 5 patterns: 1. Normal QRS (11 patients); 2. Terminal activation delay (TAD) (3 patients); 3. Incomplete right bundle branch block (IRBBB) (5 patients); 4. Epsilon wave (5 patients); 5. Complete RBBB (CRBBB) (6 patients). Timing of local ventricular activation and extent of scar was then correlated with surface QRS. Earliest endocardial and epicardial RV activation occurred on the mid anteroseptal wall in all patients despite CRBB pattern on ECG. Total RV activation times increased from normal QRS to prolonged TAD, IRBBB, epsilon wave, and CRBBB, respectively (103.9 ± 5.6 , 116.3 ± 6.5 , 117.8 ± 2.7 , 146.4 ± 16.3 , and 154.3 ± 6.3 , respectively, $P < 0.05$). Total epicardial scar area (cm^2) was similar among the different ECG patterns. Median endocardial scar burden was significantly higher in patients with epsilon waves even compared with patients with CRBBB (34.3 vs. 11.3 cm^2 , $P < 0.01$). Timing of epsilon wave corresponded to activation of the subtricuspid region in all patients. Epsilon waves are often associated with severe conduction delay and extensive endocardial scarring in addition to epicardial disease. The timing of epsilon waves on surface ECG correlated with electrical activation of the sub-tricuspid region.

If we considered that epsilon waves are located after the J-point at the beginning of ST segment only, the phenomenon theoretically could not be a depolarization criterion because ST segment occurs during the repolarization. The following figure explains depolarization and repolarization intervals on ECG.



QRS complex: Set of deflections that represent ventricular depolarization.

J-point: Approximate point of convergence between the end of QRS complex and the onset of ST segment. It is considered the point at which the QRS complex finishes and the ST segment begins. The J-point is an essential landmark for measuring QRS duration and ST segment elevation and/or depression. J-point represents approximate the end of depolarization and the beginning of repolarization as determined by the surface ECG. There is an overlap of ≈ 10 ms (**Mirvis 1982**). In the classical concept, epsilon waves are located after this point. In the embracing concept, the epsilon waves could be inside the QRS complex, consequently have the same meaning as fQRS. Okano et al (**Okano 1995**) observed that there is no difference in electrophysiologic findings in patients with or without epsilon waves. Negative potentials are present on the anterior chest in ST-T isopotential, ST-T and QRST isointegral maps in all of the patients. The area of these negative potentials was closely correlated with RV dilatation and dysfunction. It is concluded that epsilon waves are not the direct counterpart of delayed potentials, but the reflection of the peripheral conduction delay, and that primary change seems to play large part of the genesis in negative T waves of ARVC/D.

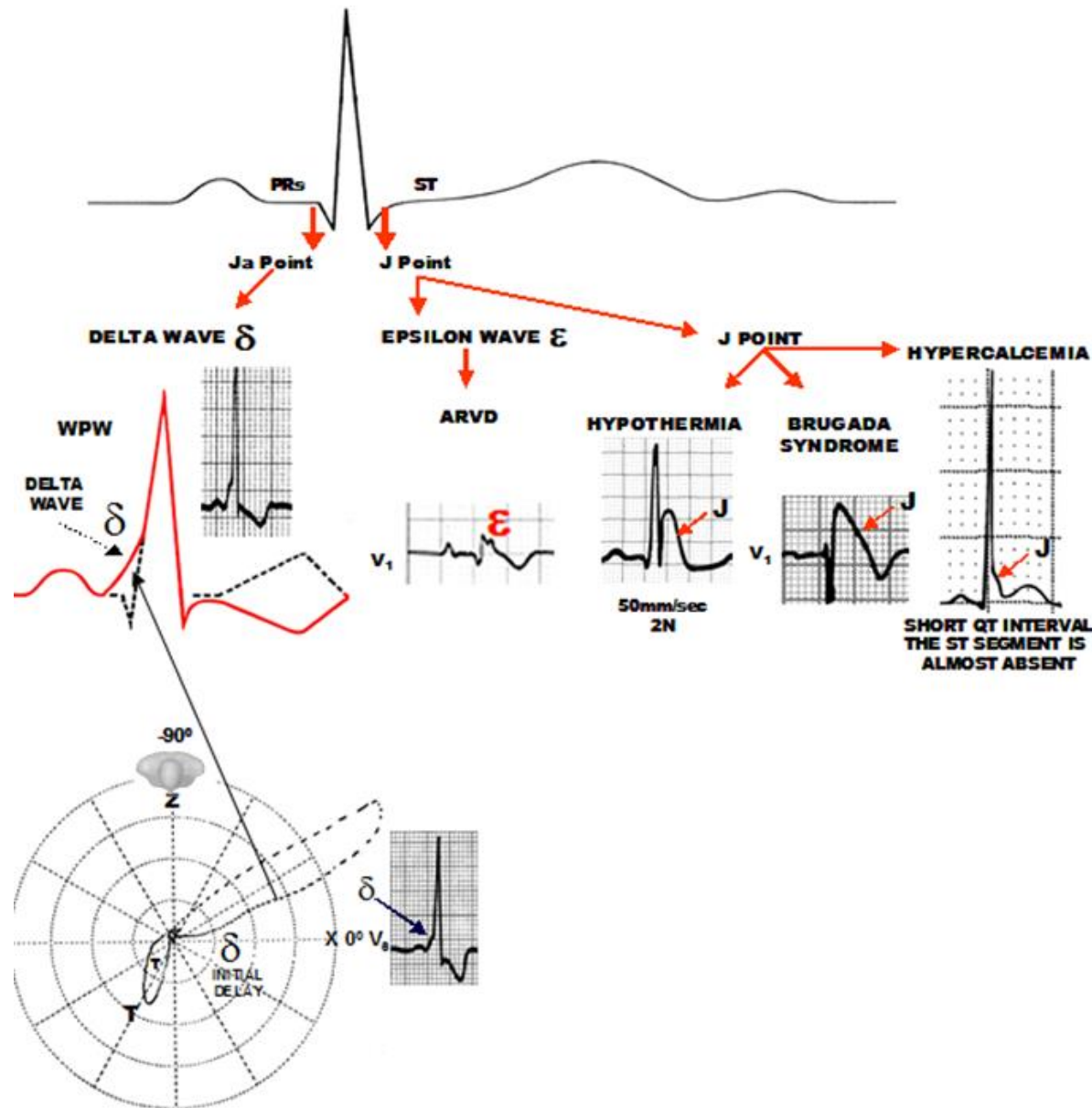
ST segment: it stretches from the J point (union of ST with the end of QRS complex) until the onset of the T wave, which is usually hard to determine. In electrocardiography, the ST segment connects the QRS complex and the T wave and has a duration of 80 to 120 ms. The ST segment corresponds to phase 2 of action potential (AP).

T wave: Normal profile of T wave with slow ascending ramp and faster descending ramp. It is coinciding with phase 3 of AP. T duration is 100 to 250 ms (up to five times more than ventricular depolarization).

QT interval or electric systole: interval between the first recognizable part of QRS up to the final recognizable area of the T wave (the latter may be hard to determine precisely). The end of T is defined as the return of the T wave to the T-P baseline.

U wave: Last, inconstant and smallest deflection of ECG that is recorded immediately after T wave and before the P of the following cycle, of equal polarity to the preceding T, i.e. positive where T also is. Voltage of U is always lower than 50% of the width of the preceding T and generally between 5 and 25% of it. Usually it does not exceed 1 mm, being in average of 0.33 mm. If it reaches 1.5 mm or more, it is considered high, however, there may be normal U waves of up to 2 mm (0.2 mV) in II and from V2 to V4.

The figure below shows a comparative location and aspect of delta (δ), epsilon (ϵ), and J waves.



Observation: In WPW type ventricular preexcitation, a wave located at the Ja point (end of PR segment and onset of QRS complex) is observed, called delta wave (δ). Following the Greek alphabet, the wave should be called Epsilon (ϵ), located near the J point (end of QRS complex and onset of ST segment).

V. Meaning of epsilon waves

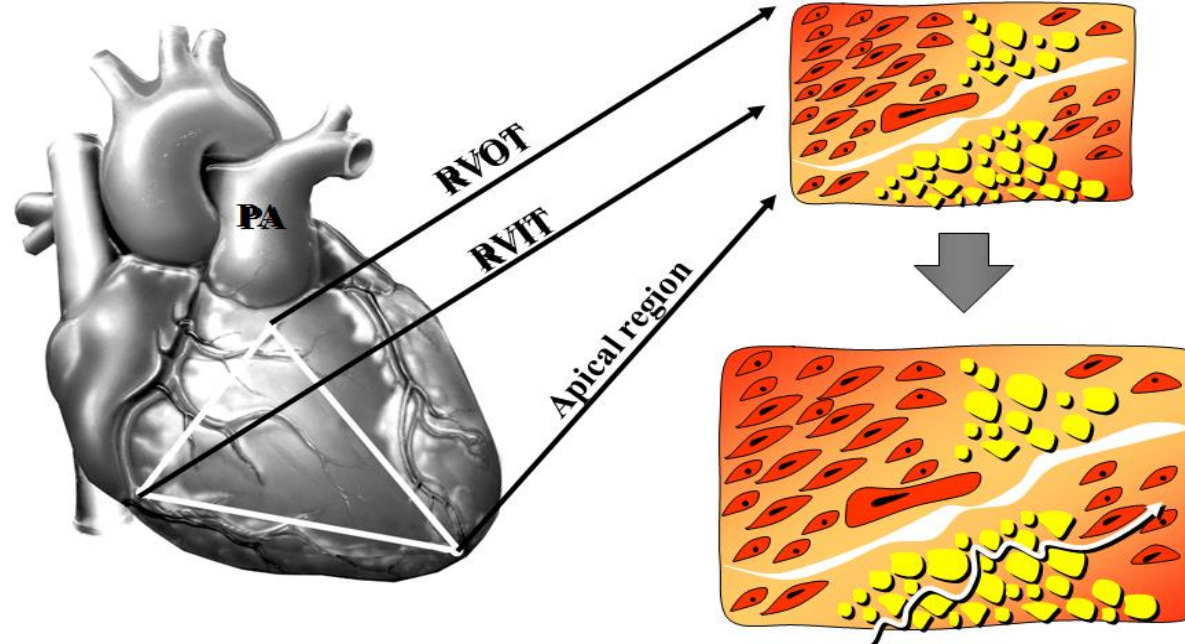
Epsilon waves and other depolarization abnormalities in the right precordial leads are thought to represent delayed activation of the right ventricular outflow tract (RVOT) in ARVC/D.

Epsilon waves are a major depolarization criterion that represent in the right precordial leads delayed activation of the RVOT in ARVC/D (**Tanawuttiwat 2016**) but they are an insensitive sign when we use S-ECG. Right precordial epsilon potentials were found in 23% in S-ECG and in 75% in highly amplified and modified recording technique (**Peters 2003**). On the other hand, these waves represent a post-excitation phenomenon: delayed activation of “islands” of viable right ventricular myocytes interspersed in myocardium that does not depolarize normally (**Hurst 1998 b**).

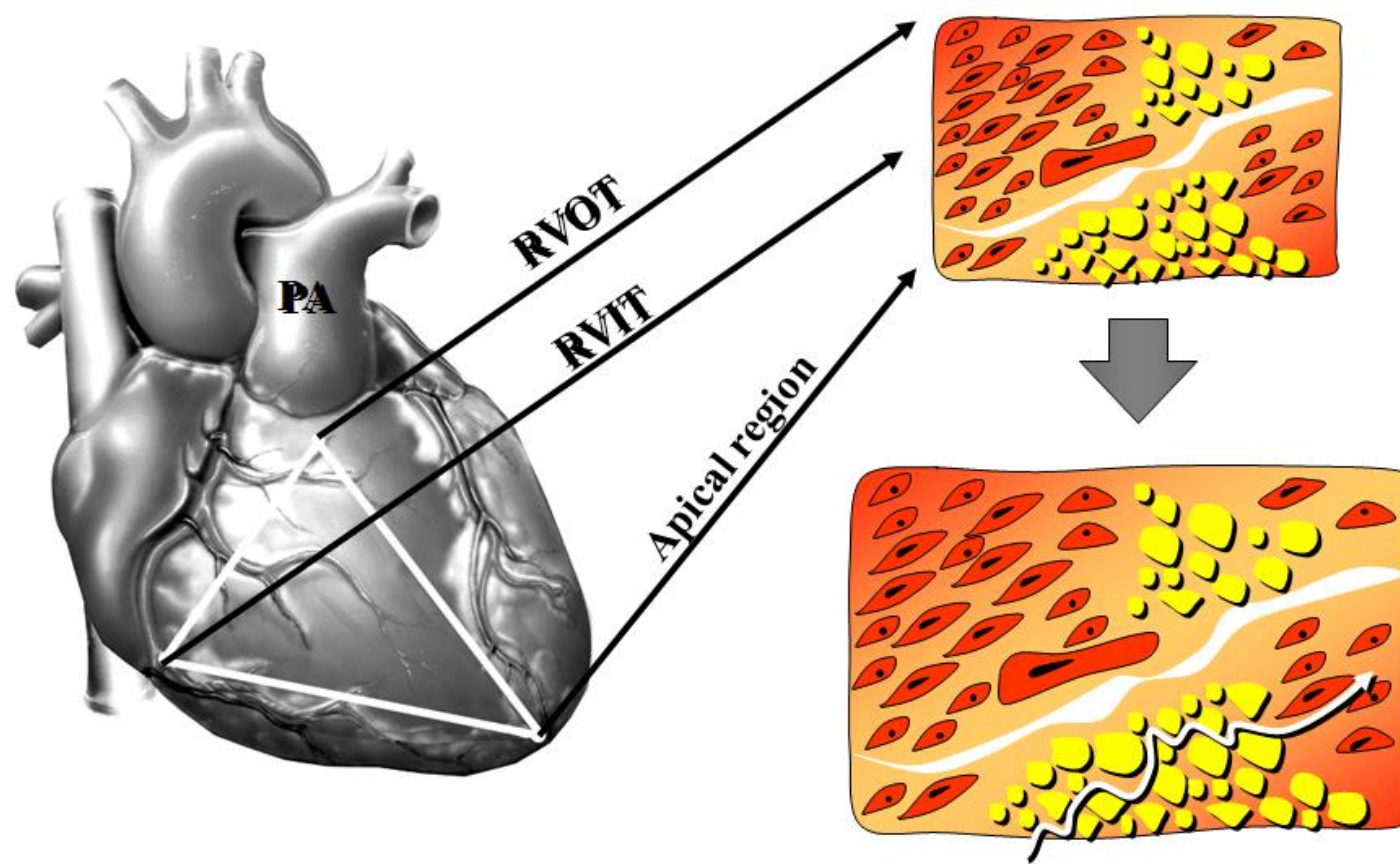
VI. Origin focus of epsilon waves

The figure below shows the focus location of the epsilon wave on right ventricular free wall in the area called triangle of dysplasia. The angles of this triangle are: the RVOT, the right ventricle inflow tract (RVIT) and the apex of the right ventricle.

The so-called "triangle of dysplasia" : its angles are right ventricular outflow tract(RVOT), right ventricular inflow tract RVIT and apex of RV



Ventricular aneurysms and fibrofatty infiltration(yellow) at the right ventricular free wall is considered pathognomonic hallmark of ARVC/D.



Triangle of dysplasia: its angles are RVOT, RVIT and apex of RV.

VII. Possible leads where epsilon waves can be observed

Leads: epsilon waves are observed mainly in right precordial leads from V_1 to V_3 however are also found the frontal plane, especially in inferior leads. The duration of the QRS complex may be a bit longer in leads V_1 and V_2 than in leads V_5 and V_6 .

VIII. Sensitivity ECG for detection of epsilon waves Frequency in ARVC/D with S-ECG, with F-ECG and with R-ECG

Epsilon waves are observed in approximately 15-30% of the most severe cases of ARVC/D when is used the S-ECG. This percentage increases if we use the ECG with the modified protocol such as F-ECG (**Peters 2014**) and R-ECG. Although the small wiggles may be seen in the routine ECG, they may be seen more readily in F-ECG (**Gottschalk 2014**). The presence of epsilon waves by the Fontaine lead system F-ECG() provide a high degree of suspicion for the disease (**Chiladakis 2010**). However, epsilon wave is more commonly seen on SAECG.

IX. Prognosis significance in ARVC/D

Epsilon waves aid in the prognosis and risk stratification of patients with ARVC/D (**Marcus 2015**). Detection of epsilon waves on 12-lead ECG reflects significant RVOT involvement, which was associated with episodes of sustained ventricular tachycardia (SVT) but not sudden cardiac death (SCD) or heart failure (**Protonotarios 2015**). The fQRS complex on standard ECG (S-ECG) predicts fatal and nonfatal arrhythmic events in patients with ARVC/D (**Peters 2012 a;b**). Therefore, large scale and prospective studies are needed to confirm these findings (**Canpolat 2013**). fQRS is a valuable factor to predict total mortality and major adverse cardiac events (MACE) in patients with: 1) coronary artery disease (CAD) (**Gong 2015**); 2) sarcoidosis: multivariate analyses revealed that fQRS complexes are associated with risk of developing cardiac events cardiac events in extracardiac sarcoidosis (**Nagao 2015**); 3) Brugada syndrome (**Morita 2008**). In this entity, the presence of fQRS and early repolarization correlates with increased risk in several studies (**Adler 2015**). On multivariable analysis, a history of VF and syncope episodes, inferolateral ER pattern, and f-QRS were independent predictors of documented ventricular fibrillation (VF) and SCD (**Tokioka 2014**). In a large multicenter, observational, long-term study, the ECG findings that were useful to predict adverse outcome in patients with ARVC/D were: inferior leads T-wave inversion, a precordial QRS amplitude ratio of ≤ 0.48 , and fQRS (correspondent to termed "pre-, top-, and postsilons") (**Saguner 2014**).

X. Pathognomonic character of epsilon waves

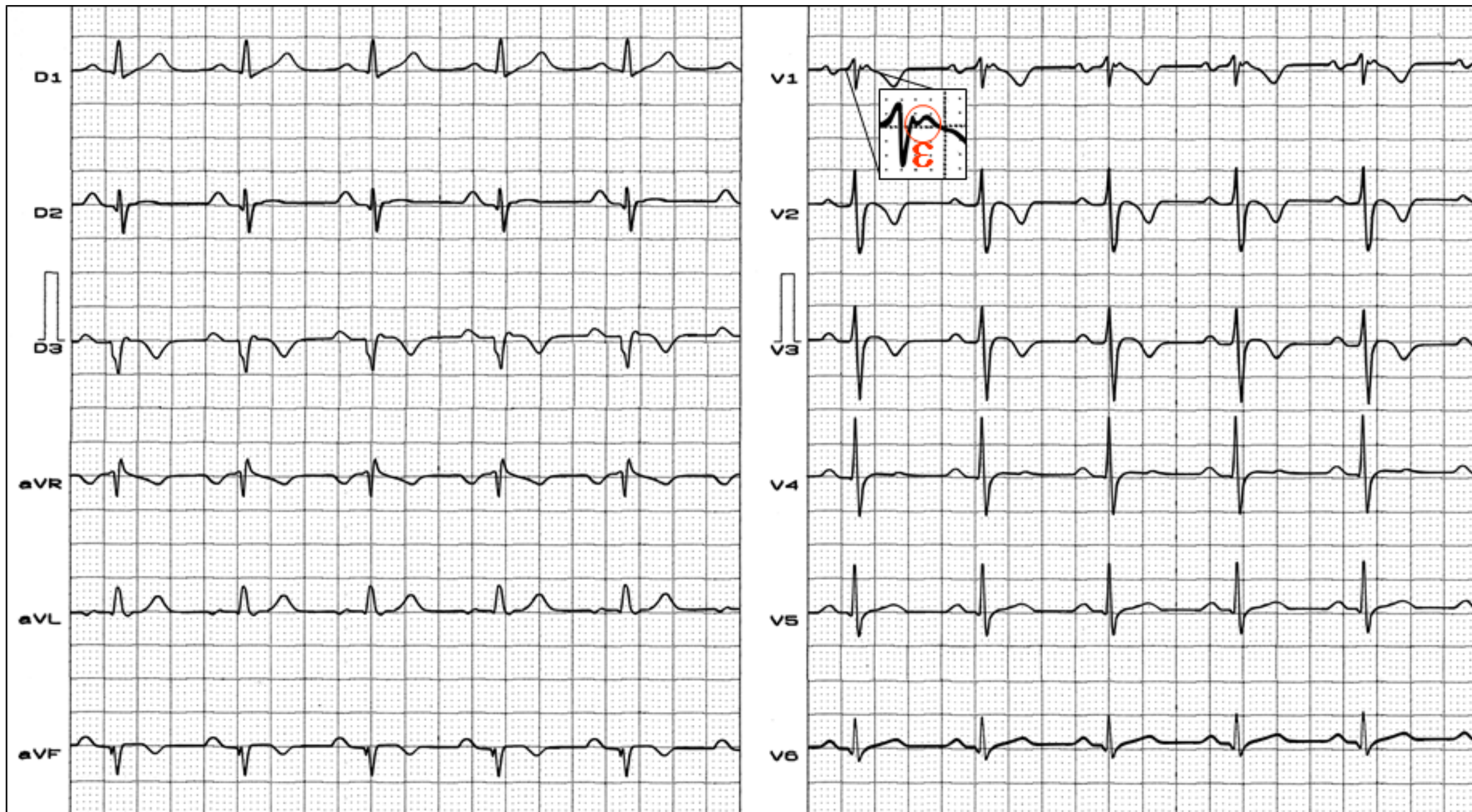
Pathognomonic character: in spite of the characteristics in ARVC/D, they are not pathognomonic, since they have been described in other physiological and pathological scenarios associated with myocardial damage:

1. Physiological epsilon waves

Ventricular hypertrophy in senior elite endurance athletes: Epsilon wave was found in 3 senior athletes (1.57%) from 347 elite endurance athletes (seniors–190, juniors–157), mean age of 20; 200 subjects mean age of 21, belonging to the control group of 505 normal sedentary population (**Macarie 2009**). Bizarre QRS, ST-T patterns suggestive of abnormal impulse conduction in the right ventricle, including the right outflow tract, associated with prolonged QTc interval in some cases were observed in highly trained endurance athletes. The genetic analyses, negative in most athletes, identified surprising mutations in SCN5A and KCN genes in some cases (**Macarie 2009**).

2. Pathological epsilon waves

- **Giant-cell myocarditis:** Epsilon waves are a major diagnostic criterion for ARVC/D, but also other cardiac pathologies such as giant-cell myocarditis can cause severe RV conduction disturbances manifesting with epsilon waves and VT on surface ECG (**Vollmann 2014**).
- **Sickle cell anemia** (**Hurst 1998**).
- **Brugada syndrome:** it is believed that Brugada syndrome and ARVC/D are different clinical entities regarding the clinical presentation and the genetic predisposition. The coexistence of these two relatively rare clinical entities was also reported (**Hoogendijk 2012**). In clinic practice, there may be cases where the dividing line is not so clear (**An 2008; Ozeke 2009**). Epsilon waves appear to be rare in Brugada syndrome patients and were found in 2 of 47 patients by Letsas et al (**Letsas 2011**), and in 1 patient from a total of 12 unrelated index Brugada syndrome patients were included in the study by Yu et al (**Yu 2014**).
- **Idiopathic ventricular fibrillation in the absence of Brugada syndrome phenotype** with loss-of-function mutation of the SCN3B-encoded sodium channel β_3 subunit (**Valdivia 2010**).
- **During exercise stress testing or treadmill stress testing in asymptomatic gene carriers:** Depolarization abnormalities during exercise testing in asymptomatic gene carriers were found to develop more frequently compared with healthy controls: epsilon waves appeared in 4 of 28 (14%) (**Perrin 2013**). Recently, Adler et al showed to uncover epsilon waves in asymptomatic patients carrying mutations in the PKP2 gene. This finding suggests that exercise testing may be valuable for the diagnosis of ARVC/D and that exercise-induced epsilon waves may be found in various genetic subtypes of this disease (**Adler 2015**).
- **After repair Fallot tetralogy** (**George 2011**).
- **Right ventricular myocardial infarction** (**Zorio 2010; Andreou 2012**).
- **Inferior or lateral MI (old dorsal)** (**Zorio 2005**).
- **Infiltrative diseases, such as cardiac sarcoidosis** (**Santuchi 2004**), increasing evidence suggests that cardiac sarcoidosis might produce the pathological substrate required for production of epsilon waves. Therefore, differentiating these two entities is of paramount clinical importance (**Khaji 2013**). The ECG below shows a single epsilon wave in a patient with sarcoidosis.



Clinical diagnosis: cardiac sarcoidosis.

ECG diagnosis: SAQRS -60° , negative T wave from V1 to V3, Epsilon wave (ε) in V1.

High-resolution ECG (SAECG) or signal-averaged electrocardiogram (SAECG): epsilon waves are observed more frequently with this method.

- In ARVC/D, SAECG frequently is associated to LPs.
- The ϵ wave may be observed in surface ECG; however, it is seen much more frequently in SAECG (**Gregor 2003**).
- SAECG is used to detect LPs and ϵ waves in ARVD carriers.
- Patients with positive SAECG (presence of LP) have statistically significant increase of SVT and/or SCD in comparison to those with normal SAECG or branch block.
- SAECG with LP constitutes a marker of arrhythmic events in patients with non-ischemic dilated cardiomyopathies. On the contrary, patients with dilated cardiomyopathies with normal SAECG, display worsening only if they develop progressive cardiac heart failure (CHF) (**Mancini 1993**).
- Fibro-fatty substitution of the myocardium is the substrate of slow and fragmented activation, responsible for the presence of LP.
- Abnormal SAECG seems to correlate with the severity of the disease.
- SAECG does not seem a sensitive resource in the minor or concealed forms of the disease, since in these patients there is no proper information with this method (**Oselladore 1995**).
- The combination of the analysis of time domain and frequency domain of SAECG may be useful for screening patients carriers of ARVC/D. This combination of both domains increases sensitivity without reducing specificity.
- Use of filters with a range between 20 and 250 Hz (substituting the classical ranges between 40 and 250 Hz) (**Kinoshita 1995**).
- The presence of LP in ARVD is found in 70 to 80% of cases. These LPs may identify patients with a tendency to develop VT runs in little apparent or restricted forms, and it serves to differentiate them from benign RVOT idiopathic VT, with no underlying structural disease. In these cases, SAECG has LP in 0 to 5% of the cases as in normal patients.
- When there is structural heart disease, LPs are found in 20 to 40% of cases. In doubtful cases, invasive studies are necessary to rule out a limited form of cardiomyopathy (**Fauchier 1996**).
- In absence of branch block, the presence of LP in SAECG is proportional to the size of the RV cavity, and thus is parallel to RV dysfunction (**Mehta 1996**).
- In order to study the differences between benign repetitive monomorphic VT (MVT) that originate in the RV and the VT from ARVC/D, ECG during the event and SAECG may be helpful.

- ECG during VT and SAEKG may be useful to differentiate both entities. In the case of ARVC/D, VT presents QS in V1 and QRSD related to the amount of fibrous tissue existing in the RV (**Kazmierczak 1998**) There are significant differences for filtered and non-filtered QRS, low duration sign and square root. In absence of CLBBB, these differences become non-significant for filtered or non-filtered QRS (**Kazmierczak 1998**).
- There is a narrow correlation between the result from SAEKG and the extension of the disease, with the presence of VT.
- SAEKG is not a valuable resource in minor forms of the disease, but as this is a noninvasive method, it may be useful to assess the progression of the disease (**Nava 2000**).
- In comparison to S-ECG, SAEKG detects abnormalities at higher rates in patients carriers of ARVC/D (57% vs. 86%). SAEKG is more sensitive as screening test than 12-lead S- ECG to detect patients carriers of ARVC/D (**Sekiguchi 2001**).
- The anatomopathological process of ARVD also considers late ventricular potentials, which when they are registered as LP in SAEKG, indicate electrical stability worsening associated to rapid progression of SAEKG, while clinical parameters remain unchanged. This fact suggests that progression parameters in SAEKG are markers of electrical instability increase (**Bauce 2002**).
- Sensitivity, specificity, predictive value and accuracy of the different criteria of SAEKG were estimated in comparison to sustained monomorphic VT (SMVT) inducibility. Filtered QRS duration in SAEKG is considered as predictive for the result of the electrophysiological study and ARVC/D evolution (**Nasir 2003 a;b**).
- The average of presence of LPs in ARVD is between 70-80%, with extreme values of 47-100%. The latter percentage is observed in severe forms and with documented spontaneous VT.
- SAEKG is a very useful resource to follow the evolution of the disease;
- In relatives of the patients, SAEKG presents a positivity of LP between 4-16%;
- Detecting posterior potentials improves by using 25 Hz filters and specificity is better observed in the orthogonal lead Z;
- SAEKG should be considered a standard test in the study of patients with suspicion or carriers of ARVC/D;
- Future research is necessary to confirm the value of SAEKG as predictor of arrhythmic risk and determining factor of progression of the disease, as well as to study the prevalence of SAEKG in relatives of the patients, thus allowing early detection;
- The majority of elite and amateur athletes participating in high dynamic and high static sports, reveal a prolongation of the filtered QRS duration on the SAEKG, and according to the 2010 Task Force criteria for the diagnosis of ARVC/D, these athletes therefore demonstrate LPs. The extent of filtered QRS duration prolongation is positively correlated with RV dimensions. Therefore SAEKG findings should be interpreted with caution in endurance athletes. (**Jongman 2015**). Multidisciplinary continuing studies on ARV/CD will help to answer some of these questions (**Nasir 2003**).

- SAECG fulfilling all 3 Task Force criteria. The method is an independent risk predictor of malignant events in ARVC/D patients. SAECG may play a valuable role in ARVC/D risk stratification(**Liao 2014**).
- Interobserver variability in the assessment of epsilon waves is high; however, the impact of epsilon waves on ARVC/D diagnosis is negligibly low. The results urge to exercise caution in the assessment of epsilon waves, especially in patients who would not otherwise meet diagnostic criteria (**Platonov 2016**).

Progressive character of epsilon waves

ECG changes during long-term follow-up, in a large cohort of patients (111 patients from three tertiary care centers in Switzerland) with ARVC/D showed that ECG progression is significant for epsilon waves (baseline 14% vs. follow-up 31%, $p = 0.01$) (**Saguner 2015**).

Value of ECG in ARVC/D

Epsilon wave is considered to be a major depolarization criterion for diagnosis by the Task Force for ARVC/D diagnosis (**McKenna 1994; Fontaine 1999; Marcus 2010**).

ECG diagnosis of ARVC/D may be difficult in the initial stage of the disease, since a normal ECG is found in up to 40% of patients during the first year of follow-up. Jaoude et al (**Jaoude 1996**) found a strong correlation between QRS or T wave changes and the length of follow-up after the first symptom; mean time interval between first VT and ECG recording is significantly longer in patients with negative T waves in the right precordial leads, wide QRS, or left axis deviation, than in patients without such abnormalities. A normal ECG is found in 40% of patients during the first year of follow-up, 8% at 5 years, and never later than the 6th year. ARVC/D can be excluded if the ECG is found to be normal 6 years or later after a first VT event.

ECG association: Inversion of T wave in leads V1-V3 and/or ϵ wave found in 70% of patients with ARVC/D. Epicardic electrophysiological studies in dysplastic areas reveal the LP that occur at the end of the QRS complex, in the J point, and at the onset of the ST segment, explained by fibro-fatty substitution of myocardial tissue (**Fontaine 1984**).

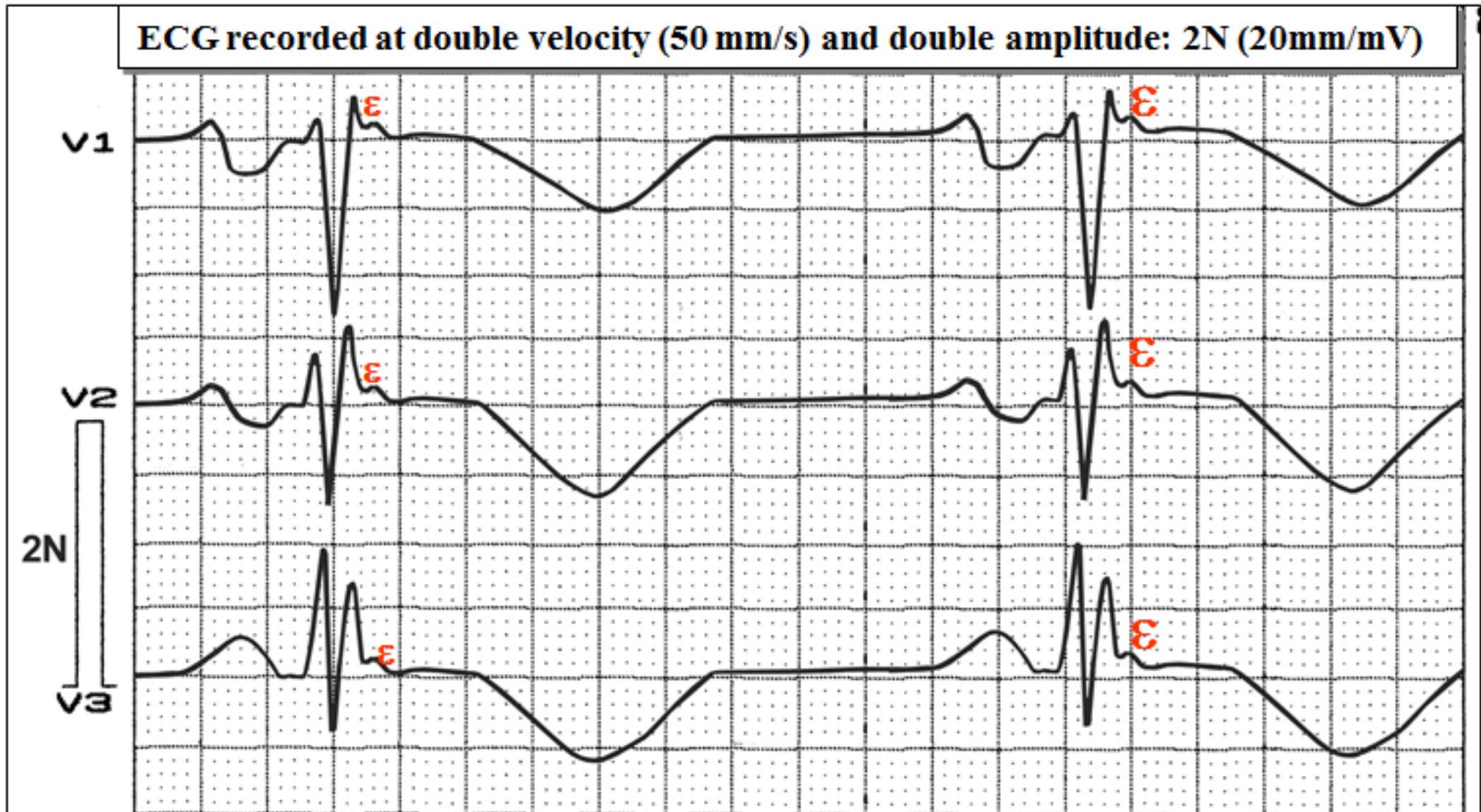
Epsilon wave and relationship to VT: the simple presence of these waves indicate slow and fragmented conduction, which favors reentry circuits, which in turn result in M-VT runs with CLBBB morphology by originating in the RV (**Hurst 1998; McKenna 1994**).

The tracing should run at a double velocity (50 mm/s) and double voltage (20 mm/s) to compare the duration of QRS complexes (QRSd) in different leads, as well as to try to record epsilon waves.

The ECG below shows more clearly the epsilon wave with double velocity and double voltage.

ECG recorded at double velocity (50 mm/s) and double amplitude: 2N (20mm/mV)

**Double
amplitude
(20 mm/mV)**



The rate of widespread T-wave inversion (exceeding V_3) was significantly higher in patients with epsilon waves than in those without.

Comparative sensitivity of

- Standard 12-lead electrocardiography (S-ECG)
- Right-sided precordial lead electrocardiography (R-ECG) R-ECG (V_3R , V_4R , V_5R),
- Fontaine bipolar precordial lead electrocardiography (F-ECG). The Fontaine bipolar precordial leads placed at the manubrium of sternum, xiphoid, and V_4 positions using the right arm connection, left arm connection, and left foot connection, respectively
- Detection by these 3 methods
- Signal-averaged ECG

Because these waves are of relatively low voltage and may go undetected by standard electrocardiography (S-ECG) or unnoticed by the interpreter (**Zorio 2005**).

Value of the Fontaine bipolar precordial leads (**Gottschalk 2014**)

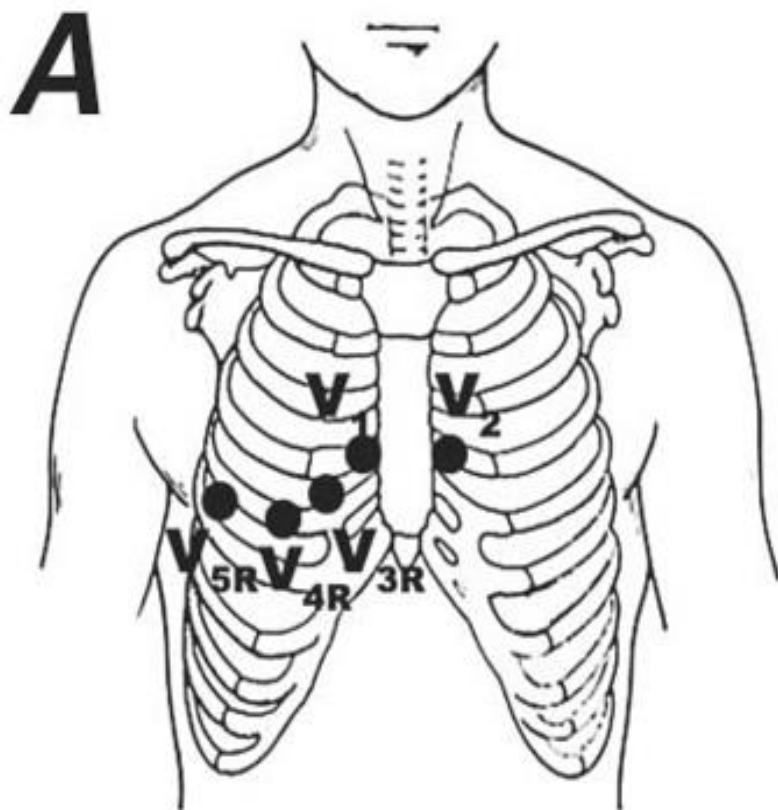
The tracing should be obtained from I and aVF at double velocity and amplitude, placing the electrode of the left arm on the xiphoid appendix, the one from the right arm on the manubrium sternum, and the one from the left leg on the rib at the fourth or fifth space with the aim of improving the ability to detect epsilon waves.

The Fontaine bipolar precordial leads are placed at the manubrium of sternum, xiphoid, and V_4 position using the right arm connection, left arm connection, and left foot connection, respectively.

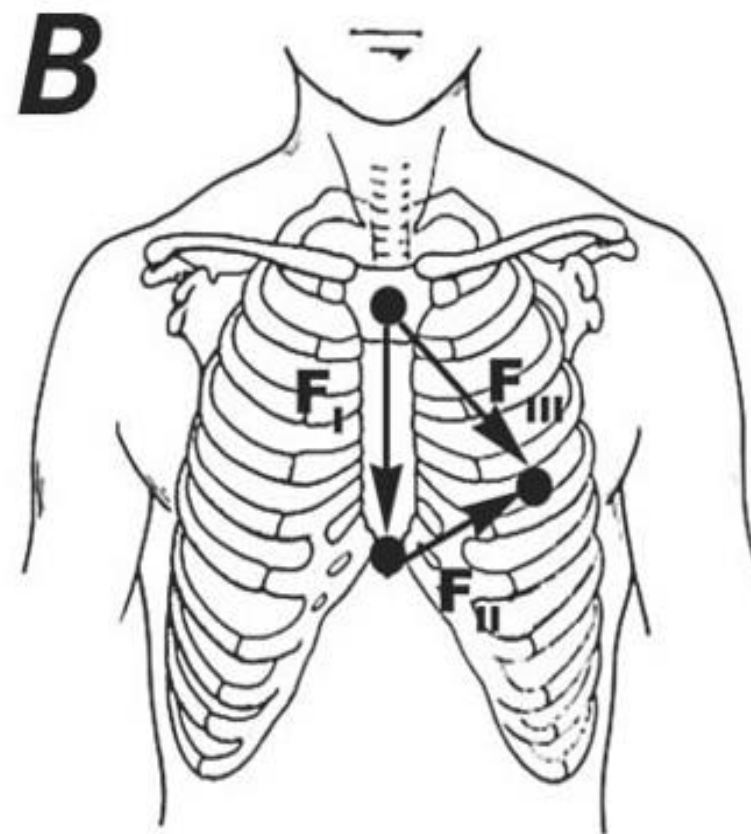
Epsilon waves are detected by:

- Standard ECG (S-ECG)
- Right ECG (R-ECG)
- Fontaine bipolar precordial leads (F-ECG)

The figure below shows electrodes location in R-ECG and F-ECG



Right precordial leads



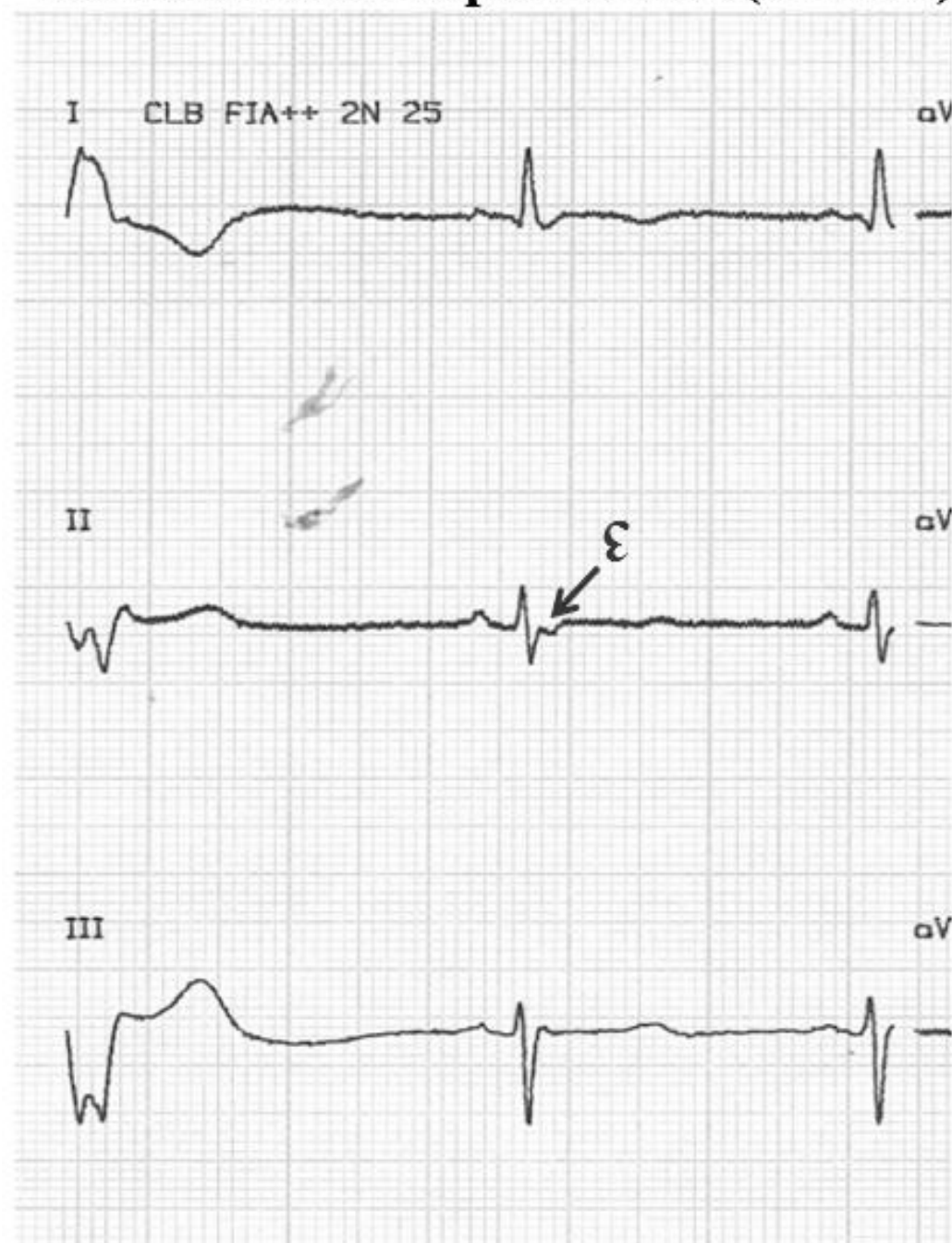
The Fontaine bipolar precordial leads

The detection rate using combined methods is significantly higher than that by S-ECG alone.

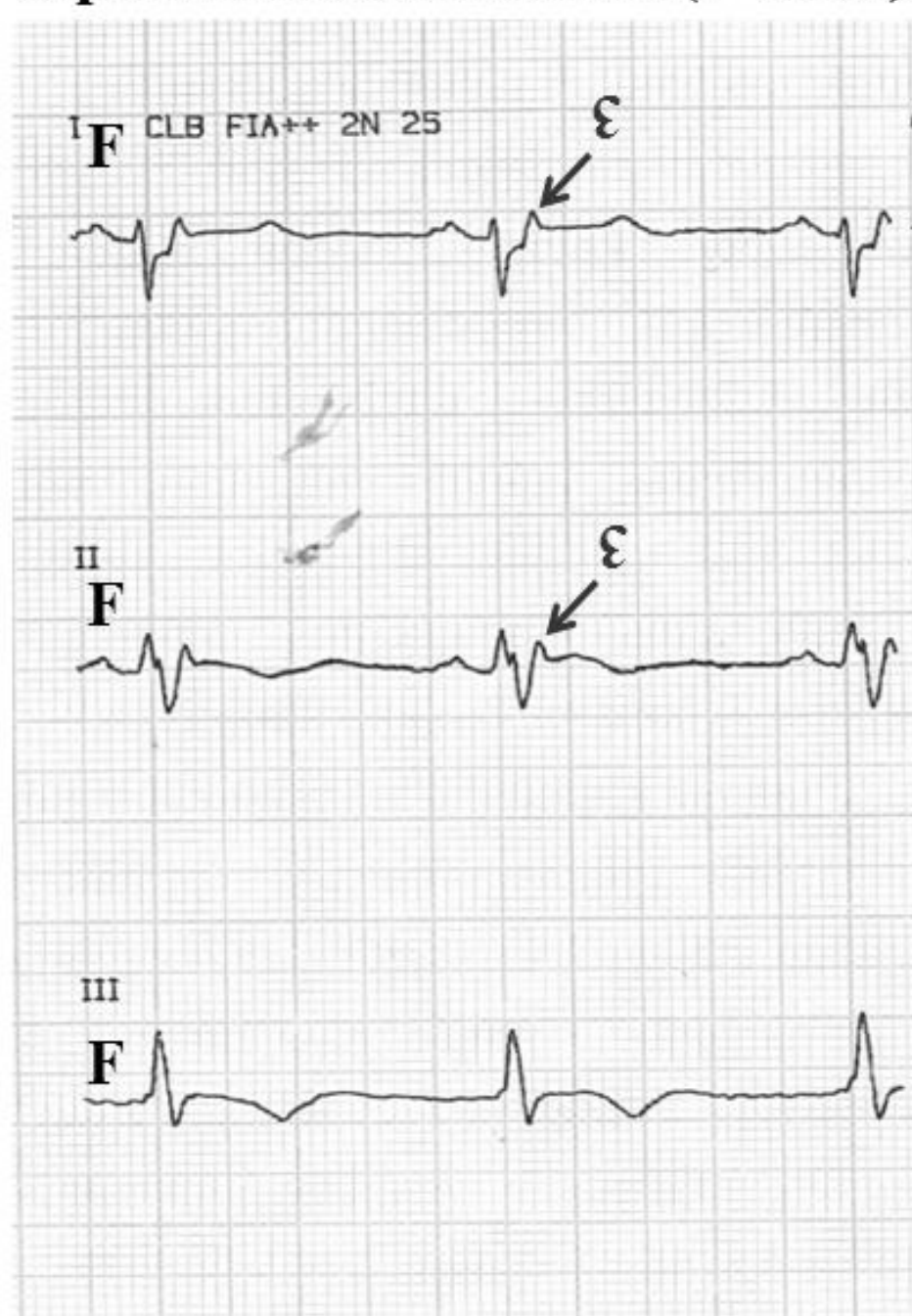
Fontaine bipolar precordial lead have the best sensitivity among the three options. The placement of the foot lead (positive) in position V4 provides, instead of regular leads I, II, and III, three bipolar chest leads that can be called FI, FII, and FIII. Tracings are then produced by setting the machine on regular leads I, II, and III. This arrangement is used to record specifically the potentials developed in the RV, from the RVOT to the diaphragmatic area. The vertical bipolar lead FI (similar to aVF lead) seems to be the most appropriate to record epsilon waves; it also magnifies the atrial potentials. As LPs were supposed to be the result of late activation of a limited group of fibers, the term "post-excitation" looked logical, since it was observed after the main excitation of the ventricle, leading to the QRS complex. The term "epsilon" was appropriate, because it occurs in the Greek alphabet after delta; thus, delta represents the pre-excitation and epsilon the post-excitation phenomenon (**Fontaine 1999**).

The bipolar precordial Fontain leads of the next figure (S-ECG x F-ECG) show major sensibility of F-ECG related S-ECG leads.

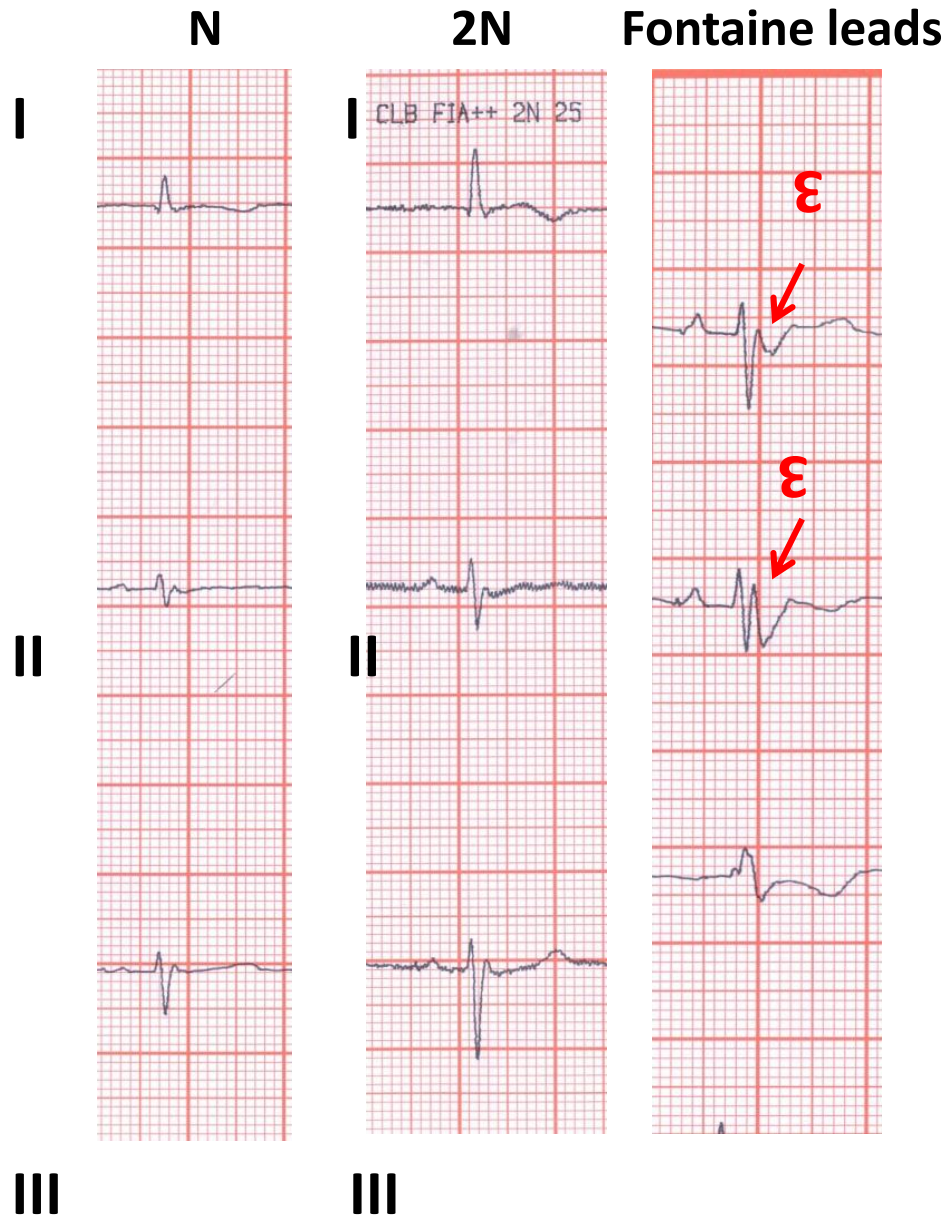
Standard ECG bipolar leads (S-ECG)



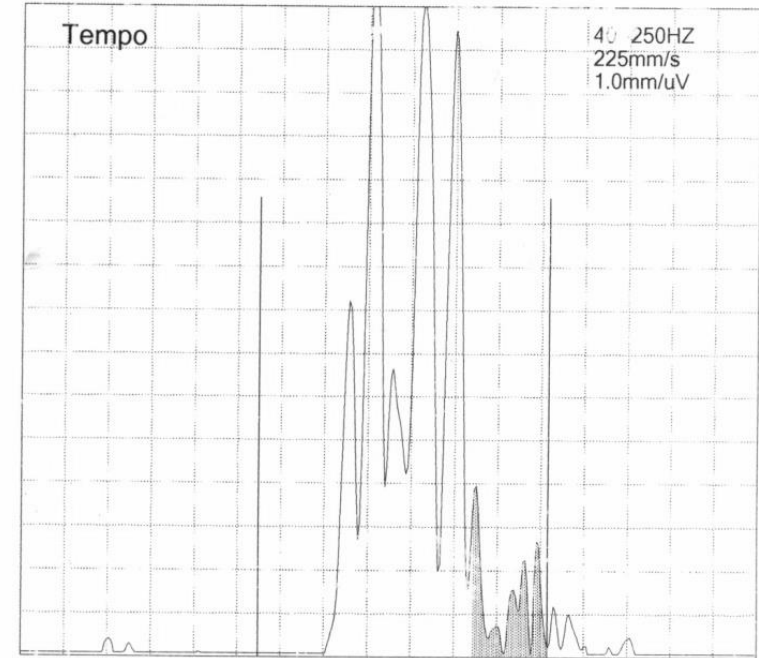
Bipolar leads of Fontaine (F-ECG)



2014



ECGAR



COMMON		Duration(ms)		RMS Voltages (uV)	
Filter :	40-250Hz	Std QRS	158	Last 40ms	10
Cycle :	199	Total QRS	152	SD of Noise	0.00 uV
		LAS<40 uV	46		

Others ECG features in ARVC/D

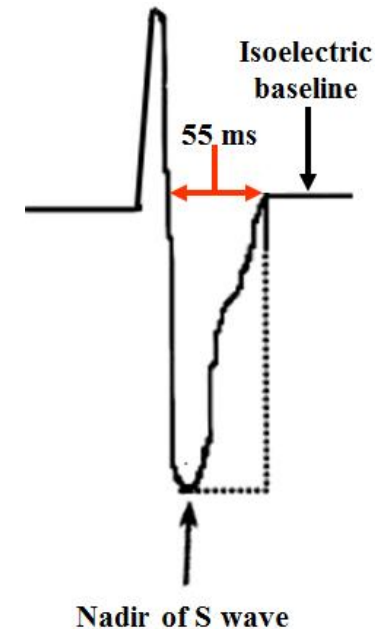
Approximately 90% of patients carriers of ARVC/D present ECG anomalies. ECG abnormalities were more frequent at 10-year and 5-year follow-up than on initial tracings. A normal ECG was found in 40% of patients during the first year of follow-up, 8% at 5 years, and never later than the 6th year. Consequently, ARVC/D diagnosis may be excluded if ECG is normal 6 years of follow-up (**Jaoude 1996**). In ARVC/D, a normal ECG is considered reassuring. However, some patients with ARVC/D experiencing ventricular arrhythmias have a normal ECG. Interpretation of ECG in young and older athletes requires in-depth knowledge in cardiology and sports medicine. The interpretation can only be carried out by considering medical history, clinical examination and ethnicity. Profound and long-term experience of athlete's ECG interpretation is required to protect athletes and to prevent cardiac emergencies (**Löllgen 2015**).

Main ECG features in ARVC/D classification:

- I. Depolarization criteria
 - Right ventricular parietal block: A prolonged S-wave upstroke in V1 through V3 ($\geq 55\text{ms}$)
- II. Repolarization criteria
 - Inverted T-wave in the right precordial leads V1-3 or anterior T wave inversion (TWI) above 12 years with no RBB (repolarization criteria):

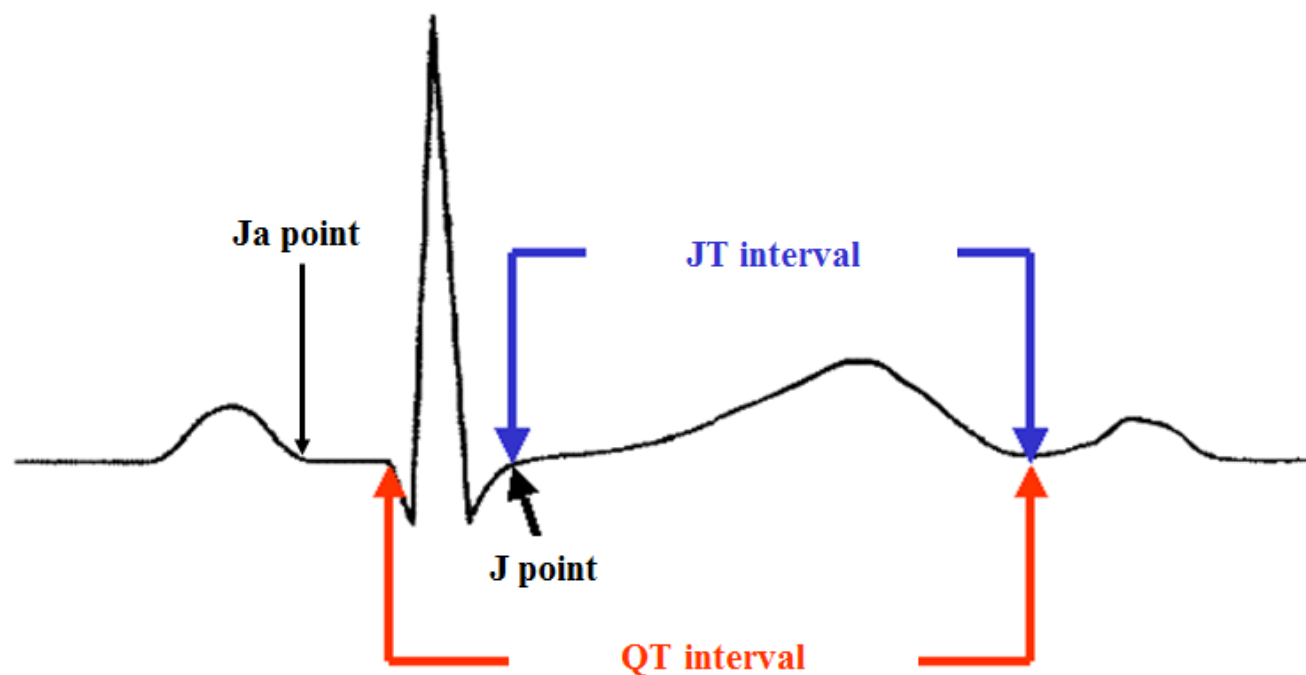
Depolarization criteria

- 1) **Right ventricular parietal block** (**Fontaine 1984**): Prolonged S-wave duration due to slow depolarization of the terminal part of the QRS because the RV is the last part of the heart to undergo depolarization. A prolonged S-wave upstroke in V1 through V3 ($\geq 55\text{ms}$) is the most frequent ECG finding in ARVC/D and should be considered as a diagnostic ECG marker. Among those without RBBB, a prolonged S-wave upstroke in V1 through V3 $\geq 55\text{ ms}$ was the most prevalent ECG feature (95%) and correlated with disease severity and induction of VT on EPS (Figure at side).



This feature also best distinguished ARVCD (diffuse and localized) from RVOT. The sensitivity of this criterion is not known in other entities and it speaks in favor of slow RV conduction. A study shows that the sign is not specific, since it is found in Brugada syndrome (**Pitzalis 2003**) with QT interval prolongation only from V1 to V3. If QT interval prolongation occurs only from V1 to V3, it is clear that this is due to depolarization time prolongation. If we admit that in Brugada syndrome there is some degree of RBBB, this QT interval prolongation may be partially due to this fact. QT interval constitutes a classical measurement for ventricular repolarization; however, it includes depolarization (QRS), which represents the so-called “electrical systole”, which includes ventricular depolarization and repolarization. In these cases of branch block and WPW, it is better to measure the JT interval and not QT (Figure below).

The JT interval value and its limits



QT interval is used to measure ventricular repolarization; nevertheless, this parameter includes ventricular depolarization (QRS) and represents the so-called electrical systole, which is the addition of ventricular depolarization (QRS) and repolarization ($ST/T = JT$ interval).

If bundle branch block or WPW type ventricular pre-excitation occurs, the QTc interval does not express ventricular repolarization correctly. In these cases, JT interval measurement is more reliable ($JT = QT - QRSd$) than QT interval, because the parameter excludes depolarization that is prolonged, as a consequence of sequential activation of biventricular chamber (normally this activation is simultaneous).

- 2) Localized QRSD prolongation on right precordial leads $> 110\text{ms}$ (depolarization/conduction abnormality).
- 3) $\text{QRSd}_{V1+V2+V3} / \text{QRSd}_{V4+V5+V6} > 1.2$ in approximately 65% of cases. QRS prolongation located in right precordial leads has 91% sensitivity, 90% specificity that predicts VT in patients carriers of ARVC/D (**Nasir 2003; 2004**).
- 4) The terminal S wave length and area in the right precordial leads are diagnostically useful and suitable for automatic analysis in ARVC/D. The bipolar chest leads (CF leads) are diagnostically superior to the unipolar precordial leads. Among members of ARVC families, those with mutations had shorter QRS length in V2 and V3 and smaller QRS area in lead V2 compared with those without mutations. In ARVC patients, the CF leads were diagnostically superior to the standard unipolar precordial leads. Terminal S wave duration in $V1 \geq 48 \text{ ms}$ and T wave negativity in CF leads separated ARVC patients from matched controls with 90% sensitivity and 86% specificity. (**Batchvarov 2015**)
Observation: The bipolar chest leads (CF leads) is a lead that resembles V1 (modified CL1 lead) The positive electrode is placed at V1 and the negative electrode is placed close to the left shoulder. It is frequently used for detecting arrhythmias during continuous monitoring of the patients admitted to the coronary care unit.
- 5) **Epsilon waves, epsilon potentials, ventricular post-excitation waves** (**Maia 1991**), **post-excitation (Epsilon) waves** (**Okano 1995**) or **Fontaine waves** due to slow conduction in the RV. The extent of ECG abnormalities correlate with the degree of structural change in the RV (**Marcus 2009**).
 - I. **fQRS:** fQRS in the S wave of right precordial leads identifies patients with recurrent VT, primary VF, and recurrent ICD discharges; $\text{fQRS} \geq 3$ leads characterized patients who died from SCD (**Peters 2012**).
 - II. **Reduced QRS amplitude:** Q waves or precordial QRS amplitudes $< 1.8 \text{ mV}$;
 - III. **Poor R Wave Progression (PRWP) on precordial leads:** The most likely cause of PRWP is clockwise rotation caused by RV enlargement (**Fontaine 1984**).
 - IV. Complete or incomplete RBBB based on the findings from epicardial mapping and histological data, is likely attributable not only to the impaired septal predivisional right bundle branch but also to distal block on RV free wall due to the irregular and delayed propagation of activation in the zones of dysplasia.

Repolarization criteria

V. Inverted T-wave in the right precordial leads V1-3 or anterior T wave inversion (TWI) above 12 years with no RBB (repolarization criteria): TWI on 12-lead ECG is usually dismissed in young people as normal persistence of the juvenile pattern of repolarization. However, TWI is a common ECG abnormality of cardiomyopathies such as hypertrophic cardiomyopathy and ARVC/D which are leading causes of SCD in athletes. In absence of CRBBB in patients >12 years of age, TWI from V1 to V3 is a sign with great value for the diagnosis. The juvenile pattern of TWI in V₁-V₃ or beyond is a normal variant in children under 12 years of age. This variant is present in 1%-3% of the healthy population aged 19 to 45 years and 87% of patients with ARVC/D (**Capulzini 2010**). In normal, young patients, there is usually positive T polarity in V1; however, it may flatten and nearly always has a positive polarity in V2. In symptomatic patient's carriers of ARVC/D, the ECG generally shows TWI in V1 and V2, which may reach up to V6 (**Fontaine 1994**). Physiological cardiac adaptation to regular exercise, including biventricular dilation and TWI, may create diagnostic overlap with ARVC/D. There are no electrical, structural, or functional cardiac differences between athletes exhibiting TWI and athletes without TWI. When athletes are compared with ARVC/D patients, markers of physiological remodeling included early repolarization, biphasic TWI, voltage criteria for RVH or LVH, and symmetrical cardiac enlargement. Indicators of RV pathology included the following: syncope; Q waves or precordial QRS amplitudes <1.8 mV; 3 abnormal SAECG parameters; delayed gadolinium enhancement, RV ejection fraction $\leq 45\%$, or wall motion abnormalities at CMRI; >1,000 premature ventricular contractions (or >500 non-RVOT) per 24 h; and symptoms, ventricular tachyarrhythmias, or attenuated blood pressure response during exercise (**Zaidi 2015**). Nonspecific parameters included the following: prolonged QRS terminal activation; ≤ 2 abnormal SAECG parameters; RV dilation without wall motion abnormalities; RVOT ectopy; and exercise-induced T-wave pseudonormalization. In ARVC/D, TWI is due to scarring of the free wall of the RV and regional conduction delay on free wall RV (**Marcus 1982, Peters 2003, Steriotis 2009**), is one of the most common ECG abnormalities in ARVC/D. To day is considered a major taskforce diagnostic criterion (**Marcus 2010; Sen-Chowdhry 2007**) may be the causes of TWI in V1-V3 or beyond. It is a secondary rather than a primary repolarization abnormality. TWI beyond V3 is more common in ARVC/D patients in the advanced stage of the disease with severe RV dilatation and LV involvement. Thus it has been considered a risk factor and perhaps an indication of a poor prognosis. TWI in the right precordial leads can also be seen in many other conditions such as acute pulmonary embolism, athlete heart, Brugada syndrome, long QT syndrome caused by *KCNH2* mutations or compound mutations, and occasionally in normal adult female. Exercise-induced T-wave pseudonormalization.

VI. ST segment elevation: The combination of J-point elevation and TWI confined to lead V1-V4 offers the potential for an accurate differentiation between 'physiologic' and 'cardiomyopathic' anterior TWI, among athletes of both white/Caucasian or black/Afro Caribbean descent (**Calore 2015**). Conversely, ST-segment elevation without J-point elevation preceding anterior TWI may reflect cardiomyopathy. is not uncommon in ARVC/D (**Peters 1999**). In a cohort study, 37% of ARVC/D patients had a ST elevation. Among these, 42% showed a small notch in the first half of the ST segment and such findings are more frequently seen in patients in the presence of epsilon waves.

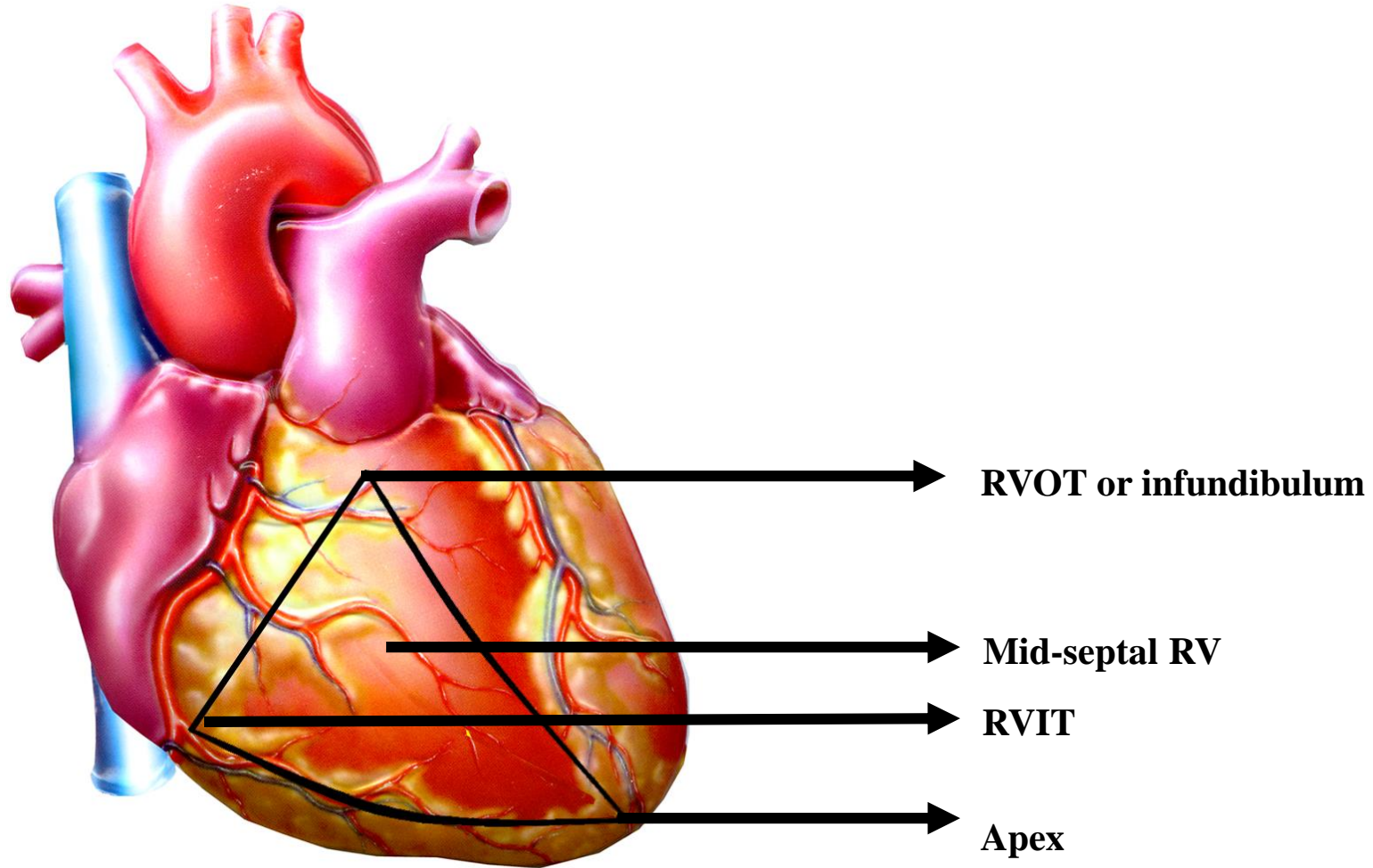
Ventricular arrhythmias

Nonsustained or sustained ventricular tachycardia in the morphology of LBBB with superior axis: Predominant negative or indeterminate in inferior leads and positive in aVL is considered a major criterion following 2010 revised Task Force Criteria for the Diagnosis of ARVC/D. VT with LBBB morphology and an inferior axis commonly originates from the RVOT. In contrast to ARVC/D, RVOT VT occurs in structurally normal hearts (occasionally the RVOT is dilated and RV regional wall motion abnormalities are seen on cardiac magnetic resonance image (CMRI) and is readily treatable with verapamil and β-blockers or radiofrequency ablation. The ECG in sinus rhythm in RVOT VT is normal as is the SAECG. In contrast to ARVC/D, there are no family screening implications with RVOT VT. Other differentials to consider include idiopathic dilated cardiomyopathy (IDCM) and Uhl's anomaly. Patients with IDCM usually have a progressive decline in left ventricular function, in contrast to ARVC/D where the right heart is primarily affected (with rare exceptions) (**Galvão Braga 2014**).

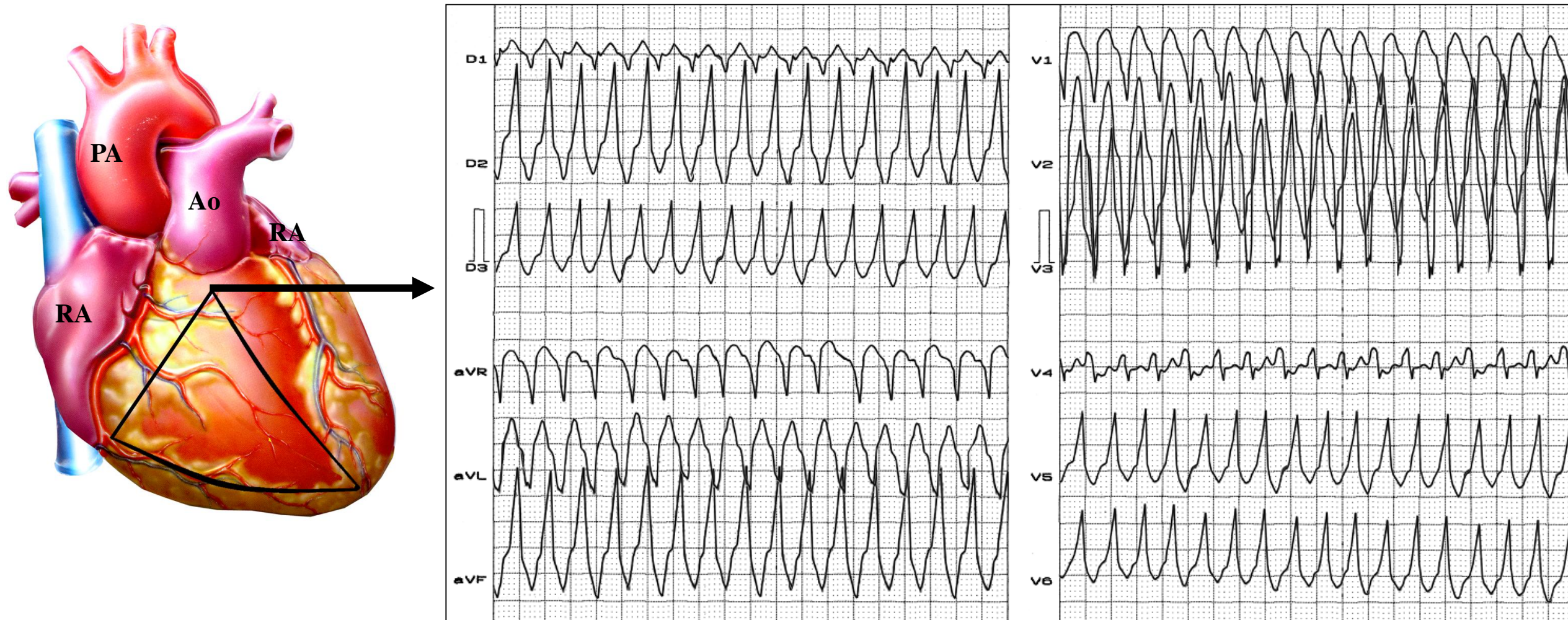
ECG differentiation of idiopathic right ventricular outflow tract ectopy with LBBB/inferior axis from early ARVC/D
(Novak 2016)

	Idiopathic right ventricular outflow ectopy	Early ARVD/C
QRS duration >160 ms	27%	60%
R peak time >80 ms	24%	65%
Initial QRS slurring	12%	40%
QS pattern in lead V1	36%	90%
QRS axis >90°	24%	60%

Relationship between the site of origin and QRS complex configuration in VT monomorphic VT that originates in the RV

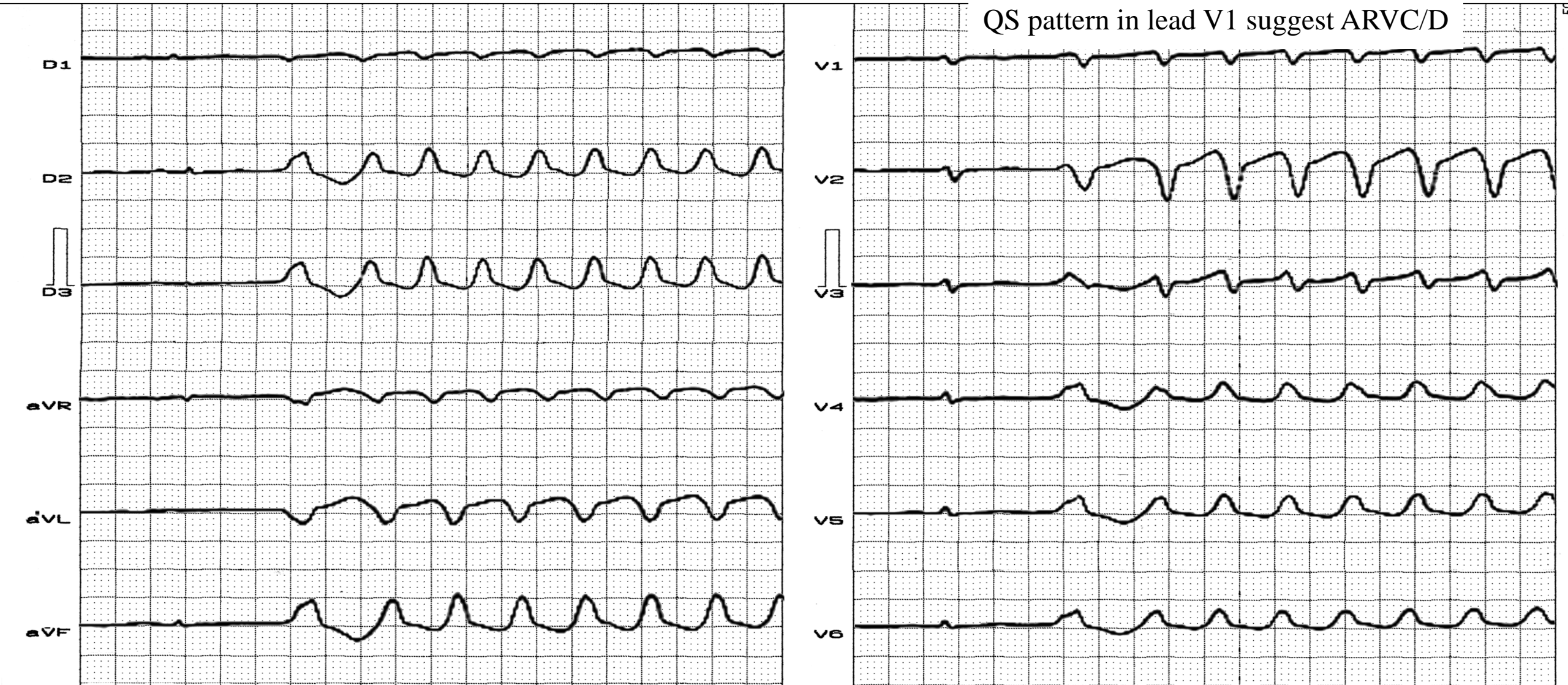


Characteristics of MVT that originates in the RVOT



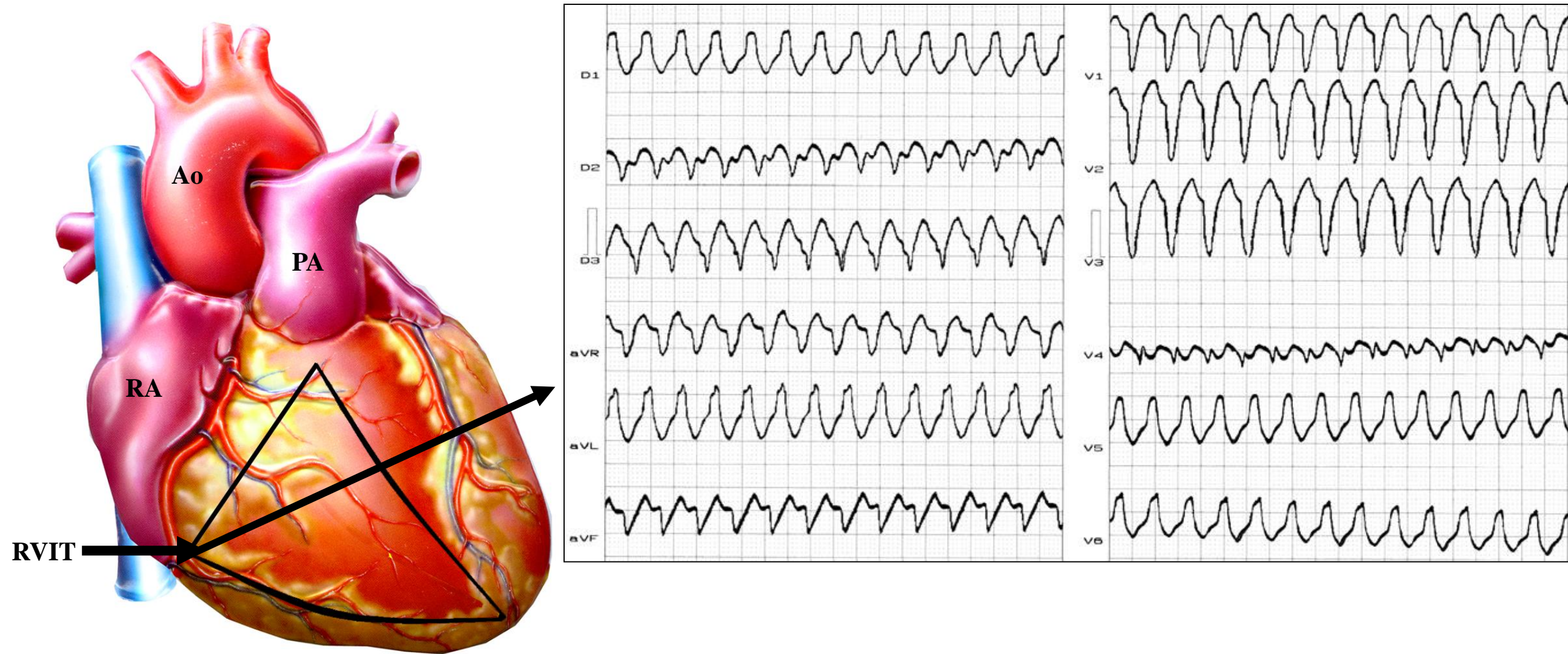
SMVT with CRBBB pattern and inferior axis in the frontal plane: positive complexes in inferior leads and negative in aVL and aVR. In this case, SÂQRS is located at the right of +90°, thus indicating origin in the RVOT. In these cases, SAQRS is between +90° and +120° ("QS" type QRS in I). This feature suggest Early ARVD/C

MVT that originates in the RVOT (Infundibulum)



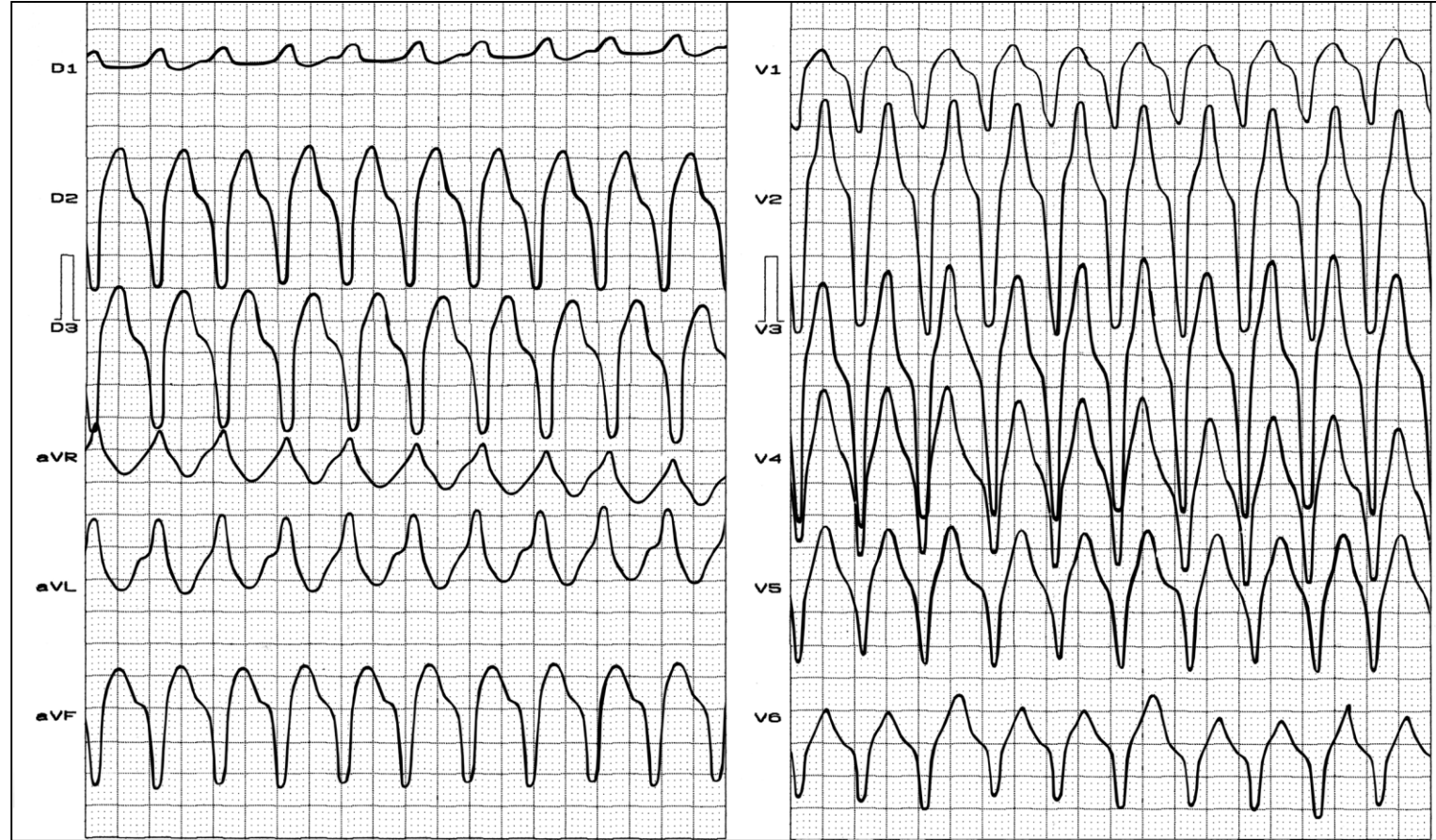
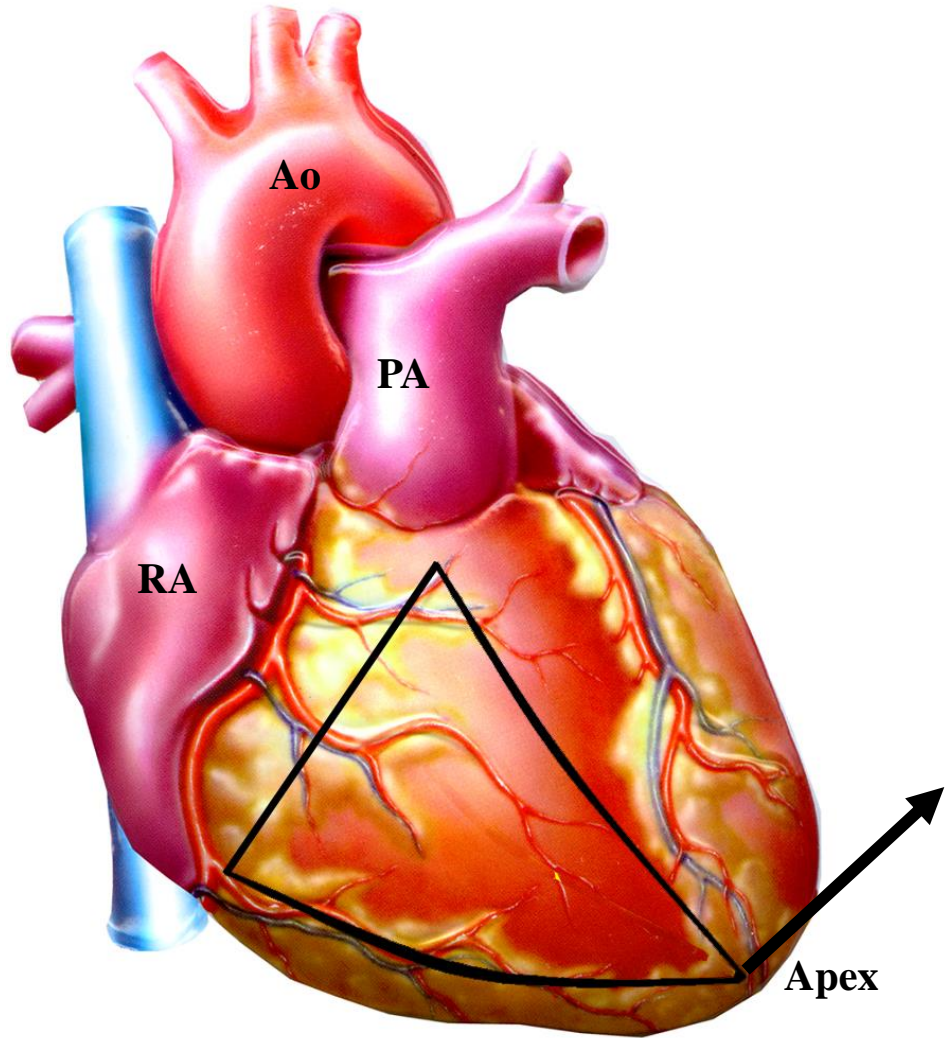
MVT that originates in the RVOT with CLBBB pattern and inferior axis in patient carrier of ARVC/D after cardiac arrest. QRS axis $>90^\circ$ and QS in V1 suggest ARVC/D.

MVT that originates in the Right Ventricular Inflow Tract



MVT with a heart rate of 214 bpm, pattern of CLBBB and electrical axis with extreme shift to the left: it originates in the RVIT. This QRS axis indicates presence of structural heart disease.

MVT that originates in the apex



VT with CLBBB morphology and SAQRS axis with extreme shift to the left: negative QRS complexes in inferior leads, positive in I, aVL and aVR, associated to negative QRS complexes from V1 to V4 or V1 to V6, which indicate focus of origin in the RV apex (it indicates structural heart disease).

In Uhl's anomaly the RV myocardium or "Parchment Right Ventricle" is paper thin and devoid of myocardium. There is no replacement of muscle by fatty tissue. It usually presents in childhood.
1,000 ventricular extra systoles (or >500 non-RV outflow tract) per 24 h.

	Ulh Anomaly, Uhl's Disease or "Parchment RV"	ARVC/D
Family history	No, but the anomaly has been described in identical twins (Hoback 1981) in a familial pattern (Digglemann 1984), and in the elderly (Obma 1974).	Present in 30% to 50% of cases. When the disease is identified genetic screening should be performed among patient's family members (Loire 1998).
Gender (M/F)	1.3 to 1.0	2.9 to 1
Age at presentation	Infant and Childhood, perhaps a case of 63-year old was reported (Luders 1988). There are two clinical types: 1) A fatal infantile type in which extreme hypoplasia is present. intractable CHF is invariably present. 2) Milder adult type in which the anatomical lesion is usually more limited.; in the adult type severe arrhythmias often constituted the major clinical problem (Drory 1977).	Adolescents and young adults, perhaps there are rare references in childhood (Kriebel 2003)
Associations with others entities	It can be seen together with some other congenital anomalies. There are references of association with functional pulmonary atresia (Cote 1973; Iakovtsova 1989; Tumbarello 1998), pulmonary valve atresia, patent ductus arteriosus, foramen ovale (Fuertes 1984) and with cardiac tamponade (Kisacik 1999).	No.
Usual mode of Clinical presentation	In infancy, it may occur with severe right-sided heart failure as well as asymptomatic cardiomegaly (Kilinc 2000). In the adult type severe arrhythmias often constituted the major clinical problem.	Palpitations, syncope, or SCD. ARVC/D may have progressed to CHF in the advanced form of the disease with low cardiac output syndrome.

	Ulh Anomaly, Uhl's Disease or "Parchment RV"	ARVC/D
Pathogenesis	May be due to the onset of apoptosis of the RV, which starts in infancy or childhood and is a continuous process. Congenital anomaly that occurred in the early development of the human embryo, caused by destruction of the right cardiogenic fold. On the other hands, Rosenquist and de Haan think that the destruction or loss of the myocardium of the RV would have had to occur after the heart had been fully developed.	Process of apoptosis starts in adolescence and can be intermittent.
Cardiothoracic index	Over 0.60 is more common (Fontaine 1982).	Normal cardiac silhouette or only slight cardiomegaly.
Exercise induced deaths	Rare	Uncommon
Pathology	Whole heart in diffuse forms (parchment heart). Absence of myocardium in the juxta-septal anterior wall of the RV (Tabib 1992) Partial aplasia of the myocardium of the anterior wall of the RV (Luders 1988) or RV myocardial hypoplasia (Iakovtsova 1989).	1) Fatty (40%): adipose infiltration of the RV was either isolated (20%) or associated with fibrosis (74.5%) and lymphocytes (5.5%). 2)Fibro-fatty (60%) associated to RV wall thinning as a consequence of apoptosis and secondary repair by fibro-fatty tissue mediated by patchy myocarditis. The association with focal lymphocytic myocarditis is high, as well as with LV and septum involvement; and appearance of RV aneurysms and inflammation is almost exclusive to the fibro-fatty variety. Whether inflammation is a primary phenomenon or a spontaneous reaction to apoptosis, still remains to be solved (Basso 1996).

	Ulh Anomaly, Uhl's Disease or "Parchment RV"	ARVC/D
Macroscopic appearances (Uhl 1952)	Severe dilatation of the ventricle and almost complete absence of muscle fibres only leaves a few zones with surviving, partially degenerated myocardial fibres. The parietal wall was paper thin with complete absence of musculature and apposition of the endocardial and epicardial layers (Gerlis 1993). Heart with a parchment-like appearance to its walls (Sutter 1996). No fatty tissue interposed between layers of myocardium	Seems to be a slowly progressive condition with one or more localizations in the RV where the myocardium is replaced by adipose or fibro-adipose tissue with progression of lesions from the epicardium towards the endocardium. The subepicardial layers resemble a plexiform structure of partially degenerated myocardial fibers within fibro-adipose tissue. These fibers may be the site of slowing of activation and the anatomical basis of intraventricular reentry phenomena. Fatty replacement of myocardium, Inflammation, enhanced fibrosis, and loss of function, apoptosis.
Associated cardiopaties	Dysplasia of the tricuspid valve Pulmonary atresia Ductus arteropusus	No
Age of clinical presentation	Neonatal or infantile live	Adults
Usual mode of presentation	Congestive cardiac failure (CCF) Arrhythmias or heart blocks are rare	Frequent arrhythmias
Incidence	Very rare	Is estimated at 1:5000 to 1:1000.

The Revised Task Force Criteria for ARVD / ARVC (Marcus 2010)

I. Global or regional dysfunction and structural alterations* Major/Minor

Major By 2D echo	Minor By 2D echo
<p>Regional RV akinesia, dyskinesia, or aneurysm and 1 of the following (end diastole): PLAX RVOT ≥ 32 mm (corrected for body size [PLAX/BSA] ≥ 19 mm/m²) PSAX RVOT ≥ 36 mm (corrected for body size [PSAX/BSA] ≥ 21 mm/m²) or fractional area change $\leq 33\%$</p>	<p>Regional RV akinesia or dyskinesia and 1 of the following (end diastole): PLAX RVOT ≥ 29 to < 32 mm (corrected for body size [PLAX/BSA] ≥ 16 to < 19 mm/m²) PSAX RVOT ≥ 32 to < 36 mm (corrected for body size [PSAX/BSA] ≥ 18 to < 21 mm/m²) or fractional area change $> 33\%$ to $\leq 40\%$</p>
By MRI:	By MRI
<p>Regional RV akinesia or dyskinesia or dyssynchronous RV contraction and 1 of the following: Ratio of RV end-diastolic volume to BSA ≥ 110 mL/m² (male) or ≥ 100 mL/m² (female) or RV ejection fraction $\leq 40\%$</p>	<p>Regional RV akinesia or dyskinesia or dyssynchronous RV contraction and 1 of the following: Ratio of RV end-diastolic volume to BSA ≥ 100 to < 110 mL/m² (male) or ≥ 90 to < 100 mL/m² (female) or RV ejection fraction $> 40\%$ to $\leq 45\%$</p>
By RV angiography:	
Regional RV akinesia, dyskinesia, or aneurysm	

II. Tissue characterization of wall

Major	Minor
Residual myocytes <60% by morphometric analysis (or <50% if estimated), with fibrous replacement of the RV free wall myocardium in ≥ 1 sample, with or without fatty replacement of tissue on endomyocardial biopsy	Residual myocytes 60% to 75% by morphometric analysis (or 50% to 65% if estimated), with fibrous replacement of the RV free wall myocardium in ≥ 1 sample, with or without fatty replacement of tissue on endomyocardial biopsy

III. Repolarization abnormalities

Major	Minor
Inverted T waves in right precordial leads (V1, V2, and V3) or beyond in individuals >14 years of age (in the absence of complete RBB QRS ≥ 120 ms)	Inverted T waves in leads V ₁ and V ₂ in individuals >14 years of age (in the absence of complete right bundle-branch block) or in V4, V5, or V6 Inverted T waves in leads V ₁ , V ₂ , V ₃ , and V ₄ in individuals >14 years of age in the presence of complete RBBB

IV. Depolarization/conduction abnormalities

Major	Minor
Epsilon wave (reproducible low-amplitude signals between end of QRS complex to onset of the T wave) in the right precordial leads (V ₁ to V ₃)	Late potentials by SAECG in ≥ 1 of 3 parameters in the absence of a QRS duration of ≥ 110 ms on the standard ECG
	Filtered QRS duration ≥ 114 ms

	Duration of terminal QRS <40 μV (low-amplitude signal duration) ≥38 ms
	Root-mean-square voltage of terminal 40 ms ≤20 μV
	Terminal activation duration of QRS ≥55 ms measured from the nadir of the S wave to the end of the QRS, including R', in V ₁ , V ₂ , or V ₃ , in the absence of complete right bundle-branch block

V) Ventricular Arrhythmias

Major	Minor
Nonsustained or sustained ventricular tachycardia of left bundle-branch morphology with superior axis (negative or indeterminate QRS in leads II, III, and aVF and positive in lead aVL)	Non-SVT or S-VT of RV outflow configuration, LBBB morphology with inferior axis (positive QRS in leads II, III, and aVF and negative in lead aVL) or of unknown axis >500 PVCs per 24 hours (Holter)

VI. Family history

Major	Minor
ARVC/D confirmed in a first-degree relative who meets current Task Force criteria	History of ARVC/D in a first-degree relative in whom it is not possible or practical to determine whether the family member meets current Task Force criteria
ARVC/D confirmed pathologically at autopsy or surgery in a first-degree relative	Premature sudden death (<35 years of age) due to suspected ARVC/D in a first-degree relative

Identification of a pathogenic mutation† categorized as associated or probably associated with ARVC/D in the patient under evaluation	ARVC/D confirmed pathologically or by current Task Force Criteria in second-degree relative
---	---

PLAX indicates parasternal long-axis view; RVOT, RV outflow tract; BSA, body surface area; PSAX, parasternal short-axis view; aVF, augmented voltage unipolar left foot lead; and aVL, augmented voltage unipolar left arm lead.

Diagnostic terminology for original criteria: This diagnosis is fulfilled by the presence of 2 major, or 1 major plus 2 minor criteria or 4 minor criteria from different groups. Diagnostic terminology for revised criteria: definite diagnosis: 2 major or 1 major and 2 minor criteria or 4 minor from different categories; borderline: 1 major and 1 minor or 3 minor criteria from different categories; possible: 1 major or 2 minor criteria from different categories.

* Hypokinesis is not included in this or subsequent definitions of RV regional wall motion abnormalities for the proposed modified criteria.

† A pathogenic mutation is a DNA alteration associated with ARVC/D that alters or is expected to alter the encoded protein, is unobserved or rare in a large non–ARVC/D control population, and either alters or is predicted to alter the structure or function of the protein or has demonstrated linkage to the disease phenotype in a conclusive pedigree. E.g.: in TMEM43, DSP, PKP2, DSG2, DSC2, JUP.

ARVC/D clinical phases	
Concealed phase	Subtle structural changes within the RV, Usually no symptoms, May have minor VT. High risk of SCD.
Overt phase	Noticeable structural/functional changes within the RV, Symptoms ventricular dysrhythmias, presyncope, syncope, palpitations
Weakening of RV	RV dilates and weakens, RV failure symptoms: edema of legs or ankles, abdominal distension, dyspepsia, anorexia
Weakening of LV	LV dilates and weakens, HF Symptoms: dyspnea on exertion, orthopnea, breathlessness.

Predictors of adverse outcome in patients with arrhythmogenic right ventricular dysplasia/cardiomyopathy

- Positive history of Congestive heart failure CHF (independent risk predictor);
- Presence of LV involvement (independent risk predictor) (**Mast 2015**);
- History of cardiac arrest or ventricular tachycardia with haemodynamic compromise, along with left ventricular involvement and younger age;
- LA dilatation: Increased atrial myocardial vulnerability is an expression of direct involvement of the atrial myocardium or can be an indirect result of advanced ventricular myocardial disease;
- Prolonged PR interval;
- QRSd > in V1;
- Presence of bundle branch block.;
- Inferior leads T wave inversion, a precordial QRS amplitude ratio of ≤ 0.48 , and QRS fragmentation constituting valuable variables to predict adverse outcome (**Saguner 2014**).

	ARVC/D	Cardiac sarcoidosis
Family history	Frequently	Possible, but rare
Sex (F/M) ratio	1:2.9	female to male ratio of 1: 1.46
Inheritance pattern	Most familial cases of the disease have autosomal dominant pattern of inheritance, which means one copy of an altered gene in each cell is sufficient to cause the disorder. Rarely, ARVC has an autosomal recessive pattern of inheritance, which means both copies of a gene in each cell have mutations. The parents of an individual with an autosomal recessive condition each carry one copy of the mutated gene, but they typically do not show signs and symptoms of the condition.	The first reported association between sarcoidosis and specific gene products was the association between class I HLA-B8 antigens and acute sarcoidosis (Brewerton 1977). Sarcoidosis likely results from an interplay of environmental and genetic factors. Inherited susceptibility. Siblings of patients with sarcoidosis have about a fivefold increased risk of developing sarcoidosis. Familial sarcoidosis was first reported in 1923 in two affected sisters (Martenstein 1923)
Dermatologic features	Present in 25% of patients with sarcoidosis. Erythema nodosum, lupus pernio, maculopapular, nodular, scar, plaque, angiolupoid, ichthyosiform, lichenoid, annular, verrucous, psoriasiform, and ulcerative lesions and subcutaneous nodules.	Striate palmoplantar keratoderma, hypotrichosis with or without skin vesicles and lethal acantholytic epidermolysis bullosa (Nitoiu 2014). In Naxos disease is characteristic palmoplantar keratoderma and woolly hair (Narin 2003).
Ocular features	Anterior polar subcasular cataract (APC) has been described in a single family with ARVD/C (Frances 1997). The proband and his sister both had ARVD/C and APC. The gene was linked to 14q24qter and it is autosomal recessive.	Uveitis, Orbital and adnexal involvement may involve the lacrimal gland, the eyelid, the orbit, and the lacrimal sac. Involvement of optic nerve(observed in 5-38% of patients with neurosarcoid.) Löfgren syndrome: erythema nodosum, bilateral hilar adenopathy, arthralgias and anterior uveitis in 6% of patients). Heerfordt syndrome: uveitis, parotid enlargement and occasionally papilledema.

	ARVC/D	Cardiac sarcoidosis
Type, associated, Locus	<p>Genes ARVC/D has mutations in desmosomal genes.</p> <p>I. ARVD11pl; OMIM: 107970; Gene TGFB3; Locus: 14q23-q24</p> <p>II. ARVD2 Cardiac Ryanodine Receptor; OMN: 600996; Gene: RYR2; Locus: 1q42-q43. Rare</p> <p>III. ARVD3; OMIM: 602086; Gene?; Locus: 14q12-q22</p> <p>IV. ARVD4; OMIM: 602087; Gene: ?; Locus: 2q32.1-q32.3</p> <p>V. ARVD5; OMIM:604400; Gene: protein 43 TMEM43; Locus: 3p23 Unknown prevalence.</p> <p>VI. ARVD6; OMIM: 604401; Gene: ?; Locus: 10p14-p12</p> <p>VII. ARVD7; OMIM:609160; Gene: DES; Locus: 10q22.3</p> <p>VIII. ARVD8; OMIM:607450; Gene: DSP; Locus: 12p11</p> <p>IX. ARVD9; OMIM:609040; Gene: PKP2. Plakophilin-2; Locus: 12p11; Prev. 11% - 43%</p> <p>X. ARVD10; OMIM:610193; Gene: DSG2 Desmoglein-2 ; Locus: 18q12.1-q12; ; Prevalence:12% - 40%</p> <p>XI. ARVD11; OMIM:610476; Gene: DSG2; Desmocollin-2 Locus:18q12.1; Prev: 1% - 5%</p> <p>XII. ARVD12; OMIM:61528; Gene: JUP Plakoglobin; Locus::17q21. Prevalence: Rare.</p> <p>XIII. Mutation in non-desmosomal gene LDB3 c.1051A>G localized in the Z-line Cypher/ZASP protein (Lopez-Ayala 20015).</p> <p>Four additional genes associated with ARVC/D have been mapped but not identified (locus ARVD3, ARVD4, ARVD6 and ARVD7. Additional loci remain undetermined (McNally 2016)</p> <p>Recessive form: Naxos disease was originally described by Protonotarios in 1986. This disease is characterized by the triad diffuse nonepidermolytic palmoplantar keratoderma, and woolly hair. Locus 17q21 (Coonar 1998).</p>	<p>human leukocyte antigen (HLA) alleles</p> <p>HLA-A; Risk Alleles A*1 (Martinetti 1995)</p> <p>HLA-B; Risk Alleles B*8 Susceptibility in several populations (Brewerton;1977; Hedfors1983; Gardner 1984)</p> <p>HLA-DPBI *0201 Not associated with sarcoidosis (Maliarik 998; Schurmann1998)</p> <p>HLA-DQBI *0201 Protection Lofgren's syndrome, mild disease in several populations (Iannuzzi 2003);</p> <p>HLA-DQBI *04 Protection in several populations (Iannuzzi 2003)</p> <p>HLA-DQBI *1101 Susceptibility in whites and Africans Americans Stage II/III chest X-ray (Rossmann 2003)</p> <p>HLA-DRB3 *1501 Associated with Lofgren's syndrome (Sato 2002; Rossmann2003)</p> <p>HLA-DRB1*0301/DQB1*0201 has been associated with good prognosis in Löfgren's syndrome.</p> <p>HLA-DRB3*0101 Susceptibility /disease progression in whites (Bogunia-Kubik 2001).</p> <p>On chromosome 6 identified the BTNL2 gene. It is a member of the B7 receptor family that probably functions as a T-cell costimulatory molecule. It resides in the class II major histocompatibility complex (MHC) region of chromosome 6p and associated with sarcoidosis susceptibility in a white German population.</p> <p>Early-onset sarcoidosis (EOS) CARD15 mutations with constitutive nuclear factor-κB activation: common genetic etiology with Blau syndrome (Kanazawa 2005)</p>

	ARVC/D	Cardiac sarcoidosis
Multisystemic involvement	No	It is the rule
Pulmonary involvement	No	Yes, chronic interstitial granulomas in the alveolar structures (alveolitis) associated with polyclonal hypergamaglobulinemia, consequence of activated lung T lymphocytes
Mitral regurgitation	Only in late stage, when involvement of LV or the exceptional isolated LV involvement	It is common
Pericardial effusion	Absent	Frequent
Improved CMRI with corticosteroids	No	Yes
Extensive angiography analysis with RV angiography	The best definition of ARVC/.D is obtained by extensive angiographic analysis with measurement of oxygen saturation and pressure curves in different positions, coronary angiography and biventricular angiography in order to distinguish between some in regard to RV involvement similar cardiac entities	Ventricular aneurysm is sometimes present. Free wall of the RV thin, dyskinetic with dilatation is possible.
VT characteristic	Great predominance of LBBB pattern (exception the rare isolated LV AVC/D. Pathogenic gene mutations are found in 65% of subjects diagnosed with ARVC/D. Mutation carriers, especially PKP2, have a higher proportion of a history of VT and more inducible fast VT (Bao 2013).	Scar-related VT with both RBBB and LBBB QRS configurations (Koplan 2006).
Chest roentgenogram	Eventual RV cardiomegaly	Typical 4-stages features
Ocular involvement	No	Very frequently. Ocular inflammation uveitis: Anterior or posterior granulomatous, conjunctival lesions and scleral plaques.

	ARVC/D	Cardiac sarcoidosis
ECG	<p>Presence of epsilon waves are considered major despolarization criteria. More frequent in the right precordial leads low-amplitude signals between end of QRS complex to onset of the T wave.</p> <p>Pure ARVC/D without LV involvement shows “more than complete RBBB” (parietal block) without fQRS in V1-V2 or epsilon in aVR. When it also affects the LV fQRS in V1-V3 and epsilon in aVR is frequent (Peters 2015).</p> <p>Inverted T waves in right precordial leads (V1to V3) or beyond in individuals age >14 years (in the absence of CRBBB)</p>	<p>Possible epsilon waves but exceptional (Santucci. 2004).</p> <p>Pseudo MI patterns frequent in extensive forms and more than complete RBBB</p>
Dermatological manifestations	No	Erythema nodosum, a lower-extremity panniculitis with painful, erythematous nodules (often with Löfgren syndrome), lupus pernio (the most specific associated cutaneous lesion), violaceous rash on the cheeks or nose (common) and paculopapular plaques (uncommon)

Sarcoidosis Theoretical considerations

Sarcoidosis is a chronic multisystem inflammatory disease of unknown etiology that manifests as noncaseating epithelioid granulomas, usually in multiple organs and predominantly in the lungs and intrathoracic lymph nodes.

Epidemiology

The prevalence is 10 times greater for African Americans than for whites. Approximately 20% of patients who are African American reported an affected family member, while only 5% of whites in the United States who have sarcoidosis state they have family members also diagnosed with sarcoidosis. African Americans seem to experience more severe and chronic disease (**Cox 2005**).

In African Americans, siblings and parents of sarcoidosis cases have about a 2.5-fold increased risk for developing the disease.

Prevalence: it is about 4.7–64 in 100 000

Incidence: of 1.0–35.5 in 100 000 per year. The age-adjusted incidence is 11 cases per 100,000 population in whites but 34 cases per 100,000 population in African Americans. The highest rates are reported in northern European and African-American individuals, particularly in women, and the lower rate is reported in Japan. Differences in prevalence and incidence are linked to age, sex, ethnic origin, and geographical location. *United States* Incidence ranges from 5-40 cases per 100,000 population. The age-adjusted incidence for whites is 11 cases per 100,000 population. The incidence is considerably higher for African Americans, at 34 cases per 100,000 population. Incidence is 20 cases per 100,000 population in Sweden and 1.3 cases per 100,000 population in Japan. Sarcoidosis occurs in China, Africa, India, and other developing countries. Although its incidence may be low, the disease remains hidden and often is misdiagnosed as tuberculosis.

Working on the World Trade Center (WTC) debris pile after the September 11, 2001 terrorist attacks was associated with sarcoidosis (**Jordan 2011**) (odds ratio, 9.1; 95% confidence interval, 1.1-74.0), but WTC dust cloud exposure was not (odds ratio, 1.0; 95% confidence interval, 0.4-2.8).

Sex: female to male ratio of 1:1.46. Morbidity, mortality, and extrapulmonary involvement are higher in affected females (**Krell 2012**).

Age: Seventy percent of patients are aged 25–45 years, Incidence peaks in persons aged 25-35 years although a second incidence peak occurs in women older than 50 years in Europe and Japan (**Morimoto 2008**). A second peak occurs for women aged 45-65 years.

The clinical expression of sarcoidosis is affected by epidemiological and socioeconomic factors. Elderly-onset sarcoidosis is much more common in women and shows higher rates of change in general health and extrapulmonary manifestations (**Varron 2012**).

Etiology

The cause of the disease is not known; however, both genetic and environmental factors seem to play a role (**Sverrild 2008**). As yet, no bacterial, fungal, or viral antigen has been consistently isolated from the sarcoidosis lesions. Sarcoidosis is neither a malignant nor an autoimmune disease.

Hereditary genetic factors: Sarcoidosis is usually sporadic, but is familial in 3.6–9.6% of cases (**Muller-Quernheim 1999**). Siblings have a higher risk of sarcoidosis than do parents, suggesting a recessive mode of inheritance with incomplete penetrance (**Rybicki 2001**). An 80-fold increase in risk in monozygotic twins lends support to the notion that genetic factors might account for two-thirds of disease susceptibility (**Sverrild 2008**).

The investigation of known and novel risk variants for sarcoidosis and specific clinical phenotypes in various ethnicities highlights the genetic complexity of the disease. Detailed subanalysis of disease phenotypes revealed the potential for prediction of extra-pulmonary organ involvement and therapy response based on the patient's genotype.

With relevance to granuloma formation, genes involved in apoptotic processes and immune cell activation were further confirmed (ANXA11 and BTNL2) in multiple ethnicities; others were newly identified (XAF1). Linking mechanism to clinical application, a TNF variant was shown to correlate with anti-TNF response in sarcoidosis patients (**Fischer 2015**).

Several lines of evidence suggest a genetic predisposition and associations have been demonstrated with HLA antigens. HLA-DQB1 has been proposed as one of the candidate genes. the combination DQB1*0602/DRB1*150101 is a strong positive marker for severe pulmonary sarcoidosis (**Voorter 2005**). A proposed schema for the genetic subtypes of sarcoidosis. *DRB1*01* and *DQB1*0501* are protective for overall sarcoidosis. The *DRB1*0401–DQB1*0301* haplotype is protective for sarcoidosis overall but a risk factor for uveitis as shown. Within sarcoidosis, *DRB1*0301–DQB1*0201* is associated with Löfgren's syndrome. Lung sarcoidosis is associated with both *DRB1*12* and **1401/2*. *DRB1*0803* is a risk factor not only for uveitis, but also for neurological and cardiac sarcoidosis. Splenomegaly is associated with *DRB1*0602*. See figure in the next slide (**Sato 2007**).

Genetic factors in Sarcoidosis

Inherited susceptibility. Siblings of patients with sarcoidosis have about a fivefold increased risk of developing sarcoidosis. The entity affects the human leukocyte antigen (HLA) alleles:

1. HLA-A; Risk Alleles A*1 (**Martinetti 1995**)
2. HLA-B; Risk Alleles B*8 Susceptibility in several populations (**Brewerton;1977; Hedfors1983; Gardner 1984**)
3. HLA-DPBI *0201 Not associated with sarcoidosis (**Maliarik 998; Schurmann1998**)
4. HLA-DQBI *0201 Protection Lofgre's syndrome, mild disease in several populations (**Iannuzzi 2003**)
5. HLA-DQBI *04 Protection in several populations (**Iannuzzi 2003**)
6. HLA-DQBI *1101 Susceptibility in whites and Africans Americans Stage II/III chest X-ray (**Rossmann 2003**)
7. HLA-DRB3 *1501 Associated with Löfgren's syndrome (**Sato 2002; Rossmann2003**)
8. HLA-DRB1*0301/DQB1*0201 has been associated with good prognosis in Löfgren's syndrome.
9. HLA-DRB3*0101 Susceptibility /disease progression in whites (**Bogunia-Kubik 2001**).

On chromosome 6 identified the BTNL2 gene. It is a member of the B7 receptor family that probably functions as a T-cell costimulatory molecule. It resides in the class II major histocompatibility complex (MHC) region of chromosome 6p and associated with sarcoidosis susceptibility in a white German population.

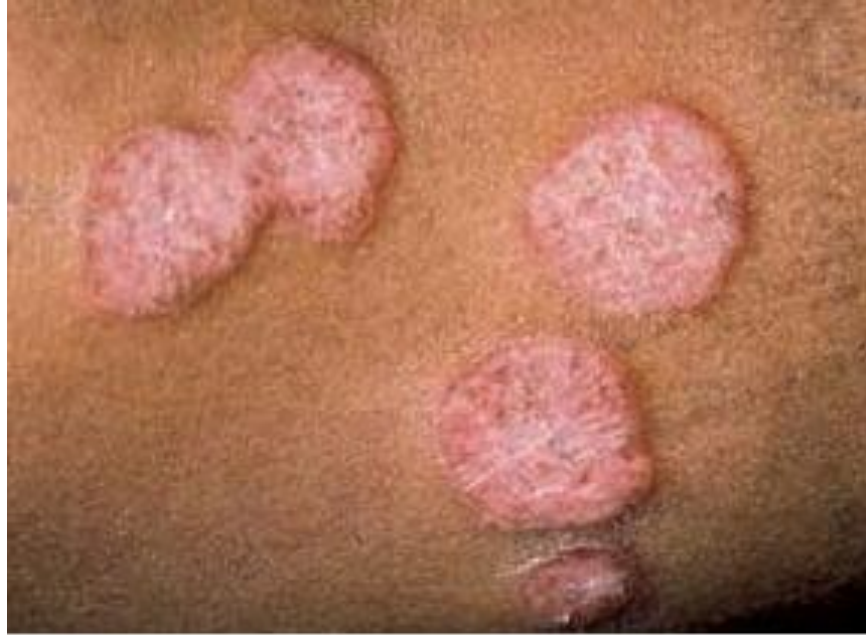Early-onset sarcoidosis (EOS) CARD15 mutations with constitutive nuclear factor- κ B activation: common genetic etiology with Blau syndrome (**Kanazawa 2005**)

Signs and symptoms

The presentation in sarcoidosis varies with the extent and severity of organ involvement, as follows: I) Asymptomatic (incidentally detected on chest imaging \approx 5% of cases; II) Systemic complaints (fever, anorexia observed in 45% of cases).

Pulmonary complaints: dyspnea on exertion, cough, chest pain, and hemoptysis (50% of cases), Löfgren syndrome (fever, bilateral hilar lymphadenopathy, and polyarthralgias): common in Scandinavian patients, but uncommon in African-American and Japanese patients. Pulmonary physical examination usually is normal. Crackles may be audible. Exertional oxygen desaturation may be present.

Dermatologic manifestations may include: erythema nodosum, a lower-extremity panniculitis with painful, erythematous nodules (often with Löfgren syndrome), lupus pernio (the most specific associated cutaneous lesion), violaceous rash on the cheeks or nose (common) and papulopustular plaques (uncommon).



Sarcoidosis—indurated, erythematous plaques

Ocular involvement: Ocular inflammation is often the first manifestation of the disease, and uveitis can be the driving force for treatment (**Liu 2015**). Ocular involvement may lead to blindness if untreated, may manifest as follows: Anterior or posterior granulomatous uveitis (most frequent) and conjunctival lesions and scleral plaques. Eye symptoms can include: dry and itchy eyes, eye pain, vision loss, a burning sensation and a discharge from the eyes.

Lymphocytic meningitis (rare)

Cranial nerve palsies and hypothalamic/pituitary dysfunction (rare)

Osseous involvement: In patients with active chronic sarcoidosis 22% of patients had osseous abnormalities on fluorodeoxyglucose (FDG) positron emission tomography-computed tomography (PET/CT) that mostly were not detected on CT (**Grozdic Milojevic 2016**).

Cardiac involvement: is common and significantly alters the patient's prognosis. Manifestations of cardiac sarcoidosis include congestive heart failure, conduction abnormalities, atrial and ventricular arrhythmias, palpitations, pre-syncope, syncope and sudden cardiac death (**Chapelon-Abrieu 2004**). Cardiac complications are the second leading cause of sarcoidosis-related death, after respiratory complications, in the United States (**Swigris 2011**). Early diagnosis of cardiac sarcoidosis remains difficult in the absence of specific symptoms. Cardiac involvement may occur and lead to an adverse outcome: the heart mechanics will be affected and that causes ventricular failure, and the cardiac electrical system will be disrupted and lead to third degree atrioventricular block, malignant ventricular tachycardia, and heart block and sudden cardiac death. The evolution and prognosis of the disease are strongly correlated to an early and appropriate treatment. There is no standardized approach for the early diagnosis of cardiac sarcoidosis.

Cardiac sarcoidosis (CS) can be clinically silent or can present with vague constitutional symptoms, heart failure, palpitations, presyncope, or syncope. The clinical manifestations of CS depend not only upon the location and extent of granulomatous inflammation, but also on the stage of the disease process. Early diagnosis and prompt initiation of corticosteroid therapy with or without other immunosuppressants is crucial. Sarcoidosis granulomas can affect any part of the heart but there is a clear predilection for certain areas. The most common areas of involvement are the basal segment of the inferolateral left ventricular free wall and the basal interventricular septum, followed by the atrium, papillary muscles, the right ventricle and the pericardium. In its early stages, sarcoid is an active inflammatory disorder that causes myocardial swelling and edema, progressing in later stages to fibrosis (myocardial scarring). When cardiac involvement occurs, the outcome is fatal. Cardiac sarcoidosis is insidious to diagnose because it is usually asymptomatic and when clinically apparent, it may have a wide variety of manifestations.

Isolated CS is relatively rare, there are certain clinical features that should raise suspicion of this disease variant. Patients with isolated cardiac sarcoidosis tend to be younger (25– 55 years old) and often present with unexplained high grade AV block, VT, or CHF. In these patients a search for sarcoidosis should be undertaken as conventional antiarrhythmic and CHF treatments may be ineffective. Given the propensity for sarcoidosis to involve the respiratory system and mediastinum, screening with chest imaging (CXR, and/or chest CT) is indicated. Likewise, a routine ophthalmological examination may reveal characteristic findings. In view of the potential side-effects of immunomodulating therapies, every effort should be undertaken to obtain diagnostic tissue from an extracardiac source prior to the initiation of treatment for presumed CS. When extracardiac sarcoidosis is not evident but suspicion for CS remains high, further investigation with advanced cardiac imaging (CMRI and/or cardiac PET-CT) is indicated, looking for characteristic patterns. A cardiac biopsy may be necessary if diagnosis remains in doubt after all other measures have been undertaken to detect CS.

Values and features of Cardiologic Diagnosis methods

I. Electrocardiogram

A resting ECG is an appropriate screening test to order in all patients with confirmed or suspected sarcoidosis. Abnormalities on ECG (e.g., conduction disturbances arrhythmias, or nonspecific ST and T-wave changes) can be demonstrated in 20 to 31% of sarcoid patients (**Fahy 1996**). In a large population survey of 963 Japanese patients with sarcoidosis, 22% had right bundle branch block, premature supraventricular or ventricular contractions, or ST-T wave abnormalities compared with 17% of healthy age- and sex-matched controls (**Numao 1976**). Atrioventricular block was also a common ECG finding. Another series from northern Sweden compared 86 consecutive patients with various stages of sarcoidosis with 86 age- and sex-matched healthy controls (**Thunell 1983**). Twenty-seven sarcoidosis patients (31%) had conduction or repolarization disorders compared with 12 controls (14%). A prospective study of 80 young patients with sarcoidosis and no history of cardiac complaints detected abnormalities on ECGs in 41 patients (50%), including conduction defects, abnormal repolarization, and arrhythmias (**Stein 1973**). In a series of 84 consecutive autopsied patients with sarcoidosis, 20 had documented ECG abnormalities (i.e., premature ventricular contractions (PVCs), bundle branch block, first-degree heart block, or supraventricular arrhythmias) during life (**Silverman 1978**). In a smaller series of 35 patients with sarcoidosis without overt cardiac involvement, six had resting ECG abnormalities, including sinus bradycardia, sinus tachycardia, or right bundle branch block (**Gibbons 1991**). From these various series, approximately 20 to > 30% of patients with sarcoidosis appear to have detectable ECG abnormalities.

The prevalence of ECG abnormalities correlated with the severity of cardiac involvement. In one necropsy study, 15% of patients without detectable cardiac involvement had ECG abnormalities. In contrast, 42% of patients with mild cardiac involvement (microscopically evident granulomas) and 75% of patients with severe involvement (gross evidence of cardiac granulomas or infiltration) at necropsy had arrhythmias or conduction disturbances. Furthermore, the types of ECG abnormalities differ among patients with varying degrees of myocardial involvement. For example, a higher percentage of patients with eventually fatal autopsy-proven myocardial sarcoidosis had complete heart block and ventricular tachycardia, whereas left axis deviation and ST-T wave changes were more common among patients with positive biopsies for myocardial sarcoidosis (**Silverman 1978**).

Concerns about the relatively low sensitivity of resting ECG for detecting cardiac involvement have been raised. Furthermore, the clinical significance of nonspecific ECG abnormalities is unclear. Any abnormality on ECG should prompt further evaluation with an imaging study, to document or exclude cardiac involvement by sarcoidosis.

Summary ECG in Sarcoidosis

- Low to intermediate/ intermediate sensitivity/specificity.
- In patients with a histologic diagnosis of extracardiac sarcoidosis, cardiac sarcoidosis is suspected when item (a) and one or more of items (b) though (e) are present: (a) CRBBB, left axis deviation, atrioventricular block, VT, PVCs (\geq Lown 2), or abnormal Q or ST-T change on the ECG or ambulatory ECG.
- Finding: variables degree of AV block since mild first-degree atrioventricular (AV) block until advance AV block or complete AV block, intraventricular conduction disturbance (IVCD)/bundle branch block (BBB), PVCs monomorphic or polymorphic, sinus tachycardia, pseudoinfarct pattern, left ventricular hypertrophy (LVH), negative T waves, fragmented QRS and exceptionally epsilon waves, with bursts of rapid polymorphic VT, Useful as a screening tool in patients with extracardiac sarcoidosis. Complete AV block is the most common, and VT/VF the second most common arrhythmia in this disease, both of which are associated with SCD (**Kusano 2016**). The Selvester QRS scoring estimates CS-associated myocardial damage and identifies patients with cardiac sarcoidosis equally well as CMRI with late gadolinium enhancement (CMRI-LGE). A higher QRS score is also associated with an increased risk of life-threatening events in CS, indicating its potential use as a risk predictor (**Sobue 2015**). All patients with sarcoidosis should have an annual ECG. Patients who report palpitations should have a thorough evaluation with at least Holter monitoring.

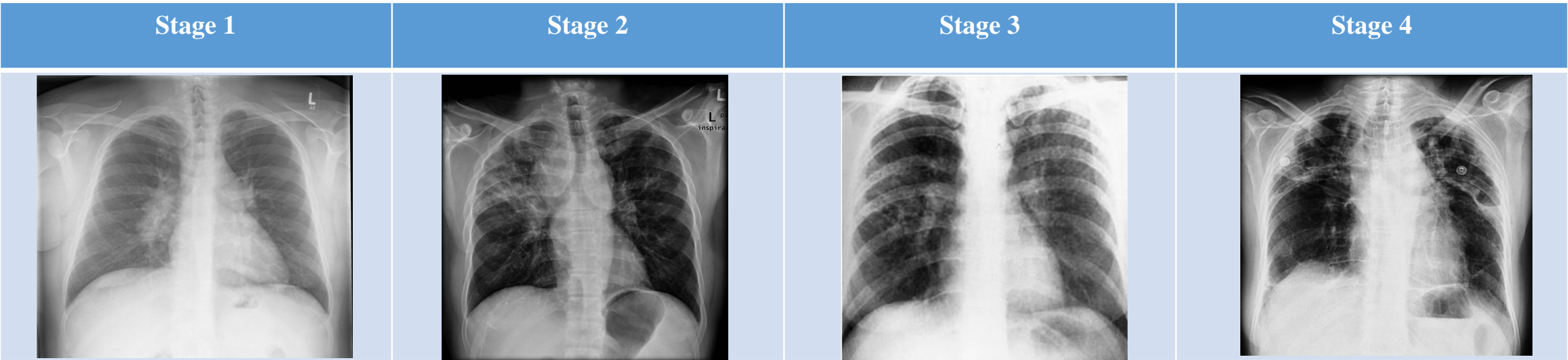
II. Holter Monitor

- Intermediate sensitivity/specificity
- Finding: Frequent PVCs (.100/day), non-sustained VT (NSVT), AV block.
- **Comments:** Useful as a screening tool in patients with extracardiac sarcoidosis. Useful in monitoring response to treatment.

III. Chest radiography: Central to the initial evaluation.
Pulmonary sarcoidosis may be classified on a chest radiograph into 5 stages (**Jannette 2007; Miller 1995**):

Staging of sarcoidosis

Stage 0	<ul style="list-style-type: none">Normal chest radiographic findings. No pulmonary radiological lesion. 5-10% of patients at presentation.
Stage I	<ul style="list-style-type: none">Bilateral hilar lymphadenopathy. The lungs are normal. Hilar or mediastinal nodal enlargement only. 45-65% of patients at presentation. 60% go onto complete resolution.
Stage II	<ul style="list-style-type: none">Bilateral hilar lymphadenopathy and infiltrates. Nodal enlargement and parenchymal disease. 25-30% of patients at presentation.
Stage III	<ul style="list-style-type: none">Infiltrates alone. Parenchymal disease only. 15% of patients at presentation.
Stage IV	<ul style="list-style-type: none">Fibrosis. End-stage lung (pulmonary fibrosis)



Diffuse reticulonodular pattern, the lung parenchyma is distorted by fibrosis, and the right hilum is retracted due to right upper lobe fibrosis. Although in general patients progress from one stage to the next this system does to correlate particularly well on clinical severity. In fact, chest x-ray appearances often are more dramatic than functional impairment.

IV. Transthoracic Echocardiogram

- Low to intermediate / intermediate sensitivity/specificity
- **Finding:** LV or RV dysfunction, abnormalities in wall thickness, septal thickening/thinning, mitral regurgitation, local aneurysms, pericardial effusion, pulmonary hypertension. LV dilatation and systolic dysfunction.
- **Comments:** Low sensitivity as sole imaging modality. Widely available, safe, and relatively low cost. Prognostic information via ejection fraction (EF) that can be monitored over time.

V. Routine chest computed tomography (CT): Adds little to radiography.


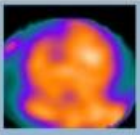

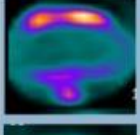


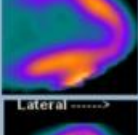
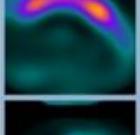
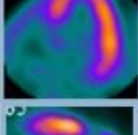
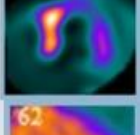


VI. High-resolution CT (HRCT) scanning of the chest: May be helpful; identifies active alveolitis versus fibrosis, and findings correlate with biopsy yield.

VII. Gallium scans: Used infrequently; has low sensitivity and specificity, but may be helpful when the clinical picture remains confusing despite histologic evidence of noncaseating granulomas (eg, differentiating chronic hypersensitivity pneumonitis from sarcoidosis).

VIII.Cardiac PET/CT

- High / intermediate sensitivity/specificity
- **Finding:** Focal or focal on diffuse myocardial FDG uptake.
- **Comments:** Test of choice for diagnosing cardiac sarcoidosis. Simultaneous assessment for myocardial perfusion defects increases specificity. Can be done in patients with implanted cardiac devices. Useful in monitoring treatment response.

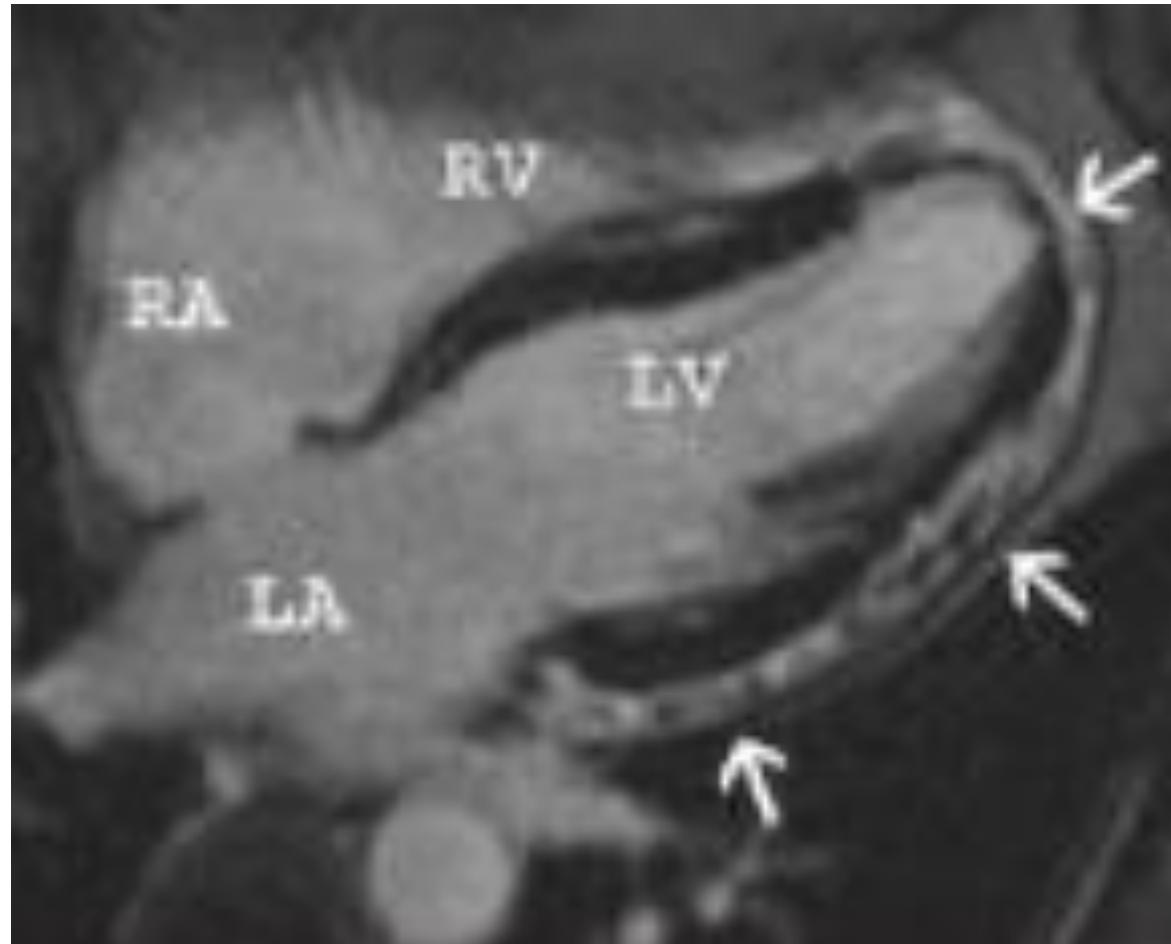
IX. F-fluoro-2-deoxyglucose positron emission tomography (18F-FDG PET) in the diagnosis and assessment of cardiac sarcoidosis. 18F-FDG PET has many practical advantages in assessing disease activity and monitoring treatment response. Accumulating data support the growing role of 18F-FDG PET in the diagnosis and risk stratification of patients with cardiac sarcoidosis. Recently, CMRI and 18F-FDG PET have been demonstrated to be useful tools for the non-invasive diagnosis of cardiac sarcoidosis as well as therapeutic evaluation tools, but are still unsatisfactory. Imaging modalities that can both identify disease and predict response to therapy are paramount to improve management of cardiac sarcoidosis. The multi-modality assessment based on CMRI and PET/CT has significantly improved the detection of cardiac sarcoidosis. Recent studies have demonstrated the promising potential of CMRI and 18F-FDG PET in the diagnosis and assessment of cardiac sarcoidosis. 18F-FDG PET has many practical advantages in assessing disease activity and monitoring treatment response in patients with cardiac sarcoidosis.

STAGES	Perfusion/FDG Patterns			
	Perfusion Defect	FDG-Uptake		
Normal	None		No/ Low	
Early	None		FDG uptake high	
Progressive	Mild			
Peak active	Moderate			
Progressive myocardial impairment	Severe			
Fibrosis	Severe		Low	

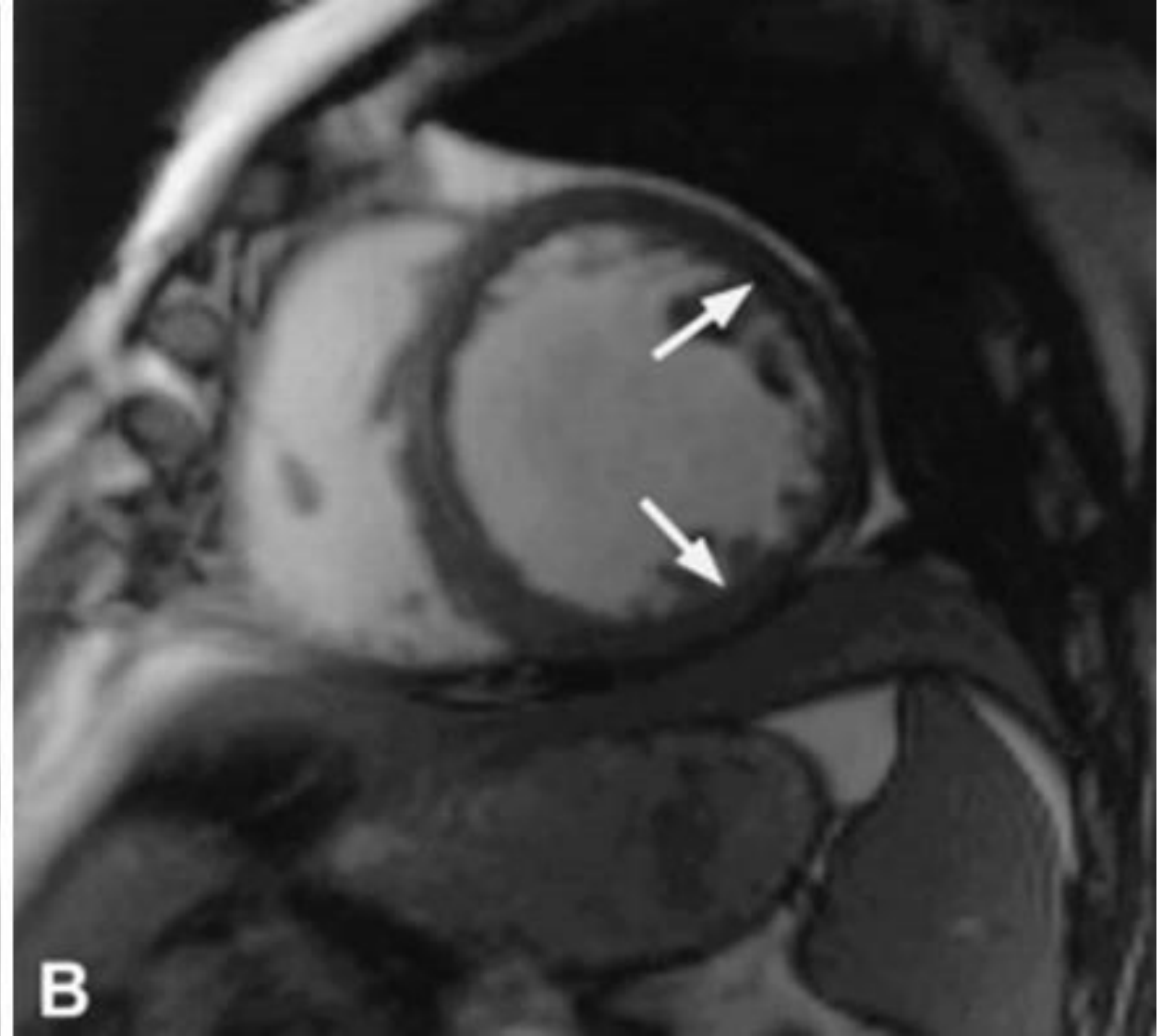
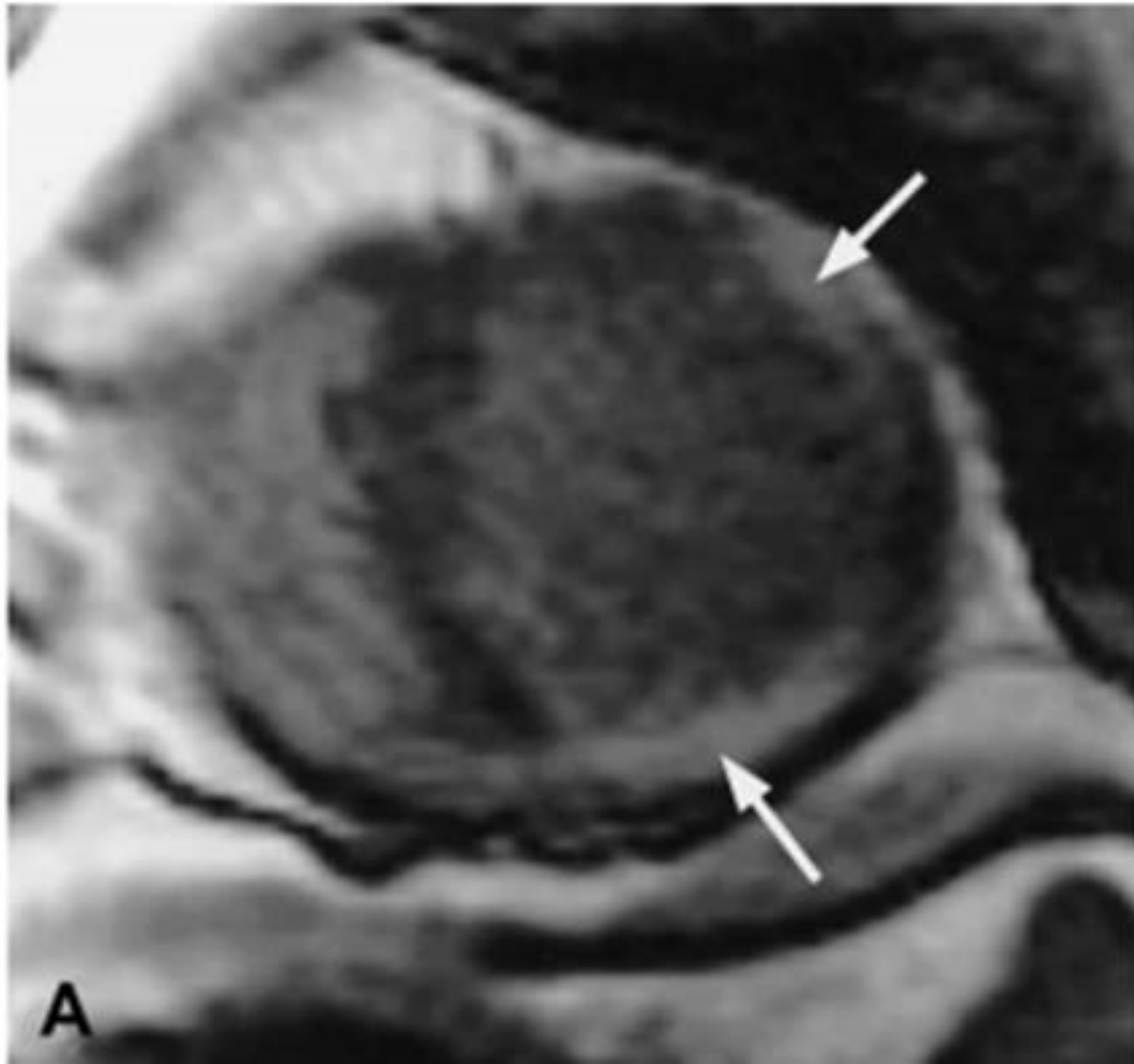
Perfusion and fluorine-18-fluoro-deoxy-glucose uptake in cardiac sarcoidosis. Perfusion and metabolism patterns in various stages of cardiac sarcoidosis.

X. CMRI:

- High / intermediate-high sensitivity/specificity
- **Findings:** Increased signal intensity on T2- weighted image indicates edema. LGE in areas consistent with known sarcoid pattern of cardiac involvement
- **Comments:** Test of choice for diagnosing cardiac sarcoidosis. No exposure to radiation, it has a prognostic implication, correlates with disease activity, cannot be done in patients with ICDs or PPM limiting its use in following patients over time.



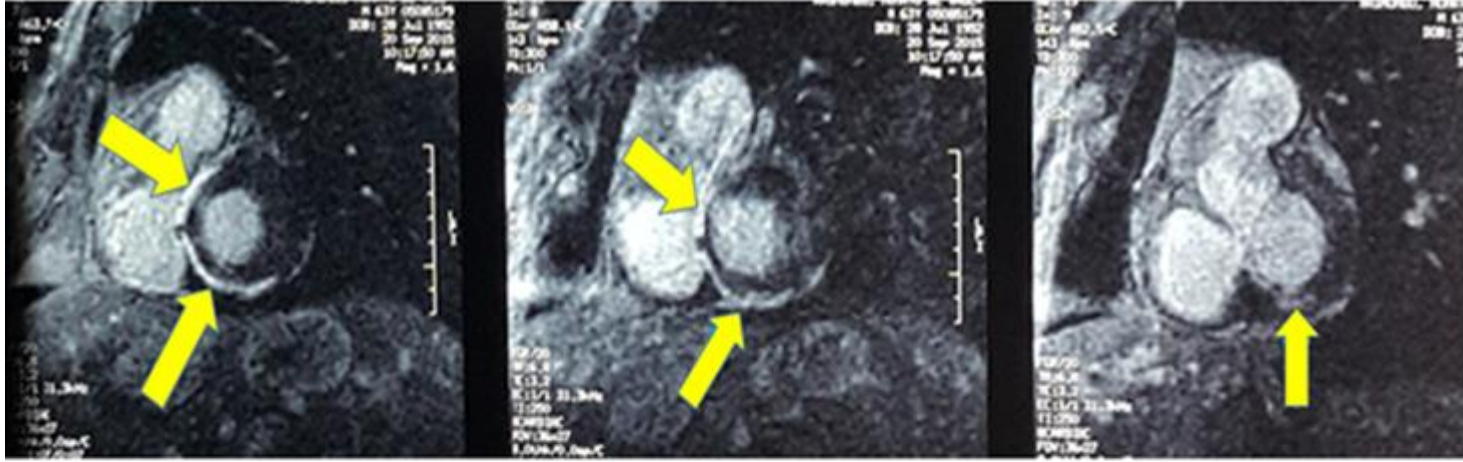Cardiac sarcoidosis. Four-chamber CMRI-LGE in a patient with known sarcoidosis and heart block shows diffuse myoepicardial enhancement (arrows) in a pattern consistent with cardiac sarcoidosis.



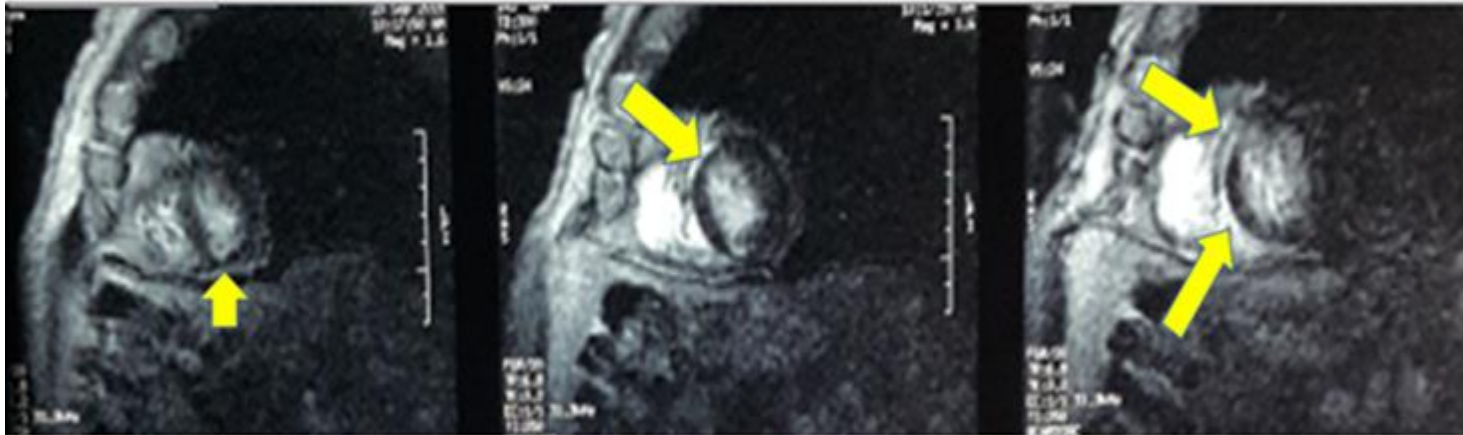- (A) Cardiovascular magnetic resonance study (inversion recovery-gradient echo, short-axis view, 10 min after administration of 0.1 mmol/gadolinium-DTPA) of patient 1, a 53-year-old man with a history of stage 2 pulmonary sarcoidosis, who presented with congestive cardiac failure. Arrows point toward the enhanced myocardial segments (**Deng 2002; Cerqueira 2002; Sekiguchi 1996**).
- (B) The end-systolic frame (steady-state-free precession, short axis view) of this slice demonstrated regional loss of wall thickness and hypokinesia of the gadolinium-enhanced segments.

Cardiac Magnetic Resonance Image short axis view (images of the present case)

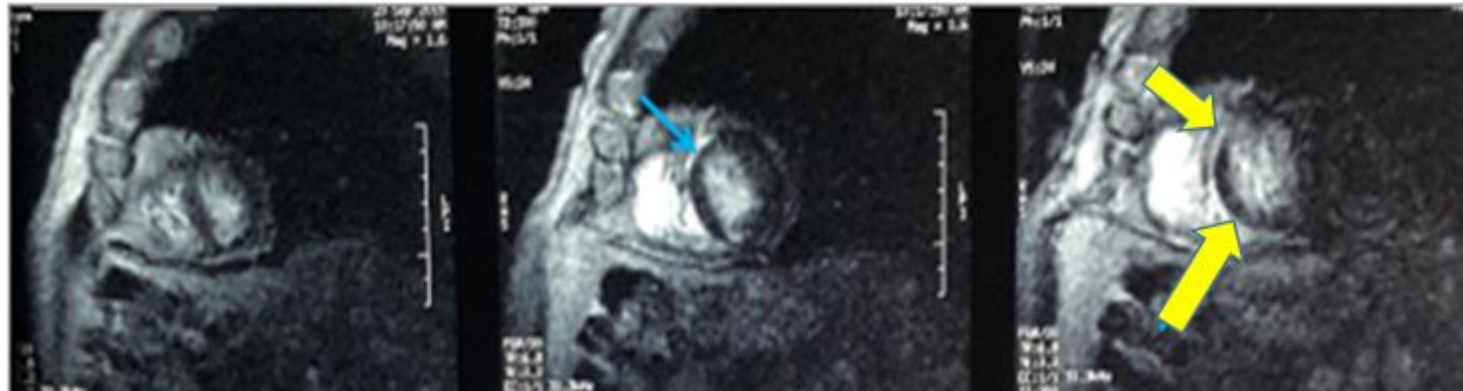Basal



Medial



Apical



The pattern of fibrosis is very suggestive of sarcoidosis, with meso-epicardial predominance. Continuous bands of late enhancement are observed, affecting the subepicardial regions of the inferior and septal walls of the basal and mid-cavitary portions of the left ventricle, with discrete extension into the basal infero-lateral and mid-cavitary segments. The distribution is not limited to vascular territories.

XII. Pulmonary function tests and a carbon monoxide diffusion capacity test of the lungs for carbon monoxide (DLCO) are used routinely in evaluation and follow-up. Possible findings are as follows: an isolated decrease in DLCO is the most common abnormality, a restrictive pattern is seen in patients with more advanced pulmonary disease. Approximately 15-20% of patients have obstruction.

XIII. Cardiopulmonary exercise testing is a sensitive test for identifying and quantifying the extent of pulmonary involvement. Cardiopulmonary exercise testing also may suggest cardiac involvement that otherwise is not evident. Impaired heart rate recovery during the first minute following exercise has been shown to be an independent predictor for cardiovascular and all-cause mortality (**Arai 1989**), and it may identify patients who are at high risk for ventricular arrhythmias and sudden death (**Shetler 2001**).

XIV. Routine laboratory evaluation is often unrevealing, but possible abnormalities include the following:

- Hypercalcemia (about 10-13% of patients) (**Hishida 2016**)
- Hypercalciuria (about a third of patients)
- Elevated serum alkaline phosphatase
- Elevated angiotensin-converting enzyme (ACE) levels (**Tasaki 2012**)

XV. Kveim test (KST): consists of injecting the Kveim reagent, a particulate suspension prepared from granulomatous splenic tissue of a patient with sarcoidosis, into the skin of a person with suspected. $\approx 50\%$ -80% of patients with sarcoidosis have a positive reaction and develop noncaseating granulomas in the injection. The false-positive rate has been quoted at 1%-5%, although most of the underlying data are more than 40 years old. It is most helpful in delineating sarcoidosis as a cause of erythema nodosum, uveitis, liver granulomas, hypercalciuria and meningitis. It is the patient's preference when he is confronted with the choice between a skin test or alternatively bronchoscopy, lung biopsy or aspiration liver biopsy. It also creates considerable academic interest for it reflects granuloma formation vividly when viewed by modern immunopathology techniques. Its disadvantage is that it takes a month to provide a result; a critical month in which systemic steroids are avoided for this would suppress the test. The immunopathology of the KST test is similar to spontaneous sarcoid granuloma formation, and evolution of the KS granuloma may provide clues to the cause of sarcoidosis and other granulomatous disorders (**James 1991**). Once a tool for the noninvasive diagnosis of sarcoidosis, the KST is no longer used clinically. The reasons behind this discontinuation are the availability of transbronchial biopsy, difficulty obtaining a clinically validated KST reagent, and the possibility of disease transmission with the injection of human tissue. The Kveim reaction is still not fully understood, and the active component of what causes the antigenic response has not been identified. As such, it is still used for research purposes to better understand the etiology of sarcoidosis.

XVI.Endomyocardial biopsy: myocardial sarcoid involvement is patchy, often involving the left ventricular or the basal septum and sparing the endocardium. This typical pattern of involvement explains the low diagnostic yield (,20%) of a standard right ventricular endocardial biopsy in the setting of CS (**Uemura 1999**). With the emergence of advanced cardiac imaging, including CMRI and cardiac PET-CT, patients with biopsy-proven extracardiac sarcoidosis rarely require an endomyocardial biopsy to establish a presumptive diagnosis of CS. In some cases, including isolated CS (discussed in detail below), cardiac biopsy can yield the appropriate diagnosis. When cardiac biopsy is contemplated, image-guided techniques can dramatically improve the yield (**Kandolin 2011**). In some cases, a tissue diagnosis of sarcoid is not possible and in these cases an empiric trial of steroid therapy with clinical improvement is felt to be highly suggestive of CS. Diagnosis requires biopsy in most of cases. Endobronchial biopsy via bronchoscopy is often done. The yield is high; results may be positive even in patients with normal chest radiographs. The central histologic finding is the presence of noncaseating granulomas with special stains negative for fungus and mycobacteria.

Management

Nonsteroidal anti-inflammatory drugs (NSAIDs) are indicated for the treatment of arthralgias and other rheumatic complaints. Patients with stage I sarcoidosis often require only occasional treatment with NSAIDs.

Treatment in patients with pulmonary involvement is as follows:

Asymptomatic patients may not require treatment. In patients with minimal symptoms, serial reevaluation is prudent. Treatment is indicated for patients with significant respiratory symptoms. Corticosteroids can produce small improvements in the functional vital capacity and in the radiographic appearance in patients with more severe stage II and III disease. For extrapulmonary sarcoidosis involving such critical organs as the heart, liver, eyes, kidneys, or central nervous system, corticosteroid therapy is indicated. Topical corticosteroids are effective for ocular disease. For pulmonary disease, prednisone is generally given daily and then tapered over a 6-month course. High-dose inhaled corticosteroids may be an option, particularly in patients with endobronchial disease. Common indications for noncorticosteroid agents include the following: Steroid-resistant disease, intolerable adverse effects of steroids, patient desire not to take corticosteroids.

Noncorticosteroid agents include:Methotrexate (MTX) has been a successful alternative to prednisone, chloroquine and hydroxychloroquine have been used for cutaneous lesions, hypercalcemia, neurologic sarcoidosis, and bone lesions. Chloroquine has been found effective for acute and maintenance treatment of chronic pulmonary sarcoidosis (**Baltzan 1999; Zic 1991**).

Cyclophosphamide has been rarely used with modest success as a steroid-sparing treatment in patients with refractory sarcoidosis (**Demeter 1988; Doty 2003**).

Azathioprine is best used as a steroid-sparing agent (**Muller-Quernheim 1999**).

Chlorambucil may be beneficial in patients with progressive disease unresponsive to corticosteroids or when corticosteroids are contraindicated (**Kataria 1980**).

Cyclosporine may be of limited benefit in skin sarcoidosis or in progressive sarcoid resistant to conventional therapy (**Kataria 1980**).

Infliximab (**Doty 2005; Yee 2001**) and thalidomide (**Baughman 2002; Fazzi 2012**) have been used for refractory sarcoidosis, particularly for cutaneous disease, as well as for the long-term management of extrapulmonary sarcoidosis (**Russell 2013**).

Infliximab appears to be an effective treatment for patients with systemic manifestations such as lupus pernio, uveitis, hepatic sarcoidosis, and neurosarcoidosis.

For patients with advanced pulmonary fibrosis from sarcoidosis, lung transplantation remains the only hope for long-term survival. Indications for transplantation include either or both of the following (**Nathan 2005**): Forced vital capacity below 50% predicted, forced expiratory volume in 1 second below 40% predicted. Sarcoidosis is a multisystem inflammatory disease of unknown etiology that predominantly affects the lungs and intrathoracic lymph nodes. Sarcoidosis is manifested by the presence of noncaseating granulomas (NCGs) in affected organ tissues. It is characterized by a seemingly exaggerated immune response against a difficult-to-discern antigen (**Ten Berge 2012**).

Pathophysiology

T cells play a central role in the development of sarcoidosis, as they likely propagate an excessive cellular immune reaction. For example, there is an accumulation of CD4 cells accompanied by the release of interleukin (IL)–2 at sites of disease activity. This may manifest clinically by an inverted CD4/CD8 ratio. Pulmonary sarcoidosis is frequently characterized by a CD4⁺/CD8⁺ ratio of at least 3.5 in bronchoalveolar lavage fluid (BALF), although up to 40% of the cases present a normal or even decreased ratio, thus limiting its diagnostic value. (**Mota 2012**). Increased production of TH1 cytokines, such as interferon, is also a feature. Moreover, both tumor necrosis factor (TNF) and TNF receptors are increased in this disease. The importance of TNF in propagating inflammation in sarcoidosis has been demonstrated by the efficacy of anti-TNF agents, such as pentoxifylline (**Zabel 1997**) and infliximab (**Doty 2005; Yee 2001**) in treating this disease.

In addition to T cells, B cells also play a role. There is evidence of B cell hyperreactivity with immunoglobulin production.

Soluble HLA class I antigens levels in serum and BALF are higher in patients with sarcoidosis. These levels tend to be significantly higher in active than in inactive stages and correlate with angiotensin-converting enzyme (ACE) levels (**Ogisu 2001**).

Active sarcoidosis has also been associated with plasmatic hypergammaglobulinemia (**Hunninghake 1981**). B-cell accumulation has been shown in pulmonary lesions, and a beneficial effect with anti-CD20 monoclonal antibody therapy has been reported in select patients. Glycoprotein KL-6 and surfactant protein D (SP-D) derived from alveolar type II cells and bronchiolar epithelial cells are significantly increased in pulmonary sarcoidosis and correlate with the percentage of lymphocytes in BALF, reflecting an inflammatory response in sarcoidosis. However, there is no significant correlation between KL-6 or SP-D levels and chest radiography findings, ACE levels, or CD4/CD8 ratio in BALF (**Hunninghake 1981**).

KL-6 has been shown to be predictive of increased pulmonary parenchymal infiltration (**Miyoshi 2010**). A study by Facco et al suggests that Th17 cells may play a role in the pathogenesis and progression of sarcoidosis; these cells were noted to be present in the blood, BALF samples, and lung tissue from patients with sarcoidosis, particularly in those with the active form of the disease (**Facco 2011**).

Prognosis

Many patients do not require therapy, and their conditions spontaneously improve. Markers for a poor prognosis include advanced chest radiography stage, extrapulmonary disease (predominantly cardiac and neurologic), and evidence of pulmonary hypertension. Multiple studies have demonstrated that the most important marker for prognosis is the initial chest radiography stage. In one study of patients with radiographic stage IV sarcoidosis, during an average follow-up of 7 years, pulmonary hypertension was observed in 30% of cases. Long-term oxygen therapy was required in 12%. Survival was 84% at 10 yrs. Cause of death in 11% patients included refractory pulmonary hypertension, acute and chronic respiratory insufficiency, and heart sarcoidosis. Seventy-five percent of fatalities are directly attributable to respiratory causes (**Nardi 2011**).

Stage	Remission (%)	Asymptomatic at 5 y/o (%)	Chest Radiograph Clearing (%)	Mortality (%)
I	60-90	95	54	0
II	40-70	58	31	11
III	10-20	25	10	18
IV	0	N/A	0	N/A

Data regarding mortality from sarcoidosis are scant. In the United States, deaths tend to result from the complications of end-stage lung disease (eg, respiratory failure, right heart failure).

Functional impairment occurs in only 15-20% of patients and often resolves spontaneously. The overall mortality rate is less than 5% for untreated patients.

The likelihood of regression for pulmonary disease correlates with the extent of parenchymal disease, as noted by chest radiography stage.

According to a study by Swigris et al (**Swigris 2011**) the rate of sarcoidosis-related mortality in the United States appears to have increased significantly from 1988-2007, particularly in black females aged 55 years or older. This study also confirmed findings from prior reports, indicating that the underlying cause of death in most patients with sarcoidosis was the disease itself (**Takase 2010**).

History

Presentation depends on the extent and severity of the organ involved. Approximately 5% of cases are asymptomatic and incidentally detected by chest radiography. Systemic complaints of fever, anorexia, and arthralgias occur in 45% of cases. Pulmonary complaints — dyspnea on exertion, cough, chest pain, and hemoptysis (rare) — occur in 50% of cases.

Löfgren syndrome symptoms consist of fever, bilateral hilar lymphadenopathy (BHL), and polyarthralgias. This presentation is associated with an excellent prognosis. Although common in Scandinavian patients, it is uncommon in African-American and Japanese patients.

Pulmonary findings

They are usually normal but may be significant for crackles. Exertional oxygen desaturation may also be found.

Chest radiography staging system: Stage 0 is normal chest radiography findings: Stage I is BHL. Stage I sarcoidosis; Stage II is BHL and infiltrates.

Ocular manifestations

About 30-60% of sarcoidosis patients develop intraocular inflammatory signs, and bilateral granulomatous uveitis is the most common presentation (**Takase 2010**).

CD4/CD8 ratio of vitreous-infiltrating lymphocytes has high diagnostic value in ocular sarcoidosis, comparable to that of the CD4/CD8 ratio in BALF lymphocytosis for pulmonary sarcoidosis (**Kojima 2012**).

International criteria for the diagnosis of ocular sarcoidosis have been determined from the results of the first International Workshop On Ocular Sarcoidosis (**Herbort 2009**). Four levels of certainty for the diagnosis of ocular sarcoidosis (diagnostic criteria) are recommended in patients in whom other possible causes of uveitis had been excluded. Criteria are as follows: Biopsy-supported diagnosis with a compatible uveitis was labeled as definite ocular sarcoidosis. If biopsy was not performed but chest the radiograph was positive, showing BHL associated with a compatible uveitis, the condition was labeled as presumed ocular sarcoidosis. If biopsy was not performed and the chest radiograph did not show BHL but there were 3 intraocular signs and 2 positive laboratory tests, the condition was labeled as probable ocular sarcoidosis. If lung biopsy was performed and the result was negative but at least 4 signs and 2 positive laboratory investigations were present, the condition was labeled as possible ocular sarcoidosis. The consensus conference identified the following 7 signs in the diagnosis of intraocular sarcoidosis (**Herbort 2009**): Mutton-fat keratic precipitates (KPs)/small granulomatous KPs and/or iris nodules (Koeppe/Busacca), Trabecular meshwork (TM) nodules and/or tent-shaped peripheral anterior synechiae (PAS), Vitreous opacities displaying snowballs/strings of pearls, multiple chorioretinal peripheral lesions (active and/or atrophic), nodular and/or segmental peri-phlebitis (+/- candlewax drippings) and/or retinal macroaneurysm in an inflamed eye, optic disc nodule(s)/granuloma(s) and/or solitary choroidal nodule and bilaterality.

The laboratory investigations or investigational procedures judged to provide value in the diagnosis of ocular sarcoidosis in patients having the above intraocular signs included the following (**Herbort 2009**): Negative tuberculin skin test in a BCG-vaccinated patient or in a patient having had a positive tuberculin skin test previously, elevated serum angiotensin-converting enzyme (ACE) levels and/or elevated serum lysozyme, Chest radiograph revealing BH, abnormal liver enzyme tests, Chest CT scan in patients with a negative chest radiograph result and ocular involvement may lead to blindness if untreated.

Cardiac manifestations

Heart block and sudden death may occur. The incidence rate of ventricular tachyarrhythmias requiring implantable cardioverter-defibrillator therapy is estimated to be 15% per year in those patients with cardiac involvement. Prophylactic implantable cardioverter-defibrillator implantation should be considered in patients with cardiac sarcoidosis (**Betensky 2012**). Corticosteroid therapy may be effective for ventricular arrhythmias in the early stage, but it is less effective in the late stage (**Yodogawa 2011**).

In one study, 90.4% of ECGs in cardiac sarcoidosis patients contained at least fragmented QRS or a BBB, compared with 36.7% of noncardiac CS patients. If patients with sarcoidosis have these ECG findings, further workup is indicated. The Japanese Ministry of Health and Welfare has used a RBBB and advanced AV block as 2 of the clinical diagnostic criteria used for diagnosis of CS (**Schuller 2011**).

The diagnosis of cardiac involvement in systemic sarcoidosis has improved with the development of CMRI. Both plasma A-type natriuretic peptide (ANP) and B-type natriuretic peptide (BNP) can be elevated in CS (**Yasutake 2005**).

Approximately 25% of patients may have NCGs at autopsy, but less than 5% have clinical cardiac disease.

Modified Japanese Ministry of Health and Welfare guidelines for diagnosing CS (**Hiraga 1993**).

- Histologic diagnosis group: endomyocardial biopsy demonstrates epithelioid granulomata without caseating granulomata.
- Clinical diagnosis group: in patients with histologic diagnosis of extracardiac sarcoidosis, CS is suspected when ‘a’ and at least one of criteria ‘b’ to ‘d’ is present, and other etiologies such as hypertension and coronary artery disease have been excluded: a) CRBBB, LBBB, left-axis deviation, AV block, VT, PVCs or pathological Q- or ST-T change on resting, or ambulatory ECG. b) Abnormal wall motion, regional wall thinning, or dilation of the LV. c) Perfusion defect by ²⁰¹thallium-myocardial scintigraphy or abnormal accumulation by ⁶⁷Ga-citrate or ^{99m}Tc-PYP myocardial scintigraphy. d) Abnormal intracardiac pressure, low cardiac output, or abnormal wall motion or depressed LVEF.

References

1. Adler A, Perrin MJ, Spears D, Gollob MH. Epsilon wave uncovered by exercise test in a patient with desmoplakin-positive arrhythmogenic right ventricular cardiomyopathy. *Can J Cardiol*. 2015;31(6):819.e1-2.
2. An HB, Li YY. Epsilon waves seen in a patient with typical electrocardiography pattern of Brugada. *Zhonghua Xin Xue Guan Bing Za Zhi*. 2008;36(2):166.
3. Andreou AY. Epsilon waves in right ventricular myocardial infarction. *Tex Heart Inst J*. 2012;39(2):306.
4. Arai Y, Saul JP, Albrecht P, et al. Modulation of cardiac autonomic activity during and immediately after exercise. *Am J Physiol*. 1989;256(1 Pt 2):H132-41.
5. Baltzan M, Mehta S, Kirkham TH, Cosio MG. Randomized trial of prolonged chloroquine therapy in advanced pulmonary sarcoidosis. *Am J Respir Crit Care Med*. 1999;160(1):192-7.
6. Basso C, Thiene G, Corrado D, Angelini A, Nava A, Valente M. Arrhythmogenic right ventricular cardiomyopathy. Dysplasia, dystrophy, or myocarditis? *Circulation*. 1996;94(5):983-91.
7. Batchvarov VN, Bastiaenen R, Postema PG, Clark EN, Macfarlane PW, Wilde AA, Behr ER. Novel electrocardiographic criteria for the diagnosis of arrhythmogenic right ventricular cardiomyopathy. *Europace*. 2015 Nov 29. pii: euv379. [Epub ahead of print]
8. Baucé B, Basso C, Nava A. Signal-averaged electrocardiographic parameter progression as a marker of increased electrical instability in two cases with an overt form of arrhythmogenic right ventricular cardiomyopathy. *Pacing Clin Electrophysiol*. 2002;25(3):362-4.
9. Baughman RP, Judson MA, Teirstein AS, Moller DR, Lower EE. Thalidomide for chronic sarcoidosis. *Chest*. 2002;122(1):227-32.
10. Berlin M, Fogdell-Hahn A, Olerup O, Eklund A, Grunewald J. HLA-DR predicts the prognosis in Scandinavian patients with pulmonary sarcoidosis. *Am J Respir Crit Care Med* 1997; 156(5):1601-5.
11. Betensky BP, Tschabrunn CM, Zado ES, et al. Long-term follow-up of patients with cardiac sarcoidosis and implantable cardioverter-defibrillators. *Heart Rhythm*. 2012;9(6):884-91.
12. Bogunia-Kubik K, Tomeczko J, Suchnicki K, Lange A. HLA-DRB1*03, DRB1*11 or DRB1*12 and their respective DRB3 specificities in clinical variants of sarcoidosis. *Tissue Antigens*. 2001;57(1):87-90.
13. Brewerton DA, Cockburn C, James DC, James DG, Neville E. HLA antigens in sarcoidosis. *Clin Exp Immunol* 1977;27(2):227-9.
14. Calore C, Zorzi A, Sheikh N, et al. Electrocardiographic anterior T-wave inversion in athletes of different ethnicities: differential diagnosis between athlete's heart and cardiomyopathy. *Eur Heart J*. 2015 Nov 17. pii: ehv591. [Epub ahead of print]

15. Canpolat U, Kabakçi G, Aytemir K, et al. Fragmented QRS complex predicts the arrhythmic events in patients with arrhythmogenic right ventricular cardiomyopathy/dysplasia. *J Cardiovasc Electrophysiol*. 2013;24(11):1260-6.
16. Capulzini L, Brugada P, Brugada J, Brugada R. Arrhythmia and right heart disease: from genetic basis to clinical practice. *Rev Esp Cardiol*. 2010;63(8):963-83.
17. Cerqueira MD, Weissman NJ, Dilsizian V, et al. AHA Writing Group on Myocardial Segmentation and Registration for Cardiac Imaging. Standardized myocardial segmentation and nomenclature for tomographic imaging of the heart. *Circulation* 2002;105(4):539–42.
18. Chapelon-Abrie C, de Zuttere D, Duhaut P, et al. Cardiac sarcoidosis: a retrospective study of 41 cases. *Medicine (Baltimore)* 2004;83(6):315–34.
19. Chiladakis JI, Zagli F, Karantalis V, Alexopoulos D. New diagnosis of arrhythmogenic right ventricular cardiomyopathy in an octogenarian with the help of Fontaine electrocardiographic leads. *Europace*. 2010;12(8):1197-8.
20. Coonar AS, Protonotarios N, Tsatsopoulou A, et al. Gene for arrhythmogenic right ventricular cardiomyopathy with diffuse nonepidermolytic palmoplantar keratoderma and woolly hair (Naxos disease) maps to 17q21. *Circulation*. 1998;97(20):2049-58.
21. Côté M, Davignon A, Fouron JC. Congenital hypoplasia of right ventricular myocardium (Uhl's anomaly) associated with pulmonary atresia in a newborn. *Am J Cardiol*. 1973;31(5):658-61.
22. Cox CE, Davis-Allen A, Judson MA. Sarcoidosis. *Med Clin North Am*. 2005;89(4):817-28.
23. Demeter SL. Myocardial sarcoidosis unresponsive to steroids. Treatment with cyclophosphamide. *Chest*. 1988;94(1):202-3.
24. Deng JC, Baughman RP, Lynch JP. Cardiac involvement in sarcoidosis. *Semin Resp Crit Care Med*. 2002;23(6):513–27.
25. Digglemann U, Baur HR. Familial Uhl's anomaly in the adult. *Am J Cardiol*. 1984;53(9):1402-3.
26. Doppalapudi H, Yamada T, Ramaswamy K, Ahn J, Kay GN. Idiopathic focal epicardial ventricular tachycardia originating from the crux of the heart. *Heart Rhythm*. 2009;6(1):44-50.
27. Doty JD, Mazur JE, Judson MA. Treatment of corticosteroid-resistant neurosarcoidosis with a short-course cyclophosphamide regimen. *Chest*. 2003;124(5):2023-6.
28. Doty JD, Mazur JE, Judson MA. Treatment of sarcoidosis with infliximab. *Chest*. 2005;127(3):1064-71.
29. Drory Y, Deutsch V, Shem-Tov A, Feldman S, Kariv I. Hypoplasia of the right ventricular myocardium (Uhl's disease). Report of a case with review of the literature. *G Ital Cardiol*. 1977;7(1):89-94.
30. Facco M, Cabrelle A, Teramo A, et al. Sarcoidosis is a Th1/Th17 multisystem disorder. *Thorax*. 2011;66(2):144-50.

31. Fahy GJ, Marwick T, McCreery CJ, Quigley PJ, Maurer BJ. Doppler echocardiographic detection of left ventricular diastolic dysfunction in patients with pulmonary sarcoidosis. *Chest* 1996;109(1):62-6.
32. Fauchier JP, Fauchier L, Babuty D, Cosnay P. Time-domain signal-averaged electrocardiogram in nonischemic ventricular tachycardia. *Pacing Clin Electrophysiol.* 1996 Feb;19(2):231-44
33. Fazzi P, Manni E, Cristofani R, et al. Thalidomide for improving cutaneous and pulmonary sarcoidosis in patients resistant or with contraindications to corticosteroids. *Biomed Pharmacother.* 2012;66(4):300-7.
34. Fischer A, Rybicki BA. Granuloma genes in sarcoidosis: what is new? *Curr Opin Pulm Med.* 2015;21(5):510-6.
35. Fontaine G, Frank R, Gallais-Hamonno F, et al. Electrocardiography of delayed potentials in post-excitation syndrome. *Arch Mal Coeur Vaiss.* 1978;71(8):854-64.
36. Fontaine G, Guiraudon G, Frank R, et al. Arrhythmogenic right ventricular dysplasia and Uhl's disease. *Arch Mal Coeur Vaiss.* 1982;75(4):361-71.
37. Fontaine G, Frank R, Tonet JL, et al. Arrhythmogenic right ventricular dysplasia: a clinical model for the study of chronic ventricular tachycardia. *Jpn Circ J.* 1984 Jun;48(6):515-38.
38. Fontaine G, Tsezana R, Lazarus A, Lascault G, Tonet J, Frank R. Repolarization and intraventricular conduction disorders in arrhythmogenic right ventricular dysplasia. *Ann Cardiol Angeiol (Paris).* 1994;43(1):5-10.
39. Fontaine G, Fontaliran F, Hébert JL, et al. Arrhythmogenic right ventricular dysplasia. *Annu Rev Med.* 1999; 50:17-35.
40. Frank R, Fontaine G, Vedel J, Mialet G, Sol C, Guiraudon G, Grosgeat Y. Electrocardiology of 4 cases of right ventricular dysplasia inducing arrhythmia.. *Arch Mal Coeur Vaiss.* 1978;71(9):963-72
41. Fuertes J, Salazar J, Mengual J, et al. Uhl's anomaly associated with atresia of the pulmonary valve. *Pediatric.* 1984;39(3):213-7.
42. Galvão Braga C, Silva P, Salgado A, Magalhães S, Themudo R. Isolated left ventricular arrhythmogenic dysplasia. *Eur Heart J Cardiovasc Imaging.* 2014;15(8):907.
43. Gardner J, Kennedy HG, Hamblin A, Jones E. HLA associations in sarcoidosis: a study of two ethnic groups. 1984;39(1):19-22.
44. George BA, Ko JM, Lensing FD, Kuiper JJ, Roberts WC. "Repaired" tetralogy of Fallot mimicking arrhythmogenic right ventricular cardiomyopathy (another phenocopy). *Am J Cardiol.* 2011;108(2):326-9.
45. Gerlis LM, Schmidt-Ott SC, Ho SY, Anderson RH. Dysplastic conditions of the right ventricular myocardium: Uhl's anomaly vs arrhythmogenic right ventricular dysplasia. *Br Heart J.* 1993;69(2):142-50.
46. Gibbons WJ, Levy RD, Nava S, et al. Subclinical cardiac dysfunction in sarcoidosis. *Chest* 1991;100(1):44-50.

47. Gong B, Li Z. Total Mortality, Major Adverse Cardiac Events, and Echocardiographic-Derived Cardiac Parameters with Fragmented QRS Complex. *Ann Noninvasive Electrocardiol.* 2016;21(4):404-12.
48. Gottschalk B, Gysel M, Barbosa-Barros R, De Sousa Rocha RP, Pérez-Riera AR, Zhang L, Fontaine G, Baranchuk A. The use of fontaine leads in the diagnosis of arrhythmogenic right ventricular dysplasia. *Ann Noninvasive Electrocardiol.* 2014;19(3):279-84.
49. Gregor P. Electrocardiography in cardiomyopathies. *Vnitr Lek.* 2003; 49 (9):727-9.
50. Grozdic Milojevic I, Sobic-Saranovic D, Videnovic-Ivanov J, Saranovic D, Odalovic S, Artiko V. FDG PET/CT in bone sarcoidosis. *Sarcoidosis Vasc Diffuse Lung Dis.* 2016;33(1):66-74.
51. Hedfors E, Lindstrom F. HLA-B8/DR3 in sarcoidosis: correlation to acute onset disease with arthritis. *Tissue Antigens* 1983;22(3):200-3.
52. Herbort CP, Rao NA, Mochizuki M. International criteria for the diagnosis of ocular sarcoidosis: results of the first International Workshop On Ocular Sarcoidosis (IWOS). *Ocul Immunol Inflamm.* 2009;17(3):160-9.
53. Hiraga H, Yuwai K, Hiroe M, et al. Guideline for the Diagnosis of Cardiac Sarcoidosis Study Report on Diffuse Pulmonary Diseases. Tokyo: Japanese Ministry of Health and Welfare; 1993. P. 23–24.
54. Hoback J, Adcoff A, From AHL, Smith M, Shafer R, Chesler E. A report of Uhl's disease in identical twins: evaluation of right ventricular dysfunction with echocardiography and nuclear angiography. *Chest.* 1981;79(3):306-10.
55. Hoogendijk MG. Diagnostic dilemmas: overlapping features of Brugada syndrome and arrhythmogenic right ventricular cardiomyopathy. *Front Physiol.* 2012;3:144.
56. Hunninghake GW, Crystal RG. Mechanisms of hypergammaglobulinemia in pulmonary sarcoidosis. Site of increased antibody production and role of T lymphocytes. *J Clin Invest.* 1981;67(1):86-92.
57. Hurst JW. Naming of the waves in the ECG, with a brief account of their genesis. *Circulation.* 1998;98(18):1937-42.
58. Hurst JW. Comments about the electrocardiographic signs of right ventricular infarction. *Clin Cardiol* 1998;21(4):289–91.
59. Iakovtsova AF, Bruk BM, Zakrevskii VN, Sorokina IV. Myocardial hypoplasia of the right heart ventricle (Uhl's anomaly). *Arkh Patol.* 1989;51(9):69-71.
60. Iannuzzi MC, Maliarik MJ, Poisson LM, Rybicki BA. Sarcoidosis susceptibility and resistance HLA-DQB1 alleles in African Americans. 2003;167(9):1225-31.
61. James DG, Williams WJ. Kveim-Siltzbach test revisited. *Sarcoidosis.* 1991;8(1):6-9.
62. Jannette Collins, Eric J. Stern. In: *Chest radiology. The essentials.* Wolters Kluwer Health/Lippincott Williams & Wilkins, Philadelphia; 2007.

63. Jaoude Leclercq JF, Coumel P. Progressive ECG changes in arrhythmogenic right ventricular disease. Evidence for an evolving disease. *Eur Heart J*. 1996;17(11):1717-22.
64. Jongman JK, Zaidi A, Muggenthaler M, Sharma S. Relationship between echocardiographic right-ventricular dimensions and signal-averaged electrocardiogram abnormalities in endurance athletes. *Europace*. 2015;17(9):1441-8.
65. Jordan HT, Stellman SD, Prezant D, Teirstein A, Osahan SS, Cone JE. Sarcoidosis diagnosed after September 11, 2001, among adults exposed to the World Trade Center disaster. *J Occup Environ Med*. 2011;53(9):966-74.
66. Kanazawa N, Okafuji I, Kambe N, et al. Early-onset sarcoidosis and CARD15 mutations with constitutive nuclear factor-kappaB activation: common genetic etiology with Blau syndrome. *Blood*. 2005;105(3):1195-7.
67. Kandolin R, Lehtonen J, Graner M, et al. Diagnosing isolated cardiac sarcoidosis. *J Intern Med* 2001;270(5):461–8.
68. Kataria YP. Chlorambucil in sarcoidosis. *Chest*. 1980;78(1):36-43.
69. Kawamura M, Gerstenfeld EP, Vedantham V, et al. Idiopathic ventricular arrhythmia originating from the cardiac crux or inferior septum: epicardial idiopathic ventricular arrhythmia. *Circ Arrhythm Electrophysiol*. 2014;7(6):1152-8.
70. Kazmierczak J, De Sutter J, Tavernier R, Cuvelier C, Dimmer C, Jordaens L. Electrocardiographic and morphometric features in patients with ventricular tachycardia of right ventricular origin. *Heart*. 1998;79(4):388-93.
71. Khaji A, Zhang J, Kowey P, Martinez-Lage M, Kocovic D. Mega-epsilon waves on 12-lead ECG--just another case of arrhythmogenic right ventricular dysplasia/cardiomyopathy? *Electrocardiol*. 2013;46(6):524-7.
72. Kilinc M, Akdemir I, Sivasli E. A case with Uhl's anomaly presenting with severe right heart failure. *Acta Cardiol*. 2000;55(6):367-9.
73. Kinoshita O, Fontaine G, Rosas F, et al. Time- and frequency-domain analyses of the signal-averaged ECG in patients with arrhythmogenic right ventricular dysplasia. *Circulation*. 1995;91(3):715-21.
74. Kisacik HL, Ozdemir K, Altunkeser B, Oğuzhan A, Göksel S. UHL's anomaly. *Jpn Heart J*. 1999;40(4):503-7.
75. Kojima K, Maruyama K, Inaba T, et al. The CD4/CD8 ratio in vitreous fluid is of high diagnostic value in sarcoidosis. *Ophthalmology*. 2012;119(11):2386-92.
76. Koplan BA, Soejima K, Baughman K, Epstein LM, Stevenson WG. Refractory ventricular tachycardia secondary to cardiac sarcoid: electrophysiologic characteristics, mapping, and ablation. *Heart Rhythm*. 2006;3(8):924-9.
77. Krell W, Bourbonnais JM, Kapoor R, Samavati L. Effect of smoking and gender on pulmonary function and clinical features in sarcoidosis. *Lung*. 2012;190(5):529-36.

78. Kriebel T, Korte T, Kandolf R, et al. Arrhythmogenic right ventricular dysplasia/cardiomyopathy - diagnosis in childhood. *Z Kardiol.* 2003;92(5):418-24.
79. Kukla P, Jastrzębski M, Kurdzielewicz W. Higher right precordial leads and Fontaine leads: the better detection of QRS fragmentation and epsilon wave in arrhythmogenic right ventricular dysplasia-cardiomyopathy. *Kardiol Pol.* 2012;70(9):958-9.
80. Kusano KF, Satomi K. Diagnosis and treatment of cardiac sarcoidosis. *Heart.* 2016;102(3):184-90.
81. Larroussi L, Badhwar N. Ventricular Tachycardia Arising from Cardiac Crux: Electrocardiogram Recognition and Site of Ablation. *Card Electrophysiol Clin.* 2016;8(1):109-13.
82. Letsas KP, Efremidis M, Weber R, et al. Epsilon-like waves and ventricular conduction abnormalities in subjects with type 1 ECG pattern of Brugada syndrome. *Heart Rhythm.* 2011;8(6):874-8.
83. Liao YC, Lin YJ, Chung FP, Chang SL. Risk stratification of arrhythmogenic right ventricular cardiomyopathy based on signal averaged electrocardiograms. *Int J Cardiol.* 2014;174(3):628-33.
84. Loire R, Tabib A. Arrhythmogenic right ventricular dysplasia and Uhl disease. Anatomic study of 100 cases after sudden death. *Ann Pathol.* 1998;18(3):165-71.
85. Löllgen H. The ECG of athletes. *Herzschrittmacherther Elektrophysiol.* 2015;26(3):274-90.
86. Luders H, Luders P. Uhl's anomaly of the heart. *Zentralbl Allg Pathol.* 1988;134(8):727-30.
87. Maia IG, Sá R, Bassan R, et al. Arrhythmogenic right ventricular dysplasia. *Arq Bras Cardiol.* 1991;57(2):97-102.
88. Maliarik MJ, Chen KM, Major ML, Sheffer RG, Popovich J Jr, Rybicki BA, Iannuzzi MC. Analysis of HLA-DPB1 polymorphisms in African-Americans with sarcoidosis. 1998;158(1):111-4.
89. Macarie C, Stoian I, Dermengiu D, et al. The electrocardiographic abnormalities in highly trained athletes compared to the genetic study related to causes of unexpected sudden cardiac death. *J Med Life.* 2009;2(4):361-72.
90. McKenna WJ, Thiene G, Nava A, et al. Diagnosis of arrhythmogenic right ventricular dysplasia/cardiomyopathy. Task Force of the Working Group Myocardial and Pericardial Disease of the European Society of Cardiology and of the Scientific Council on Cardiomyopathies of the International Society and Federation of Cardiology. *Br Heart J.* 1994;71(3):215-8.
91. Mancini DM, Wong KL, Simson MB. Prognostic value of an abnormal signal-averaged electrocardiogram in patients with nonischemic congestive cardiomyopathy. *Circulation.* 1993;87(4):1083-92.
92. Marcus FI, Fontaine GH, Guiraudon G, et al. Right ventricular dysplasia: A report of 24 adult cases. *Circulation.* 1982;65:384-98.
93. Marcus FI. Guy Fontaine: a pioneer in electrophysiology. *Clin Cardiol.* 1998; 21(2):145-6.

94. Marcus FI, Zareba W. The electrocardiogram in right ventricular cardiomyopathy/dysplasia. How can the electrocardiogram assist in understanding the pathologic and functional changes of the heart in this disease? *J Electrocardiol.* 2009;42(2):136.e1-5.
95. Marcus FI, McKenna WJ, Sherrill Detal. Diagnosis of arrhythmogenic right ventricular cardiomyopathy/dysplasia Proposed modification of the task force criteria. *Eur Heart J.* 2010; 31:806–14.
96. Marcus FI. Epsilon Waves Aid in the Prognosis and Risk Stratification of Patients With ARVC/D. *J Cardiovasc Electrophysiol.* 2015. doi: 10.1111/jce.12775. [Epub ahead of print]
97. Martinetti M, Tinelli C, Kolek V, et al. “The sarcoidosis map”: a joint survey of clinical and immunogenetic findings in two European countries. *Am J Respir Crit Care Med* 1995;152(2):557-64.
98. Mast TP, Teske AJ, vd Heijden JF, et al. Left Ventricular Involvement in Arrhythmogenic Right Ventricular Dysplasia/Cardiomyopathy Assessed by Echocardiography Predicts Adverse Clinical Outcome. *J Am Soc Echocardiogr.* 2015 ;28(9):1103-13.
99. Mehta D, Goldman M, David O, Gomes JA. Value of quantitative measurement of signal-averaged electrocardiographic variables in arrhythmogenic right ventricular dysplasia: correlation with echocardiographic right ventricular cavity dimensions. *J Am Coll Cardiol.* 1996;28(3):713-9.
100. Miller BH, Rosado-de-Christenson ML, McAdams HP, Fishback NF. Thoracic sarcoidosis: radiologic-pathologic correlation. *Radiographics.* 1995;15(2):421-37.
101. Miyoshi S, Hamada H, Kadowaki T, et al. Comparative evaluation of serum markers in pulmonary sarcoidosis. *Chest.* 2010;137(6):1391-7.
102. Morimoto T, Azuma A, Abe S, et al. Epidemiology of sarcoidosis in Japan. *Eur Respir J.* 2008;31(2):372–9.
103. Morita H, Kusano KF, Miura D, et al. Fragmented QRS as a marker of conduction abnormality and a predictor of prognosis of Brugada syndrome. *Circulation.* 2008;118(17):1697–704.
104. Mota PC, Morais A, Palmares C, et al. Diagnostic value of CD103 expression in bronchoalveolar lymphocytes in sarcoidosis. *Respir Med.* 2012;106(7):1014-20.
105. Muller-Quernheim J, Kienast K, Held M, Pfeifer S, Costabel U. Treatment of chronic sarcoidosis with an azathioprine/prednisolone regimen. *Eur Respir J.* 1999;14(5):1117-22.
106. Nagao S, Watanabe H, Sobue Y, et al. Electrocardiographic abnormalities and risk of developing cardiac events in extracardiac sarcoidosis. *Int J Cardiol.* 2015;189:1-5.
107. Nardi A, Brillet PY, Letoumelin P, et al. Stage IV sarcoidosis: comparison of survival with the general population and causes of death. *Eur Respir J.* 2011;38(6):1368-73.

- 108.Nasir K, Rutberg J, Tandri H, Berger R, Tomaselli G, Calkins H. Utility of SAECG in arrhythmogenic right ventricle dysplasia. *Ann Noninvasive Electrocardiol.* 2003;8(2):112-20.
- 109.Nasir K, Tandri H, Rutberg J, et al. Filtered QRS duration on signal-averaged electrocardiography predicts inducibility of ventricular tachycardia in arrhythmogenic right ventricle dysplasia. *Pacing Clin Electrophysiol.* 2003;26(10):1955-60.
- 110.Nasir K, Bomma C, Tandri H, Roguin A, Dalal D, Prakasa K, Tichnell C, James C, Spevak PJ, Marcus F, Calkins H. Electrocardiographic features of arrhythmogenic right ventricular dysplasia/cardiomyopathy according to disease severity: a need to broaden diagnostic criteria. *Circulation.* 2004;110(12):1527-34.
- 111.Nathan SD. Lung transplantation: disease-specific considerations for referral. *Chest.* 2005;127(3):1006-16.
- 112.Nava A, Folino AF, Bauce B, et al. Signal-averaged electrocardiogram in patients with arrhythmogenic right ventricular cardiomyopathy and ventricular arrhythmias. *Eur Heart J.* 2000;21(1):58-65.
- 113.Nitoiu D, Etheridge SL, Kelsell DP. Insights into desmosome biology from inherited human skin disease and cardiocutaneous syndromes. *Cell Commun Adhes.* 2014;21(3):129-40.
- 114.Numao Y, Sekiguchi M, Fruie T, et al. A study of cardiac involvement in 963 cases of sarcoidosis by ECG and endomyocardial biopsy. *Ann NY Acad Sci* 1976;76:607-614.
- 115.Obma R, Perry LW, Scott LP. Uhl's anomaly of the heart with atrial septal defect and valvular pulmonary stenosis. *Med Ann District Columbia.* 1974;43(8):413-8.
- 116.Ogisu N, Sato S, Kawaguchi H, et al. Elevated level of soluble HLA class I antigens in serum and bronchoalveolar lavage fluid in patients with sarcoidosis. *Intern Med.* 2001;40(3):201-7.
- 117.Okano Y. Electrocardiographic findings in arrhythmogenic right ventricular dysplasia (ARVD) evaluated by body surface mapping. *Nihon Rinsho.* 1995;53(1):230-8.
- 118.Oselladore L, Nava A, Buja G, et al. Signal-averaged electrocardiography in familial form of arrhythmogenic right ventricular cardiomyopathy. *Am J Cardiol.* 1995;75(15):1038-41.
- 119.Ozeke O, Cavus UY, Atar I, Ozin B, Ilkay E. Epsilon-like electrocardiographic pattern in a patient with Brugada syndrome. *Ann Noninvasive Electrocardiol.* 2009;14(3):305-8.
- 120.Platonov PG, Calkins H, Hauer RN, et al. High interobserver variability in the assessment of epsilon waves: Implications for diagnosis of arrhythmogenic right ventricular cardiomyopathy/dysplasia. *Heart Rhythm.* 2016;13(1):208-16.

- 121.Perrin MJ, Angaran P, Laksman Z, et al. Exercise testing in asymptomatic gene carriers exposes a latent electrical substrate of arrhythmogenic right ventricular cardiomyopathy. J Am Coll Cardiol. 2013;62(19):1772-9.
- 122.Peters S, Peters H, Thierfelder L. Risk stratification of sudden cardiac death and malignant ventricular arrhythmias in right ventricular dysplasia-cardiomyopathy. Int J Cardiol. 1999;71:243–50.
- 123.Peters S, Trümmel M Diagnosis of arrhythmogenic right ventricular dysplasia-cardiomyopathy: value of standard ECG revisited. Ann Noninvasive Electrocardiol. 2003;8(3):238-45.
- 124.Peters S, Trümmel M, Koehler B, Westermann KU. The value of different electrocardiographic depolarization criteria in the diagnosis of arrhythmogenic right ventricular dysplasia/cardiomyopathy. J Electrocardiol. 2007;40(1):34-7.
- 125.Peters S, Truempel M, Koehler B. Prognostic value of QRS fragmentation in patients with arrhythmogenic right ventricular cardiomyopathy/dysplasia.. J Cardiovasc Med (Hagerstown). 2012;13(5):295-8
- 126.Peters S. QRS fragmentation in patients with arrhythmogenic right ventricular cardiomyopathy and complete right bundle branch block: a risk stratification. Eur Heart J Acute Cardiovasc Care. 2012;1(3):236-9.
- 127.Peters S. QRS fragmentation and epsilon waves in Fontaine leads in arrhythmogenic right ventricular cardiomyopathy: re: "The use of fontaine leads in the diagnosis of arrhythmogenic right ventricular dysplasia" and "Arrhythmogenic right ventricular cardiomyopathy: contribution of different electrocardiographic techniques". Int J Cardiol. 2014;176(3):1015-6.
- 128.Peters S. Electrocardiographic characteristics of arrhythmogenic right ventricular dysplasia, cardiac sarcoidosis and arrhythmogenic biventricular cardiomyopathy. Int J Cardiol. 2015;196:38-41.
- 129.Protonotarios A, Anastasakis A, Tsatsopoulou A, et al. Clinical Significance of Epsilon Waves in Arrhythmogenic Cardiomyopathy. J Cardiovasc Electrophysiol. 2015. doi: 10.1111/jce.12755. [Epub ahead of print]
- 130.Rybicki BA, Iannuzzi MC, Frederick MM, et al. Familial aggregation of sarcoidosis: a Case-Control Etiologic Study of Sarcoidosis (ACCESS). Am J Respir Crit Care Med. 2001;164(11):2085–91.Rossman MD, Thompson B, Frederick M, *et al.* HLA-DRB1*1101: a significant risk factor for sarcoidosis in blacks and whites. 2003;73(4):720-35.
- 131.Platonov PG, Calkins H, Hauer RN, et al. High interobserver variability in the assessment of epsilon waves: Implications for diagnosis of arrhythmogenic right ventricular cardiomyopathy/dysplasia. Heart Rhythm. 2016;13(1):208-16
- 132.Perrin MJ, Angaran P, Laksman Z, et al. Exercise testing in asymptomatic gene carriers exposes a latent electrical substrate of arrhythmogenic right ventricular cardiomyopathy. J Am Coll Cardiol. 2013;62(19):1772-9.

- 133.Peters S, Peters H, Thierfelder L. Risk stratification of sudden cardiac death and malignant ventricular arrhythmias in right ventricular dysplasia-cardiomyopathy. *Int J Cardiol.* 1999;71:243–50.
- 134.Peters S, Trümmel M Diagnosis of arrhythmogenic right ventricular dysplasia-cardiomyopathy: value of standard ECG revisited. *Ann Noninvasive Electrocardiol.* 2003;8(3):238-45.
- 135.Peters S, Trümmel M, Koehler B, Westermann KU. The value of different electrocardiographic depolarization criteria in the diagnosis of arrhythmogenic right ventricular dysplasia/cardiomyopathy. *J Electrocardiol.* 2007;40(1):34-7.
- 136.Platonov PG, Calkins H, Hauer RN, et al. High interobserver variability in the assessment of epsilon waves: Implications for diagnosis of arrhythmogenic right ventricular cardiomyopathy/dysplasia. *Heart Rhythm.* 2016;13(1):208-16
- 137.Perrin MJ, Angaran P, Laksman Z, et al. Exercise testing in asymptomatic gene carriers exposes a latent electrical substrate of arrhythmogenic right ventricular cardiomyopathy. *J Am Coll Cardiol.* 2013;62(19):1772-9.
- 138.Peters S, Peters H, Thierfelder L. Risk stratification of sudden cardiac death and malignant ventricular arrhythmias in right ventricular dysplasia-cardiomyopathy. *Int J Cardiol.* 1999;71:243–50.
- 139.Peters S, Trümmel M Diagnosis of arrhythmogenic right ventricular dysplasia-cardiomyopathy: value of standard ECG revisited. *Ann Noninvasive Electrocardiol.* 2003;8(3):238-45.
- 140.Peters S, Trümmel M, Koehler B, Westermann KU. The value of different electrocardiographic depolarization criteria in the diagnosis of arrhythmogenic right ventricular dysplasia/cardiomyopathy. *J Electrocardiol.* 2007;40(1):34-7.
- 141.Russell E, Luk F, Manocha S, Ho T, O'Connor C, Hussain H. Long term follow-up of infliximab efficacy in pulmonary and extra-pulmonary sarcoidosis refractory to conventional therapy. *Semin Arthritis Rheum.* 2013;43(1):119-24.
- 142.Saguner AM, Ganahl S, Baldinger SH, et al. Usefulness of electrocardiographic parameters for risk prediction in arrhythmogenic right ventricular dysplasia. *Am J Cardiol.* 2014;113(10):1728-34.
- 143.Schuller JL, Olson MD, Zipse MM, et al. Electrocardiographic characteristics in patients with pulmonary sarcoidosis indicating cardiac involvement. *J Cardiovasc Electrophysiol.* 2011;22(11):1243-8.
- 144.Sekiguchi M, Yazaki Y, Isobe M, Hiroe M. Cardiac sarcoidosis: diagnostic, prognostic and therapeutic considerations. *Cardiovasc Drugs Ther.* 1996;10(5):495–510.
- 145.Sekiguchi K, Miya Y, Kaneko Y, et al. Evaluation of signal-averaged electrocardiography for clinical diagnosis in arrhythmogenic right ventricular dysplasia. *Jpn Heart J.* 2001;42(3):287-94.

- 146.Sen-Chowdhry S, Syrris P, Ward D, Asimaki A, Sevdalis E, McKenna WJ. Clinical and genetic characterization of families with arrhythmogenic right ventricular dysplasia/cardiomyopathy provides novel insights into patterns of disease expression. *Circulation*. 2007;115(13):1710–20.
- 147.Shetler K, Marcus R, Froelicher VF, et al. Heart rate recovery: validation and methodologic issues. *J Am Coll Cardiol*. 2001;38(7):1980-7.
- 148.Silverman KJ, Hutchins GM, Bulkley BH. Cardiac sarcoid: a clinicopathologic study of 84 unselected patients with systemic sarcoidosis. *Circulation*. 1978;58(6):1204-11.
- 149.Sobue Y, Harada M, Koshikawa M1, et al. QRS-based assessment of myocardial damage and adverse events associated with cardiac sarcoidosis. *Heart Rhythm*. 2015;12(12):2499-507.
- 150.Stein E, Jackler I, Stimmel G, Stein W, Siltzbach LE. Asymptomatic electrocardiographic alterations in sarcoidosis. *Am Heart J*. 1973;86(4):474-7.
- 151.Steriotis AK, Baucé B, Daliento L, et al. Electrocardiographic pattern in arrhythmogenic right ventricular cardiomyopathy. *Am J Cardiol*. 2009;103(9):1302–8.
- 152.Sultan A, Lüker J, Willems S, Steven D. [Ablation of an idiopathic "ventricular rarity"--ventricular tachycardia originating from the crux cordis]. *Dtsch Med Wochenschr*. 2014;139(39):1929-31.
- 153.Surawicz B, Knilans TK. Chou's Electrocardiography in clinical practice. Adult and pediatric. Fifth Edition. 2001. Chapter 12. pp 263. WB Saunders Company.
- 154.Sutter A, Gujer HR. Left and right ventricular dysplasia and Uhl's anomaly. A case report. *Am J Forensic Med Pathol*. 1996;17(2):141-5.
- 155.Sverrild A, Backer V, Kyvik KO, Kaprio J, Milman N, Svendsen CB. Heredity in sarcoidosis: a registry-based twin study. *Thorax*. 2008;63(10):894-6.
- 156.Swigris JJ, Olson AL, Huie TJ, et al. Sarcoidosis-related mortality in the United States from 1988 to 2007. *Am Respir Crit Care Med*. 2011;183(11):1524–30.
- 157.Tabib A, Loire R. Anatomoclinical study of 100 cases of hypoplasia of the right ventricular muscle (including 89 unexpected sudden deaths). Relation with Uhl's anomaly. *Arch Mal Coeur Vaiss*. 1992;85(12):1789-95.
- 158.Takase H, Shimizu K, Yamada Y, Hanada A, Takahashi H, Mochizuki M. Validation of international criteria for the diagnosis of ocular sarcoidosis proposed by the first international workshop on ocular sarcoidosis. *Jpn J Ophthalmol*. 2010;54(6):529-36.
- 159.Tanawuttiwat T, Te Riele AS, Philips B, et al. Electroanatomic Correlates of Depolarization Abnormalities in Arrhythmogenic Right Ventricular Dysplasia/ Cardiomyopathy. *J Cardiovasc Electrophysiol*. 2016;27(4):443-52.

160. Tasaki M, Hattori N, Ihara D, et al. Case report: A case of Hodgkin lymphoma required a differential diagnosis from sarcoidosis due to elevated serum level of angiotensin converting enzyme (ACE). *Nihon Naika Gakkai Zasshi*. 2012;101(5):1401-3.
161. Ten Berge B, Kleinjan A, Muskens F, et al. Evidence for local dendritic cell activation in pulmonary sarcoidosis. *Respir Res*. 2012;13:33.
162. Thunéll M, Bjerle P, Stjernberg N. ECG abnormalities in patients with sarcoidosis. *Acta Med Scand* 1983;213(2):115-8.
163. Tokioka K, Kusano KF, Morita H, et al. Electrocardiographic parameters and fatal arrhythmic events in patients with Brugada syndrome: combination of depolarization and repolarization abnormalities. *J Am Coll Cardiol*. 2014;63(20):2131-8.
164. Tumbarello R, Adatia I, Yetman A, Boutin C, Izukawa T, Freedom RM. From functional pulmonary atresia to right ventricular restriction. Long term follow up of Uhl's anomaly. *Int J Cardiol*. 1998;67(2):161-4.
165. Uemura A, Morimoto S, Hiramitsu S, Kato Y, Ito T, Hishida H. Histologic diagnostic rate of cardiac sarcoidosis: Evaluation of endomyocardial biopsies. *Am Heart J* 1999;138(2 Pt 1):299–302.
166. Uhl HS. A previously undescribed congenital malformation of the heart: almost total absence of the myocardium of the right ventricle. *Bull Johns Hopkins Hosp*. 1952;91(3):197-209.
167. Valdivia CR, Medeiros-Domingo A, Ye B, Shen WK, Algiers TJ, Ackerman MJ, Makielski JC. Loss-of-function mutation of the SCN3B-encoded sodium channel $\beta 3$ subunit associated with a case of idiopathic ventricular fibrillation. *Cardiovasc Res*. 2010;86(3):392-400.
168. Varron L, Cottin V, Schott A, Broussolle C, Sève P. Late-onset sarcoidosis: a comparative study. *Medicine (Baltimore)*. 2012;91(3):137–43.
169. Vollmann D, Goette A, Kandolf R, Hasenfuss G. Epsilon waves in giant-cell myocarditis. *Eur Heart J*. 2014;35(1):9.
170. Voorter CE, Drent M, van den Berg-Loonen EM. Severe pulmonary sarcoidosis is strongly associated with the haplotype HLA-DQB1*0602-DRB1*150101. *Hum Immunol*. 2005;66(7):826-35.
171. Wang J, Yang B, Chen ML, et al. Prevalence of Epsilon wave in patients with arrhythmogenic right ventricular cardiomyopathy. *Zhonghua Xin Xue Guan Bing Za Zhi*. 2009;37(5):413-6.
172. Wang J, Yang B, Chen H, et al. Epsilon Waves Detected by Various Electrocardiographic Recording Methods in Patients with Arrhythmogenic Right Ventricular Cardiomyopathy *Tex Heart Inst J*. 2010; 37(4): 405–11.
173. Yasutake H, Seino Y, Kashiwagi M, Honma H, Matsuzaki T, Takano T. Detection of cardiac sarcoidosis using cardiac markers and myocardial integrated backscatter. *Int J Cardiol*. 2005;102(2):259-68.
174. Yee AM, Pochapin MB. Treatment of complicated sarcoidosis with infliximab anti-tumor necrosis factor-alpha therapy. *Ann Intern Med*. 2001;135(1):27-31.

- 176.Yodogawa K, Seino Y, Ohara T, Takayama H, Katoh T, Mizuno K. Effect of corticosteroid therapy on ventricular arrhythmias in patients with cardiac sarcoidosis. *Ann Noninvasive Electrocardiol.* 2011;16(2):140-7.
- 177.Yu J, Hu J, Dai X, et al. SCN5A mutation in Chinese patients with arrhythmogenic right ventricular dysplasia. *Herz.* 2014;39(2):271-5.
- 178.Zabel P, Entzian P, Dalhoff K, Schlaak M. Pentoxifylline in treatment of sarcoidosis. *Am J Respir Crit Care Med.* 1997;155(5):1665-9.
- 179.Zaidi A, Sheikh N, Jongman JK, et al. Clinical Differentiation Between Physiological Remodeling and Arrhythmogenic Right Ventricular Cardiomyopathy in Athletes With Marked Electrocardiographic Repolarization Anomalies. *J Am Coll Cardiol.* 2015;65(25):2702-11.
- 180.Zic JA, Horowitz DH, Arzubaga C, King LE Jr. Treatment of cutaneous sarcoidosis with chloroquine. Review of the literature. *Arch Dermatol.* 1991;127(7):1034-40.
- 181.Zorio E, Arnau MA, Rueda J, et al. The presence of epsilon waves in a patient with acute right ventricular infarction. *Pacing Clin Electrophysiol* 2005;28(3):245–7.