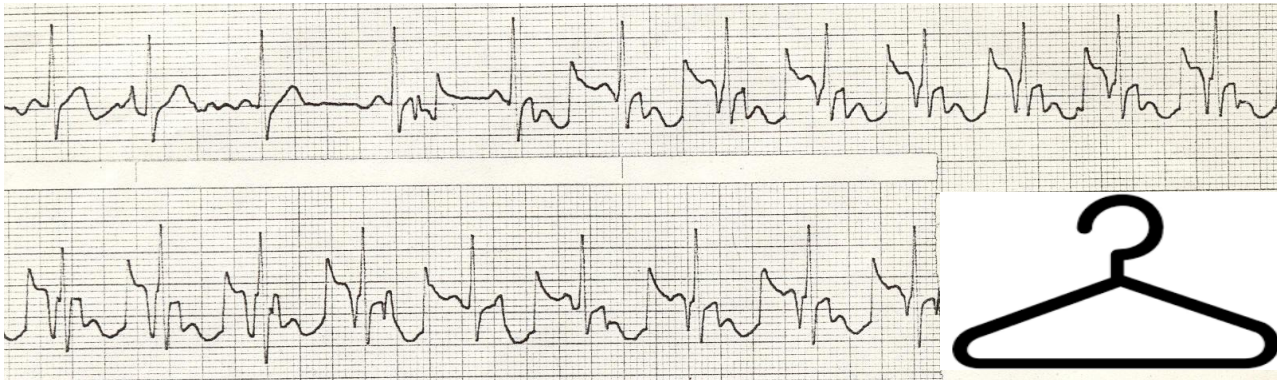


## Bizarre electrocardiographic patterns

ECG of a man who swallowed his hanger  
ECG de um homem que engoliu um cabide  
ECG de um hombre que engolió una percha

Courtesy of Dr. Alan E. Lindsay



Frank G. Yanowitz, MD Professor of Medicine University of Utah School of Medicine Cardiologist, LiVe Well Center Intermountain Healthcare  
389 South 900 East Salt Lake City, Utah 84102

[385-282-2723](tel:385-282-2723) (office)

[801-718-9811](tel:801-718-9811) (cell)

[frank.yanowitz@imail.org](mailto:frank.yanowitz@imail.org)