

J Wave Syndromes: Diagnosis, prognosis and treatment

Andrés Ricardo Pérez-Riera, MD PhD

Orientador de Post graduación de la Facultad de Medicina do ABC, Santo André - SP, Brasil

El autor declara no tener conflictos de intereses

Classification of the waves of the electrocardiogram

1. Normal waves

I. Constant and visible

- a) P-wave
- b) QRS complex: Q/q; R/r; S/s; R'/r'; S'/s'
- c) T-wave

II. Constant and invisible

- a) T-a or T-P-wave

III. Inconstant

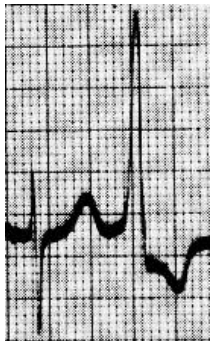
- a) The “enigmatic” U-wave (**Pérez-Riera 2008**)

2. Pathological waves

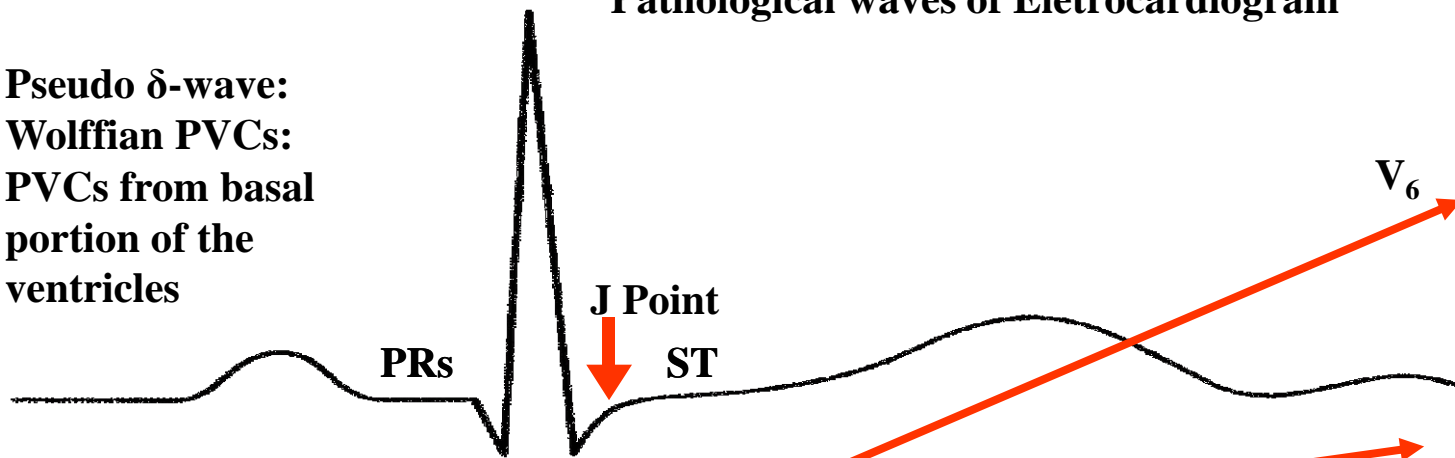
- a) Delta (δ) –wave of ventricular preexcitation (Wolff-Parkinson-White (WPW) syndrome)
- b) Pseudo delta (δ) –waves:
 - a) Wolffian PVCs: PVCs from basal portion of the ventricles – QRS complexes predominantly positive in all precordial leads (V1-V6) (**Rosenbaum 1969**)
 - b) Epicardial ventricular tachycardias
 - c) Slurred QRS upstroke mimicking delta (δ) waves in hypertrophic cardiomyopathy (**Marine 2013**)
- c) **J-wave**, J deflection, "the camel's hump"/ camel-hump sign, “late δ wave”, elevated J-point, hathook junction, hypothermic wave, K wave, H wave, current of injury, or Osborn wave: a J wave is defined as either notching or a slur at the QRS terminal > 0.1 mV above the isoelectric line or without ST segment elevation at least in two contiguous leads.
- d) Lambda (λ)-wave or Gussak wave (**Gussak 2004**): Peculiar shape of J wave?
- e) Epsilon (ϵ) wave, epsilon potential or Fontaine wave

Pathological waves of Eletrocardiogram

V₃



Pseudo δ -wave:
Wolffian PVCs:
PVCs from basal
portion of the
ventricles

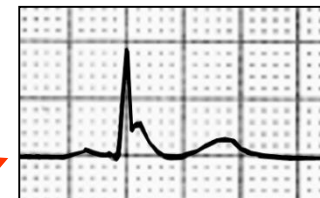


J Point

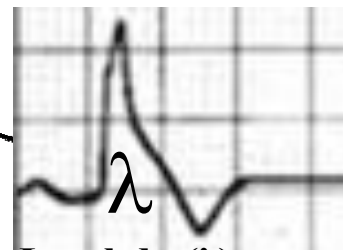
ST

J Wave

Idiopathic VF

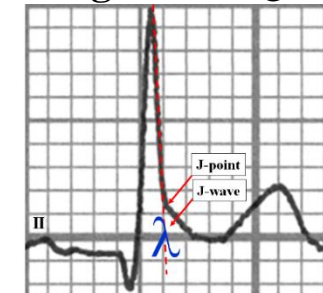


V₆

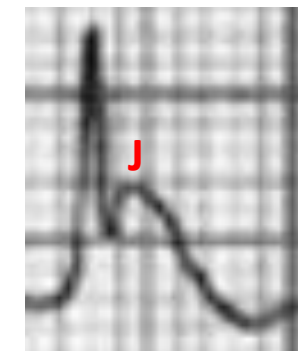


Lambda (λ)-wave
or Gussak wave

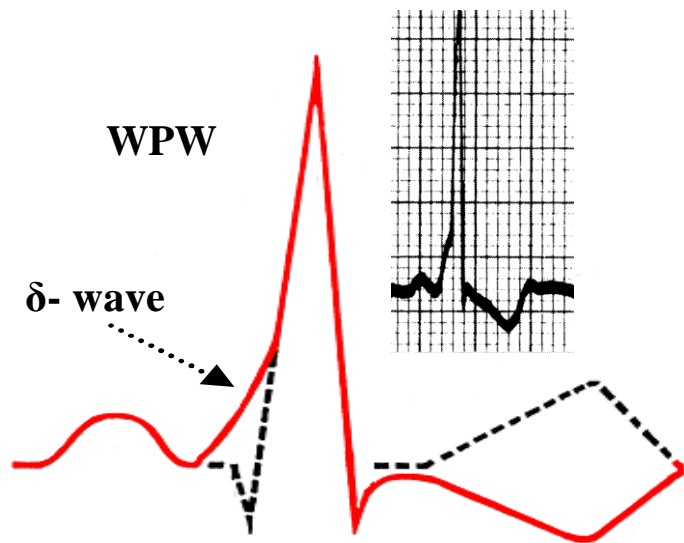
Congenital SQTs



Brain injury



δ -wave and pseudo δ -wave

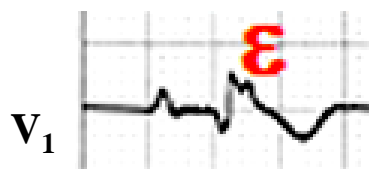


WPW

δ - wave

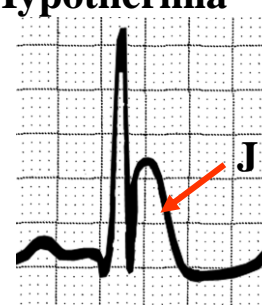
Epsilon
wave

ARVC/D



V₁

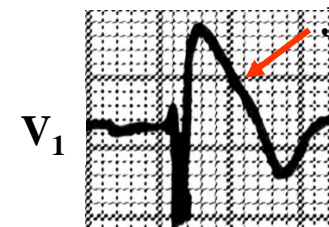
Hypothermia



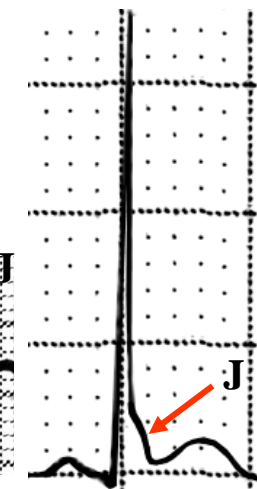
50mm/sec
2N

Hypercalcemia

Brugada
syndrome

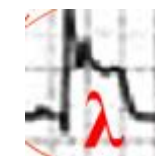


V₁



Short QT interval
The ST segment is
almost absent

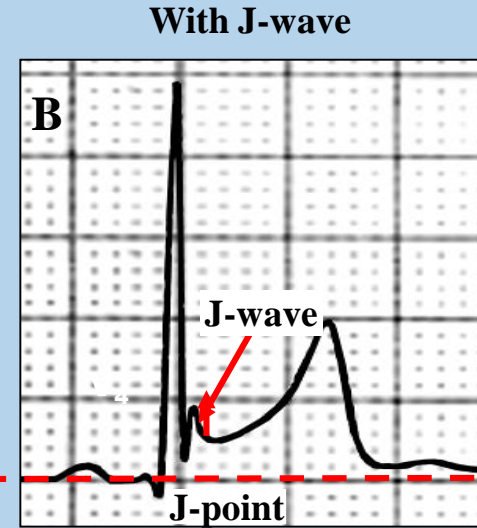
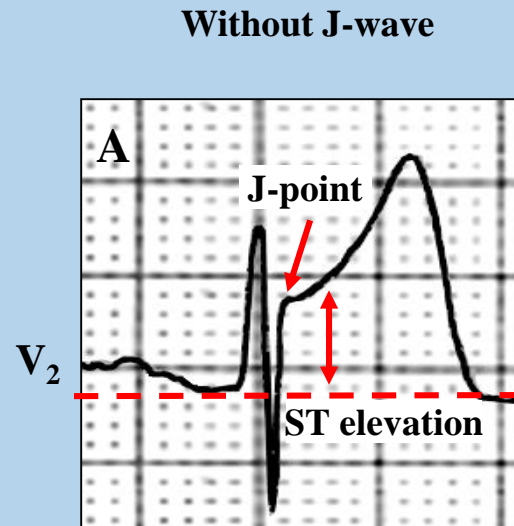
Prinzmetal



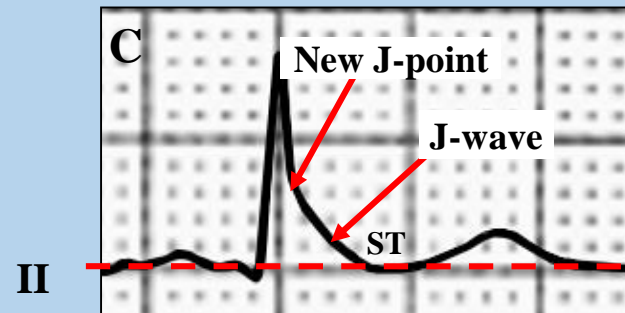
CAD



Classical definition of ERP: STSE associated with concave upward ST-segment elevation and prominent T waves in at least two contiguous leads.

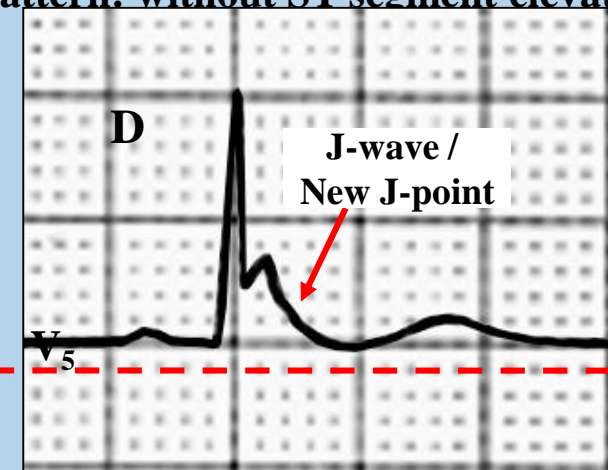


New definition of early repolarization pattern: without ST segment elevation



Slurred QRS downstroke without STE

**QRS slurring without STSE
producing a positive hump**



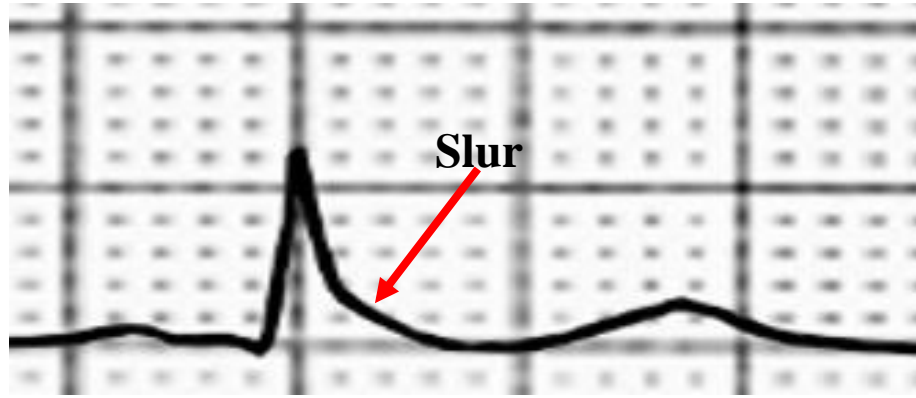
**J-wave or the new “J-point elevation” without
STE**

**QRS notching without STSE + a positive
Deflection(hump) inscribed on terminal QRS complex**

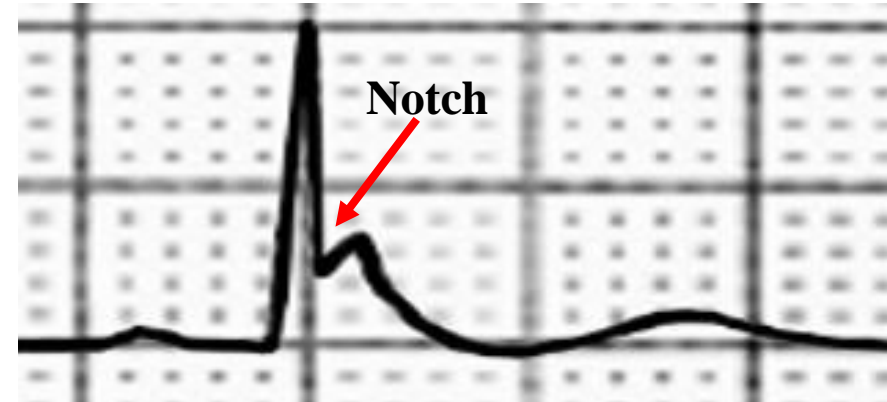
Clinical causes of J-wave or elevated J-point

1. Hypothermic J- wave or Osborn wave: hypothermia mediated VT/VF
2. Normothermic states
 - ❖ ERS. ER a J-point elevation, notching or slurring of the terminal portion of the R wave (J wave) QRS slurring or notching in at least 2 contiguous inferior or lateral leads.

Slurring without STSE



QRS notching without STSE



- ❑ Type 1: early repolarization pattern (ERP) in the lateral precordial leads, healthy black male athletes

➤ Genetic forms

J-wave syndromes: a group of clinical entities that share similar molecular, ionic and cellular mechanism and marked by amplified J wave on the ECG and a risk of PVT/VF.

○ Without apparent structural heart disease

- J-wave Syndromes**
- BrS: J-wave in the right precordial leads V1-V3
 - Overlapping between BrS and ERS
 - IVF
 - SQTS

○ With structural heart disease

- Concealed forms of arrhythmogenic dysplasia of the right ventricle (**Nava 1988**)

➤ Acquired forms

- Ischemia- mediated VT/VF: Vasospastic angina, Prinzmetal J waves/ Ischemic J-Waves
- Miscellaneous
 - ✓ Hypercalcemia
 - ✓ Brain injury
 - ❖ Subarachnoid hemorrhage
 - ❖ Acute intracranial hypertension
 - ❖ Transient postictal hemiplegia (Todd's paralysis) (**O'Connell 2013**)
 - ✓ Damage to sympathetic nerves in the neck: or spinal cord injury leading to loss of sympathetic tone
 - ✓ Cardiopulmonary arrest from over sedation (**Shinde 2007**)
 - ✓ Accessory third papillary muscle with a prominent J-wave
 - ✓ Hypervagotonia.

Repolarization versus depolarization mechanism

I. Ventricular **repolarization** components on the electrocardiogram

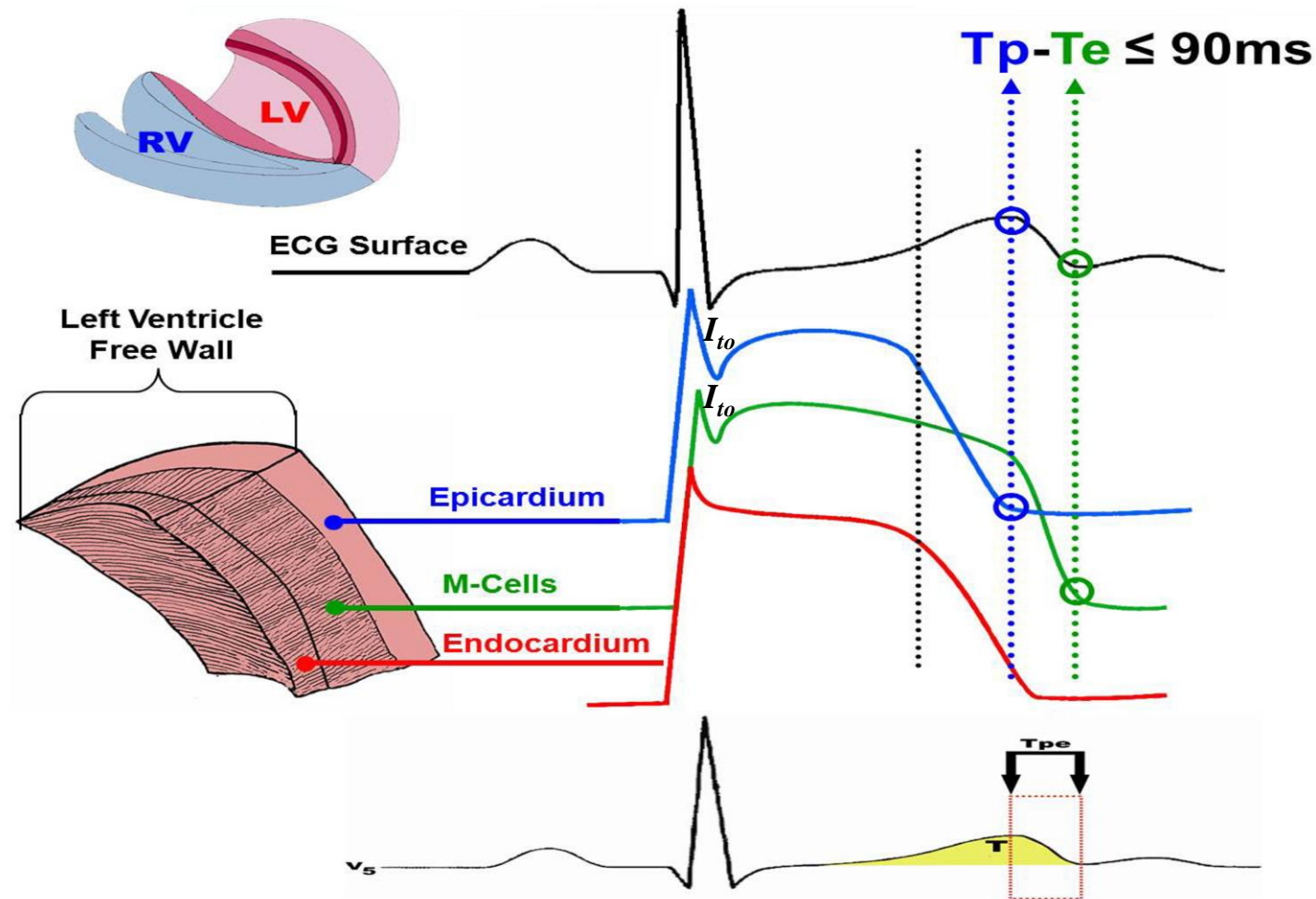
- ❖ J-wave
- ❖ ST-segment
- ❖ T-wave
- ❖ U-wave

- Transmural voltage gradient during early ventricular repolarization: phases 1 and 2 of AP
- Electrical heterogeneity among ventricular endocardium and epicardium during repolarization.
- The ventricular epicardium denotes an AP with a prominent transient outward K^+ current (I^{to})-mediated notch.
- The AP of the endocardium shows a much smaller I^{to} current.
- J waves are associated with Phase 2 reentrant arrhythmias,

II) Ventricular **depolarization** components on the electrocardiogram

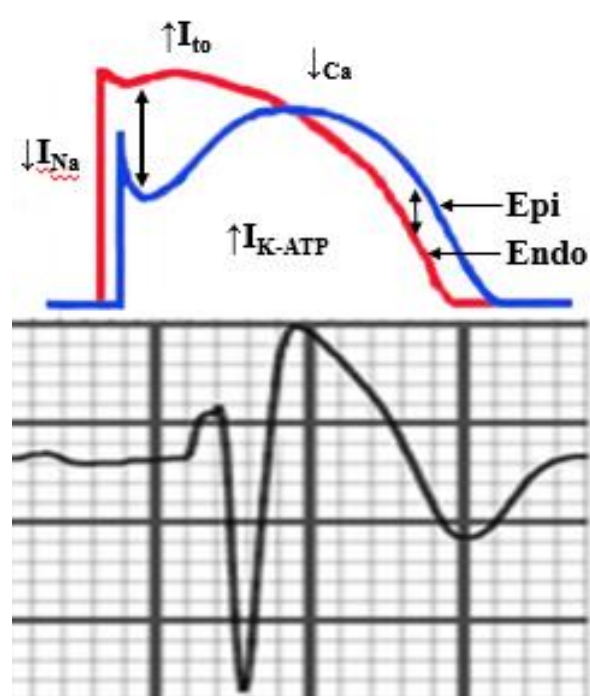
1. QRS fragmentation (fQRS)
2. QRS duration ≥ 120 ms in V2 and II
3. Epsilon wave
4. Right Bundle branch conduction Delay
5. Left Bundle branch block
6. QT peak
7. QT end
8. r-J interval
9. Late potentials (LPs)

Transmembrane APs from epicardium, endocardium and midmyocardium (M cells): repolarization mechanism



A prominent AP notch in the epicardium mediated by I_{to} channels is responsible for the appearance of J wave on the ECG of BrS, IVF.

Early repolarization mechanism in Brugada syndrome Repolarization mechanism



Gene mutations SCN5A and other

Fever
Ischaemia
Multiple Drugs
Cocaine
Alcohol
Hypokalaemia
Hypothermia

$\downarrow I_{Na}; \downarrow I_{Ca}$

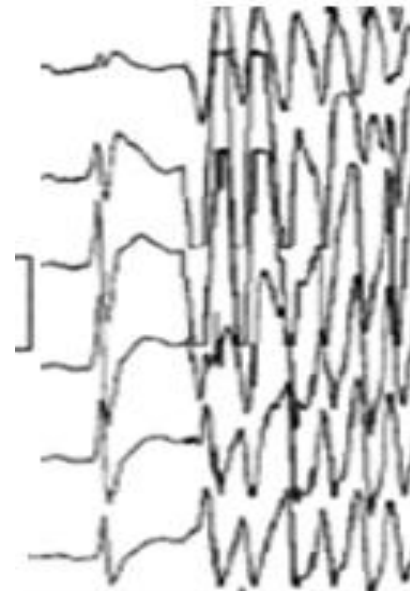
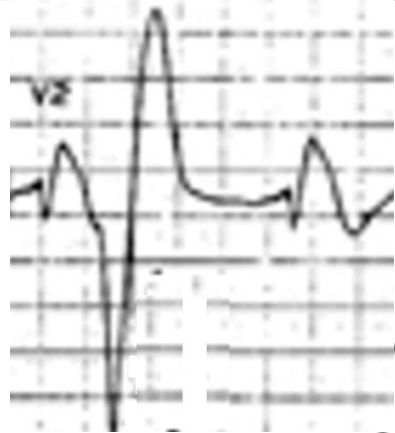$I_{to}; \uparrow I_{K-ATP}$

Type 1 Brugada Pattern

Short-coupled PVCs/
Polymorphic VT

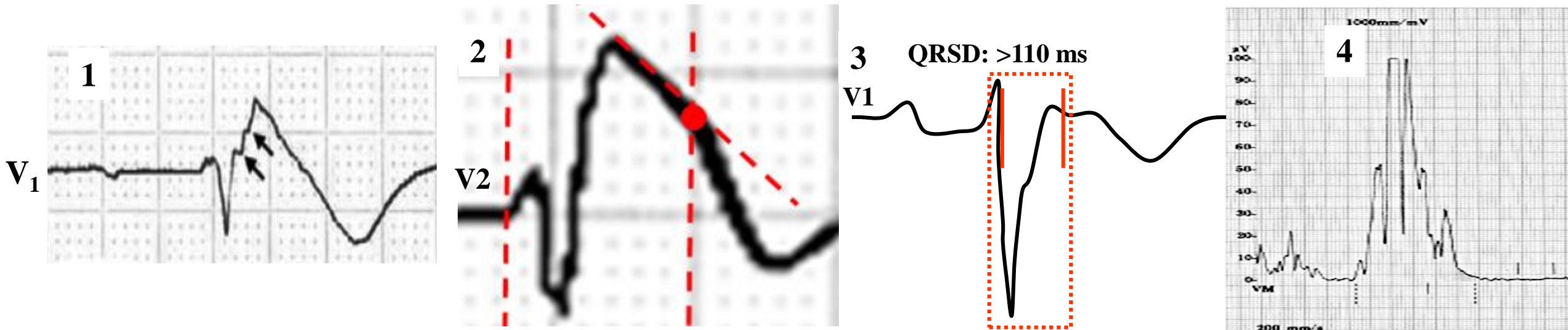
Self-terminating
VT/VF

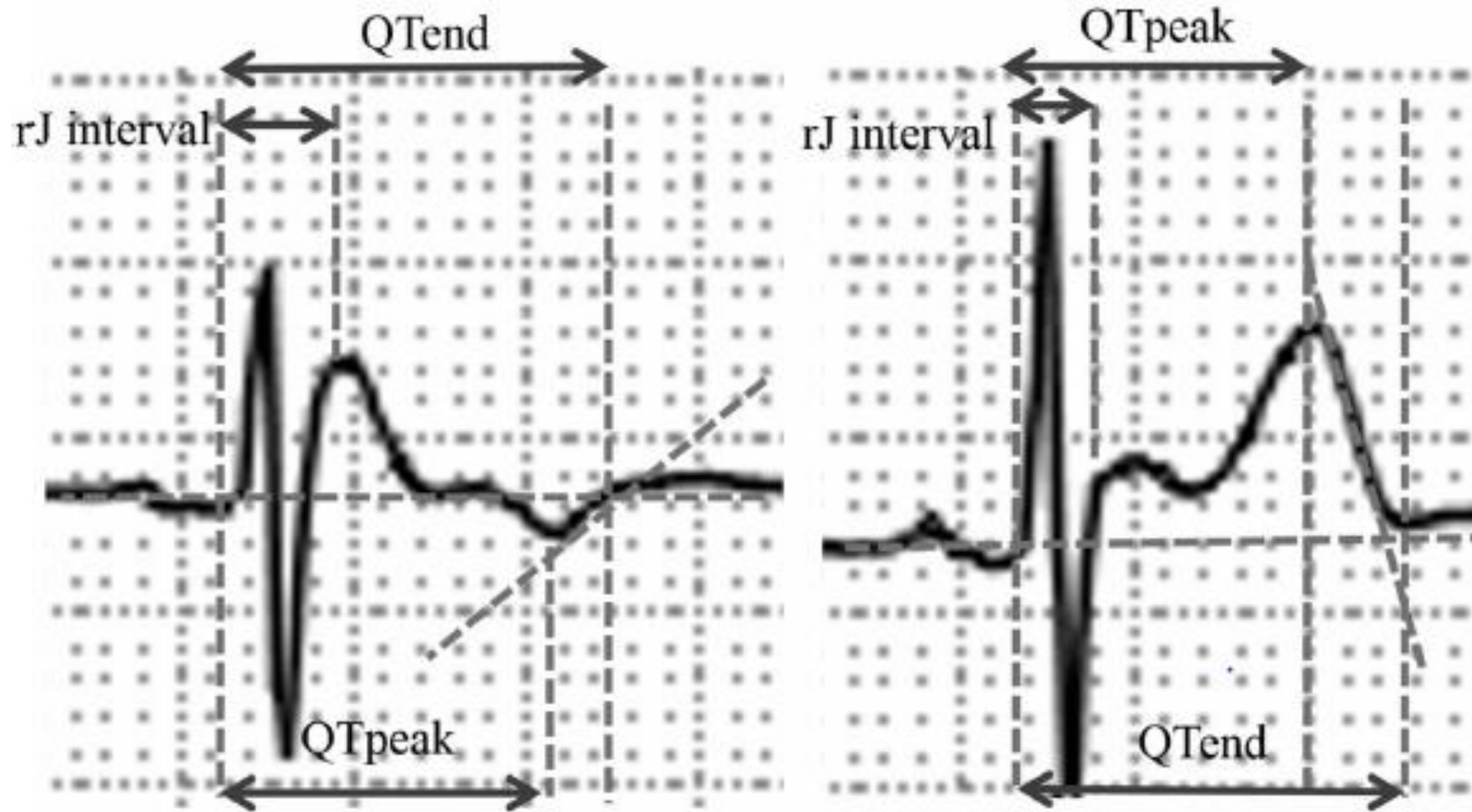
Sustained VF



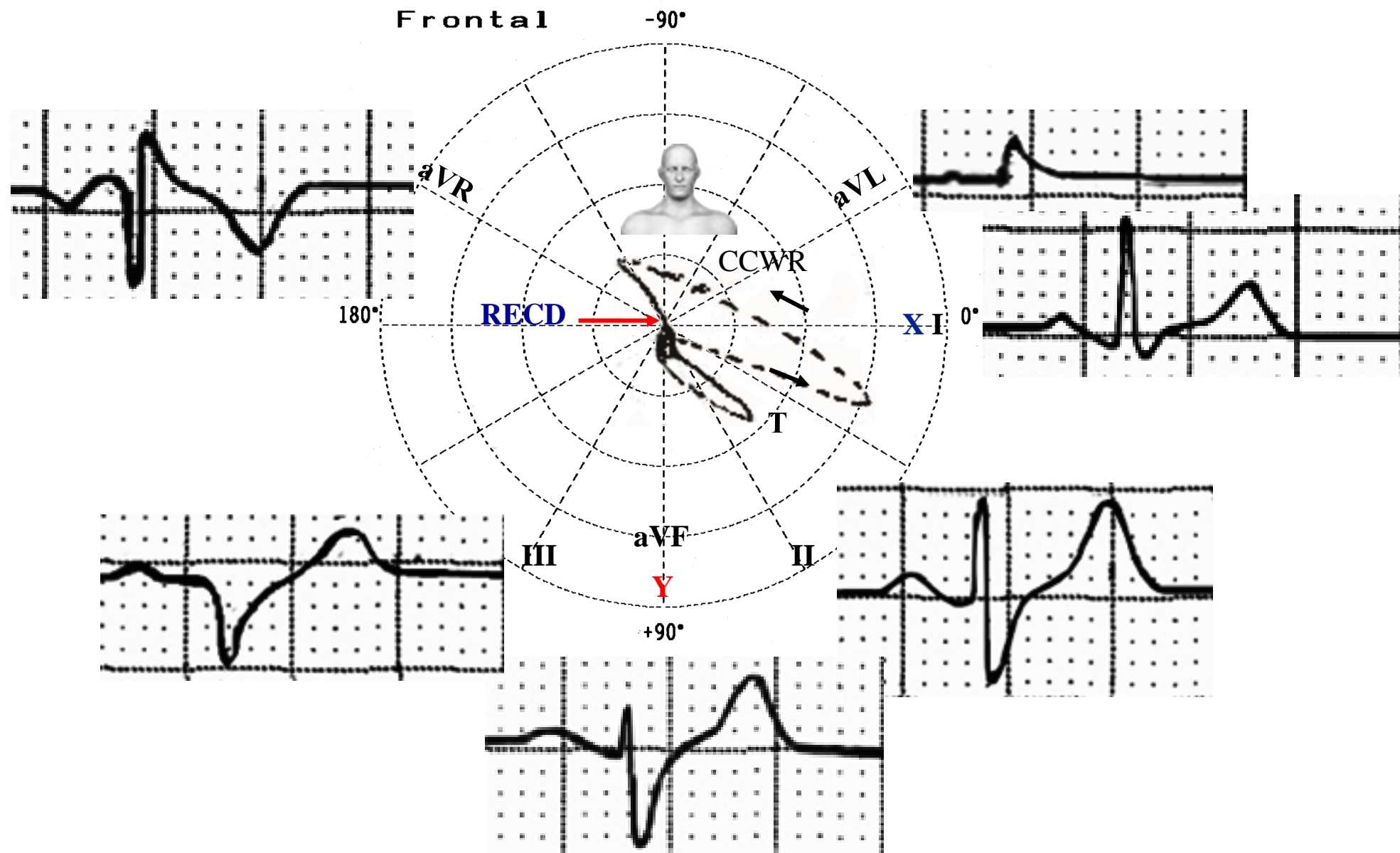
Depolarization mechanism

1. QRS fragmentation or fragmented QRS complex (fQRS): defined as ≥ 2 notches of the R wave or in the nadir of the S wave in at least 2 consecutive leads.
2. QRS duration ≥ 120 ms in V2 and II, f-QRS are powerful depolarization marker for VF/SCD is a significant S-wave (≥ 0.1 mV and/or ≥ 40 ms) in lead I in patients with BrS (**Calò 2016**)
3. QT-interval prolongation in . right precordial leads (**Pitzalis 2003**)
4. Presence of LPs on SAECG: 1) Total filtered QRS duration (f-QRS) ≥ 114 ms; 2) Root Mean Square voltage (RMS40) of the terminal 40 ms of the f-QRS complexes ≥ 20 μ V; and 3) Duration of low-amplitude signals 40 μ V of the f-QRS complexes (LAS₄₀) ≥ 38 ms. LP is identified when 2 of the criteria are satisfied. 5) Right End Conduction Delay on VCG





r-J interval, defined as the time between the earliest deflection of the QRS complex and J wave



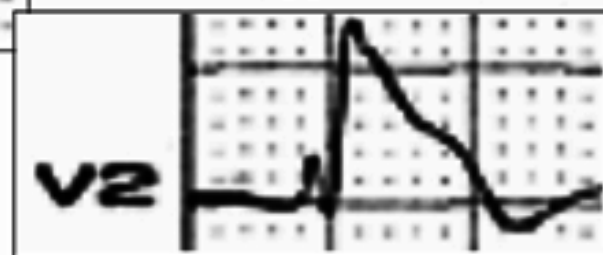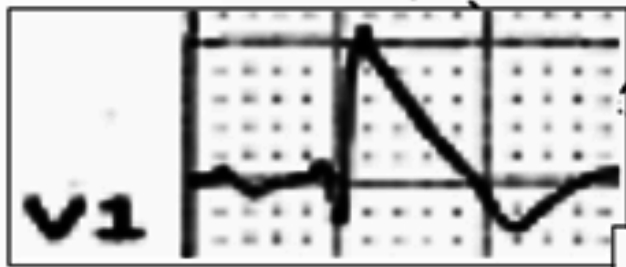
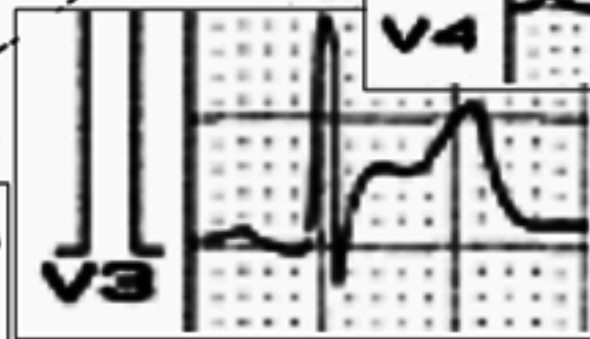
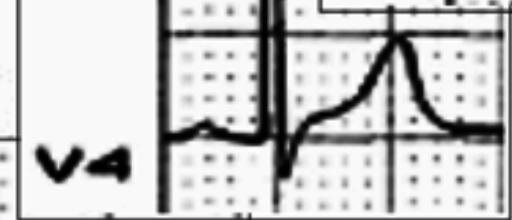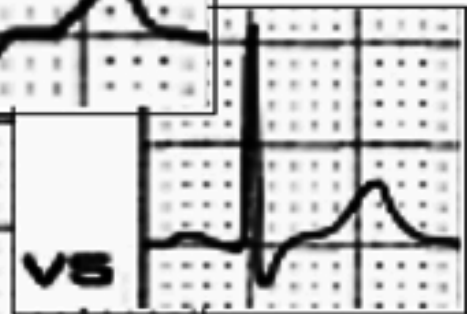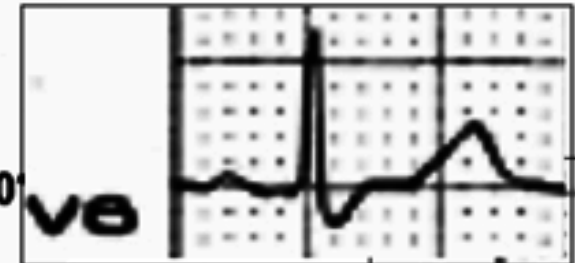
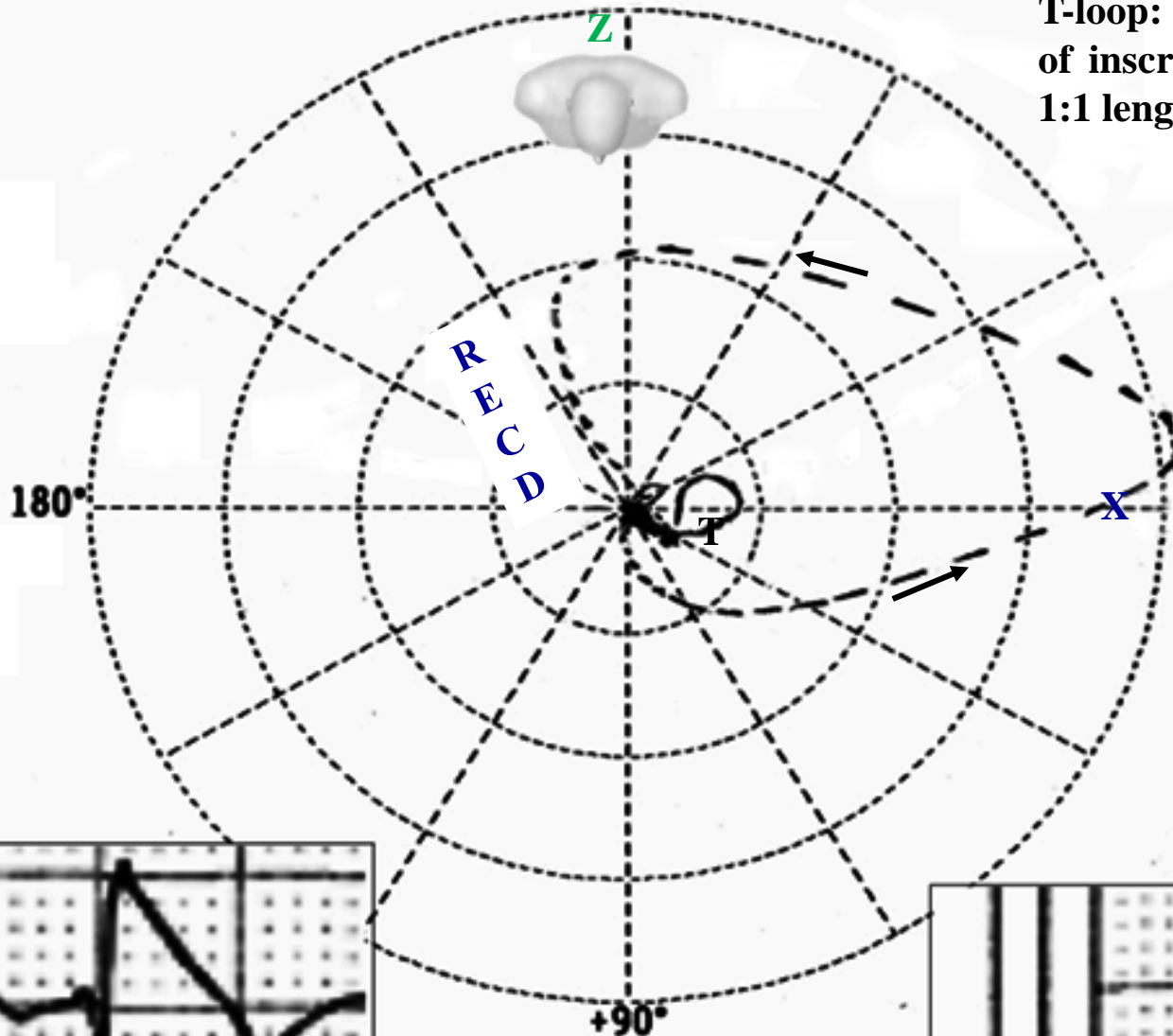
The 10 to 20ms initial forces are directed to left and downward (in LAFB this forces are directed to right and downward). Counterclockwise rotation(CCWR) with extreme left axis deviation, $S_{II} > S_{III}$, prominent final R wave in aVR and prolonged R-peak time in this lead ,

Horizontal -90°

Z

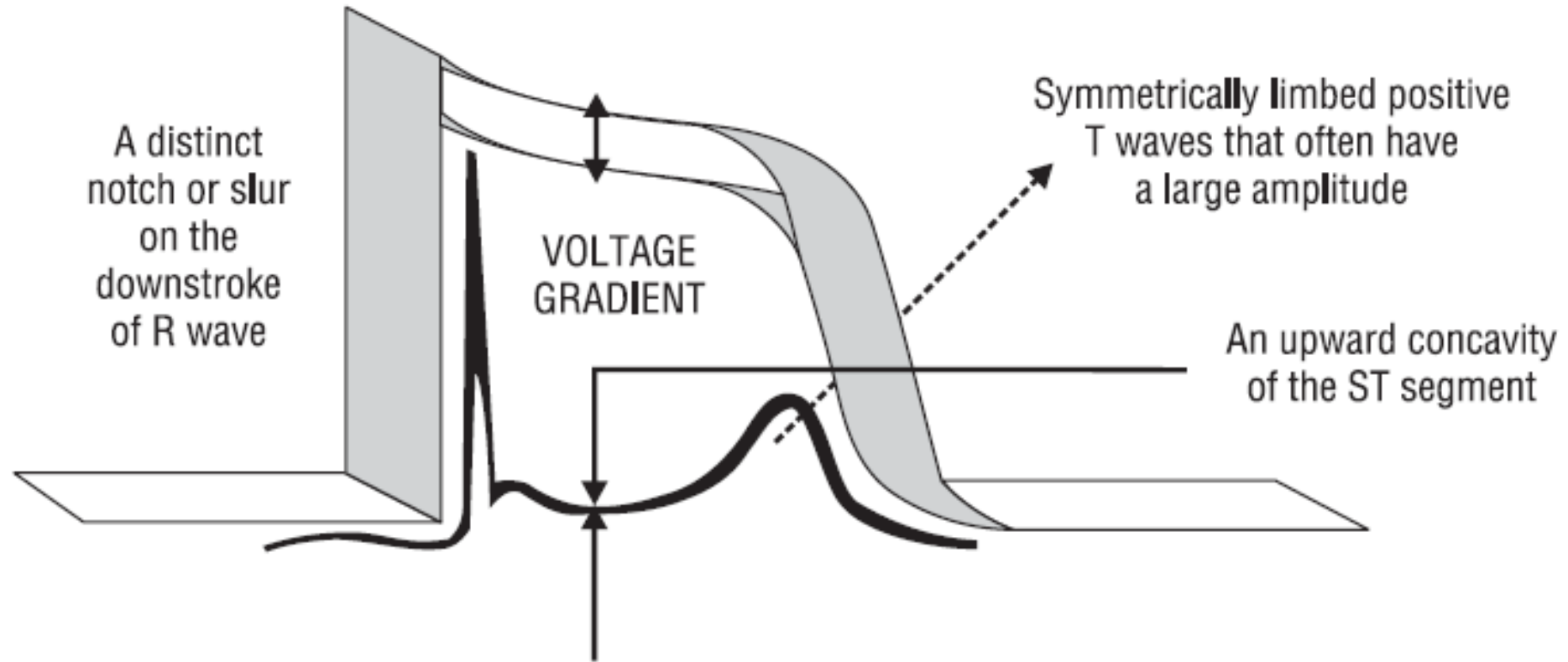
T-loop: Rounded, small, with symmetrical velocity of inscription of afferent and efferent limbs and a 1:1 length/width ratio: Repolarization mechanism.

RECD on right posterior quadrant:
Depolarization mechanism



Type 1 Brugada pattern

Benign early repolarization mechanism



An elevated takeoff of the ST segment at the J point of the QRS complex, varying from 1 to 4 mm relative to the isoelectric line

J-wave syndromes						
Characteristics	Inherited				Acquired	
	ERS type 1	ERS type 2	ERS type 3	BrS	Ischemia-mediated VT/VF	Hypothermia-mediated VT/VF
Average age of first event	healthy black male athletes		35 years	30-40 years	40-50 years	40-50 years
Anatomic location	Lateral LV	Inferior LV	Both ventricles	RVOT	Both ventricles	Both ventricles
Leads displaying J point/J wave	I, V4-6	II, III, aVF	Global	V1-3	Any of 12 leads	Any of 12 leads
Response of J wave/ST elevation to						
Bradycardia or pause	↑	↑	↑	↑	Not available	Not available
Na-channel blockers	↓ →	↓ →	↓ →	↑	Not available	Not available
Male predominance	75%			80%		
Sex dominance	Male	Male	Male	Male	Male	Either
VT/VF	Rare common in healthy athletes	Yes	Yes, electrical storms	Yes	Yes	Yes

ERS: Early repolarization syndrome; BrS: Brugada syndrome; LV: Left ventricle; RVOT: Right ventricular outflow tract; VT: Ventricular tachycardia; VF: Ventricular fibrillation;

J-wave syndromes						
Characteristics	Inherited				Acquired	
	ERS type 1	ERS type 2	ERS type 3	BrS	Ischemia-mediated VT/VF	Hypothermia-mediated VT/VF
Response to quinidine					Limited data	
J wave/STSE	↓	↓	↓	↓		
VT/VF	↓	↓	↓	↓		↓
Response to isoproterenol			Limited data		Not available	Not available
J wave/STSE	↓	↓		↓		
VT/VF	↓	↓		↓		
Gene mutations	CACNA1C, CACNB2B	KCNJ8, CACNA1C, CACNB2B	CACNA1C	SCN5A, SCN1B, SCN2B, SCN3B, SCN10A, CACNA1C, CACNB2, CACNA2D1, GPD1L, KCND3, KCNE3, KCNE1L, (KCNE5), KCNJ8, HCN4, ABCC9, RANGRF, PKP2, FGF12, SLMAP, TRPM4	SCN5A	Not available

ERS: Early repolarization syndrome; BrS: Brugada syndrome; STSE: ST segment elevation; VT: Ventricular tachycardia; VF: Ventricular fibrillation

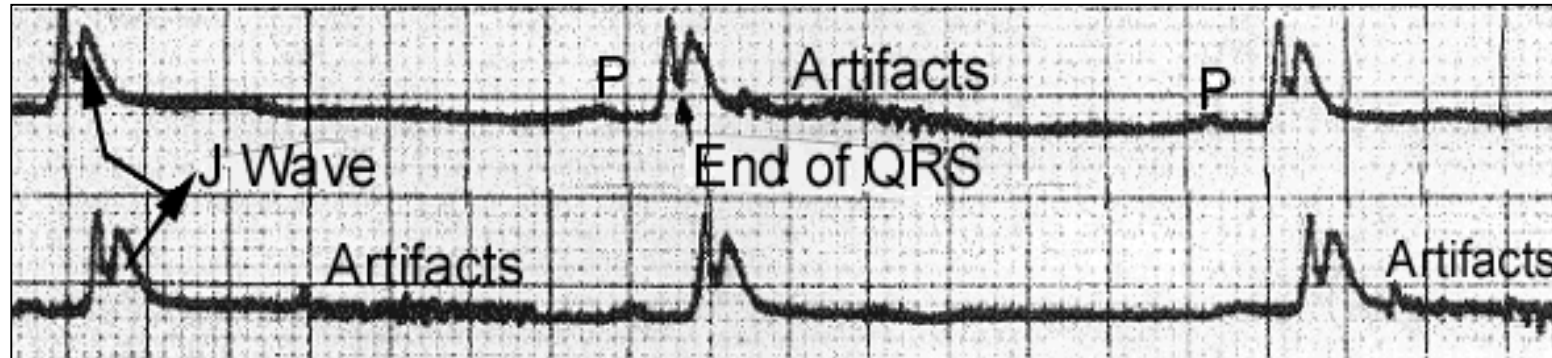
1. Hypothermic J- wave or Osborn wave ECG features

Concept: hypothermia is defined as the condition where central temperature (rectal, esophageal or tympanic) is below 35°C. Hypothermia may be accidental, metabolic, or therapeutic.

Accidental hypothermia is more frequent in countries with cold weather, during winter season. The hypothermal state is characterized by drop in basal metabolism, decrease in O₂ consumption and greater production of CO₂.

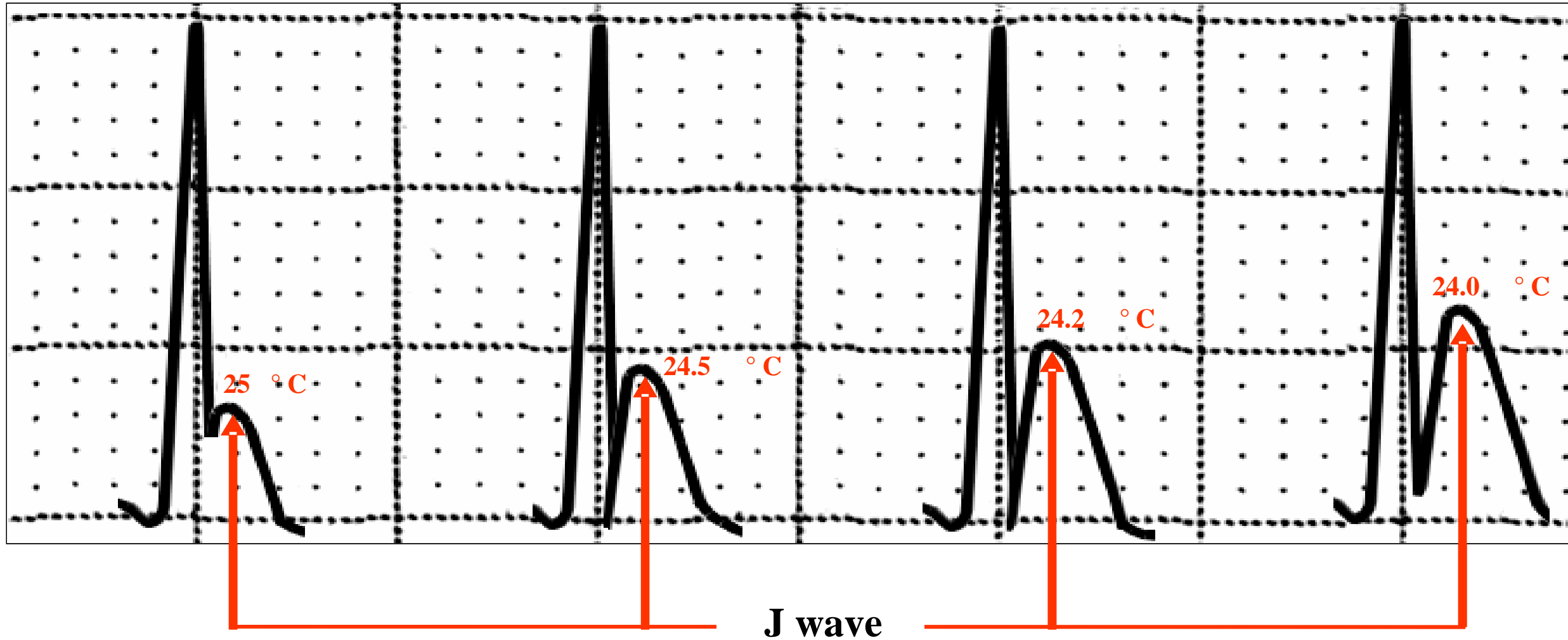
During hypothermia, a gradual decrease of heart rate is observed and systolic volume, with progressive drop of blood pressure later, which becomes significant when central temperature values close to 23°C are reached.

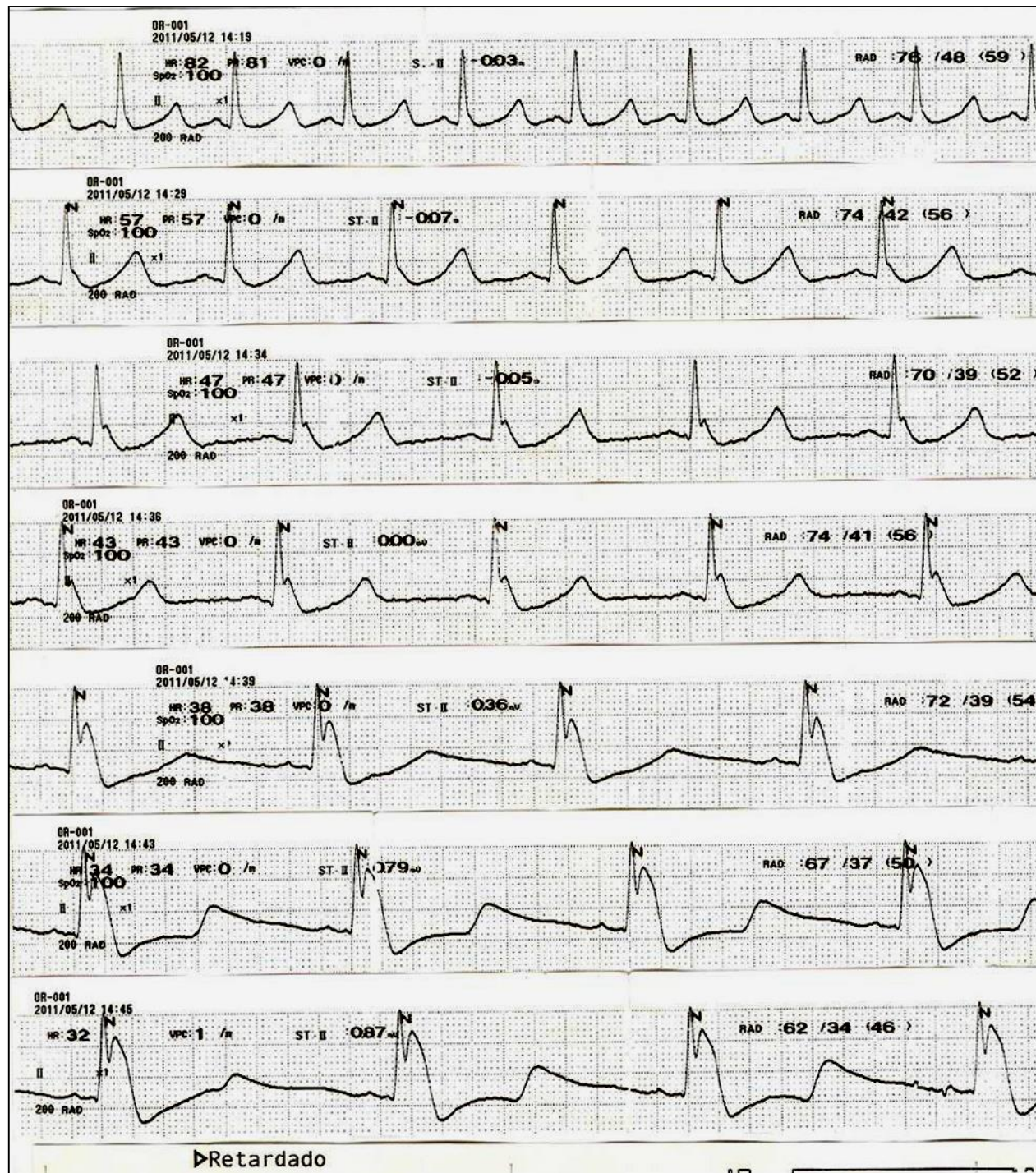
- **Sinus bradycardia**, but in the initial phase tachycardia by release of adrenaline
- **Atrial fibrillation** (50% of cases), temperature < 32°C.
- **Artifacts:** fluctuation in the baseline caused by the muscular trembling. Only in the initial phase (of struggle), when body temperature is between 36 and 32°C.



- **PR interval** prolongation
- **QRS complex:** decrease in voltage and increase in duration.
- **QT and QTc intervals** prolongation.
- Both supraventricular and ventricular arrhythmias
- Very characteristic extra wave, called J wave between the end of QRS complex and ST segment onset, not pathognomonic (may be observed in normothermia conditions, positive and prominent in V₅ and V₆. Inverse correlation between J wave voltage (mm) and central temperature

Inverse and significant correlation between J wave voltage (mm) and central temperature in hypothermia





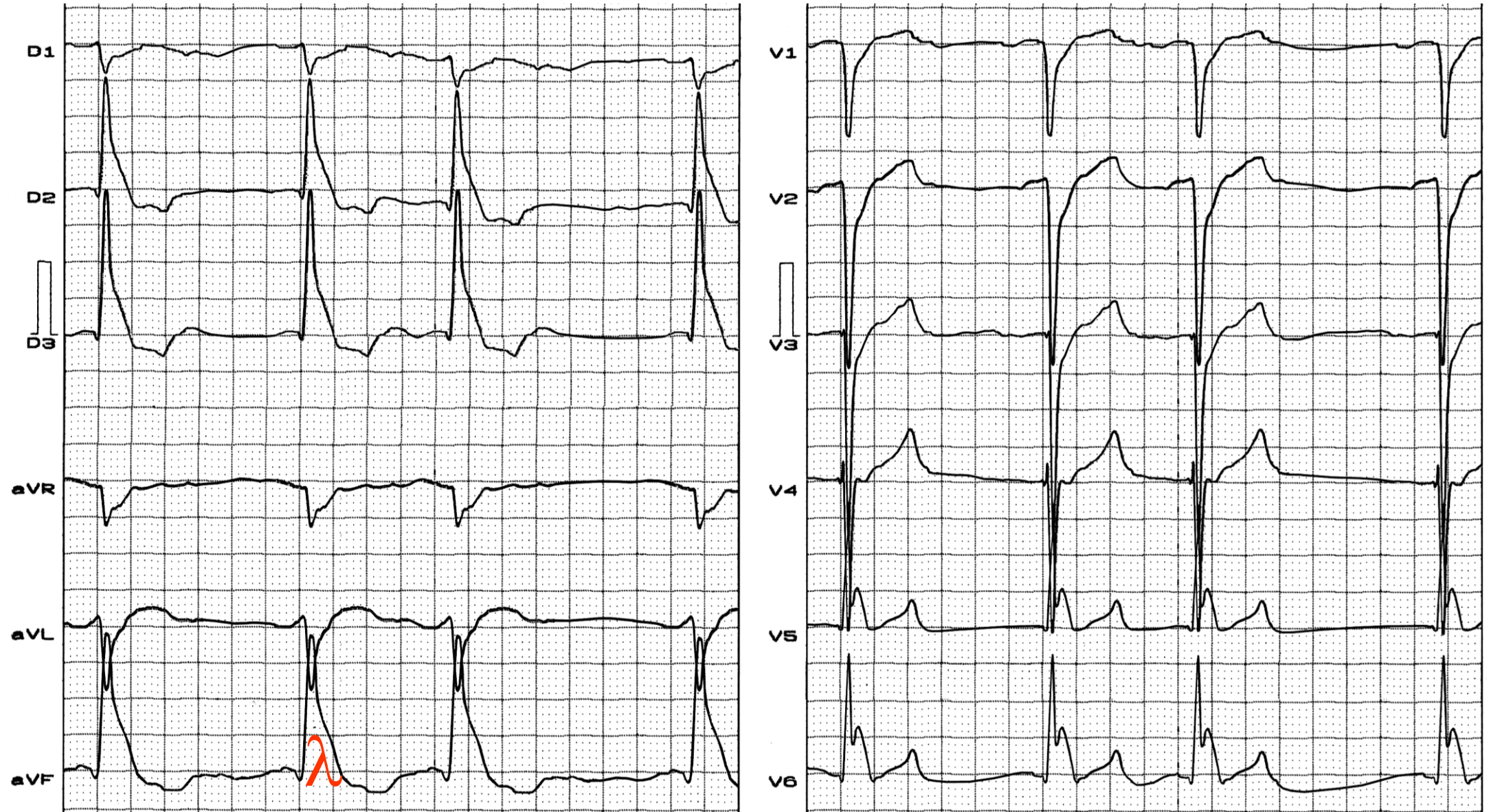
The tracing was obtained during cooling of the blood before a surgical procedure of the heart. Although the ECG obtained was somewhat expected, what was striking is that the progressive development and augmentation of the J wave was recorded.

Most of the hypothermia cases are published in the moment when the patient is rescued and after recovery. On the other hand, in this case we can see the time course of changes up to the simulation of a monophasic action potential.

Additionally, significant bradycardia is observed and the QT interval was too prolonged, something that usually is not given much attention in the published cases.

Courtesy from Prof. Dr. Raimundo Puerta from Cuba

Name: PASA; **Gender:** Male; **Age:** 47 y/o; **Ethnic group:** Afro-descendant; **Weight:** 61 Kg;
Height: 1.68 m; **Date:** 03/07/2008; Central body temperature: 29°C.



Severe hypothermia. Atrial fibrillation with slow ventricular response. Left posterior fascicular block pattern. Gussak wave or lambda wave.

2. Normothermic states

J-wave syndromes: a group of clinical entities that share similar molecular, ionic and cellular mechanism and marked by amplified J wave on the ECG and a risk of PVT/VF.

J-wave syndromes

• BrS: J-wave in the right precordial leads V1-V3

• IVF

• SQTS

⌋

Type 2: ERP in the inferior (II, III, aVF) or inferolateral leads (II, III, aVF, V5-6). Intermediate risk.
Type 3: ERP global (inferior, lateral, and right precordial leads). Highest risk.

Brugada syndrome

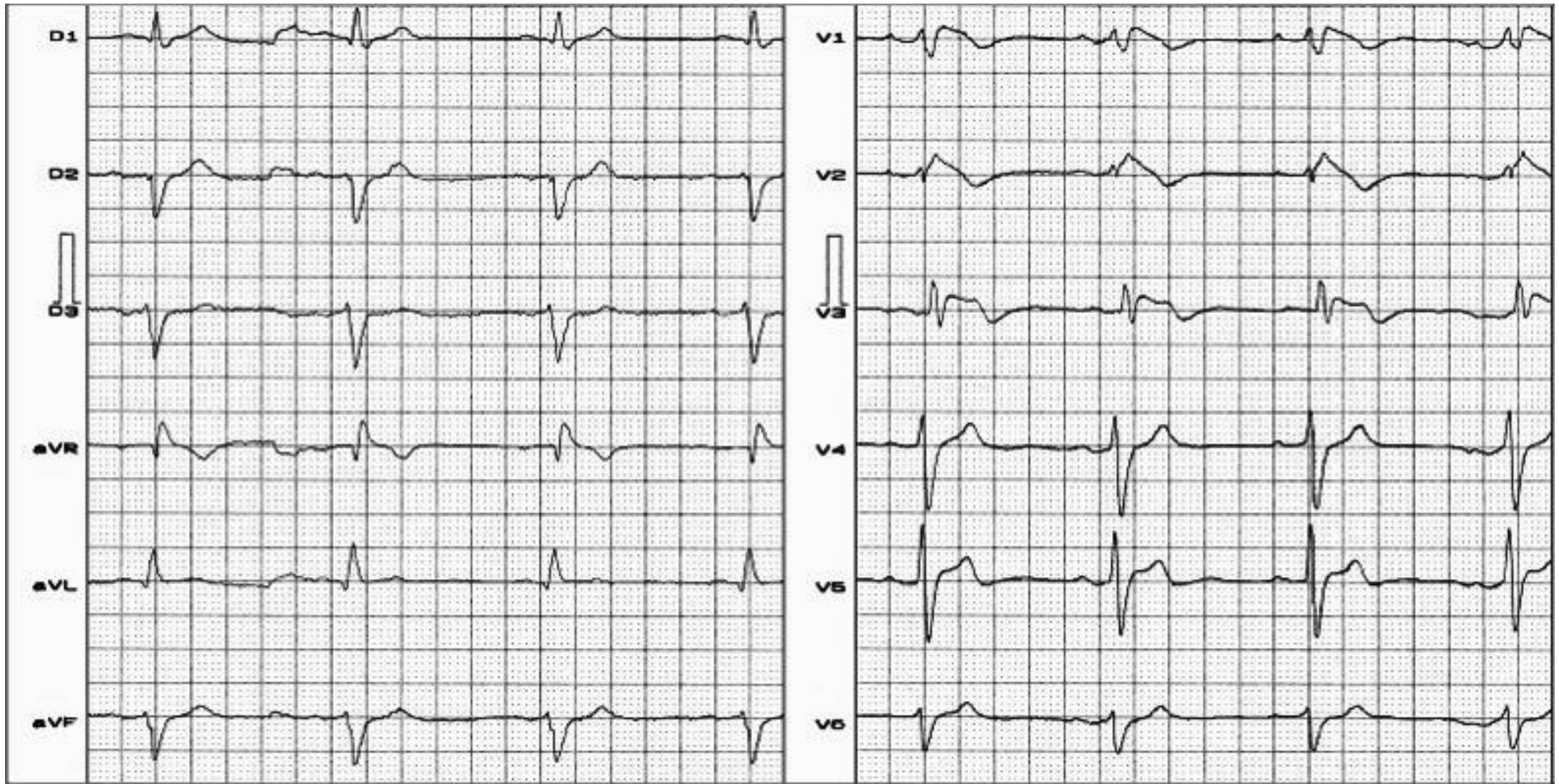
Concept

Clinical and electrocardiographic entity (without apparent structural heart disease) hereditary heterogeneous pattern with autosomal dominant transmission (33% of cases) or sporadic (67%), mainly caused by mutation in the SCN5A gene encoding the α subunit of Na⁺ channel (Na (v) 1.5) located on the short arm of chromosome 3 (locus: 3p21). Until present date, 20 types of genes affected are known. Clinically manifested by a tendency to syncope and/or sudden death in 60-80% of cases during night rest, with great male predominance (8:1), endemic in Southeast Asia (Thailand, Philippines) and Japan, predominantly in productive life time (young adult).

Diagnosis criteria

1. Absence of apparent structural heart disease
2. Absence of drugs effects, electrolyte disturbance and CHD
3. Documented PVT/VF
4. Family history of SCD at <45 years in first-degree relatives
5. Type 1 ECG Brugada pattern (coved-type) in proband and family members
6. Induction of VT/VF with Programmed Electrical Stimulation
7. Syncope, cardiac arrest or nocturnal agonal respiration.

Name: MK; **Age:** 38 y/o; **Gender:** Male; **Ethnic Group:** Asian; **Weight:** 68 kg; **Height:** 1.70 m



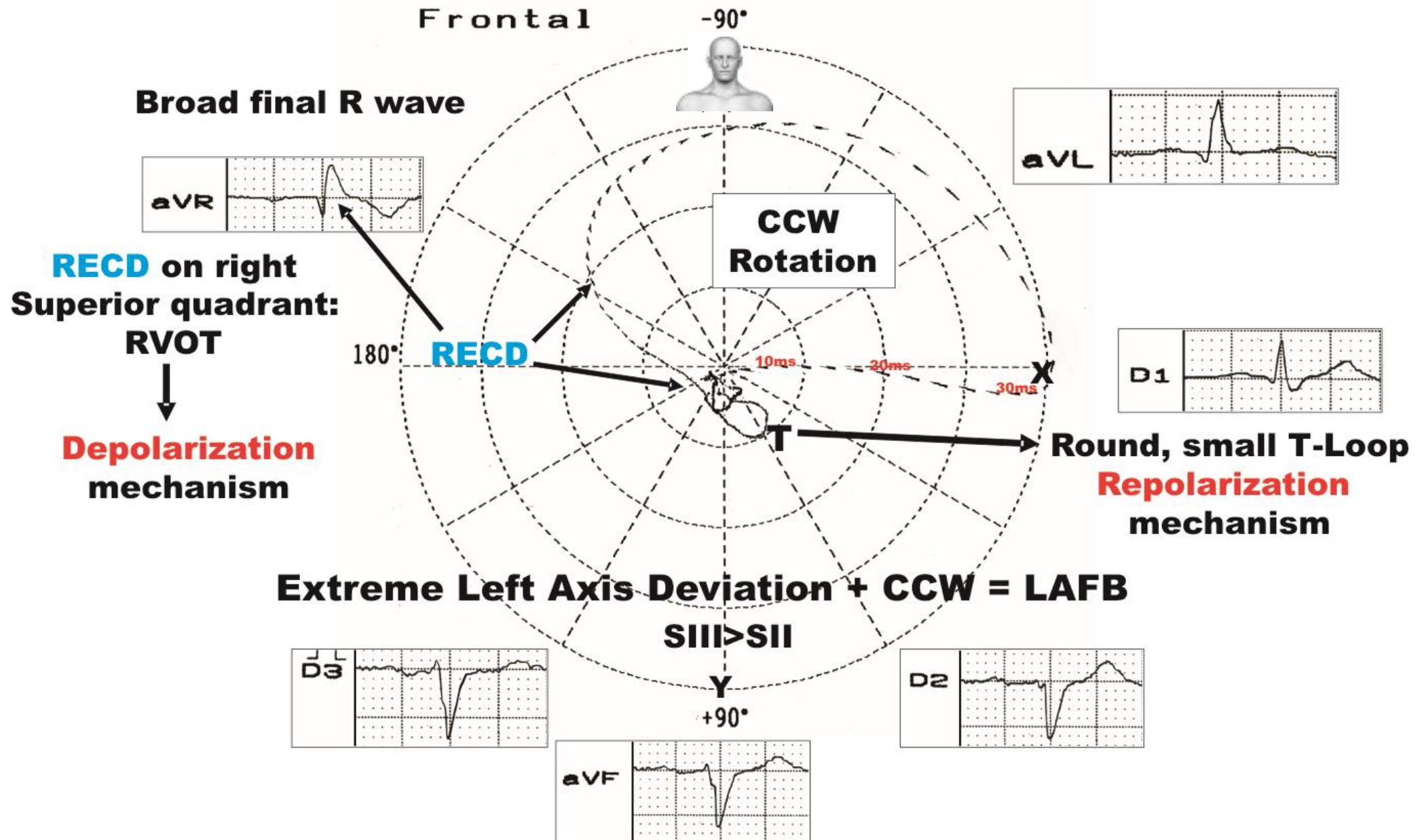
Clinical diagnosis: Syncope. Positive familial background of sudden death in young (≤ 35 y/o) first-degree relative. Genetic research performed: negative.

ECG diagnosis: Sinus bradycardia (HR <60 bpm), Brugada type 1 ECG pattern, prolonged QRS duration, aVR signal: final R wave of aVR lead >3 mm, fQRS in V1-V2.

Extreme left axis deviation: Left anterior fascicular block? or Right superior fascicular block?

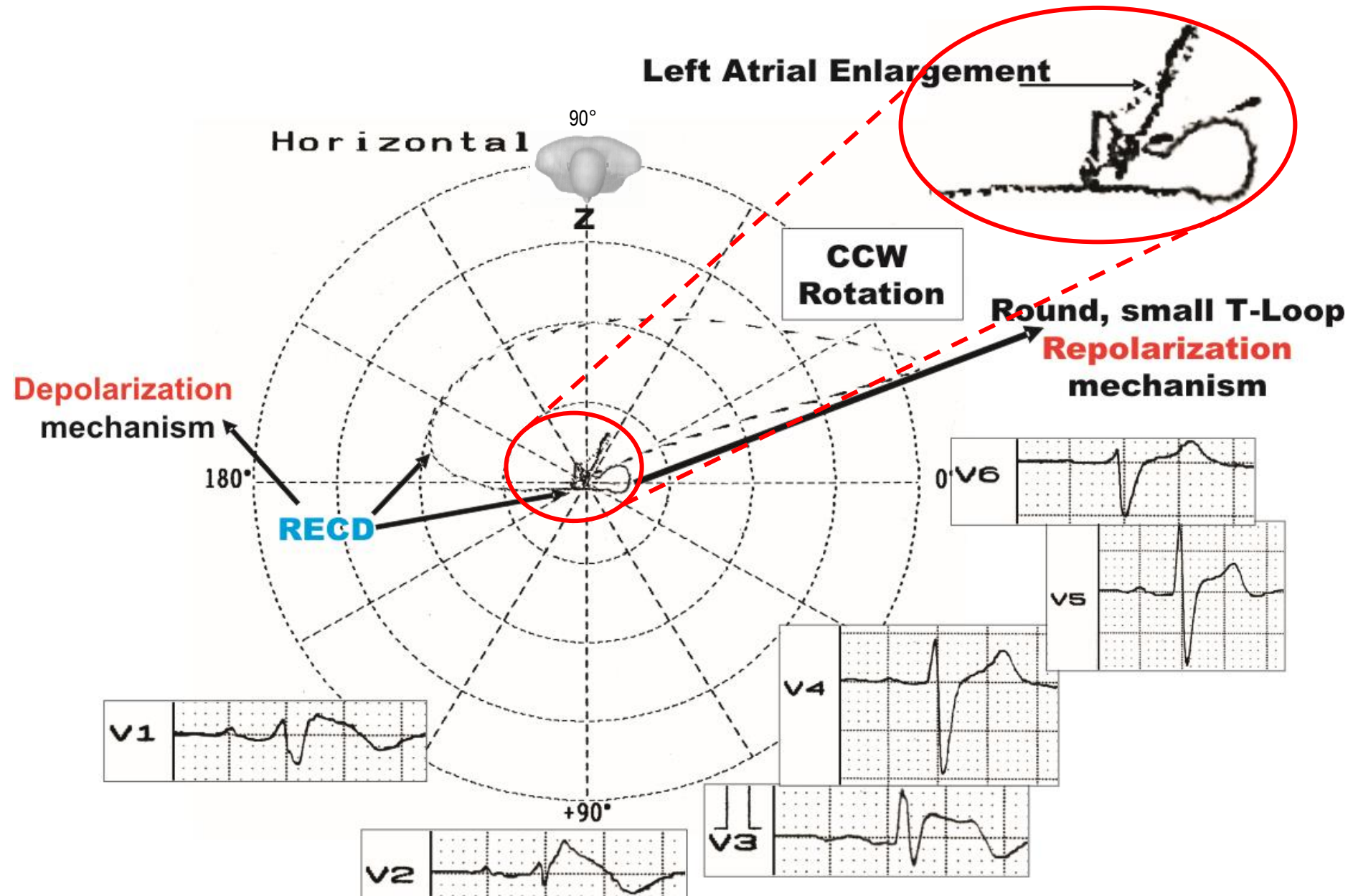
ECG/VCG correlation in the frontal plane

Name: MK; Age: 38 y/o; Gender: Male; Ethnic Group: Asian; Weight: 68 kg; Height: 1,70 m



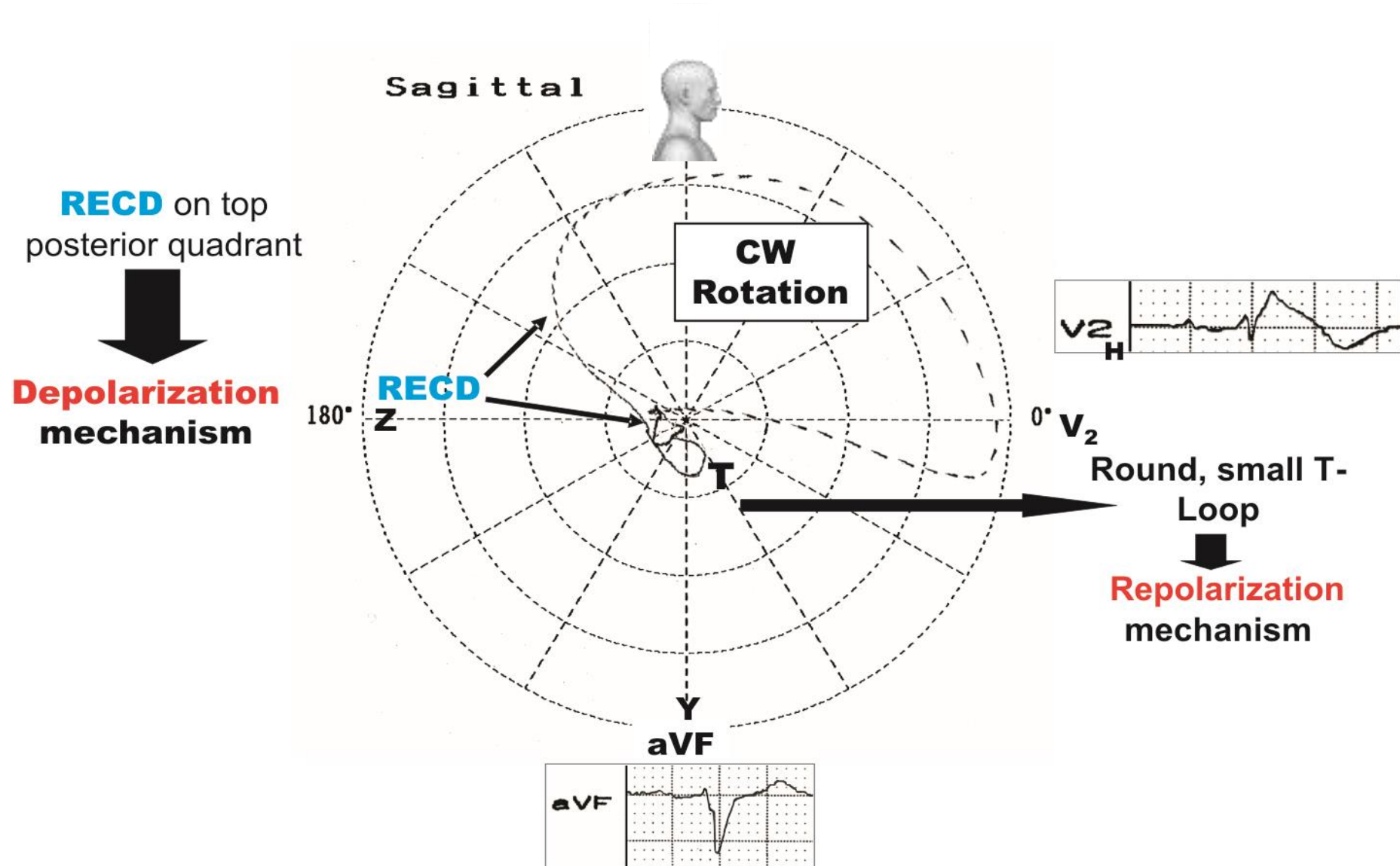
ECG/VCG correlation horizontal plane

Name: MK; **Age:** 38 y/o; **Gender:** Male; **Ethnic Group:** Asian; **Weight:** 68 kg; **Height:** 1.70 m.



ECG/VCG correlation in the right sagittal plane

Name: MK; Age: 38 y/o; Gender: Male; Ethnic Group: Asian; Weight: 68 kg; Height: 1.70 m

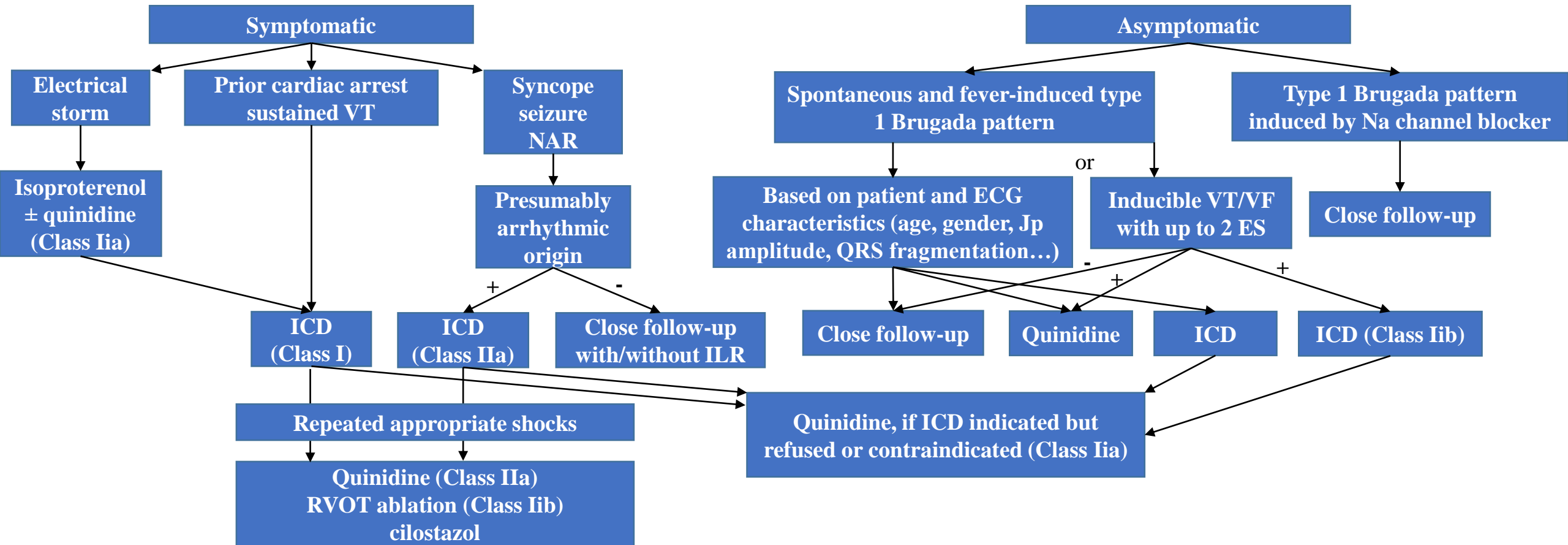


Indication for therapy of patients with BrS. Recommendations with class designation are taken from Priori et al ([Antzelevitch 2016](#)).

Recommendations without class designation are derived from unanimous consensus of the authors

Type 1 Brugada pattern

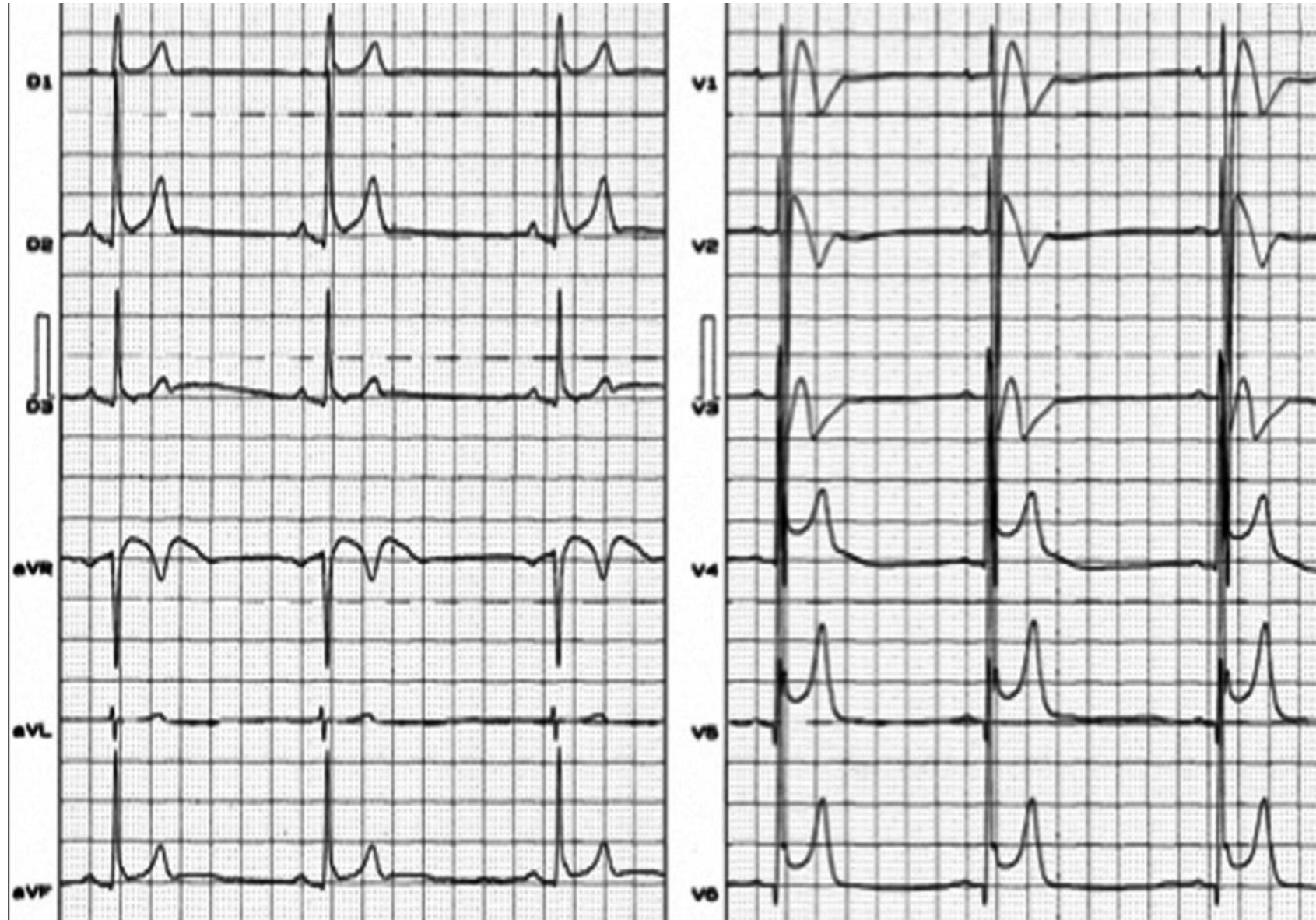
- Avoid drugs that may induce or aggravate ST segment elevation in right precordial leads (www.brugadadrugs.org)
- Avoid cocaine and excessive alcohol intake
- Immediately treat fever with antipyretic drugs (Class I)



ES: extra stimulus at right ventricular apex; ICD: implantable cardioverter defibrillator; ILR: implantable loop recorder; NAR: nocturnal agonal respiration; RVOT: right ventricular outflow tract; VF: ventricular fibrillation; VT: ventricular tachycardia

Diagnosis of BrS (proposed Shangai score system)	Points
I. ECG (12 lead/ambulatory)	
A) Spontaneous type 1 BrP at conventional or high levels	3.5
B) Fever induced type 1 BrP at conventional or high levels	3
C) Type 2 or 3 BrP that converts with provocative drug challenge	2
*Only award points once for highest score within this category. One item from this category must apply.	
II. Clinical history*	
A) Unexplained cardiac arrest documented VF/polymorphic VT	3
B) Nocturnal agonal respirations	2
C) Suspected arrhythmic syncope	2
D) Syncope of unclear mechanism/unclear etiology	1
E) Atrial flutter/fibrillation in patients <30 years without alternative etiology	0.5
*Only award points once for highest score within this category. One item from this category must apply.	
III. Family history	
A) First or second degree relative with definitive BrS	2
B) Suspicious SCD (fever, nocturnal, Brugada aggravating drugs) in a first or second degree relative	1
C) Unexplained SCD <45 years in a first/second degree relative with negative autopsy	0.5
*Only award points once for highest score within this category. One item from this category must apply.	
IV. Genetic test result	
A) Probable pathogenic mutation in BrS susceptibility gene	0.5
Score (requires at least one ECG finding) ≥3.5 points: probable/definitive BrS; 2-3 points: possible BrS; <2 points: nondiagnostic	

Overlapping between BrS and ERS



Twelve-lead ECG from the same 20-year-old man, recorded 72 hours later. The ERP persists, and there is now sinus bradycardia with a Brugada type 1 ECG pattern (coved type) in leads V1 to V3. The ST-segment elevation seen in lead aVR has been identified as a potential high-risk marker for ventricular arrhythmia in patients with BrS.

Similarities between early repolarization syndrome and Brugada syndrome

	BrS	ERS	Possible mechanism(s)
Male predominance	Yes (>75%)	Yes (>80%)	Testosterone modulation of ion currents underlying the epicardial AP notch
Average age of first event	30-50	30-50	
Associated with mutation of rare variants in KCNJ8, CACNA1C, CACNB2, CACNA2D, SCNSA, ABCC9, SCN110A	Yes	Yes	Gain of function in outward currents (I_{K-ATP}) or loss of function in inward current (I_{Ca} or I_{Na})
Relatively short QT intervals in subjects with Ca channel mutations	Yes	Yes	Loss of function of I_{Ca}
Dynamic of ECG	High	High	Autonomic modulation of ion channel currents underlying early phases of epicardial AP
VF often occurs during sleep or at low level of physical activity	Yes	Yes	Higher level of vagal tone and higher levels of I_{to} at the slower heart rates
VT/VF trigger	Short-coupled PVC	Short-coupled PVC	Phase 2 reentry
Ameliorative response to cilostazol	Yes	Yes	Increase I_{Ca} reduced I_{to} due to slow recovery from inactivation
Effect of Na channel blockers on unipolar epicardial electrogram	Augmented J waves	Augmented J waves	Outward shift of balance of current in the early phases of epicardial AP
Fever	Augmented J waves	Augmented J waves (rare)	Accelerated inactivation of I_{Na} and accelerated recovery of I_{to} from inactivation
Hypothermia	Augmented J waves mimicking BrS	Augmented J waves	Slower activation of I_{Ca} leaving I_{to} unopposed. Increased phase 2 reentry but reduced pVT due to prolongation of AP duration.

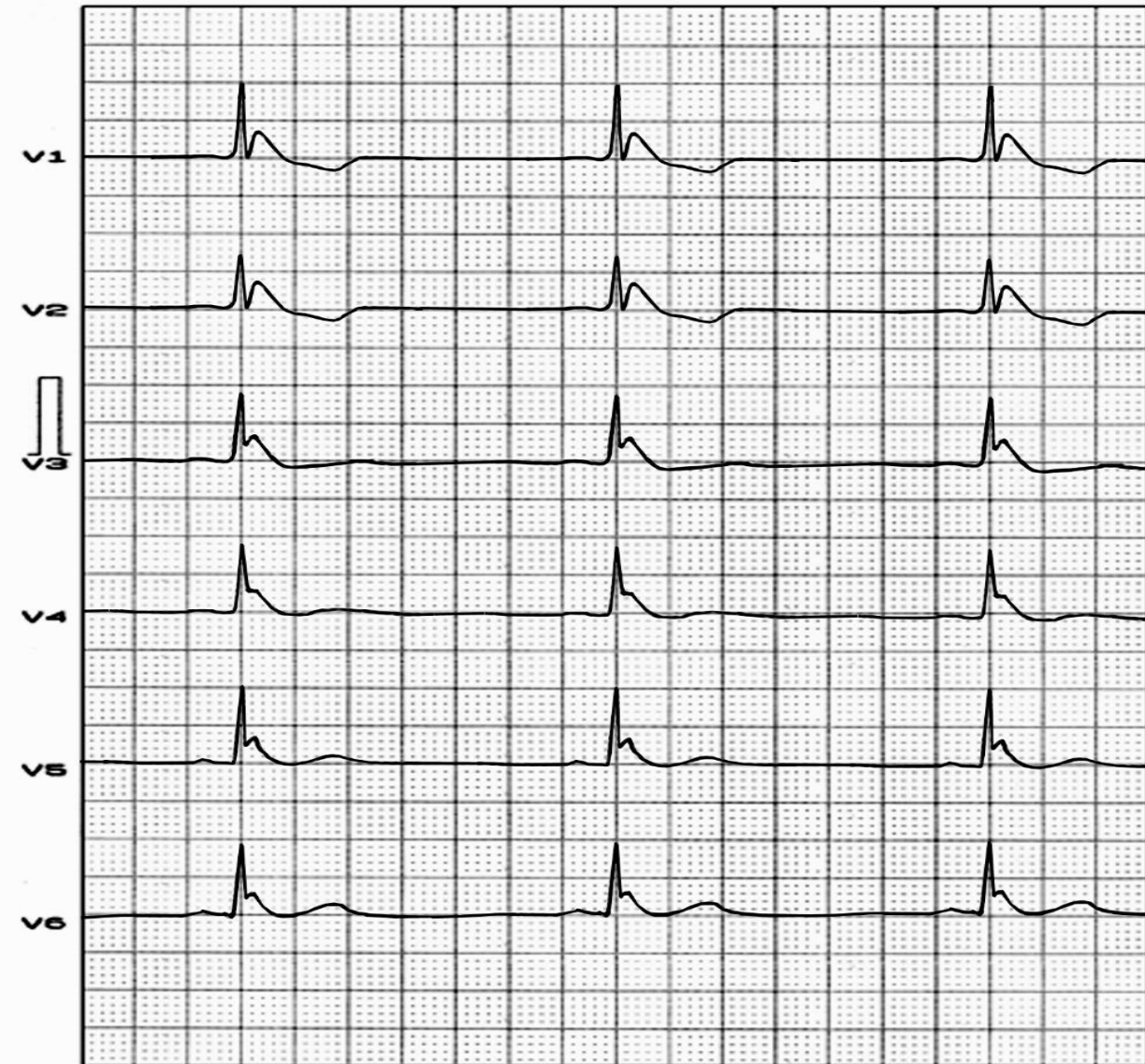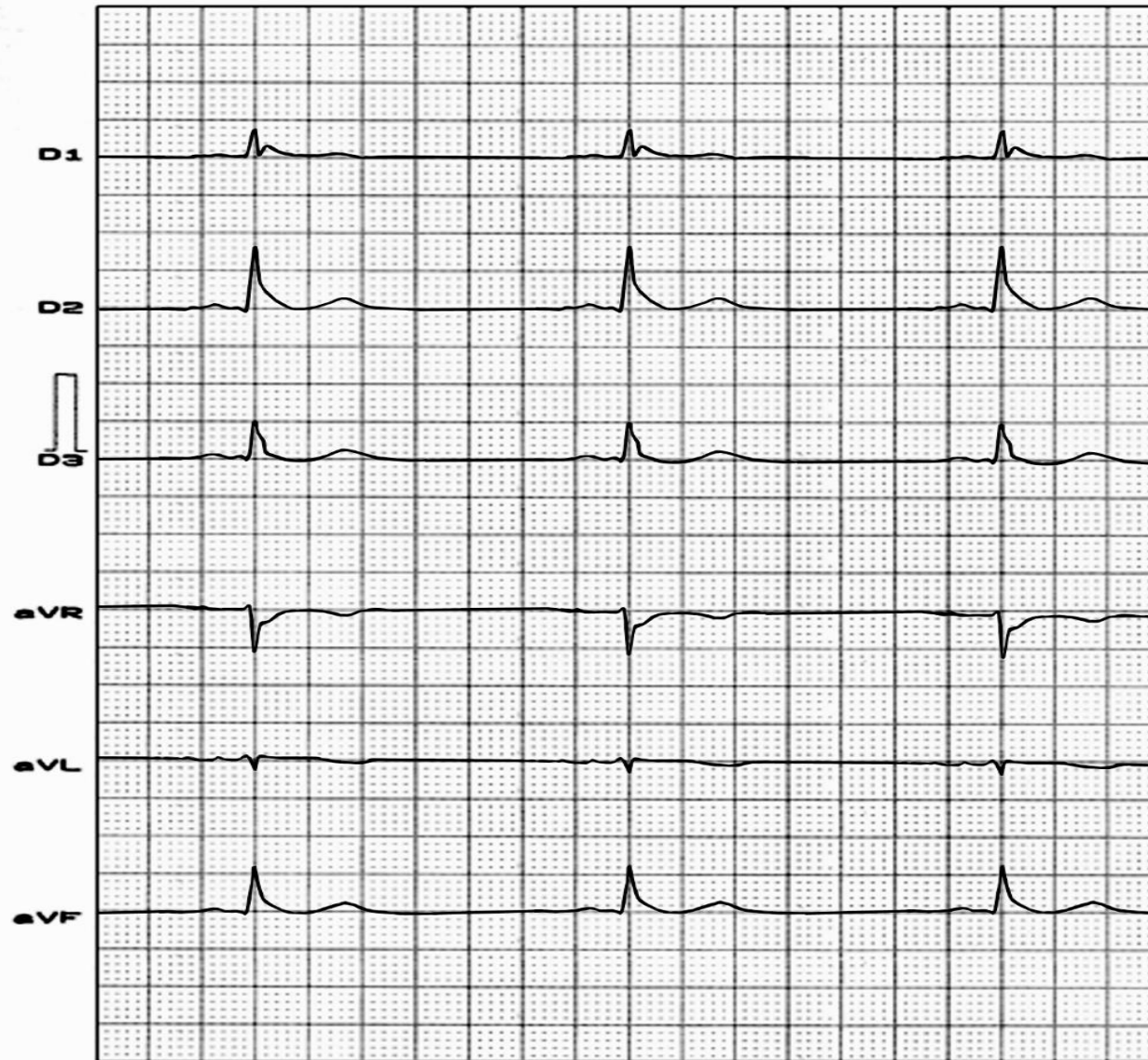
Differences between BrS and ERS

	BrS	ERS	Possible mechanism(s)
Region most involved	RVOT	Inferior LV wall	Higher levels of I _{to} and/or differences in conduction
Leads affected	V1-V3	II, III, aVF, V4-V6, I, aVL	Both inferolateral
Regional difference in prevalence	Asia	Europe	
Incidence of late potentials in signal average ECG	Higher	Lower	
Prevalence in atrial fibrillation	Higher	Lower	
Effect on Na channel blocker on ECG	Increased J wave	Reduced J wave	Reduction of J wave in the setting is thought to be due largely to prolongation of QRS. Accentuation of repolarization defects predominates in BrS, whereas accentuation of depolarization defects predominates in ERS.
Structural changes, including mild fibrosis and reduced expression of Cx43 in RVOT or fibrofatty infiltration in cases of ARVC. Imaging studies have also revealed wall motion abnormalities and mild dilatation in the region of RVOT	Higher in some forms of the syndrome	Unknown	Some investigators have hypothesized that some of these changes may be the result of rater than the cause of the BrS substrate which may create a hibernation-like state due to loss of contractility in the RVOT secondary to loss of the AP dome.

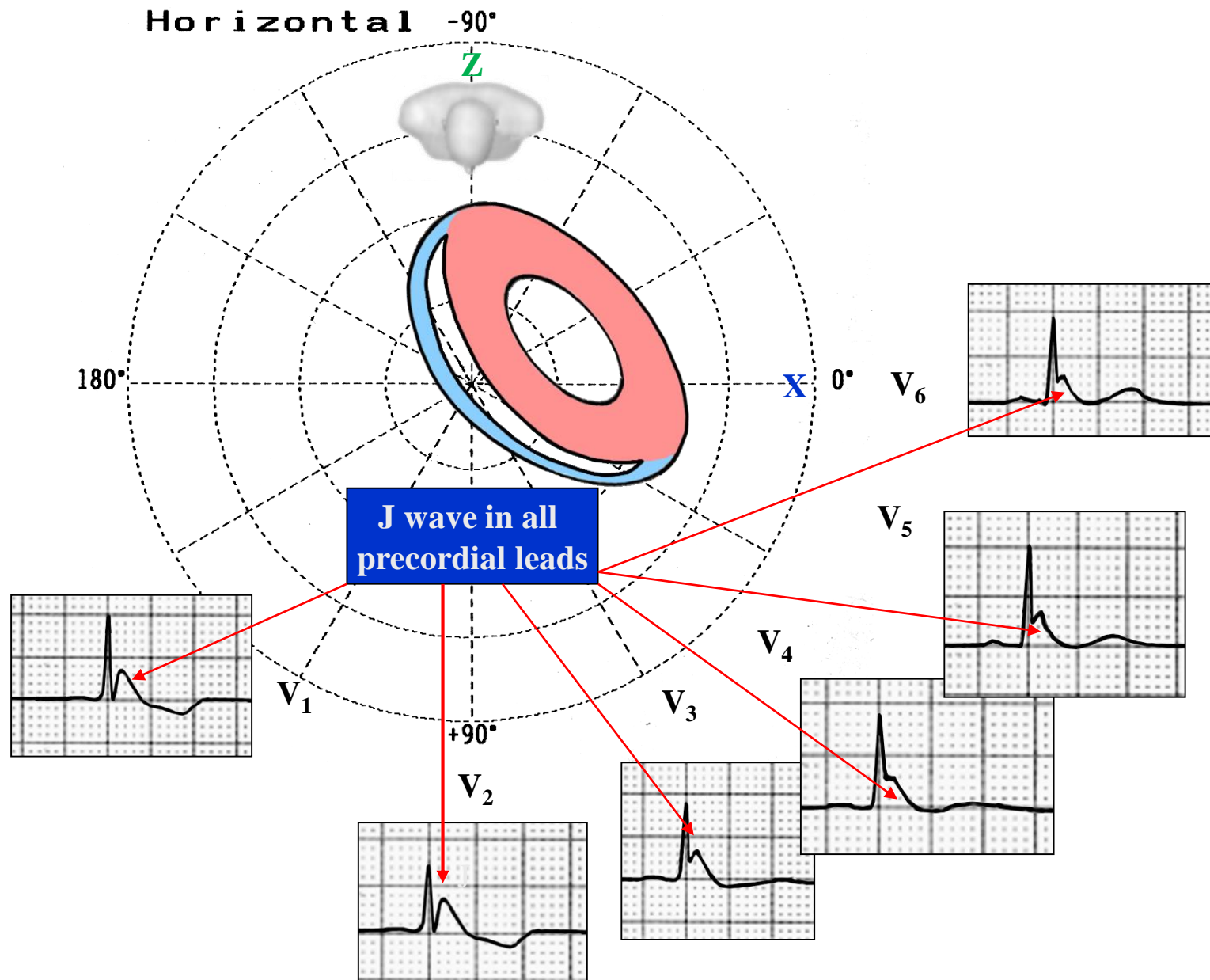
AP: Action potential; ARVC: Arrhythmogenic Right Ventricular Cardiomyopathy; BrS: Brugada syndrome; ERS: Early Repolarization Syndrome; LV: Left Ventricle; PVC: Premature Ventricular Contraction; pVT: Polymorphic Ventricular Tachycardia; RVOT: Right Ventricular Outflow Tract; VF: Ventricular Fibrillation; VT Ventricular Tachycardia

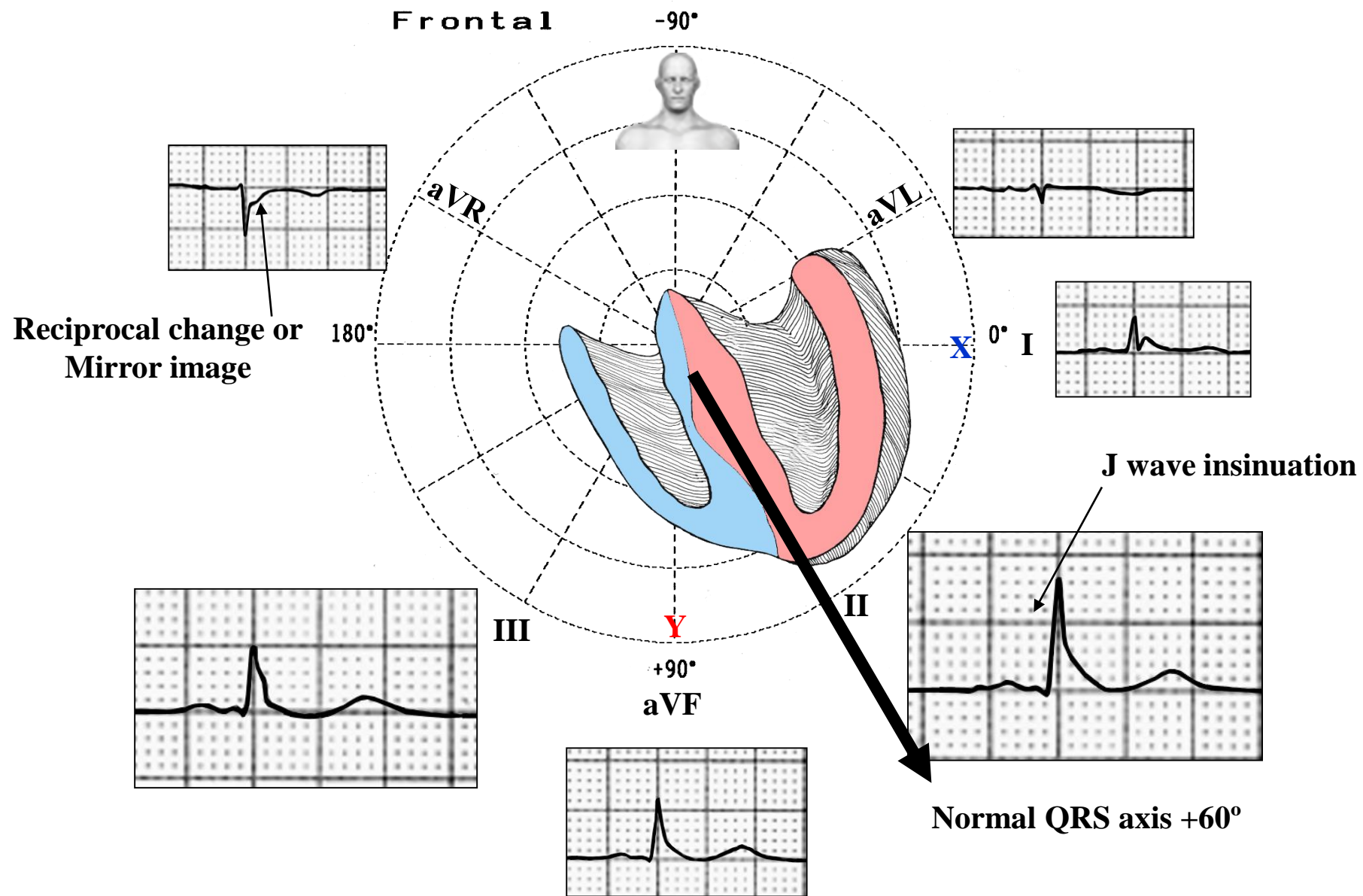
Differential diagnosis of J wave and intraventricular conduction defect–mediated notch syndromes (IVCD)		
	J-wave	IVCD-induced end QRS notch
Male predominance	Yes	No
Average age at initial presentation	Young adults	Old adults
Most common morphology	Dome-like smooth appearance	Relatively sharp appearance
Response to change in heart rate	Bradycardia- and pause-dependent augmentation of J wave, which may be accompanied by T-wave inversion	Tachycardia and prematurity-dependent augmentation of the notch
Structural heart diseases	Rare	Common History of myocardial infarction and/or cardiomyopathy

Example of idiopathic ventricular fibrillation with “malignant” Early Repolarization Syndrome type 3

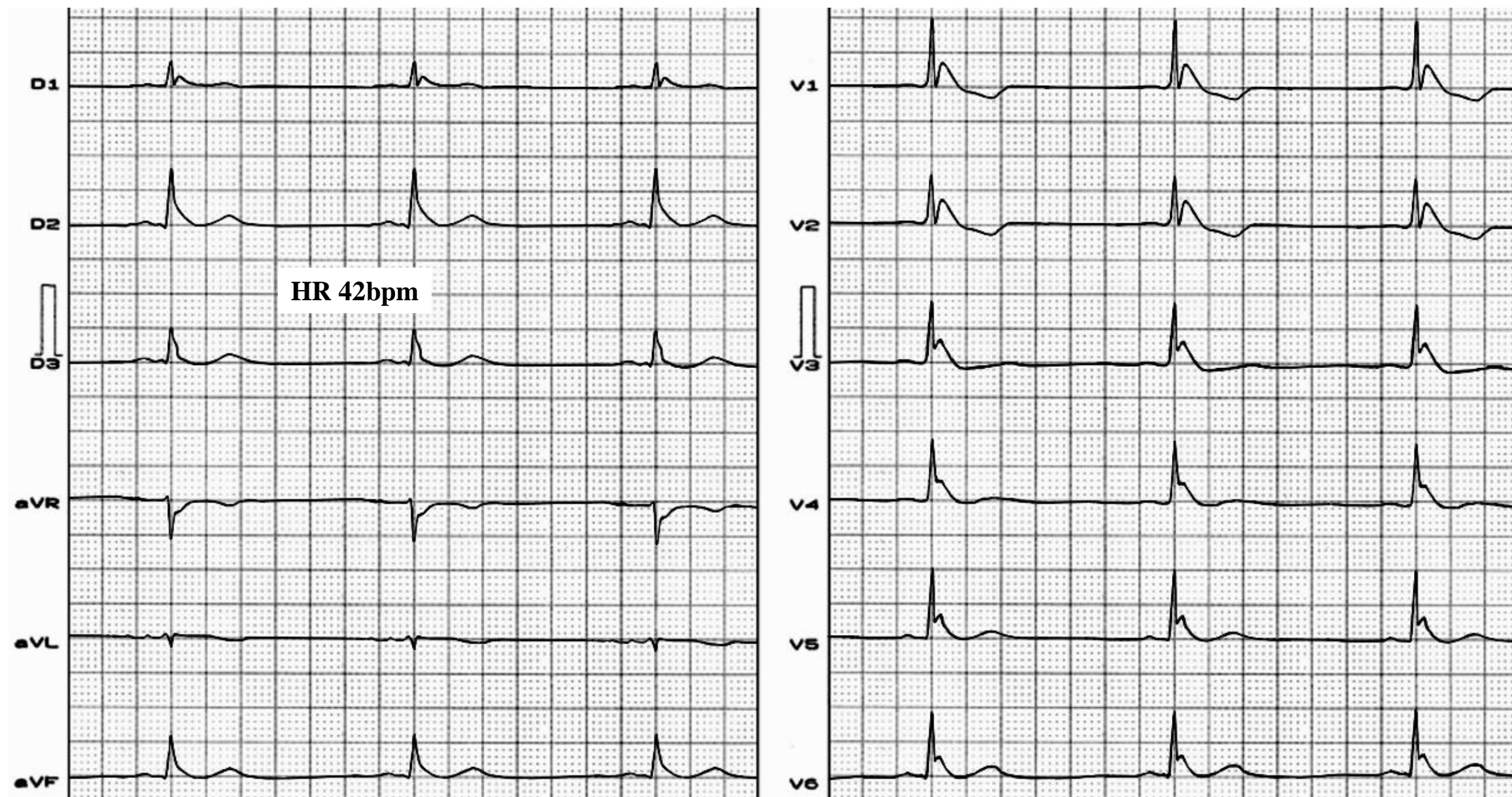


Classical case of ERS Type 3

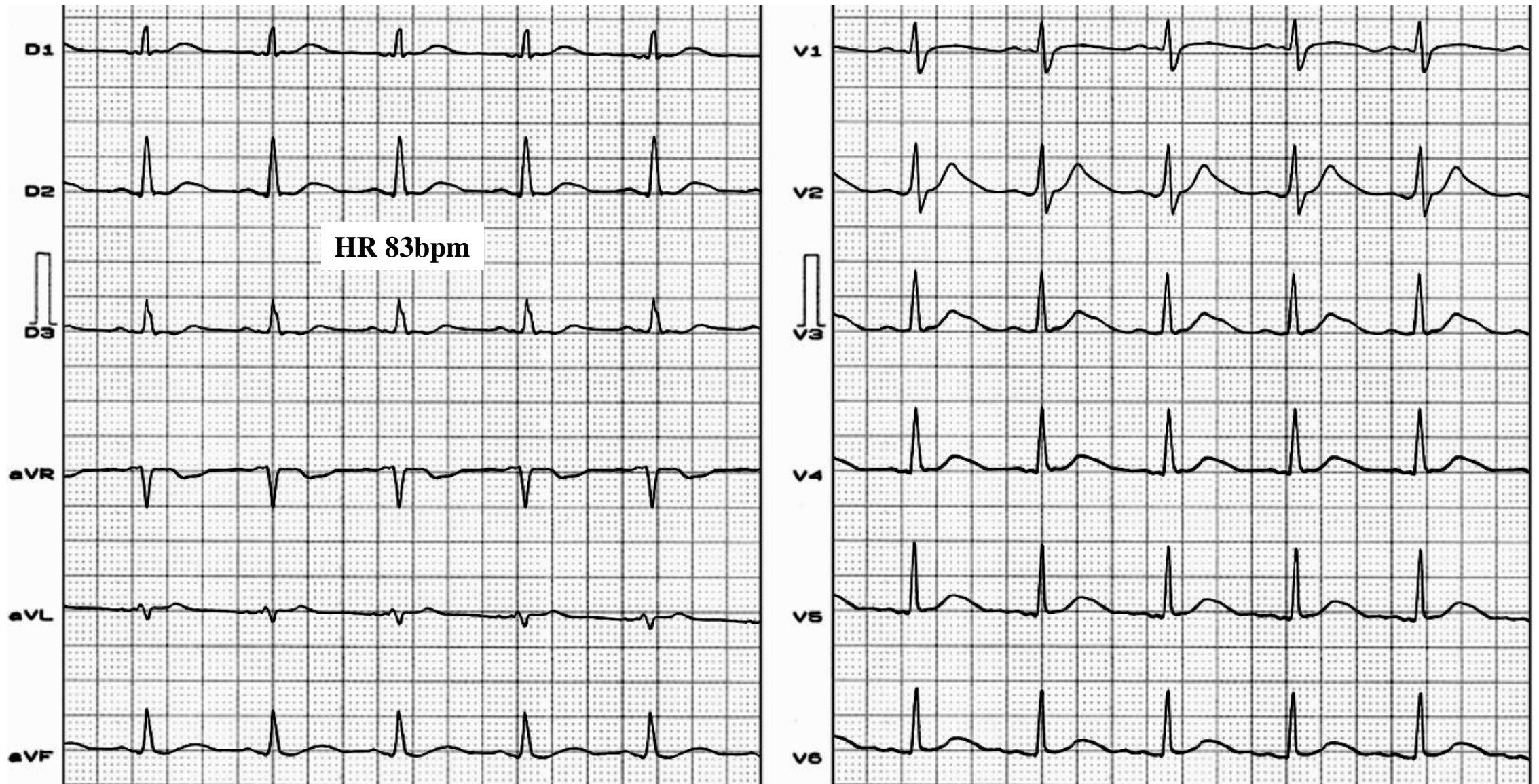




A: Basal tracing. We observe J-wave across all precordial and inferior leads.

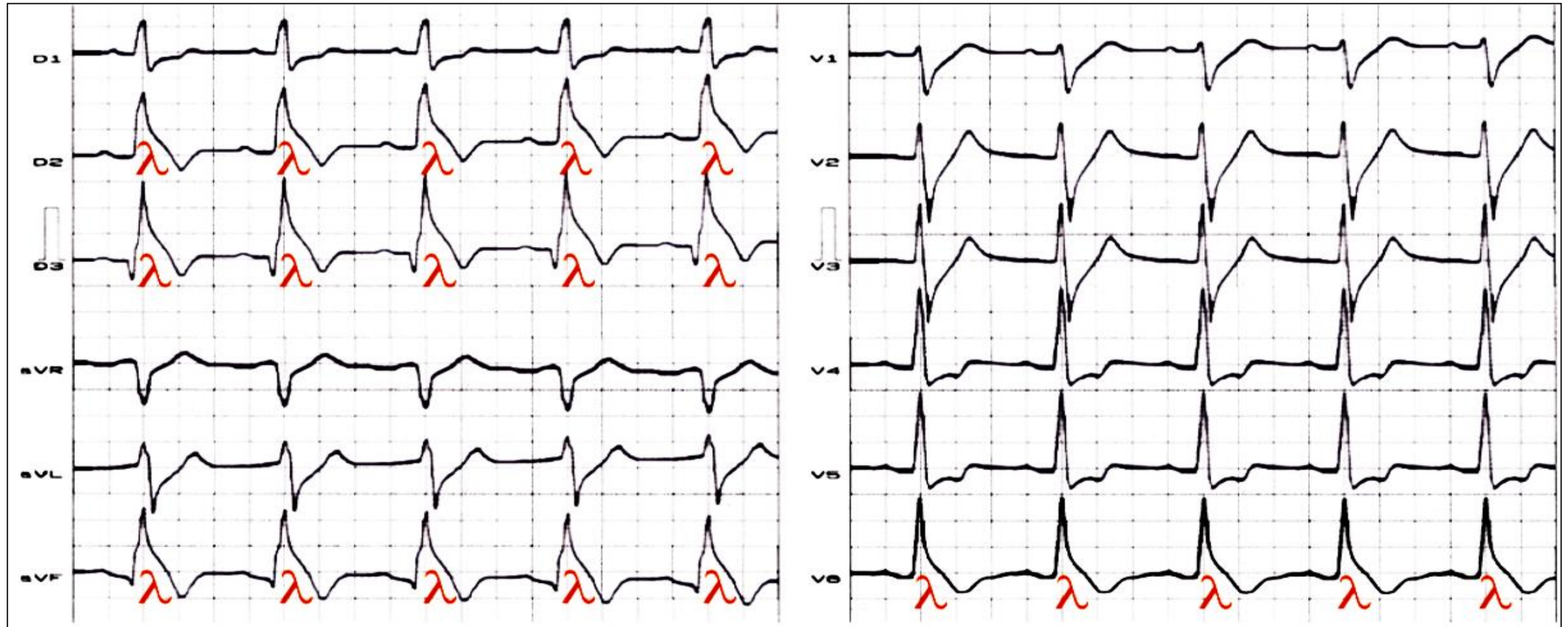


B: ECG after two days after oral quinidine 1500 mg/day



Comments: The drug reduces the magnitude of the Ito channel – mediator of phase 1 and consequently normalize the elevation of the ST segment. Additionally, it could improve repolarization due to its vagolytic effect (M2 muscarinic receptor block) and to the exacerbation of reflex sympathetic tone.

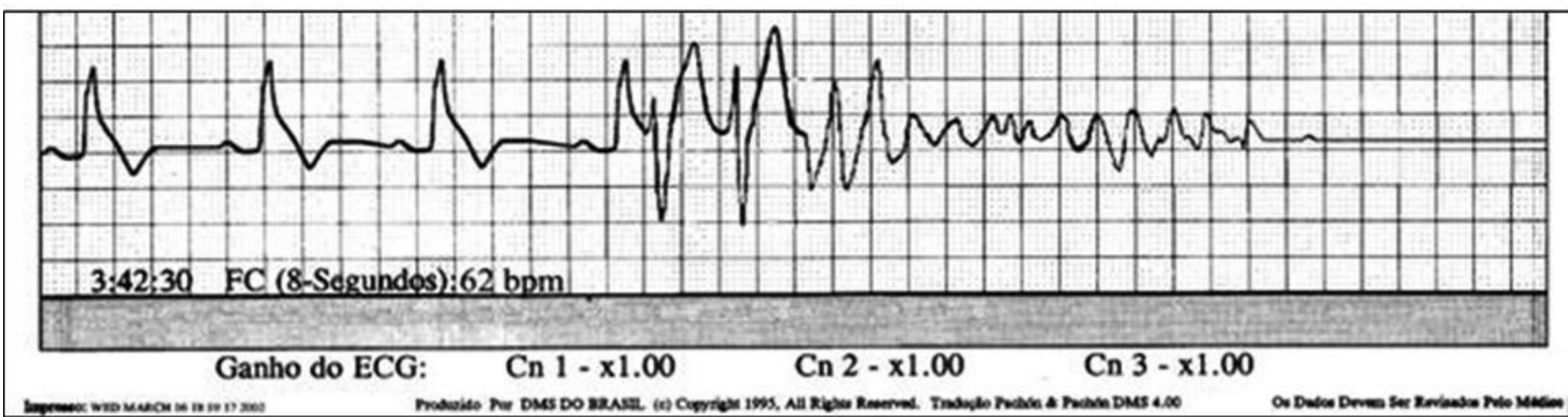
Convex upward J waves, with horizontal/descending ST segments or "lambda-wave" ST shape are suggestive of IVF with early repolarization abnormalities. Premature ventricular contractions with very short coupling and "R on T" phenomenon are characteristics with two pattern: When originate from right ventricular outflow tract left bundle branch block morphology and from peripheral Purkinje network, left bundle (**Pérez-Riera 2012**). The following ECG below belongs to a young Asian man with typical lambda wave in the context of J-wave syndromes type II.



The patient was a young symptomatic (repetitive syncope episodes) Thai man, with positive familial background of SCD in young first degree relatives. He died 24h after performing this ECG. The ECG shows persistent ST segment elevation in the inferior and low lateral precordial apical leads (V5-V6), associated with concomitant reciprocal or mirror image in the anteroseptal wall that was not modified with the use of sublingual nitrate in absence of hypothermia, electrolyte imbalance or ischemia (**Riera 2004**).

Typical PVT in atypical Brugada Syndrome

Name: YAS; **Gender:** M; **Age:** 26 y/o; **Ethnic group:** Asian; **Weight:** 64 kg; **Height:** 1.68 m; **Date:** May 03, 2002; **Time:** 3:42 A.M. (sleeping)



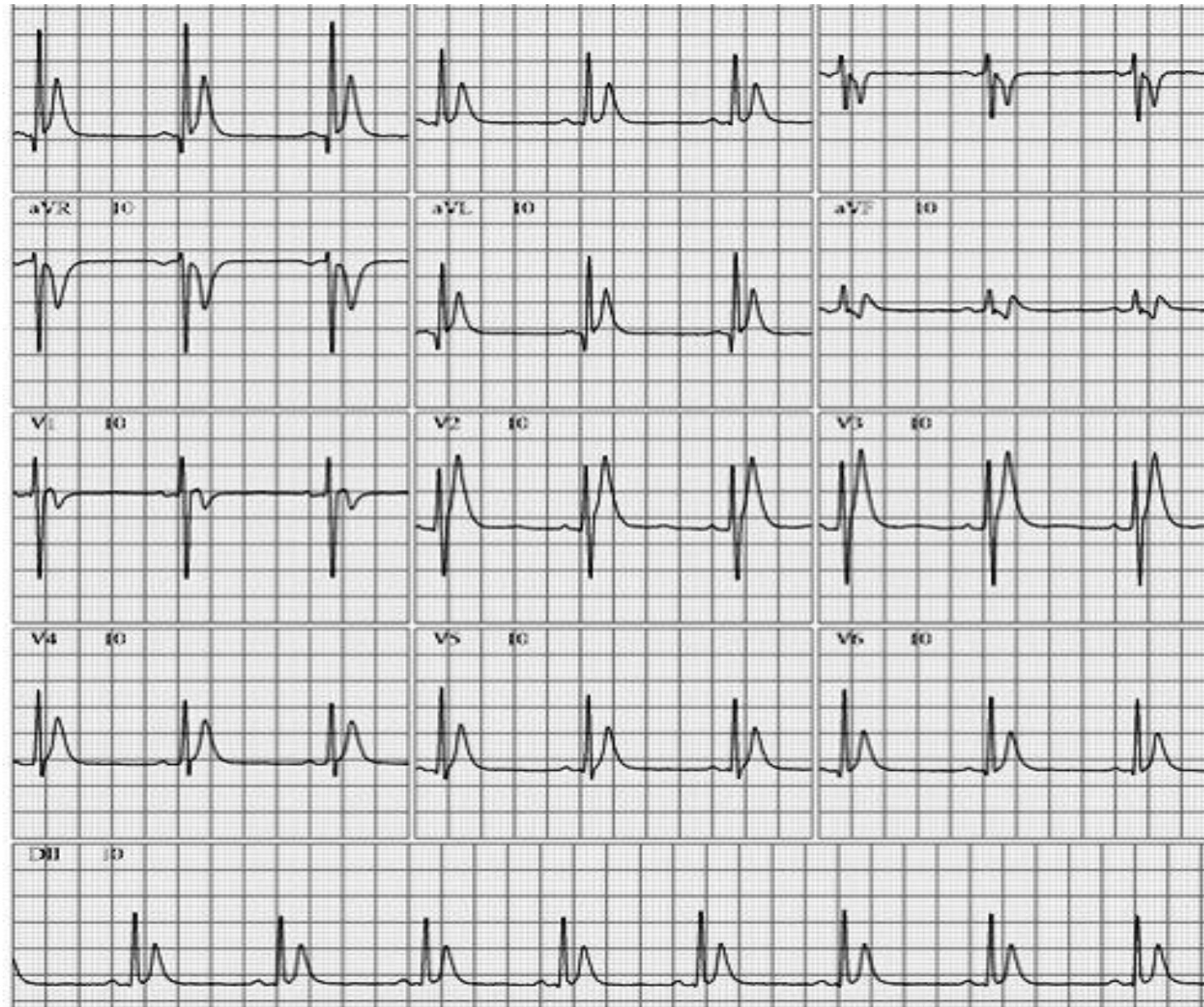
Long-term (Holter) ECG recording: sudden cardiac death by IPVT/VF with short coupling ending in cardiac arrest.

Short QT syndrome with early repolarization

The main features of congenital SQTS are:

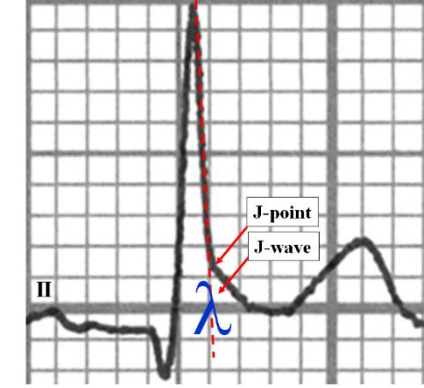
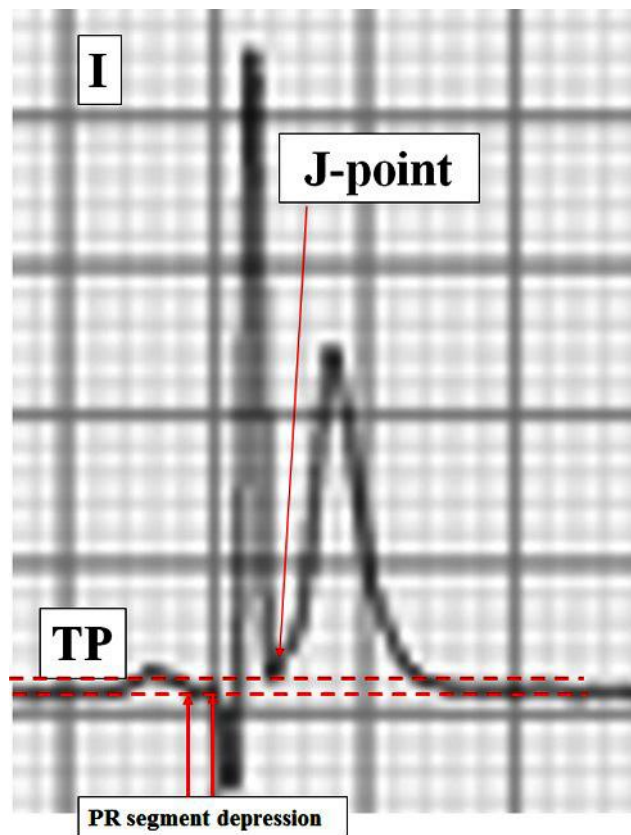
- Absence of structural heart disease
- Familial clinical-electrocardiographic entity
- Autosomal dominant inheritance or sporadic, and genetically heterogeneous
- Constant and uniform very short QT and QTc intervals (QTc interval ≤ 330 ms)
- Positive family history for sudden cardiac death (SCD)
- Manifested by syncope, sudden death, dizziness and high tendency to appearance of episodes of paroxysmal runs of atrial fibrillation (AF)
- The response to exercise testing is a slight reduction of the QT interval during the increase in heart rate.
- Short refractory periods and tendency for inducible AF and VF were seen in electrophysiology studies (EPSs).
- Autopsy did not reveal any structural heart disease

Name: MTC; **Sex:** F; **Age:** 54 y/o; **Date:** March 20, 2014; **Ethnic group:** Caucasian. ECG of one sister of the proband.

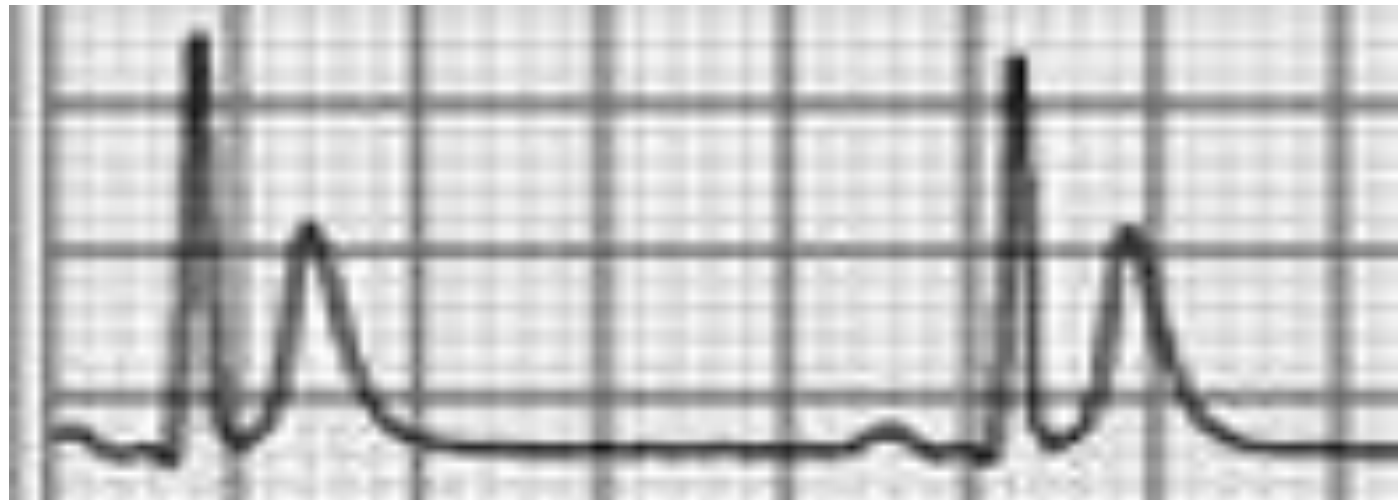


Clinical diagnosis: Congenital short QT syndrome with mutation in Caveolin-3 (SQT7).

ECG diagnosis: Sinus rhythm, HR = 68 bpm; P wave: ; $\hat{S}AP + 32^\circ$, PR interval duration: 120 ms, PR segment depression (>0.5 mm) in II and V5, absence of ST segment, positive-negative T wave or “minus-plus T wave sign” in aVF, and QT = 280 ms; QTc = 295 ms.

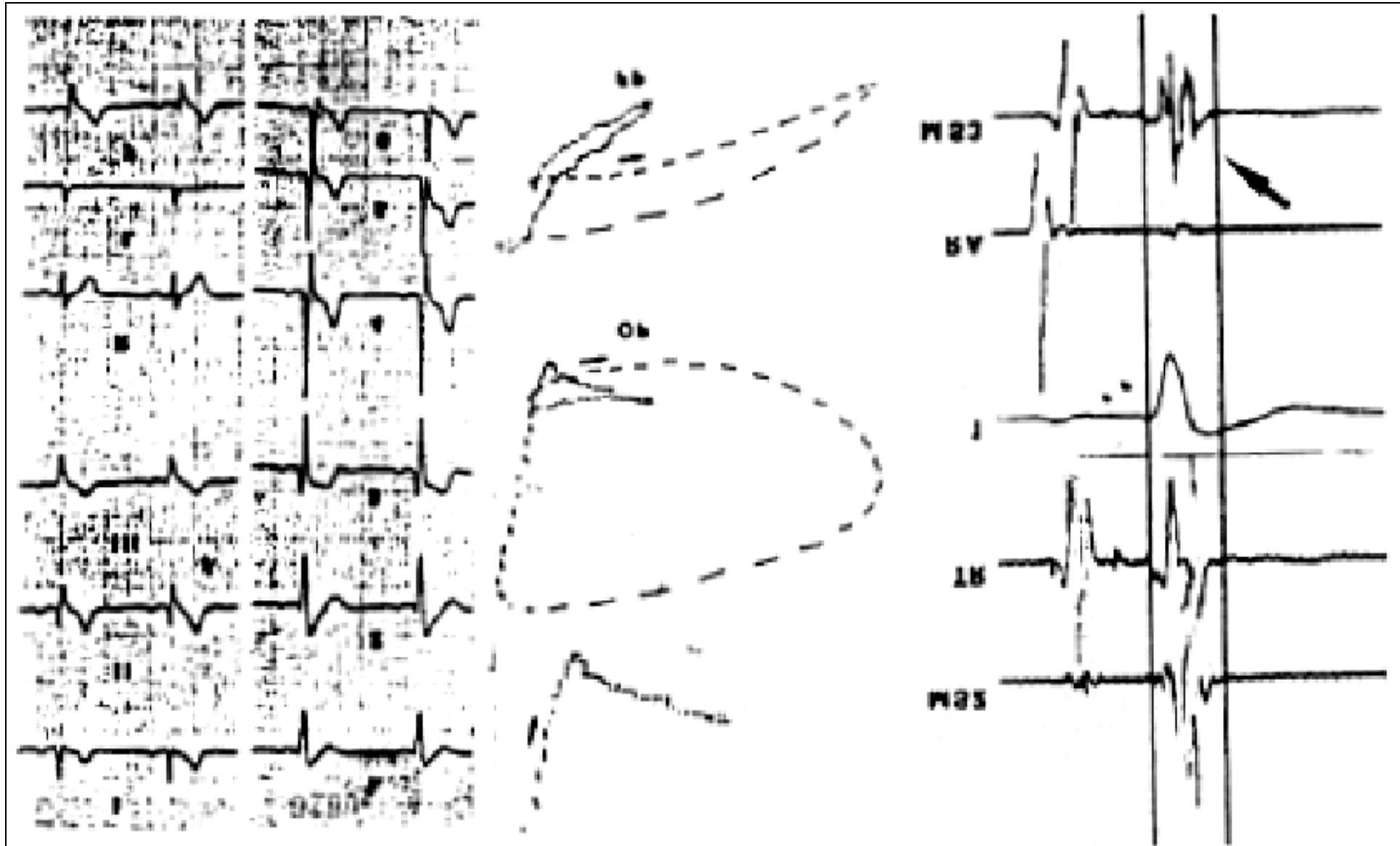


El primer punto de inflexión de la rampa descendente de la onda R es considerado el punto J real. En estos casos el método de la “línea tangente” es ideal. Elevación del segmento ST = 0,8 mm. Consideramos una variante tipo C atípica de patrón de repolarización precoz. El aspecto de lambda es un marcador de arritmias fatales.



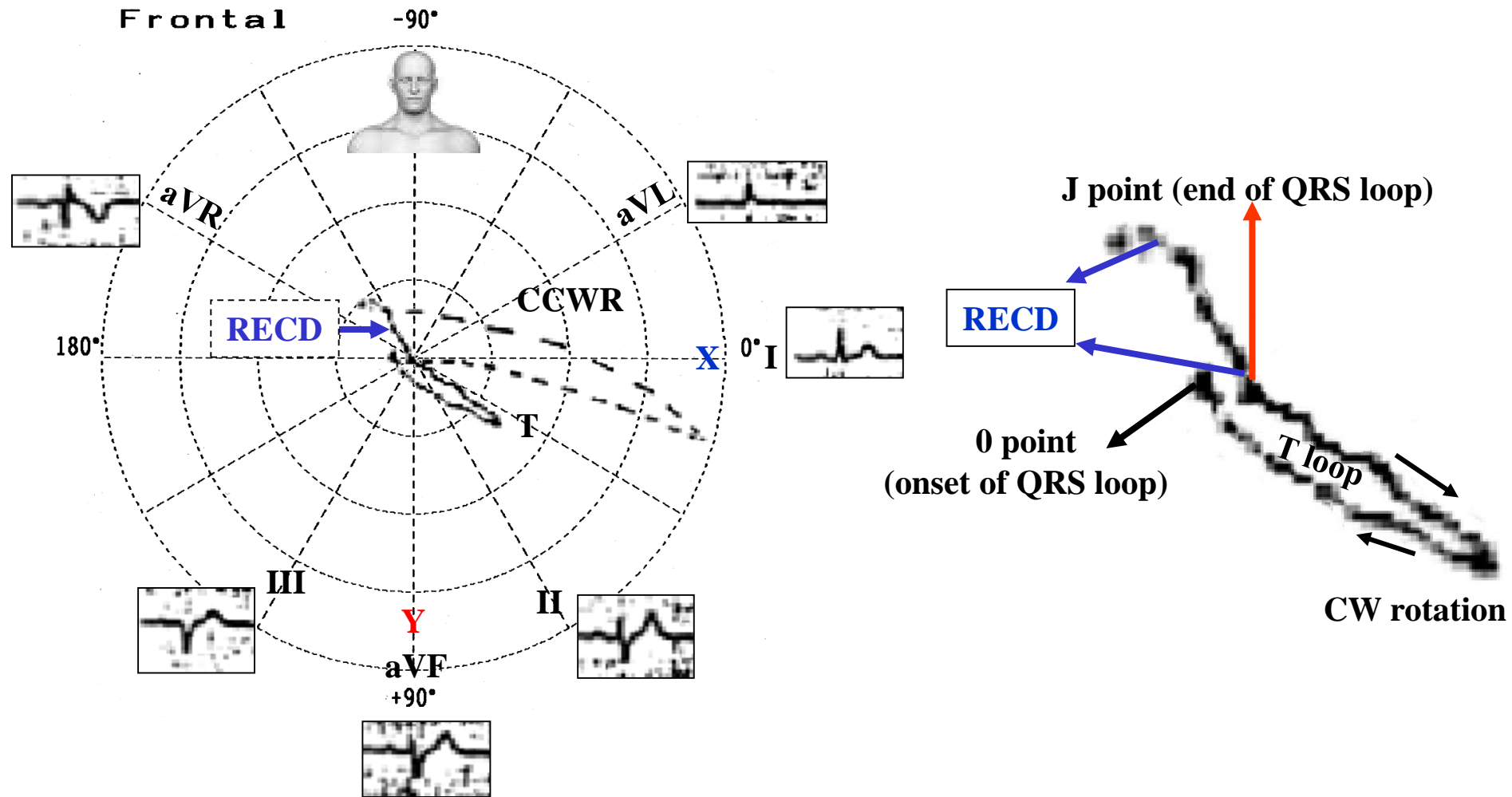
Concealed forms of arrhythmogenic dysplasia of the right ventricle

36-year-old patient, episode of VF



The authors interpreted this tracing as early repolarization pattern. Today we know that this is the typical type 1 ECG Brugada pattern, which from the vectorcardiographic point of view is diagnosed as **RECD** by one of the RB fascicles of the RBB (**Nava 1988**).

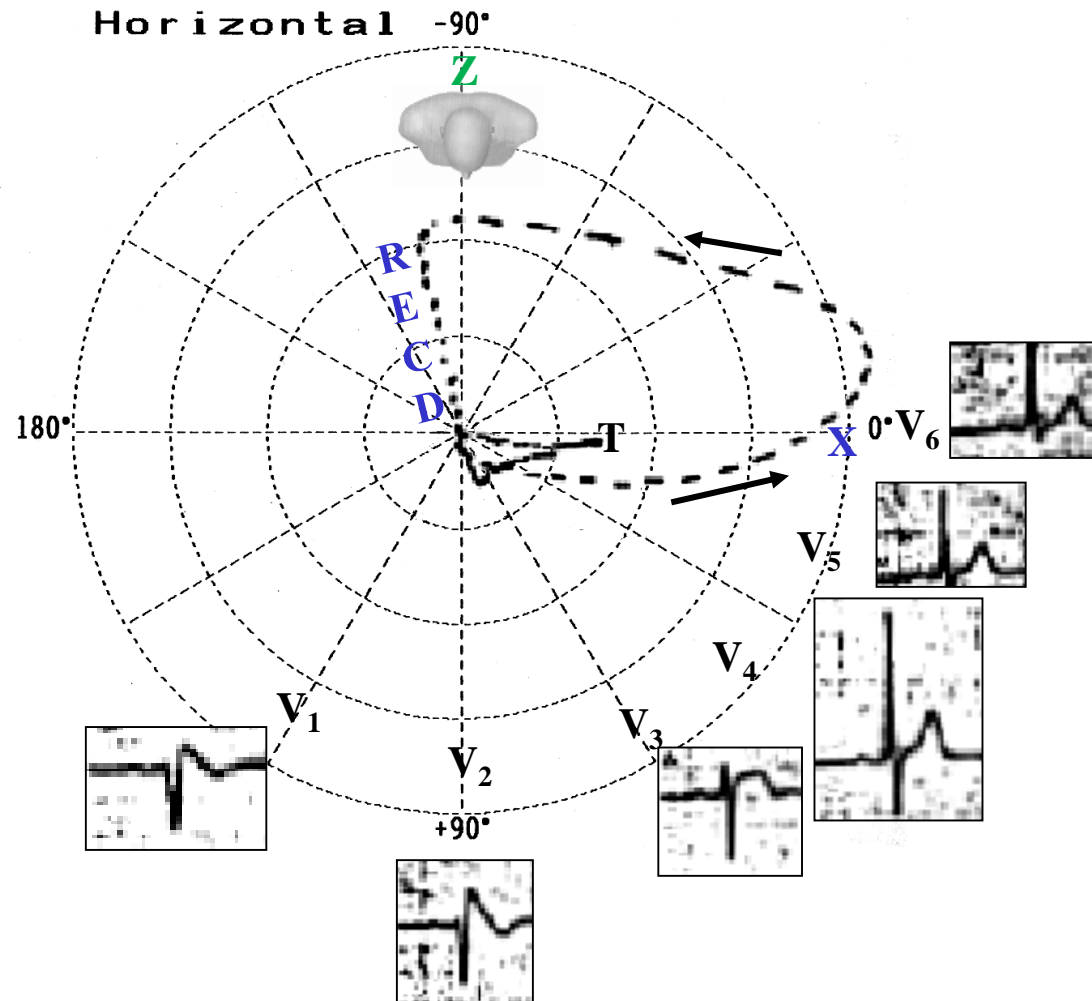
ECG/VCG correlation in the frontal plane, Dr. Nava's patient



SÂQRS with extreme shift in left superior quadrant between -30° and -90° . Initial 10 to 20 ms vector heading below and to the left, rapid passage from left to right between 50 to 60 ms. The 0 point (onset of QRS loop) does not match J point (end of QRS loop). Both points move away in a proportional way to the degree of ST segment shift.

Conclusion: RECD on right superior quadrant by the superior fascicle of the right branch, located in the RVOT.

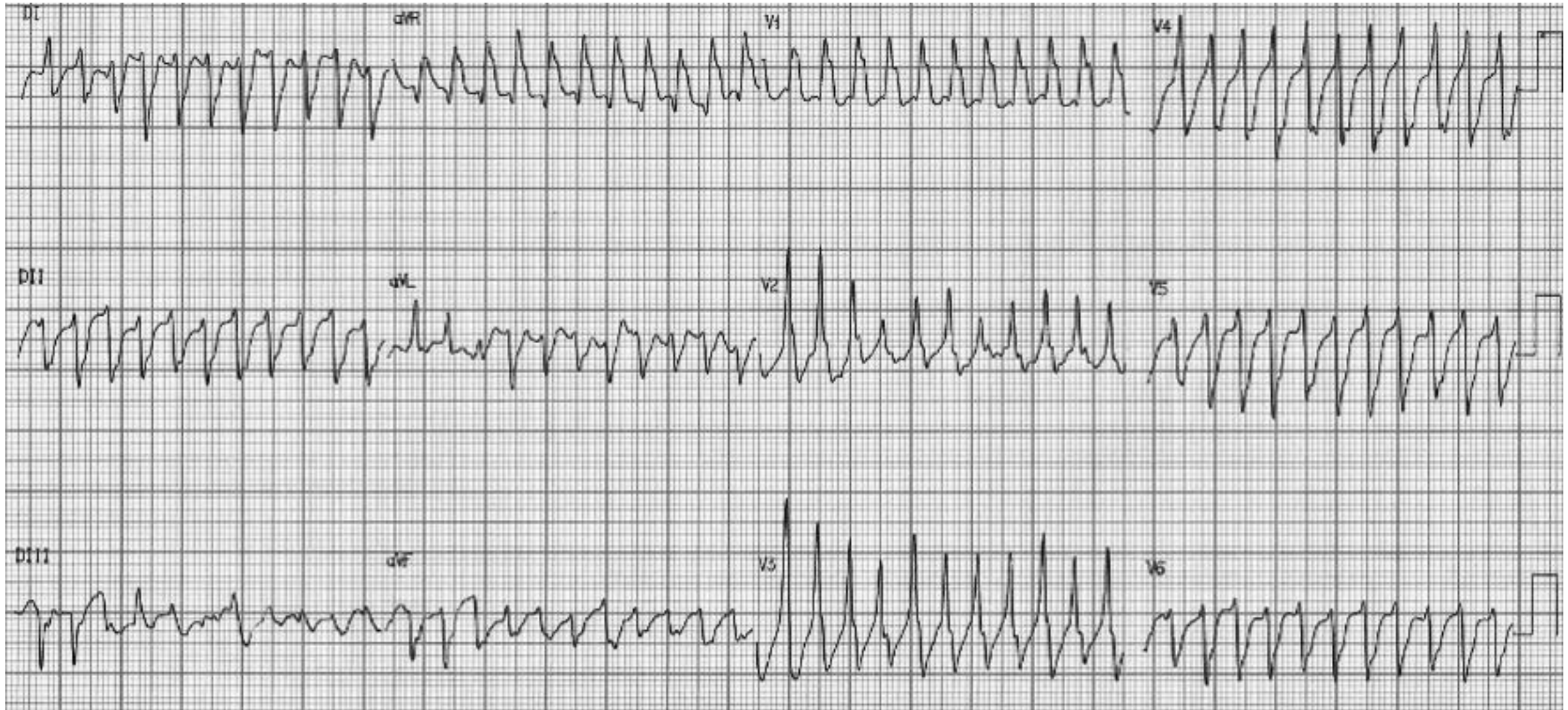
ECG/VCG correlation in the horizontal plane, Dr. Nava's patient



Initial 10 to 20 ms vector heading forward and leftward (typical right bundle branch block), CCW rotation and RECD located in the right posterior quadrant.

Conclusion: RECD with typical type 1 ECG Brugada pattern in the right precordial leads.

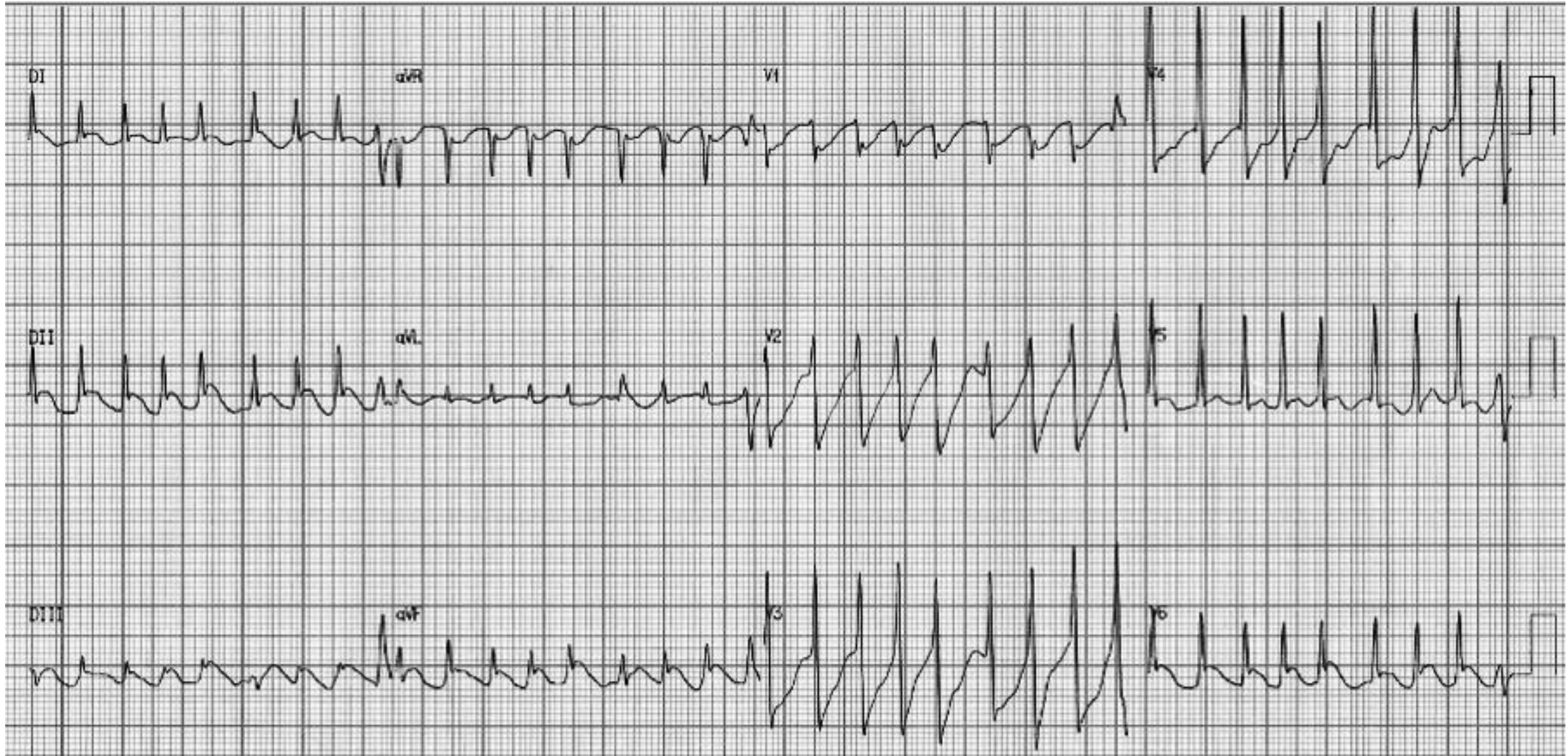
ECG at admission (08:32 A.M.) - Massive J-waves in the context of intracranial hemorrhage



Clinical diagnosis: 56-year-old female who presented to the emergency department with a decreased level of consciousness following intensification of a two-week long worsening headache. The patient's past medical history was significant for hypertension for which she was on no medication. On physical exam, she was unconscious (Glasgow Coma Scale (GCS) 6).

ECG diagnosis: Wide-complex QRS VT (160 ms) at a rate of 294 bpm with visible fusion and capture beats. Monophasic R-waves in leads V1–V2 indicated left ventricular origin.

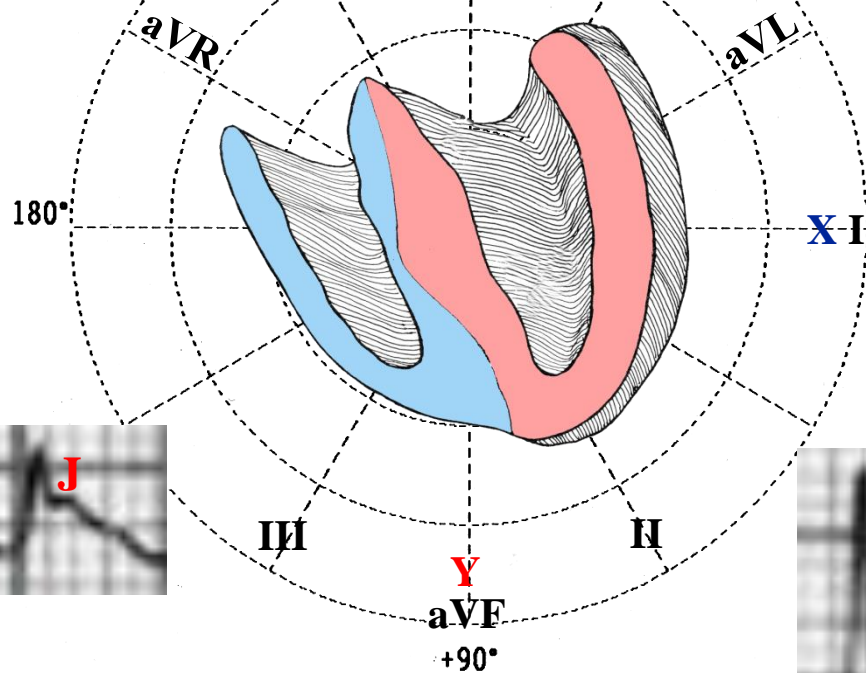
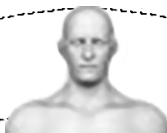ECG performed at 08:40 A.M. – after cardioversion



ECG diagnosis: The patient was electrically cardioverted and a second ECG performed after 8 minutes demonstrated rapid AF at 188 bpm and massive J-waves (maximal amplitude: 0.47 mV in lead II) with ST-segment elevation in the inferolateral leads and ST-segment depression in the anterior leads (V1–V4).


Frontal

-90°

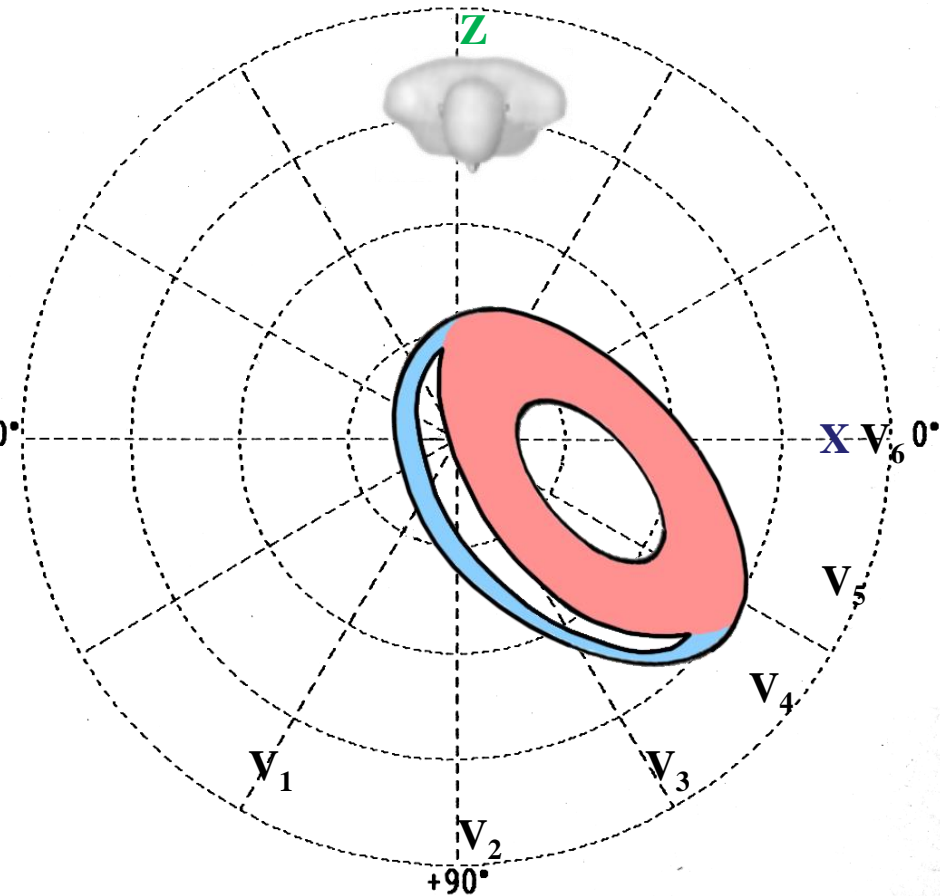


Horizontal -90°

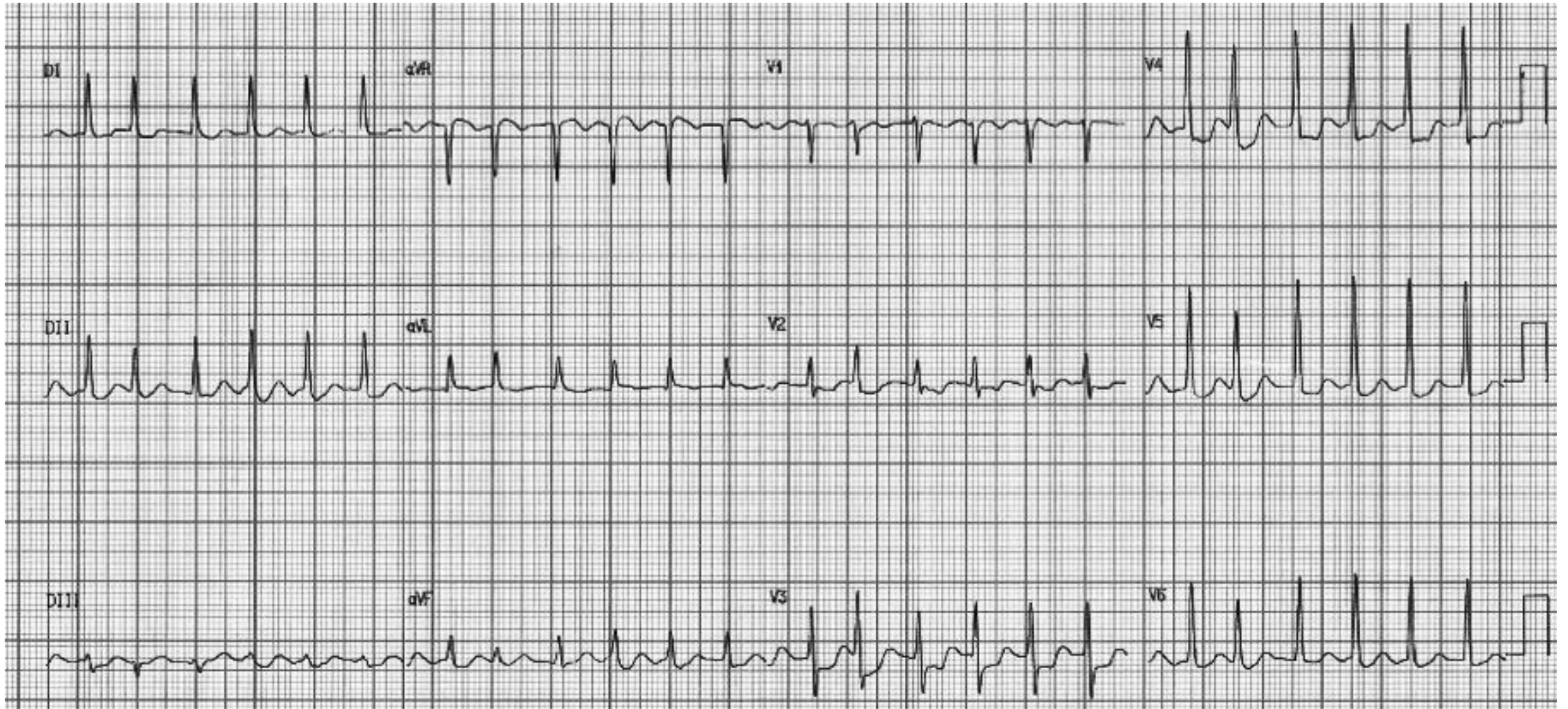
Z



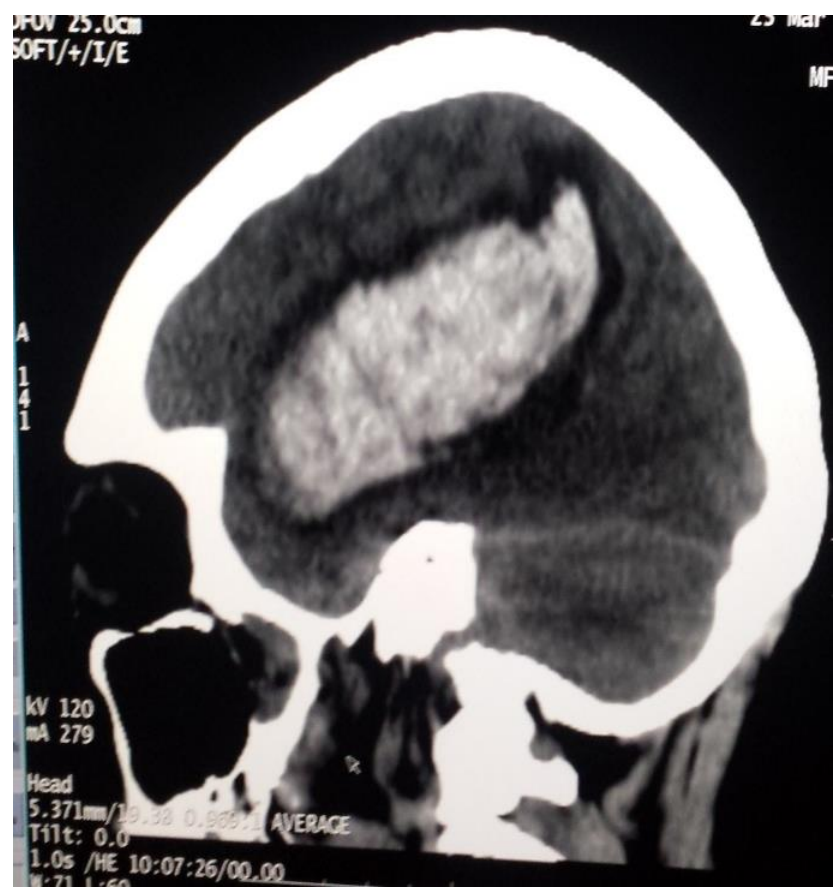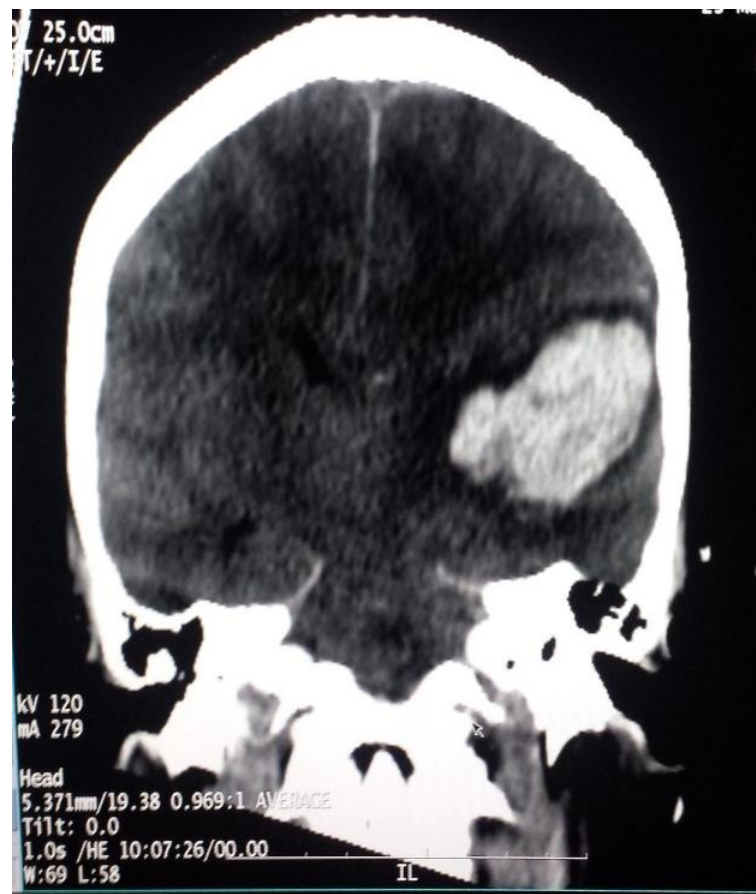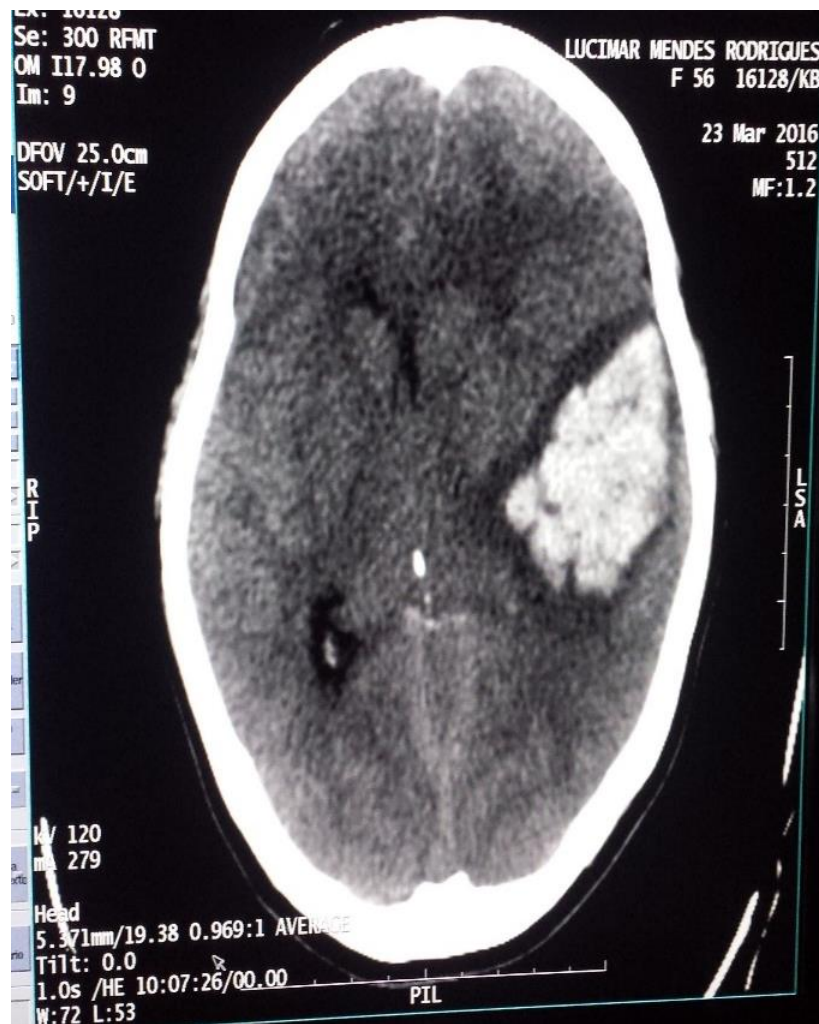180°



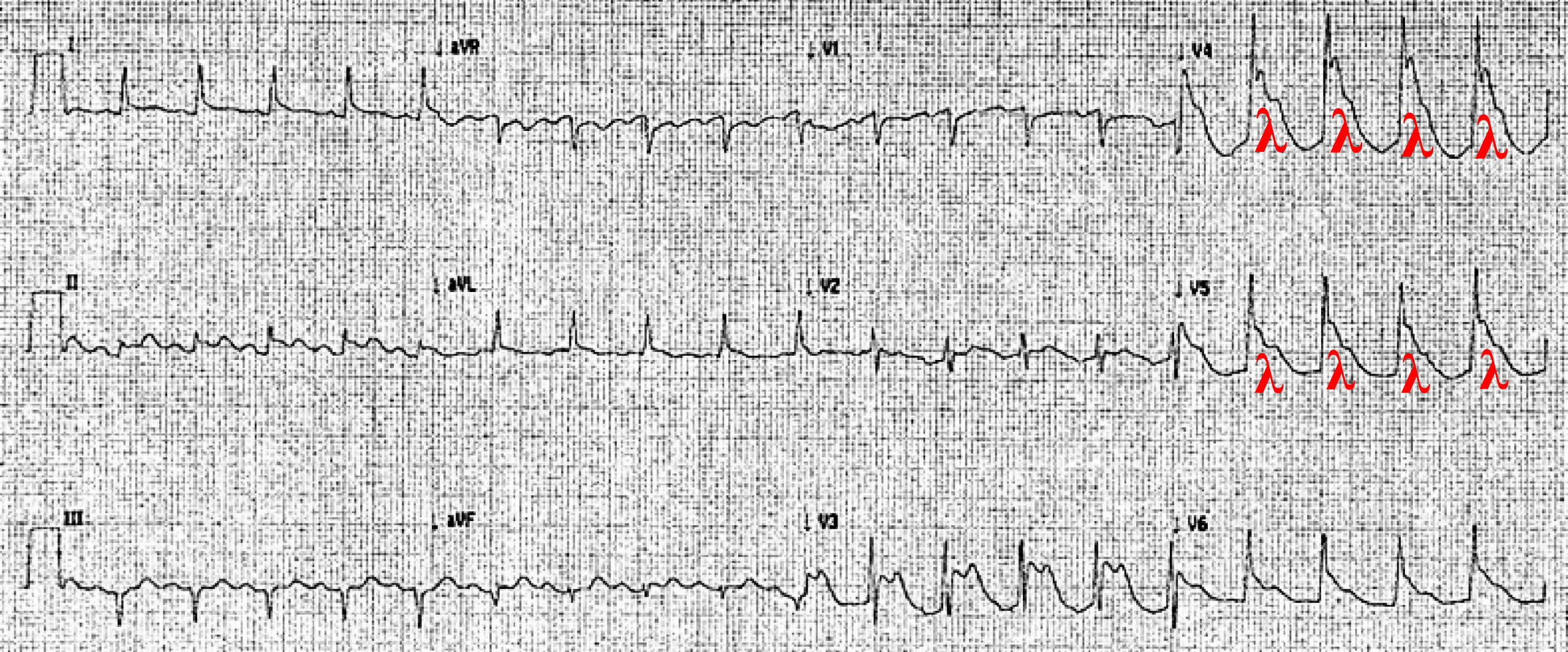
ECG performed at 09:57 A.M.



ECG diagnosis: Third ECG performed after 1 hour 17 minutes after the second one depicted AF at 145 bpm, ST-segment abnormalities and spontaneous disappearance of the J-waves.



Computed tomography of the brain showing a massive intraparenchymal hematoma.



Clinical diagnosis: ECG performed subsequent postictal confusion/hemiplegia with left-sided upper and lower extremity hemiparesis: cerebral and cardiac hypoperfusion (ischemia) following a postictal event with an increase in sympathetic tone.

ECG diagnosis: Lambda waves in the setting of cerebral injury such as trauma or hemorrhage; however, ECG evidence of a dynamically displaced J-point has not been previously described in the setting of postictal hemiplegia.

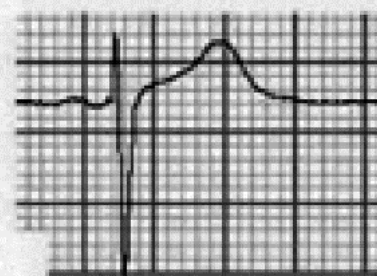
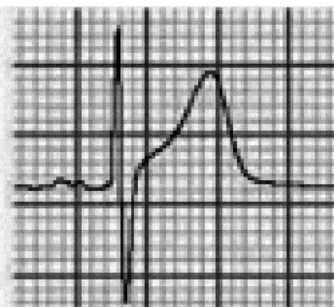
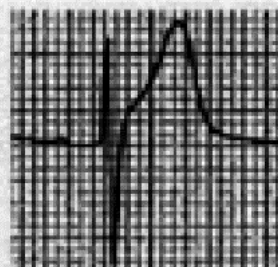

45 min

90 min

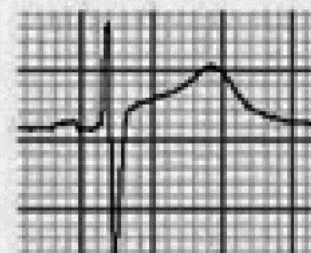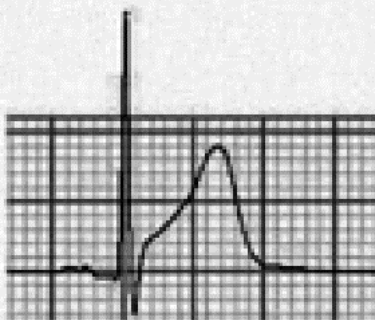
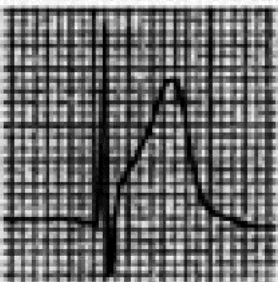

120 min

16 hours

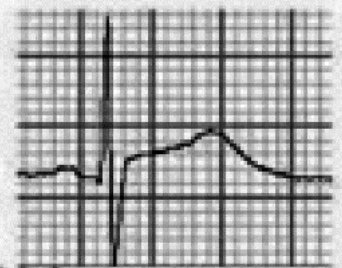
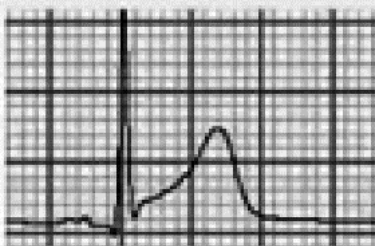
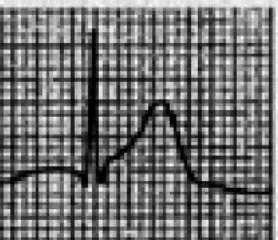

V3



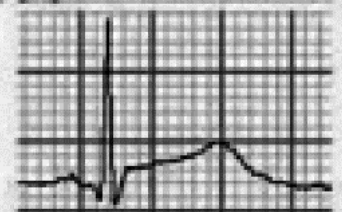
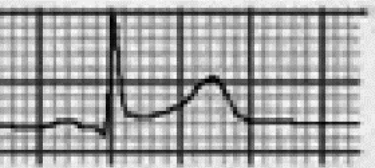
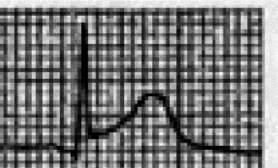
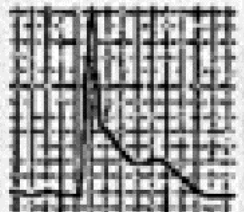
V4



V5



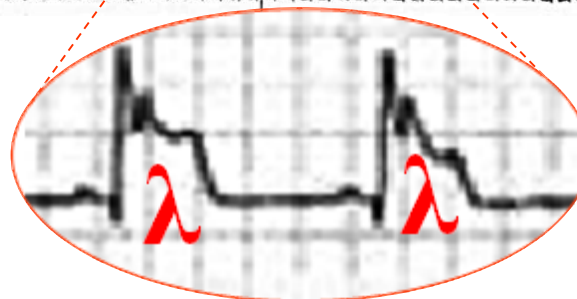
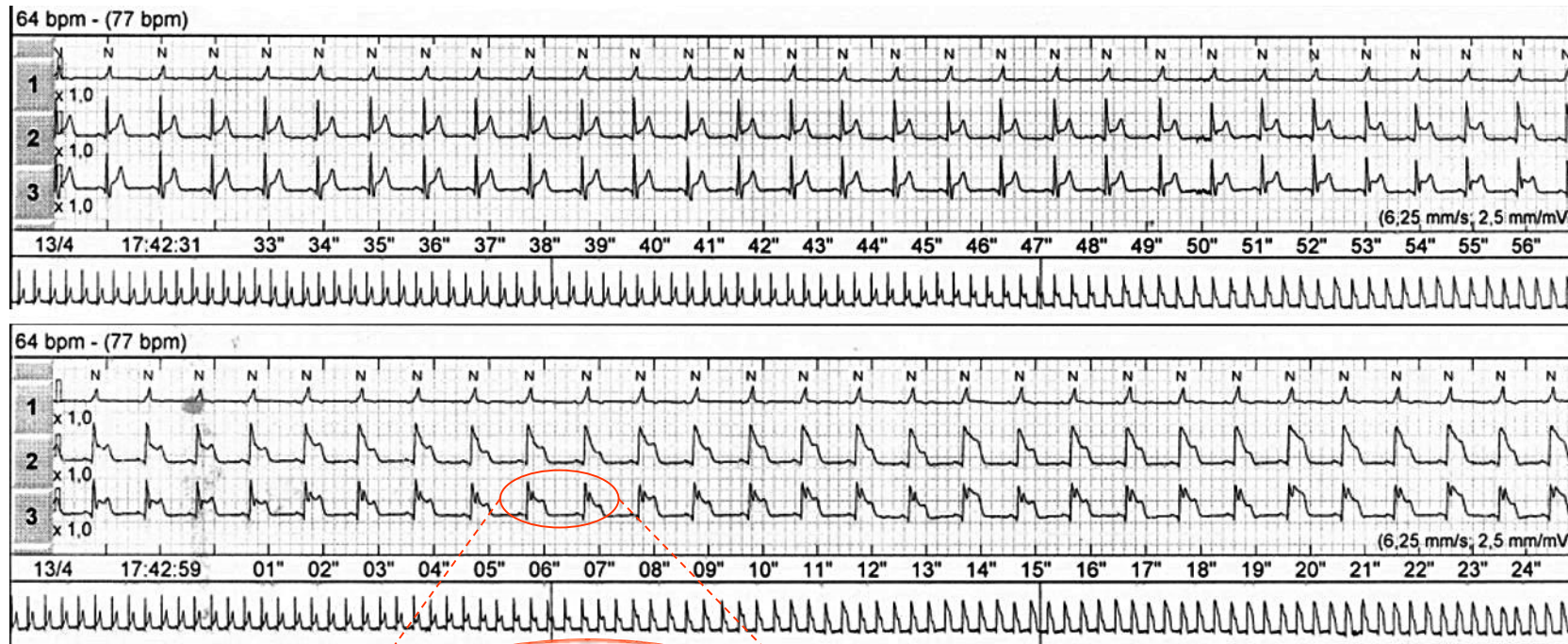V6



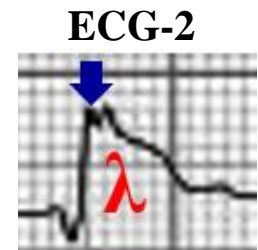
Ischemia- mediated VT/VF: Vasospastic angina, Prinzmetal J waves/ Ischemic J-Waves

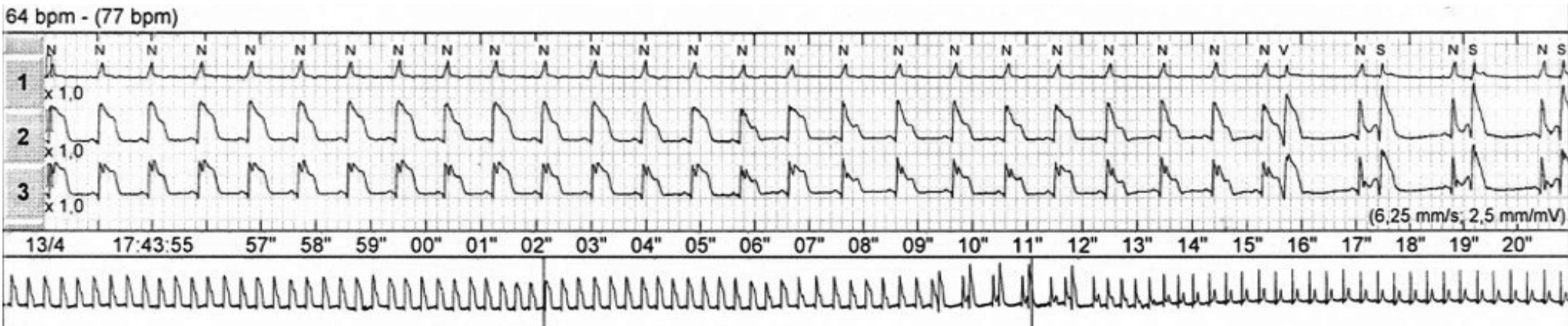
During myocardial ischemia in patients with Prinzmetal vasospastic angina. J-wave augmentations caused by myocardial ischemia during coronary spasms has lambda wave morphology. The presence and augmentation of J waves, especially prominent J waves with the characteristic ST-elevation patterns, were associated with VF (**Sato 2012**).

We show a continuous Holter monitoring below belonging to a man who had coronary revascularization a time ago, during an episode of angina and concomitant ST segment elevation and ischemic giant J-wave "lambda-like type" associated with Premature Ventricular Contractions with Bigeminy sequence and very short coupling. The PVCs disappear immediately after cessation of vasospastic ischemia with administration of sublingual nitrate.

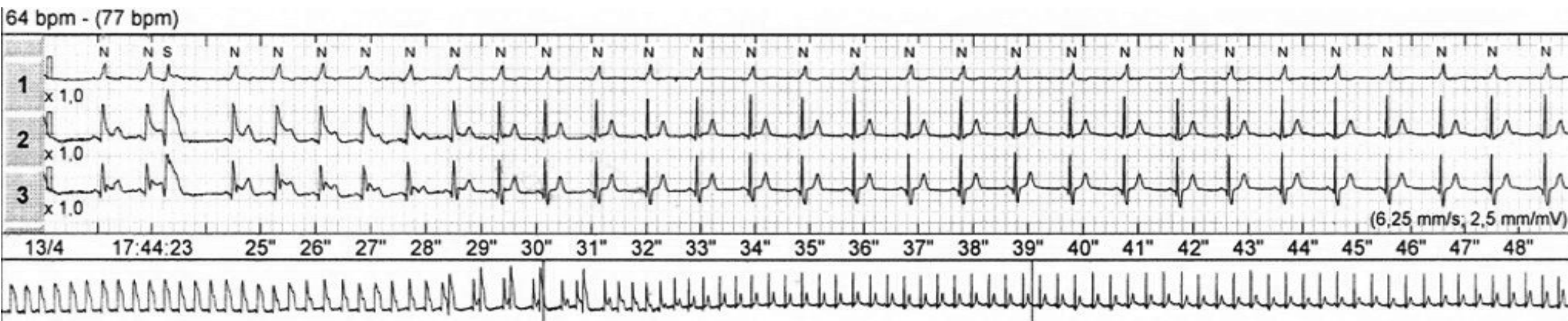


Observation: the pattern is very similar with ECG-2 from the present case because we have f-QRS + lambda wave.

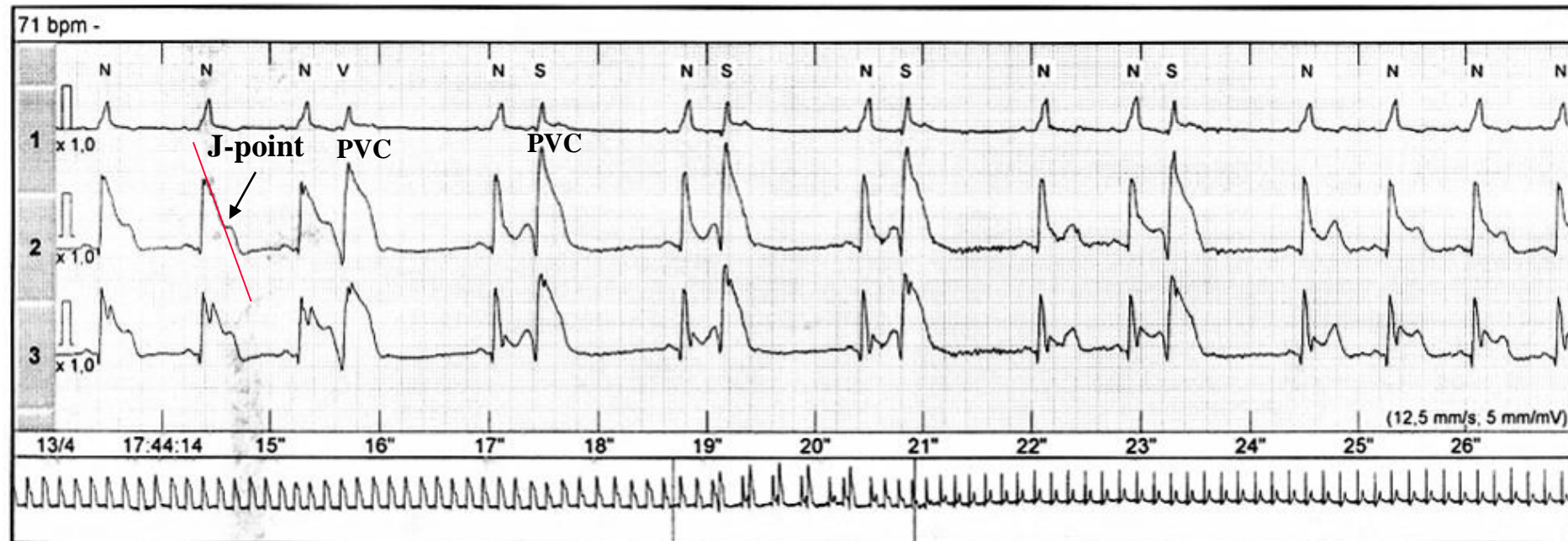




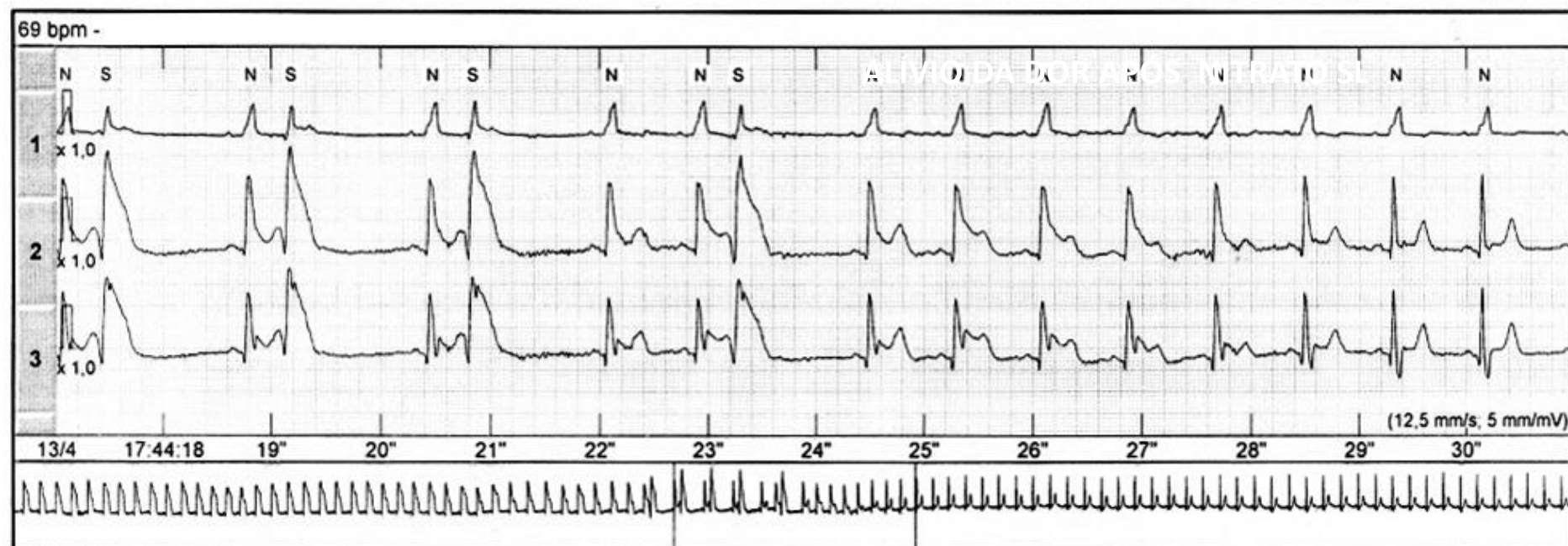Holter monitoring shows STSE with lambda wave pattern during Prinzmetal angina. The last 4 group of beats are formed by sinus beat followed by premature ventricular contraction.



The first beat is sinus rhythm with minimal STSE. The second one has drastically augmentation of STSE followed by short coupled PVC. From third to eighth beat there are minimal STSE. The remaining trace has normal ST segment level.

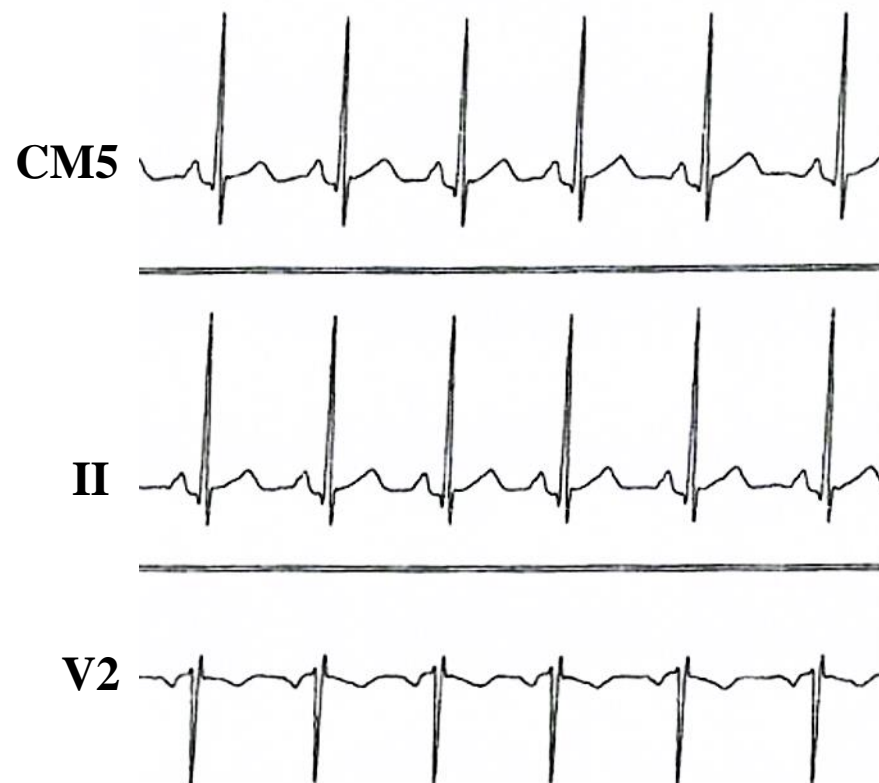


Premature ventricular contractions (PVCs) occurring after each sinus beat (bigeminy) with lambda wave shape.

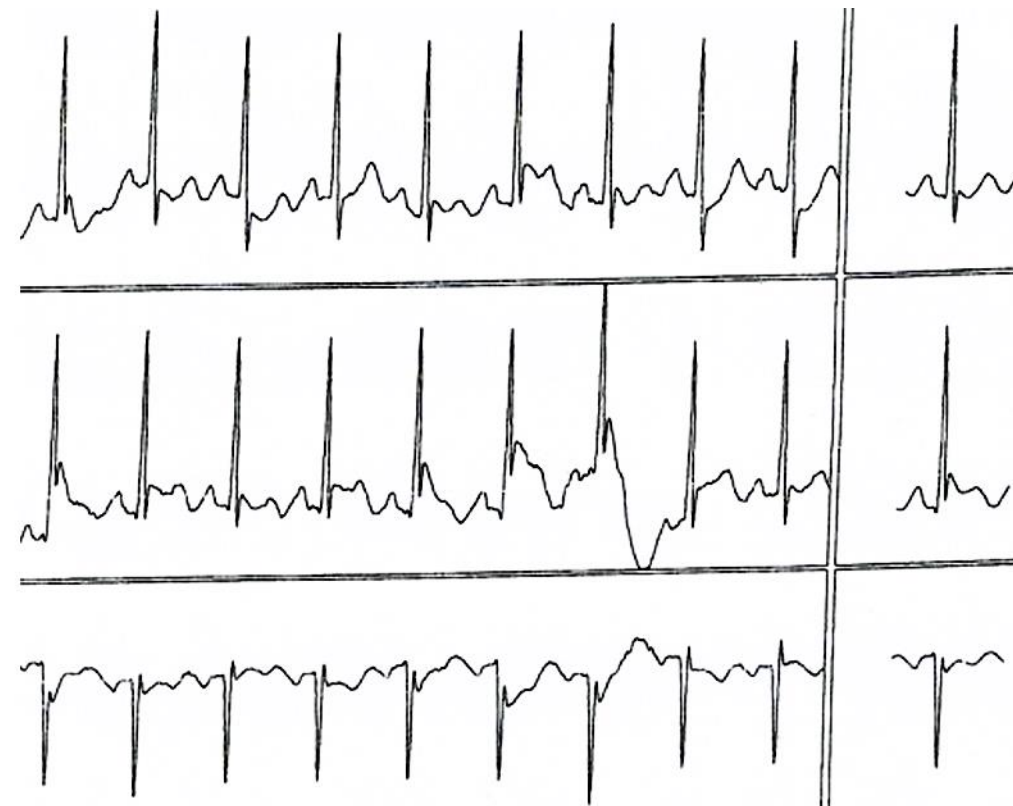


Concomitant with retrosternal chest pain in a 56-year old man with a recent history of angina

ECG at rest



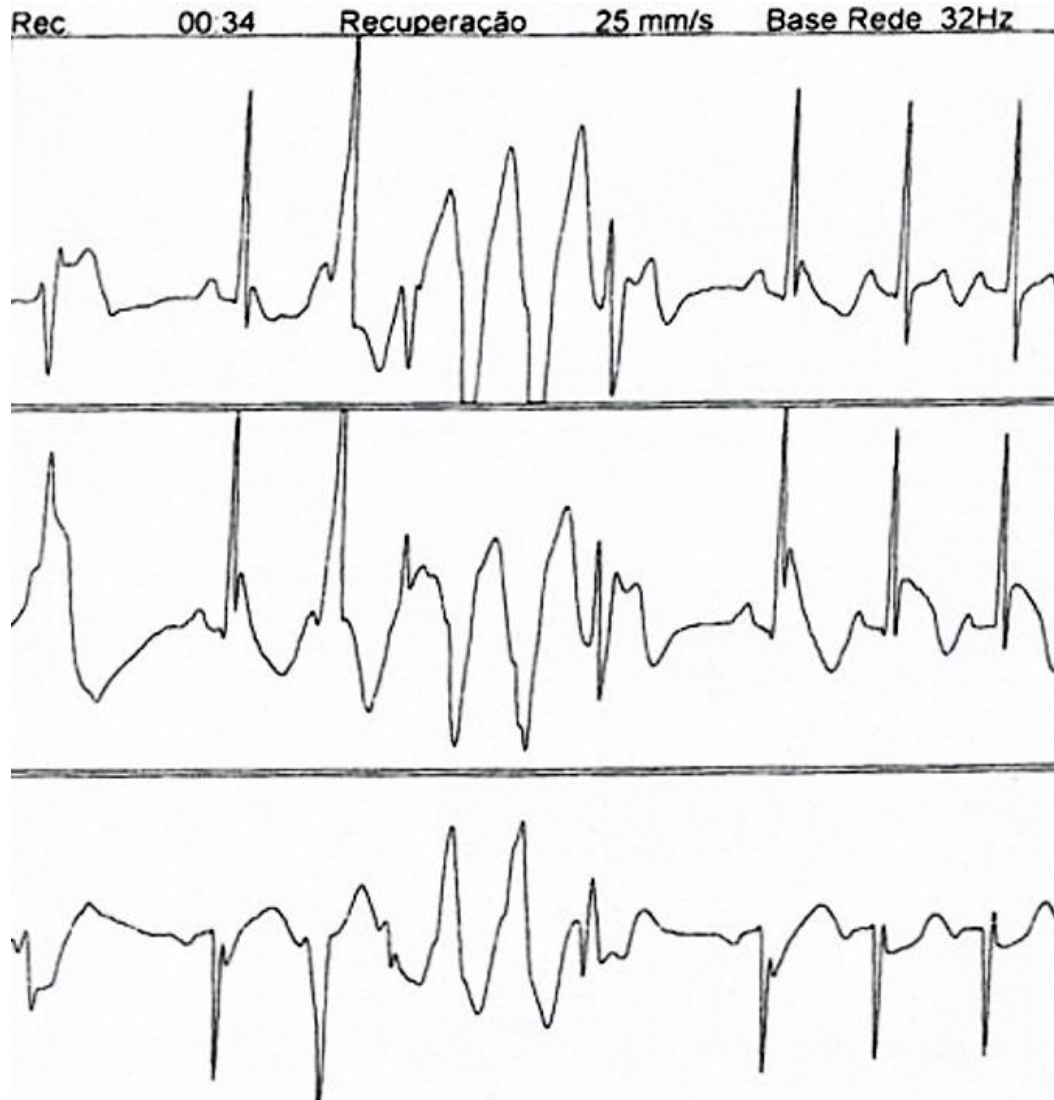
During minute 01:32 of a treadmill exercise test



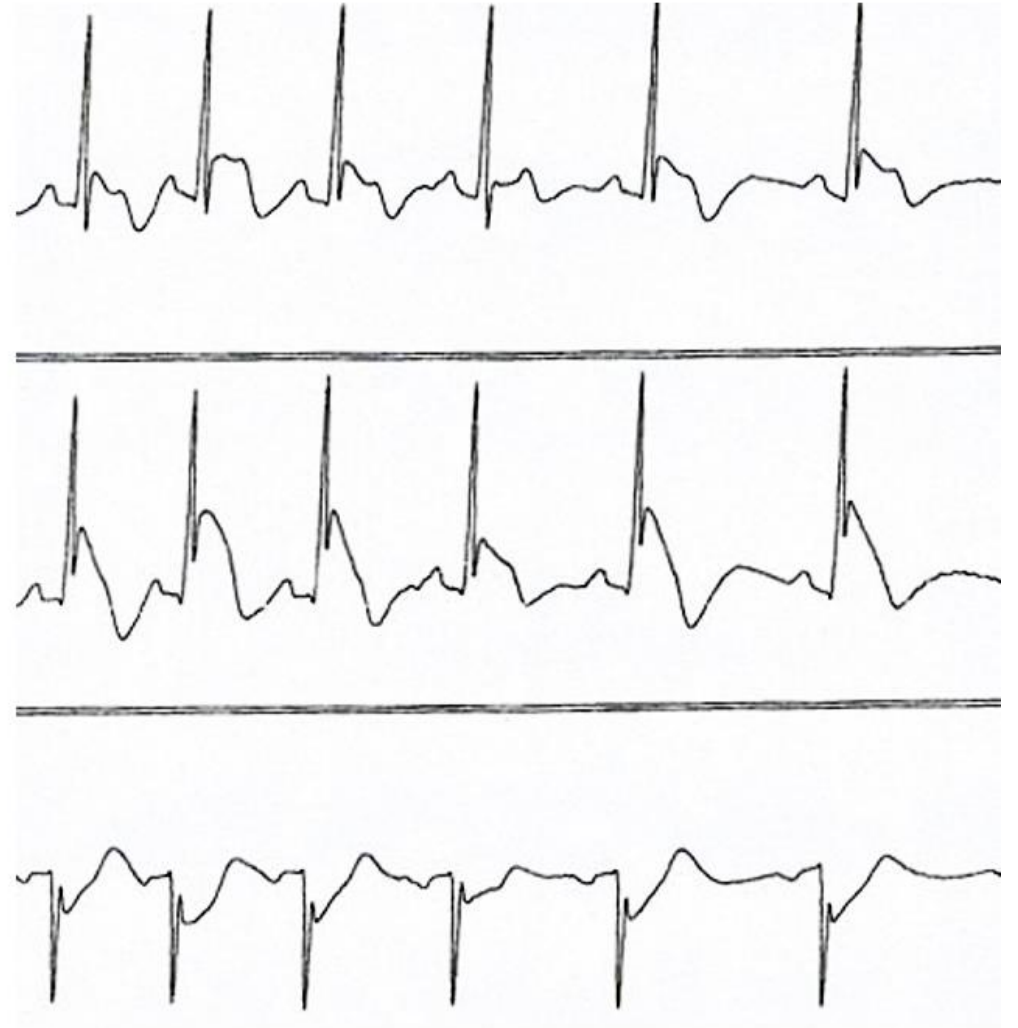
treadmill exercise test

Recovery phase

Minute 00:34

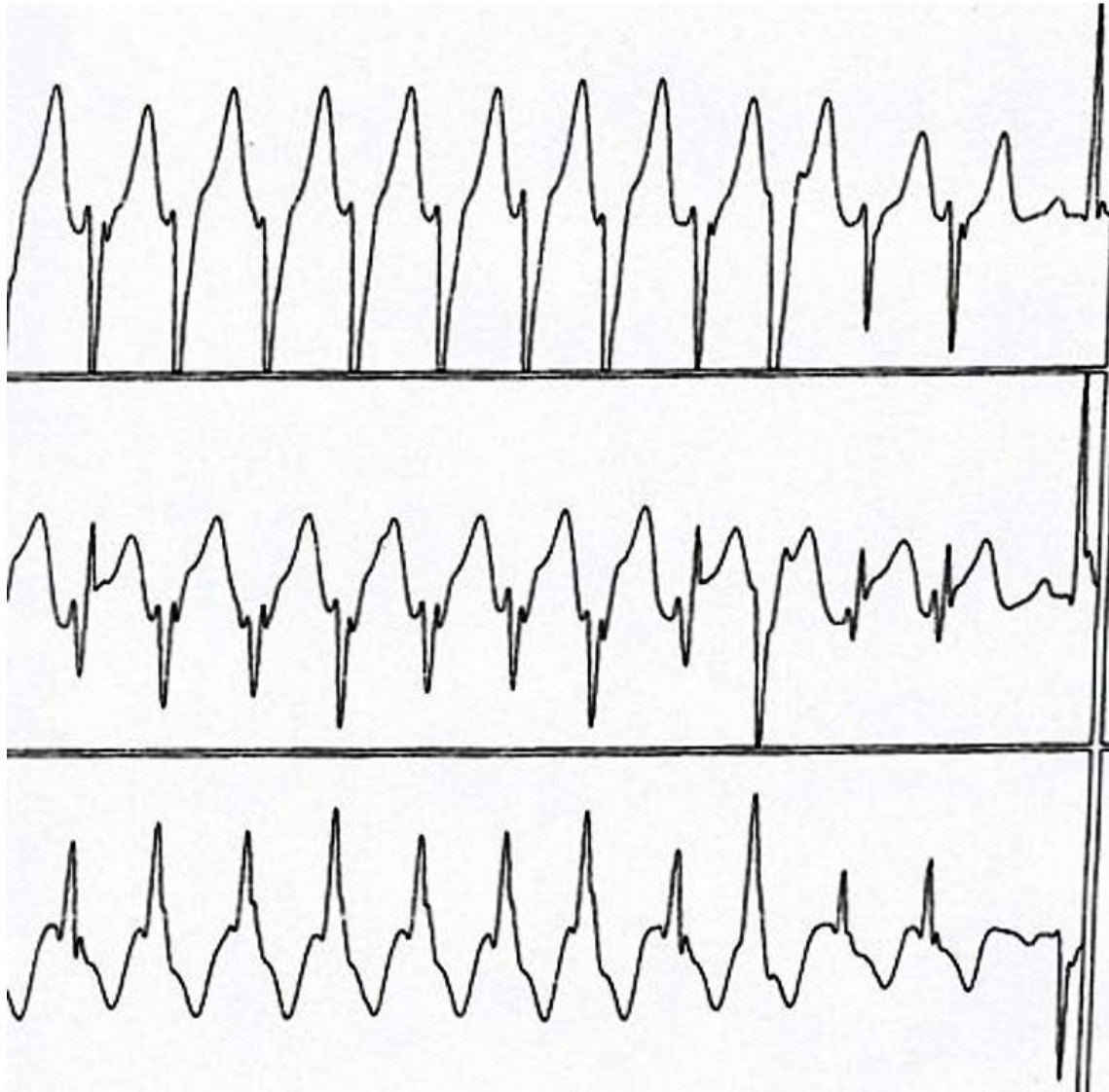


Minute 1:00

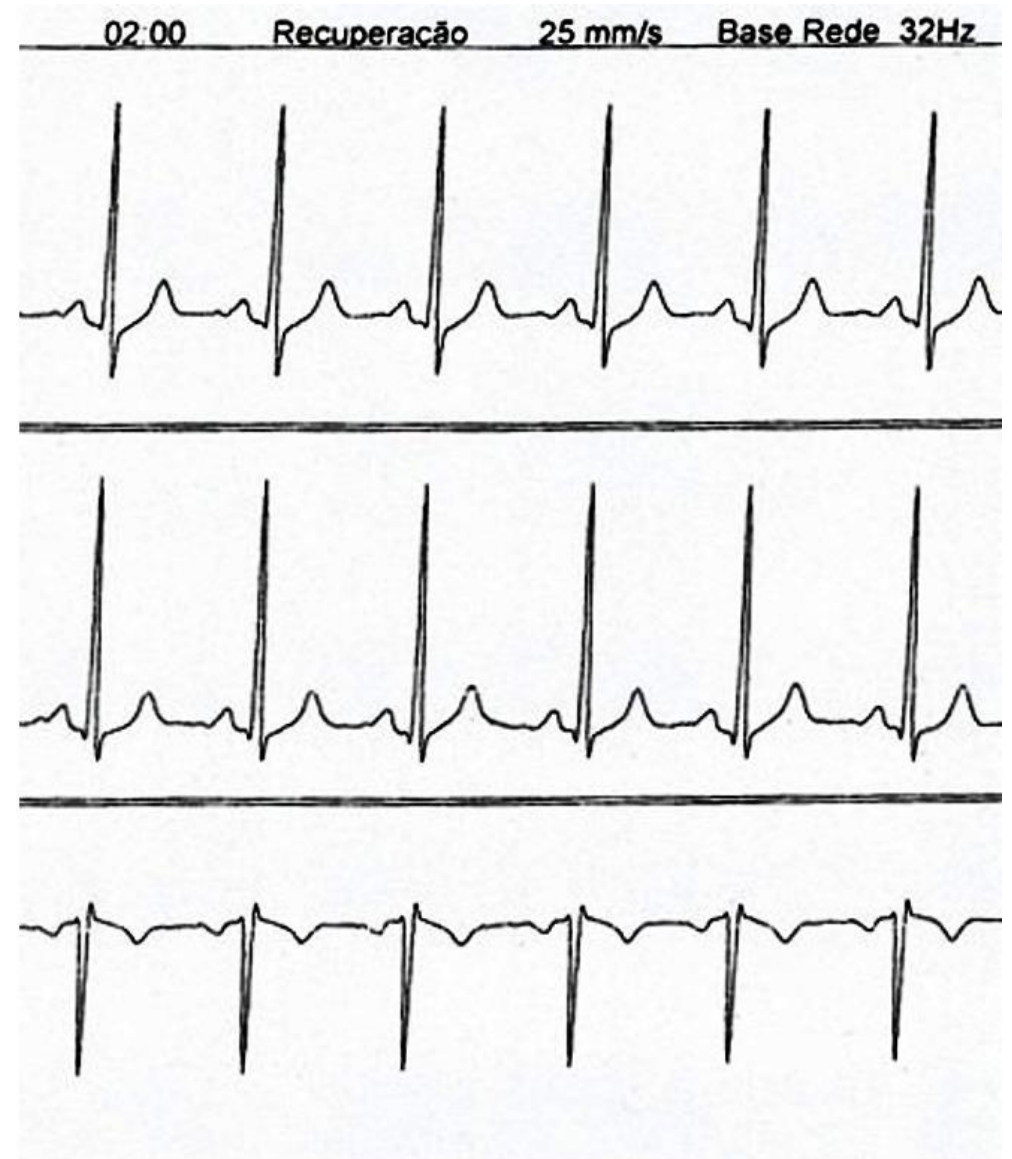


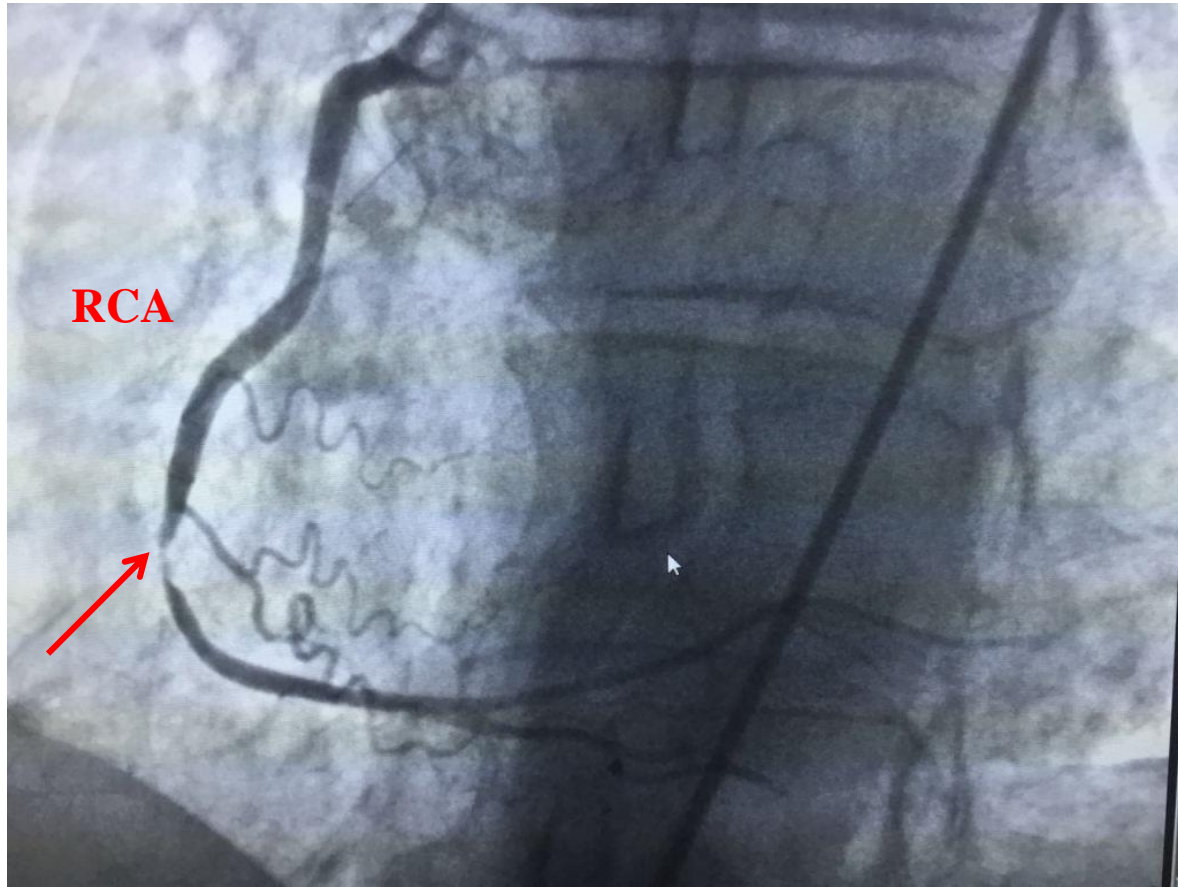
Recovery phase

Minute 01:43

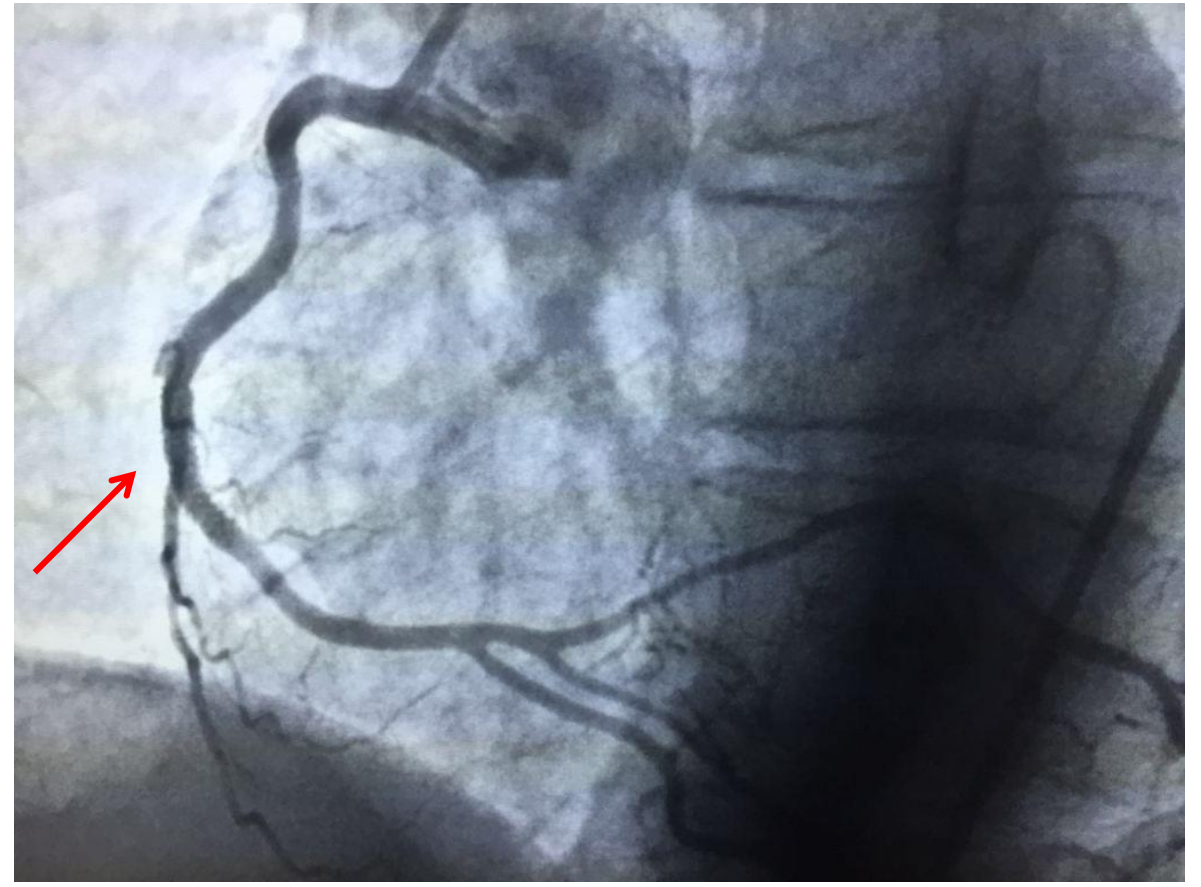


Minute 2:00



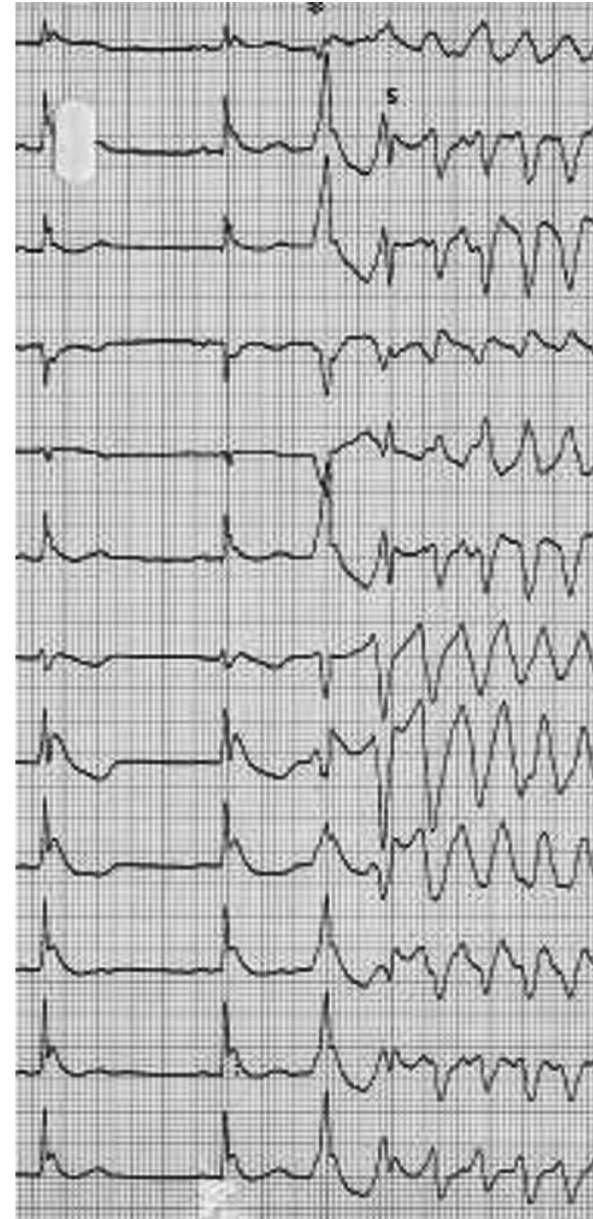
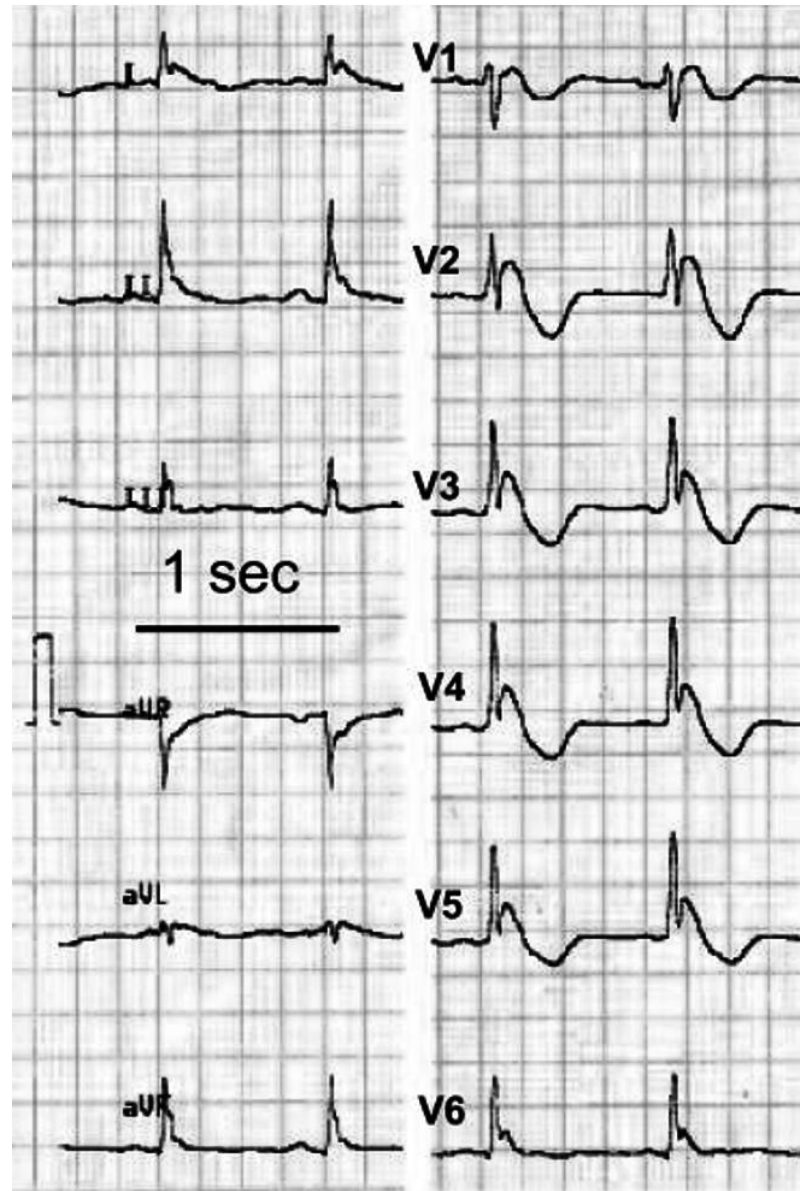


Before PCI



After PCI

Monstrous J-waves

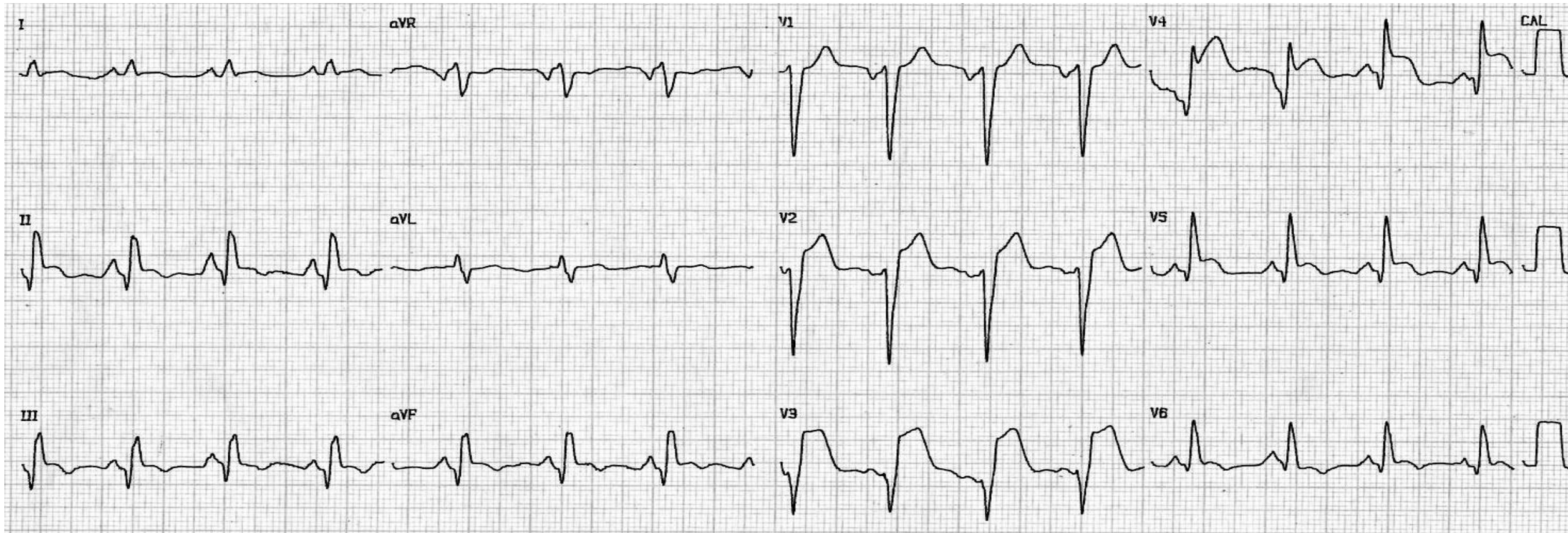


Bernard A, Genée O, Grimard C, Sacher F, Fauchier L, Babuty D. Electrical storm reversible by isoproterenol infusion in a striking case of early repolarization. *J Interv Card Electrophysiol.* 2009;25(2):123-7.

J-wave in the context of coronary artery disease: Ischemic J-Waves

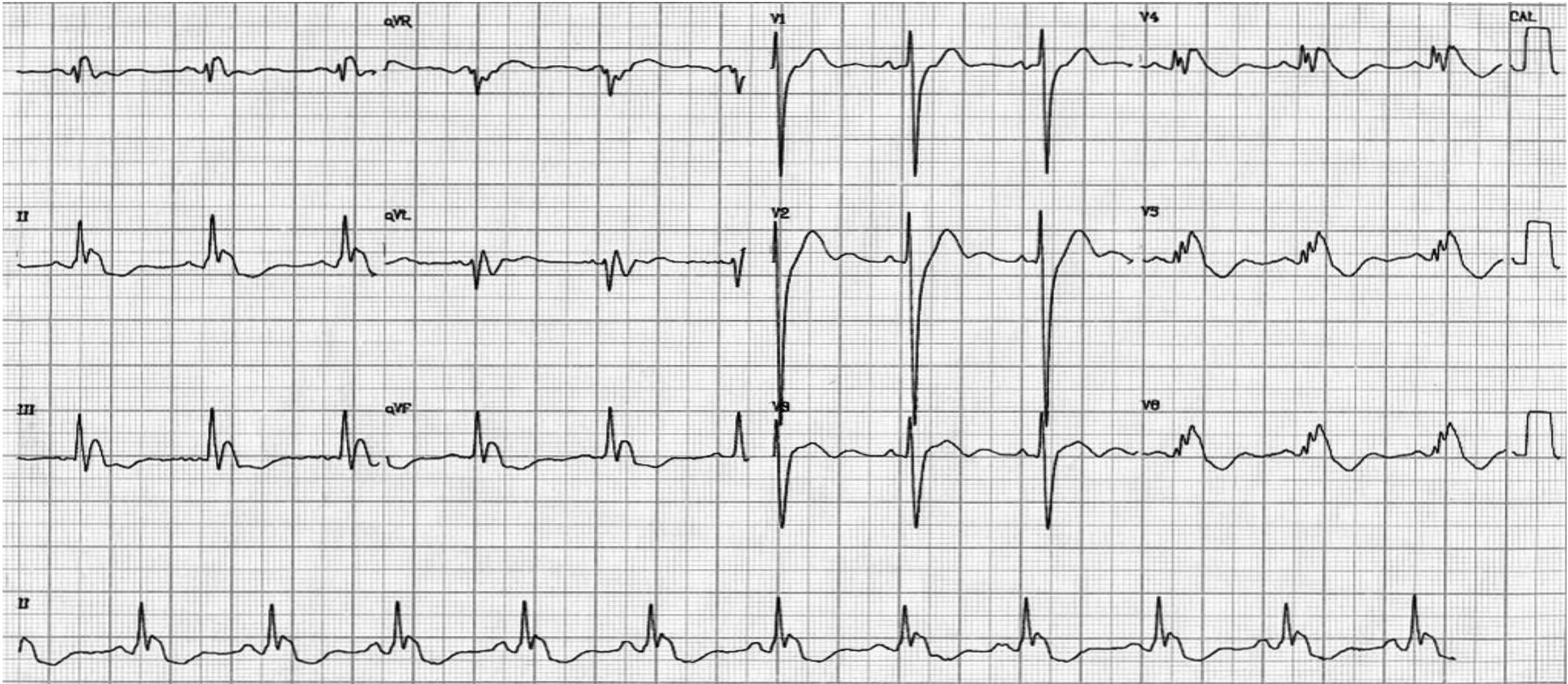
Female, 53-year-old patient, admitted in the Messejana Hospital on 29-04-2004, with STSEMI. She was immediately sent to hemodynamic laboratory. Coronarography showed severe lesion in the left main coronary artery (LMCA) (95%) + occlusion in RCA + LCx in 90%. She was sent to emergency surgery with placement of saphenous graft (LADA and LCx marginal). Echo showed: LV=70/54; LA=44; EF=45% + moderate mitral valve insufficiency.

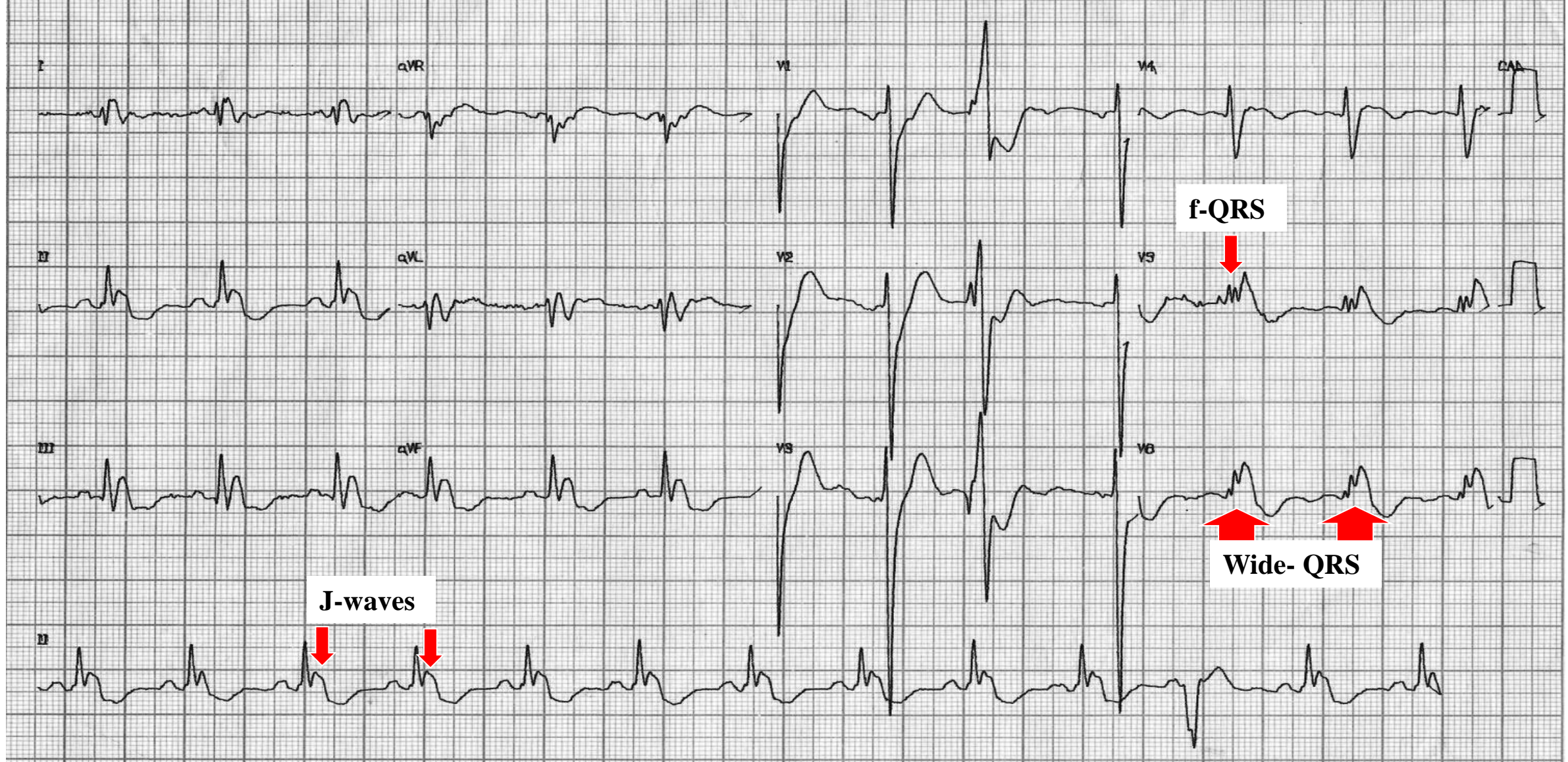
ECG-1 performed on 2004



She was admitted in 2012 with ischemic cardiomyopathy, CHF functional class IV
Left heart catheterization: aorto-coronary by-pass, all occluded. Severe systolic ventricular dysfunction (LVEF=30%).
This patient was in functional class III in the infirmary, waiting for a heart transplant.
She died suddenly.

ECG-1 performed on 2012

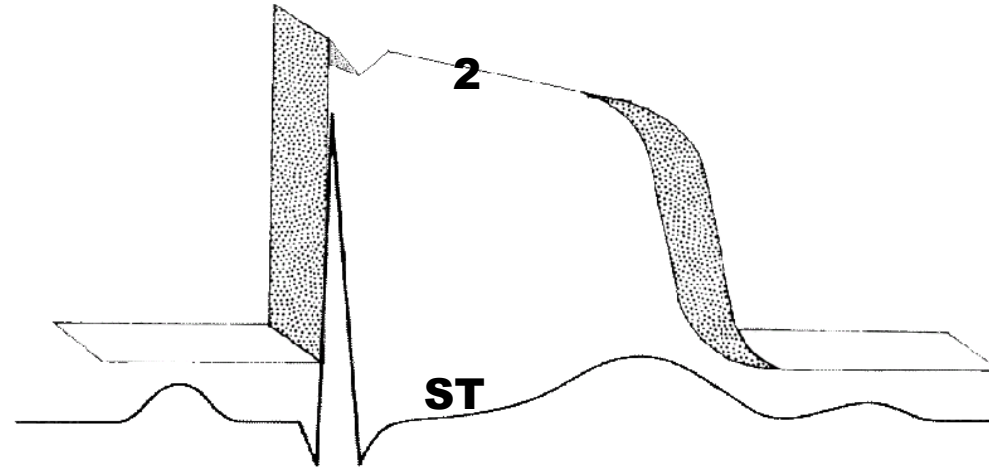




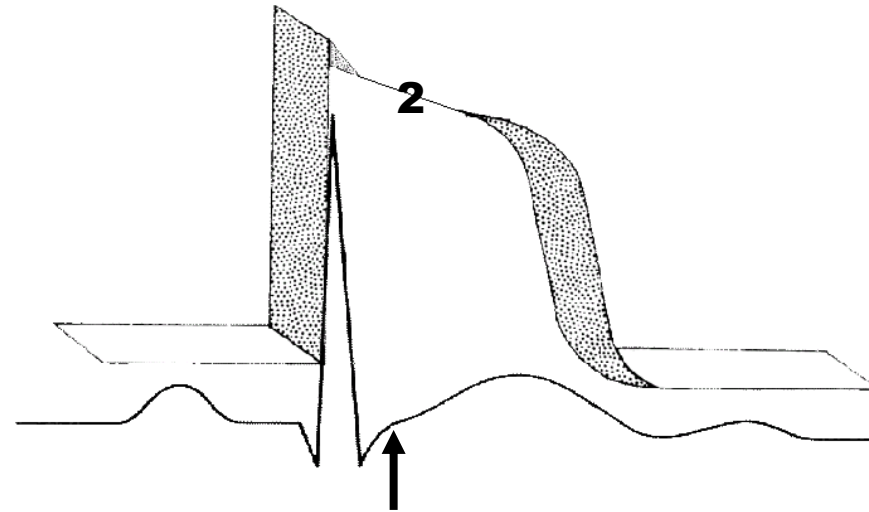
Association of f-QRS in at least two contiguous leads on the 12-lead ECG + Wide QRS complexes + J-waves ≥ 0.1 mV combined with a descending/horizontal ST segment constitute a malignant ER pattern (**Misuzawa 2014**). Identifying patients with higher risk of fatal arrhythmias after CABG surgery. All are components of multifactorial risk for increased morbidity and mortality, sudden cardiac death and recurrent cardiovascular events.

Comparative of monophasic action potential with surface ECG in normal conditions and in hypercalcemia

Normal



Hypercalcemia

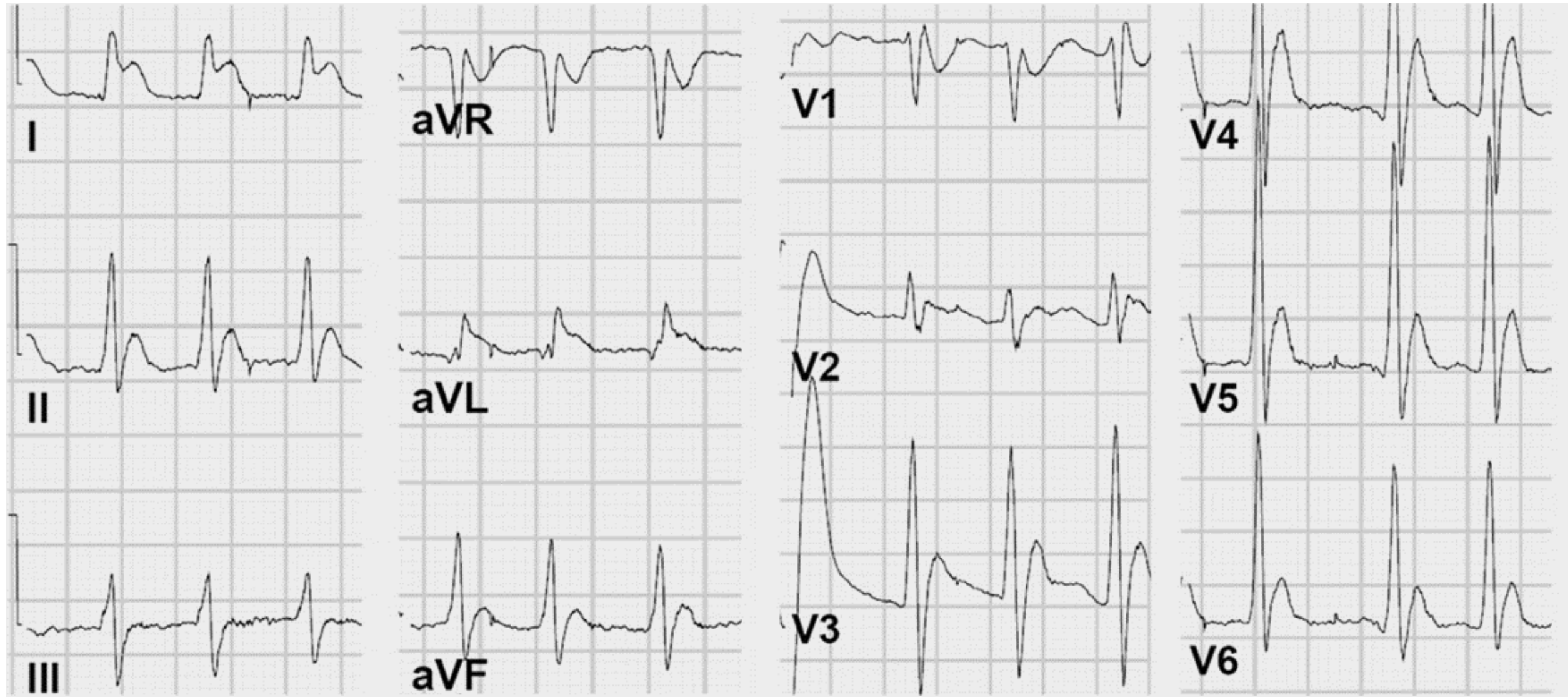


Almost absent ST segment

QTc interval shortening, Q-oTc interval shortening: interval from Q wave onset to T wave onset corrected according to HR.

Q-aT interval decrease: interval between QRS onset to T wave apex. Values below 270 ms are diagnostic.

Typical ECG of hypercalcemia: Short QT interval and J-wave



J-waves in hypercalcaemia are presumably due to an increase in the calcium-activated outward current and a decrease in the inward calcium current. This lead to all-or-none repolarization of the action potential (end of Phase 1 in the epicardium), creating an Ito channel-mediated transmural voltage gradient during ventricular repolarization.

Proposed Shanghai Score System for diagnosis of early repolarization syndrome	
I. Clinical history	Points
A. Unexplained cardiac arrest, documented ventricular fibrillation or polymorphic ventricular tachycardia	3
B. Suspected arrhythmic syncope	2
C. Syncope of unclear mechanism/unclear etiology	1
*Only award points once for highest score within this category	
II. Twelve-lead ECG	
A. Early repolarization ≥ 0.2 mV in ≥ 2 inferior and/or lateral ECG leads with horizontal/descending ST segment	2
B. Dynamic changes in J-point elevation (≥ 0.1 mV) in ≥ 2 inferior and/or lateral ECG leads	1.5
C. ≥ 0.1 mV J-point elevation in at least 2 inferior and/or lateral ECG leads	1
*Only award points once for highest score within this category	
III. Ambulatory ECG monitoring	
A. Short-coupled premature ventricular contractions with R on ascending limb or peak of T wave	2
IV. Family history	
A. Relative with definite early repolarization syndrome (ERS)	2
B. ≥ 2 first-degree relatives with a II.A.ECG pattern	2
C. First-degree relative with a II.A. ECG pattern	1
D. Unexplained sudden cardiac death <45 years in a first- or second-degree relative	0.5
*Only award points once for highest score within this category	
V. Genetic test result	
A. Probable pathogenic ERS susceptibility mutation Score (requires at least 1 ECG finding) - ≥ 5 points: Probable/definite ERS; 3–4.5 points: Possible ERS <3 points: Nondiagnostic	

Expert Consensus Recommendations on ER Therapeutic Interventions (Priori 2013)

- I. Class I: ICD implantation is recommended in patients with a diagnosis of ERS who have survived a cardiac arrest.
- II. Class IIa: Isoproterenol infusion can be useful in suppressing electrical storms in patients with a diagnosis of ERS. Quinidine in addition to an ICD can be useful for secondary prevention of VF in patients with a diagnosis of ERS.
- III. Class IIb: ICD implantation may be considered in symptomatic family members of ERS patients with a history of syncope in the presence of ST-SE .1 mm in two or more inferior or lateral leads.
- IV. ICD implantation may be considered in asymptomatic individuals who demonstrate a high-risk ER ECG pattern (high J-wave amplitude, horizontal/descending ST-segment) in the presence of a strong family history of juvenile unexplained SCD with or without a pathogenic mutation
- V. Class III: ICD implantation is not recommended in asymptomatic

Differential diagnosis of early repolarization pattern

Other causes of early repolarization pattern include the following:

- Juvenile ST pattern
- Pericardial disease (pericarditis, pericardial cyst, pericardial tumor)
- Hypothermia
- Hyperthermia
- Myocardial tumor (lipoma)
- Hypertensive heart disease
- Athlete's heart
- Myocardial ischemia
- ST segment elevation myocardial infarction (i.e., antero-septal myocardial infarction)
- Fragmented QRS (terminal notching)
- Hypocalcemia
- Hyperkalemia
- Thymoma
- Aortic dissection
- Arrhythmogenic right ventricular cardiomyopathy
- Takotsubo cardiomyopathy
- Neurologic causes (intracerebral bleeding, acute brain injury)
- Myocarditis
- Chagas disease
- Cocaine use