

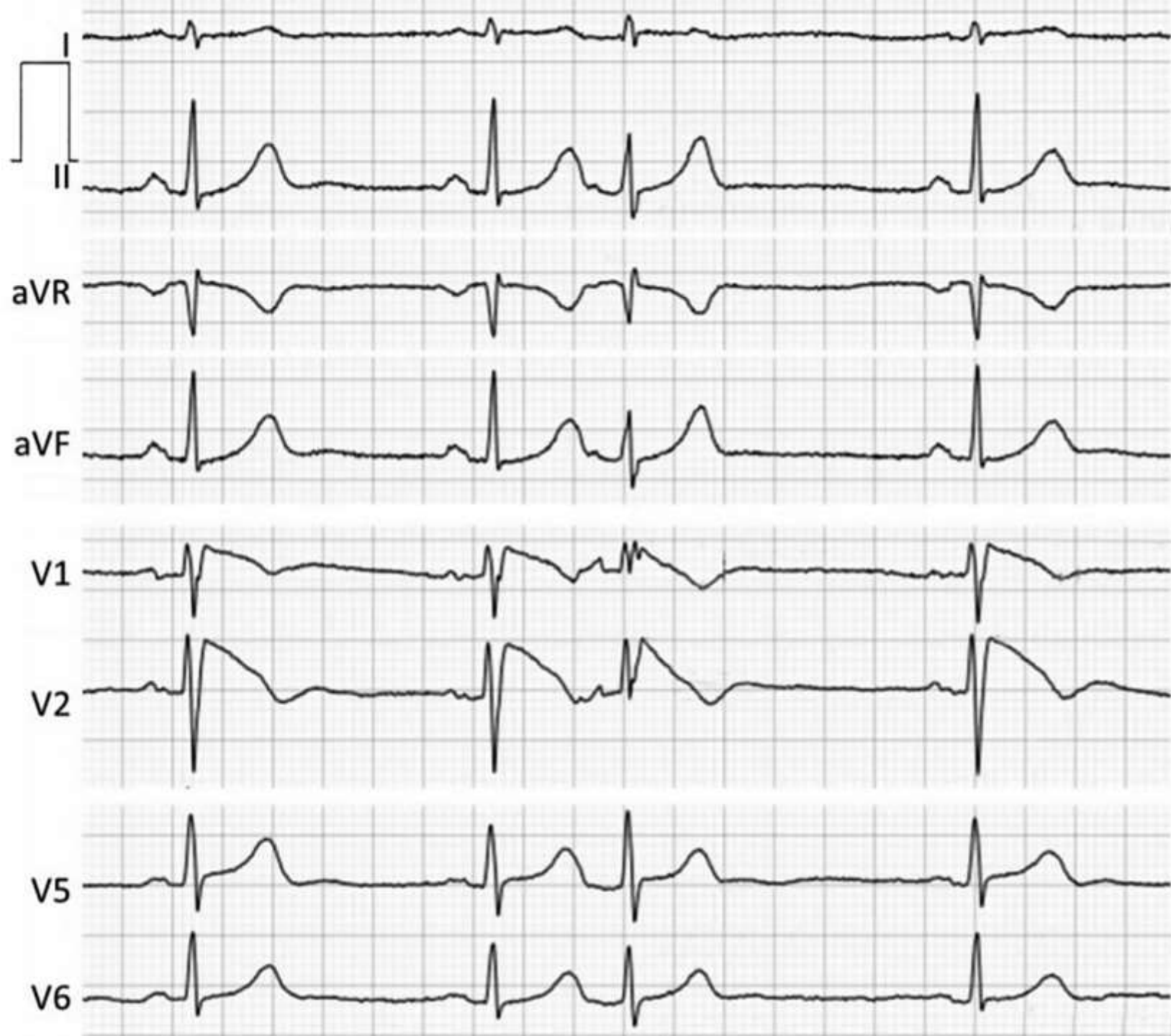


Spontaneous Type 1 Brugada ECG pattern associated with premature atrial beat, anything else in this premature QRS complex?





Colleagues opinions

Their are fractionated potentials as well which is a sign of increased risk but not sure if it occurs only with APC value opinion of group.

Melvin Scheinman, USA



Buenas noches estimado Andrés! Creo que en esta extrasístole auricular además de presentar el Br tipo 1 se observan ondas épsilon, sobre todo en V1.

Quizás un síndrome de superposición con displasia arritmogénica.

Juan Carlos Manzardo

Good evening dear Andrés!

I think that in this atrial extrasystole, in addition to presenting the type 1 BrS, epsilon waves are observed, especially in V1.

Perhaps an overlap syndrome with arrhythmogenic dysplasia.

Juan Carlos Manzardo, Argentina

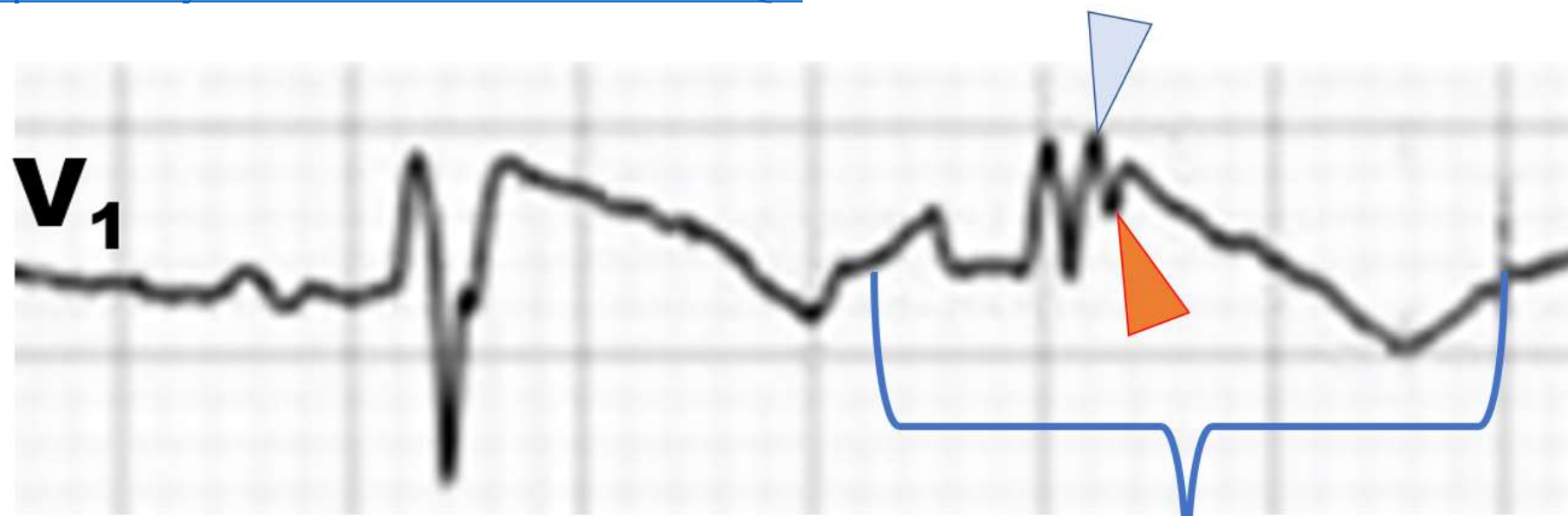


In this case QRS fragmentation(fQRS) as a marker of slow conduction in the RVOT

Pedro Brugada ***“Lo mejor para el corazón es reír, amar y ser feliz”***

"The best thing for the heart is to laugh, love and be happy"

<https://www.youtube.com/watch?v=d-diB65scQU>



Premature atrial beat

Fragmented QRS (fQRS) is a marker of myocardial scar evaluated by 12-leads ECG. fQRS is defined as an additional spike/s inside of the QRS complexes without bundle branch block (light blue and red isosceles triangles) within the QRS complex. In patients with CAD, fQRS is associated with myocardial scar detected by single photon emission tomography and is a predictor of cardiac events. fQRS is a predictor of mortality and arrhythmic events in patients with LV dysfunction. The usefulness of fQRS for detecting myocardial scar and for identifying high-risk patients has been expanded to several cardiac entities, such as **cardiac sarcoidosis**, **ARVC**, **ACS (STEMI and NSTEMI)**, **coronary slow flow**, **Takotsubo cardiomyopathy**, **BrS**, **acquired LQTS**, **hypertrophic cardiomyopathy**, and others. fQRS can be applied to patients with wide QRS complexes and is associated with myocardial scar and prognosis..

The changes I am noting in the QRS complex following the APC are

- 1) Some intraventricular aberration
- 2) Obvious decrease in ST elevation
- 3) Suspected QRS fragmentation or changes in relation with the rate-dependent QRS aberration.

All quite expected findings.

Do you see something else??



Belhassen, Bernard

Heart Institute, Hadassah University Hospital, Kiriat Hadassah, PO Box 12000, Jerusalem 91120, Israel.

bblhass@tasmc.health.gov.il

Hola Amigo

En V1, en la extrasístole se evidencia una posible onda épsilon, evocando una displasia/cardiomiopatía arritmogénica do ventrículo derecho(DAVD).

¿Asociación de síndrome de Brugada con displasia/cardiomiopatía arritmogénica do ventrículo derecho(C/DAVD)?

Hello Friend

In V1, a possible epsilon wave is evident in atrial premature beat, evoking a right ventricular cardiomyopathy/dysplasia (C/DAVD).

_Association of Brugada Dysplasia / Arrhythmia Cardiomyopathy of the Right Ventricle (DAVD)?

Juan José Sirena MD Santiago del Estero, Argentina



Prezado Andrés: A extra-sístole atrial apresenta um aspecto de fQRS ou uma onda épsilon.

Adail Paixão-Almeida MD Vitoria da Conquista Bahia Brazil

English

Dear Andrés: Atrial Premature Contraction (APC) has an aspect of fQRS or an epsilon wave.

Adail Paixão-Almeida MD, Vitoria da Conquista, Bahia, Brazil



Querido amigo profesor Andres R Perez Riera yo creo que en la extrasistole auricular se ve en v2,v3 una onda épsilon

Un abrazo

Samuel

Dear friend professor Andres R Perez Riera I think that in the atrial extrasystole an epsilon wave is seen in v2, v3.

A hug

Samuel Sclarovsky, Israel



Hola Andrés comparto la opinión que luego de la ESV se observa claramente una onda Epsilon en V1. Además presenta una desviación del eje a la izquierda y cambios de la onda T en V1 Y V2. No observo la derivación V3. Conocemos la asociación de ambas entidades.

Por lo que además del patrón de Brugada tipo I espontáneo presenta criterios diagnósticos positivos para DAVD, lo que se evidenciara con la RNM cardíaca.

Un cordial saludo

Martín Ibarrola

Hi Andrés, I share the opinion that after the premature atrial contractions an epsilon wave is clearly observed in V1. It also presents an axis deviation to the left and changes of the T wave in V1 and V2. I don't see lead V3.

We know the association of both entities. Therefore, in addition to the spontaneous type I Brugada pattern, it presents positive diagnostic criteria for ARVD, which is evident in cardiac MRI.

A cordial greeting

Martin Ibarrola, Argentina



Final considerations

By Andrés Ricardo Pérez-Riera, MD PhD



Andrés having a classic Argentinian barbecue at the Physician's Club, SP, Brazil

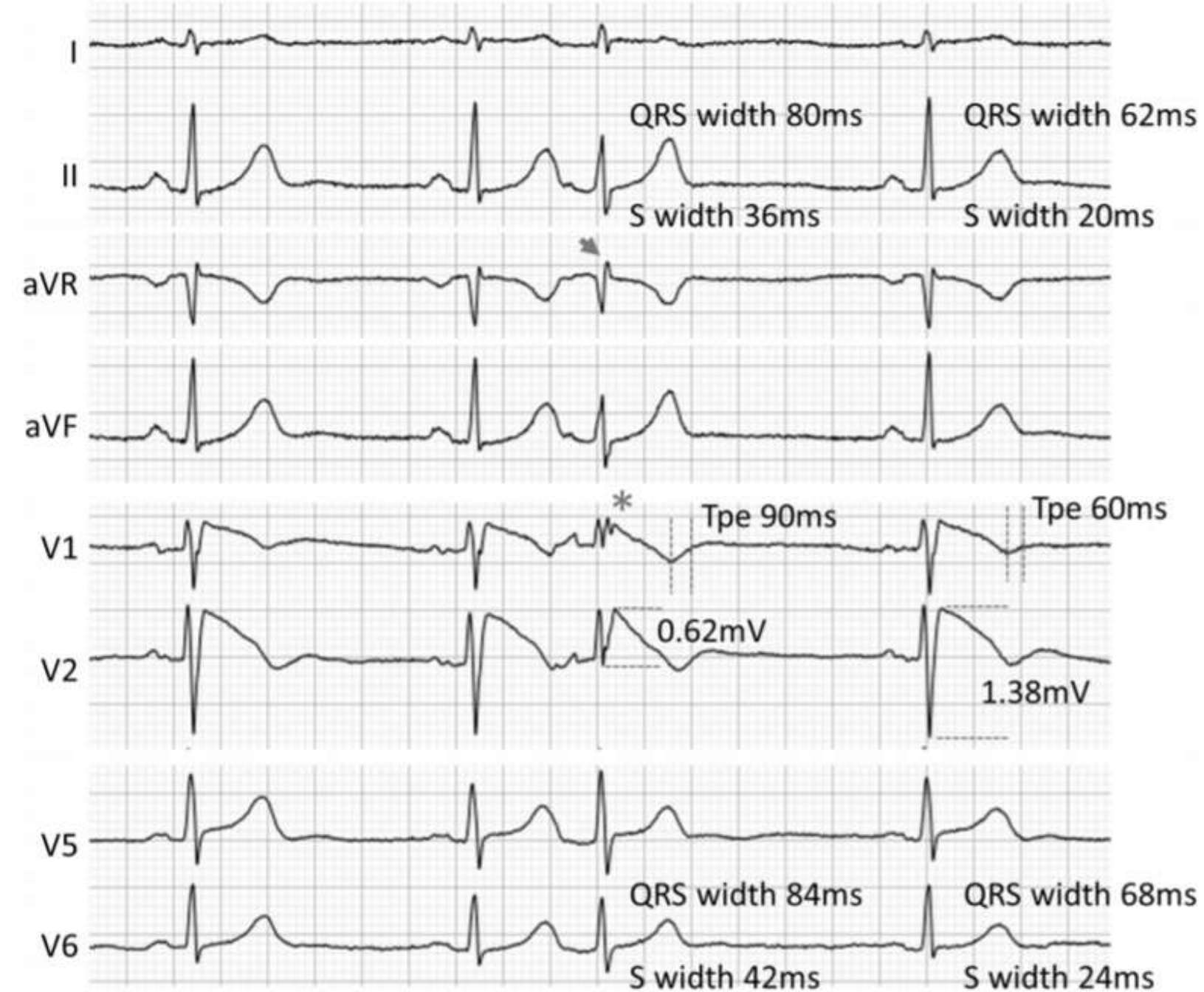
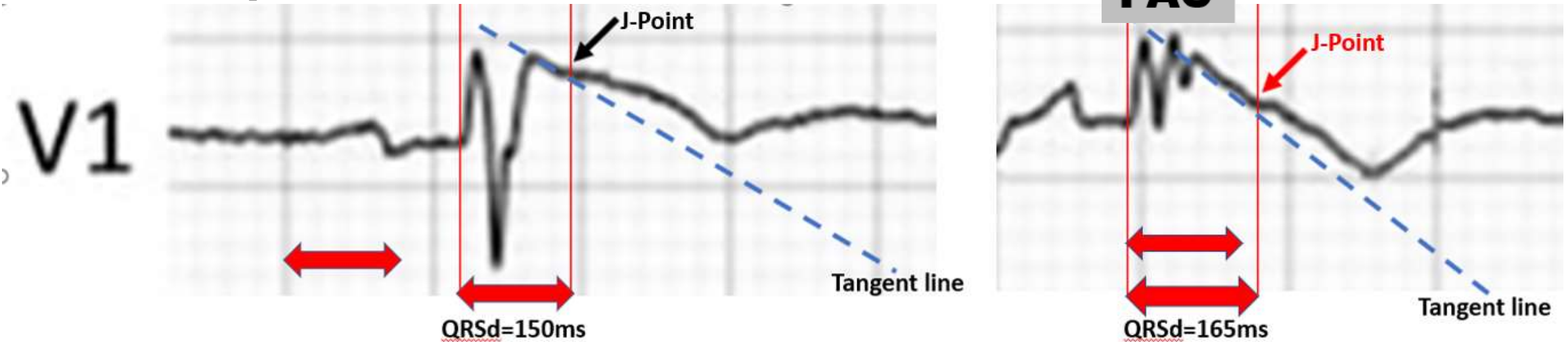


Figure to the side: ECG of a patient with BrS. The first, second, and fourth QRS complexes show normal sinus rhythm with type 1 Brugada ECG pattern in V1-V2. PAC causes third QRS complex via normal conduction system with premature excitation and right conduction delay inside the RVOT because the third QRS complex shows wider QRS and S deeper in leads II, aVF, V5, and V6 and lower QRS amplitude in leads V1 and V2 compared with other complexes. The amplitude of final R wave in lead aVR is also larger (arrow). Fragmented QRS also appears in lead V1 (*). These features should indicate a close relationship between ventricular conduction delay on RVOT and specific ECG features. Interestingly, third QRS complex also shows longer Tpeak -Tend interval (Tpe) in leads V1 and V2 compared with others.(90ms vs 60ms)

Characteristic of the third beat

- 1) Wider QRS duration of PAC related basal QRS baseline complexes using tangent line method ($>15\text{ms}$)
- 2) Lower QRS amplitude in PAC

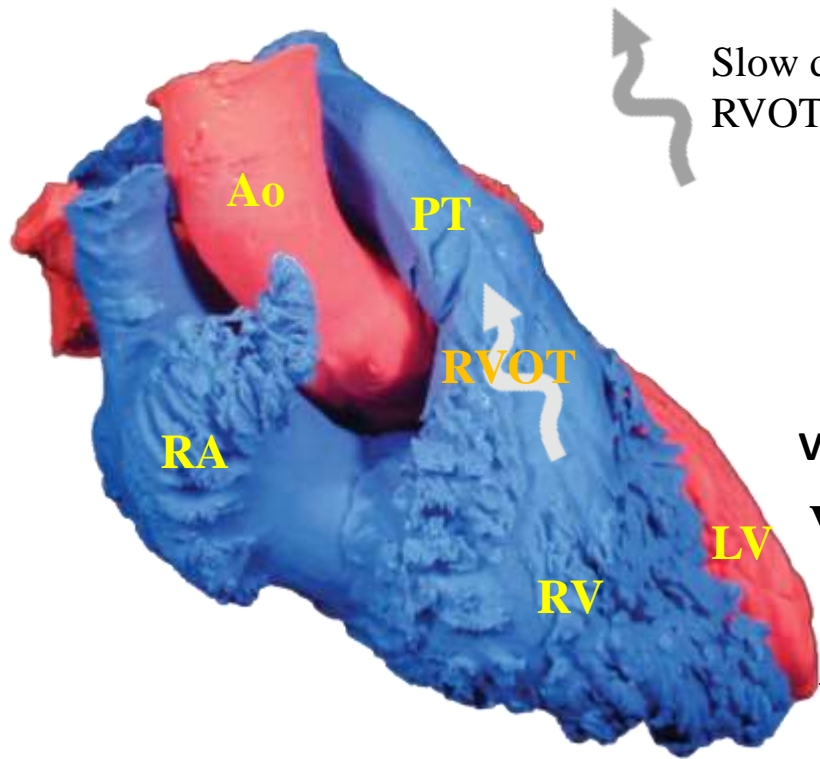
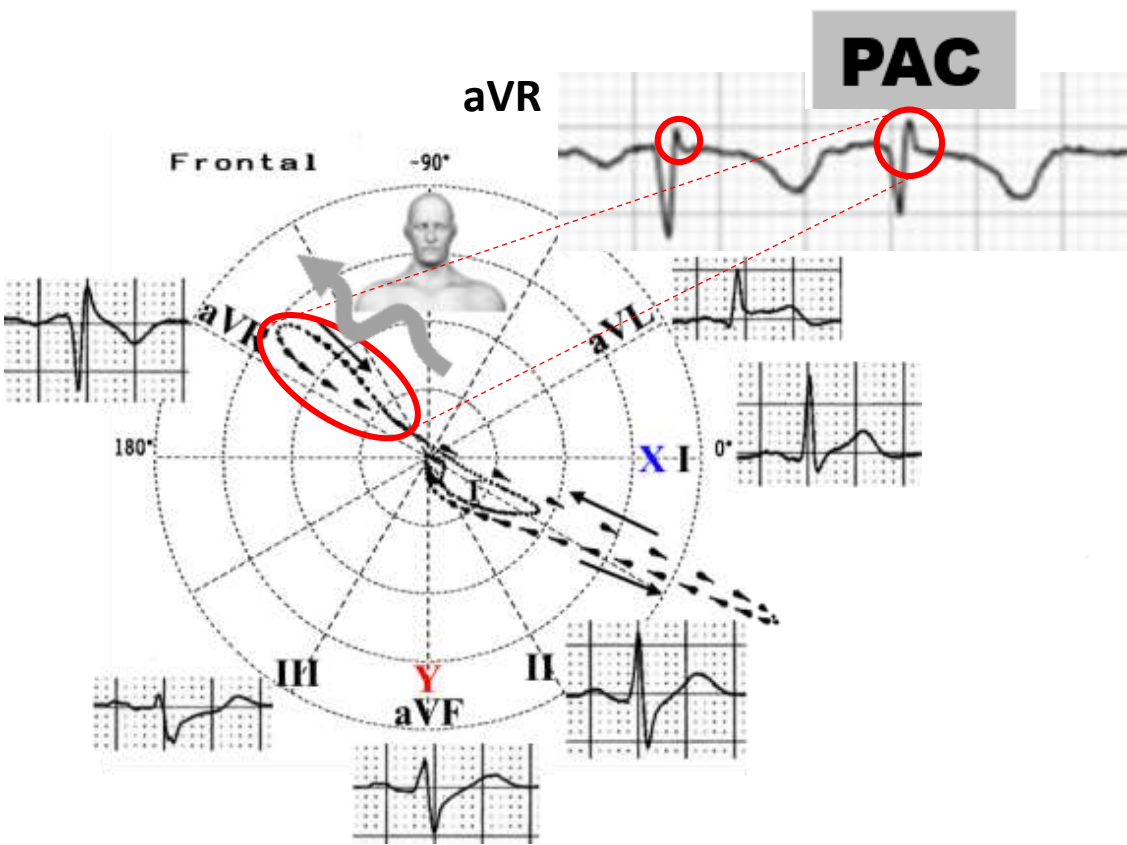


The diagnosis of BrS and risk stratification of affected patients are based on a coved-type $\geq 2\text{ mm}$ ST-segment elevation followed by negative symmetrical T-wave in the right precordial leads. This typical ECG pattern may be present persistently, intermittently or only after administration of sodium-channel blockers. Spontaneous type 1 pattern is considered a risk marker of ventricular events.

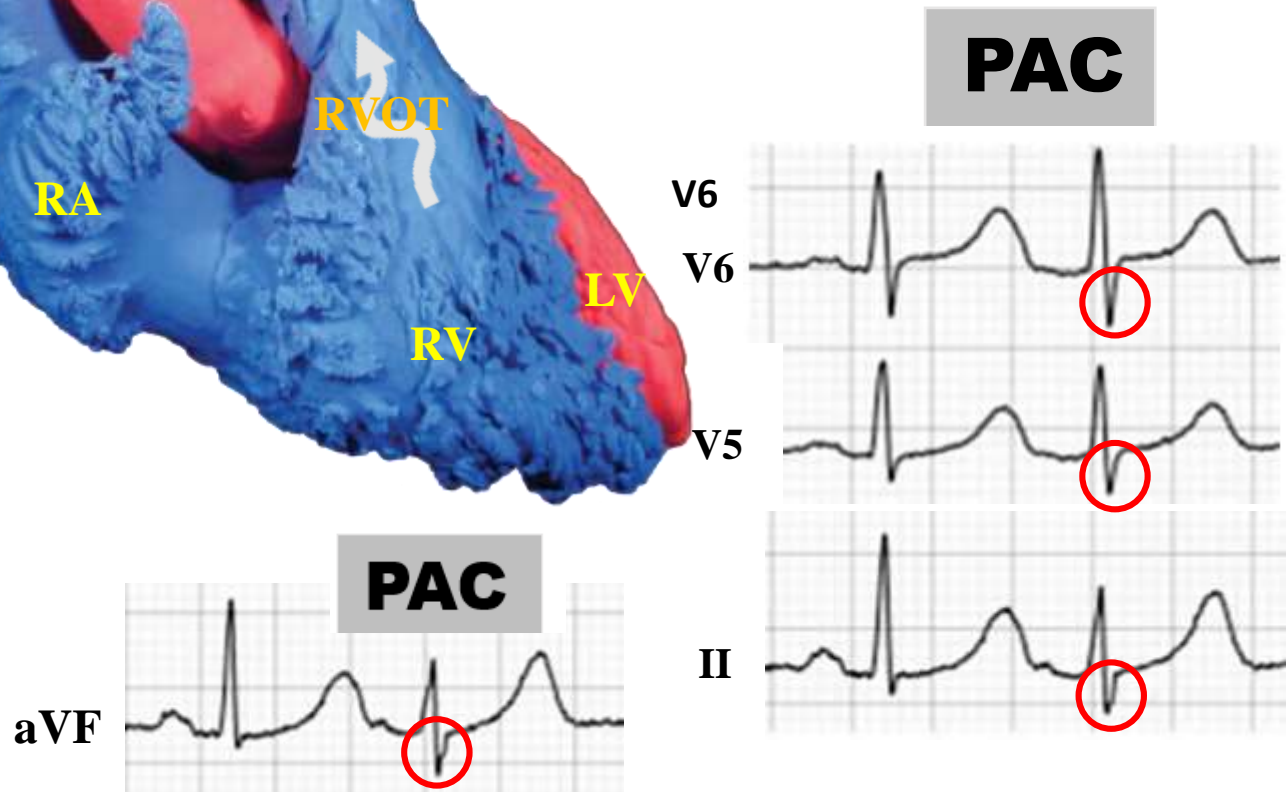
Meaning of prolonged baseline QRS duration ($\geq 120\text{ ms}$) in the right precordial leads

Prolonged QRS duration as measured on a standard 12-lead ECG is associated with ventricular arrhythmia and could serve as a simple noninvasive marker of vulnerability to life-threatening cardiac events in patients with Brugada syndrome. (Ohkubo K et al 2011)

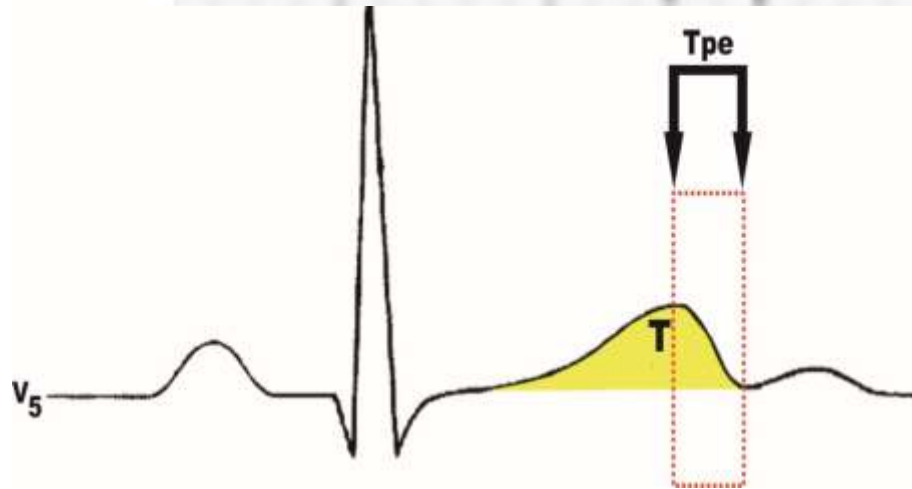
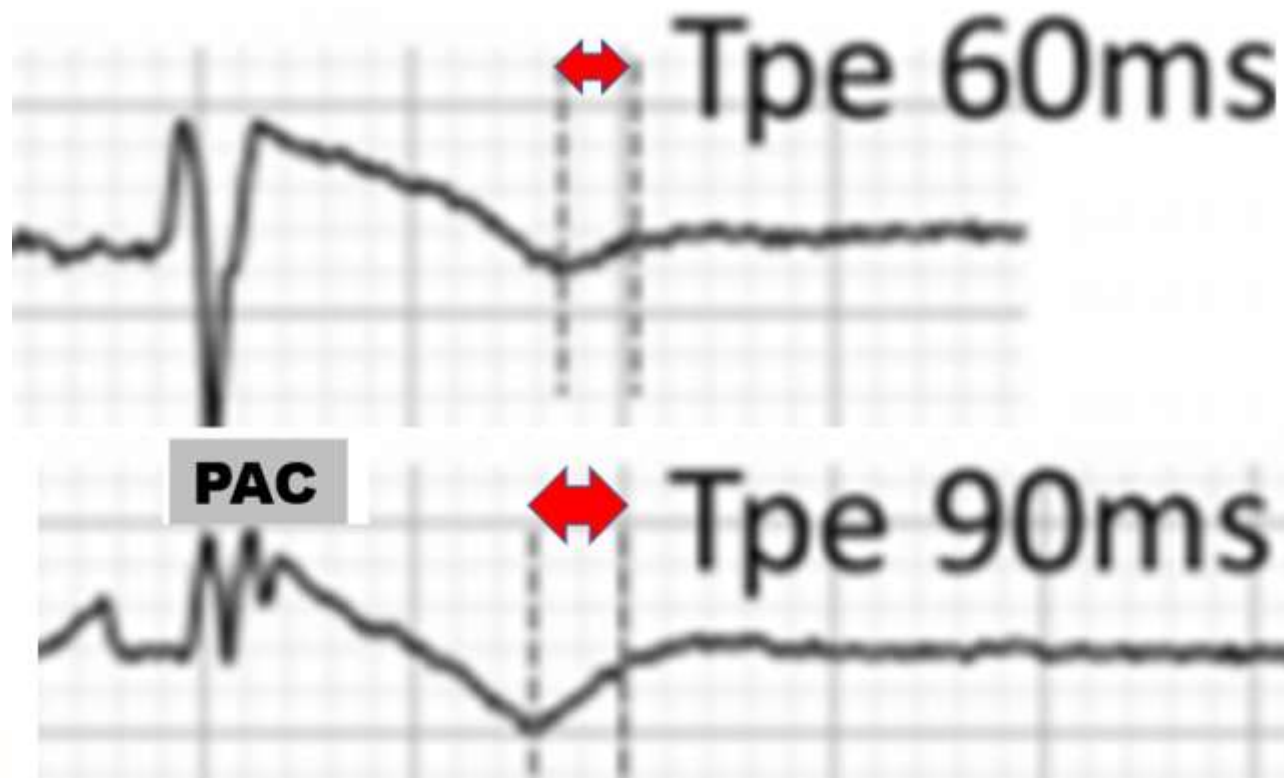
The amplitude of final R wave of **PAC** in lead aVR is minimally also larger: RVOT conduction delay



Slow dromotropic disturbance in the RVOT (depolarization hypothesis).



The third QRS complex is a premature atrial complex (**PAC**). It shows wider QRS and deeper S wave in the inferolateral leads II, aVF, V5, and V6



Interval elapsed from the apex to the end of T wave (Tpeak-Tend interval or Tpe). Tpe may correspond to transmural dispersion of repolarization and consequently, the amplification of this interval is associated to malignant ventricular arrhythmias

Premature atrial contraction (PAC) -induced premature activation of ventricle exacerbates ventricular conduction and results in prolongation of QRS interval, fragmented (fQRS), and S width, and decrease in QRS amplitude (**Nagase S, 2020**).

ECG markers in identifying patients at risk in Brugada syndrome

1. Augmented P-wave duration in lead II, P-wave dispersion (**Letsas, 2009**).
2. PR prolongation consequence of HV split or HV prolongation (**Miyamoto, 2011**).
3. The presence of atrial fibrillation (**Kusano, 2008**).
4. Presence of prominent final R wave on aVR lead R wave ≥ 3 mm or R/q ≥ 0.75 in lead aVR (aVR sign). Slow conduction at the RVOT may contribute to the induction of VF by PVS (**Babai Bigi, 2007**).
5. The presence of a spontaneous type I ECG, history of syncope, ventricular effective refractory period <200 ms, and QRS fragmentation seem useful to identify candidates for prophylactic ICD (**Priori, 2012**).
6. Inferolateral early repolarization (**Kamakura, 2009**).
7. Prolonged QRS duration measured from lead II or lead V2 ≥ 120 ms (**Junttila, 2008**).
8. QTc interval more than 460 ms in lead V2 (**Take, 2011**) and QT-interval prolongation in right precordial leads (**Pitzalis, 2003**).
Increase in QRS complex duration ($>110^\circ$) in the right precordial leads, in absence of CRBBB: parietal block.
9. $T_{\text{peak}} - T_{\text{end}}$ prolongation and $T_{\text{peak}} - T_{\text{end}}$ dispersion (**Castro Hevia, 2006**).
10. Loss of rate-dependent QT dynamics (**Sangawa, 2009**).

11. The presence of horizontal (as opposed to rapidly ascending) ST segment after the J point (**Takagi, 2013**).
12. Augmentation of the ST segment elevation during the early recovery phase of exercise test (**Makimoto, 2010**).
13. Concomitant high daily fluctuation of ECG and positive signal-averaged electrocardiogram (SAECG) parameters (**Tatsumi H, 2006**).
14. Dynamic alterations in the amplitude of the ST elevation (**Take, 2011**).
15. Deep negative T wave in lead V1 (**Miyamoto, 2011**).
16. Day-to-day variations/ fluctuation of T wave amplitude variability (**Yoshioka K, 2013**).
17. The presence of late potentials (LPs) (**Ikeda, 2001**).
18. The appearance and disappearance of the J wave
19. Increased Tpeak-Tend interval as a marker of dispersion of repolarization (**Castro Hevia, 2006; Lambiase, 2010; Wang, 2007; Antzelevitch, 2017**). Tpeak-Tend interval has been proposed as a marker of transmural dispersion of repolarization. However, preferential delayed activation in the epicardium can also delay the end of local repolarization, leading to the dispersion of repolarization.
20. Decreased QT/RR-variability (**Talib, 2014**).

Sieira’s risk score model with all variables that showed statistical relationship with events in patients with BrS (**Sieira, 2017**): score include:

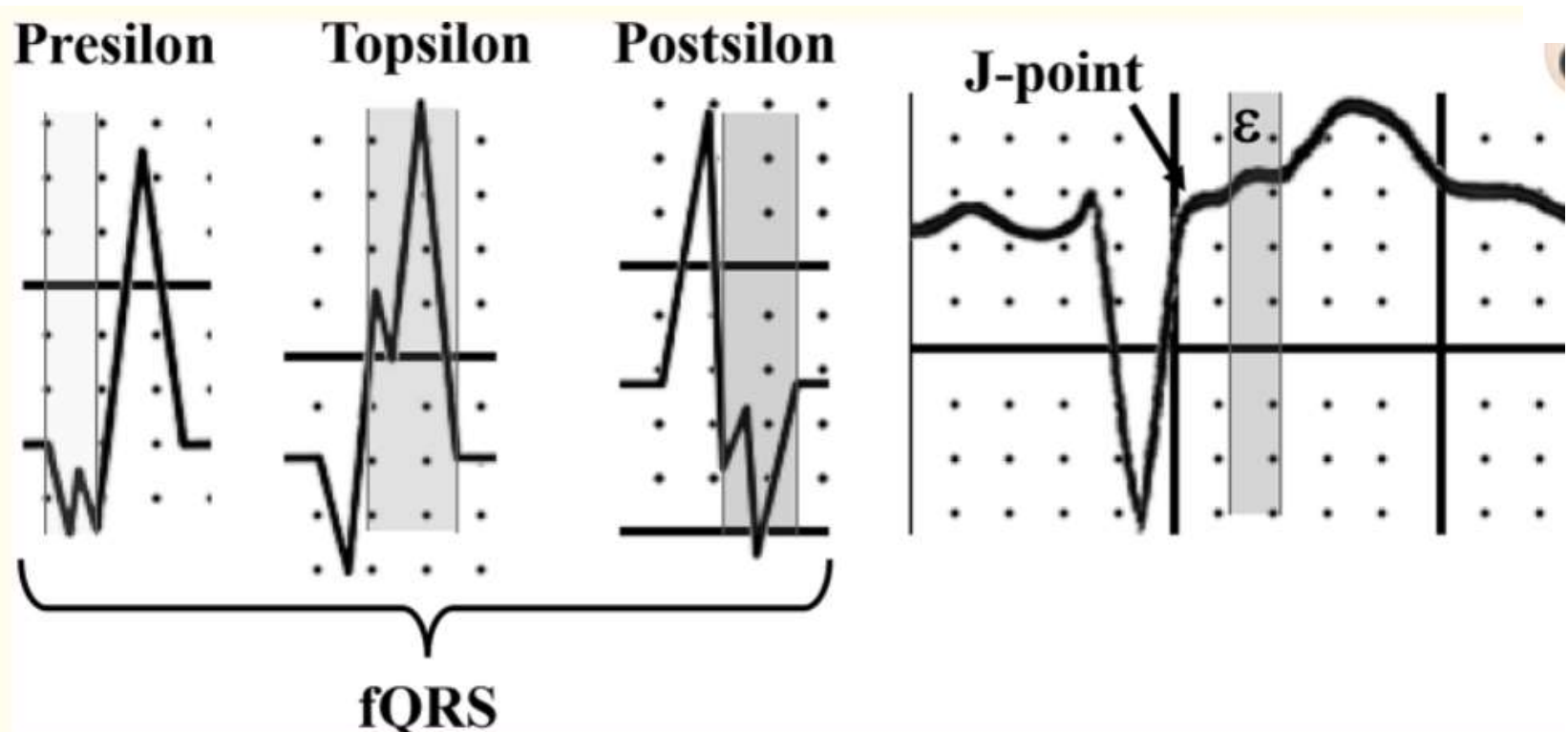
Risk factor	Points
Spontaneous type 1 pattern	1
Early familial antecedents of SCD. Early SCD in first-degree relatives had an event incidence rate of 3.1% year as compared with 1.3% year if it was not present.	1
Inducible VF or VT lasting at least 30 s during EPS whit a single site of stimulation on RV apex, three basic pacing cycles (600, 500, and 430 ms), and introduction of up to three VPBs down to a minimum of 200 ms.	2
Presentation as syncope	2
Sinus node dysfunction (SND) (predictive performance of 0.82)	3
Presentation as aborted sudden cardiac death (SCD)	4

A score > 2 confer a 5-year event probability of 9.2%. This model had a high predictive performance: 0.90. The protocol for EPS is not yet standardized. It is also unclear whether EPS should be performed once or whether it should be repeated every few years.

Morita's Risk Evolution of ECG parameters with a comparison of asymptomatic patients with symptomatic patients: sustained or new appearance of type 1 ECG, increase in QRS and Tpe intervals, and increase in fQRS. If patients have the progression of these ECG abnormalities, prophylactic ICD implantation will be considered. (**Morita, 2018**). Some questions still remain: for example, it is well known that most of the time, BrS patients have very long periods where they are asymptomatic even after a VF episode. Moreover, why is there usually a peak of events around age 40 but a decrease in the event rate after this age? If there were a progression of ECG parameters over time, one could suppose that the risk of this pathology progresses over time which is definitely not the case in this pathology. So, even if it is probably too early to directly adapt this information to clinical practice, the authors should be thanked for having stressed the importance of the regular follow-up of BrS patients with special attention to ECG criteria related to arrhythmic risk. (**Probst, 2018**).

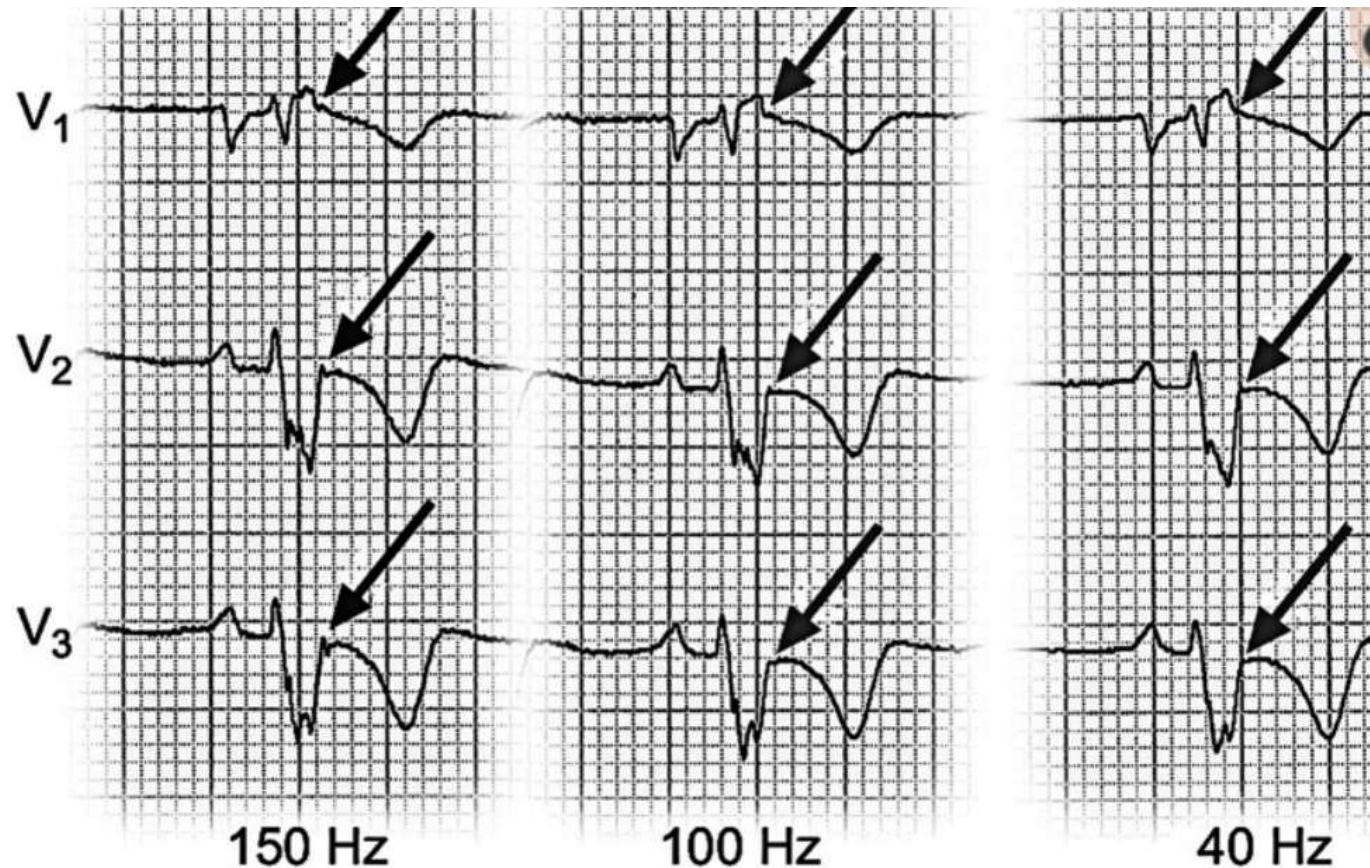
Researches have demonstrated overlap features between BrS and ARVC.

1. Sodium channel blockers can induce BrS ECG pattern in a subgroup of patients with ARVC (**Peters, 2004**)
2. Epsilon-like waves are seen in some patients with type 1 ECG Brugada pattern. Epsilon-like waves are more common in drug-induced type 1 ECGs than in spontaneous type 1 ECGs (**Letsas, 2011**) such as the present case. Rather than using the term “epsilon wave,” we use the term “epsilon-like wave” because distinguishing the epsilon wave from the fQRS wave was difficult.
3. The epsilon wave is located between the end of the QRS complex and beginning of the ST-segment. In contrast, a fQRS is defined as the presence of additional spikes within the QRS complex. (**Pérez-Riera, 2019**).



The side figure shows the three possibilities of fragmented QRS in ARVC: at the beginning (**Presilon**), in the middle (**Topsilon**) and at the end (**Postsilon**) of the QRS complex, and when the ϵ wave is located after the J-point and the beginning of the ST-segment. Although the ϵ wave is a depolarization abnormality (late potential), it is recorded at the beginning of repolarization.

4. Because the epsilon wave is of low amplitude, it may be affected by ECG filter settings. At the recommended 150-Hz cutoff frequency the epsilon (ϵ) wave is best detected in the right precordial leads. Currently ECG guidelines recommend a cutoff of 150 Hz for adolescents and adults and 250 Hz for children (Kligfield, 2007). The ECG acquisition is often accompanied by high-frequency electromyographic noise. The noise is difficult to filter due to considerable overlapping of its frequency spectrum with the frequency spectrum of the ECG. In clinical practice a 40-Hz cutoff frequency may be used to reduce muscle noise and improve the appearance of the tracing. This approach results in the loss of important information, which was demonstrated in a case report, where ϵ waves were masked by excessive low-pass filtering in a patient with ARVC (Fig. below). Therefore, it is possible that the prevalence of the ϵ wave in ARVC patients may be underestimated.



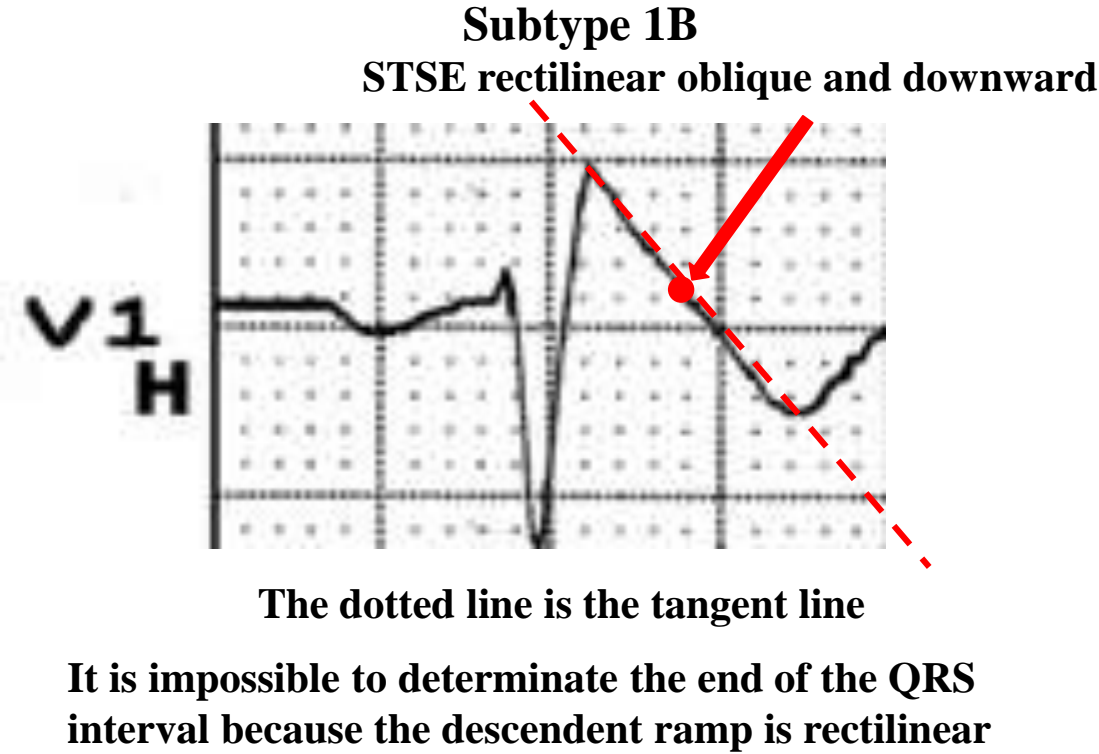
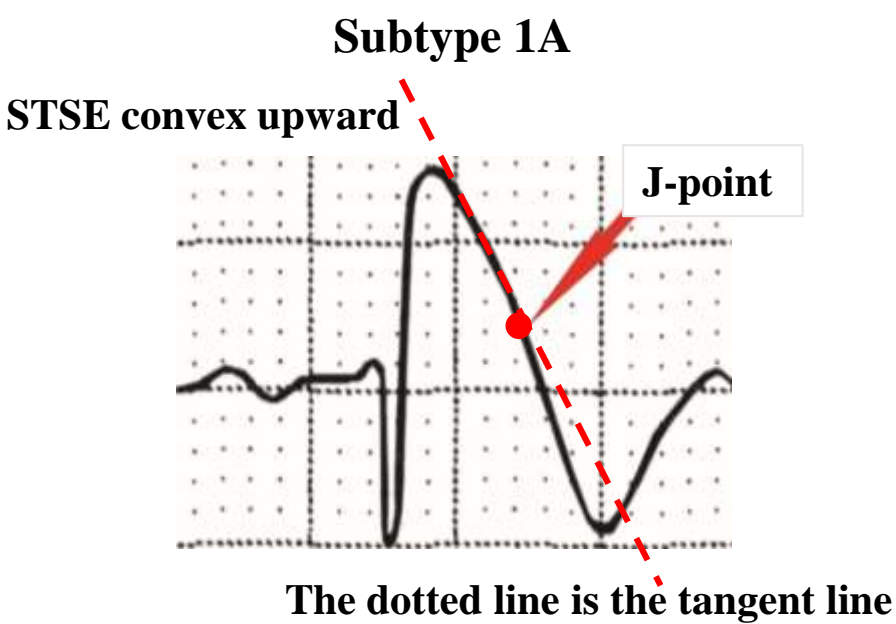
Epsilon wave only observed with 150 Hz filter. Low-pass filter cutoff frequency influences the detection of the ϵ wave in AC: at the recommended 150 Hz cutoff frequency, the ϵ wave is detected in leads V1-V3. At a 100 Hz cutoff frequency, the ϵ wave is attenuated in V1-V2 and absent in V3. At 40 Hz, the ϵ wave disappears from leads V1-V3 (modified from (Garcia-Niebla, 2016)).

5. The occurrence of additional spikes at the end of QRS complex or immediately after the QRS complex in BrS is not certain. The term “epsilon-like wave” has been used to avoid such discrepancies in ECG interpretation.
6. Epsilon and fQRS have similarly high diagnostic values, and epsilon-like potentials in different leads at the beginning, top, or end of the QRS complex are typical ECG findings in patients with ARVC (**Zhang L & Riera 2006**).
7. RV wall motion abnormalities or RV dilatation, characteristic of ARVC, has been observed in patients with BrS (**Catalano, 2009**).
8. Zumhagen S et al. detected during endocardial biopsies of patients with type 1 ECG Brugada fibrofatty replacement (**Zumhagen, 2009**).
9. Gene mutations involving ARVC/D have been identified in some patients with BrS (**Koopmann, 2007**). These overlapping features are considered a result either of genetic interactions or of the combined influence of BrS’ electrophysiological abnormalities and ARVC/D’s structural abnormalities.
10. A subgroup of BrS patients may demonstrate the features of ARVC long after the initial BrS diagnosis. Structural heart diseases and histological findings consistent with ARVC have been revealed after autopsy of patients who were diagnosed with BrS and who died suddenly (**Tada, 1998**). Thus, careful observation of the changing clinical course is vital and may indicate the transformation from BrS to ARVC. Detailed evaluation in the cases of suspected overlap of BrS and ARVC is needed to determine a better treatment course for these patients.

4. In BrS, frequently, defining the end of QRS interval is difficult, and it is still controversial where the J wave represents depolarization component or repolarization component.

Where is the end of QRS complex (J point) in the subtype 1B?

Right precordial leads



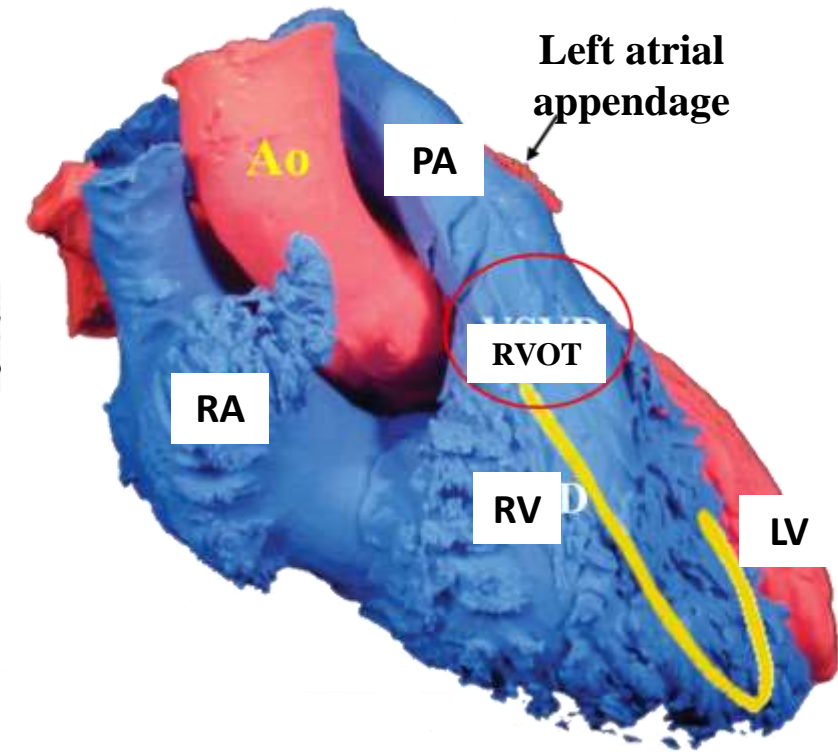
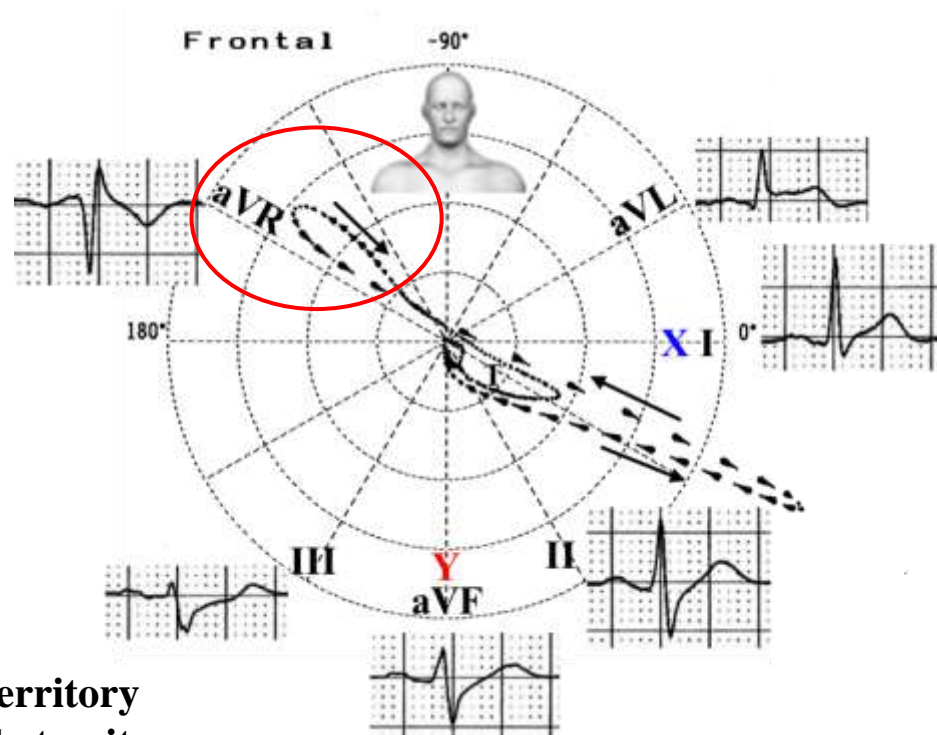
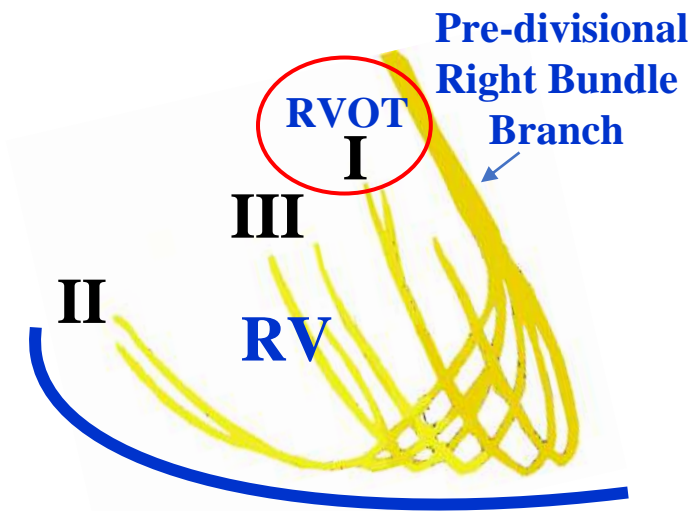
In BrS with type 1 ECG pattern, and in concealed forms of ARVC/D, it is difficult to determine accurately when the QRS complex ends and repolarization starts; in other words, it is difficult to know the precise location of the J point.

- 11. QRS complexes duration in $\frac{V_1+V_2+V_3}{V_4+V_5+V_6}$ is \geq than 1.2 are observed in both ARCD and BrS
- 12. BrS may display prolongation in QT interval duration from V_1 to V_3 and subsequently prolongation of QTc interval in the right precordial leads (**Pitzalis 2003**).
- 13. Increase in QRS interval duration ($>110^\circ$) in V_1 , V_2 and V_3 , in absence of CRBBB: parietal block.is observed in both entities ARVC and BrS
- 14. Late potentials in high resolution ECG are registered in both entities .

ARVC versus BrS (Modified from **Corrado, 2016**)

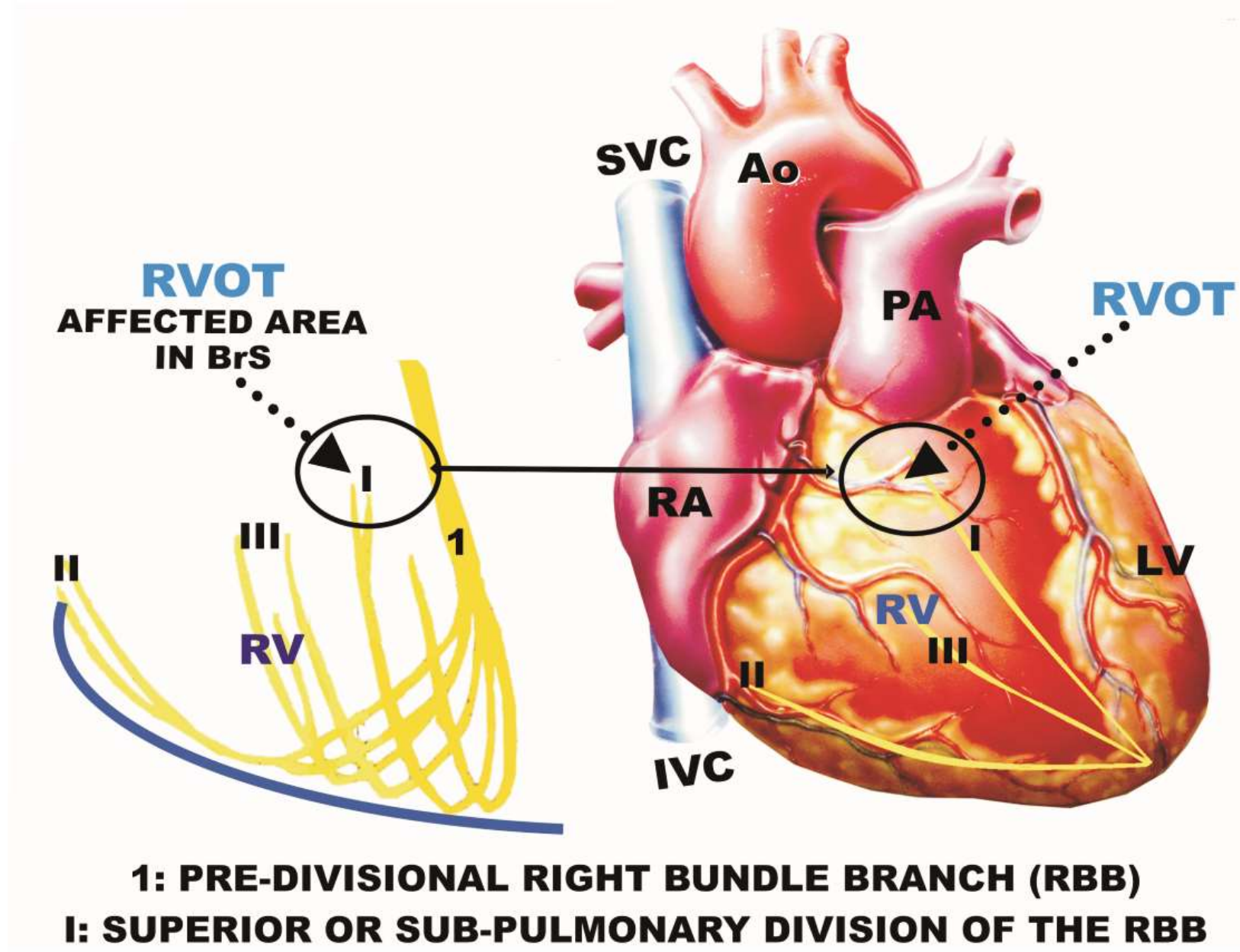
	ARVC	BrS
Age of presentation (yrs)	15-30	30-40
Gender and race	M/F 3:1	M/F 8:1 Asian precominance
Distribution	Word-wide. Italy, Naxos Island Grece	Word-wide Southeast Asia: Thailand “ lai-tai”, Philippines “bangungut”” Japan “pokkuri”,
Inheritance	AD AR	AD
Predominant pathogenetic genes	Desmossomal genes	SCN5A
Typical symptoms Events circunstance	Palpitations, syncope, cardiac arest. Events at esforce	Syncope and or cardiac arest predominat at rest or sleep
ECG changes	Fixed , TWI on right precordial, epsilon wave, AV conduction times normals, MVT wih LBBB patern, VF	Dynamics, Type 1/Type 2 frequently prolonged P-wave, PR interval, QRS interval, HV, split His, AF, polymorphic VT, rare MVT, VF
Mechanism of VT	Scar-realted reentry	Phase 2 reentry
Natural history	Sudden death, heart failure	Sudden death

Distribution of the three fascicles of the His bundle right branch in the RV free wall



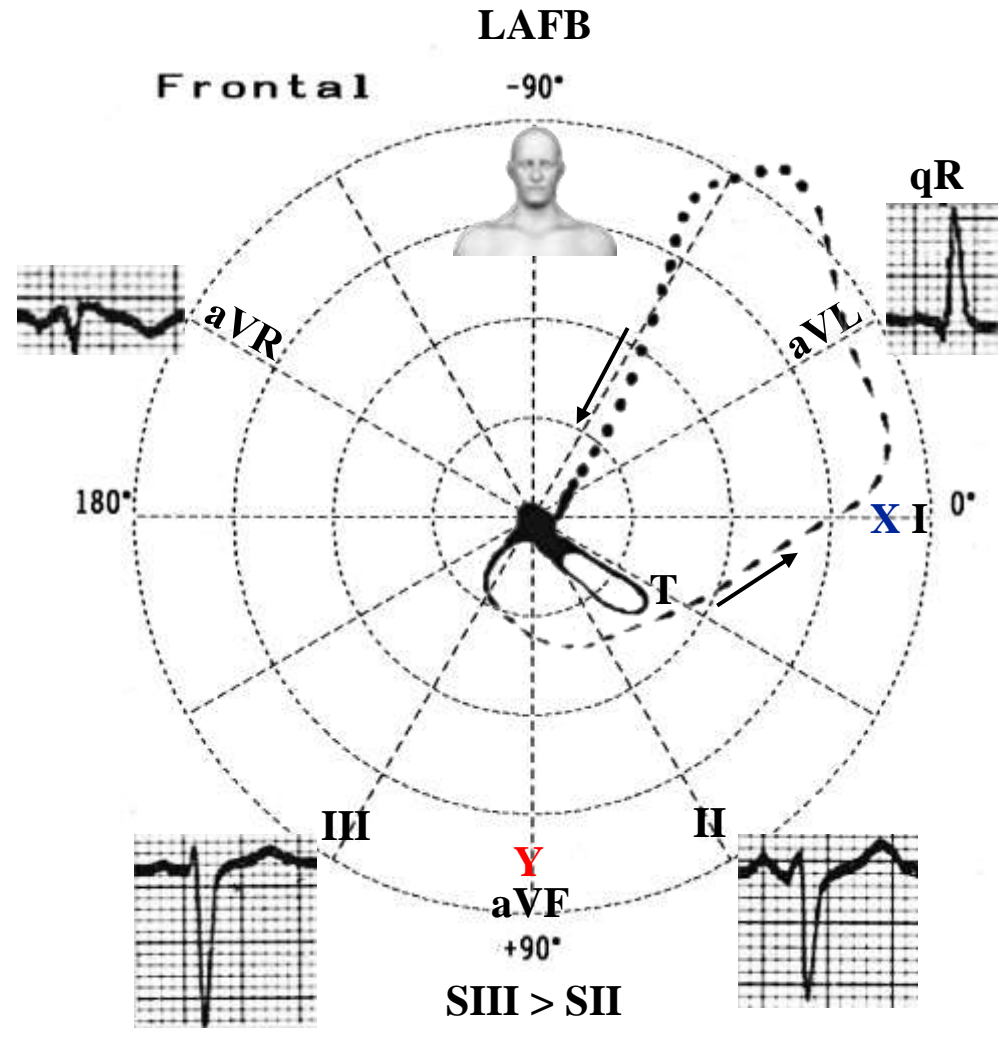
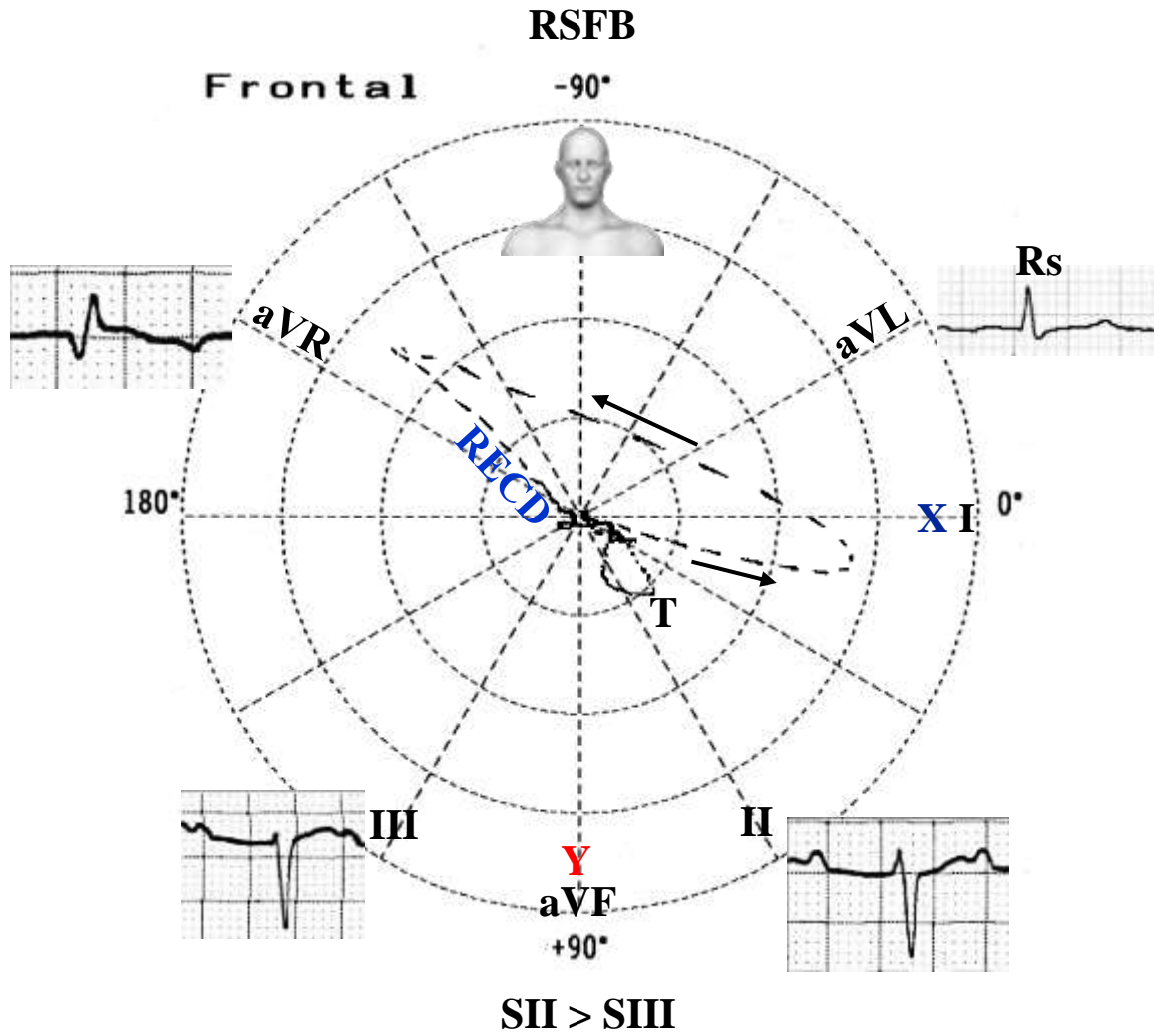
- I – Superior or subpulmonary fascicle territory**
- II – Inferior or posterior-inferior fascicle territory**
- III – Middle fascicle territory**

Structural epicardial alterations in the right ventricular outflow tract (RVOT) are the substrate for the conduction anomalies in Brugada syndrome (BrS). Electroanatomic mapping of endocardial unipolar voltage is an emerging tool that identifies accurately epicardial anomalies in the RVOT in BrS. Endocardial unipolar voltage mapping of the RVOT detects electroanatomical abnormalities in patients with BrS. Wide areas of abnormalities in endocardial unipolar voltage reflect structural epicardial abnormalities in the RVOT of patients with BrS (Letsas KP. Europace. 2018 Jun 1;20(FI1):f57-f63). BrS is associated to interstitial subepicardial fibrosis and a reduction in gap junction expression (connexin-43) in the RVOT, responsible for abnormal potentials, and its ablation abolishes BrS phenotype and arrhythmias risky for life. BrS is also associated to an increase in collagen throughout the heart. Abnormal myocardial structure and conduction are, therefore, responsible for BrS (Nademanee K. J Am Coll Cardiol. 2015 Nov 3;66(18):1976-1986).



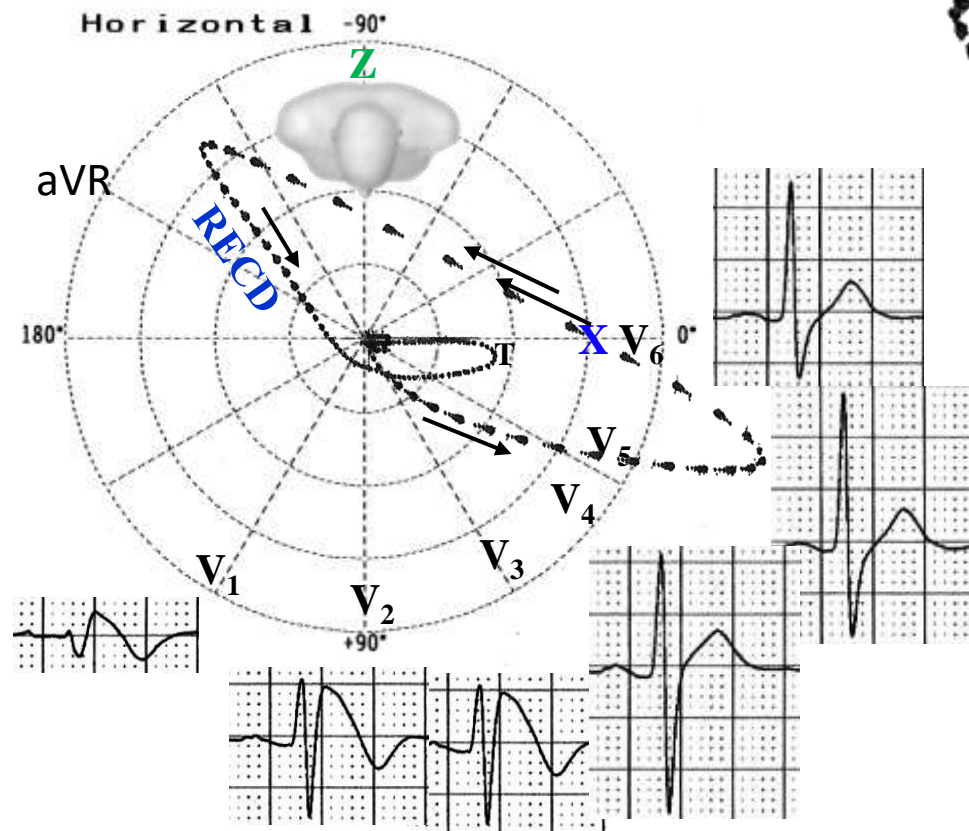
The figure shows the three hypothetical clusters of fibers (I, II and II) on the free wall of the right ventricle, and the partial superior right Hissian system affected in BrS: “Right Superior Fascicular Block” (depolarization mechanism).

ECG/VCG differential diagnosis between right superior fascicular block (RSFB) and left anterior fascicular block (LAFB) (**Pérez-Riera, 2005**)

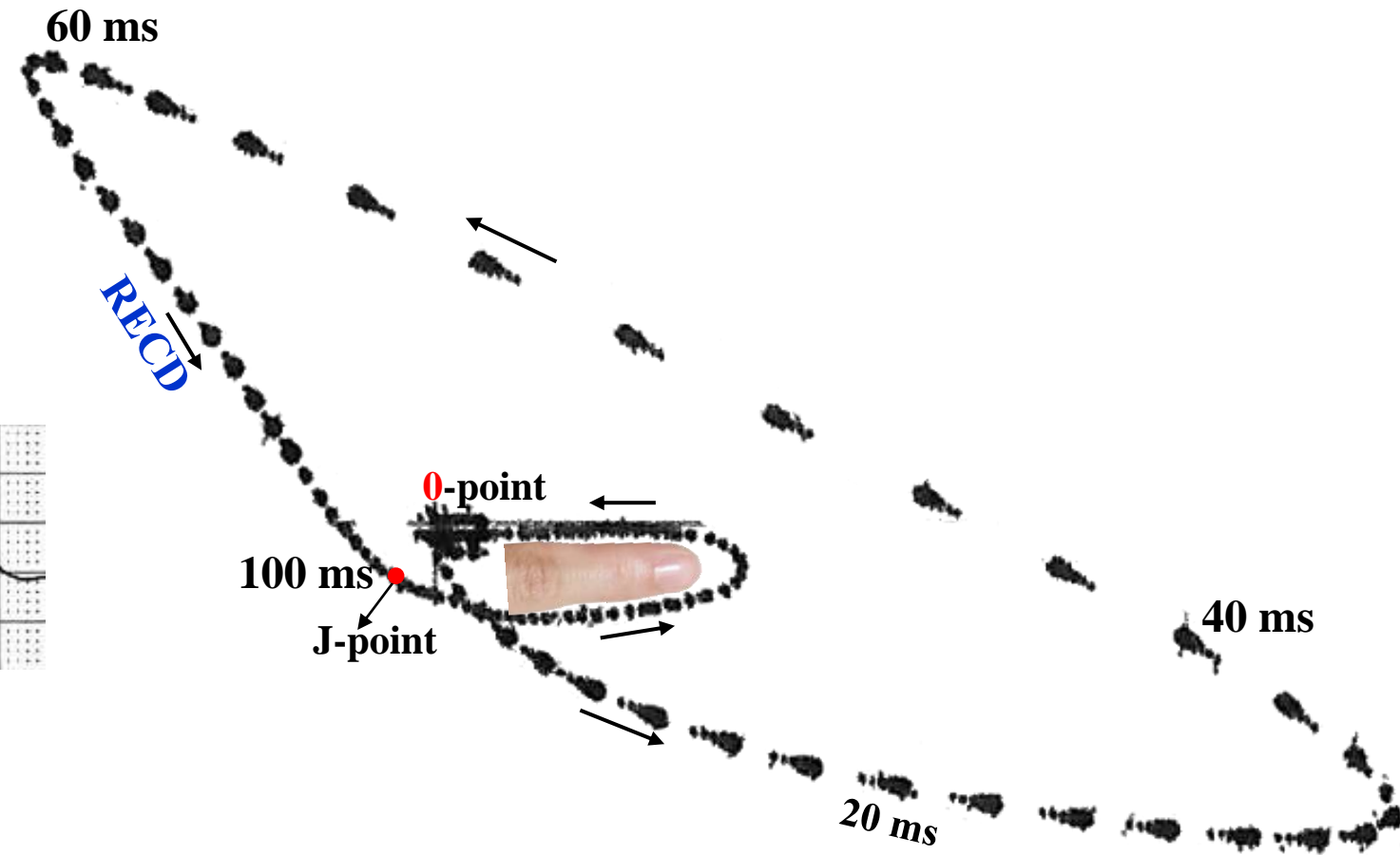


	LAFB	RSFB
Initial 10 ms vector of QRS loop	Heading downward and to the right	Heading downward and to the left
QRS morphology in I & aVL	qR pattern	Rs
SII/SIII ratio	SIII>SII	SII>SIII
Location of end conduction delay (ECD)	In the left superior quadrant when present	In the right superior quadrant (Pastore, 1983)
Prominent R wave in aVR (R-wave \geq 0.3 mV)	Absent	It could be present and it is called aVR sign (Babai Bigi, 2007).
Morphology of QRS loop of vectorcardiogram in the horizontal plane	Similar to normal	Similar to type-C right enlargement pattern: initial vector to the front and leftward, counterclockwise rotation and 20% or more of the area of the loop located in the right posterior quadrant in the horizontal plane (Luna Filho, 1989)

ECG/VCG correlation in the horizontal plane




QRS and T loops characteristics in the horizontal plane




Initial 20ms forces directed to front and leftward, rapid passage from left to right between 40ms to 60ms and the final 40ms with Right End Conduction Delay (**RECD**) on posterior right quadrant: **depolarization mechanism**. J-point in the front and the right related the point **0**. Both points are very distant from each other, which marks the elevation of point J and the ST segment typical of Brugada type 1 pattern, The T-loop pointing left as a finger, with both efferent and afferent limbs with slow and similar speed inscription. The QRS loop remembers the type C right ventricular overload typical of chronic obstructive pulmonary disease(COPD) or emphysema (**Luna filho, 1989**).

Normal T loop in the HP




Points J and 0 together.
 Shape: elongated, elliptic or linear.
 Direction: to the left and front, around 23° (-14° to $+45^\circ$).
 Efferent limb of slower inscription than the afferent one.
 Rotation: nearly always counterclockwise, except for the linear morphology.
 Magnitude: mean 0.34 mV (0.15 to 0.60 mV).
 QRS/T angle: it could be as wide as 93° .



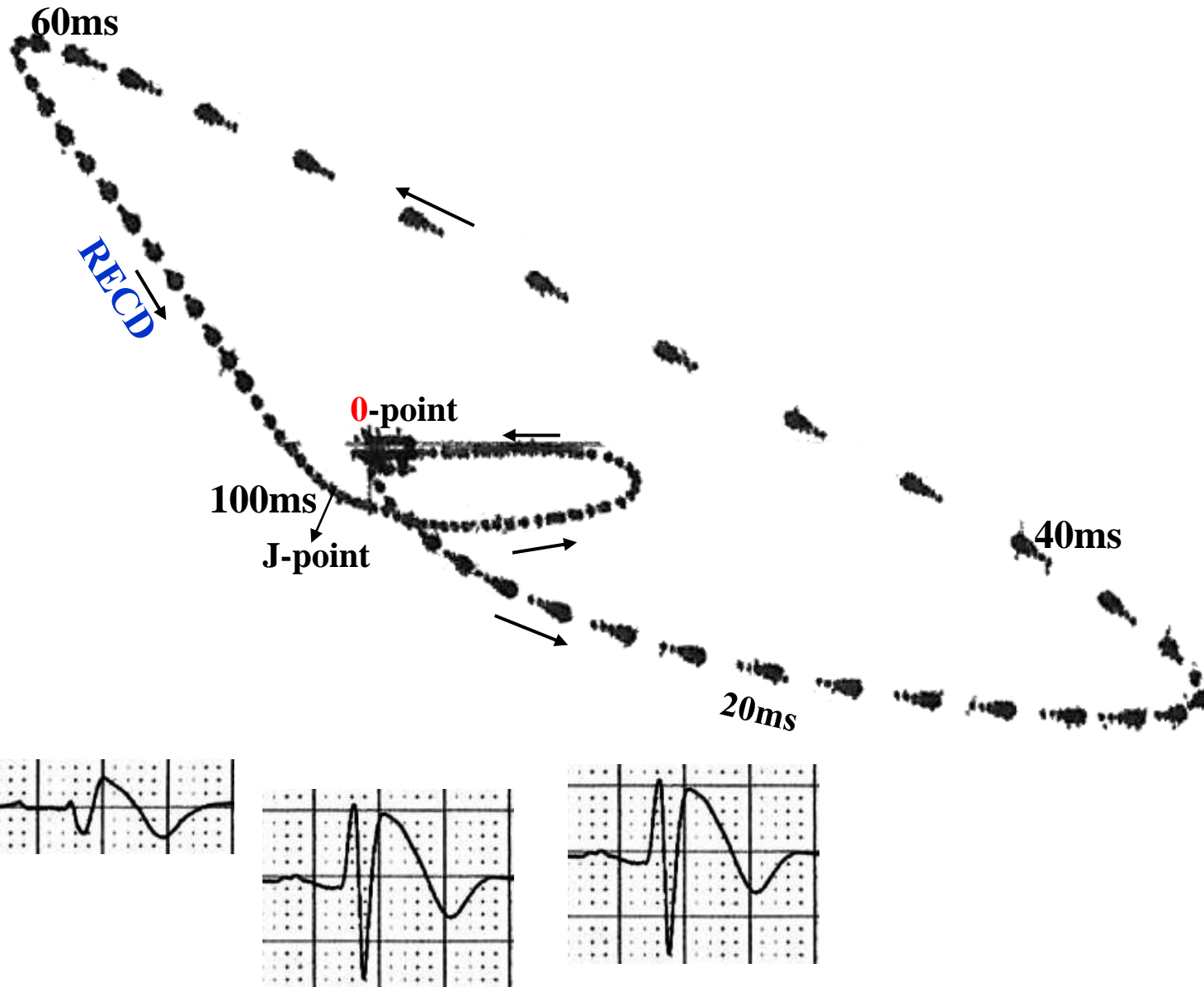
T loop in type 1 Brugada pattern

We propose “index finger” sign to denominate the T loop in the horizontal plane.



Points J and 0 are separated ≥ 2 mm, indicating J point and ST segment elevation. When both points are distant >1 mm it indicates ST segment elevation, which is not observed in VCG. This may be indicative of early repolarization pattern, Brugada syndrome with types 1 and 2 pattern, idiopathic ventricular fibrillation, congenital short QT syndrome, ST-segment elevation acute coronary syndrome, Prinzmetal variant angina, acute pericarditis in phase 1, left ventricular aneurysm of anterior wall. Both the afferent and efferent limbs present slow inscription, dashes very close to one another.
 Shape: elliptic or with “finger” shape.
 Direction: to the left, around $+5^\circ$.
 Rotation: counterclockwise.
 Magnitude: 0.34 mV.
 QRS/T angle: 7° .

QRS and T loops characteristics in the horizontal plane in Brugada type 1 pattern QRS and T loops in RVH type C, III or special



RECD: right end conduction delay

