

Paciente masculino de 57 años cuyo ECG es sugestivo de miocardiopatía hipertrófica – 2008

Dr. Feliciano Pérez Casar

Estimado Edgardo, te envío este ECG por si crees de interés distribuirlo, en la forma que creas oportuna. Se trata de un varón de 57 años que acudió a chequeo de empresa. Ningún antecedente familiar o personal de interés. Exploración cardiaca normal. No hipertensión. No factores de riesgo. Ante el ECG le realizan ECO que es normal. Coronariografía que es normal. Gammagrafía isotópica que es normal. Me envían el ECG que está realizado en posición supina porque le van a hacer un test de esfuerzo para saber mi opinión antes de realizalo, ocultándome los datos que antes te he expuesto.

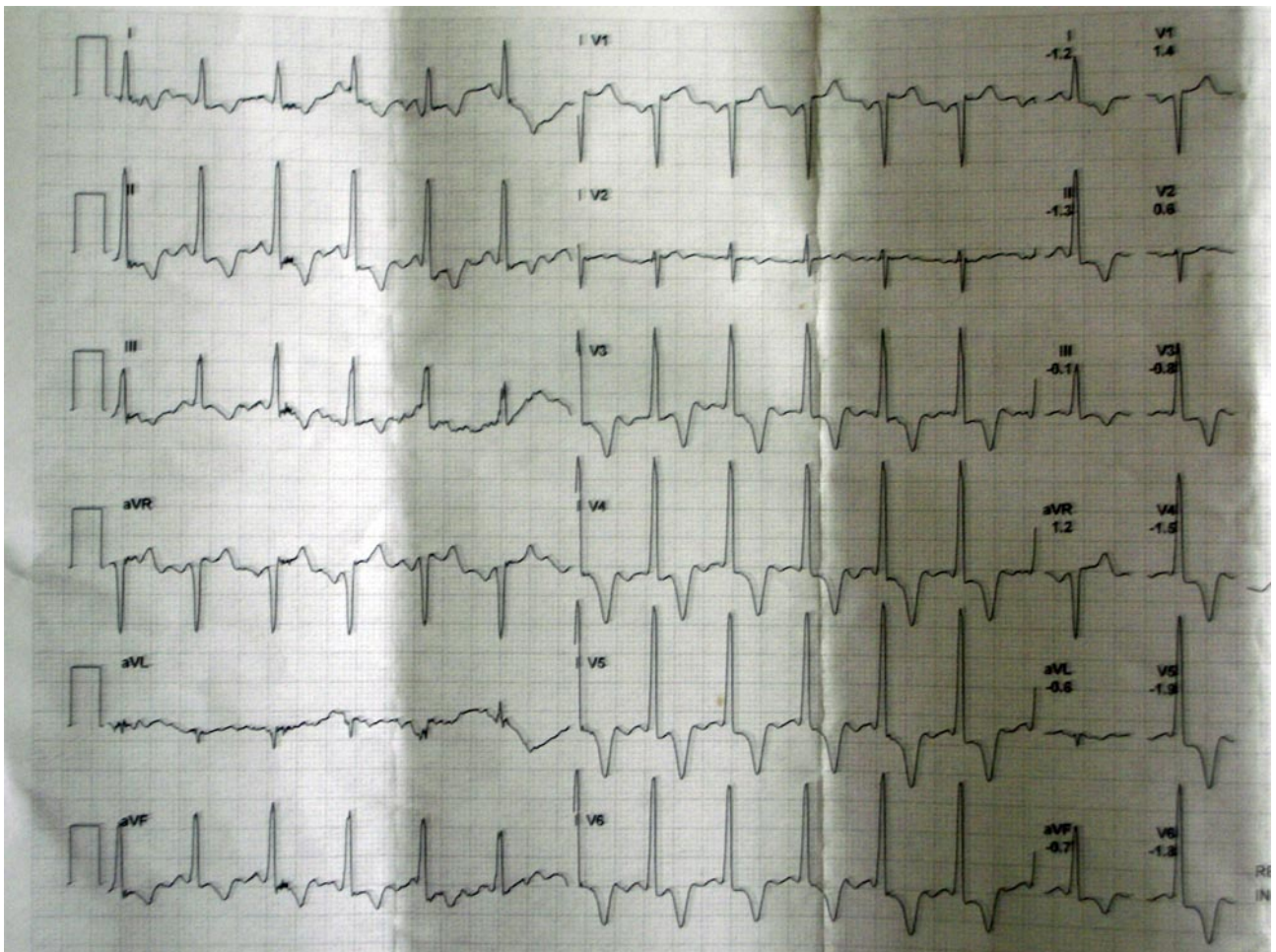
Opino que debe de realizarse y quedo pendiente de su resultado informándome a posteriori que es normal pero no veo el trazado.

El examen del mismo a mi juicio corresponde a un PR corto, con las alteraciones en la repolarización secundario al mismo, despolarización y repolarización acelerada. Dado que no son frecuentes dichas alteraciones en el PR corto, espero de la audiencia otras opiniones

Cordialmente

Feliciano Pérez Casar

PD: el Dr. Federico Curra ha colaborado en el tratamiento de la imagen



OPINIONES DE COLEGAS

Parece un ECG de Miocardiopatía Hipertrofica, es raro que el ECO haya sido normal. No veo lo del PR corto .

Dr. Amilcar Lezcano

Opino lo mismo que el Dr Lezcano. Esos altos voltajes del QRS sobre todo en precordiales junto a esas T negativas, simétricas y profundas con ascenso del ST en V1 y aVR van a favor de miocardiopatía hipertrófica.

Saludos,

Javier García Niebla.

Queridos amigos tenho forte suspeita que o “ecocardiografista” que fez o ECHO no detecto o problema. Isto - na nossa experiência - não é raro de acontecer nas cardiomiopatias hipertróficas apicais não obstrutivas. Existem forças anteriores proeminentes predominantes nas derivações intermediárias. Nestes casos, a parede livre do VE não possui o normal decréscimo da espessura da base ao ápice fato que em ecocardiografistas não muito experientes passa despercebido. Por outra parte o septo apresenta-se com maior espessura na parte inferior (apical) o que oculta os fatos em mãos não muito experientes. O ECG reflete SVE com “strain pattern” com ângulo QRS/T próximo dos 180° e ondas R proeminentes nas precordiais intermediárias. Concordo com Lescano e Javier.

Edgardo gostaria comentar outras coisinhas mas meu sobrinho esteve usando o computador e deve ter deletado o traçado.

Poderias me reenviar?

Envio-lhes estes comentários interessantes sem as figuras que são muito pesadas. Mas tarde se desejam mando as figuras. Peço desculpa porque este resumo o escrevi em english.

Apical Hypertrophic CardioMyopathy (ApHCM)

This entity may cause prominent anterior forces (PAF) translated by R waves with increased voltage in right precordial (V1-V2) and/or intermediary leads (V3-V4) **(1)**.

Prominent R waves in right precordial leads (V3R, V1 and V2) may be observed and mistakenly attributed to right ventricular hypertrophy (RVH), as PAF may be due to hypertrophy in the left septal mass, which causes increase of magnitude of the 1AM vector. Concomitantly, deep q or Q waves may be found; however with duration <40 ms (20 to 50% of cases) in inferior leads and/or from V4 through V6, because the septal vector frequently is heading upward, to the front and the right

A conclusive proof that wide R wave of right precordial leads may be due to left septal mass hypertrophy, is its disappearance after surgical myectomy on the left ventricular outflow tract (LVOT) area in patients with severe obstructive HCM, non responsive to drugs

Exceptionally, patterns of true RVH have been described in HCM, originating PAF, right anterior potentials, predominant and not dependent on left septal mass hypertrophy, since the echocardiographic study reveals RVH (2) In nonobstructive forms hypertrophic nonobstructive cardiomyopathy forms (NO-HCM)), Japanese researchers (3) have highlighted the relative frequency with which the typical electrocardiographic features of LSFH are observed:

- 1) R waves with great voltage in intermediary right precordial leads (mid-precordial changes);
- 2) R wave "in crescendo" from V2 through V4 and decreasing from V5 through V6;
- 3) Absence of initial q wave in left leads DI (87%) and V5 (91%);
- 4) Marked anterior and left shifts of QRS loop in the HP (74%) (> 2/3 of the QRS loop area located in the left anterior quadrant);
- 5) T loop located in the right posterior quadrant (91%).

The intraventricular septum (IVS) is thicker in its inferior part (absence of normal decrease in septal thickness at the base of the apex). Additionally, the free wall of the left ventricle is hypertrophic. Anterior and left shift of QRS loop is marked in the HP, and below and to the left in the FP, translated by R waves of greater voltage in V4 and DII, absence of q waves in the left leads and greater inversion of T wave in V4 and DII. The authors attribute the ECG-VCG modifications to selective hypertrophy of the inferior third or apex of IVS (involvement of the distal IVS and the apex).

The following is observed:

- 1) Anterior and left shift of QRS loop in the HP and below and to the left in the FP, translated by R waves with greater voltage in V4 and DII;
- 2) The absence of q waves in left leads is attributed by the authors to ILBBB or LSFH;

3) Greater T wave inversion in V4 and DII, and

4) T loop located back and to the right (this would be the result of delayed repolarization in the apical region)

Nakaya et al (4) observed PAF in HCM, particularly in NO-HCM as broad R from V2 through V4 and QRS loop with more than 2/3 of the area located in the left anterior quadrant, associated to absence of convexity at the right of the vector of the first 20 ms. The authors suggest that the phenomenon may be due to true LSF and attribute it to LSF involvement by fibrosis of the septum.

Acase reported from Nakaya et al, of a patient carrier of NO-HCM, where interventricular septum IVS has a very increased thickness in echocardiogram, and QRS loop of VCG in the HP with typical characteristics of LSF: 1) Absence of initial convexity to the right of the first 20 ms of QRS loop; 2) 2/3 of the area located in the left anterior quadrant (at the front of the X orthogonal lead (0° to $\pm 180^\circ$))

In this case the diagnosis of LSF is ruled out by the presence, although minimal, of initial q wave in left leads

Conclusion: SEVERE ApHCM, GREAT NONOBSTRUCTIVE SEPTAL HYPERTROPHY IN THE APICAL REGION.

NO-HCM localized to the cardiac apex (wall thickening is confined to the most distal region at the apex,) or apical hypertrophic cardiomyopathy (ApHCM) is a specific variant of HCM. This disease has been first described in where the prevalence is much higher than in the western world

ApHCM, occurs in only 1 to 2% of the non-Japanese population. Only a limited number of sarcomere gene defects (eg, cardiac actin Glu101Lys) consistently produce ApHCM (5). A single amino acid substitution in actin causes either CHF or maladaptive cardiac hypertrophy, depending on its effect on actin structure and function. De novo mutations in cardiac actin gene were identified in two patients with sporadic HCM who presented with syncope in early childhood. Patients were heterozygous for missense mutations resulting in Pro164Ala and Ala331Pro amino acid substitutions, adjacent to regions of actin-actin and actin-myosin interaction, respectively. A mutation that cosegregated with familial HCM was also found, causing a Glu99Lys substitution in a weak actomyosin binding domain. The cardiac phenotype in many affected patients was characterized by an ApHCM (6).

The typical features of AHC include:

1) Giant negative T waves in the precordial ECG leads Giant negative T waves negativity mayor or equal 1.0 mV (). Giant negative T waves are more common in Japanese patients than American patients: 15% invs 3% in US (7);

2) Sometimes R-wave voltage and T-wave negativity progressively decreased in magnitude at serial electrocardiograms;

3) Non-sustained or sustained VT in patients that developed apical aneurysm with normal coronary arteries;

4) A spade-like configuration of the left ventricle at end-systole in the right anterior oblique projection Non-spade ApHCM was newly identified on cardiac magnetic resonance (CMR) short-axis images, and this could be an additional, important underlying cause of moderately to severely inverted T waves. The area of hypertrophied myocardium is confined to a narrow region of the septum or the anterior or lateral wall at the apical level (non-spade apical hypertrophic cardiomyopathy (8));

5) The absence of an outflow tract pressure gradient;

6) Mild symptoms;

7) The prognosis of ApHCM with regard to SCD is believed to be better than that of common HCM Patients with the ApHCM had a benign clinical course. However, the mutation Arg719Trp in the cardiac beta-myosin heavy chain (beta MHC) gene is a high risk factor for sudden death and can be associated with an unusual ApHCM (9);

8) Progressing to myocardial necrosis and aneurysm formation because of the chronic myocardial ischemia at the apex eventually is observed (10);

9) 123I-MIBG imaging revealed regional sympathetic denervation in the inferior and lateral regions.

Recent observations suggest that the risk of SCD might be increased not only in common HCM, but also in Japanese-type ApHCM (11).

PES demonstrated reproducible induction of VF in aborted SD and presyncopal patients, resulting in the need for an ICD and amiodarone

Patients with refractory atrial fibrillation with a rapid ventricular response suffered from serious congestive heart failure (HF). A prudent assessment and strategy in patients with this disease would be indispensable in avoiding a disastrous outcome.

To clarify the mechanisms of ECG abnormalities in hypertrophic cardiomyopathy, 102 patients were examined with CMR. Distribution and magnitude of hypertrophy and late-enhancement were correlated with ECG abnormalities:

1) Abnormal Q waves reflect the interrelation between upper anterior septal thickness and other regions of the left and right ventricles, and wider Q waves are associated with late-enhancement;

2) Conduction disturbances and absent septal Q waves are associated with late-enhancement;

3) The depth of negative T waves is related to craniocaudal asymmetry and apical late-enhancement (12).

As many as 25% of Japanese patients with HCM have predominately apical involvement. Despite its low incidence, physicians caring for patients with chest pain need to consider ApHCM, in their differential diagnosis (13).

In ApHCM, sustained cavity obliteration is an important pathophysiologic condition as well as hypertrophy, ischemia, and prolonged QTc, which are considered jointly related to the development of aneurysm through interactions (14).

References

- 1) Maron BJ, Wolfson JK, Cirio E, et al Relation of electrocardiographic abnormalities and patterns of left ventricular hypertrophy identified by 2-dimensional echocardiography in patients with hypertrophic cardiomyopathy *Am J Cardiol.* 1983; 51:189-194.
- 2) Comella A, Magnacca M, Gistri R, et al Right ventricular involvement in hypertrophic cardiomyopathy. A case report and brief review of the literature *Ital J Cardiol.* 2004; 5:154-159.
- 3) Cheng CH, Nobuyoshi M, Kawai C, et al ECG pattern of left ventricular hypertrophy in non obstructive hypertrophic cardiomyopathy: The significance of the mid-precordial changes *Am J Cardiol.* 1997; 79:687-695.
- 4) Nakaya Y, Hiasa Y, Murayama Y, et al Prominent anterior QRS force as a manifestation of left septal fascicular block *J Electrocardiol.* 1978; 11:39-46.
- 5) Arad M, Penas-Lado M, Monserrat L, et al Gene mutations in apical hypertrophic cardiomyopathy *Circulation.* 2005; 112: 2805-2811.
- 6) Olson TM, Doan TO, Kishimoto NY, et al Inherited and de novo mutations in the cardiac actin gene cause hypertrophic cardiomyopathy *J Mol Cell Cardiol.* 2000; 32: 1687-1694.
- 7) Kitaoka H, Doi Y, Casey SA, Comparison of prevalence of apical hypertrophic cardiomyopathy in and the *Am J Cardiol.* 2003; 92:1183-1186.
- 8) Suzuki J, Watanabe F, Takenaka K, et al New subtype of apical hypertrophic cardiomyopathy identified with nuclear magnetic resonance imaging as an underlying cause of markedly inverted T waves *J Am Coll Cardiol.* 1993; 22: 1175-1181.
- 9) Dohlemann C, Hebe J, Meitinger T, Apical hypertrophic cardiomyopathy due to a de novo mutation Arg719Trp of the beta-myosin heavy chain gene and cardiac arrest in childhood A case report and family study. *J Am Coll Cardiol.* 2002; 39:638-645.
- 10) Marcus CB, Kapoor A, [Donohue TJ](#) Apical aneurysm in a patient with apical hypertrophic cardiomyopathy *Conn Med.* 2006; 70:297-300.
- 11) Ridjab D, Koch M, Zabel M, Schultheiss HP, [Morguet AJ](#) Cardiac Arrest and Ventricular Tachycardia in Japanese-Type Apical Hypertrophic Cardiomyopathy *Cardiology.* 2006; 107:81-86.
- 12) Dumont CA, Monserrat L, Soler R, et al Interpretation of electrocardiographic abnormalities in hypertrophic cardiomyopathy with cardiac magnetic resonance *Eur Heart J.* 2006; 27:1725-1731.

13) Iskandar SB, Dittus K, [Merrick D](#) Uncommon cause of a common disease South Med J 2003; 96:828-830.

14) Matsubara K, Nakamura T, Kuribayashi T, et al Sustained cavity obliteration and apical aneurysm formation in apical hypertrophic cardiomyopathy J Am Coll Cardiol. 2003; 42:288-295.

Abraço a todos

Andrés R. Pérez Riera

Sin ningún ánimo de defender al ecografista, y sólo de ser objetivo, es frecuente que en mi país -y supongo que en muchos de la región también- ("en todas partes se cuecen habas") se solicite un estudio ecocardiográfico sin ofrecer al ecocardiografista ningún dato. Quien ve imágenes no es ningún adivino y debe tener al menos un breve resumen del cuadro clínico y los exámenes previos efectuados (ECG y Rx de tórax, habitualmente). En tal caso, buscará apuntar mejor para encontrar algún daño estructural cardíaco. Si yo observara previamente ese trazado, por supuesto que buscaría algún segmento hipertrófico del SIV. Si fuera en el caso un miocardiopatía hipertrófica apical no obstructiva (como pareciera sugerir Andrés), ¿qué recomendaciones darían al paciente? Tengo la impresión -no la certeza- que la estrategia terapéutica sería diferente que si fuera una hipertrofia septal basal obstructiva del tracto de salida del ventrículo izquierdo (miomectomía,"alcoholización" del segmento afectado)

Cordial saludo

Luciano Pereira

Estimados colegas.

Pienso que se ha hecho un excelente análisis del ECG de este paciente y me sumo al criterio de que las ondas T negativas y profundas en precordiales, a veces más difusas y los grandes vectores se corresponden con una cardiomiopatía hipertrófica de la variedad apical, que por ser del tipo no obstructivas, (No SAM, ni gradiente sistólico en TSVI), tienen un curso más benigno, por lo que algunas de las investigaciones pueden resultar negativas, como se expone. No obstante quería referirme al Ecocardiograma que constituye mi perfil básico y sin ánimo de criticar o ser poco ético, estaría más conforme con una foto de una vista 4C apical ó longitudinal, para poder afirmar que este estudio resulta totalmente negativo.

Saludos.

Dr. Francisco Rodríguez Martorell.

Apreciados colegas, estoy de acuerdo con la mayoría de las opiniones sobre una posible Miocardiopatía Hipertrófica (un ECG muy típico) en un paciente sin antecedentes patológicos y actualmente asintomático. Sabemos bien que en la mayoría no hay clínica, pero para otros la primera manifestación puede ser la muerte súbita, por eso mismo debemos tener cuidado en la realización de las pruebas diagnósticas. Sería ideal repetirla y enviar las imágenes para descartar nuestras dudas. Realizo pruebas de esfuerzo a deportistas de élite dos veces por semana (la mayoría son de raza negra) y en una Ecocardiografía (previa a la PE), detecté un septum de 18mm con un claro diagnóstico de MHO en un atleta que jamás había sido estudiado. Sería bueno repetirla y así descartar las dudas.

Me llama la atención la realización de la coronariografía. ¿Cuál era el motivo?

Atentamente,

Dr. Oswald Londono

