

Single episode of wide unstable QRS complex wide tachycardia in a elderly man with coronary heart disease and severe left ventricular dysfunction



Marcelo **Garcia-Leal**, MD, Ribeirão Preto, SP, Brazil

Médico assistente da divisão de Cardiologia do Hospital das Clínicas da Faculdade de Medicina de Ribeirão Preto-USP

Portuguese:

Relato de caso

Paciente de 68 anos, branco, sabidamente portador de cardiomiopatia isquêmica, com severa disfunção ventricular por sequela de infartos em várias paredes, com queixa de um episódio de palpitações rápidas que desencadeavam dor torácica e hipotensão (sem síncope, nem afetação cognitiva). Foi considerado instável e revertido com cardioversão elétrica. A análise do evento (Figura 1) nos sugeria TV tanto pelo aspecto clínico quanto eletrocardiográfico. Talvez o início do QRS rápido nas derivações inferiores poderia sugerir taquicardia supraventricular com aberrância. O paciente nos foi encaminhado para possível implante do CDI. Mas ao analisar o ECG pós reversão (Figura 2), notamos semelhança com o padrão do evento.

Perguntas:

1. Qual diagnóstico do evento (Figura 1) e pós evento (Figura 2) sem considerar o conhecimento do ritmo de base?
2. Qual a conduta apropriada?

Dr. Marcelo **Garcia-Leal**, Ribeirão Preto, SP, Brasil

English

Case report

A 68-year-old, male, Caucasian, known to have ischemic cardiomyopathy, with severe ventricular dysfunction due to the sequelae of infarctions on several walls, complaining of an episode of rapid palpitations that triggered chest pain and hypotension (without syncope or cognitive impairment). It was considered unstable and reverted with electrical cardioversion. The analysis of the event (Figure 1) suggested VT in the clinical and electrocardiographic aspects. Perhaps the onset of rapid QRS in the lower leads could suggest supraventricular tachycardia with aberrancy. The patient was referred to our center for possible ICD implantation. But while analyzing the post-reversal ECG (Figure 2), we noted similarity with the pattern of the event.

Questions:

1. Which is the diagnosis of the event (Figure 1) and post event (Figure 2) without considering the knowledge of the base rhythm?
2. Which is the correct approach?

Figure 1

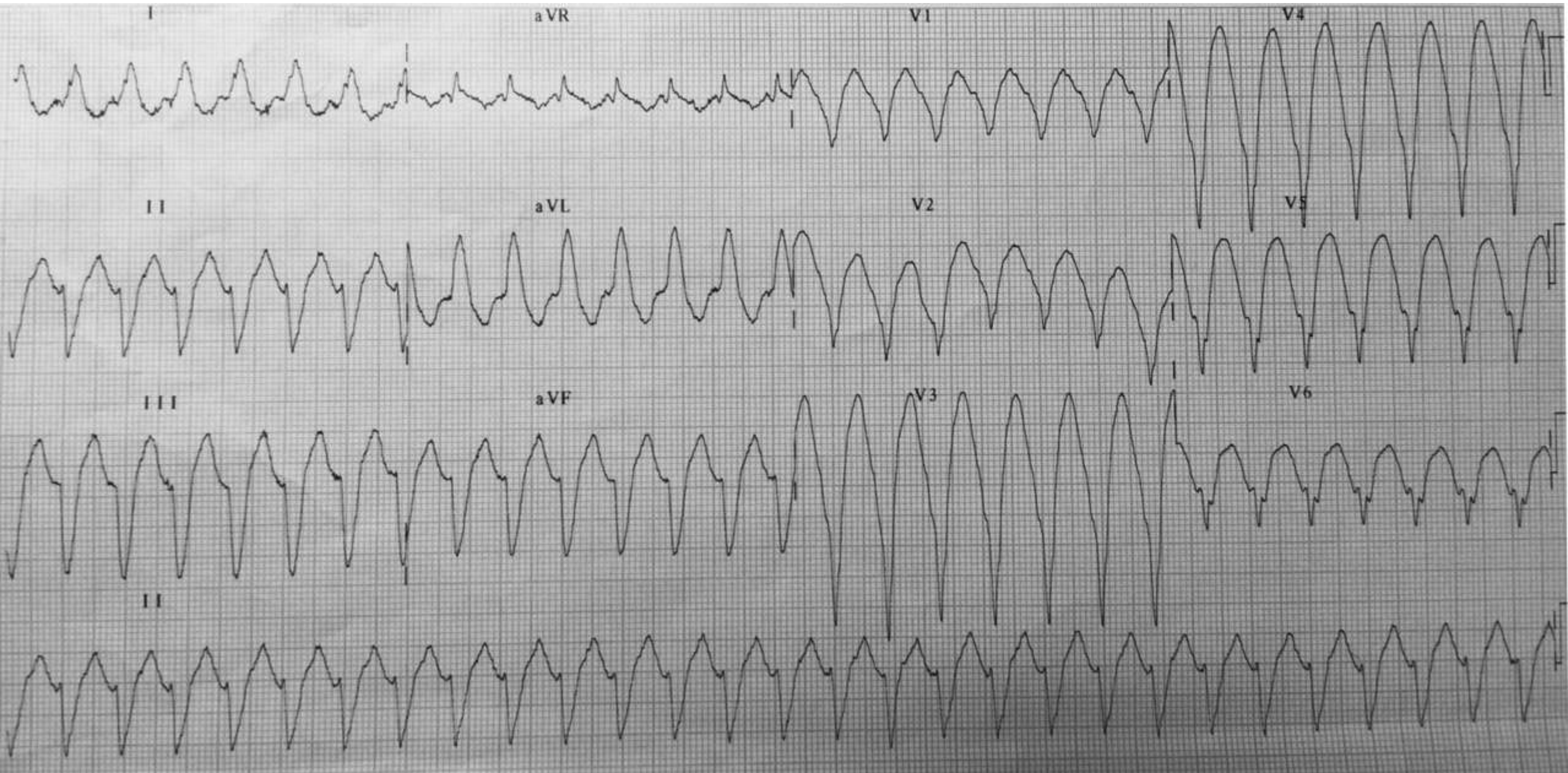
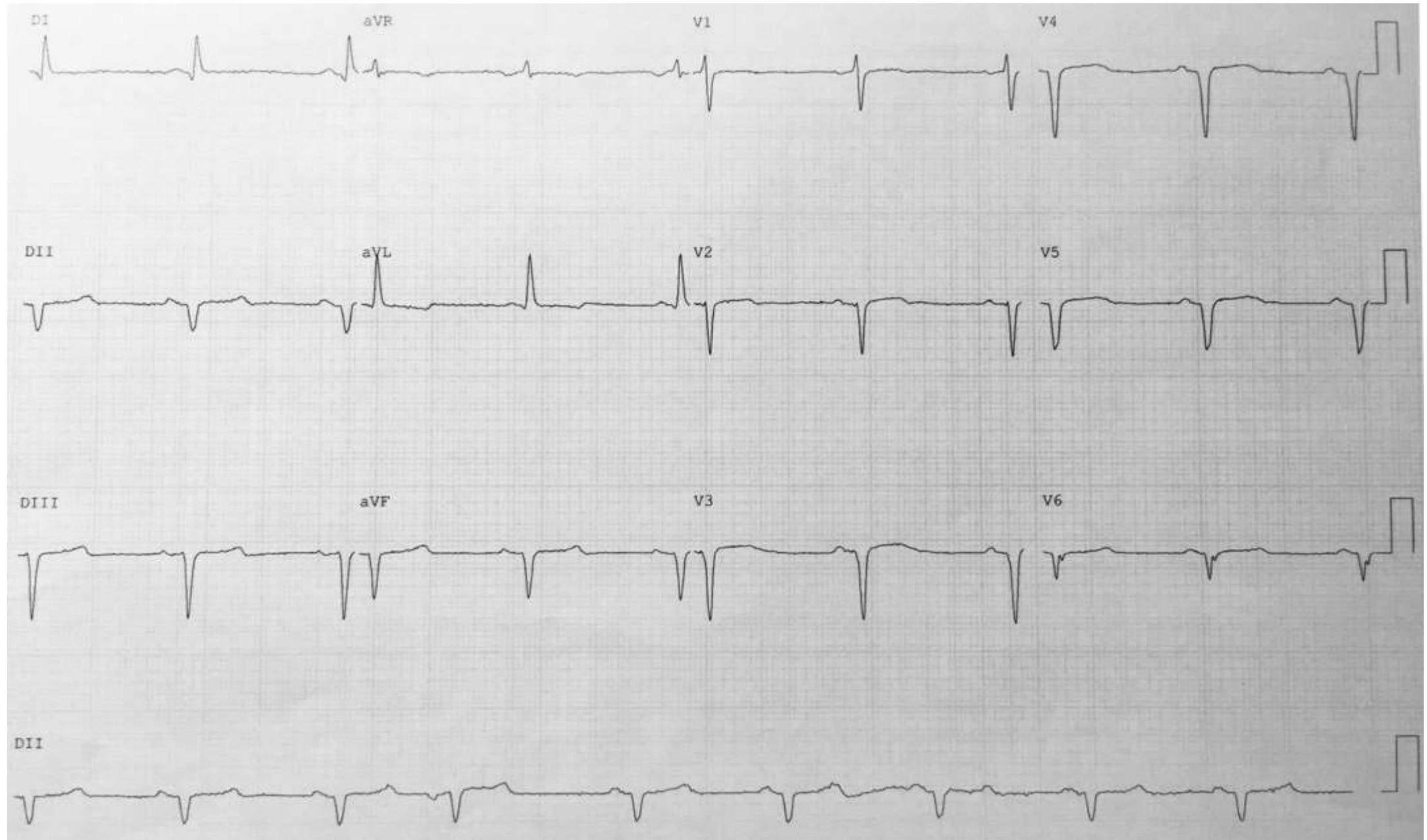
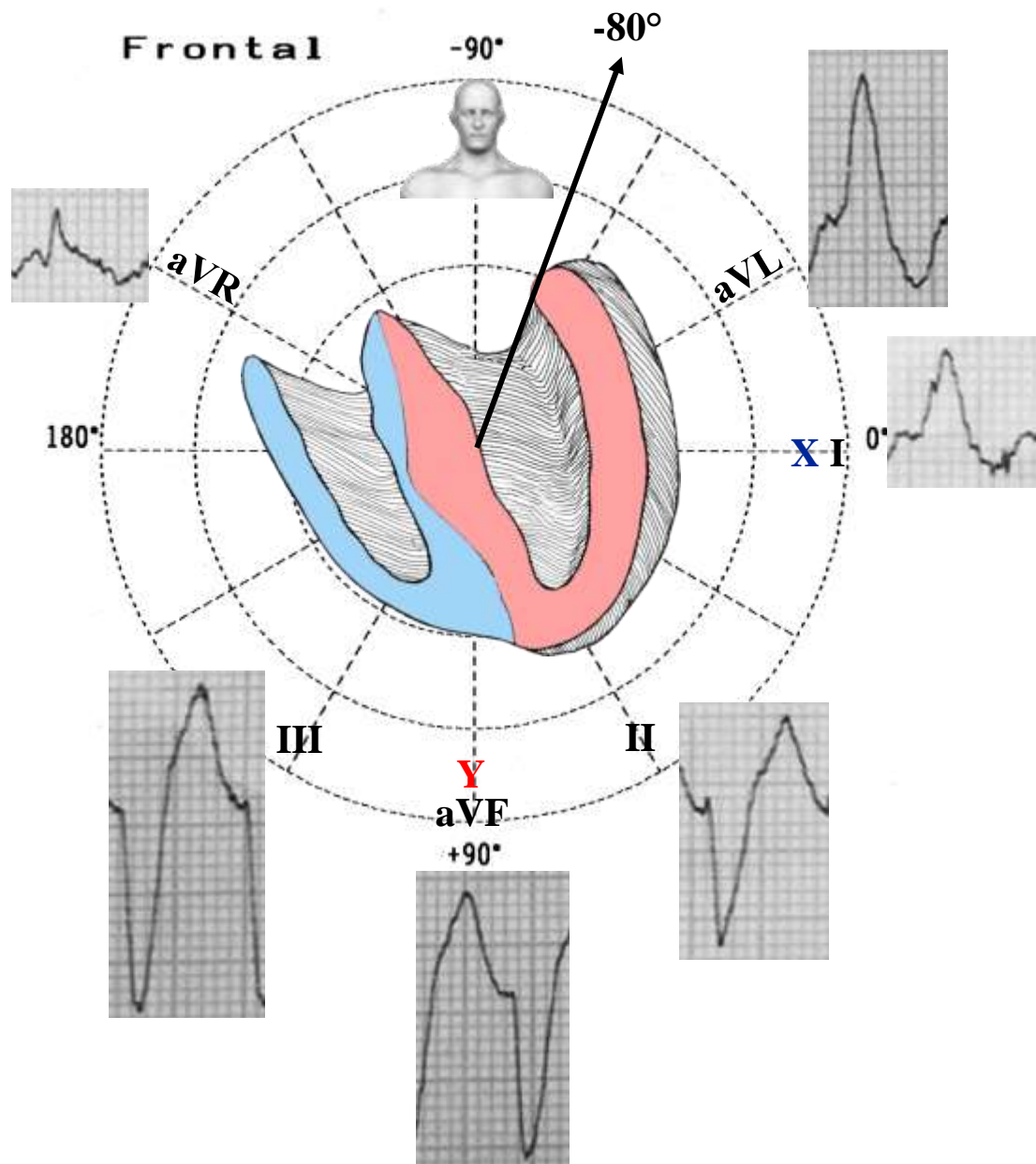


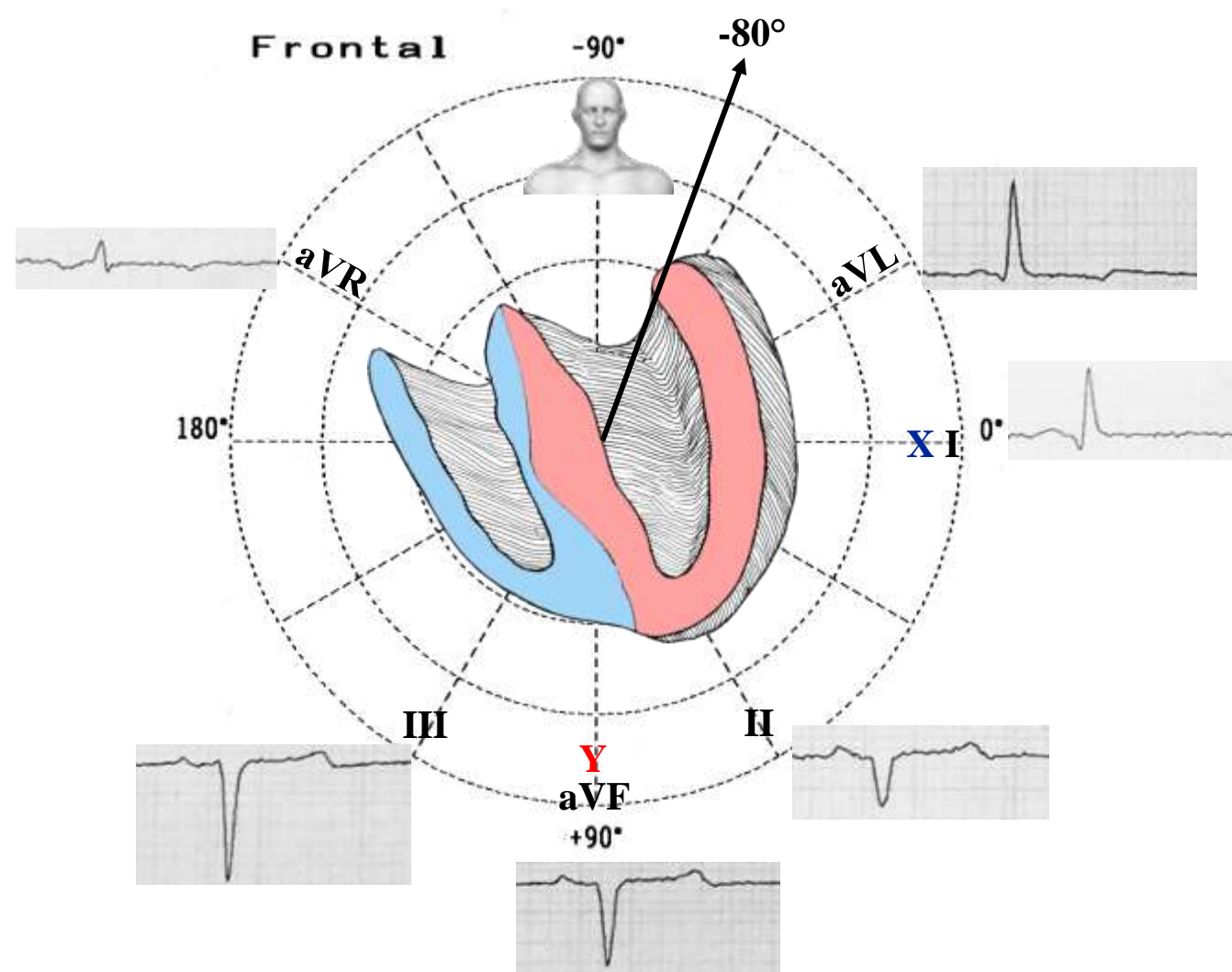
Figure 2 ECG after reversion



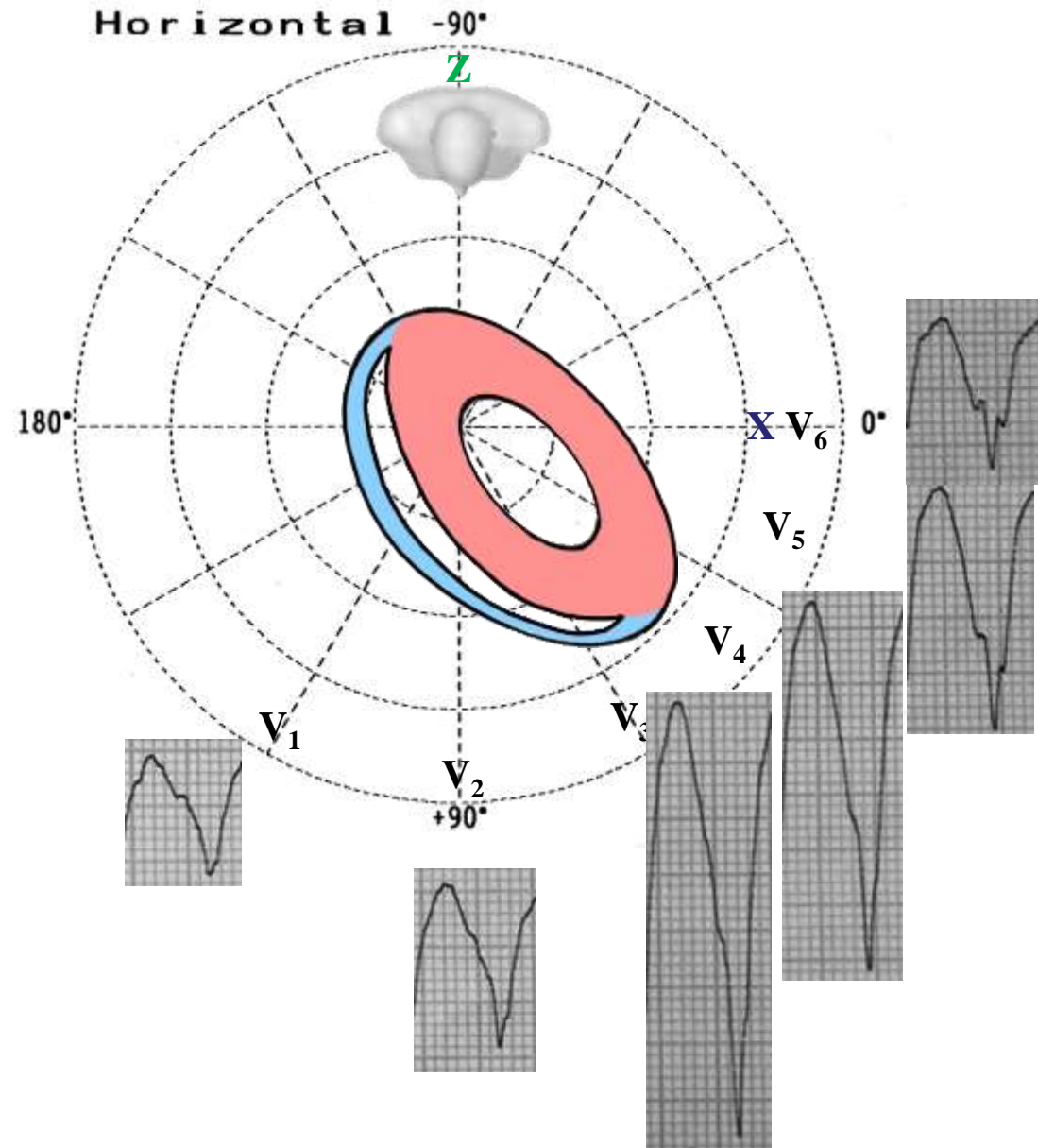
ECG in the FP (Figure 1)



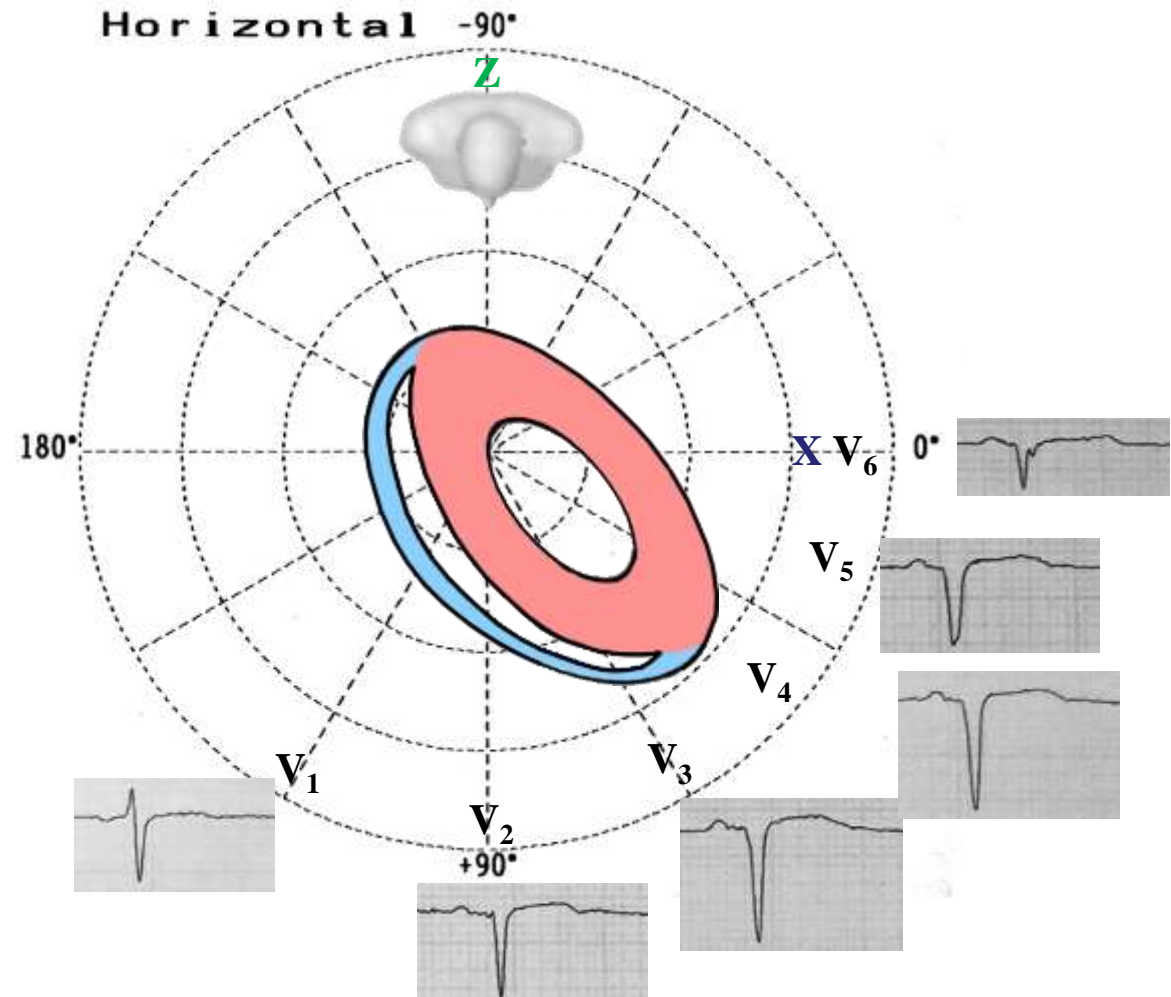
ECG in the FP (Figure 2)



ECG in the HP (Figure 1)



ECG in the HP (Figure 2)



Colleagues opinions

That's ventricular tachycardia, I suspect bundle branch reentry VT.

I' do EP study and ablation.

If BBR, easy to ablate the right bundle branch. If myocardial VT, ablation more challenging and less effective.

I'd implant ICD anyway afterwards.

Cordially

Sergio L. **Pinski MD**

Cleveland Clinic Florida FL in Weston, FL 2950 Cleveland Clinic Blvd Weston, FL 33331. USA

Sergio L. Pinski, MD is a practicing Cardiac Electrophysiologist in Weston, FL. Dr. Pinski graduated from University de Buenos Aires in 1973 and has been in practice for 34 years. Dr. Pinski also specializes in Cardiology (Cardiovascular Disease) and Internal Medicine. He currently practices at Cleveland Clinic Florida and is affiliated with Aventura Hospital & Medical Center, Broward Health Medical Center and Cleveland Clinic Hospital.. In addition to English, Dr. Pinski's practice supports these languages: German, Spanish and Arabic. He has 93 publications indexed to Pubmed in high impact Journals.



Hello, I have nothing to add to Sergio's analysis.

The axes of the arrhythmia are very close to the one during sinus rhythm, but despite this I think it is ventricular tachycardia.

Kind regards

Kjell Nikus

Tampere

Finland



When all the QRS complexes in the precordial ECG leads are wide and all have a QS morphology, this is diagnostic of ventricular tachycardia.

Hope this helps,

Albert L. Waldo, MD, PhD (Hon)
The Walter H. Pritchard Professor of Cardiology
Professor of Medicine
Professor of Biomedical Engineering
Case Western Reserve University
Harrington Heart & Vascular Institute
University Hospitals Case Medical Center
Cleveland, OH University Hospitals Cleveland Medical Center 11100 Euclid Avenue, MS LKS 5038, Room 3080, Cleveland, OH 44106,
Ph (216) 844-7690. FAX (216) 844-7196 USA.



Email Albert.Waldo@Case.edu; Albert.Waldo@uhhospitals.org alw2@case.edu

Dr Albert L. Waldo, MD, FACC. is a cardiologist in Cleveland, Ohio OH, USA. He is affiliated with University Hospitals Case Medical Center. He received his medical degree from State University of New York Down state Medical Center College of Medicine and has been in practice for many years. He is one of 65 doctors at University Hospitals Case Medical Center who specialize in Cardiovascular Disease. He has dedicated more than 40 years to the field of cardiac electrophysiology and is most known for entrainment, which has been useful for localizing components of the re-entry circuit for ablation. Dr. Waldo, is currently the Walter H. Pritchard Professor of Cardiology and Medicine at Case Western University School of Medicine. He has 267 manuscript indexed in Pubmed.

Portuguese

Caro Marcelo

Teus traçados são sempre interessantes. Este é um taqui com QRS alargado, padrão de BRE com desvio à esquerda tipo BDASE. Tem degrau no QRS septal sugerindo zona inativa septal e tem pança de Cabrera em antero-laterais sugerindo zona inativa lateral. O início do QRS é rápido sugerindo taquicardia supraventricular com BRE e mantendo as características que depois elucidam-se com o traçado pós cardioversão. Como tem infarto prévio, mandam as regras que a chance de TV seja de quase 100%. Este deve ser a exceção à regra !

Grande abraço

Jose Claudio **Lupi-Kruse MD** Porto Alegre, Rio Grande do Sul(RS) Brasil

English

Dear Marcelo

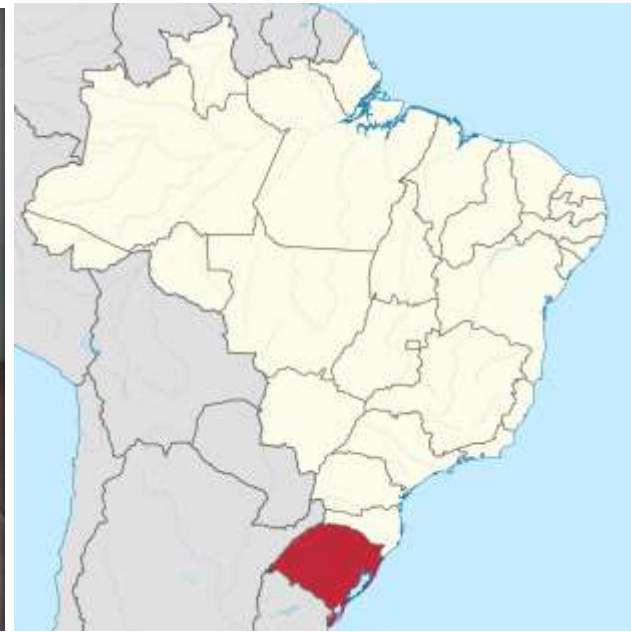
Your tracings are always interesting. This is a broad QRS tachycardia with LBBB pattern and extreme left QRS axis deviation “LAFB type”. It has notches in the QRS septal wall and Cabrera sign in the lateral leads suggesting anterolateral MI. The onset of the QRS is rapid suggesting supraventricular tachycardia with LBBB aberrancy and keeping the characteristics that later elucidate with the post cardioversion tracing. As he has previous MI, the rules says the chance of VT is almost 100%. This should be the exception to the rule!

Big hug

Jose Claudio **Lupi-Kruse MD**

Porto Alegre,

State of Rio Grande do Sul (RS) Brazil.



This is a ventricular tachycardia originating from an old apical and septal MI. There is most likely an apical aneurysm. The reentrant circuit is in the left ventricle with exit site in the right ventricle. The QRS complexes are negative in all the precordial leads (negative concordance) characteristic of VTs originating from the LV apex. The fact that the axis of the QRS in sinus rhythm is similar to the axis of the QRS during tachycardia is irrelevant. This is not a left bundle branch block. During tachycardia the q waves in lead I and aVL are absent as well as the initial r wave in V1.

I would do an EP study and ablation followed by ICD implantation.

Best regards,
Mario D. Gonzalez

Dr. Mario Gonzalez, MD is a Doctor primarily located in Hershey, Pennsylvania(PA), United States. His specialties include Clinical Cardiac Electrophysiology and Internal Medicine.

Dr. Gonzalez is affiliated with Penn State Milton S Hershey Medical Center.



Spanish

La arritmia corresponde a una taquicardia ventricular originada en la punta del Ventrículo Derecho. El ECG de base muestra Ritmo sinusal, Hemibloqueo izquierdo anterior, secuela de infarto anterior extenso y apical. Aparentemente no hay aneurisma cardiaco.

Gerardo Nau Buenos Aires Argentina

English

The arrhythmia corresponds to a ventricular tachycardia originated from the apex of the Right Ventricle. The baseline ECG shows sinus rhythm, anterior left hemiblock, consequence of an extensive anterior and apical infarction. Apparently there is no cardiac aneurysm.

Gerardo **Nau** MD Buenos Aires Argentina



The ECG in wide complex tachycardia with negative concordance in the V leads and left axis deviation is always VT until proven otherwise. However, the QRS morphology in sinus rhythm is very similar to the one in tachycardia (ECG 1) with remote anterior myocardial infarction, a small r wave in lead V1 and Q waves in the inferior leads with left axis deviation. The least possibility is atrial flutter with 2:1 AV conduction. However, I still favor VT.
Looking forward to receiving the comments.

Very best,
Mohammad Shenasa, MD, FACC, FESC, FAHA, FHRS,
Heart & Rhythm Medical Group
105 N. Bascom Ave Suite 204
San Jose, CA 95128 USA.
[408-930-9400](tel:408-930-9400) (Mobile)
[408-286-2922](tel:408-286-2922) (Fax)
mohammad.shenasa@gmail.com



Spanish

Buen día! Creo se trata de una TV monomorfa, en un paciente sexagenario con la cardiopatía isquémica descrita. Con origen probable en región septo-apical de VI. No descarto aneurisma de punta. En ritmo sinusal concuerdo con Dr Nau.

Conducta CDI.

Me despido cordialmente.

Dr Juan Carlos Manzardo

English

Good morning! I believe it is a monomorphic VT in a sexagenarian patient with the described ischemic heart disease. The probable focus origin in the septoapical region of the LV. I do not rule out aneurysm of the LV apex. In sinus rhythm I agree with Dr Nau.

Approach: CDI implantation.

Cordially.

Juan José Mazzardo MD Mendoza Argentina



Spanish

El ECG basal en ritmo sinusal muestra un primer vector del complejo QRS dirigido hacia arriba, a la derecha y ligeramente hacia delante (r en DIII, Q en DII y aVF y R/s en aVR), la rotación de este bucle en el plano frontal es horaria (R/s en aVR). A pesar de que el eje está desviado hacia la izquierda la rotación es horaria lo cual hace el diagnóstico de necrosis inferior; el HBAI yo no lo puedo diagnosticar. El plano horizontal; V1 presenta onda R (resultados de la activación del VD) y luego decrece abruptamente visualizándose complejos QS (infarto anterior extenso). En el primer ECG (el de la taquiarritmia) el vector inicial se dirige levemente hacia abajo a la izquierda y atrás. Si esto fuese una TSV con aberrancia de BCRE, la gran secuela previa que posee originaria que las primeras fuerzas derechas aumentadas (onda Q en DI, y aumento de la onda R de V1). En este caso al contrario vemos desaparición de las fuerzas derechas. En la derivación aVR se puede objetivar el cambio de rotación del complejo QRS que en este caso es anti-horaria. Estamos en presencia de una imagen similar a un BRI con un eje desviado a la izquierda. Impresiona como una TV cuyo origen es la región apical del VD y podría corresponder a una reentrada rama-rama como se a mencionado anteriormente.

Afectuosamente Isabel

English

ECG basal: sinus rhythm with the first vector of the QRS complex directed upwards, to the right and slightly forward (r in III, Q in II- aVF and Rs in aVR),

Fontal plane The QRS loop rotation is clockwise (CW) : Rs in aVR. Although the QRS axis is shifted to the left, the QRS rotation is CW, which makes the diagnosis of myocardial infarction in the inferior wall. It is not possible the diagnosis of LAFB.

Horizontal plane: V1 presents R wave (results of RV activation) and then decreases abruptly by showing QS complexes (extensive anterior infarction). In the first ECG (the event) the initial vector is located slightly to down, left and back. If this were a with SVT - LBBB aberrancy, the previous large sequel that possesses would originate increased first right forces (Q wave in I, and increased R wave in V1). In this case, on the other hand, we see the disappearance of the right forces. In aVR lead can be observe the change of the QRS complex rotation, which is CCW in this case. We are in the presence of a similar image to a LBBB with extreme left axis deviation.

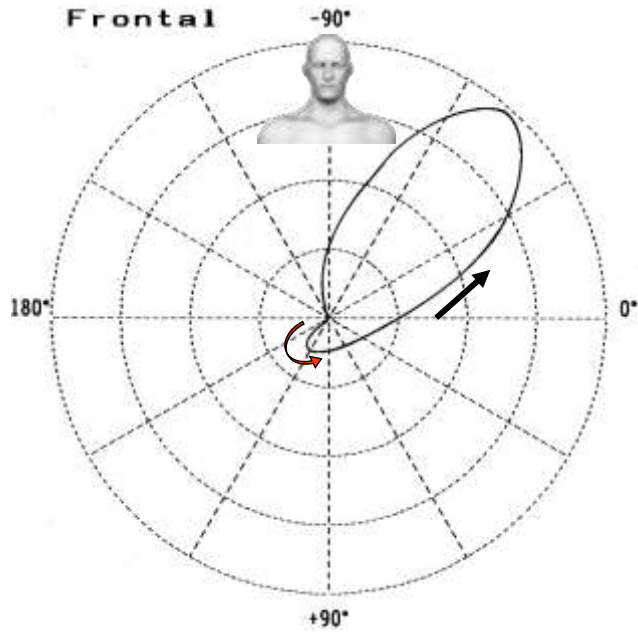
It surprises me how a VT with focus is the apical region of the RV could correspond to a branch-to-branch reentry ventricular tachycardia as mentioned Dr Pinski previously.

Affectionately Isabel Konopka Buenos Aires Argentina

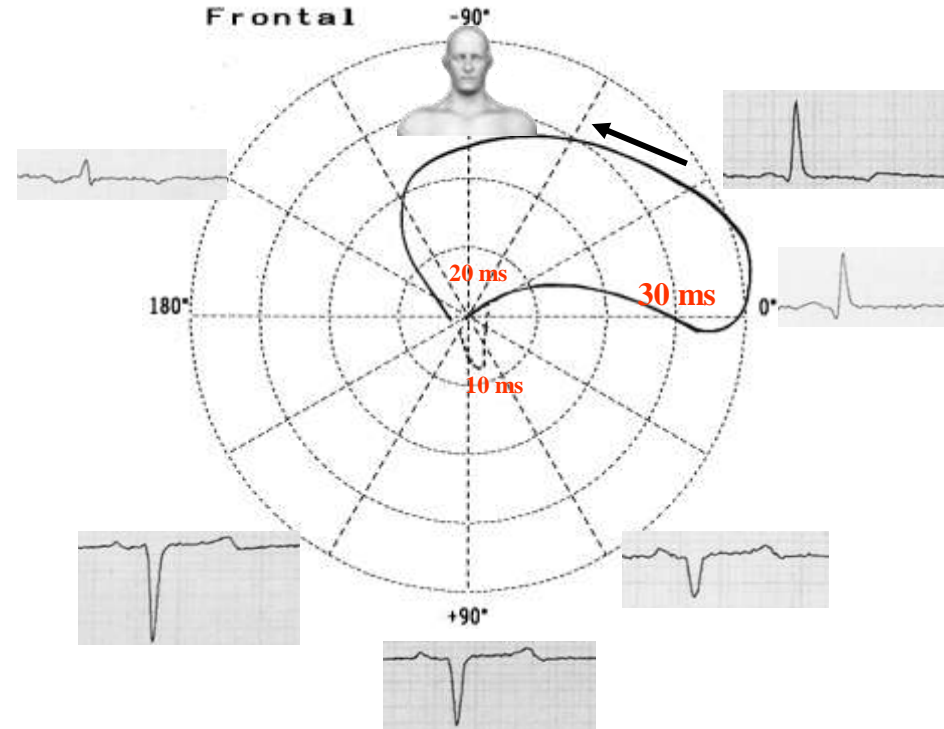
Please read the next slide



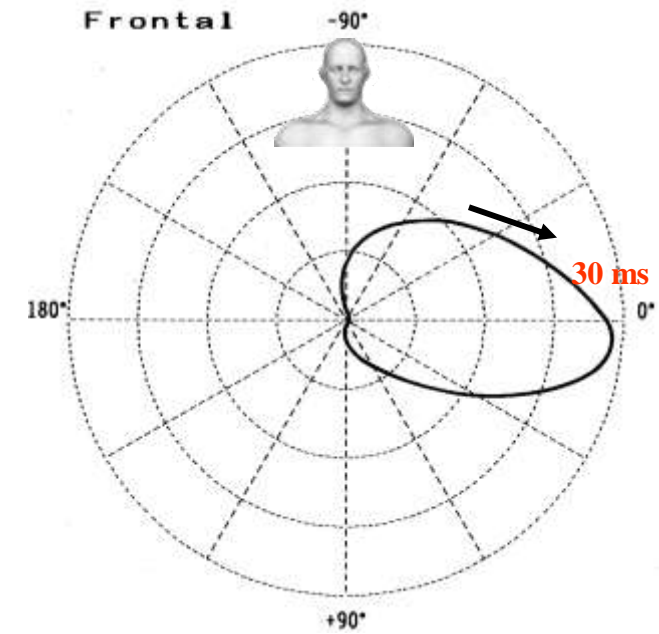
Comparison of QRS loops in the frontal plane in left anterior fascicular block (LAFB), diaphragmatic infarction and association of both



LAFB



Diaphragmatic infarction + LAFB



Diaphragmatic infarction

Dear Isabel, do you think the middle figure corresponds to the present case?

Andrés

Comparison of QRS loops in the frontal plane in left anterior fascicular block (LAFB), diaphragmatic infarction and association of both

Isolated LAFB: QRS loop with the vector of the initial 10 to 20 ms, heading below and to the right, with counterclockwise rotation, extreme shift of SAQRS in the left superior quadrant in the FP.

Inferior infarction: QRS loop of clockwise rotation with the vector of the initial 25 ms, located above the orthogonal X lead, with clockwise rotation, heading from right to left and with the efferent limb of superior convexity;

LAFB associated with inferior infarction: initial portions of 20 to 30 ms of the QRS loop shifted upward and with clockwise rotation (as inferior infarction) and final portions also shifted upward; however, showing sudden change in rotation (it becomes counterclockwise).

LAFB may mask diaphragmatic infarction, when necrosis has respected the basal inferior infarction and posteroinferior papillary muscle of the mitral valve, the site where the left posterior fascicle (LPF) ends. In presence of LAFB, the stimulus activates the LV by the left posterior fascicle (LPF), which ends at the base of the postero-inferior papillary muscle of the mitral valve, originating an initial vector heading below and responsible for the inscription of an initial r wave in the inferior leads, which hides the not so extensive inferior infarction, when it does not involve the base of the papillary muscle.

If inferior necrosis is extensive and involves the basal inferior region of the LV, it removes the 1st vector of LAFB, and the initial r wave of II, III and aVF disappears, with only the vectors of the lateral and antero-superior regions of the LV manifesting, which move away from the inferior wall, originating the QS pattern in these leads. In this case, the LAFB cannot hide the inferior infarction pattern.

Globally, in acute infarction in any wall, LAFB appears in 5% of the cases, and complete AV block develops only in 3% of the cases, with a mortality estimated in 27% (without block, 15%). Between diaphragmatic infarctions, nearly 12% to 13% develop LAFB. Out of 87 patients admitted in emergency with the first infarction in inferior wall, 17 had associated LAFB. The appearance of LAFB identifies a specific group with more extensive coronary injuries and atherosclerotic disease of the LAD (**Assali 1997**).

Hi,

At first glance, the abnormal rhythm looks like ventricular tachycardia. However, I believe that it is supraventricular tachycardia with aberrant intraventricular conduction. There is no evidence of AV dissociation, although listening for beat to beat variation in S1 intensity would help. Instead, there is observable atrial activity at about 300 beats/min, but without the baseline disruption usually seen in atrial flutter. Also, although the QRS complexes are very wide during the tachycardia, their directions are similar to those of the QRS complexes in the subsequent sinus rhythm. Although both ECGs show marked left axis deviation, the timing of relevant parts of the QRS in the leads suggests that the direction of ventricular depolarization in the frontal plane is clockwise and the QRS in Lead aVR terminates in an S wave. Therefore, the LAD is probably due to previous inferior myocardial infarction, not hemiblock. The patient also has a prior antero-apical MI. In sinus rhythm, the PR interval is normal and there are no delta waves. Therefore, this is not WPW. I believe that the tachyarrhythmia represents atrial flutter with aberrant intraventricular conduction.

Dr. Robert “Bob” Warner, MD, Ohio, USA
Tigard Research Institute



Final conclusion by Marcelo **Garcia-Leal**, Andrés Ricardo **Pérez-Riera** and Raimundo **Barbosa Barros**



Marcelo **Garcia-Leal**, MD,
Ribeirão Preto, SP, Brazil

Médico assistente da divisão de Cardiologia
do Hospital das Clínicas da Faculdade de
Medicina de Ribeirão Preto-USP

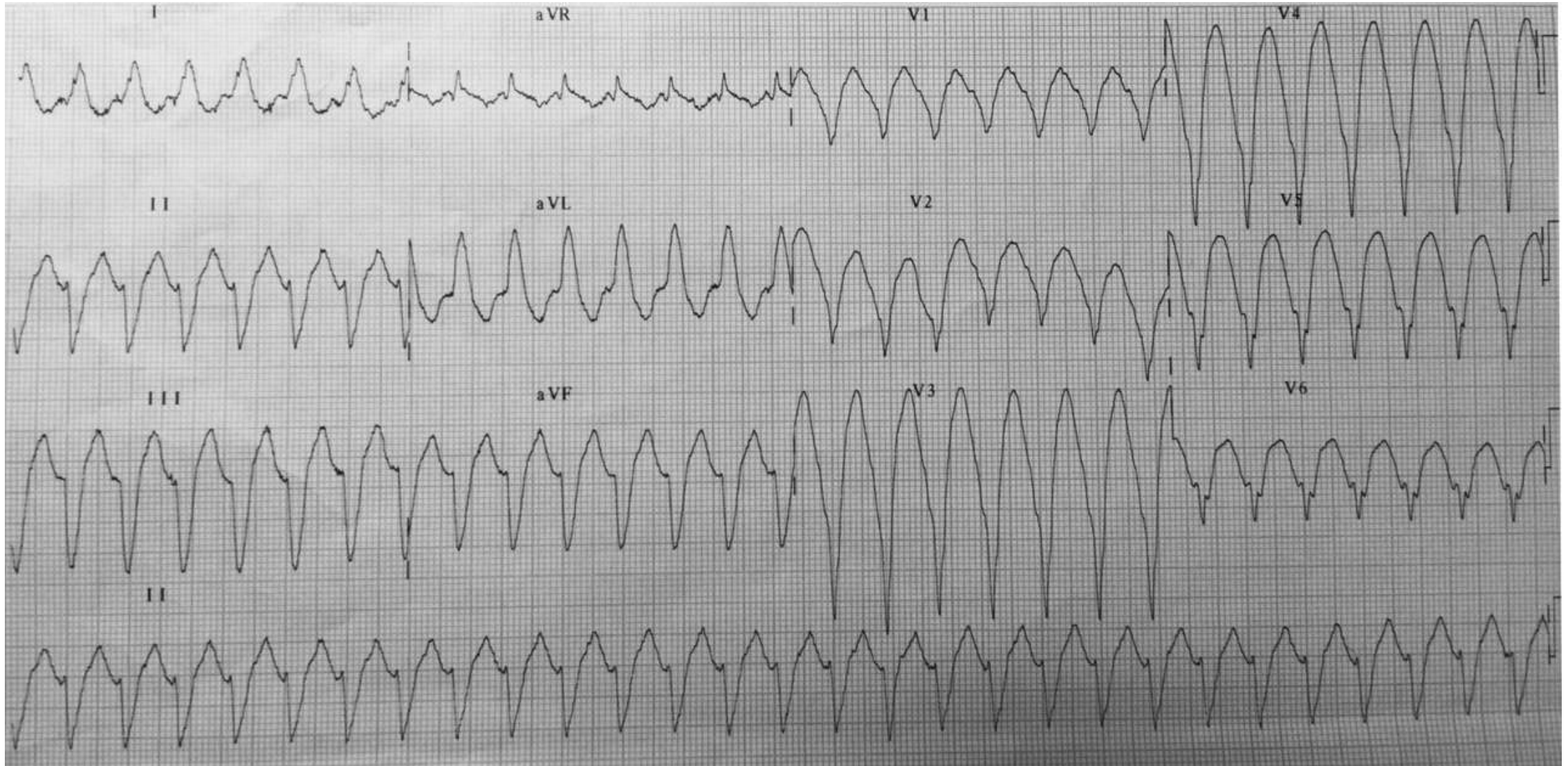


Andrés Ricardo **Pérez-Riera**, M.D. Ph.D.
Design of Studies and Scientific Writing
Laboratory in the ABC School of Medicine,
Santo André, São Paulo, Brazil
<https://ekgvvg.wordpress.com>



Raimundo **Barbosa-Barros**, MD
Chief of the Coronary Center of the Hospital de
Messejana Dr. Carlos Alberto Studart Gomes.
Fortaleza – CE- Brazil

Figure 1



ECG diagnosis: broad sustained regular monomorphic complex tachycardia. HR 166 bpm, QRS duration 161 ms (very broad), extreme QRS axis deviation (-80°), totally negative precordial concordance across precordial leads. This occurs when the precordial leads consist of complexes that are entirely negative during a broad QRS tachycardia (absence of RS complexes from V1 to V6), absence of AV dissociation features (capture or fusion beats), both are suggestive of VT.

Electrocardiographic QRS morphology criteria favoring ventricular tachycardia over supraventricular tachycardia			
Authors	Date	Morphology	Criteria favoring VT
Wellens et al (Wellens 1978)	1978	RBBB-like	Monophasic R in V1
			qR, QS, RS in V1
			rS, QS, qR in V6
			R/S < 1 in V6 (S > R or QS in V6)
			Left axis deviation
Kindwall et al (Kindwall 1988)	1988	LBBB-like	R in V1 or V2 > 30 ms;
			Any Q wave in V6
			Onset of QRS to nadir of S ≥ 60 ms in V1 or V2
			Notching of downstroke of S in V1 or V2
Akhtar et al (Akhtar 1988)	1988		Positive QRS concordance across the precordium
			Extreme left axis deviation (-90° to ± 180°)
		LBBB-like	Right axis deviation QRS > 160 ms
		RBBB-like	QRS > 140 ms

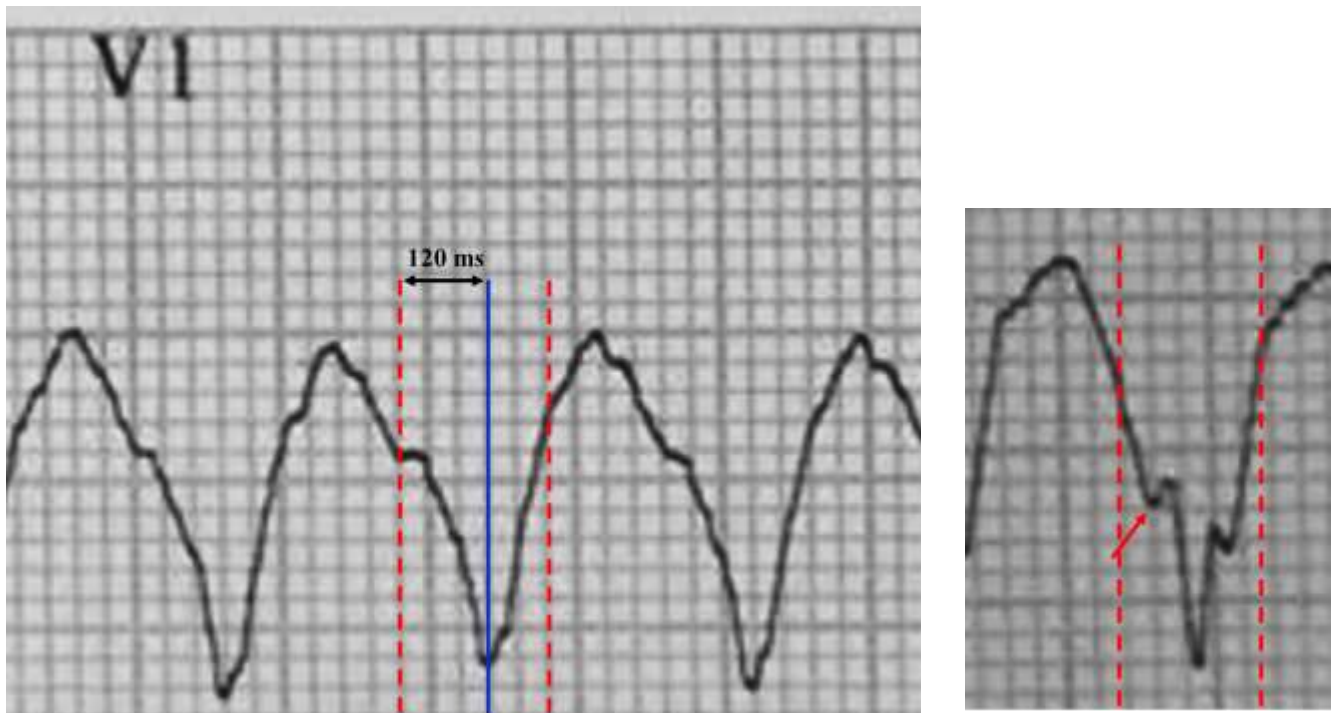
Authors	Date	Morphology	Criteria favoring VT
Brugada et al (Brugada 1991)	1991		Absence of RS complex in all precordial leads. See explanation in the slides 20, 21, 22.
			R to S interval > 100 ms in \geq one precordial lead
			Wellens' morphologic criteria in leads V1 or V6
Griffith (Bundle Branch Block) algorithm (Griffith 1994)	1994		See explanation in the slide 23.
The ACC algorithm Blomström-Lundqvist et al (Blomström-Lundqvist 2003)	2003		See explanation in the slide 24.
Vereckei et al (Vereckei 2008)	2008		Initial R wave in lead aVR
			Initial r or q wave > 40 ms in lead aVR
			Notch on descending limb of negative onset, predominantly negative QRS in lead aVR
			$v_i/v_t \leq 1$

Authors	Date	Morphology	Criteria favoring VT
Miller et al (Miller 2009)	2009		First step: Determine the atrioventricular ratio. In the presence of AV dissociation, the diagnosis is VT. If not, got to Step 2. Second step: QRS axis in the FP in the right superior quadrant (northwest quadrant axis). When present, it indicates VT. When absent, go to Step 3. Third step: Vi/Vt ratio when > than 1, SVT-A is diagnosed; if not, continue to the Step 4. Fourth step: Absence of RS pattern in the precordial leads indicates VT. If not, go to Step 5. Fifth step: RS interval in the precordial leads >100 ms indicates VT. If not, continue to Step 6. Sixth step: in the case of a tachycardia with LBBB-like morphology, an initial r <30 ms or an interval from QRS onset to the nadir of S in V1 <60 ms indicates SVT-A.

Authors	Date	Morphology	Criteria favoring VT
Pava et al (Pava 2010)	2010		A criterion to differentiate VT from SVT-A: the R wave peak time (RWPT) in II. Distance from onset of the QRS to the first change in polarity (either nadir Q or peak R) in lead II. If the RWPT is ≥ 50 ms the likelihood of a VT very high (positive likelihood ratio 34.8). This criterion has sensitivity 60%, specificity 82.7%.

vi/vt: Ratio of voltage amplitude during initial 40 ms of QRS complex relative to terminal 40 ms in any lead with a bi- or multiphasic QRS complex; LBBB: Left bundle branch block; RBBB: Right bundle branch block

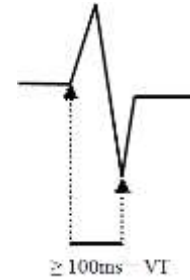QRS duration




QRS duration (QRSd) = 161 ms: QRSd >160 ms in V1 (**Akhtar 1988**) negative patterns suggest VT. Presence of Brugada’s sign: the distance from the onset of the QRS complex to the nadir of the S-wave is > 100ms, onset of QRS to nadir of S ≥ 60 ms in V1 or V2 (**Kindwall 1988**), presence of Josephson’s sign: notching in the descendant ramp of the S-wave (red arrow), before nadir of the QRS complex. Absence of RS complex in all precordial leads (**Brugada 1991**).

Brugada algorithms to differentiate VT from SVT-A (Brugada 1991)

- I. First step:** absence of an RS complex in all precordial leads? Yes = VT; No = second step
- II. Second step:** R to S interval ≥ 100 ms in precordial leads from V1 to V6? Yes = VT (highly specific of VT, however not much sensitive); No = third step



- III. Third step:** AV dissociation (capture or fusion beats)? Yes = VT; No = Fourth step. Presence of anterograde AV dissociation between atria and ventricles; i.e. independent from each other. When it is present ($>50\%$ of the cases) is of great diagnostic value and highly specific of VT. The sign is highly specific for VT; however, not much sensitive. It is characterized by the interruption of monomorphic pattern by narrow beats, mildly anticipated, and preceded by P wave. For the existence of complete capture beats, the existence of A-V dissociation is necessary. The rate of VT should not be very high. The lower the HR, the more frequent the capture beats. For this reason, the VT with a greater number of capture beats is the AIVR (Accelerated IdioVentricular Rhythm). Possible and characteristic presence of fusion beats (“dressler beats”). These are beats with a morphology of intermediary QRS between pure sinus beats and pure ectopic beats, because the ventricular complex results from the activation of the biventricular chamber by two wavefronts: the one preceding VT and sinus: the resulting beat is an incomplete capture beat (fusion beat). Fusion beats are not pathognomonic of VT because they are also observed in Atrial Fibrillation (AF) with an Accessory Pathway (AP) or WPW type ventricular pre-excitation, telediastolic ventricular extrasystoles, parasystole.



IV. Fourth step: Morphology criteria for VT present both in precordial leads V1-2 and V6? Yes = VT; No = SVT-A. Complete RBBB pattern, QRS \geq 140 ms = VT < 140 ms = SVT-A. Pattern of CLBBB \geq 160ms = VT. Duration < 160 ms = SVT-A. If there is pattern of CRBBB present in V₁, the presence of monophasic QRS (R) or biphasic QRS (RR') is most frequently seen. In the latter, the voltage of the R wave in V₁ is less than R': "Rabbit Ears". The presence of tachycardia with CRBBB morphology and triphasic complex in V₁ should make us think of SVT with aberrant conduction and not on VT. In V1-V2 negative pattern, broad R initial wave(> 30 mm), slurred/notched S ou QS downstroke, and delayed S nadir in V1 and/or V2(> 60mm) or Q wave in V6 is indicative of VT. On the other hand in V1 negative patterns, a narrow r initial wave and clean S downstroke in V1 and V2 is suggestive of SVT-A. In V1 positive patterns, a monophasic R or biphasic complex (qR, RS) or a taller left "rabbit ear" (**Gozensky 1974**) in V1 is indicative of VT. On the other hand, in V1 positive patterns triphasic is indicative of SVT-A.

ECG Signs of VT when mainly negative in V1 using leads V1-V2 , and V6 (Kindwall 1988**)**

Criteria	Specificity (%)	Sensitivity(%)	Predictive Accuracy(%)
R > ms in V1-V2	100	36	100
Any Q in V6	96	55	98
> 60 ms to S nadir in V1-V2	96	63	98
Notched downstroke in S or QS in V1-V2	96	36	97
Combined criteria	89	100	96

Summary of Brugada steps

Step 1: Absence of RS complex in all leads V1-V6?

Yes: Dx is ventricular tachycardia!

Step 2: No: Is interval from beginning of R wave to nadir of S wave $>0.1s$ in any RS lead?

Yes: Dx is ventricular tachycardia!

Step 3: No: Are AV dissociation, fusions, or captures seen?

Yes: Dx is ventricular tachycardia!

Step 4: No: Are there morphology criteria for VT present both in leads V1 and V6?

Yes: Dx is ventricular tachycardia!

No: Diagnosis is supraventricular tachycardia with aberration (SVT-A)!

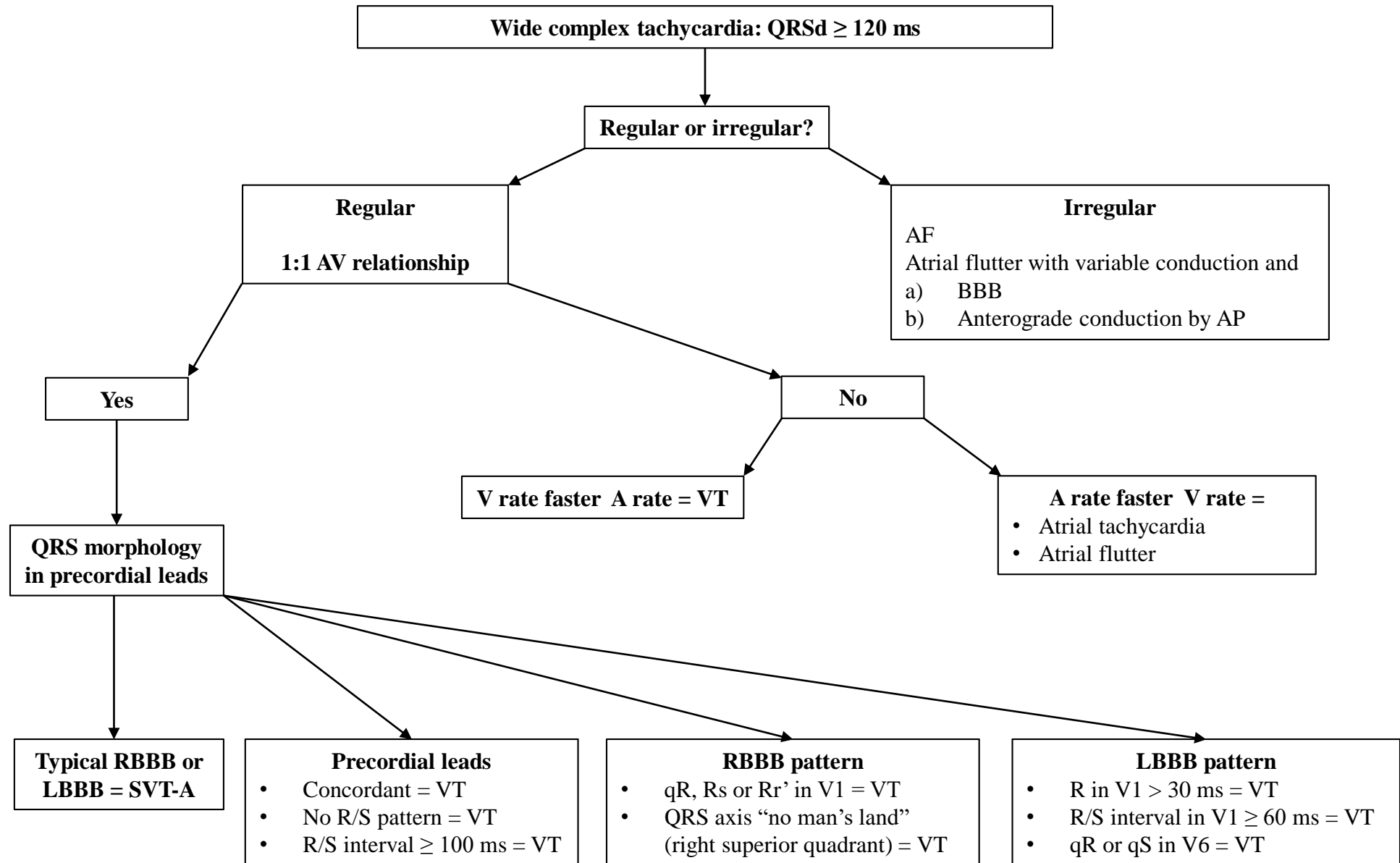
Griffith (Bundle Branch Block) algorithm (**Griffith 1994**)

The criterion for a diagnosis of SVT-A

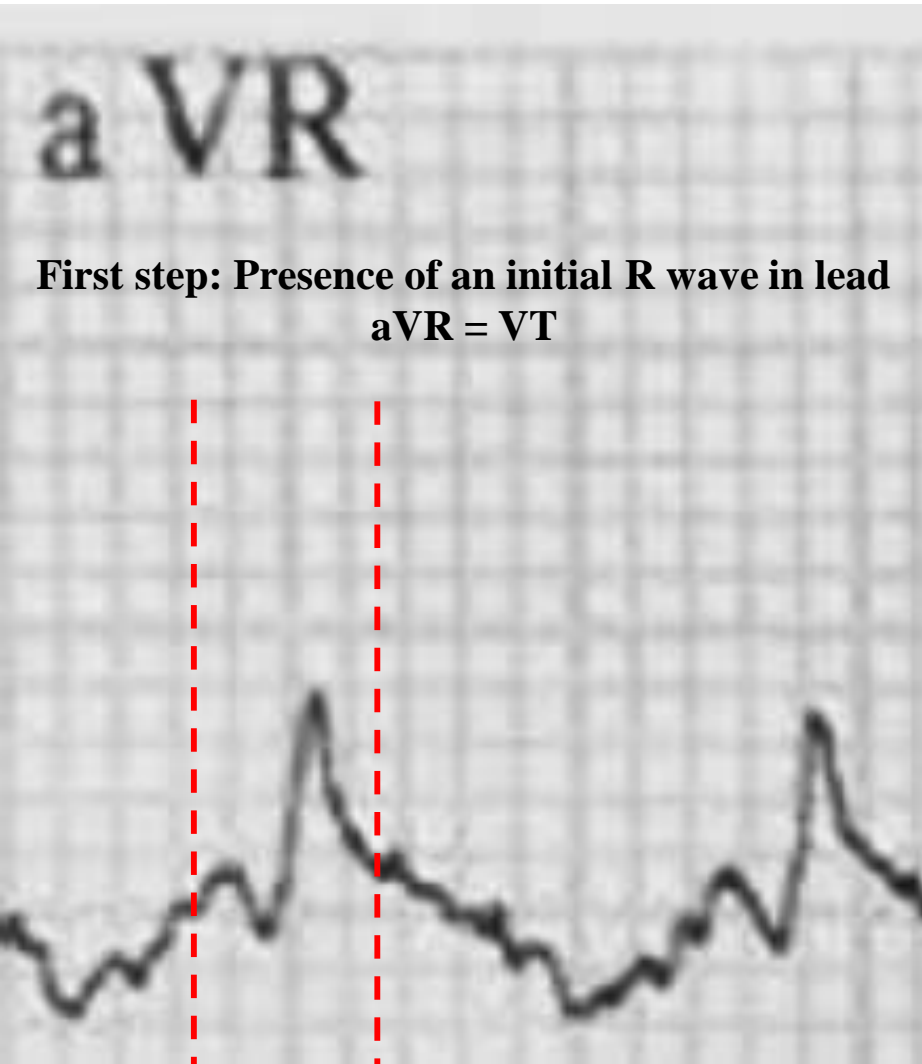
- **LBBB pattern** = rS or QS wave in leads V1-V2, delay to S wave nadir < 70 ms, and R wave and no Q wave in lead V6;
- **RBBB pattern** = rSR' wave in lead V1 and an RS wave in lead V6, with R wave height greater than S wave depth).

These criteria, require only knowledge of typical bundle branch block patterns, are highly sensitive.. Unfortunately the Griffith algorithm is the least specific for VT, in that it misclassified 60% of SVTs; this seems to be its major limitation. However, due to its high sensitivity for VT, its overall accuracy was similar to those of the other algorithms. The original report refers specificity of 96% and sensitivity of 64%, whereas the present values are lower. Similarly, Lau et al (**Lau 2000**) reported a specificity of only 44%.

The ACC algorithm (**Blomström-Lundqvist 2003**)



The aVR or Vereckeï algorithm

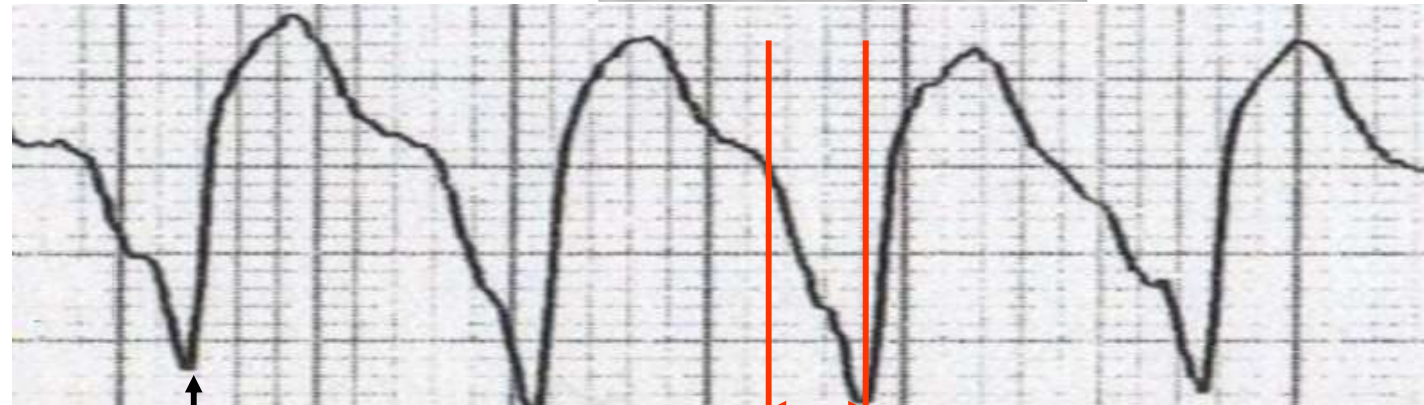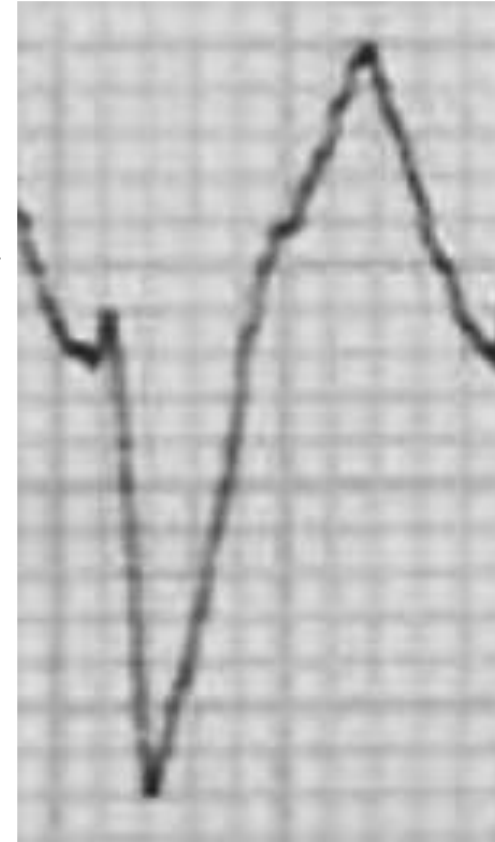


First step: Presence of an initial R wave in lead aVR = VT

Initial R wave in lead aVR, initial r or q wave > 40 ms in lead aVR (**Vereckeï 2008**)

R-Wave Peak Time at II or ultrasimple criterion (**Pava 2010**)

A criterion to differentiate VT from SVT-A: the R wave peak time (RWPT) in II. Distance from onset of the QRS to the first change in polarity (either nadir Q or peak R) in lead II. If the RWPT is ≥ 50 ms the likelihood of a VT very high (positive likelihood ratio 34.8). This criterion has sensitivity 60%, specificity 82.7% (**Pava 2010**).

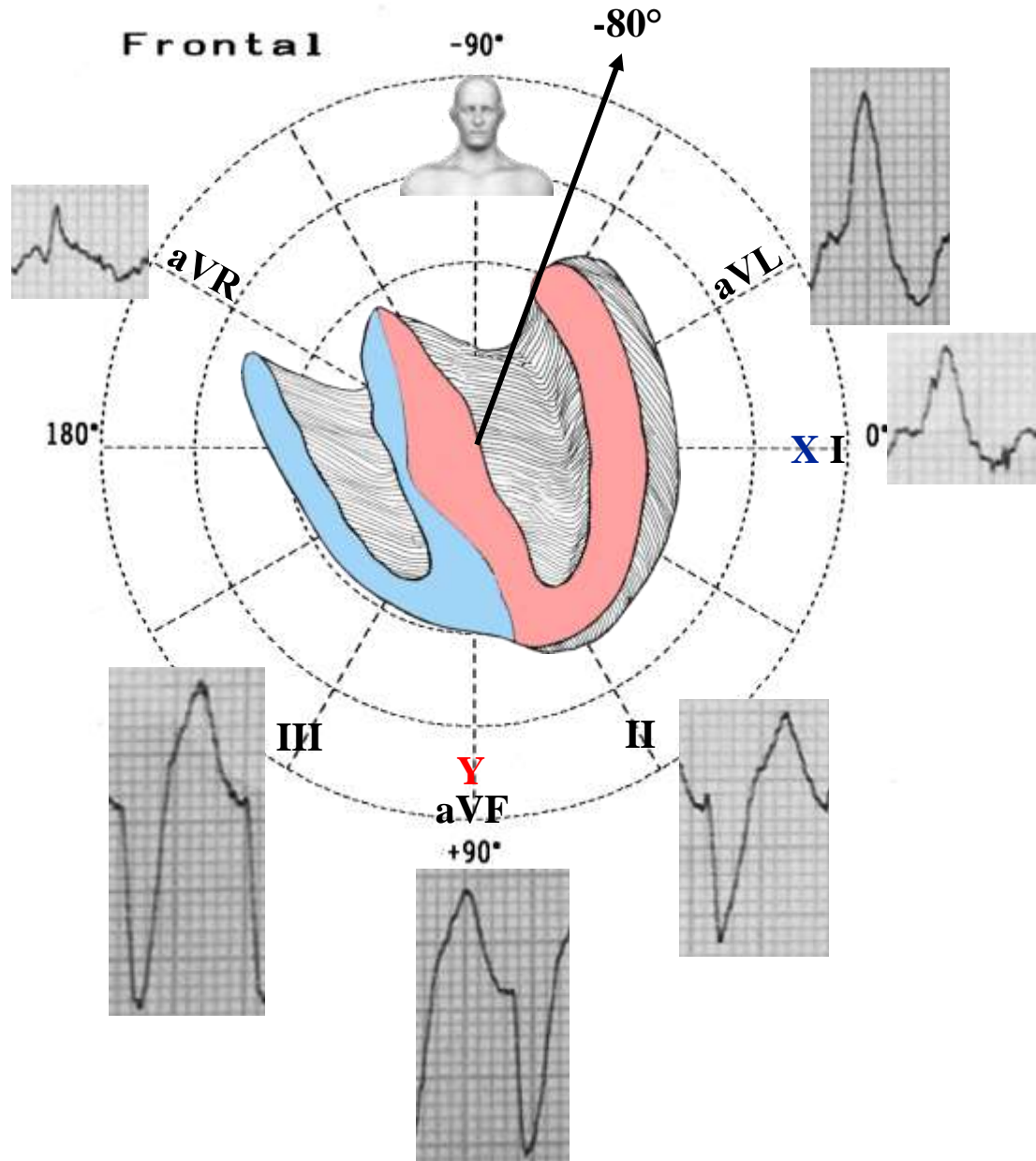


Nadir Q

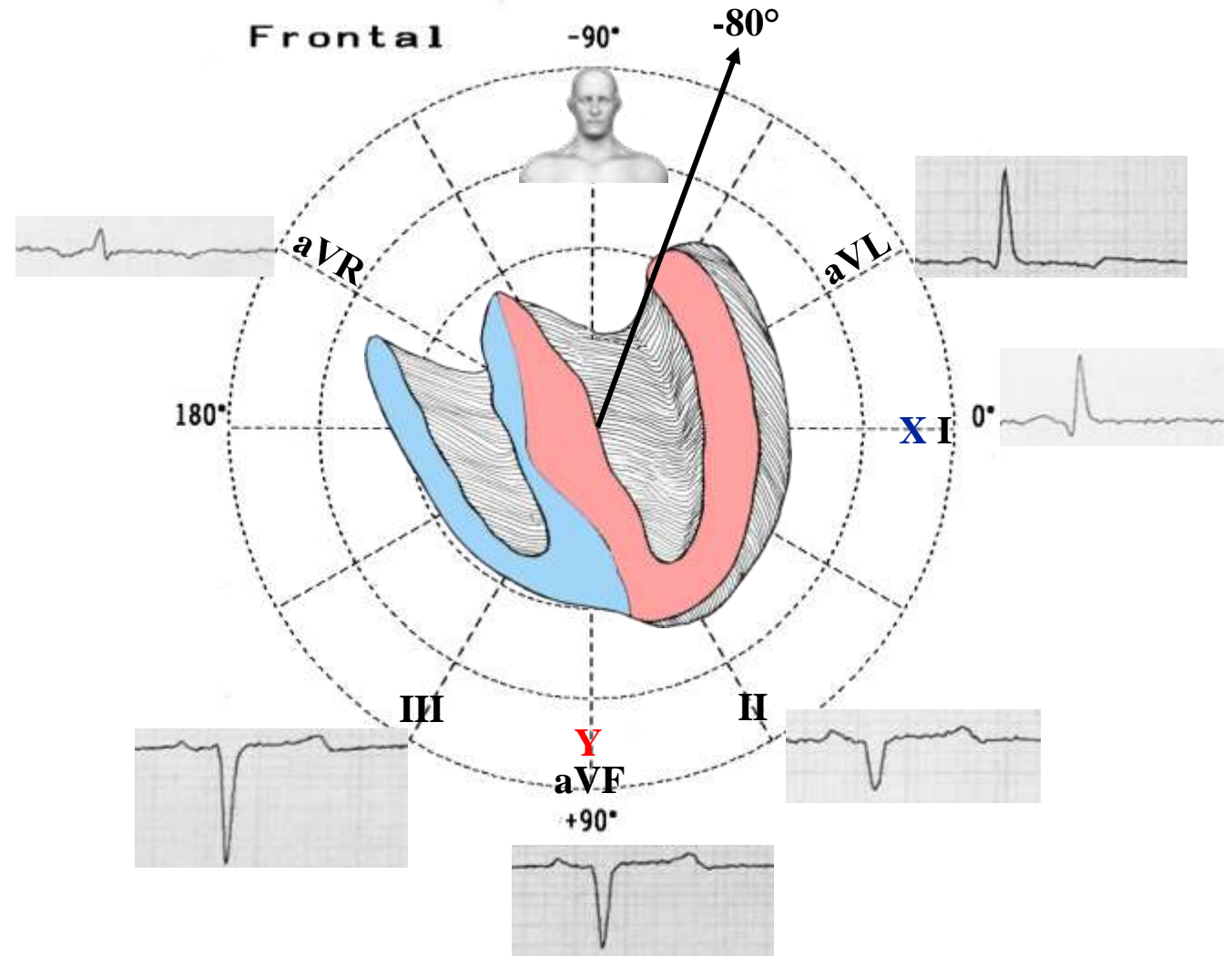
R-Wave Peak Time (RWPT): ≥ 50 ms = VT

ECG in the FP (Figure 1)

Wellens criteria for VT (**Wellens 1978**)

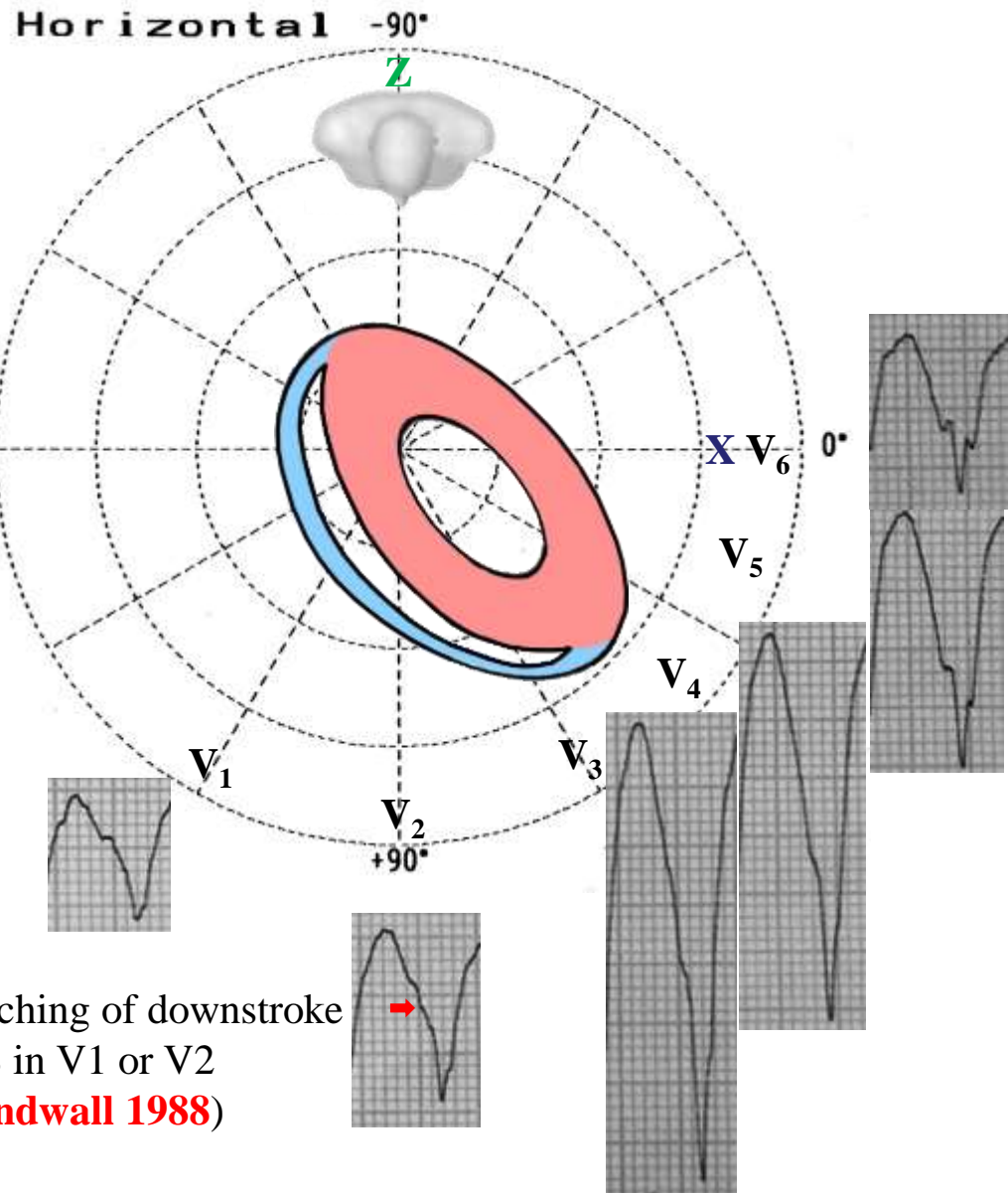


ECG in the FP (Figure 2)

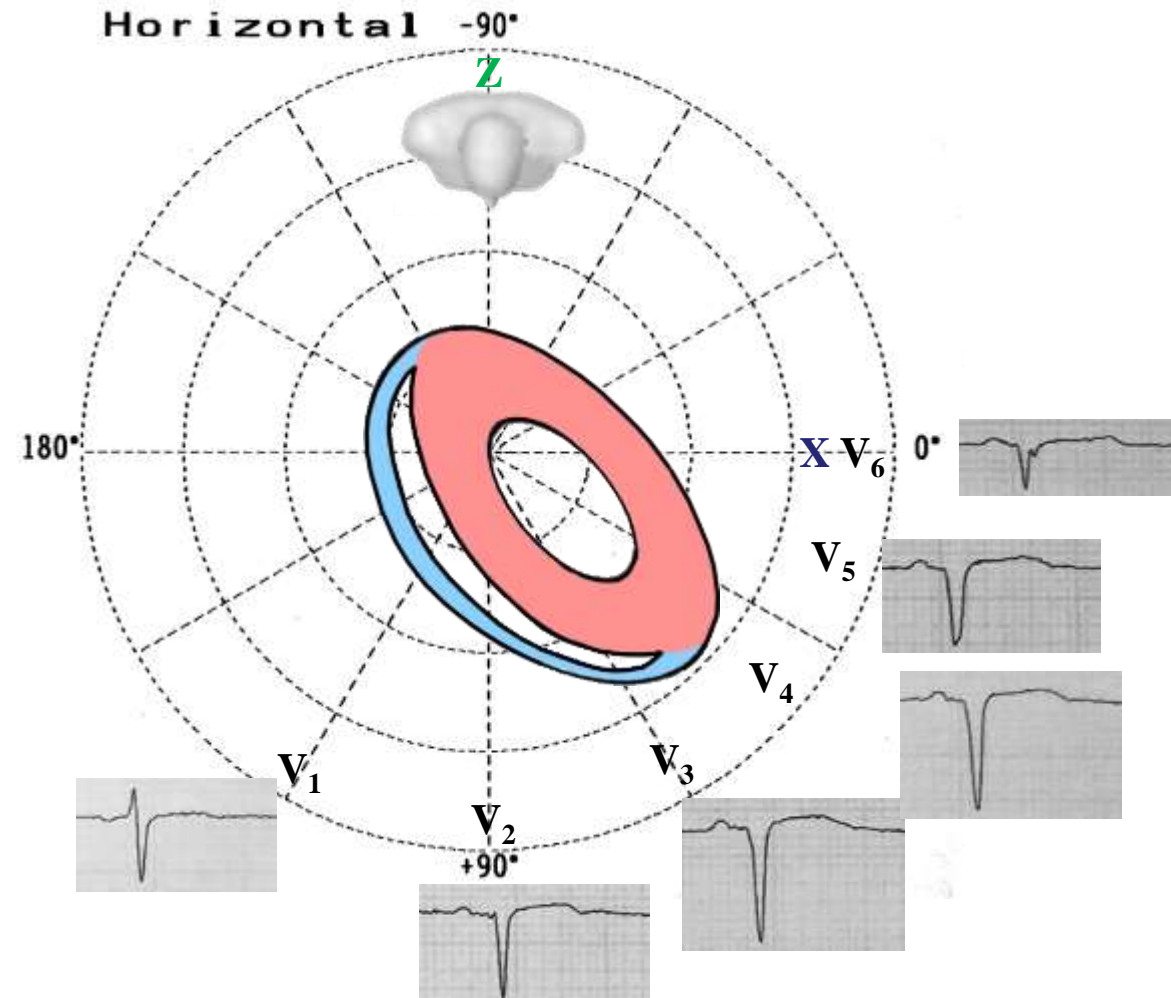


Extreme left axis deviation (-90° to $\pm 180^\circ$): VT (**Kindwall 1988; Akhtar 1988**)

ECG in the HP (Figure 1)

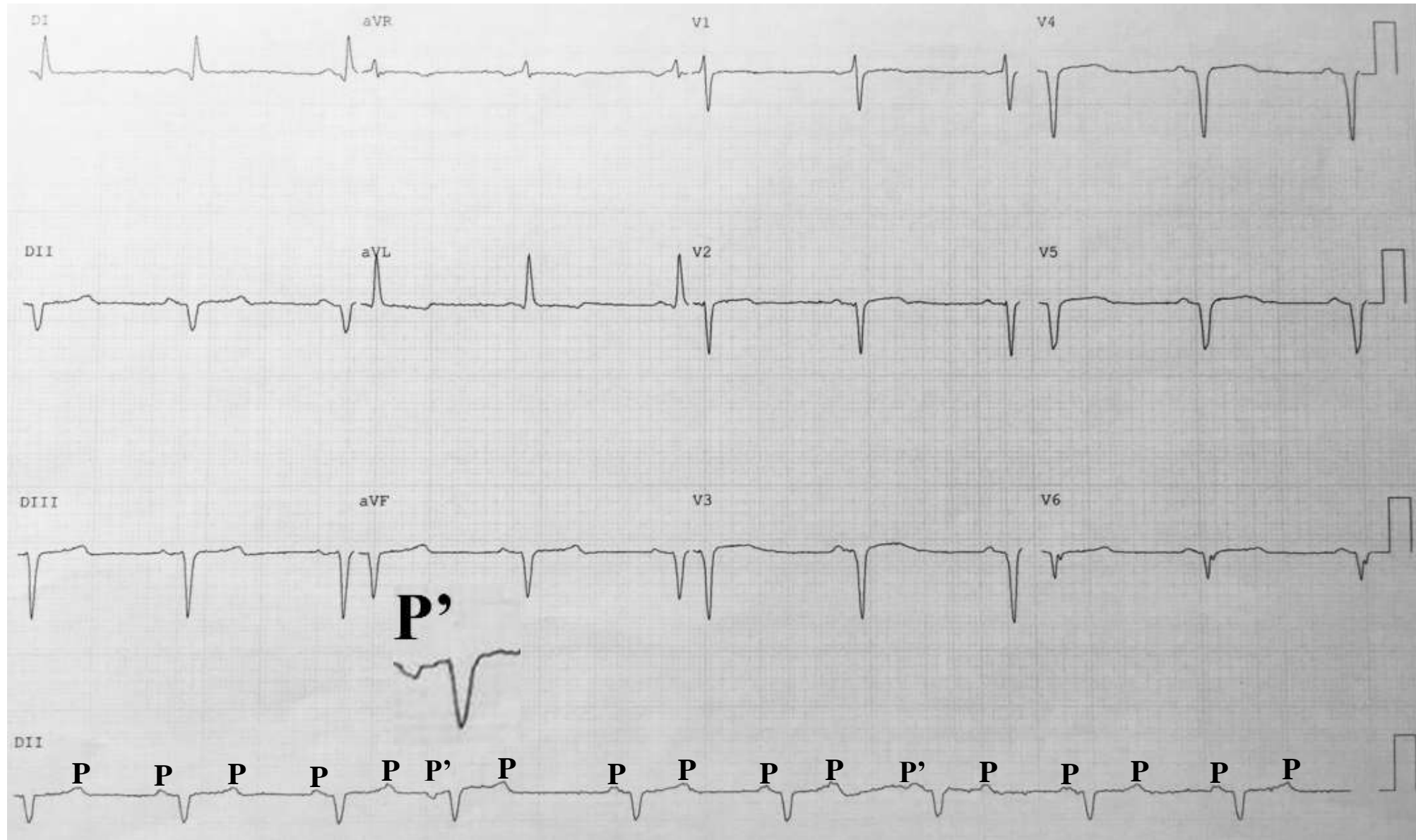


ECG in the HP (Figure 2)



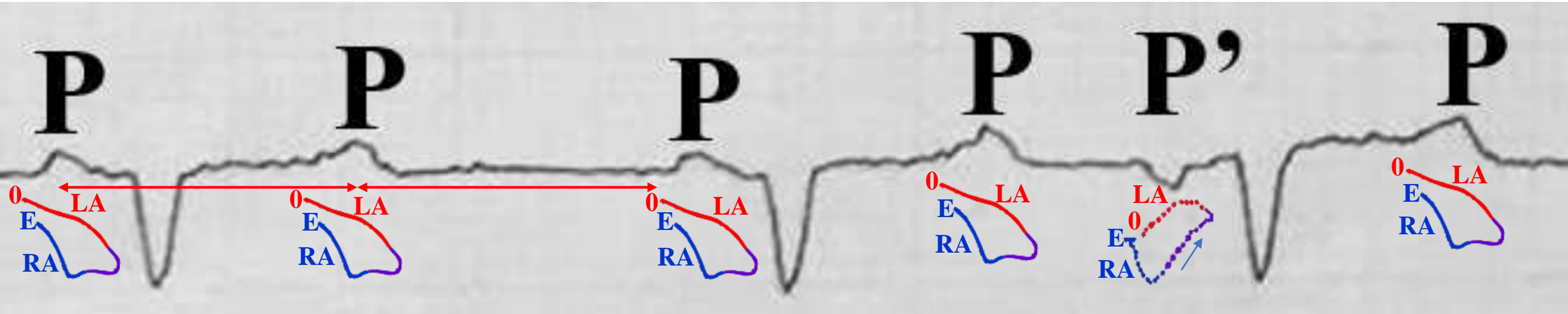
Negative precordial concordance across precordial leads (when the precordial leads consist of complexes that are entirely negative during a broad QRS tachycardia). Any Q wave in V6 (Kindwall 1988).

Figure 2 ECG after reversion



ECG diagnosis: Second degree 2:1 AV block Mobitz II with narrow QRS (see next slide), ventriculophasic arrhythmia, ventricular HR 52 bpm, P duration 112 ms, P voltage 0.8 mm, P axis +30°. Extensive transmural anterior infarction. Probably LAFB associated with inferior MI.

Long II strip: P-waves/hypothetical P-loops



Prolonged P-wave

The PP intervals which contain a QRS complex are shorter than the PP intervals which do not contain it. This phenomenon is present in more than 40% of cases with complete AV block and less common in the setting of second-degree 2:1 AV block. It is characterized by intermittent non-conducted P waves without progressive prolongation of the PR interval. Mobitz II is usually due to failure of conduction at the level of the His-Purkinje system (i.e. below the AV node). Mobitz II is more likely to be due to structural damage to the conducting system (e.g. infarction, fibrosis, necrosis). In around 75% of cases, the conduction block is located distal to the Bundle of His, producing broad QRS complexes (such as the present case). In the remaining 25% of cases, the conduction block is located within the His Bundle itself, producing narrow QRS complexes. Mobitz II is an “all or nothing” phenomenon whereby the His-Purkinje cells suddenly and unexpectedly fail to conduct a supraventricular impulse. There may be no pattern to the conduction blockade, or alternatively there may be a fixed relationship between the P waves and QRS complexes, e.g. 2:1 block, 3:1 block. Mobitz II is much more likely than Mobitz I to be associated with hemodynamic compromise, severe bradycardia and progression to 3rd degree heart block. Onset of hemodynamic instability may be sudden and unexpected, causing syncope (Stokes-Adams attacks) or sudden cardiac death. The risk of asystole is around 35% per year. Mobitz II mandates immediate admission for cardiac monitoring, backup temporary pacing and ultimately insertion of a permanent pacemaker. Additionally, the fifth P-wave (P') is probably a premature atrial contraction near sinus node with Bachman conduction delay and caudo-cephalic or caudocranial left atrial activation. This is compatible with second degree interatrial block.

2:1 second degree AV block with narrow QRS

- 1) Each two P waves, one is blocked;
- 2) The conducted P should have a constant PR interval, whether normal or prolonged;
- 3) It is impossible to determine if this is type I or II by surface ECG;
- 4) The changes in the rate of conduction may indicate if this is type I or II; or if in the change the PR interval remains constant, it will be type I;
- 5) In terms of percentage, 35% are supra-Hisian (nodal), 15% Hisian and 50% infra-Hisian;
- 6) In terms of percentage, 50% presents narrow QRS and 50% wide QRS;
- 7) 2:1 AV block with narrow QRS complex, nearly always indicates supra-Hisian nodal location.

In the case of 2:1 AV block (2 P waves for every QRS complex) it is impossible to differentiate type I from type II Mobitz block based solely on the P:QRS ratio or on a pattern of lengthening PR intervals. In this case, a lengthened PR interval with a normal QRS width is most likely indicative of a type I-like pathology, and a normal PR interval with a widened QRS is most likely indicative of a type II-like pathology.

Vagal maneuvers (e.g. carotid massage) may also be used in this case to increase the parasympathetic tone to the AV node. This tends to create lower P:QRS ratios, which may cause a type I pathology to convert to a 3:2 or 4:3 pattern and may cause a type II pathology to resolve to a 1:1 pattern, if it has any effect at all.

2:1 AV block can possibly be from either second degree type I AV nodal block (Wenckebach) or second degree type II AV nodal block. This distinction is crucial since the former is usually benign while the later requires implantation of a permanent pacemaker. A general rule to remember is that if the PR interval of the conducted beat is prolonged AND the QRS complex is narrow, then it is most likely second degree type I AV nodal block (Wenckebach). Alternatively, if the PR interval is normal and the QRS duration is prolonged, then it is most likely second degree type II AV block and a pacemaker is probably warranted.

Second degree type I AV nodal block is an issue in the AV node itself which is subject to sympathetic and parasympathetic tone while second degree type II AV block is "infranodal" conduction disease of the His-Purkinje system, therefore altering AV nodal conduction would have no effect. Outside of acute myocardial infarction, sustained 2:1 and 3:1 AV block with a wide QRS complex occurs in the His-Purkinje system in 80% of cases and 20% in the AV node.

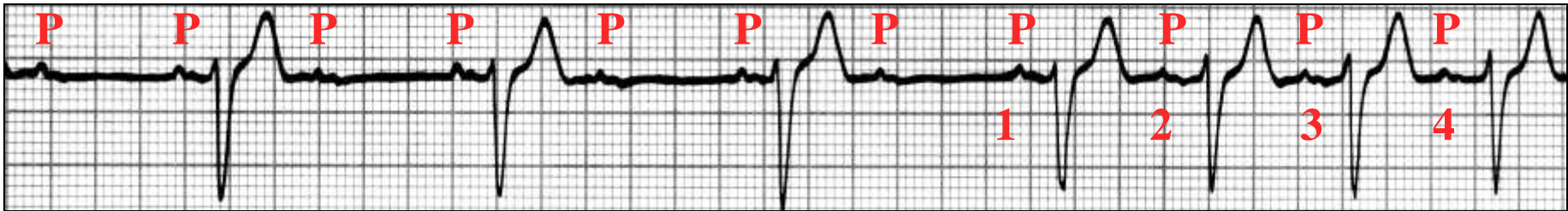In order to distinguish between the two potential rhythms when an ECG reveals 2:1 AV nodal block, a couple of different maneuvers can be employed:

Carotid sinus massage or adenosine: This slows the sinus rate allowing the AV node more time to recover, thus reducing the block from 2:1 to 3:2 and unmasking any progressing prolonging PR intervals that would indicate second degree type I AV nodal block.

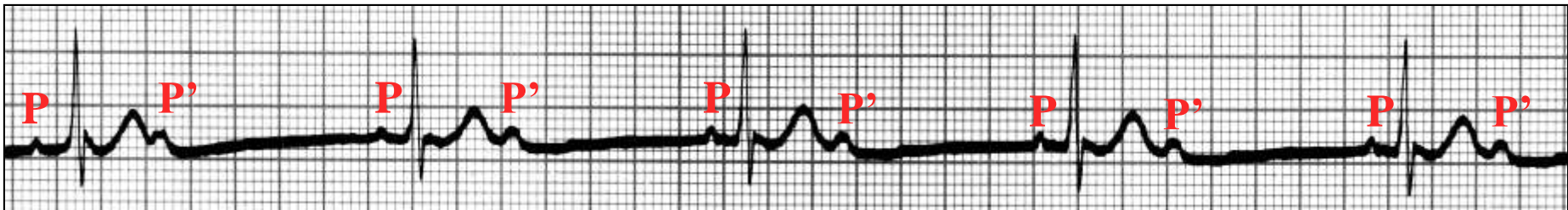
Atropine administration: This enhances AV nodal conduction and could eliminate second degree type I AV nodal block since it is due to slowed AV nodal conduction. The administration of atropine in patients with His-Purkinje disease may increase the degree of AV block (**Barold 2001**)

Exercise ECG testing (enhances AV nodal conduction and could eliminate second degree type I AV nodal block since it is due to slowed AV nodal conduction)

Example of intermittent 2:1 2nd degree AV block (up) and example of pseudo 2:1 2nd degree AV block by blocked atrial extrasystole (down)



2:1 2nd degree AV block, which over the last four complexes is conducted 1:1. During this type of conduction, the PR interval is gradually prolonged, indicating that the second degree block is supra-hisian. For instance, in the 1st, the PR interval is 160 ms, and in the 4th beat, it is 220 ms.



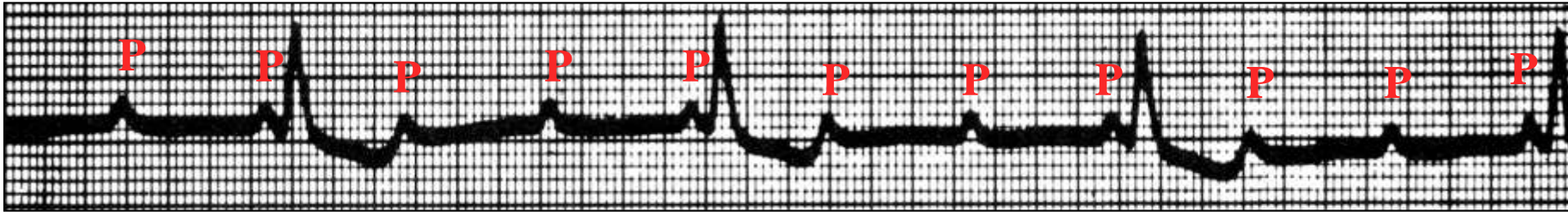
Pseudo 2:1 2nd degree AV block: the second P wave (P') has a morphology different from the conducted P wave, being ectopic, premature and not conducted: sinus rhythm with blocked atrial extrasystoles. P' waves are atrial extrasystoles.

High degree or advanced AV block ECG criteria

- 1) Two or more successive P waves are blocked;
- 2) AV ratio $\geq 3:1$;
- 3) Constant PR interval in all conducted beats;
- 4) Atrial rate greater than the ventricular one;
- 5) The clinical significance is comparable to complete AV block;
- 6) The phenomenon of concealed conduction may be responsible by the ventricular response failure.

Comment:

High grade AV block: A type of severe second degree heart block with a very slow ventricular rate but still some evidence of occasional AV conduction. **AV dissociation:** This term indicates only the occurrence of *independent atrial and ventricular contractions* and may be caused by entities other than complete heart block (e.g. “interference-dissociation” due to the presence of a ventricular rhythm such as AIVR or VT).



Conducted P waves have a constant PR interval of 180 ms; each two blocked P waves, one is conducted (rate 3:1).

Bundle Branch Reentrant Ventricular Tachycardia or Branch-to-branch reentry ventricular tachycardia

In patients with conduction delays within the His-Purkinje system, macro reentries through the right and left branch bundles may cause sustained broad ventricular tachycardias (VTs) that are called bundle branch reentrant VT (BBR-VT) or branch-to-branch reentry VTs (BBR-VT). Macroreentry involving the His-Purkinje system was originally described by Akhtar in 1974, in which premature RV stimulation produced ventricular echo beats with a LBBB morphology (**Akhtar 1974**). Sustained BBR-VT as a clinical entity was identified by Caceres et al. (**Caceres 1989**) BBR-VT involving the bundle of His, both bundle branches, and the ventricular myocardium in the circuit BBR-VT is well known to be commonly associated with structural heart diseases and severe left ventricular dysfunction based on underlying structural heart diseases such as dilated cardiomyopathy, ischemic cardiomyopathy, prior valve surgery or valvular heart disease. BBR-VT is a macro-re-entrant VT involving the His-Purkinje system and usually requires some form of conduction delay in it (**Eckart 2007**). BBR-VT is relatively rare with an incidence of about 6% to 8% of inducible sustained monomorphic VT (SM-VT) series (**Caceres 1989; Cohen 1991; Lopera 2004; Balasundaram 2008**). Additionally, it is usually a highly malignant arrhythmia. BBR-VT usually results in marked hemodynamic compromise and often presents with syncope, presyncope, or sudden cardiac arrest. BBR-VT is associated with serious hemodynamic decompensation, and the clinical presentation in $\approx 75\%$ of patients with inducible BBR-VT is syncope or cardiac sudden death. Class I indications for referral to an electrophysiologist for invasive testing include S-VT, especially if associated with symptoms of hemodynamic compromise and associated with LV dysfunction. ECGs recorded during sinus rhythm often show evidence of distal conduction system disease, with a prolonged PR interval and a nonspecific “LBBB-like” intraventricular conduction delay (wide QRS complex). Typical LBBB is an uncommon finding on the resting ECG although some patients may have apparent complete antegrade LBBB with intact retrograde LBB conduction. (**Blanck 1995b**)

Blanck et al reported that 45 of 48 patients with BBR-VT showed structural heart disease and prolonged baseline H-V interval of >60 ms. They

also presented in another report that H-V intervals were prolonged in the 3 patients with BBR-VT without overt structural heart disorder. Presentation of BBR-VT in this case is an unusual one because of normal structural heart and normal H-V interval of 48 ms during sinus rhythm (**Blanck 1993a**). When a VT is induced, the presence of His deflections preceding every ventricular deflection should alert one to the possibility of this entity. It is important to show that oscillations in the H-H cycle length results in variations in V-V cycle length. Entrainment of the tachycardia from atrium and RV apex and characteristics of postpacing intervals can be used to differentiate this arrhythmia from intramyocardial reentry and supraventricular tachycardia with aberrancy. On EPS, conduction through the His-Purkinje system (baseline HV interval) is typically prolonged, averaging 80 ms (normal 35-55 ms) compatible with trifascicular conduction disease. The diagnosis of this type of arrhythmia is very important as it does not generally respond to pharmacological treatment, with high recurrence rates, and may result in palpitations, syncope, sudden cardiac death(SCD) or multiple therapies in patients with implantable cardiac defibrillators(ICDs). It is extremely important to diagnose BBR-VT, as it can be cured through radiofrequency catheter ablation(RFCA). RBB ablation usually cures the BBR-VT, and recurrence is uncommon. The underlying cardiac disease and ventricular dysfunction dictate the prognosis and choice of device therapy in these patients. RFCA via endocardial or epicardial catheter placement can be used to treat VT in patients who have LV dysfunction from prior MI, cardiomyopathy, BBR-VT and various forms of idiopathic VT. On EPS, conduction through the His-Purkinje system (baseline HV interval) is typically prolonged, averaging 80 ms (normal 35-55 ms) compatible with trifascicular conduction disease. Antiarrhythmic therapy is usually ineffective. Fortunately, RFCA of the RBB easily cures this arrhythmia. However, the patient may require permanent pacing if there is baseline antegrade LBBB or the HV interval prolongs to more than 90-100 ms. About 25% of patients have other inducible VTs (**Blanck 1993a**). These patients are best managed with an adjunctive ICD. Many patients with BBR-VT have advanced LV dysfunction, wide QRS complexes and symptoms of HF which makes them appropriate candidates for cardiac resynchronization-ICD therapy.

BBR-VT Etiologies

I) With structural heart disease

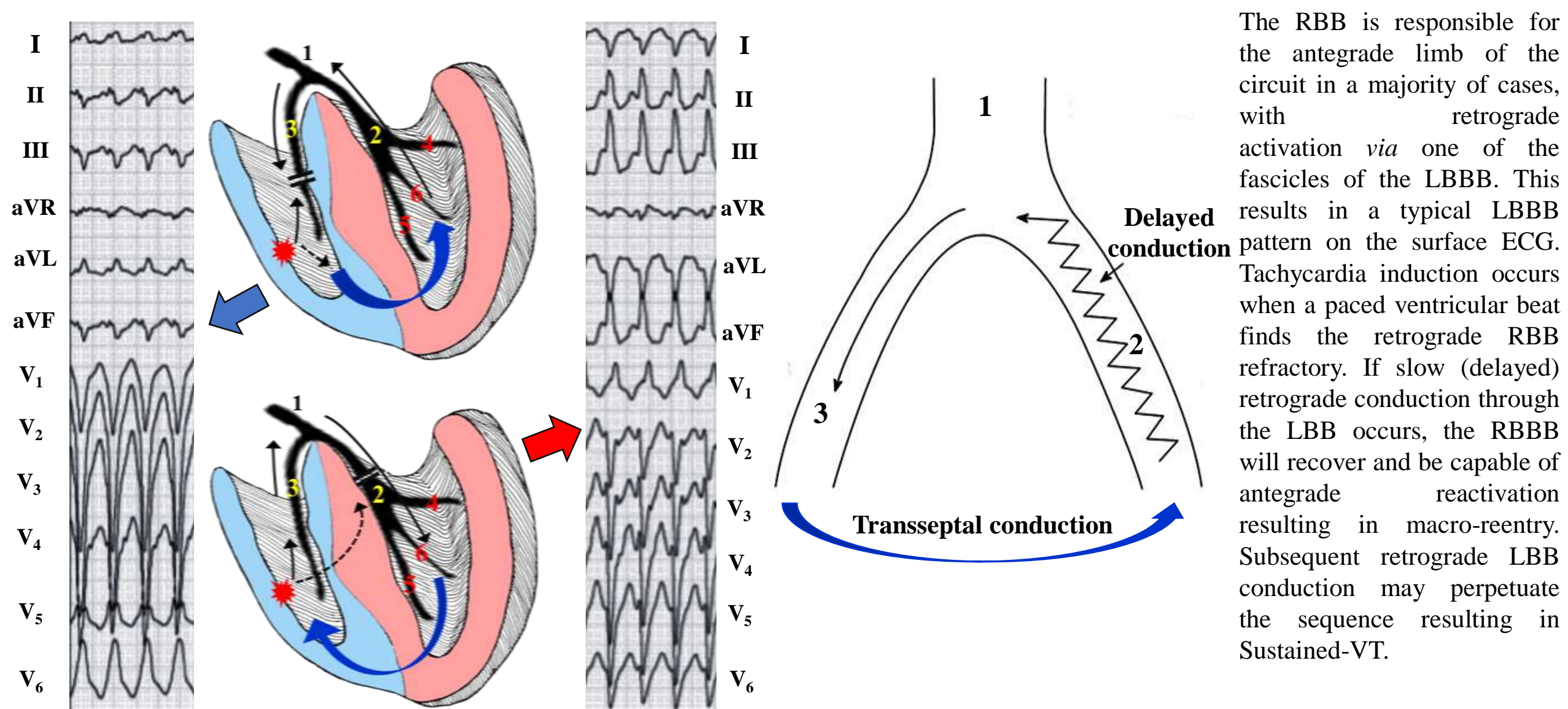
1. Non-ischemic dilated cardiomyopathy
2. Myotonic dystrophy (**Ramirez 2002; Mironov 2015**).
3. Hypertrophic cardiomyopathy
4. Endomyocardial fibrosis (EMF) without ventricular dilation (**Prabhu 2016**)
5. Left ventricular noncompaction(LVNC). LVNC is a rare form of a primary genetic cardiomyopathy considered to be the result of abnormal intrauterine arrest of the myocardial compaction process.(**Barra 2013**)
6. Valvular heart disease.
7. After corrective surgical aortic valve and mitral valve replacement without clear cause-effect relationship. (**Eckart 2007**)
8. Transcatheter aortic valve replacement (TAVR) procedure is now a well-established percutaneous procedure for patients with symptomatic severe aortic stenosis who are deemed high risk from a traditional surgical aortic valve replacement. Conduction abnormalities post TAVR have been well described with high incidence of permanent pacemaker implantation.4 TAVR procedure requiring valvuloplasty and stented valve is likely to affect the conduction system, possibly creating the right milieu for bundle branch reentry
9. Congenitally corrected transposition of the great arteries (**Kato 2015**)
10. Isolated conduction disturbances of the His-Purkinje system (HPS).(**Blanck 1993 b**)

II) A) BBR-VT in the absence of myocardial or valvular dysfunction and prolonged HV interval

Main characteristic:

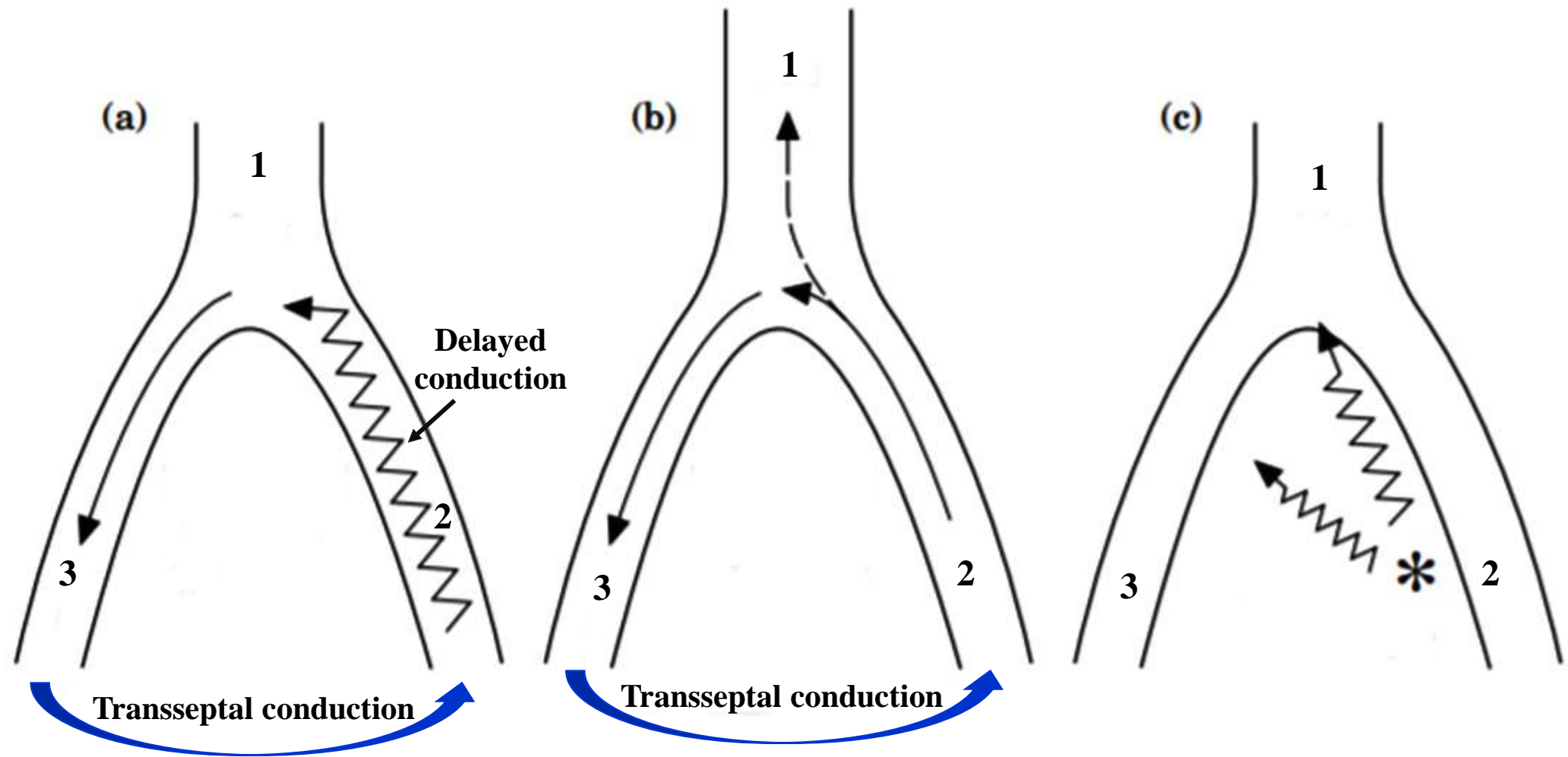
- 1) Prolonged HV interval.
- 2) Programmed RV stimulation initiate BBR-VT with l left or right BBB pattern.
- 3) Catheter ablation of the RBB abolish bundle branch reentry. Complete RBBB persist, and patients remain asymptomatic without antiarrhythmic drugs. (**Blanck 1993b**).

B) BBR-VT in the absence of prolonged HV interval during sinus rhythm A prolonged HV interval during SR is not a prerequisite for BBR-VT. Functional His-Purkinje system abnormalities appear to be the electrophysiologic substrate for this specific type of BBR-VT. Functional His-Purkinje block (split His potentials, a jump of HV interval induced by programmed atrial stimulation or burst pacing) or phase 3 block(**Li 2002**)

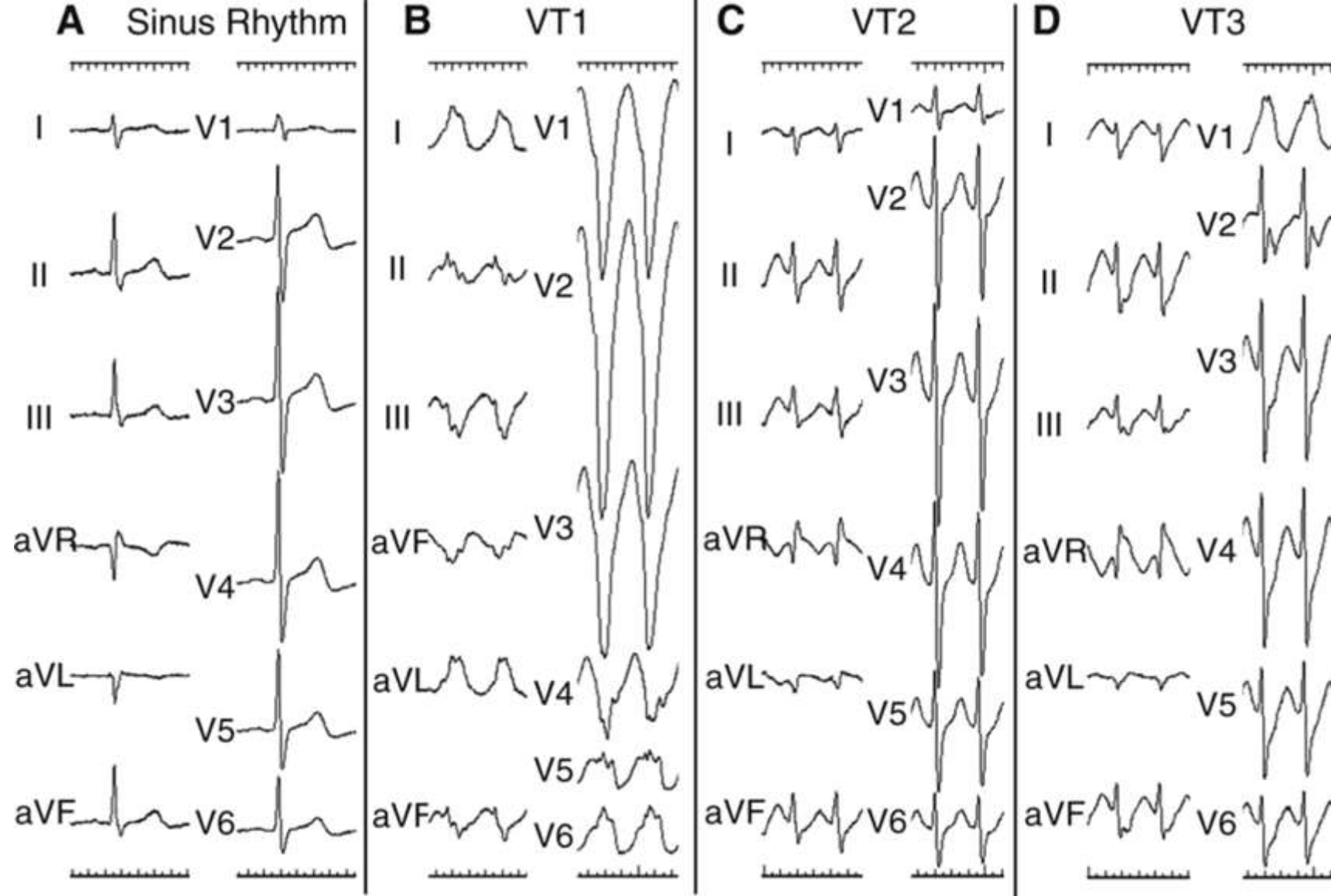


The RBB is responsible for the antegrade limb of the circuit in a majority of cases, with retrograde activation *via* one of the fascicles of the LBBB. This results in a typical LBBB pattern on the surface ECG. Tachycardia induction occurs when a paced ventricular beat finds the retrograde RBB refractory. If slow (delayed) retrograde conduction through the LBB occurs, the RBBB will recover and be capable of antegrade reactivation resulting in macro-reentry. Subsequent retrograde LBB conduction may perpetuate the sequence resulting in Sustained-VT.

Reentry between the bundle branches, in the upper image, a stimulus (extrastimulus or premature ventricular contraction) from the RV depolarizes the branches retrograde, but finds the RBB refractory, ascending by the LBB, reaching the His and activating the ventricles anteriorly through the the RBB, therefore with LBBB morphology of LBB and closing the circuit by activating the LBB again in retrograde form. In the lower image, the stimulus can climb up the RBB, but the LBB is refractory, completing the same circuit, but in the opposite direction. 1: His; 2: LBB; 3: RBB; 4: LPF; 5: LAF; 6: LSF



Diagrams illustrate possible mechanisms that can explain His bundle activation during VT. (a) The His bundle is represented as a necessary limb of the reentry circuit. This exists in typical bundle branch reentry. (b) Special type of bundle branch reentry, in which the His bundle is activated passively and is not part of the obligate reentry circuit. Slow retrograde activation is shown with the stippled line. In this case, it would be highly unusual to find block in the common bundle before His activation, if such an anatomical-electrophysiological possibility can even exist. (c) The most likely possibility that explains the present findings. In this case, fascicular activation occurs via retrograde passive activation and then proceeds to the His bundle. The authors suspect that this fascicular/ventricular reentry with passive activation of the His bundle explains these findings. 1: His bundle; 2: LBB; 3: RBB



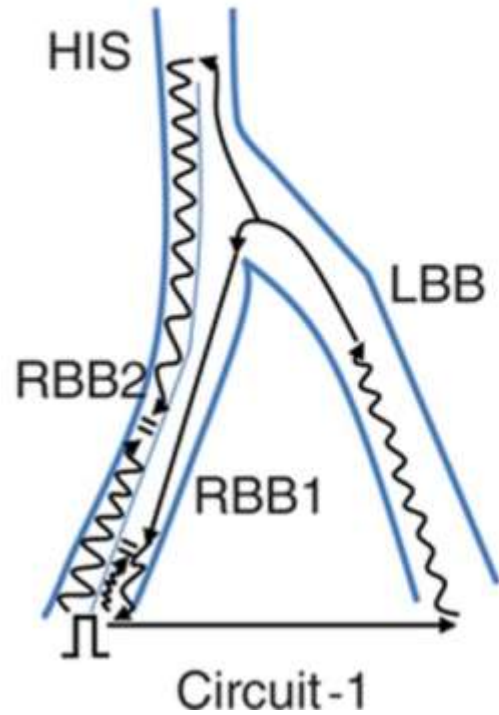
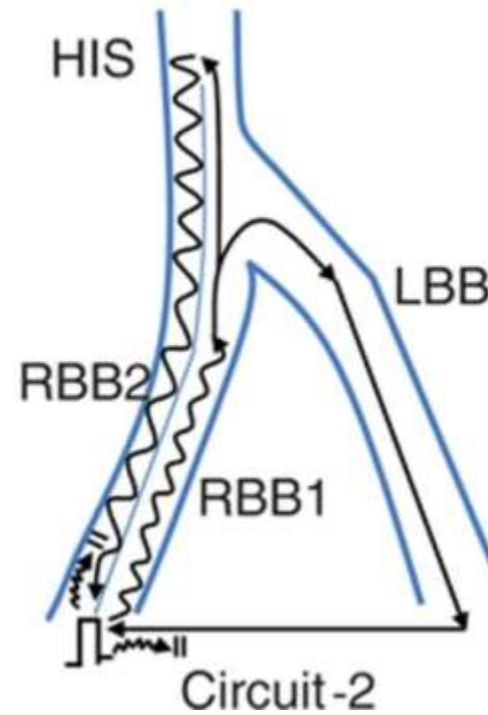
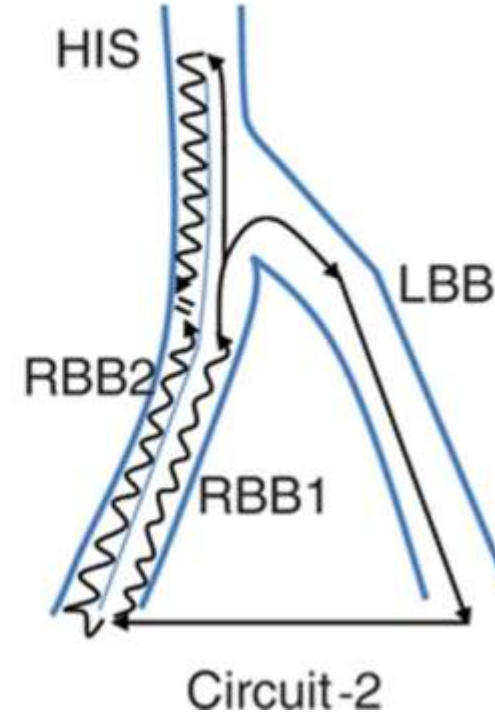
Twelve-lead ECG of sinus rhythm and VT.

A, Sinus rhythm showed slight right axis deviation.

B, VT1 showed VT with LBBB pattern.

C, VT2 had VT with narrow QRS complexes and similar morphology to that of sinus rhythm.

D, VT3 VT with RBBB morphology observed after spontaneous conversion from VT2.

A VT1 (LBBB)**B** VT2 (narrow)**C** VT3 (RBBB)

Schematic presentation of VT circuit. Longitudinal dissociation of His-right bundle system was marked as the straight line in the direction of the His-RBB, and RBB conduction pathway was divided into RBB1 and RBB2. (**Kusa 2013**)

A, VT1 was BBR-VT with LBBB morphology. Impulse from RVA blocks retrogradely in the RBB1-Purkinje muscle system (short wavy arrow), and at this time His-bundle activation occurs via the LBB. Effective propagation of RBB1 takes place after recovery of excitability so that RBB-VT is finally organized (Circuit-1). Slow antegrade His-RBB2 conduction collides with retrograde impulse anywhere along the RBB2 and therefore is not included within Circuit-1.

B, VT2 accompanied by narrow QRS complexes similar to that of sinus rhythm. Unidirectional block required for reentry and subsequent BBR-VT circuit (Circuit-2) represented reverse direction as VT1.

C, VT3 with RBBB morphology. Propagation pattern was the same as VT2 except that antegrade RBB2 conduction blocked more proximally. Note that the relationship of ventricular activation sequence between V_H and V_{RV} is also accounted for in these schematics. RBBB indicates RBBB.

BBR-VT diagnosis criteria (criteria A) (**Cohen 1991; Caceres1989; Touboul 1983**):

- 1) QRS-complex morphology with typical BBB pattern consistent with ventricular depolarization through the appropriate bundle branch;
- 2) AV dissociation during tachycardia;
- 3) Exclusion of a tachycardia from supraventricular origin by established criteria;
- 4) Prolonged HV interval during sinus rhythm;
- 5) A stable His or bundle-branch electrogram preceding each ventricular activation during tachycardia with an HV interval longer than, equal to, or <10 ms shorter than that recorded during sinus rhythm; and
- 6) Spontaneous changes in the bundle potential CL preceding similar changes in the ventricular CL. Because BBR has been found to be the tachycardia mechanism despite criterion 6 not being demonstrated (**Merino 1998; Blanck 1993**).

BBR-VT diagnosis was also established when all the following criteria (criteria B) were fulfilled:

- 1) All 6 criteria A were fulfilled except for criterion 6, that is, spontaneous changes in the bundle potential CL followed rather than preceded similar changes in the ventricular CL;
- 2) ≥ 1 additional BBR-VT morphologies were also inducible and fulfilled all criteria A;
- 3) The difference in tachycardia CL was ≤ 30 ms compared with those of the other induced BBR-VTs;
- 4) No MR-VT, either sustained or nonsustained, was inducible;
- 5) The patient had no structural heart disease; and
- 6) The inducibility of all tachycardias was suppressed after bundle-branch ablation.
- 7) Observation of orthodromic concealed fusion (concealed fusion with tachycardia QRS-complex morphology preservation) during entrainment by pacing from the atrium was an additional criterion sufficient but not mandatory to distinguish BBR-VT from MR-VT. (**Narasimhan 1997**).
- 8) Suppression of inducibility after right or left bundle-branch ablation, both at baseline and during isoproterenol infusion, was achieved in all except 2 entrained BBR-VTs. Bundle-branch ablation was not performed in these 2 BBR-VTs or in 2 nonentrained BBR-VTs because BBR-VT had never been clinically documented, it was well tolerated and difficult to induce, and defibrillator implantation (patients 10, 11, and 14) or successful catheter ablation (patient 13) of the clinical tachycardia was performed.
- 9) Interfascicular tachycardia was distinguished from the 4 BBR-VTs with an RBBB configuration by fascicular electrograms and because the former typically displays a markedly shorter HV interval (>10 ms) than that recorded during sinus rhythm. AVNRT diagnosis was established according to previously published standard criteria (**Josephson 2002**).

Differential diagnosis of BBR VT

The differential diagnosis of BBR VT includes other mechanisms of VT and different types of supraventricular tachycardia with aberrant conduction. All electrophysiological findings and pacing maneuvers described above that prove participation of the HPS in the tachycardia mechanism and exclude passive retrograde activation of the HPS help to differentiate between bundle branch reentry and other mechanisms of VT. The exclusion of supraventricular tachycardia is particularly important because QRS morphology during BBR VT is a typical bundle branch block pattern and also may be similar to that in sinus rhythm. The differential diagnosis should be based on the complimentary use of the diagnostic criteria of bundle branch reentry as well as supraventricular tachycardia (**Josephson 2002**).

Since AV dissociation is typically present during BBR-VT, the differential diagnosis is usually narrowed to AV nodal reentrant tachycardia, junctional tachycardia and hypothetical mechanisms such as intrahisian reentry and orthodromic tachycardia using a retrograde nodo-fascicular (ventricular) pathway.

Orthodromic AV reciprocal tachycardia, tachycardia using an antegrade atrio-fascicular (ventricular) accessory pathway, and atrial tachycardia need to be also considered when 1:1 ventriculo-atrial conduction is present. Entrainment with manifest QRS fusion during ventricular pacing and ability to terminate or reset the tachycardia with ventricular extrastimulus introduced when His bundle is refractory will rule out atrial tachycardia, **AV nodal reentrant tachycardia**, junctional tachycardia and intrahisian reentry. In all types of supraventricular tachycardia, the difference between the first postpacing interval after entrainment from the right ventricular apex and the tachycardia cycle length should be much longer than 30 ms. Because the postpacing interval (PPI) after entrainment has been correlated with the distance from the pacing site to the reentrant circuit, BBR-VT entrainment by pacing from the right ventricular apex (RVA) should result in a PPI similar to the tachycardia cycle length (TCL). This factor may differentiate BBR-VT from other mechanisms of wide-QRS-complex tachycardia with AV dissociation, such as myocardial reentrant VT (MR-VT) or AV nodal reentrant tachycardia (AVNRT), in which the circuit is usually located away from the RVA. A PPI-TCL >30 ms, after entrainment by RVA stimulation, makes BBR-VT unlikely. Conversely, a PPI-TCL <30 ms is suggestive of BBR-VT but should lead to further investigation by use of conventional criteria. (**Merino 2001**)

References

1. Akhtar M, Damato AN, Batsford WP, Ruskin JN, Ogunkelu JB, Vargas G. Demonstration of re-entry within the His-Purkinje system in man. *Circulation*. 1974;50(6):1150–62.
2. Akhtar M, Shenasa M, Jazayeri M, Caceres J, Tchou PJ. Wide QRS complex tachycardia. Reappraisal of a common clinical problem. *Ann Intern Med*. 1988;109(11):905–12.
3. Assali A, Sclarovsky S, Herz I, Solodky A, Sulkes J, Strasberg B. Importance of left anterior hemiblock development in inferior wall acute myocardial infarction. *Am J Cardiol*. 1997;79(5):672-4.
4. Balasundaram R, Rao HB, Kalavakolanu S, Narasimhan C. Catheter ablation of bundle branch reentrant ventricular tachycardia. *Heart Rhythm* 2008;5(6 Suppl):S68-72.
5. Barra S, Moreno N, Providência R, Gonçalves H, Primo JJ. Incessant slow bundle branch reentrant ventricular tachycardia in a young patient with left ventricular noncompaction. *Rev Port Cardiol*. 2013;32(6):523-9.
6. Blanck Z, Dhala A, Deshpande S, Sra J, Jazayeri M, Akhtar M. Bundle branch reentrant ventricular tachycardia: cumulative experience in 48 patients. *J Cardiovasc Electrophysiol*. 1993;4(3):253–62.a
7. Blanck Z, Jazayeri M, Dhala A, Deshpande S, Sra J, Akhtar M. Bundle branch reentry: a mechanism of ventricular tachycardia in the absence of myocardial or valvular dysfunction. *J Am Coll Cardiol*. 1993;22(6):1718-22.b
8. Blanck Z, Deshpande S, Jazayeri MR, Akhtar M. Catheter ablation of the left bundle branch for the treatment of sustained bundle branch reentrant ventricular tachycardia. *J Cardiovasc Electrophysiol*. 1995;6(1):40–3.
9. Blomström-Lundqvist C, Scheinman MM, Aliot EM, et al. ACC/AHA/ESC guidelines for the management of patients with supraventricular arrhythmias--executive summary. a report of the American college of cardiology/American heart association task force on practice guidelines and the European society of cardiology committee for practice guidelines (writing committee to develop guidelines for the management of patients with supraventricular arrhythmias) developed in collaboration with NASPE-Heart Rhythm Society. *J Am Coll Cardiol* 2003;42(8):1493-531.
10. Brugada P, Brugada J, Mont L, Smeets J, Andries EW. A new approach to the differential diagnosis of a regular tachycardia with a wide QRS complex. *Circulation*. 1991;83(5):1649–59.
11. Caceres J, Jazayeri M, McKinnie J, Avitall B, Denker ST, Tchou P, Akhtar M. Sustained bundle branch reentry as a mechanism of clinical tachycardia. *Circulation*. 1989;79(2):256–70.

12. Cohen TJ, Chien WW, Lurie KG, Young C, Goldberg HR, Wang Y et al. Radiofrequency catheter ablation for treatment of bundle branch reentrant ventricular tachycardia: results and long-term follow-up. *J Am Coll Cardiol* 1991;18(7):1767–73.
13. Eckart RE, Hruczkowski TW, Tedrow UB, Koplan BA, Epstein LM, Stevenson WG. Sustained ventricular tachycardia associated with corrective valve surgery. *Circulation* 2007;116(18):2005-11.
14. Griffith MJ, Garratt CJ, Rowland E. Effects of intravenous adenosine on verapamil-sensitive "idiopathic" ventricular tachycardia. *Am J Cardiol.* 1994;73(11):759-64.
15. Josephson ME. *Clinical Cardiac Electrophysiology: Technique and Interpretation*. 3rd ed. Philadelphia: Lippincott Williams & Wilkins; 2002.
16. Kato K, Yagishita D, Ejima K, Manaka 1, Shoda M, Hagiwara N. Incessant bundle branch reentrant ventricular tachycardia in a patient with corrected transposition of the great arteries. *Heart Rhythm Case Rep.* 2015;1(6):434-8.
17. Kusa S, Taniguchi H, Hachiya H, Miyazaki S, Nakamura H, Uchiyama T, Iesaka Y. Bundle branch reentrant ventricular tachycardia with wide and narrow QRS morphology. *Circ Arrhythm Electrophysiol.* 2013;6(6):e87-91.
18. Li YG, Grönefeld G, Israel C, Bogun F, Hohnloser SH. Bundle branch reentrant tachycardia in patients with apparent normal His-Purkinje conduction: the role of functional conduction impairment. *J Cardiovasc Electrophysiol.* 2002;13(12):1233-9.
19. Lopera G, Stevenson WG, Soejima K, et al. Identification and ablation of three types of ventricular tachycardia involving the His-Purkinje system in patients with heart disease. *J Cardiovasc Electrophysiol.* 2004;15(1):52–8.
20. Merino JL, Carmona JR, Ferna'ndez-Lozano I, Peinado R, Basterra N, Sobrino JA. Mechanisms of sustained ventricular tachycardia in myotonic dystrophy: implications for catheter ablation. *Circulation.* 1998;98(6):541–6.
21. Merino JL, Peinado R, Fernandez-Lozano I, et al. Bundle-branch reentry and the postpacing interval after entrainment by right ventricular apex stimulation: A new approach to elucidate the mechanism of wide-QRS-complex tachycardia with atrioventricular dissociation. *Circulation.* 2001;103(8):1102–8.
22. Miller JM, Das MK. Differential diagnosis for wide QRS complex tachycardia. In: *Cardiac electrophysiology. From Cell to Bedside*. Fifth Edition. Eds.: Zipes DP, Jalife J. Saunders, Elsevier 2009, pp. 823-830.
23. Mironov NY, Mironova NA, Saidova MA, Stukalova OV, Golitsyn SP. Rare Cause of Wide QRS Tachycardia. *Case Rep Cardiol.* 2015; 2015:151269.
24. Mizusawa Y, Sakurada H, Nishizaki M, Ueda-Tatsumoto A, Fukamizu S, Hiraoka M. Characteristics of bundle branch reentrant ventricular tachycardia with a right bundle branch block configuration: feasibility of atrial pacing. *Europace.* 2009;11(9):1208-13.

25. Narasimhan C, Mohammad R, Jazayeri R, et al. Ventricular tachycardia in valvular heart disease: facilitation of sustained bundle branch reentry by valve surgery. *Circulation* 1997;96(12):4307–13.
26. Pava LF, Perafán P, Badiel M, et al. R-wave peak time at DII: a new criterion for differentiating between wide complex QRS tachycardias. *Heart Rhythm*. 2010;7(7):922-6.
27. Prabhu MA, Prasad BV, Thajudeen A, Namboodiri N. Bundle branch reentry: A rare mechanism of ventricular tachycardia in endomyocardial fibrosis, without ventricular dilation. *Indian Heart J*. 2016;68 Suppl 2:S198-S201.
28. Ramirez CJ, Rodriguez DA, Velasco VM, Rosas F. Myotonic dystrophy and bundle-branch reentrant tachycardia. *Rev Esp Cardiol*. 2002;55(10):1093-7.
29. Singh G, Lahiri MK, Khan A, Schuger CD. Bundle branch reentrant ventricular tachycardia after transcatheter aortic valve replacement. *Heart Rhythm Case Rep*. 2017;3(3):177-85.
30. Touboul P, Kirkorian G, Atallah G, et al. Bundle branch reentry: A possible mechanism of ventricular tachycardia. *Circulation*. 1983;67(3):674–80.
31. Verecke A, Duray G, Szénási G, Altemose GT, Miller JM. New algorithm using only lead aVR for differential diagnosis of wide QRS complex tachycardia. *Heart Rhythm*. 2008;5(1):89–98.
32. Wellens HJ, Bär FW, Lie KI. The value of the electrocardiogram in the differential diagnosis of a tachycardia with a widened QRS complex. *Am J Med*. 1978;64(1):27–33.