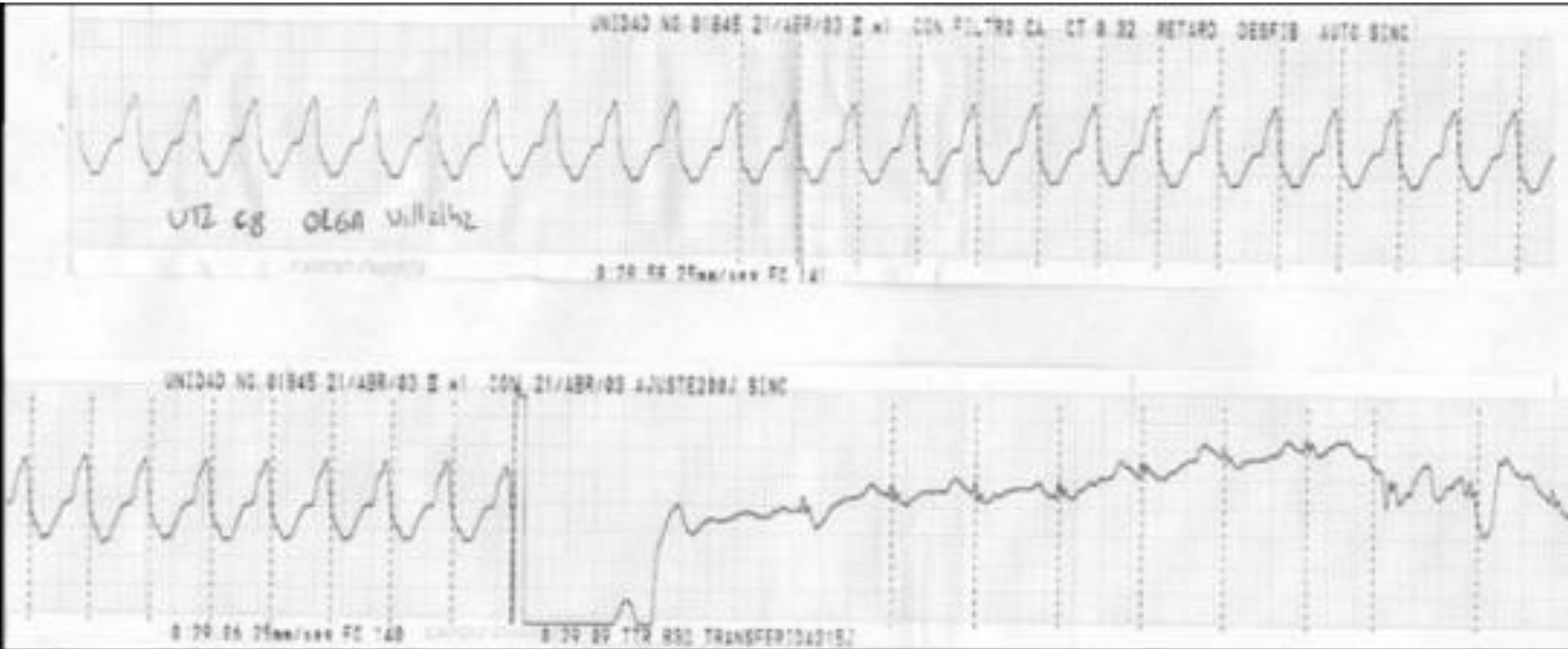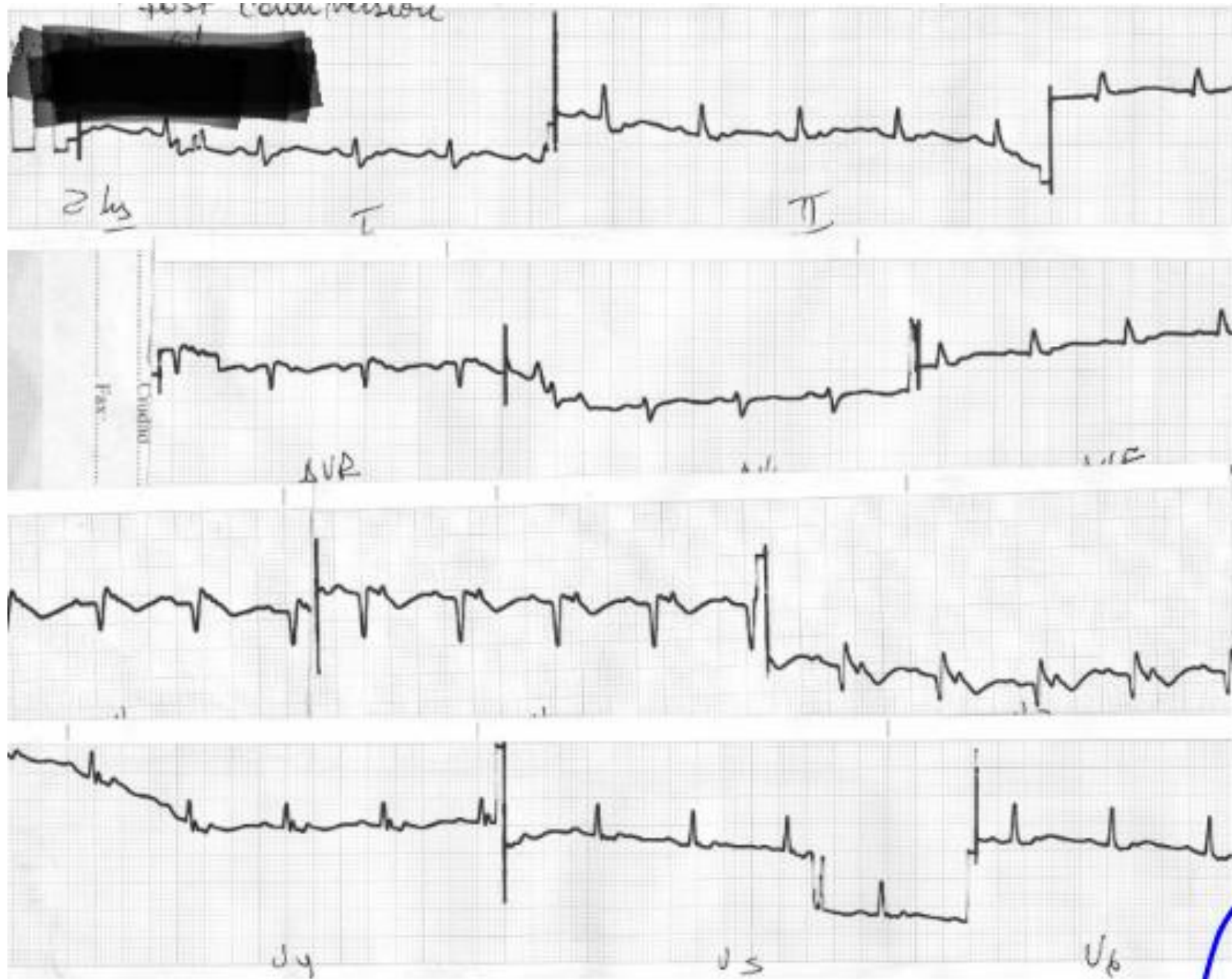




Monomorphic VT Typical of structural heart disease



Type 1 Brugada pattern associated with epsilon wave. Suggest canceled forms of ARVC/D See next comments

Brugada Syndrome and minors forms of Arrhythmogenic Right Ventricular Cardiomyopathy/Dysplasia Phenotype overlapping

By Andrés Ricardo Pérez-Riera & Raimundo Barbosa-Barros.

Brugada syndrome (BrS) is a clinical-electrocardiographic entity characterized by dynamic J-point and ST-segment elevation ≥ 2 mm rectilinear descendent or convex upward in right precordial leads (V1 to V3) followed by negative T wave that is unrelated to ischemia, electrolyte disturbances, or obvious structural heart disease was reported by Osher and Wolff in 1953 (**Osher 1953**), but was first described as a distinct clinical entity associated with a high risk of sudden cardiac death by the Brugada brothers (**Brugada 1991**). Pedro and Josep Brugada, presented an abstract at the annual NASPE meeting describing a new clinical-cardiological syndrome, typified by the association of right bundle branch block (RBBB), persistent ST segment elevation, normal QT interval and sudden cardiac death (SCD). In 1992, the Catalanian brothers (Spain), presented the first description of the entity adding four more patients to their initial description, making a total of eight patients. (**Brugada 1992**) This would be the last clinical-cardiological entity to be identified in the 20th century (**Pérez-Riera 2001**).

The three main electrocardiographic elements of the initial description cannot be gifts:

Right Bundle Branch Block (RBBB): We demonstrate using vectorcardiography (VCG) that there are cases of BrS without IRBBB or CRBBB that explain the non-existence of final S broad wave in the left leads. Cases with only the ST segment elevation (**Pérez-Riera 2012**) Additionally, in more cases of BrS have right end conduction delay in right ventricular outflow tract territory, when the right bundle branch is not a fascicle. In most of cases, BrS has not truncular, septal or predivisional RBBB.

Persistent ST segment elevation is not true because today we know that the ST segment elevation is dynamic and/or concealed, not persistent/permanent.

Normal QT interval: The QT interval is not always normal because frequently there are a discrete QT interval prolongation, on right precordial leads (from V1 to V3) like occur in ARVC/D consequence of parietal block. (**Pitzalis 2003**). Additionally, calcium channel-mediated variant of BrS has a shorter-than-normal QT interval. Antzelevitch et al (**Antzelevitch 2007**.) described the first report of loss-of-function mutations in genes encoding the cardiac L-type calcium channel associated with a familial sudden cardiac death syndrome in which a BrS phenotype combined with shorter-than-normal QT intervals was observed.

Martini et al (**Martini 1989**) established the relationship between the ECG pattern of RBBB and ST segment elevation on right precordial leads. These authors described six patients with apparent idiopathic ventricular fibrillation, three of whom had early repolarization ECG pattern from V1 to V3. In these patients, underlying structural abnormalities of the right ventricle were clinically documented.

Ventricular fibrillation (VF) and SCD may occur in patients with a distinctive ECG type 1 Brugada pattern. Corrado et al. (**Corrado 1996**) described 16 members of a family affected by this syndrome underwent noninvasive cardiac evaluation, including ECG, Holter monitoring, stress testing, echocardiography and signal-averaged electrocardiography(SAECG); two patients had electrophysiological study (EPS) and angiography. Endomyocardial biopsy was performed in one living patient, and postmortem examination, including study of the specialized conduction system, was performed in one victim of sudden death. Five years before a fatal cardiac arrest, the proband had been resuscitated from sudden cardiac arrest due to recorded VF. Serial ECGs showed a prolonged PR interval, RBBB, extreme left-axis deviation and type 1 Brugada ECG pattern, in the absence of apparent clinical structural heart disease. Postmortem investigation disclosed right ventricular dilation and myocardial atrophy with adipose replacement of the right ventricular free wall as well as sclerotic interruption of the right bundle branch. A variable degree of RBBB and upsloping right precordial ST segment was observed in seven family members; four of the seven had structural right ventricular abnormalities on echocardiography and late potentials(LPs) on SAECG. A sib of the proband also had a prolonged HV interval, inducible VF and fibrofatty replacement on endomyocardial biopsy. An autosomal dominant familial cardiomyopathy, mainly involving the right ventricle and the conduction system, accounted for the ECG changes and the electrical instability of the syndrome.

Patients with the ECG pattern of RBBB and right precordial ST-segment elevation may experience sudden death in the setting of ARVC/D or a functional electrical disorder such as BrS. Right precordial ST-segment elevation was found in 14% of young sudden death victims with available ECG. It mostly reflected underlying ARVC/D with predominant right ventricular anterior wall involvement and characterized a subgroup of patients who share with BrS patients the propensity to die from non-exercise-related cardiac arrest and to exhibit dynamic ECG changes and polymorphic ventricular tachycardia. (**Corrado 2001**) These authors studied 16 members of an affected family and provided definitive evidence that a structural abnormality of both the right ventricle(RV) and intraventricular conduction system may present clinically as RBBB, ST segment elevation on right precordial leads and sudden death, The proband had been resuscitated from sudden cardiac arrest due VF 5 years before sudden death, Serial ECGs showed sinus rhythm, prolonged PR interval, RBBB, extreme left axis deviation, and type 1 Brugada ECG pattern on right precordial leads, without apparent structural heart disease. Post mortem investigation disclosed RV dilatation, myocardial atrophy and fibrofatty replacement of the RV free wall and sclerotic interruption of RBB.

Located prolongation has been described for QRSd interval from V1 to V3. related to $\frac{V1 + V2 + V3}{V4 + V5 + V6} > 1.2$ in 97% of the cases of ARVC/D, and it is related with the amount of fibrotic tissue in patients with VT that originate in the RV. The sensitivity of this criterion is not known in other entities and it speaks in favor of slow RV conduction.

Pitzalis et al. (**Pitzalis 2003**) show that the sign is not specific or pathognomonic, since it is found in BrS with QT interval prolongation only from V1 to V3. If QT interval prolongation occurs only from V1 to V3, it is clear that this is due to depolarization time prolongation.

If we admit that in BrS there is some degree of RBBB, this QT interval prolongation may be partially due to this dromotropic disorder. QT interval constitutes a classical measurement for ventricular repolarization; however, it includes depolarization (QRS), which represents the so-called “electrical systole”, which includes ventricular depolarization and repolarization. In these cases of branch block and Wolff-Parkinson-White type ventricular pre-excitation, it is better to measure the JT interval and not QT interval is used to measure ventricular repolarization; nevertheless, this parameter includes ventricular depolarization (QRS) and represents the so-called electrical systole, which is the addition of ventricular depolarization (QRS) and repolarization (ST/T = JT interval).

If branch block or WPW type ventricular pre-excitation occurs, the QTc interval does not express ventricular repolarization correctly. In these cases, JT interval measurement is more reliable ($JT = QT - QRSd$) than QT interval, because the parameter excludes depolarization that is prolonged, as a consequence of sequential activation of biventricular chamber (normally this activation is simultaneous). An association between ARVC/D and BrS can be supposed according to several case reports. In order to examine a possible link between ARVC/D and BrS, systematic ajmaline testing with 1 mg/kg body weight intravenously, was done in 55 patients (32 males, mean age 46.7+/-12.3 years) with ISFC/ESC criteria of ARVC/D by Peters et al (**Peters 2004**) In 9 patients ajmaline testing could demonstrate the type 1 Brugada ECG pattern . Three of these patients had recurrent syncope.

EPS revealed NS-VT with LBBB configuration and inferior axis in only one case. Systematic ajmaline testing could demonstrate a definite link between ARVC/D and BrS.

In June of 2007 Frigo et al. (**Frigo. 2007**) provides the first evidence of a homozygous missense mutation in SCN5A associated with atypical ventricular arrhythmias and right structural abnormalities. The authors described a patient showing monomorphic VT, ECG aspect of BrS, and structural heart abnormalities due to a homozygous missense mutation in SCN5A. They studied 13 subjects (six males, seven females, mean age 46 +/- 22 years) belonging to the same family underwent physical examination, basal biochemical marker detection, 12-lead ECG, Holter ECG, signal-averaged ECG, echocardiogram and genetic analysis. The proband underwent a stress test together with left and right ventricular angiography and electrophysiological study. Three subjects (the proband, his mother, and one brother) showed on ECG the type 1 Brugada pattern. Moreover, the proband presented a sustained monomorphic VT with LBBB pattern and superior axis), whereas all other family members were asymptomatic. Imaging techniques documented right ventricular structural abnormalities only in the proband. Mutation screening in SCN5A gene was performed in the proband and in available family members. The proband carries a novel SCN5A mutation, R814Q, in homozygous, whereas the parents and four siblings were heterozygous carriers of the same mutation. This study provides the first evidence of a homozygous missense mutation in SCN5A associated with atypical ventricular arrhythmias and right structural abnormalities.

Furushima et al (**Furushima 2007**), compared conduction delay in the right ventricular in BrS with that in ARVC/C using the SA-ECG 20 patients with BrS (18 men and 2 women; 55 +/- 12 years old; 9 symptomatic and 11 asymptomatic) and 8 patients with ARVC/D (six men and two women; 53 +/- 16 years old) were included. The authors assessed the presence of late potentials (LPs) and the filtered QRS duration (fQRSd) in V(2) and V(5) using a high-pass filter of 40 Hz (fQRSd:40) and 100 Hz (fQRSd:100). In ARVC/D, there was no significant difference in fQRSd:40 between V2 and V5 (158 +/- 19 vs. 145 +/- 17 ms, respectively): however, in BrS, fQRSd:40 in V2 was significantly longer than fQRSd:40 in V5 (147 +/- 15 vs. 125 +/- 10 ms, $P < 0.001$). In ARVC/D, there was no significant difference between fQRSd:40 and fQRSd:100 in V(2) and V(5) (158 +/- 19 vs. 142 +/- 23 ms and 145 +/- 17 vs. 132 +/- 9 ms, respectively). In contrast, in BrS, fQRSd:100 was significantly shorter than fQRSd:40 in V2 (110 +/- 8 ms vs. 147 +/- 15, $P < 0.001$). The relative decrease in fQRSd:100 compared with fQRSd:40 in V2 was significantly greater in BrS than in ARVC/D. The dominant prolongation of the fQRSd in the right precordial lead in BrS was different from the characteristics of ARVC/D, which may be caused by the conduction delay due to fibro-fatty replacement in RV.

Erkaptic et al (**Erkaptic 2008**) described a case of a 58-year-old man with structural heart disease changes consistent with ARVC/D. He also had a loss-of-function mutation in the cardiac sodium channel gene SCN5A, described in BrS. He first presented with NS-VT and was implanted with an ICD. He remained asymptomatic for 8 years until he developed recurrent episodes of VTs, which required multiple shocks. The patient was treated with a combination of quinidine and verapamil and since then remained free of arrhythmias. (**Peters. 2008**)

Provocative type 1 Brugada ECG pattern is an observation in approximately 16% of patients with typical ARVC/D. The value of this observation should be analyzed in a long-term follow-up of 17 patients identified by systematic ajmaline challenge. At first evaluation, one female had an aborted SCD and 8 patients suffered from recurrent syncope. ICD implantation was done in the patient with aborted SCD and in 6 patients with recurrent syncope. One of these six patients had intermittent 2-3 degrees AV block. Another patient had inducible VT at EPS. Follow-up over more than 3 years in all but one patient was characterized by documented M-VT in the patient with inducible VT and ICD implantation (6%). The patient with aborted SCD had only NS-VT's shortly after ICD implantation. From the 8 patients without syncope's two more patients developed AV block and SA block 3 degrees (18%). Lead-associated complications appeared in 3 of 8 patients with ICDs (38%). Repeated ajmaline challenge was positive in 4 of 8 cases (50%). One patient had a new mutation encoding for SCN5A gene. Peter concluded that Ajmaline challenge in typical ARVC/D characterizes a subgroup of elderly, predominantly female patients with the risk of developing conduction disease. Tachycardia-related events are rare. The indication of ICD implantation in recurrent syncope is . critical as the rate of lead-associated complications in a more than 3 years follow-up.

BrS is an inherited sudden-death arrhythmia syndrome. Na(+)-current dysfunction is central, but mutations in the SCN5A gene (encoding the cardiac Na(+)-channel Nav1.5) are present in only 20% of probands. Brugada patients display specific expression patterns for ion-channels

regulating cardiac conduction, excitability, and repolarization. A transcriptional profiling was performed by Gaborit et al (**Gaborit 2009**) on right-ventricular endomyocardial biopsies from 10 unrelated Brugada probands, 11 non-diseased organ-donors, seven heart-transplant recipients, 10 with ARVC/D, and 9 with idiopathic right-ventricular outflow-tract VT. Brugada patients showed distinct clustering differences vs. the two control and two other VT groups, including 14 of 77 genes encoding important ion-channel/ion-transporter subunits. Nav1.5 and K(+)-channels Kv4.3 and Kir3.4 were more weakly expressed, whereas the Na(+)-channel Nav2.1 and the K(+)-channel TWIK1 were more strongly expressed, in BrS. Differences were also seen in Ca(2+)-homeostasis transcripts, including stronger expression of RYR2 and NCX1. The molecular profile of Brugada patients with SCN5A mutations did not differ from Brugada patients without SCN5A mutations. These observations suggest that Brugada patients exhibit a common ion-channel molecular expression signature, irrespective of the culprit gene. This finding has potentially important implications for our understanding of the pathophysiology of BrS, with possible therapeutic and diagnostic consequences.

Overlapping characteristics of BrS and ARVC/D) have been reported, but little is known about the overlapping disease state of BrS and ARVC/D. Kataoka et al (**Kataoka 2016**) presented a 36-year-old man, hospitalized for syncope, presented with this overlapping disease state. The ECG showed spontaneous type1 pattern, and VF was induced by RVOT stimulation in an EPS. BrS was subsequently diagnosed; additionally, the presence of epsilon-like waves and right ventricular structural abnormalities met with the 2010 revised task force criteria for ARVC/D. After careful investigation for both BrS and ARVC/D, an ICD was inserted in the patient. This case revealed that BrS and ARVC/D clinical features can coexist in a single patient, and EPS might be useful for determining the phenotype of overlapping disease (e.g., BrS-like or ARVC/D-like).

Sudden unexplained nocturnal death syndrome (SUNDS) is a perplexing disorder to both forensic pathologists and clinic physicians. Desmoplakin (DSP) gene was the first desmosomal gene linked to ARVC/D which was associated with SD. To identify the genetic variants of the DSP gene in SUNDS in the southern Chinese Han population, Zhao et al (**Zhao 2016**) genetically screened the DSP gene in 40 sporadic SUNDS victims, 16 BrS patients, and 2 ERS patients using next generation sequencing (NSG) and direct Sanger sequencing. A total of 10 genetic variants of the DSP gene were detected in 11 cases, comprised of two novel missense mutations (p.I125F and p.D521A) and 8 previously reported rare variants. Of eight reported variants, two were previously considered pathogenic (p.Q90R and p.R2639Q), three were predicted in silico to be pathogenic (p.R315C, p.E1357D and p.D2579H), and the rest three were predicted to be benign (p.N1234S, p.R1308Q, and p.T2267S). This was the first report of DSP genetic screening in Chinese SUNDS and BrS. These results imply that DSP mutations contribute to the genetic cause of some SUNDS victims and maybe a new susceptible gene for BrS. An overlapping disease state of BrS and ARVC/D can change phenotypically during its clinical course. Therefore, careful examination and attentive follow-up are required for patients with BrS or ARVC/D. Both BrS and ARVC/D can cause repolarization abnormalities in right precordial leads and predispose to SCD due to ventricular arrhythmias. Although there is controversy over whether BrS is distinct from ARVC/D, it is believed that both are different clinical entities with respect to both the clinical presentation and the genetic predisposition. The coexistence of these two relatively rare clinical entities is also reported, but, some hypothesized that it is more

the genetic predisposition. The coexistence of these two relatively rare clinical entities is also reported, but, some hypothesized that it is more possible that disease of the right ventricular muscle might accentuate the Brugada electrocardiographic pattern. In clinic practice, there may be cases where the dividing line is not so clear.

In BrS and ARVC/D patients, the power of high-frequency components (80-150 Hz) was developed to a greater extent than in RVOT-VT patients. In the power analysis of the high-frequency components between BrS and ARVC/D, the frequency showing the greatest power was significantly higher in ARVC/D patients than that in BrS patients. High-frequency components were developed in ARVC/D and BrS, but not in RVOT-VT. The frequency levels showing high power by wavelet analysis obviously differ between ARVC/D and BrS. Wavelet analysis may provide new insight into unsolved mechanisms in arrhythmogenic right heart disease.

Ozeke et al (**Ozeke 2009**) reported a 33-year-old male presenting with recurrent syncope, who has a peculiar type 1 Brugada ECG pattern with epsilon-like wave in right precordial leads.

Yodogawa et al. (**Yodogawa 2011**) studied 40 subjects, including 20 patients with RVOT-VT, 10 patients with BrS, and 10 ARVC/D patients. The parameters on the SA-ECG and the frequency components recorded from the wavelet-transformed ECG were compared between the three groups. Late potentials were positive in none of the patients with RVOT-VT, seven of the patients with BrS, and all of ARVC/D patients.

ARVC/D and BrS are distinct clinical entities which diagnostic criteria exclude their coexistence in individual patients. ARVC/D is a myocardial disorder characterized by fibro-fatty replacement of the myocardium and ventricular arrhythmias. In contrast, the BrS has long been considered a functional cardiac disorder: no gross structural abnormalities can be identified in the majority of patients and its ECG hallmark of coved-type ST-segment elevation in right precordial leads is dynamic. Nonetheless, a remarkable condition. (**Hoogendik 2012**)

Differential Clinical characteristics between ARVC/D and BrS

I Age at presentation

ARVC/D

Manifest between the 15 and 35 years old. Adolescence 25–35. and early adulthood. (**Nava 2000**) The illness is cause of SCD in < 35 years old. It is the main cause of SCD in young athletes in Europe.

BrS

During adulthood with a mean age of SCD of 41 ± 15 years. 35–40. Can occur any time from early infancy to old age. The youngest individual diagnosed with the syndrome was two days old and the oldest age 85 years. (**Huang 2004**).

II) Prevalence

ARVC/D: It is estimated as 1/5000. (**Czarnowska 2003**) The prevalence is estimated at 0.4% depending on geographic circumstances. (**Hagenah 2004**).

BrS: The prevalence in Japan is 0.1%-0.2% (**Macfarlane 2013**)

From 44 unrelated index patients and family members, Schulze-Bahr et al (**Schulze-Bahr 2003**) performed a complete genetic analysis of SCN5A in BrS. The authors concluded that:

- 1) The sporadic cases are predominant: 63% against 37% of familiar cases;
- 2) Disease penetrance (disease absence in some individuals with disease gene), is complete in the SCN5A+ adult patients, but incomplete in SCN5A+ children (17%);
- 3) Genetic testing of SCN5A is especially useful in familial disease to identify individuals at cardiac risk;
- 4) In sporadic cases, a genetic basis and the value of mutation screening has to be further determined.

Summary of Differential Diagnosis Between ARVC/D and Brugada Syndrome

Clinical Characteristics	ARVC/D	Brugada Syndrome
Age at presentation	25–35	35–40
Sex, male/female	3:1	8:1
Distribution	Worldwide. Endemic in Veneto and Naxos Island	Worldwide Endemic in Thailand, Philippines and Japan
Race	Caucasian predominance	Asian predominance
Inheritance	AD/AR rare	AD
Gene mutation predominant	hRYR2, plakoglobin	SCN5A(See next table)
Clinical Characteristics	ARVC/D	Brugada Syndrome

Prevalence	≈ 1 in 5000 individuals(Corrado 1997)	More prevalent in South-East Asia the world-wide prevalence of a Brugada ECG pattern can be estimated at ~0.05% or 1 in 2000 patients. Whether this can be translated into a prevalence of BrS of 1 in 2000
Circumstances of events	Effort	At rest (85%)
Imaging	Morphofunctional RV (and LV) abnormalities	Normal (not always)
Pathology	Fibrofatty replacement	Minimal structural heart modifications
ECG depolarization	Epsilon waves (30%), QRS prolongation on right precordial leads	P-prolongation, PR prolongation Peripheric end conduction delay on RVOT territory. LAFB, f-QRS
ECG repolarization	T-wave inversion in precordial leads wihouth IRBBB or CRRR	High take-off ST segment V1 to V3.
AV conduction	Normal	PR prolongation, LAFB, Righth end conduction delay, HV prolongation, Split His.
Atrial arrhythmias	Late (secondary)	Early (primary 25%)
ECG changes	Fixed and progressive	Dynamics
Ventricular arrhythmias	Monomorphic VT	Very fast polymorphic VT
Mechanism of arrhythmias	Scar-related	Phase 2 reentry
Drug effect class I	Decrease	Increase
Drug effect class II	Decrease	Increase

Drug effect class III	Decrease	No effect or increase
Drug effect class IV	No effect or Decrease	No effect
Natural history	SCD, HF	SCD, Syncope

Genetic Defects Associated with BrS

	Locus	Gene/protein	Ion channel	Percent of probands
BrS1	3p21	<i>SCN5A, Na_v1.5</i>	↓ I _{Na}	11%–28%
BrS2	3p24	<i>GPD1L</i>	↓ I _{Na}	Rare
BrS3	12p13.3	<i>CACNA1C, Ca_v1.2</i>	↓ I _{Ca}	6.6%
BrS4	10p12.33	<i>CACNB2b, Ca_vβ2b</i>	↓ I _{Ca}	4.8%
BrS5	19q13.1	<i>SCN1B, Na_vβ1</i>	↓ I _{Na}	1.1%
BrS6	11q13-14	<i>KCNE3, MiRP2</i>	↑ I _{to}	Rare
BrS7	11q23.3	<i>SCN3B, Na_vβ3</i>	↓ I _{Na}	Rare
BrS8	12p11.23	<i>KCNJ8, Kir6.1</i>	↑ I _{K-ATP}	2%
BrS9	7q21.11	<i>CACNA2D1, Ca_v α2δ1</i>	↓ I _{Ca}	1.8%
BrS10	1p13.2	<i>KCND3, K_v4.3</i>	↑ I _{to}	Rare
BrS11	17p13.1	<i>RANGRF, MOG1</i>	↓ I _{Na}	Rare
BrS12	3p21.2-p14.3	<i>SLMAP</i>	↓ I _{Na}	Rare
BrS13	12p12.1	<i>ABCC9, SUR2A</i>	↑ I _{K-ATP}	Rare
BrS14	11q23	<i>SCN2B, Na_vβ2</i>	↓ I _{Na}	Rare
BrS15	12p11	<i>PKP2, Plakophilin-2</i>	↓ I _{Na}	Rare
BrS16	3q28	<i>FGF12, FHAF1</i>	↓ I _{Na}	Rare
BrS17	3p22.2	<i>SCN10A, Na_v1.8</i>	↓ I _{Na}	5%–16.7%
BrS18	6q	<i>HEY2 (transcriptional factor)</i>	↑ I _{Na}	Rare

Listed in chronologic order of their discovery.

Type	OMIM	Gene	Locus
ARVD1lpl	107970	TGFB3	14q23-q24
ARVD2	600996	RYR2	1q42-q43
ARVD3	602086	?	14q12-q22
ARVD4	602087	ARVC/D: Types, OMIM, Gene, and Locus	2q32.1-q32.3
ARVD5	604400	TMEM43	3p23
ARVD6	604401	?	10p14-p12
ARVD7	609160	DES	10q22.3
ARVD8	607450	DSP	6p24
ARVD9	609040	PKP2	12p11
ARVD10	610193	DSG2	18q12.1-q12
ARVD11	610476	DSC2	18q12.1
ARVD12	611528	JUP	17q21