

THE QRS DURATION ON RIGHT PRECORDIAL LEADS IN BRUGADA SYNDROME: A QUESTION WITHOUT CONSENSUS TO DAY

Andrés Ricardo Pérez Riera MD¹ Edgardo Schapachnik²

¹ Chief of Electro-Vectorcardiographic Sector, Cardiology Division, ABC's Faculty of Medicine, ABC Foundation, Santo André, São Paulo, Brazil.

² Chief of Chagas' disease Department, Dr. Cosme Argerich Hospital, Buenos Aires, Argentina.

In arrhythmogenic right ventricular cardiomyopathy/dysplasia (ARVC/D), the QRS complex may show incomplete right bundle branch block (IRBBB) in approximately 18% of the cases and the complete form (CRBBB) in 15% ¹.

The IRBBB or CRBBB pattern may be found associated to J point and ST segment elevation, convex to the top from V₁ to V₃ (coved type), followed by inverted T wave. This pattern cannot be differentiated with the electrocardiographic phenotype of Brugada syndrome. These cases are observed in the forms called "minor" or "concealed", where only sophisticated methods, such as magnetic nuclear resonance can differentiate both entities^{2,3}.

The QRS complex could be normal, with a slightly increased duration in precordial leads from V₁ to V₃ (> 110 ms) and with lower duration from V₃ to V₆. For this reason, a protocol for ECG recording when there is a suspicion of ARVD/C, has been proposed:

1. The tracing must have a double velocity and amplitude of (50 mm/s and 20 mm/s) with the aim of comparing QRS duration for all precordial leads. It is better to observe the possible presence of the epsilon wave.

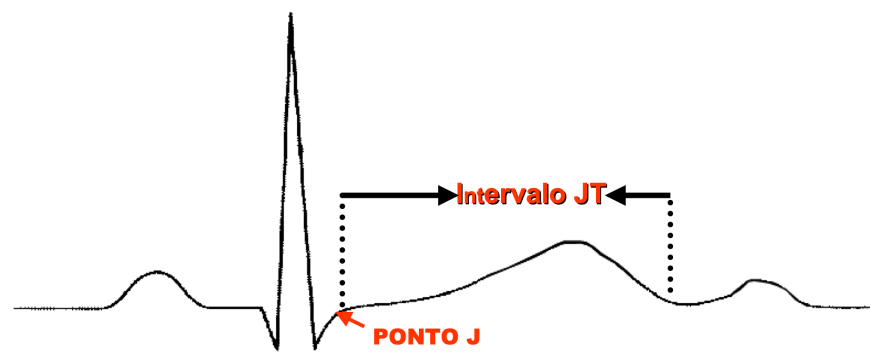
2. In the limbs leads, the right –arm electrode should be placed on the xiphoid appendage, the electrode of left arm on the manubrium of the sternum, and the one of the left leg on the rib on V₄ or V₅ with the aim of observing the epsilon wave better.

The $\text{QRSD ratio of } V_1 + V_2 + V_3 / \text{QRSD } V_4 + V_5 + V_6 > \text{ than } 1.2$ is found in 97% of the ARVC/D cases⁴.

The specificity of this criterion has not been completely established yet in patients without this entity, as well as the sensitivity; however, there is a paper showing that Brugada syndrome may also present prolongation in QT interval duration from V₁ to V₃, and consequently prolongation of the QTc interval in the right precordial leads⁵. If the QT interval is prolonged only from V₁ to V₃, being normal from V₄ to V₆, it is clear that this increase may be due to prolongation of ventricular depolarization (QRS complex) and/or by ST/T prolongation (repolarization). If we admit that in Brugada syndrome there is some degree of branch block, clearly the QT interval prolongation is due partly to this. The QTc interval constitutes the classical measurement for ventricular repolarization; however, this parameter includes ventricular depolarization (QRS), and therefore represents the so-called electric systole, which includes depolarization (QRS) and ventricular repolarization (ST/T = JT interval). See Figure 1

Figure 1

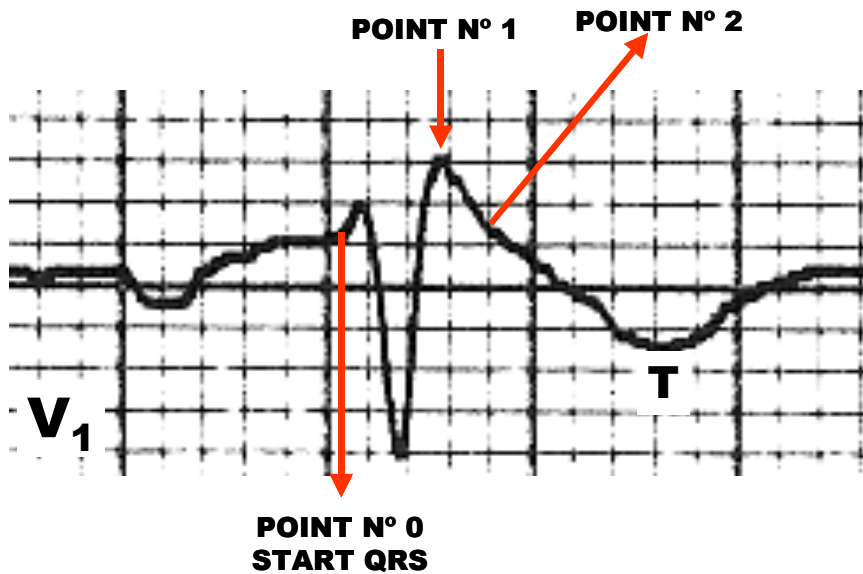
OUTLINE SHOWING JT INTERVAL LIMITS



Thus, when there is branch block (as in the case of Brugada syndrome), the measurement of ventricular repolarization through QTc may be incorrect. In these cases, the measurement of the JT interval ($JT = QT - QRSD$) is more accurate than the QT interval, because it excludes the depolarization that is found prolonged, because the biventricular chamber activates sequentially and not concomitantly as normally⁶. ***This is the reason why it is essential to know accurately the exact point where depolarization ends and repolarization begins.***

To attempt a reply, I have sent figure 2 below, to 12 members of the last Brugada Syndrome Consensus, and to 3 experts in electrocardiography, widely renowned in our field. I obtained 9 opinions: 4 stating that it was point 1; 3 considering that it was point 2; and 2 saying they were uncertain. This reply clearly shows me that this issue is far from being clear at this moment.

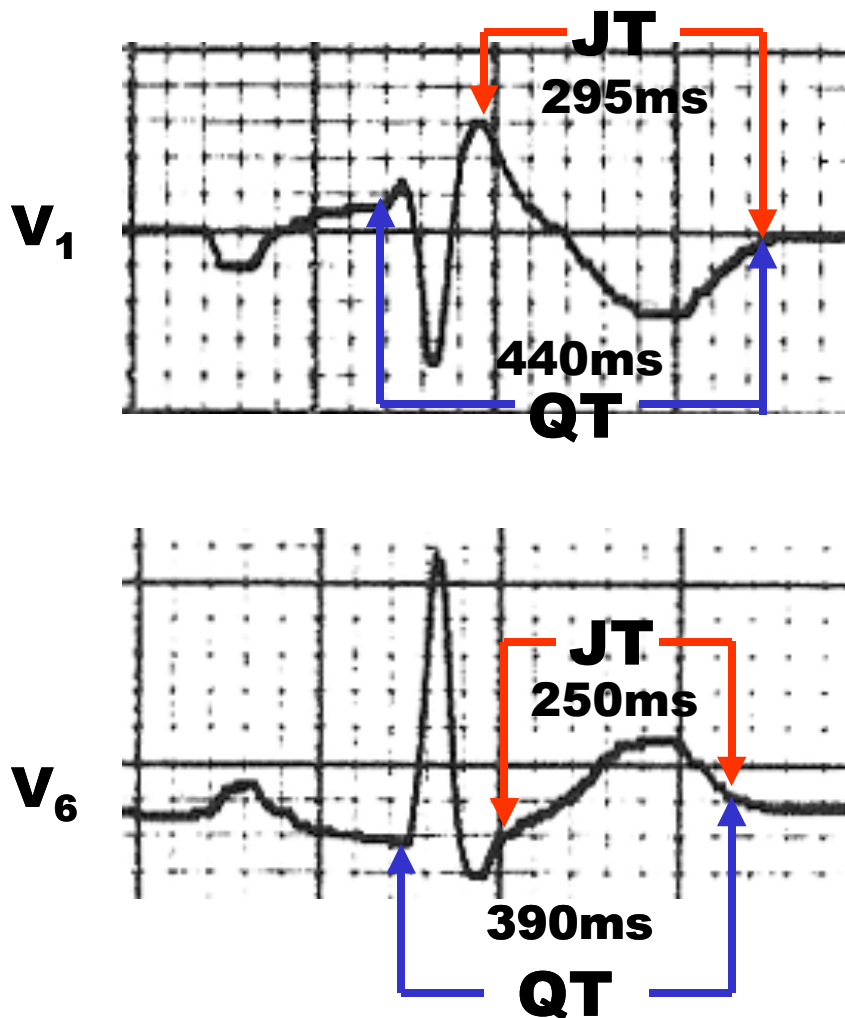
Figure 2



Even so, since by definition the J point (point 1 in the outline in figure 2) corresponds to the end of QRS and the onset of ST,

I made the measurement of the JT interval in precordial leads V₁ to V₃, and I compared it with the QT and JT intervals in V₆ lead with the aim of learning if there was a difference in the patient carrier of Brugada syndrome and on whom an increasing dose of ajmaline was administered.

Figure 3
QT AND J INTERVAL on V₁ AND V₆ IN A PATIENT WITH BRUGADA SYNDROME AFTER AJMALINE INJECTION



Conclusion: In the Brugada syndrome the QT and JT of V₁ lead is longer than V₆ lead.

References

- 1) Marcus FI, Fontaine GH, Guiraudon G, Frank R, Laurenceau JL, Malergue C, Grosgeat Y. Right ventricular dysplasia: a report of 24 adult cases. *Circulation*. 1982; 65:384-398
- 2) D'Onofrio A, Cuomo S, Musto B, Boccalatte A. Right bundle branch block, persistent ST-segment elevation in V1-V3 and sudden cardiac death: always a distinct syndrome? *G Ital Cardiol*. 1995; 25:1171-1175
- 3) Corrado D, Nava A, Buja G, et al. Familial cardiomyopathy underlies syndrome of right bundle branch block, ST segment elevation and sudden death. *J Am Coll Cardiol* 1996, 27: 443-448
- 4) Marcus FI. Electrocardiographic features of inherited diseases that predispose to the development of cardiac arrhythmias, long QT syndrome, arrhythmogenic right ventricular cardiomyopathy/dysplasia, and Brugada syndrome. *J Electrocardiol*. 2000; 33 Suppl:1-10
- 5) Pitzalis MV, Anaclerio M, Iacoviello M, Forleo C, Guida P, Troccoli R, Massari F, Mastropasqua F, Sorrentino S, Manghisi A, Rizzon P. QT-interval prolongation in right precordial leads: an additional

electrocardiographic hallmark of Brugada syndrome. J Am Coll Cardiol. 2003; 42:1632-1637

- 6) Rautaharju PM, Zhang ZM, Prineas R, Heiss G. Assessment of prolonged QT and JT intervals in ventricular conduction defects. Am J Cardiol. 2004; 93:1017-1021

Portuguese version

Na cardiomiopatia/displasia arritmogênica do VD, o complexo QRS pode mostrar bloqueio incompleto do ramo direito (BIRD) em aproximadamente 1/5 dos pacientes (18%) e a forma completa (BCRD) em 15% dos casos. **(Marcus FI, Fontaine GH, Guiraudon G, Frank R, Laurenceau JL, Malergue C, Grosgeat Y. Right ventricular dysplasia: a report of 24 adult cases. Circulation. 1982;65:384-398.)**

O padrão de BIRD ou BCRD eventualmente encontra-se associado a supradesnívelamento do ponto J e do segmento ST convexo para cima de V1

a V3 (coved type) seguido de onda T invertida. Este padrão não pode diferenciar-se com o fenótipo eletrocardiorráfico da síndrome de Brugada. Estes casos são observados nas formas chamadas “minors” ou “concealed” onde apenas métodos sofisticados como a ressonância nuclear magnética consegue diferenciar ambas entidades. **(D'Onofrio A, Cuomo S, Musto B, Boccalatte A. Right bundle branch block, persistent ST-segment elevation in V1-V3 and sudden cardiac death: always a distinct syndrome? G Ital Cardiol. 1995; 25:1171-1175) (Corrado D, Nava A, Buja G, et al. Familial cardiomyopathy underlies syndrome of right bundle branch block, ST segment elevation and sudden death. J Am Coll Cardiol 1996, 27: 443-448.)**

O complexo QRS. pode ser normal, com duração levemente aumentada nas precordiais de V₁ a V₃ (> 110ms) e de menor duração de V₃ a V₆. Por este motivo se ha proposto um protocolo para o registro do ECG perante a suspeita de C/DAVD

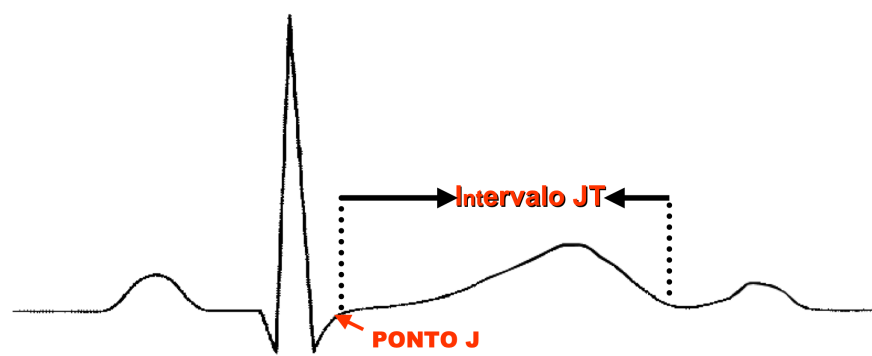
1. O traçado deve ter uma velocidade e amplitude dupla de (50mm/s e 20mm/mV) com o intuito de comparar a duração do QRS de todas as precordiais. E para melhor observar a eventual presença da onda epsilon.

2. Nos membros deverá colocar-se o eletrodo do braço direito sobre o apêndice xifóide o do braço direito sobre o manúbrio do esterno e o da perna esquerda sobre a costela no V₄ ou V₅ com o intuito de melhor observar a onda epsilon.

A relação QRSD de V₁+ V₂+ V₃/ QRSD de V₄+ V₅+ V₆ sendo > do que 1.2 encontra-se em 97% dos casos de DAVD **(Marcus FI. Electrocardiographic features of inherited diseases that predispose to the development of cardiac arrhythmias, long QT syndrome, arrhythmogenic right ventricular cardiomyopathy/dysplasia, and Brugada syndrome. J Electrocardiol. 2000; 33 Suppl:1-10.)** A especificidade deste critério ainda não está completamente estabelecida em pacientes sem este entidade assim como a sensibilidade porém, existe um trabalho mostrando que a síndrome de Brugada também pode apresentar prolongamento na duração do intervalo QT de V₁ a V₃ e conseqüentemente prolongamento do intervalo QTc nas precordiais direitas **(Pitzalis MV, Anaclerio M, Iacoviello M, Forleo C, Guida P, Troccoli R, Massari F, Mastropasqua F, Sorrentino S, Manghisi A, Rizzon P. QT-interval prolongation in right precordial leads: an additional electrocardiographic hallmark of Brugada syndrome. J Am Coll Cardiol. 2003;42:1632-1637.)**. Se o intervalo QT está prolongado apenas de V₁ a V₃ sendo normal de V₄ a V₆ esta claro que este aumento pode ser por prolongamento da despolarização ventricular (complexo QRS) e/ou por prolongamento do ST/T (repolarização). Se admitirmos que na síndrome de Brugada existe algum grau de bloqueio de ramo claramente o prolongamento do intervalo QT deve-se em parte a este. O intervalo QTc constitui a medição clássica da repolarização ventricular, porém, este parâmetro inclui a despolarização ventricular(QRS) portanto representa a chamada sístole elétrica a qual inclui a despolarização (QRS) e repolarização ventricular (ST/T= intervalo JT).

Figura 1

ESQUEMA MOSTRANDO OS LIMITES DO INTERVALO JT

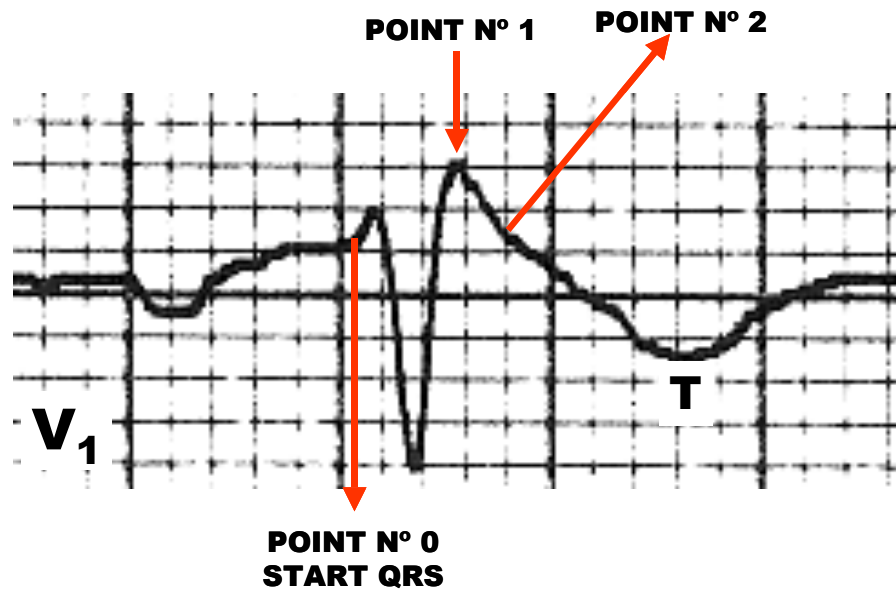


Assim, na existência de bloqueio de ramo (como no caso da síndrome de Brugada) a medição da repolarização ventricular pelo QTc pode ser incorreta. Nestes casos, a medição do intervalo JTc ($JT = QT - QRSD$) possui maior precisão do que o intervalo QTc porque exclui a despolarização que encontra-se alargada porque a câmara bi-ventricular ativou-se seqüencialmente e não concomitantemente como normalmente (**Rautaharju PM, Zhang ZM, Prineas R, Heiss G. Assessment of prolonged QT and JT intervals in ventricular conduction defects. Am J Cardiol. 2004;93:1017-1021**). Este é o motivo pelo qual se faz indispensável conhecer com precisão o ponto exato onde termina a despolarização e onde começa a repolarização.

Para tentar responder enviei a **figura 2** a seguir a 12 integrantes do consenso Brugada e a 3 experts em eletrocardiografia de reconhecido saber de nosso meio. Obtive 9 pareceres: 4 afirmando que era o ponto 1; 3 opinaram que era o ponto 2 e 2 dizendo que não tinham certeza. Esta resposta claramente me diz que a questão está longe de ser clara no momento.

Figura 2

Mesmo assim, como por definição o ponto J (ponto 1 do esquema da figura 2) corresponde ao fim do QRS e começo do segmento ST fiz medição do intervalo JT nas precordiais de V1 a V3 e o comparei com o intervalo QT e



JT em V6 com o intuito de saber se havia diferença no paciente portador da síndrome de Brugada e em qual se administrou ajmalina em dose crescente.

Figura 3

