

Progressive Systemic Sclerosis (PSS) or  
Scleroderma in Young Woman  
Would this Illness Associated with  
Arrhythmogenic Right Ventricular  
Cardiomyopathy/ Dysplasia?

Case from Dr Marcelo Leal MD & André Badran MD

Hospital das Clínicas de Ribeirão Preto no Setor de Terapia Imunológica  
São Paulo – Brasil.

Commentaries Andrés Ricardo Pérez-Riera MD. PhD.

Dear Dr. Andrés Ricardo Pérez-Riera,

This is a patient CURRENTLY admitted in the Hospital das Clínicas de Ribeirão Preto, in the Area of Immunologic Therapy, being evaluated for the chance to undergo a BONE MARROW TRANSPLANT, aiming at a better control of systemic sclerosis.

LAB, 18 years old, white, female, college student, born and coming from Porto Alegre – RS. Brazil.

Patient without history of previous morbidity. Three years ago she started with manifestations of Systemic Sclerosis, initially with Raynaud's phenomenon, calcinosis, skin sclerosis.

She started treatment with methotrexate and prednisone; in the meantime she evolved with an unsatisfactory response with ulcers in the finger tips and articular retraction. Six months ago she started with mycophenolate mofetil, and to attempt to improve the symptoms of ulcers in the fingers. Three months ago she started with bosentan. There was no evidence of pulmonary hypertension (PAH). Commentaries: *This drug is a dual endothelin receptor antagonist used in the treatment of PAH. Bosentan is a competitive antagonist of endothelin-1 at the endothelin-A (ET-A) and endothelin-B (ET-B) receptors. Under normal conditions, endothelin-1 binding of ET-A or ET-B receptors causes pulmonary vasoconstriction and in others territories. In 2007, bosentan was approved in the European Union also for reducing the number of new digital ulcers in patients with systemic sclerosis and ongoing digital ulcer disease.*

*Bosentan is a competitive antagonist of endothelin-1 at the endothelin-A (ET-A) and endothelin-B (ET-B) receptors. Under normal conditions, endothelin-1 binding of ET-A or ET-B receptors causes pulmonary vasoconstriction and in others territories. In 2007, bosentan was approved in the European Union also for reducing the number of new digital ulcers in patients with systemic sclerosis and ongoing digital ulcer disease.*

She tells that from the onset of bosentan she started presenting frequent tachycardial palpitations (1-2 per week). They generally occurred during meals, and did not cause her to interrupt them, not associated to dizziness or sweat, which were solved spontaneously after 5-30 min.

A Holter was made on her, which did not show any complex arrhythmias (May 4th, 2011). The patient states that she did not present the mentioned arrhythmia on the day she underwent the Holter. Carvedilol was prescribed for her, with no relief of symptoms (See annex 1).

On May 16th, 2011, she presented new palpitations, similar to those described, with a duration >6 hours, which led her to seek medical attention – to be admitted without criteria for instability. BP=100x60, while after amiodarone was started, she presented symptomatic hypotension (the first episode to that moment). See ECG in annex 2.

She underwent electric cardioversion with return to sinus rhythm. After such event, Cardiovascular magnetic resonance (CMR) was conducted, compatible with Arrhythmogenic Right Ventricular Dysplasia/ Cardiomyopathy( ARVD/C) (RV dilatation, annex 3). CRM has been already successfully used in the evaluation of vasculitides, systemic lupus erythematosus, myositis, and scleroderma. However, further studies are needed to evaluate its usefulness as a diagnostic and monitoring tool of cardiovascular involvement in rheumatic patients<sup>1</sup>.

An implantable cardioverter-defibrillator (ICD) was implanted on June 3rd, 2011. Medication in use:

- Amiodarone 200 mg 12/12 hs;
- Metoprolol 50 mg 12/12 hs;
- Micophenolate mophetyl 150 mg 12/12 hs;
- Prednisone 10 mg 12/12 hs;
- Bosentane 125 mg 12/12 hs.

Echocardiogram (performed in June 8th, 2011): LA=38; LVEDD: 43; LVEF: 70%; marked dilatation of right chambers. RVSD with marked depression, mild mitral and tricuspid insufficiency.

Indirect signs of significant pulmonary artery hypertension.

Intracavitary pressure contrast will be carried out.

Normal spirometry.

Our opinion was requested on a possible contraindication for bone marrow transplant as a therapy for systemic sclerosis with significant diffuse involvement. In the transplant, high doses of cyclophosphamide (200 mg/Kg) will be used; while the cardiotoxicity of which requires a prior evaluation.

1. **Mavrogeni S, Vassilopoulos D. Is There a Place for Cardiovascular Magnetic Resonance Imaging in the Evaluation of Cardiovascular Involvement in Rheumatic Diseases? Semin Arthritis Rheum. 2011 Jun 2. [Epub ahead of print]**

# Portuguese version

Trata-se de paciente internada atualmente no Hospital das Clínicas de Ribeirão Preto no Setor de Terapia Imunológica em avaliação da possibilidade de realizar transplante de medula óssea no intuito de melhor controle de esclerose sistêmica ou esclerodermia.

LAB, 18 anos, branca, feminina, universitária, natural e procedente de Porto Alegre-RS sem antecedentes mórbidos pregressos, iniciou há 3 anos manifestações de Esclerose Sistêmica, inicialmente com fenômeno de Raynaud, calcinose, esclerose cutânea.

Iniciada terapia com metotrexato e prednisona, entretanto evolui com resposta insatisfatória com úlceras nas polpas digitais e retrações articulares.

Iniciado há 6 meses micofenolato mofetil na tentativa de melhorar quadro de úlceras de extremidades. Há 3 meses associado bosentana (não possuía evidencia de hipertensão pulmonar). Não havia evidências de hipertensão pulmonar. Esta droga é um antagonista competitivo dual do receptor da endotelina-1 o endotelina-A(ET-A) e endotelina B(ET-B) empregado na hipertensão pulmonar. Em condições normais a endotelina-1 se une aos receptores da ET-A ou ET-B causando vasoconstrição pulmonar e em outros territórios. Desde o início desta droga passou a apresentar palpitações e acelerações cardíacas freqüentes (1-2X/semana que ocorriam durante as refeições geralmente, não motivavam interrupção das mesmas, não associadas à tontura ou sudorese, e com resolução espontânea após 5-30min. Chegou a realizar Holter que não evidenciou arritmias complexas (04/05/2011). Paciente refere que não apresentou a referida arritmia no dia em que estava com o Holter. Prescrito carvedilol sem melhora do quadro. **(Vide anexo 1).**

Em 16/05/2011 novo quadro de palpitação, semelhante às descritas, entretanto duração >6 horas, o que motivou procurar assistência médica - admissão sem critérios de instabilidade, PA=100x60. Após o início de amiodarona apresentou hipotensão sintomática (o primeiro episódio até então) - **Vide ECG anexo 2** - sendo realizada cardioversão elétrica com retorno para ritmo sinusal.

Após o evento foi realizado estudo de Ressonância nuclear magnética cardíaca que resultou compatível com displasia arritmogênica de ventrículo direito (**dilatação de VD anexo 3**).

Em 03/06/2011 decide-se por a implantação de um cardiodesfibrilador. Uso concomitante de amiodarona 200mg 12/12h; metoprolol 50mg 12/12h; micofenolato mofetil 1500mg 12/12h; prednisona 10mg 12/12h; bosentana 125mg 12/12h.

Ecocardiograma (08/06/2011): AE=38; DDFVE: 43; , FEVE: 70%, dilatação acentuada câmaras direitas;DSVD deprimido acentuado, Insuficiência mitral e tricúspide leves. Sinais indiretos de hipertensão arterial pulmonar significativa. Realizará aferição intra-cavitária de pressões. Espirometria normal. Foi solicitado parecer sobre possível contra-indicação à realização de transplante de medula óssea (TMO)– terapia para esclerose sistêmica com acometimento difuso importante. Na TMO será utilizado altas doses de ciclofosfamida (200mg/Kg) cuja cardiotoxicidade esperada exige avaliação prévia.

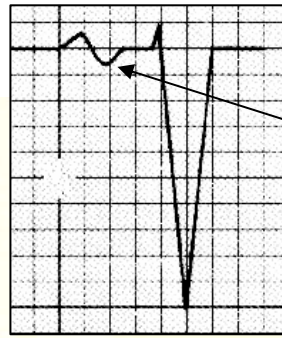
Envio informação complementar caso necessário.

Grato pela atenção,

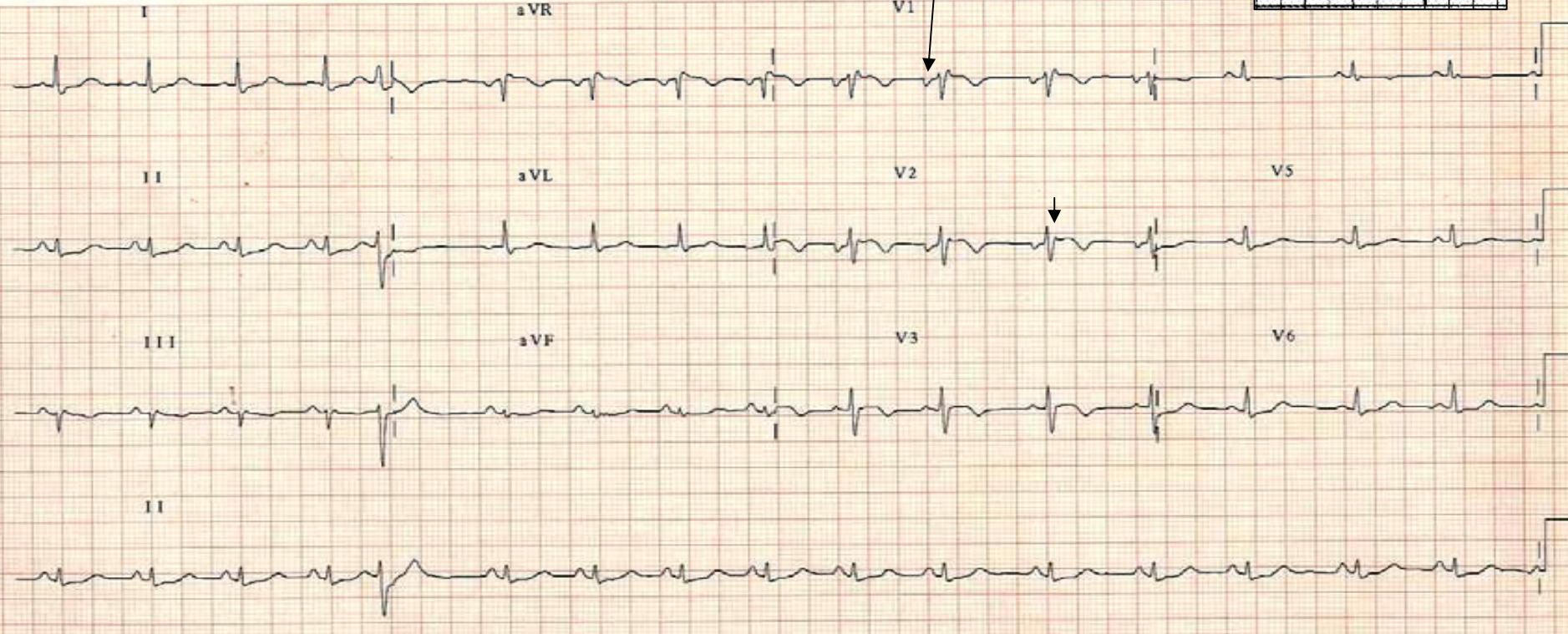
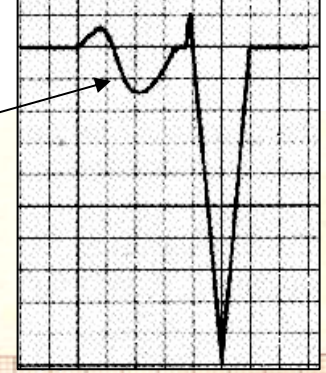
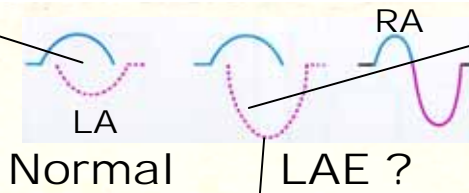
R3 André Badran

Rate	97
PR	143
QRSD	92
QT	316
QTc	401

--Axis--	
P	65
QRS	7
T	14



P-wave with final deep and slow component V<sub>1</sub>



**Left Atrial Enlargement (LAE)?**

**Incomplete RBBB: triphasic pattern in V<sub>1</sub>, QRSD < 120ms, broad final r in aVR, wide S wave in I. Incomplete RBBB is observed in ≈18% of cases if ARVD. May be QRS complexes with low voltage from V<sub>4</sub> to V<sub>6</sub>**

**Isolated PVC**

**Doubtful presence of Epsilon wave in V<sub>2</sub> lead on beginning of ST segment near J point? (arrow)**

**Negative T wave from V<sub>1</sub> to V<sub>3</sub>** In absence of CRBBB in patients >12 years old, negative T wave from V<sub>1</sub> to V<sub>3</sub> is a sign with great value for diagnosis of ARVC/D.

# ECG FEATURES IN ARVC/D

Approximately 90% of patients carriers of ARVC/D present ECG anomalies.

ARVC/D diagnosis may be excluded if ECG is normal 6 years after the VT episode<sup>1</sup>.

Rhythm: sinus rhythm; however, there is a report of the case of a male patient, 60 years old, carrier of ARVC/D, who developed sick sinus syndrome (SA node with recovery time of 6113 ms). The authors explained the cause of atrial arrhythmia by gradual reposition of right atrial myocytes by fatty tissue<sup>2</sup>.

P wave: there is a description of giant P wave associated to QRS complex of low amplitude, in patients carriers of ARVD<sup>3</sup>. Rest ECG with RVE and significant increase of QRS complex dispersion of 47.1+/-18.9 ms is observed in cases of heart failure.

Batrial enlargement and reduction of QRS dispersion of 33.0+/-23.1 ms are observed in cases of biventricular heart failure<sup>4</sup>.

PR interval: PR interval prolongation has been described<sup>5</sup>. Prolonged PR interval is a predictor of adverse results in patients with ARVC/D.

Abnormalities in depolarization and repolarization in ECG are common in cases of ARVC/D.

Abnormalities in depolarization/conduction in ECG

Prolongation of QRS complex (110 ms) located in precordial leads ( $V_1$ - $V_3$ ) in adult patients in absence of CRBBB (prolonged S wave upstroke) from  $V_1$  to  $V_3$ , 55 ms is the most prevalent characteristic of ECG (95% of cases) and are correlated with the severity of the disease and induction of VT in programmed ventricular stimulation (PVS).

1. Jaoude SA, et al. Eur Heart J. 1996; 17:1717-1122.
2. Balderramo DC, et al. Medicina (B Aires). 2004; 64: 439-441.
3. Martini B, et al. Clin Cardiol. 1990;13:143-145..
4. Peters S, et al. Int J Cardiol. 1999; 71:251-256.
5. Wisten A et al. J Intern Med. 2004; 255:213-220.

Prolongation in S wave duration in anteroseptal leads of ECG ( $V_1$ - $V_3$ ) is a significant marker for ARVC/D diagnosis in patients.

Automated medication in S wave duration (Marquette Mac12, Mac15 or MacVue) in the surface of ECG leads  $V_1$ - $V_3$ , was conducted in 141 healthy children between 5 and 15 years old ( $9.6 \pm 2.7$  years old) and they were compared to 27 pediatric patients carriers of ARVC/D.

Available ECGs were assessed in the initial and final phase in patients carriers of ARVC/D, obtained respectively at ages  $11.6 \pm 3.9$  and  $14.3 \pm 3.4$  years old.

ARVC/D was diagnosed in children with VT and CLBBB morphology, using diagnostic criteria already published for adult patients, carriers of ARVC/D or who had typical findings in biopsy.

The result from the addition of QRS complexes duration from  $V_1 + V_2 + V_3$  when divided by the addition of the duration of QRS complexes from  $V_4$  through  $V_6$  ( $V_4 + V_5 + V_6$ ). When this equation results in a value  $\geq$  than 1.2, it constitutes a sign of high sensitivity for ARVC/D diagnosis, since it is present in 98% of patients carriers of this cardiomyopathy.

Peter et al<sup>1</sup> showed that the sign is not specific of ARVC/D because it has been observed also in Brugada syndrome. This longer duration of QRS complexes at the right in precordial leads is due to the so-called right parietal block characteristic of ARVC/D.

Possibly QRS complexes may be of low voltage, which is observed when the disease is diffuse or there is participation with the conduction system. In ARVC/D there is evidence of peripheral right branch blocks, as the author Guy Fontaine<sup>2</sup> proved some time ago: topographic IRBBB or CRBBB occurs in the fascicular portion of the right branch and/or in the right ventricle free wall after the trunk of the branch splits at the base of the papillary muscle of the tricuspid valve and, this mechanism seems to be due to the participation of dysplasia in the free wall, in RVOT, in RVIT or in the apical region (Triangle of Dysplasia), area where we find dysplasia.

1) Peter S et al. Ann Noninvasive Electrocardiol 2003;8:238-245.

2) Fontaine G, et al. Arch Mal Coeur Vaiss. 1984; 77:872-879.



CRBBB pattern <sup>1;2;3</sup> is observed in 15% of cases,

IRBBB or right end conduction delay is present in 18% of cases.

Epsilon or Fontaine waves ( $\epsilon$ ): (30%) are late potentials or low amplitude and short duration oscillations near the J point (before or immediately after): major criterion: if the addition of QRS complexes duration in  $V_1 + V_2 + V_3 / V_4 + V_5 + V_6$  is  $\geq$  than 1.2;

Increase in QRS complex duration ( $>110^\circ$ ) in V1, V2 and V3, in absence of CRBBB: parietal block. Major criterion: if the addition of QRS complexes duration in  $V_1 + V_2 + V_3 / V_4 + V_5 + V_6$  is  $\geq$  than 1.2;

Prolongation in the ascending ramp of S wave from V1 to V3, in absence of CRBBB (prolonged S wave upstroke): distance from the nadir of S wave up to the isoelectric line  $\geq 55$  ms<sup>4</sup>.

Late potentials in high resolution ECG(ECG-AR).






Low voltage QRS complexes in cases where the disease is more diffuse or with involvement of conduction system.

### **Alterations of repolarization.**

ST segment elevation with different morphologies present in 25% of cases.

Inverted T wave in right precordial leads (V1 and V2)  $>12$  years old, in absence of CRBBB.

1. McKenna WJ, et al. Br Heart J 1994;71:215-218.
2. Fontaine G, et al. Annu Rev Med 1999;50:17-35
3. Marcus FI. e col. Circulation, 1982 65:384
4. Buffo Sequeira I, et al. Utility of ECG precordial S-wave duration in diagnosis of Arrhythmogenic Right Ventricular Dysplasia/Cardiomyopathy (ARVD/C) in pediatric patients canadian. Cardiovascular Congress 2003 Abstrac 504.



3

***"Fontaine discovered and named the epsilon waves. He chose the epsilon because it follows delta in the Greek alphabet and is the mathematical symbol for smallness"***<sup>1</sup>.

**Intrinsic features:** they are small notches or oscillations in variable quantities (1, 2, 3 or more).

**Location:** at the end of QRS in the J point or onset of ST segment (there is no consensus about this).

**Leads:** observed in right precordial leads; however Dr. Li Zhang et al, found the  $\epsilon$  wave in the leads of the frontal plane, especially in inferior leads.

**Frequency in ARVC/D:** approximately 15-30% of cases in 12-lead ECG. This percentage increases if we use the ECG with the modified protocol.

**Value of criterion:** considered to be a major criterion for diagnosis by the Task Force for ARVC/D diagnosis<sup>2;3</sup>.

**High resolution ECG:** observed more frequently with this method.

**Pathognomonic character:** in spite of the characteristics in ARVD, they are not pathognomonic, since they have been described in other diseases associated with myocardial damage: RV infarction, inferior or dorsal<sup>4</sup>, sarcoidosis<sup>5</sup>, sickle cell anemia, and Brugada syndrome etc.

**Meaning:** late posterior potentials (PP) that occur in the RV free wall in patients with ARVC/D.


1. Hurst JW. Circulation 1998; 98, 1837-1942
2. McKenna WJ, et al. Br Heart J 1994;71:215-218.
3. Fontaine G, et al. Annu Rev Med 1999;50:17-35
4. Zorio E, et al. Pacing Clin Electrophysiol. 2005; 28:245-247.
5. Santucci PA, et al. J Cardiovasc Electrophysiol. 2004; 15:1091-1094.

.


# POLARITY OF T WAVE FROM V1 TO V3 IN ARVC/D



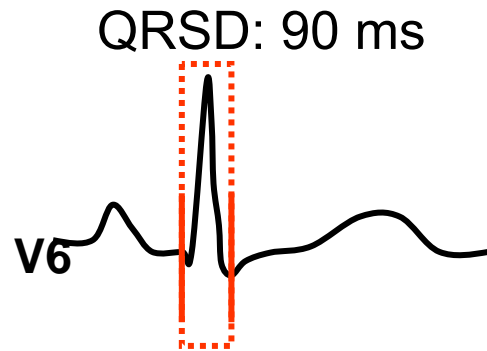
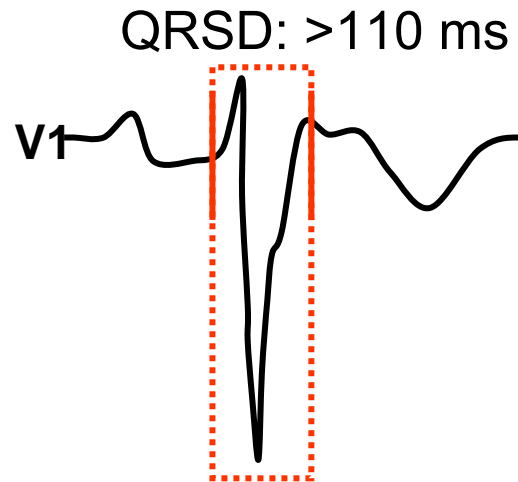
In absence of CRBBB in patients >12 years old, negative T wave from V1 to V3 is a sign with great value for diagnosis.



In normal, young patients, there is usually positive T polarity in V1; however, it may flatten and nearly always has a positive polarity in V2.



In symptomatic patients carriers of ARVCD, the ECG generally shows T wave inversion in V1 and V2, which may reach up to V61.



50 mm/s 20 mm/mV

QRSD of V1+V2+V3 / V4, V5 and V6 or  $\geq 1.2$  in approximately 65% of cases. QRS prolongation located in right precordial leads<sup>1</sup>.

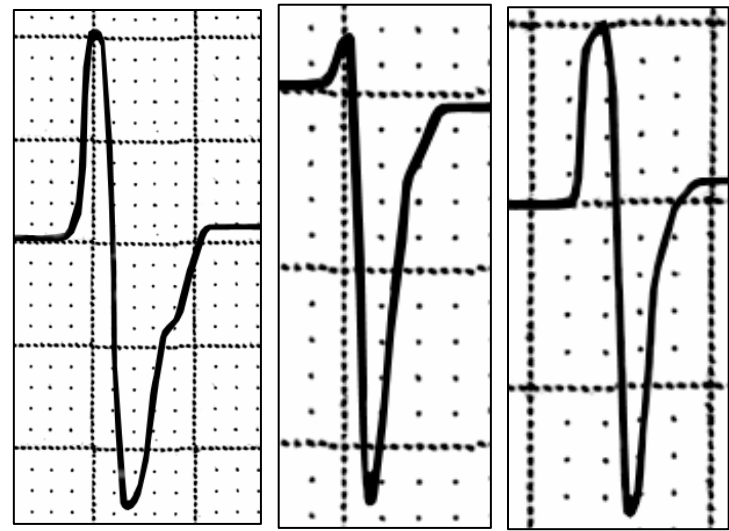
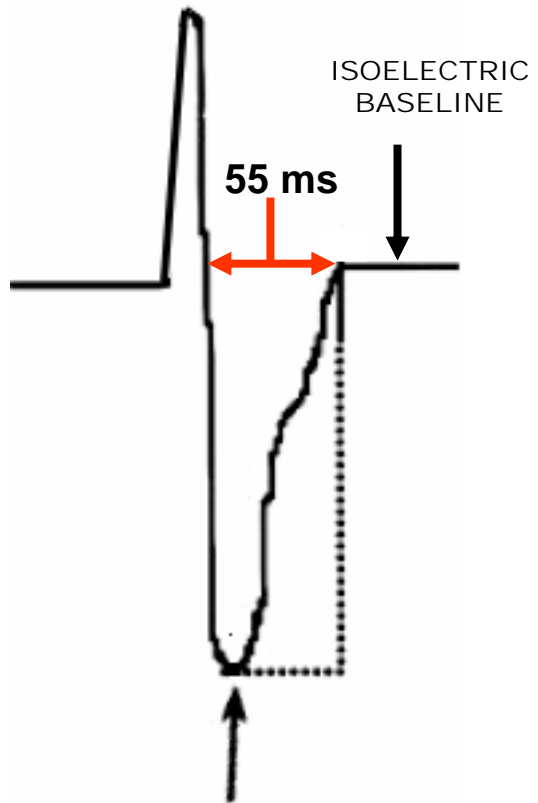
QRSD  $\geq$  from V1 to V3 with 91% sensitivity, 90% specificity that predicts VT in patients carriers of ARVD<sup>2</sup>.

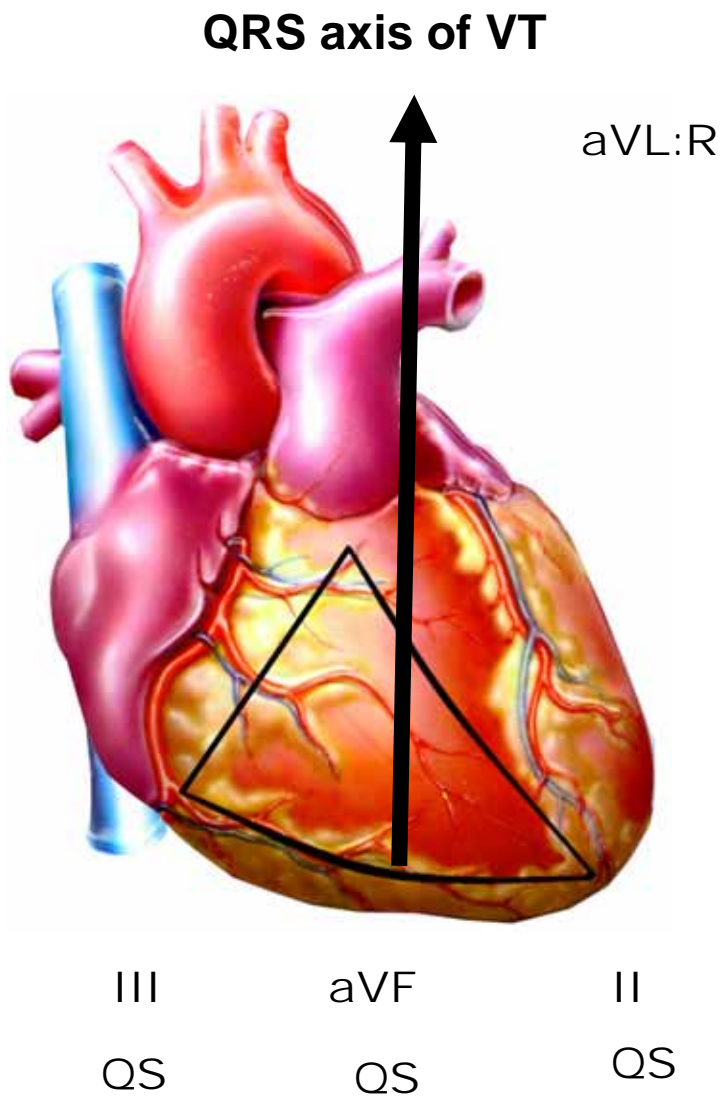
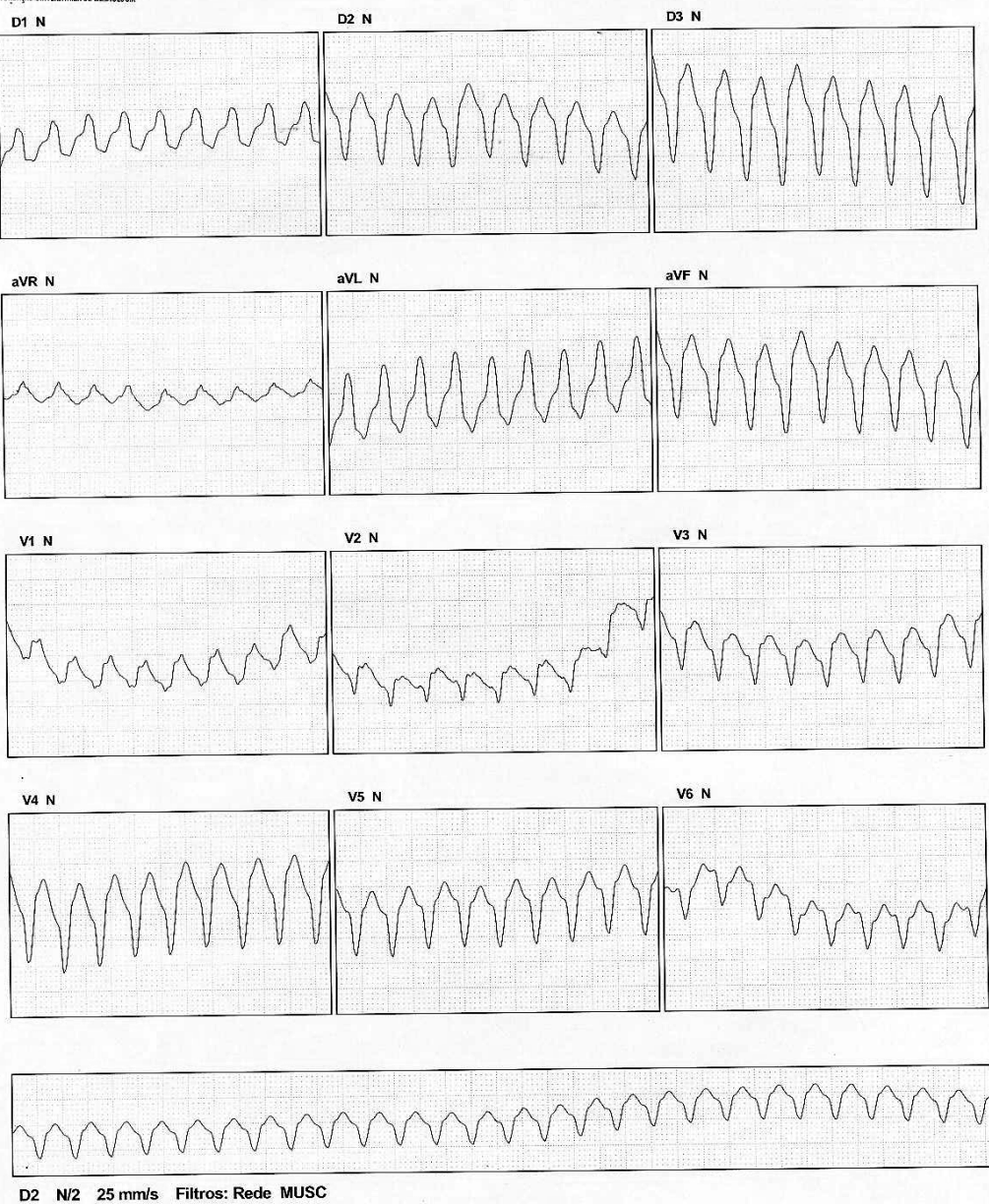
Brugada syndrome may display prolongation in QT interval duration from V1 to V3 and subsequently prolongation of QTc interval in right precordial leads<sup>3</sup>.

1) Nasir K, et al. Circulation. 2004; 110:1527-1534.

2) Nasir K, et al. Pacing Clin Electrophysiol. 2003; 26: 1955-1960.

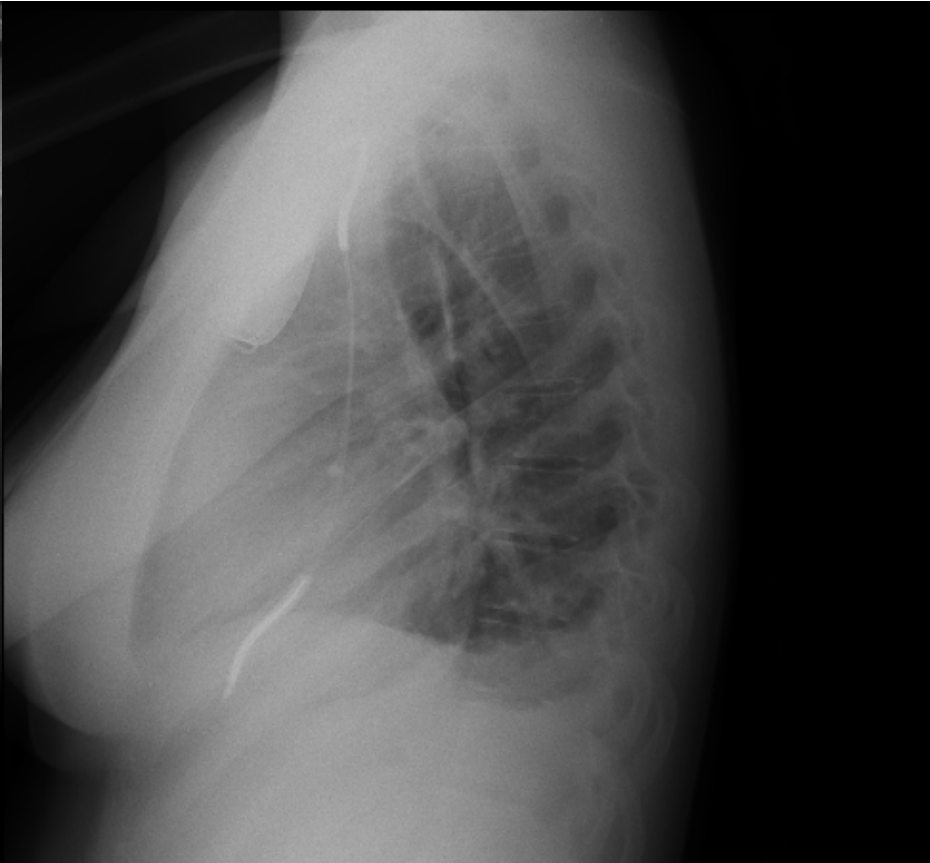
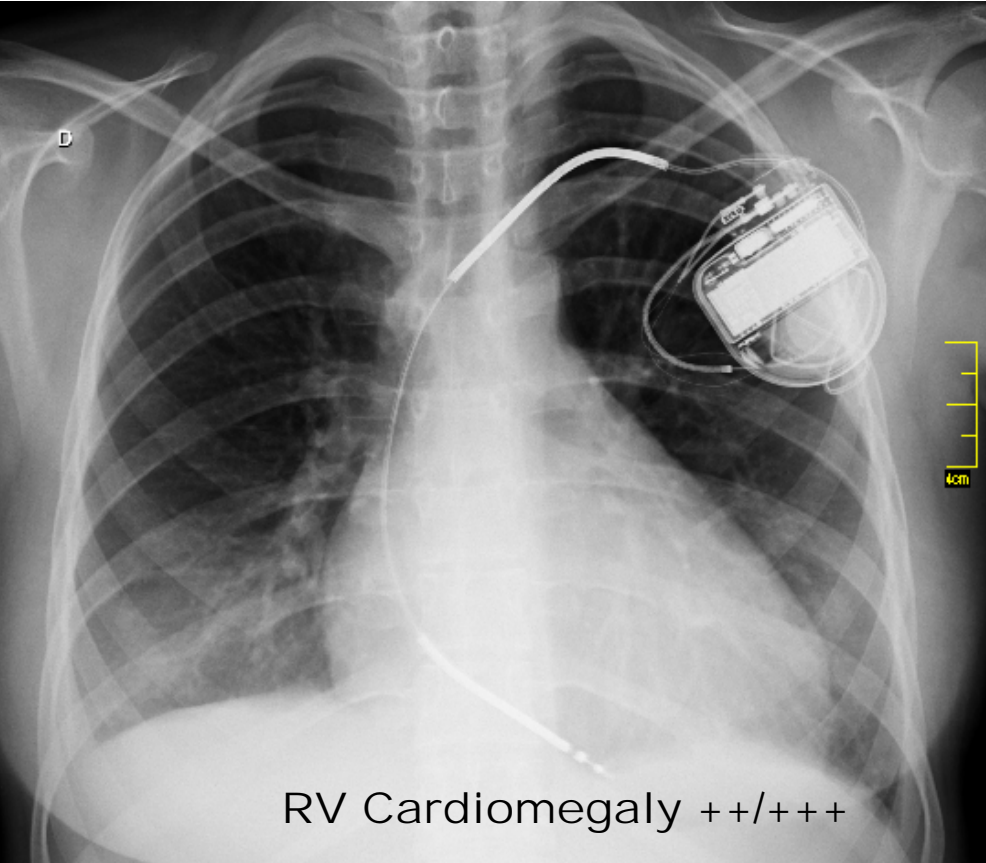
3) Pitzalis MV, et al. J Am Coll Cardiol. 2003; 42:1632-1637.





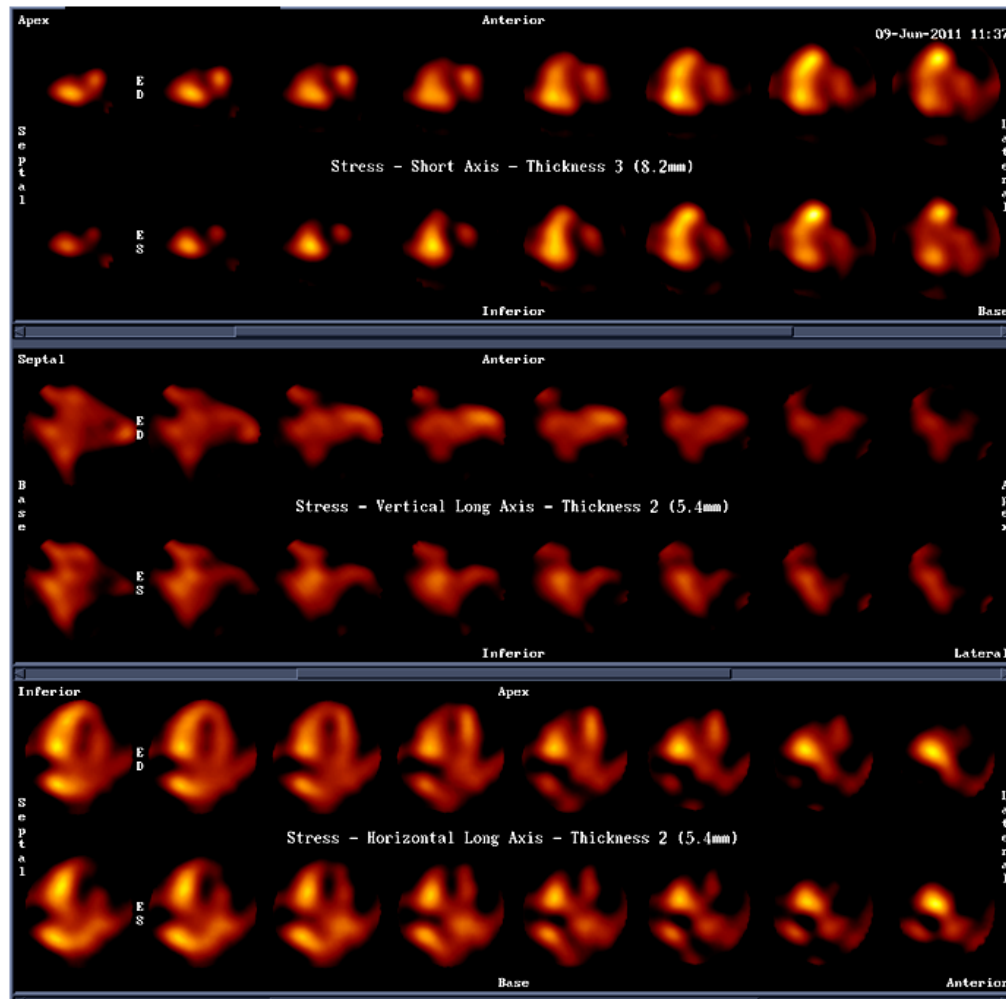
Sustained monomorphic ventricular tachycardia (S-MVT) with CLBBB morphology and SAQRS, with extreme shift to the left (negative QRS complexes in inferior leads and positive in aVL and aVR), which points out origin in the inferior wall of the Right Ventricle.

Implantable Cardioverter-defibrillator (ICD) was implanted on June 3rd, 2011.





# VENTRICULOGRAPHY



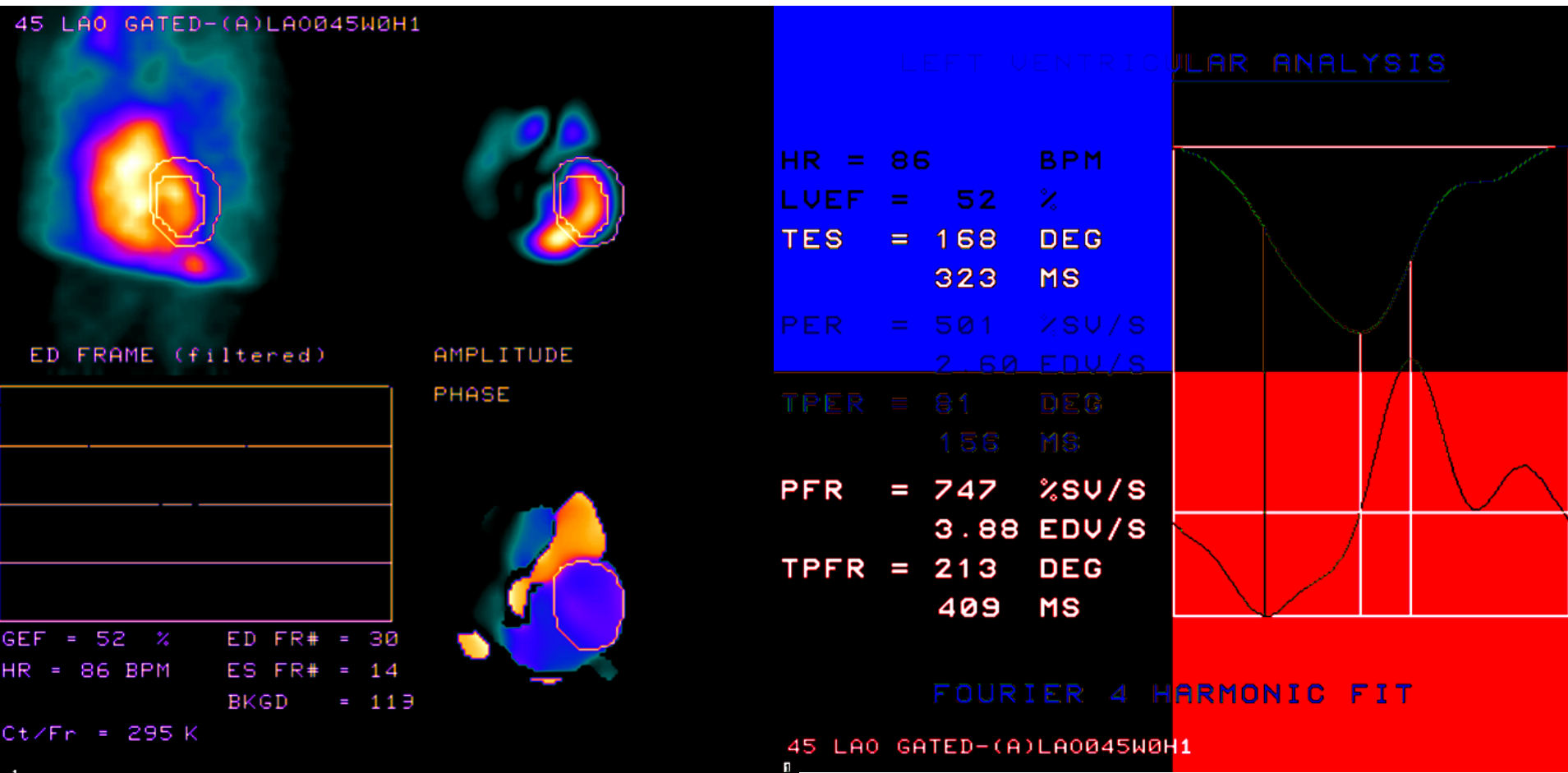
**Normal left ventricular stroke volume with LV preserved performance. Septum shows disynergic motility. Right ventricle shows marked increase in right ventricular volume and severe depression of the overall systolic performance. Diffuse hypokinesia**

# VENTRICULOGRAPHY

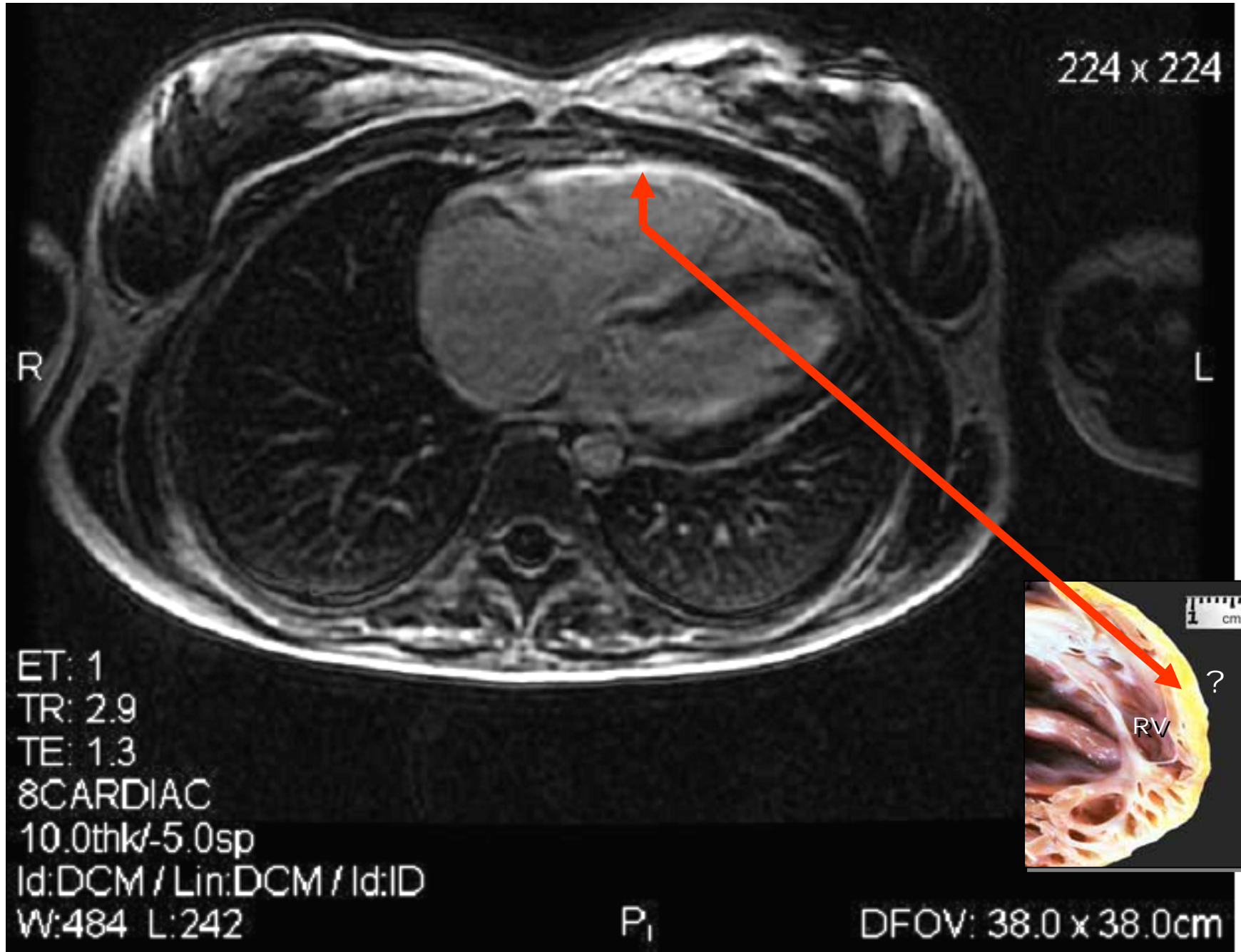
## 1/3 Image

# VENTRICULOGRAPHY

## 2/3 Image



# Cardiovascular Magnetic Resonance (CMR or MRI)



Dear Andreas,

This is a tough case. I will hesitate to diagnose ARVD. If I understood well she has only one major and one minor criteria according to the Task Force? Around 20 % of deaths are attributed directly to cardiac causes, mainly heart failure and arrhythmias, in patients with sclerosis. Is there any family history of cardiac disease? A myocardial biopsy and genotyping could help. If ARVD is rule out bone marrow transplant may help to lessen the myocardial damage. Anyway, the prognosis appears so bad that any available cure should be tempted.

I will ask my colleagues if they have had a similar case.

Kind regards,

***Prof Philippe Chevalier da França-Lyon*** [philippe.chevalier@chu-lyon.fr](mailto:philippe.chevalier@chu-lyon.fr)

# Diagnosis of Arrhythmogenic Right Ventricular Cardiomyopathy/Dysplasia

## Proposed Modification of the Task Force Criteria

---

### Original Task Force Criteria

### Revised Task Force Criteria

---

#### I. Global or regional dysfunction and structural alterations\*

##### Major

- Severe dilatation and reduction of RV ejection fraction with no (or only mild) LV impairment
- Localized RV aneurysms (akinetic or dyskinetic areas with diastolic bulging)
- Severe segmental dilatation of the RV

##### By 2D echo:

- Regional RV akinesia, dyskinesia, or aneurysm
- *and* 1 of the following (end diastole):
  - PLAX RVOT  $\geq 32$  mm (corrected for body size [PLAX/BSA]  $\geq 19$  mm/m<sup>2</sup>)
  - PSAX RVOT  $\geq 36$  mm (corrected for body size [PSAX/BSA]  $\geq 21$  mm/m<sup>2</sup>)
  - *or* fractional area change  $\leq 33\%$

##### By MRI:

- Regional RV akinesia or dyskinesia or dyssynchronous RV contraction
- *and* 1 of the following:
  - Ratio of RV end-diastolic volume to BSA  $\geq 110$  mL/m<sup>2</sup> (male) or  $\geq 100$  mL/m<sup>2</sup> (female)
  - *or* RV ejection fraction  $\leq 40\%$

##### By RV angiography:

- Regional RV akinesia, dyskinesia, or aneurysm

##### Minor

- Mild global RV dilatation and/or ejection fraction reduction with normal LV
- Mild segmental dilatation of the RV
- Regional RV hypokinesia

##### By 2D echo:

- Regional RV akinesia or dyskinesia
- *and* 1 of the following (end diastole):
  - PLAX RVOT  $\geq 29$  to  $<32$  mm (corrected for body size [PLAX/BSA]  $\geq 16$  to  $<19$  mm/m<sup>2</sup>)
  - PSAX RVOT  $\geq 32$  to  $<36$  mm (corrected for body size [PSAX/BSA]  $\geq 18$  to  $<21$  mm/m<sup>2</sup>)
  - *or* fractional area change  $>33\%$  to  $\leq 40\%$

##### By MRI:

- Regional RV akinesia or dyskinesia or dyssynchronous RV contraction
- *and* 1 of the following:
  - Ratio of RV end-diastolic volume to BSA  $\geq 100$  to  $<110$  mL/m<sup>2</sup> (male) or  $\geq 90$  to  $<100$  mL/m<sup>2</sup> (female)
  - *or* RV ejection fraction  $>40\%$  to  $\leq 45\%$

1. Marcus FI, McKenna WJ, Sherrill D, Basso C, Bauce B, Bluemke DA, Calkins H, Corrado D, Cox MG, Daubert JP, Fontaine G, Gear K, Hauer R, Nava A, Picard MH, Protonotarios N, Saffitz JE, Sanborn DM, Steinberg JS, Tandri H, Thiene G, Towbin JA, Tsatsopoulou A, Wichter T, Zareba W. Diagnosis of arrhythmogenic right ventricular cardiomyopathy/dysplasia: proposed modification of the task force criteria. *Circulation*. 2010 Apr 6;121:1533-1541.

Original Task Force Criteria

Revised Task Force Criteria

II. Tissue characterization of wall

Major

- Fibrofatty replacement of myocardium on endomyocardial biopsy

- Residual myocytes <60% by morphometric analysis (or <50% if ? estimated), with fibrous replacement of the RV free wall myocardium in  $\geq 1$  sample, with or without fatty replacement of tissue on endomyocardial biopsy

Minor

- Residual myocytes 60% to 75% by morphometric analysis (or 50% to 65% if estimated), with fibrous replacement of the RV free wall myocardium in  $\geq 1$  sample, with or without fatty replacement of tissue on endomyocardial biopsy

III. Repolarization abnormalities

Major

- Inverted T waves in right precordial leads ( $V_1$ ,  $V_2$ , and  $V_3$ ) or beyond in individuals >14 years of age (in the absence of complete right bundle-branch block QRS  $\geq 120$  ms) +

Minor

- Inverted T waves in right precordial leads ( $V_2$  and  $V_3$ ) (people age >12 years, in absence of right bundle-branch block)

- Inverted T waves in leads  $V_1$  and  $V_2$  in individuals >14 years of age (in the absence of complete right bundle-branch block) or in  $V_4$ ,  $V_5$ , or  $V_6$
- Inverted T waves in leads  $V_1$ ,  $V_2$ ,  $V_3$ , and  $V_4$  in individuals >14 years of age in the presence of complete right bundle-branch block

Legenda

□ ausente

? Não avaliado

+ presente

## Original Task Force Criteria

## Revised Task Force Criteria

## IV. Depolarization/conduction abnormalities

## Major

- Epsilon waves or localized prolongation (>110 ms) of the QRS complex in right precordial leads (V<sub>1</sub> to V<sub>3</sub>)

- Epsilon wave (reproducible low-amplitude signals between end of QRS complex to onset of the T wave) in the right precordial leads (V<sub>1</sub> to V<sub>3</sub>)

## Minor

- Late potentials (SAECG)

- Late potentials by SAECG in  $\geq 1$  of 3 parameters in the absence of a QRS duration of  $\geq 110$  ms on the standard ECG
- Filtered QRS duration (fQRS)  $\geq 114$  ms
- Duration of terminal QRS <40  $\mu$ V (low-amplitude signal duration)  $\geq 38$  ms
- Root-mean-square voltage of terminal 40 ms  $\leq 20$   $\mu$ V
- Terminal activation duration of QRS  $\geq 55$  ms measured from the nadir of the S wave to the end of the QRS, including R', in V<sub>1</sub>, V<sub>2</sub>, or V<sub>3</sub>, in the absence of complete right bundle-branch block

## V. Arrhythmias

## Major

- Nonsustained or sustained ventricular tachycardia of left bundle-branch morphology with superior axis (negative or indeterminate QRS in leads II, III, and aVF and positive in lead aVL)

## Minor

- Left bundle-branch block–type ventricular tachycardia (sustained and nonsustained) (ECG, Holter, exercise)
- Frequent ventricular extrasystoles (>1000 per 24 hours) (Holter)

- Nonsustained or sustained ventricular tachycardia of RV outflow configuration, left bundle-branch block morphology with inferior axis (positive QRS in leads II, III, and aVF and negative in lead aVL) or of unknown axis
- >500 ventricular extrasystoles per 24 hours (Holter)

## VI. Family history

### Major

- Familial disease confirmed at necropsy or surgery
- ARVC/D confirmed in a first-degree relative who meets current Task Force criteria
- ARVC/D confirmed pathologically at autopsy or surgery in a first-degree relative
- Identification of a pathogenic mutation† categorized as associated or probably associated with ARVC/D in the patient under evaluation

### Minor

- Family history of premature sudden death (<35 years of age) due to suspected ARVC/D
- History of ARVC/D in a first-degree relative in whom it is not possible or practical to determine whether the family member meets current Task Force criteria
- Familial history (clinical diagnosis based on present criteria)
- Premature sudden death (<35 years of age) due to suspected ARVC/D in a first-degree relative
- ARVC/D confirmed pathologically or by current Task Force Criteria in second-degree relative



Global or regional dysfunction and structural alterations

II. Tissue characterization of wall

III. Repolarization abnormalities

IV. Depolarization/conduction abnormalities

V. Arrhythmias

VI. Family history

» Definite diagnosis:  
2 major or  
1 major and 2 minor criteria or  
4 minor from different categories;

» Borderline:  
1 major and 1 minor or  
3 minor criteria from different categories;

» Possible:  
1 major or  
2 minor criteria from different categories

# Colleagues commentaries

I don't understand why they started bosentan in this patient when there is "no evidence "of pulmonary hypertension. The bosentan may cause fluid retention and increase RV preload. I suspect BM transplant for scleroderma is investigational and if she has significant RV failure due to ARVC with arrhythmias, BM transplant in this patient will likely be associated with higher risk for treatment related mortality.

From **Dr. Teresa DeMarco of our transplant service**

On 6/12/11 12:06 PM, "Scheinman, Melvin" <scheinman@medicine.ucsf.edu  
wrote:

This is out of my league.Do you have any thing rationale to say that may help?

I am not aware of a case of scleroderma and associated ARVC. She has a RV dilated cardiomyopathy with VT arising from the body of the RV. She also has pulmonary hypertension that could in part be responsible for the RV enlargement.

MRI frequently overinterprets the diagnosis of ARVC. I prefer to see an additional imaging modality to confirm the MRI findings. You may wish to consider RV angio with septal and free wall biopsy. Frank Marcus MD Sarver Heart Center, University of Arizona, Tucson, Arizona, USA. [fmarcus@u.arizona.edu](mailto:fmarcus@u.arizona.edu)

---

Yo no conozco un solo caso de esclerodermia asociado DAVD. La joven tiene una miocardiopatía dilatada del VD con TVM originada del cuerpo del VD. Ella también tiene hipertensión pulmonar que podría ser en parte responsable por la dilatación del VD. La resonancia puede sobreestimar la frecuencia del diagnóstico de ARVD. Yo prefiría ver modalidades de imagen adicionales para confirmar los hallazgos de la resonancia magnética. Consideraría realizar una angio de VD y biopsia de la pared libre y septal.

---

I totally agree with you Dr. Marcus that pulmonary artery pressure is the KEY to differentiate sclerosis with cardiac involvement from ARVD. Thus we don't have to be fooled by ECG or other images-because they can be very mimic to each other. Following the simple logic it does not cost a thing to figure it out.

Kind regards, Li Zhang, MD [ldlzhang@gmail.com](mailto:ldlzhang@gmail.com) Director, Cardiovascular Outcomes Research Main Line Health Heart Center Lankenau Hospital Associate Professor Lankenau Institute for Medical Research 558 MOB East 100 Lancaster Avenue Wynnewood, PA 19096 U.S.A. Tel: 610-645-2694 Cell: 484-222-1876

Conuerdo totalmente con el Dr Marcus que la presión en la AP es la llave para diferenciar la esclerodermia con compromiso cardiaco de la DAVD. Por lo tanto no debemos dejarnos engañar por los datos del ECG y de otros métodos de imagen porque ellos puede imitar unos a los otros.

The MRI is a very helpful tool for physicians. Among other conditions, it can help detect or diagnose:

1. Aortic disease as dissection, aneurysm and coarctation;
2. Blockages within the cerebral arteries (which supply oxygen-rich blood to the brain) or the coronary arteries (which supply oxygen-rich blood to the heart);
3. Cardiomyopathies including those affecting the RV such ARVC/D;
4. Cardiac masses such as intracardiac tumor or invasive lung malignancy.
5. Pericardial diseases such as constrictive pericarditis or hematoma;
6. The severity of a myocardial infarction;
7. Heart valve diseases;
8. Disease in the arteries outside the heart;
9. Congenital heart disease before or after surgical repair.

## **About MRI tests**

The magnetic resonance imaging test uses a powerful magnetic field to create images of structure and organs within the body. It is safe and non-invasive tests that can help physicians diagnose a wide range of diseases and conditions without subjecting the patient to needles, radiation, radioactive isotopes or dyes. An MRI works by placing the patient in a chamber surrounded by a magnetic field. The center (*nucleus*) of every atom of the patient's body responds to the magnetic force in characteristic ways, allowing a computer to produce very clear cross-sectional or three-dimensional images. There are a few common variations of the standard MRI, including:

Spin echo imaging, or the "black blood" approach. This depicts the tissue of the heart as bright and the blood as dark. It allows the physician to get a very good picture of the anatomical structure of the heart and the coronary arteries. It is especially useful when diagnosing atherosclerosis because it allows physicians to get a very clear view of the structure of the living coronary arteries.

Cine MRI, or “bright blood” approach. This depicts the blood as bright and the cardiac tissue as dark. It allows the physician to evaluate the ventricles, heart valves and other heart structure. Phase velocity mapping. This allows physicians to directly measure blood flow and is helpful to diagnose heart valve disease or narrowing of the coronary arteries.

MRI scans also can be used:

To assess patients’ progress after a heart attack

To evaluate blockages in the coronary arteries (which could rupture and cause a heart attack)

To identify a stroke

To detect blockages of the carotid arteries that could lead to stroke

To detect an atrial myxoma (heart tumor).

Recent research may lead to an expansion in the role of MRI in stroke treatment. Researchers from the National Institute of Neurological Disorders and Stroke (NINDS) in Maryland have devised a new technique for assessing the severity of a stroke and predicting how fully stroke patients will recover. Their process includes a brain MRI, a stroke assessment test and the number of hours between the onset of the stroke and the time the MRI was conducted. The results are expressed on a scale of 0 to 7, with 7 indicating the best possible score. Researchers believe this technique will help patients and physicians weigh the risks and benefits of treatment options.

### **Potential risks with MRI tests**

There is little preparation required for an MRI, but it is very important to remove all metal objects (e.g., rings, earrings, necklaces) just before the test. Not only should all metal objects be removed from the patient, but also there should be no metal objects inside the room in which the MRI is being performed. It is also very important that patients with implanted metal devices or other metallic materials inside the body avoid an MRI. an MRI.

These objects include (but are not limited to):

Pacemakers

ICDs

Artificial hips, knees or other joints

Inner ear implants

Titanium implants in the mouth

Aneurysm clip of the brain

Neuro-muscular stimulators

Implanted drug infusion pump

If patients even suspect that they have a metal device or fragment (such as from an injury) inside their bodies, they should not have an MRI. In the cases of patients with artificial heart valves , stents, or who have undergone open-heart surgery, MRIs may be administered after a certain time period has elapsed. These patients should consult their physicians before having. In addition, there is a small risk of burns at the tattoo site involving tattoos that have high iron-oxide content. Ask the physician ordering the MRI whether a tattoo could be a problem.

Pregnant: women should also avoid having an MRI unless absolutely necessary, because risk to developing fetus is unknown. Finally, patients with tattoos or permanent makeup are encouraged to consult with their physician before an MRI is performed. These patients might feel some mild discomfort or a burning feeling on their skin due to a reaction between the metallic substances commonly found in the darker inks of the tattoo and the magnetic field generated during the test. Furthermore, large or very dark tattoos can also cause “artifacts,” or false shadows to appear on the film produced from the test.

Magnetic resonance imaging (MRI) is a safe and painless test that produces very clear cross-sectional or three-dimensional images of the body's tissues, even through bone and other obstructions. Because of its safety and clarity, the MRI is a very valuable tool that can aid in the diagnosis of a wide range of conditions. The only thing patients need to do to prepare for an MRI is to remove all metal objects (e.g., jewelry) from their body. MRI enables clear visualization of morphology of the right ventricle, and it permits characterization of the composition of the wall, especially with regard to fatty tissue. Typical MRI ARVD/C protocols include

- 1) Bright-blood gradient-echo imaging in cine mode to assess wall motion,
- 2) Dark-blood T1-weighted imaging to evaluate wall thickness, and
- 3) Specific fat-sensitive or fat-suppressive imaging to confirm fatty infiltration or transdifferentiation on short-axis views spanning the entire right ventricle.

Use of orthogonal views, attention to gating, and/or alternative fat-sensitive methods help to eliminate a false-positive signal dropout<sup>1;2;3;4;5</sup>.

1. Midiri M, Finazzo M, Brancato M, et al. Arrhythmogenic right ventricular dysplasia: MR features. *Eur Radiol.* 1997;7(3):307-12.
2. van der Wall EE, Kayser HW, Bootsma MM, et al. Arrhythmogenic right ventricular dysplasia: MRI findings. *Herz.* Jun 2000;25(4):356-64.
3. Tandri H, Macedo R, Calkins H, Marcus F, Cannom D, Scheinman M. Role of magnetic resonance imaging in arrhythmogenic right ventricular dysplasia: insights from the North American arrhythmogenic right ventricular dysplasia (ARVD/C) study. *Am Heart J.* Jan 2008;155(1):147-53.
4. Al-Mallah M, Kwong RY. Clinical application of cardiac CMR. *Rev Cardiovasc Med.* Summer 2009;10(3):134-41
5. Jain A, Tandri H, Calkins H, Bluemke DA. Role of cardiovascular magnetic resonance imaging in arrhythmogenic right ventricular dysplasia. *J Cardiovasc Magn Reson.* Jun 20 2008;10(1):32.

CMRI or MRI is increasingly becoming an important and primary diagnostic tool to confirm the presence of fat in the RV free wall. The cine MRI promises to be particularly useful for the non-invasive demonstration of RV wall motion abnormalities. The technique of performing the MRI is operator dependent and there has not been agreement among radiologists with regard to the optimal technique to perform this test in patients with suspected ARVC/D. This could result in divergent results due to different sensitivity and specificity for detecting abnormalities of the RV. A consensus of experts who perform this test is needed to solve this problem.

Familial studies have highlighted the need to broaden the diagnostic criteria, which are highly specific but lack sensitivity for early disease. Modifications have been proposed for the diagnosis of ARVC/D in relatives. Early ARVC/D is characterized by a "concealed phase" in which electrocardiographic and imaging abnormalities are often absent, but patients may nonetheless be at risk for arrhythmic events<sup>1</sup>.

Schmidt et al<sup>2</sup>. report a 20-year old patient suffering cardiopulmonary resuscitation due to ventricular fibrillation. The authors diagnosed BrS after exclusion structural heart disease and a positive ajmaline test and implanted an ICD. It was found that one brother and one sister presented the beginning of a RV dilatation and a fibrolipomatous area in the anterior wall segment of the RV compatible with a "concealed" ARVC/D. The case report demonstrates the value of familiar examination of patients with an unclear ventricular arrhythmogenic event.

Intramyocardial fat detection in ARVC/D was better with fast-gated spin-echo.

MRI alone and combined with fat suppression than was gated spin-echo MRI. When fast gated spin-echo imaging is applied in vivo, however, breath-holding constraints limit the spatial resolution for RV fat detection<sup>3</sup>.

1. Sen-Chowdhry S, Lowe MD, Sporton SC, McKenna WJ. Arrhythmogenic right ventricular cardiomyopathy: clinical presentation, diagnosis, and management. *Am J Med.* 2004;117:685-695.
2. Schmidt T, Gerckens U, Ortmeyer D, Brugada syndrome or ARVD (arrhythmogenic right ventricular dysplasia) or both? Significance and value of right precordial ECG changes *Z Kardiol.* 2002; 91:416-422.
3. Castillo E, Tandri H, Rodriguez ER, et al. Arrhythmogenic Right Ventricular Dysplasia: Ex Vivo and in Vivo Fat Detection with Black-Blood MR Imaging. *Radiology.* 2004; 232:38-48



MRI and CT imaging have emerged as clinical tools for evaluation of myocardial pathology. In addition to providing morphologic and functional information, both imaging modalities have the ability to demonstrate intramyocardial fat, which is the pathological hallmark in ARVD/C<sup>1</sup>.

Additionally, considering the evolutive nature of the disease, the non-invasiveness of MRI allows the follow-up of these patients and may be considered an excellent screening modality for the diagnosis of ARVC/D in family members. Finally, MRI can be employed in electrophysiological studies to locate the arrhythmogenic focus and reduce sampling errors<sup>2</sup>.

MRI allows the clearest visualization of the heart, in particular because the RV is involved, which is usually more difficult to explore with the other imaging modalities. Furthermore, MRI offers the specific advantage of visualizing adipose infiltration as a bright signal of the RV myocardium. MRI provides the most important anatomic, functional, and morphologic criteria for diagnosis of ARVC/D within one single study. As a result, MRI appears to be the good imaging technique for detecting and following patients with clinical suspicion of ARVC/D<sup>3</sup>.

A myocarditis involving the RV can mimic ARVC/D. An EMB in the apex, anterior free wall, inferior wall of the RV and in the septal-apical region of the LV appears the most reliable diagnostic technique, with significant prognostic and therapeutic implications. MRI showed hyperintense signals in 67% of ARVD and in 62% of myocarditis group<sup>4</sup>. MRI must be performed using cardiac gating, and should include both cine-MR sequences for evaluation of segmental and global RV function or any morphological change of the RV shape, and anatomic sequences to detect fatty or fibro-fatty infiltration of the RV myocardium<sup>5</sup>.

1. Tandri H, Bomma C, Calkins H, Bluemke DA. Magnetic resonance and computed tomography imaging of arrhythmogenic right ventricular dysplasia. *J Magn Reson Imaging*. 2004; 19:848-858.
2. di Cesare E. MRI assessment of right ventricular dysplasia. *Eur Radiol*. 2003;13:1387-1393.
3. van der Wall EE, Kayser HW, Bootsma MM, et al. Arrhythmogenic right ventricular dysplasia: MRI findings. *Herz*. 2000; 25:356-364.
4. Chimenti C, Pieroni M, Maseri A et al. Histologic findings in patients with clinical and instrumental diagnosis of sporadic arrhythmogenic right ventricular dysplasia. *J Am Coll Cardiol*. 2004; 43: 2305-2313.
5. Jacquier A, Bressollette E, Laissy J, et al. MR imaging and arrhythmogenic right ventricular dysplasia (ARVD) *J Radiol*. 2004; 85: 721-724.

Noninvasive detection of RV myocardial fibro-fatty changes in ARVD/C is possible by delayed-enhancement magnetic resonance imaging (gadodiamide MDE-MRI). Ten minutes after intravenous administration of 0.2 mmol/kg of gadodiamide, MDE-MRI is obtained. MRI findings had an excellent correlation with EMB and predicted inducible S-VT on PES, suggesting a possible role in evaluation and diagnosis of patients with suspected ARVD/C<sup>1</sup>. High frequency of "misdiagnosis" of ARVD/C is due to over-reliance on the presence of intramyocardial fat/wall thinning on MRI, incomplete diagnostic testing, and lack of awareness of the Task Force criteria. Diagnosis of ARVD/C cannot rely solely upon qualitative features on MRI<sup>2</sup>.

Additionally patients with cardiac sarcoidosis may present with clinical and morphological features similar to ARVC/D or cardiomyopathy<sup>3</sup>.

At present, the MRI is not a "robust tool " for the diagnosis of ARVC/D. In fact it is responsible for more false positive as well as false negative diagnosis of ARVC/D.

RV wall T1W hyperintensity is the most frequent finding. Sensitivity, specificity, positive predictive value, negative predictive value and prevalence were respectively: 75%, 75%, 50%, 90% and 25%. Using gated spin echo scans and short axis cine MR "strong presumption" criteria, Dumouset et al. in a retrospective study of 50 patients observed sensitivity of 82%, specificity of 87%<sup>4</sup>.

1. Tandri H, Saranathan M, Rodriguez ER, et al. Noninvasive detection of myocardial fibrosis in arrhythmogenic right ventricular cardiomyopathy using delayed-enhancement magnetic resonance imaging. *J Am Coll Cardiol*. 2005;45:98-103.
2. Bomma C, Rutberg J, Tandri H, et al. Misdiagnosis of arrhythmogenic right ventricular dysplasia/cardiomyopathy. *J Cardiovasc Electrophysiol*. 2004; 15:300-3006.
3. Ott P, Marcus FI, Sobonya RE, et al. Cardiac sarcoidosis masquerading as right ventricular dysplasia. *Pacing Clin Electrophysiol*. 2003;26:1498-1503.
4. Dumouset E, Alfidja A, Lamaison D, et al. MRI and arrhythmogenic right ventricular dysplasia (ARVD). Retrospective evaluation of 50 patients *J Radiol*. 2004; 85: 313-320.

The use of fat-suppressed in addition to non-fat-suppressed conventional T1-weighted spin-echo imaging increased interobserver agreement and confidence in diagnosis and evaluation of intramyocardial fatty infiltration in patients who were suspected to have ARVC/D<sup>1</sup>.

MRI is currently considered as the noninvasive modality of choice for evaluation of patients with suspected ARVC/D. Fatty infiltration of the RV free wall can be visible on cardiac MRI. Fat has increased intensity in T1-weighted images. However, it may be difficult to differentiate intramyocardial fat and the epicardial fat that is commonly seen adjacent to the normal heart. Also, the sub-tricuspid region may be difficult to distinguish from the atrioventricular sulcus, which is rich in fat.

MRI is currently considered as the noninvasive modality of choice for evaluation of patients with suspected ARVC/D. It is included in the WHO classification of cardiomyopathies. It has the unique ability to provide tissue characterization in addition to providing functional information<sup>2</sup>. Essential steps in improving accuracy and reducing variability include a standardized acquisition protocol and standardized analysis with dynamic cine review of regional RV function and quantification of RV and LV volumes<sup>3</sup>.

MRI and computed tomographic (CT) imaging have emerged as important clinical tools for evaluation of myocardial pathology. In addition to providing morphologic and functional information, both imaging modalities have the ability to demonstrate intramyocardial fat, which is the pathological hallmark in ARVC/D<sup>4</sup>.

1. Abbara S, Migrino RQ, Sosnovik DE, et al. Value of fat suppression in the MRI evaluation of suspected arrhythmogenic right ventricular dysplasia. *AJR Am J Roentgenol.* 2004; 182:587-591.
2. Tandri H, Friedrich MG, Calkins H, et al. MRI of arrhythmogenic right ventricular cardiomyopathy/dysplasia. *J Cardiovasc Magn Reson.* 2004; 6: 557-563.
3. Bluemke DA, Krupinski EA, Ovitt T, et al. MR Imaging of arrhythmogenic right ventricular cardiomyopathy: morphologic findings and interobserver reliability. *Cardiology.* 2003; 99: 153-162.
4. Tandri H, Bomma C, Calkins H, et al. Magnetic resonance and computed tomography imaging of arrhythmogenic right ventricular dysplasia. *J Magn Reson Imaging.* 2004;19:848-858

In ARVD/C, MRI findings consist of abnormalities in signal intensity, which usually affect the right ventricular free wall and/or the triangle of dysplasia. Fibrofatty deposition in these regions of the right ventricle may be found on T1- and T2-weighted images, where they appear as areas of either focal or diffuse high signal intensity. Other relatively nonspecific signal-intensity abnormalities in the right ventricle may be due to fibrosis or inflammation.

Regardless of the MRI findings obtained, myocardial biopsy is often warranted. In terms of morphology, diffuse or focal dilatation of the chamber of the right ventricle is a key finding in ARVD/C. Often, the free wall of the right ventricle is noticeably thinned. Motion abnormalities depend on the extent of the underlying fibrofatty infiltration and vary from a focal bulge to a low ejection fraction due to disease that is more diffuse.

MRI may be indicated in

- 1) Young athletes with frequent simple arrhythmias, even in the absence of echocardiographic abnormalities;
- 2) Patients with ventricular tachyarrhythmias in a left bundle-branch-block pattern;
- 3) Patients with palpitations, syncopal episodes, or echocardiographic abnormalities of the right ventricle; and
- 4) Patients with a familial occurrence of ARVD/C or sudden death syndrome.

### **Degree of confidence**

The role of MRI in the diagnosis of ARVD/C has been established. In conjunction with electrophysiologic, electrocardiographic, and familial indicators, MRI results are specific. MRI is considered highly sensitive and highly specific when all of the considerations discussed above are applied.

### **False positives/negatives**

MRI can be an effective noninvasive examination for fatty infiltration of the myocardium. However, because fat is a normal component of the right ventricle in humans, it is necessary to interpret MRI results in light of all of the findings in the clinical context.

# Progressive Systemic Sclerosis Overview

Systemic sclerosis is a clinically heterogeneous, systemic disorder which affects the connective tissue of the skin, internal organs and the walls of blood vessels. It is characterized by alterations of the microvasculature, disturbances of the immune system and by massive deposition of collagen and other matrix substances in the connective tissue.

Early diagnosis and individually tailored therapy help to manage this disorder, which is treatable, but not curable.

Therapy involves immunomodulation as well as the targeting of blood vessel mechanics and fibrosis.

Physical therapy and psychotherapy are also important adjunctive therapies in this multifactorial disease.

The first detailed description of a scleroderma-like disease was published by Curzio in Naples in 1753<sup>1</sup>. The patient, a young woman suffered from excessive tension and hardness of the skin. Nearly 100 years later, in 1847 Gintrac introduced the term scleroderma, as the skin was the most obvious organ involved<sup>2</sup>. The extensive involvement of internal organs has only been realized in the second half of the 20th century<sup>3;4;5</sup>.

Systemic sclerosis has an annual incidence of 1 to 2 per 100,000 individuals in the United States<sup>6</sup>. The peak onset is between the ages of 30 and 50, and the disease is more common in women. The diagnosis of systemic sclerosis and related disorders is based primarily upon the presence of characteristic clinical findings.

#### References

1. Curzio C. Discussionil anatomico-pratiche di un raro, e stravagante morbo cutaneo in una giovane donna felicemente curato in questo grande ospedale degl' incurabili. Napoli, Presso Giovanni di Simone, 1753. Curzio C. An account of an extraordinary disease of the skin and its cure. Translated by R. Watson. Philosophical Trans 1754;48:579.
2. Gintrac M. Note sur la sclerodermie. Rev Med Chir. Paris 1847;2:263-81.
3. Sackner MA. The visceral manifestations of scleroderma. Arthritis Rheum 1962;5:184-96.
4. Rodnan GP, Benedek TG. A historical account of the study of progressive systemic sclerosis (diffuse scleroderma). Ann Intern Med 1962;57:305-19.
5. Jablonska S. Scleroderma and pseudoscleroderma. Warsaw: Polish Med, 1975.
6. Lawrence RC, Helmick CG, Arnett FC, et al. Estimates of the prevalence of arthritis and selected musculoskeletal disorders in the United States. Arthritis Rheum. 1998 May;41:778-799.

# Cardiac Involvement

Cardiac involvement is often present, but rarely significant clinically. Even dyspnea and retrosternal pain are attributed mainly to other organs such as the lung or esophagus. In addition, syncope and angina pectoris may be caused by either endothelial damage of small coronary arteries or myocardial fibrosis due to other basic diseases. It is hard to prove the specificity of this involvement due to SSc itself. The prevalence reported in the literature depends upon the diagnostic methods chosen. Myocardial perfusion scintigraphy, ventriculography and echocardiography are the most sensitive techniques. Clinically manifested forms have been described in 20-25 % with a 70 % mortality after 5 years. However, autopsy revealed alterations such as myocardial fibrosis and pericardial effusion in 30-80 % of patients<sup>1;2</sup>. Myocardial fibrosis occurs as patchy or diffuse forms. Repeated episodes of ischemia and reperfusion lead to the destruction of the myocardium and replacement by connective tissue.<sup>3</sup>

In electrocardiographic studies of 80 SSc patients, hypokinetic alterations of the left ventricle were found<sup>4</sup>. Electrocardiographic abnormalities such as conduction system disturbances (27 %), signs of infarction (13.8 %), and non-specific ST and T-wave changes (13.8 %) were observed in agreement with echocardiographic findings<sup>5</sup>.

Arrhythmias are common and adversely affect survival. Ventricular tachycardia can occur in up to 19 % of patients<sup>6</sup>.

1. Lee P, Langevitz P, Alderdice CA, Aubrey M. Mortality in systemic sclerosis (scleroderma). *Q J Med* 1992;298:139-148.
2. Follansbee WP. The cardiovascular manifestations of systemic sclerosis (scleroderma). *Curr Probl Cardiol* 1986;11:241-98.
3. Reichenbach DD, Benditt EP. Myofibrillar degeneration: a response of the myocardial cell to injury. *Arch Pathol* 1968;46:189-99.
4. Hegedus I, Czirjak L. Left ventricular wall motion abnormalities in 80 patients with systemic sclerosis. *Clin Rheumatol* 1995;14:161f.
5. Candell-Riera J, Armandans-Gil L, Simeon CP. Comprehensive noninvasive assessment of cardiac involvement in limited systemic sclerosis. *Arthritis Rheum* 1996;39:1138-1145.
6. Kostis JB, Seibold JR, Turkevich D. Prognostic importance of cardiac arrhythmias in systemic sclerosis. *Am J Med* 1988;84:1007-15.

Cardiac involvement is recognized as a poor prognostic factor when clinically evident. Primary myocardial involvement is common in SSc. Increasing evidence strongly suggests that myocardial involvement is related to repeated focal ischemia leading to myocardial fibrosis with irreversible lesions. Reproducible data have shown that this relates to microcirculation impairment with abnormal vasoreactivity, with or without associated structural vascular abnormalities. Consistently, atherosclerosis and macrovascular coronary lesions do not seem to be increased in SSc. Myocardial involvement leads to abnormal systolic and diastolic left ventricular dysfunction and right ventricular dysfunction. Sensitive and quantitative methods have demonstrated the ability of vasodilators, including calcium channel blockers and angiotensin converting enzyme inhibitors, to improve both perfusion and function abnormalities further emphasising the critical role of microcirculation impairment. Recent quantitative methods such as tissue Doppler echocardiography and magnetic resonance imaging have underlined these results<sup>1</sup>.

Low heart rate variability, increased Total skin thickness score (TSS) and the presence of anti-scleroderma 70 (anti-SCL70) are correlated with preclinical cardiac involvement in SSc patients and may predict the likelihood of malignant arrhythmia and sudden cardiac death.

Raynaud's phenomenon and anti-scleroderma 70 (anti-SCL70) showed significant positive correlations with all arrhythmia parameters, while showing a significant negative correlation with the impaired ventricular diastolic function and various HRV parameters.

No correlation was found between arrhythmia and HRV parameters and disease duration, disease type, or presence of anti-centromere antibodies. Therefore, noninvasive HRV evaluation before clinical cardiac involvement in these patients might be beneficial when added to the clinical and laboratory assessments in detecting high-risk patients, and may allow for implementation of preventive measures and initiation of appropriate therapy early in the course of the disease<sup>2</sup>.

1. **Allanore Y, Meune C. Primary myocardial involvement in systemic sclerosis: evidence for a microvascular origin. Clin Exp Rheumatol. 2010 Sep-Oct;28(5 Suppl 62):S48-53.**
2. **Othman KM, Assaf NY, Farouk HM. Et al. Autonomic dysfunction predicts early cardiac affection in patients with systemic sclerosis. Clin Med Insights Arthritis Musculoskelet Disord. 2010 May 24;3:43-54.**



Echocardiography is very sensitive in detecting even small pericardial effusions and heart valve alterations<sup>1</sup>. Very useful also is the thallium scintigraphy.

The involvement of coronary arteries may lead to myocardial infarction. In addition to morphological alterations of the coronary arteries, also a cold-induced coronary spasm (cardial Raynaud's phenomenon) is discussed<sup>2</sup>.

Clinical pericarditis is present in only 10 to 15 % of patients with SSc and is more common in patients with limited disease<sup>3</sup>.

## MAIN CARDIAC MANIFESTATION IN SYSTEMIC SCLEROSIS

- Cardiomyopathy (systolic and diastolic dysfunction): Congestive heart failure
- Conduction defects
- Septal infarction pattern
- Ventricular conduction abnormalities
- Arrhythmias
- Heart blocks
- Pericarditis or pericardial effusion (impending renal crisis) ++++
- Aortitis.
- Pulmonary Hypertension

Conduction defects and arrhythmias are frequent in patients with SSc, and may result in sudden cardiac death. In patients with SSc who are affected by ventricular arrhythmias, the implantation of a cardioverter defibrillator may prevent sudden cardiac death<sup>4</sup>.

1. Clements PJ, Furst DE. Heart involvement in systemic sclerosis. *Clin Dermatol* 1994;12:267-275.
2. Alexander EL, Firestein GS, Weiss JL. Reversible cold-induced abnormalities in myocardial perfusion and function in systemic sclerosis. *Ann Intern Med* 1986;105:661-8.
3. Follansbee WP, Curtiss EI, Rahko PS. The electrocardiogram in systemic sclerosis (scleroderma): a study of 102 consecutive cases with functional correlations and review of literature. *Am J Med* 1985;79:183-92.
4. Bernardo P, Conforti ML, Bellando-Randone S, et al. Implantable Cardioverter Defibrillator Prevents Sudden Cardiac Death in Systemic Sclerosis. *J Rheumatol*. 2011 Jun 1. [Epub ahead of print]

# RELATIVE FREQUENCIES OF CARDIAC INVOLVEMENT IN SELECTED SYSTEMIC AUTOIMMUNE DISORDERS

	Pericardial	Ischemic Arteritis Thromb.	Myopathy	Conduction	Valvular	Pulmonary hypertension	Aortitis
RA	++++		+		+	+	+++
B27 Spondylo.	+		+	++++	+++		++++
SLE	++++	++/++++	+++	++++	++++	+++	+
APLA					++++	+++	
Sclero derma	++++	-/+	++			++++	
Polymyo sitis	+		+++	+++			
Sarcoidosis	+++		+			+++	++

RA: Rheumatoid Arthritis; ALA-B27: spondyloarthropaties; SLE: Systemic Lupus Erithematusus; APLA: antiphospholipid antibody syndrome; ARTERITIS/THROMBO: :coronary arteritys/thrombotic or atherosclerosis-related coronary artery dise  
 +: reported; ++: rare; +++: well described; ++++ Frequently reported;

# Differential Diagnosis of Systemic Sclerosis

1. Mixed connective tissue disease
2. Graft-versus-host disease
3. Nephrogenic systemic fibrosis (formerly known as nephrogenic fibrosing dermopathy)
4. Diabetic scleredema
5. Diffuse fasciitis with eosinophilia (Shulman's syndrome)
6. Toxic oil syndrome
7. Eosinophilia-myalgia syndrome
8. Lichen sclerosus et atrophicus
9. Sclerodermiform acrodermatitis chronica atrophicans (Lyme disease)
10. Scleromyxedema (lichen myxedematosus) associated with paraproteinemia
11. Drugs and toxins (l-tryptophan, bleomycin, pentazocine, carbidopa, vinyl chloride, silica)

After Herpes zoster it was noticed in January we observed disease progression.

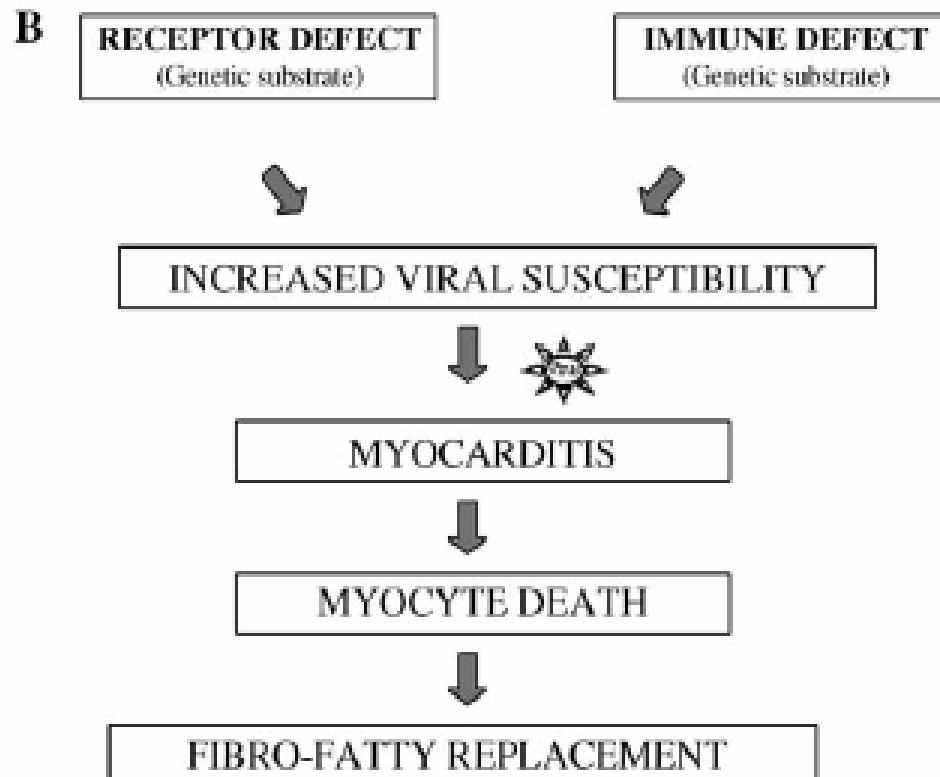
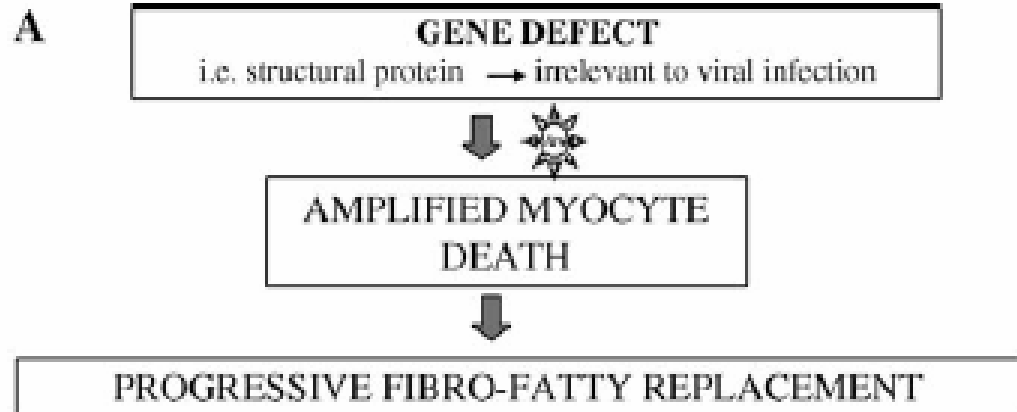
May be a link? Different cardiotropic viruses, such as adenovirus, cytomegalovirus, hepatitis C virus, and parvovirus B19 have been detected in sporadic ARVC/D forms by our group (unpublished data) as well as by other researchers

*Arrhythmogenic right ventricular cardiomyopathy/dysplasia:  
is there a role for viruses?*

Fiorella Calabrese\*, Cristina Basso, Elisa Carturan, Marialuisa Valente, Gaetano Thiene

*Institute of Pathological Anatomy, University of Padua Medical School, 35121 Padua, Italy*

Received 29 November 2004; received in revised form 2 August 2005; accepted 3 October 2005



Does the patient has two rare diseases concurrently? Or she has the spectrum of the same entity?

In 1986, an association of cardiomyopathy with wooly hair and palmoplantar keratoderma was first reported in families from the Greek island of Naxos (...) presented clinical and histopathological characteristics of ARVC/D.

In 1996, Rao et al. and 2 years later Carvajal reported a variant of Naxos disease in families from India and Ecuador, respectively

### Review Article

## Naxos disease and Carvajal syndrome: cardiocutaneous disorders that highlight the pathogenesis and broaden the spectrum of arrhythmogenic right ventricular cardiomyopathy

Nikos Protonotarios\*, Adalena Tsatsopoulou

*Yannis Protonotarios Medical Center, Hora Naxos, Naxos 84300, Greece*

Received 6 February 2004; received in revised form 24 March 2004; accepted 30 March 2004

The Carvajal Syndrome<sup>1</sup> is a familial, cardio-cutaneous, autosomal recessive entity, mapped to the short arm of chromosome 6 (6p24) and caused by a 7901delG mutation in exon 24 of desmoplakin. This is an intracellular protein that links desmosomal adhesion molecules to intermediate filaments of the cytoskeleton. It causes premature deletion of the codon located in the amino acid with number 18, causing truncation of the C-terminal domain in the region that interacts with intermediate filaments. Desmosomes are major cell adhesion junctions, particularly prominent in the epidermis and cardiac tissue and are important for the rigidity and strength of the cells. The desmosome consists of several proteins, of which desmoplakin is the most abundant. Norgett et al. described the first recessive human mutation, 7901delG, in the desmoplakin gene which causes a generalized striate keratoderma particularly affecting the palmoplantar epidermis, woolly hair and a dilated left ventricular cardiomyopathy. A number of the patients with this syndromic disorder suffer CHF in their teenage years, resulting in early morbidity. All tested affected members of three families from Ecuador were homozygous for this mutation which produces a premature stop codon leading to a truncated desmoplakin protein missing the C domain of the tail region. Histology of the skin revealed large intercellular spaces and clustering of desmosomes at the infrequent sites of keratinocyte adhesion. Immunohistochemistry of skin from the patients showed a perinuclear localization of keratin in suprabasal keratinocytes, suggesting a collapsed intermediate filament network. This study demonstrates the importance of desmoplakin in the attachment of intermediate filaments to the desmosome. In contrast to null DESMOPLAKIN: mice which die in early development, the truncated protein due to the homozygous 7901delG mutation in humans is not embryonic lethal. This suggests that the tail domain of desmoplakin is not required for establishing tissue architecture during development<sup>2</sup>.

1. Carvajal-Huerta L. Epidermolytic palmoplantar keratoderma with woolly hair and dilated cardiomyopathy. *J Am Acad Dermatol.* 1998; 39:418-421.
2. Norgett EE, Hatsell SJ, Carvajal-Huerta L, Recessive mutation in desmoplakin disrupts desmoplakin-intermediate filament interactions and causes dilated cardiomyopathy, woolly hair and keratoderma. *Hum Mol Genet.* 2000;9:2761-2766.

It is clinically characterized by:

Woolly hair present since birth;

Hyperkeratosis and palmoplantar keratoderma of early onset (approximately the first year of life);

Dilated cardiomyopathy with systolic dysfunction that leads to CHF<sup>1</sup>.

This entity should not be considered part of ARVC/D, because it causes global dilated cardiomyopathy and not ARVC/D. The cardiomyopathy is characterized by ventricular hypertrophy and dilatation, focal ventricular aneurysms, and distinct ultrastructural abnormalities of intercalated disks; however, there is no evidence of fibrofatty infiltration or replacement of myocardium. There are markedly decreased amounts of specific immunoreactive signal for desmoplakin, plakoglobin and the gap junction protein, connexin 43, at intercalated disks. The intermediate filament protein, desmin, which is known to bind desmoplakin, showed a normal intracellular pattern of distribution but failed to localize at intercalated disks<sup>2</sup>. It has a differential diagnosis with recessive Naxos disease, which affects the long arm of chromosome 17 (17q21) associated to non-epidermolytic palmoplantar keratoderma with woolly hair.

Table below shows the main differences between both entities.

**1.Duran M, Avellan F, Carvajal L. Dilated cardiomyopathy in the ectodermal dysplasia. Electro-echocardiographic observations in palmo-plantar keratoderma with woolly hair. Rev Esp Cardiol. 2000; 53:1296-1300.**

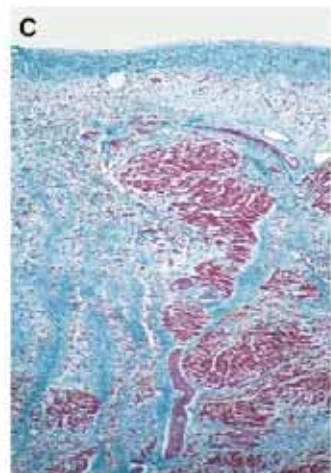
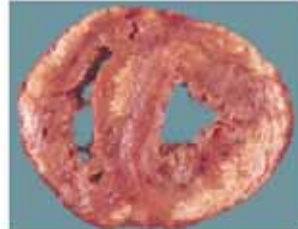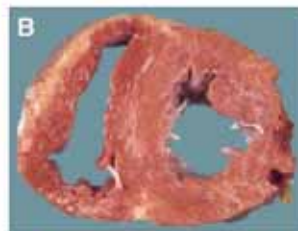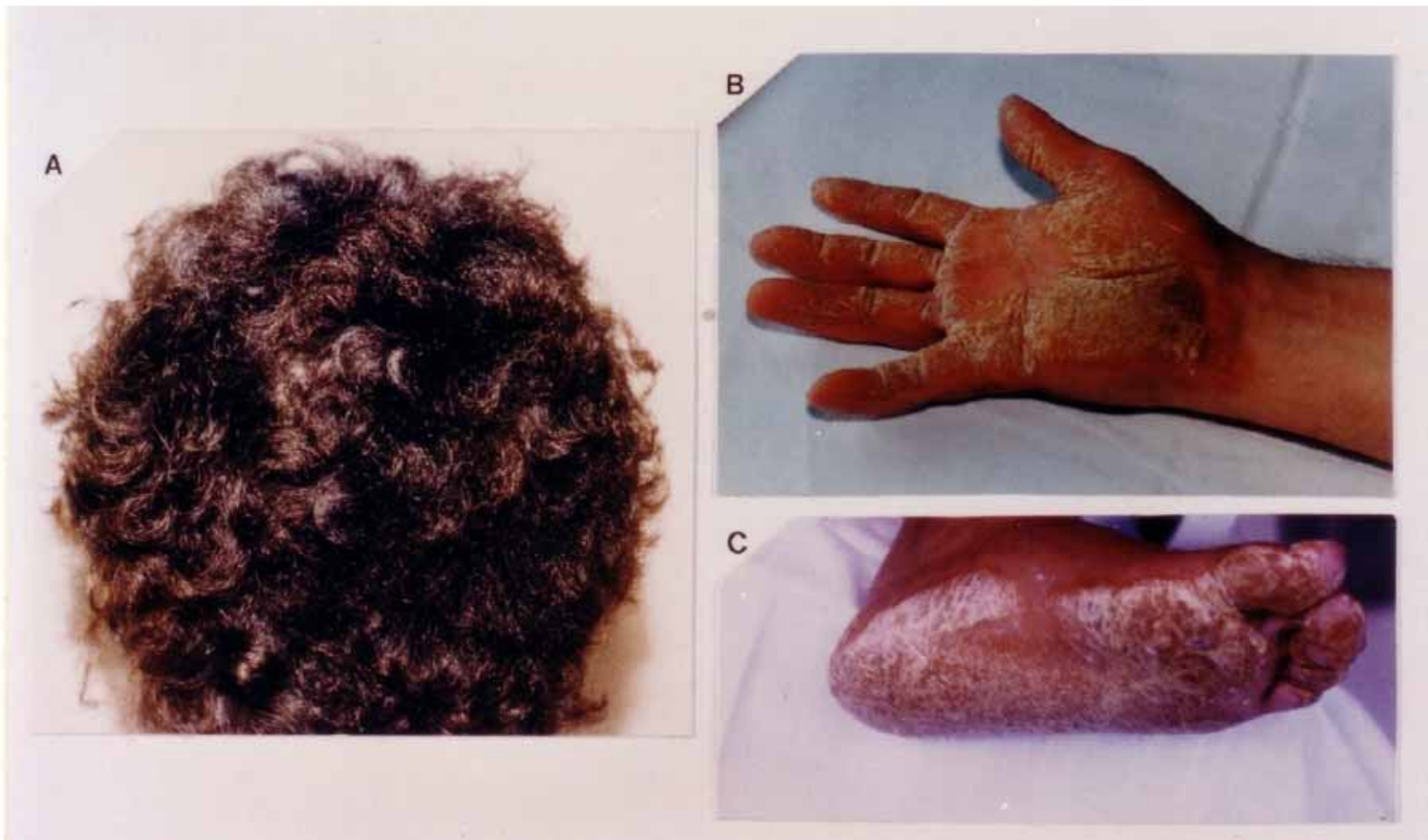
**2.Kaplan SR, Gard JJ, Carvajal-Huerta L, Ruiz-Cabezas JC, Thiene G, Saffitz JE. Structural and molecular pathology of the heart in Carvajal syndrome. Cardiovasc Pathol. 2004;13:26-32.**

# DIFFERENTIAL CHARACTERISTICS BETWEEN CARVAJAL SYNDROME AND NAXOS DISEASE

	CARVAJAL SYNDROME	NAXOS DISEASE
Inheritance pattern:	Recessive autosomal.	Recessive autosomal.
Affected chromosome:	6 short arm. (6p24). Caused by a 7901delG mutation in exon 24 of desmoplakin.	Long arm of chromosome 17 (17q21) that codifies the desmoplakin protein. This protein is a key component of desmosomes and adherens junctions, and is important for the tight adhesion of many cell types, including those in the heart and skin.
Cardiac disease:	Global dilated cardiomyopathy.	ARVC/D
Symptoms:	CHF.	Unique form of RV cardiomyopathy. It presents a high prevalence of malignant ventricular arrhythmias, including SCD. CHF.
Structural and molecular pathology of the heart:	Markedly decreased amounts of specific immunoreactive signal for desmoplakin, plakoglobin, and the gap junction protein, connexin43, at intercalated disks.	Progressive replacement of myocardial cells by fat and fibrous tissue on RV. Deletion in plakoglobin in ARVC suggests that the proteins involved in cell-cell adhesion play an important role in maintaining myocyte integrity. Thus, when junctions are disrupted, cell death, and fibrofatty replacement occur
Geographic distributions:	Spain. Ecuador. Others?	It appears in families descending from the Hellenic island of Naxos and Milos <sup>2</sup> .
Treatment	Conventional for CHF.	ICD associated to drugs <sup>3</sup> .

1. **McKoy G, Protonotarios N, Crosby A, Tsatsopoulou A, Anastasakis A, Coonar A, Norman M, Baboonian C, Jeffery S, McKenna WJ. Identification of a deletion in plakoglobin in arrhythmogenic right ventricular cardiomyopathy with palmoplantar keratoderma and woolly hair (Naxos disease). Lancet. 2000; 355:2119-2124.**
2. **Narin N, Akcakus M, Gunes T, Celiker A, Baykan A, Uzum K, Ferahbas A. Arrhythmogenic right ventricular cardiomyopathy (Naxos disease): report of a Turkish boy. Pacing Clin Electrophysiol. 2003; 26:2326-2329.**
3. **Gatzoulis K, Protonotarios N, Anastasakis A, Tsatsopoulou A, Vlasseros J, Gialafos J, Toutouzas P. Implantable defibrillator therapy in Naxos disease. Pacing Clin Electrophysiol. 2000; 23:1176-178.**





# Pró-transpante

- » Pobre resposta à terapia convencional
- » Mortalidade em cinco anos 40%-50%
- » Estudo Franco-holandês 2008 (n=26)
  - 81% melhora clínica
  - 94% melhora do acometimento cutâneo
  - Estabilização das funções pulmonar, renal e cardíaca

# Contra o transplante

- » ES apresenta uma das maiores taxas de mortalidade relacionadas ao transplante, muito provavelmente devido às más condições cardiopulmonares. PSS has the highest mortality rates related to transplantation, most likely due to poor cardiopulmonary conditions.
- » Preocupação em selecionar adequadamente o paciente Concern in selecting the patient properly
- » Ciclofosfamida 200mg/Kg Are required high dose of the drug(cardiotoxicity)

# Pro-transplant

Poor response to conventional therapy

Mortality in five years 40% to 50%

French-Duth study

81% clinical improvement

Improvement of skin condition

Stabilization of pulmonary, renal and cardiac function

# Against transplantation