

CASE REPORT

Dr. Andrés Ricardo Pérez Riera
Chief of Electovectorcardiogram Sector of Cardiology Discipline
ABC Faculty – ABC Foundation – Santo André – São Paulo – Brazil
riera@uol.com.br

Paciente adolescente, (15 anos) feminina, branca, natural e procedente de Santo André São Paulo Brasil, estudante regular da segunda série escolar. Assintomática
Motivo da consulta: avaliação para prática de atividades físicas competitivas (modalidade Handebol).

Antecedentes pessoais: nada digno de nota.

Antecedentes familiares: negativos.

Exame físico: normal.

Perguntas

- Qual a conduta adequada neste caso?**
 - Qual a localização do feixe anômalo? E porque?**
-

Teenager patient, (15 years) women's, Caucasian, natural and coming from Santo André São Paulo Brazil. Regular student of the State second school series. Asymptomatic.

Consultation reason: Evaluation for practice of competitive physical activities (Handball modality).

Personal antecedents: Nothing worthy of mark.

Family antecedents: Negative.

Physical exam: Normal.

Questions

- Which is the appropriate conduct in this case?**
- Where is the location of the anomalous pathway? And Why?**

Name: CLS

Gender: Female

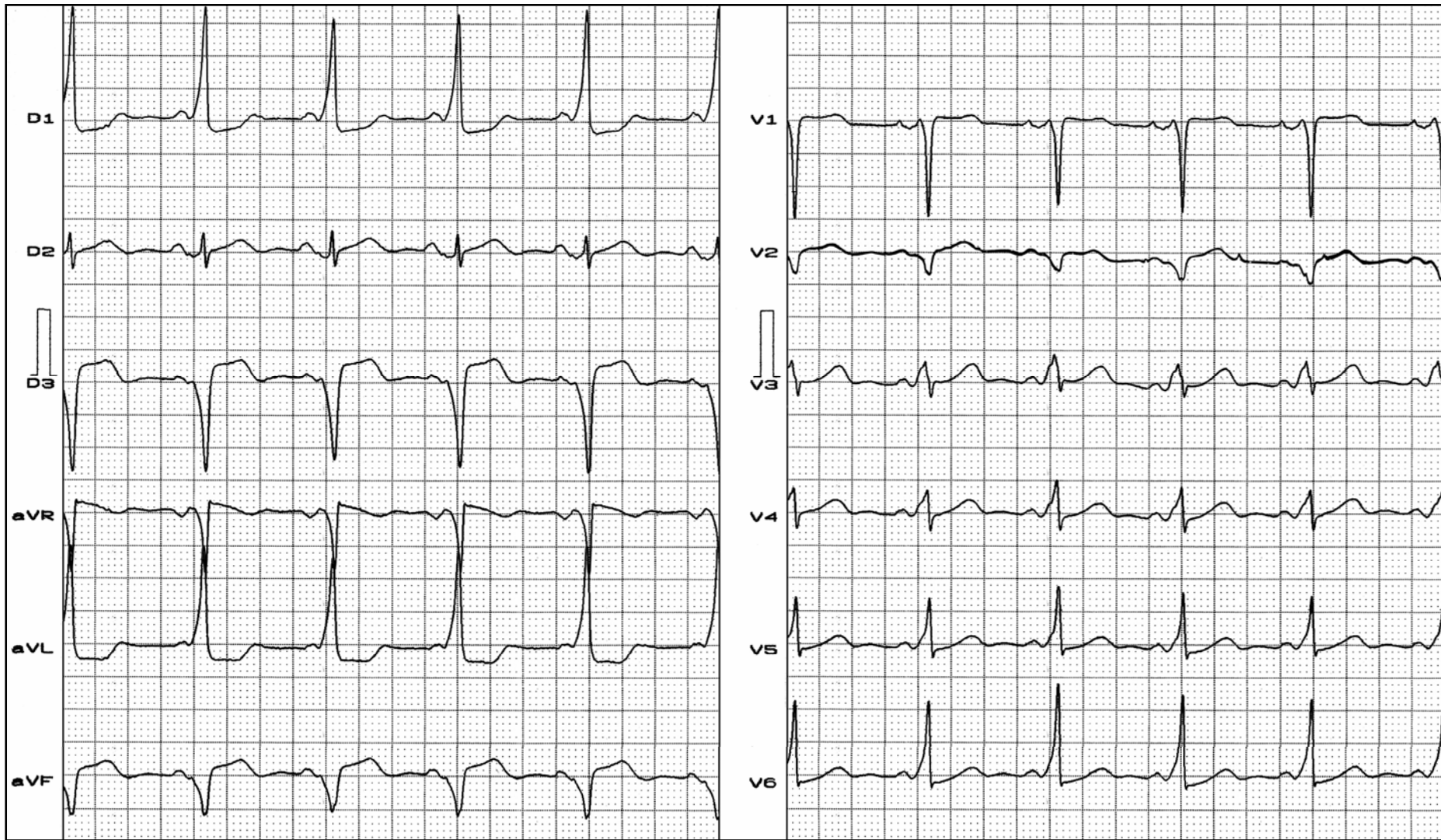
Age: 15 yo.

Ethnic Group: Caucasian

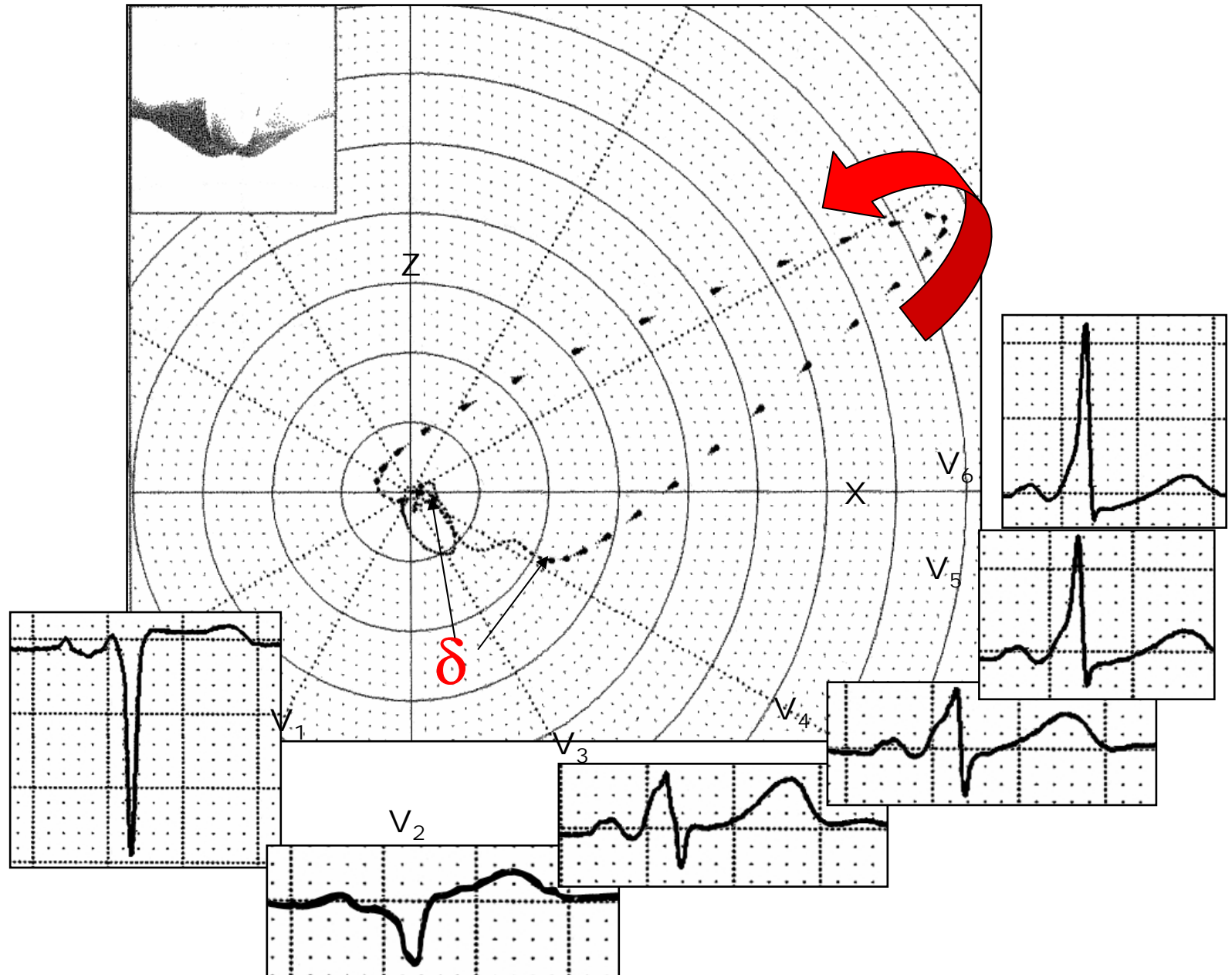
Weight: 58 Kg

Height: 1,58 m

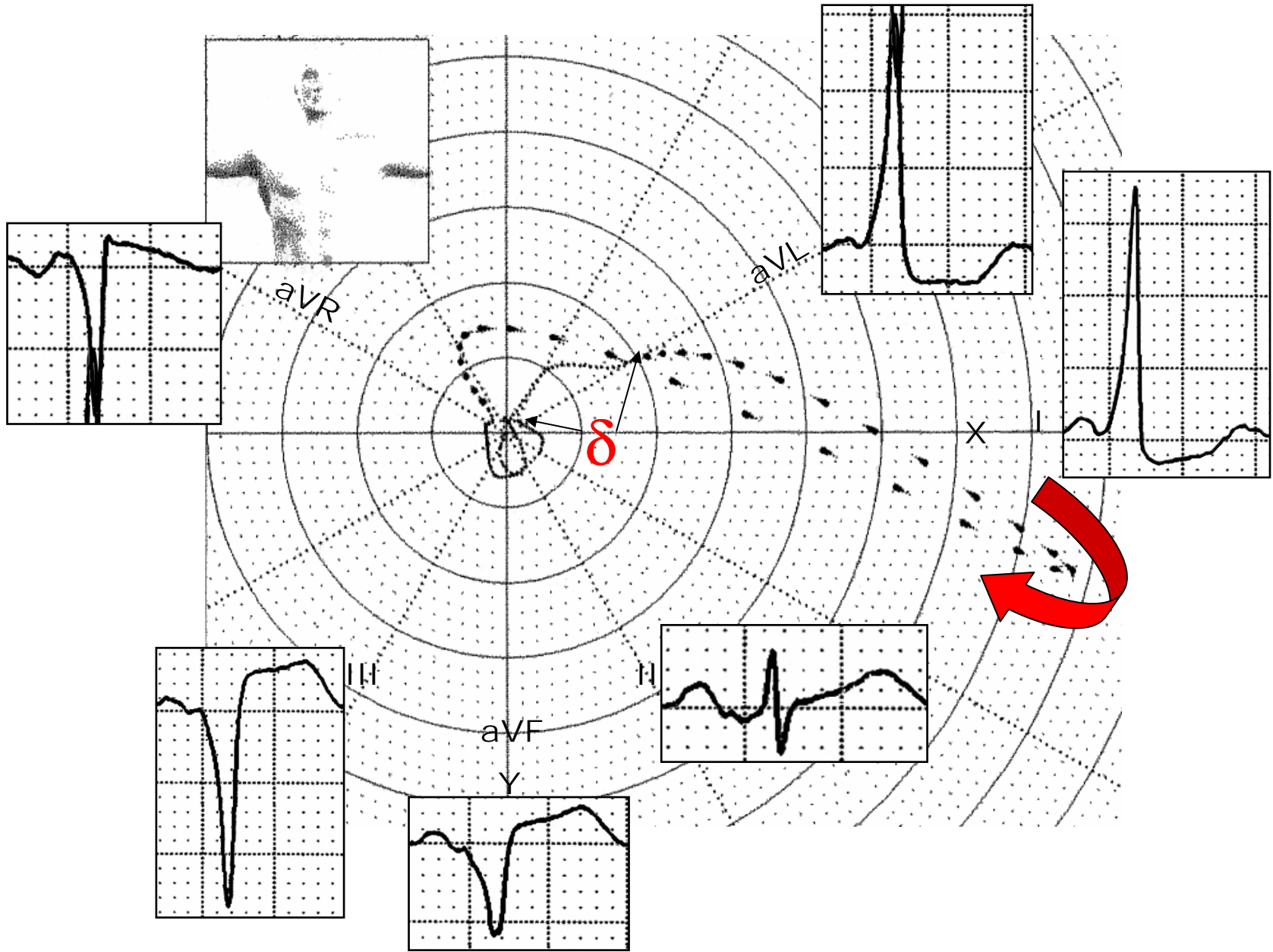
Date: 02/26/2010



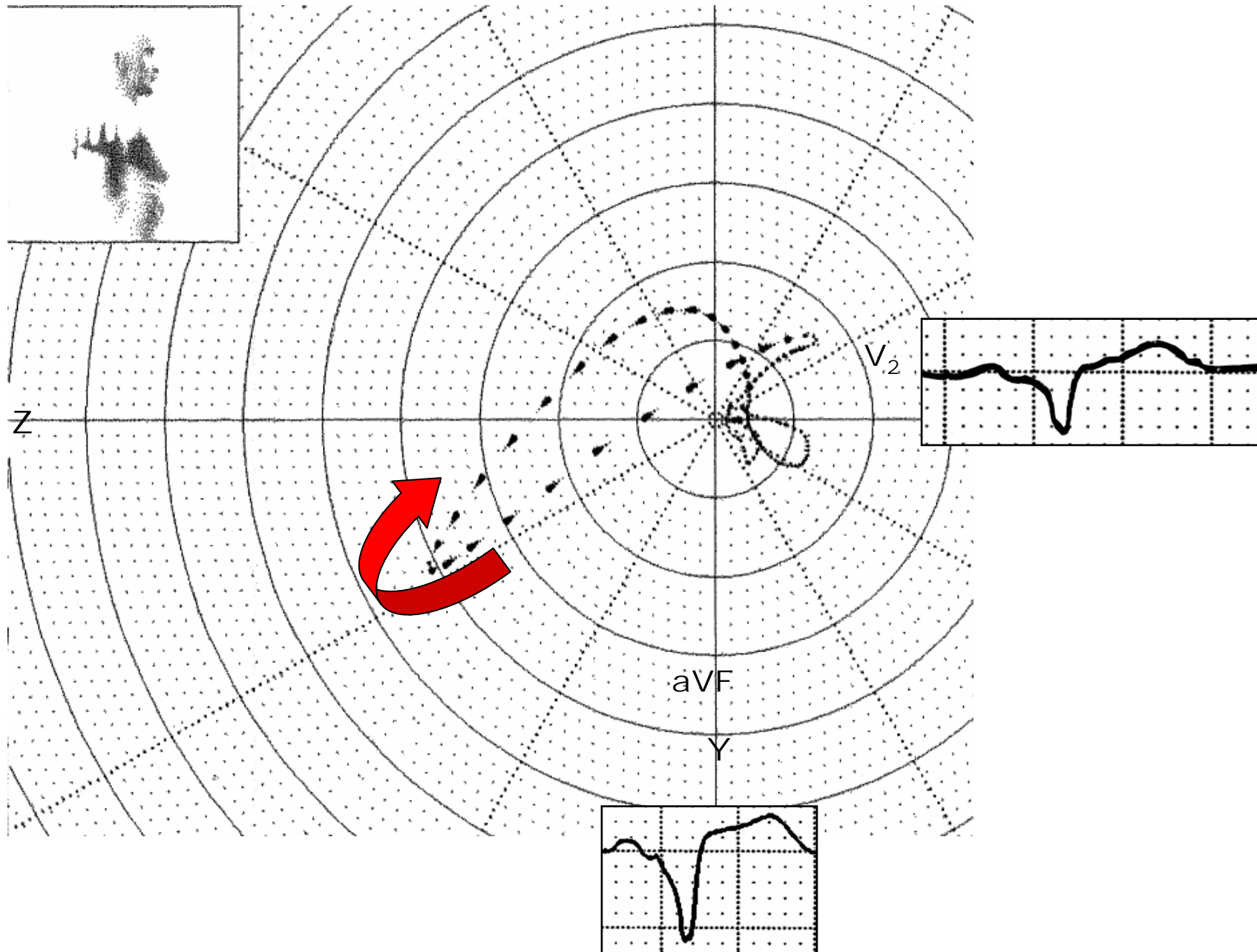
ECG/VCG CORRELATION HORIZONTAL PLANE



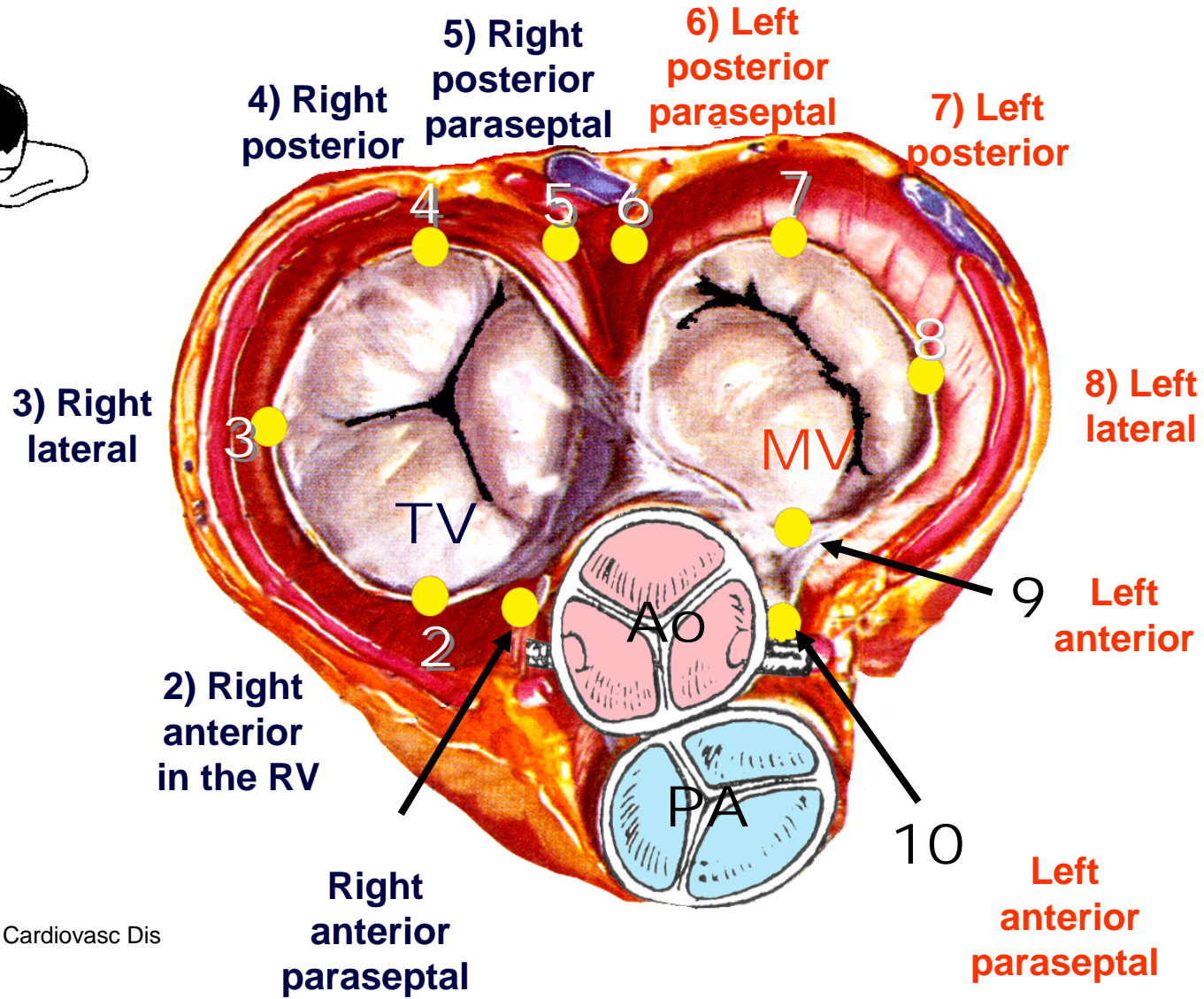
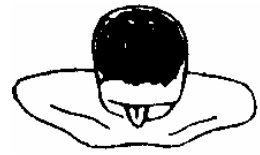ECG/VCG CORRELATION FRONTAL PLANE



ECG/VCG RIGHT CORRELATION SAGITTAL PLANE



LOCATIONS OF ANOMALOUS PATHWAYS IN WPW



Gallagher JJ Prog Cardiovasc Dis
1978;324:1612-18

Where is the location of anomalous pathway in this case?