

**EARLY REPOLARIZATION VARIANT:
EPIDEMIOLOGICAL ASPECTS, MECHANISM, AND DIFFERENTIAL
DIAGNOSIS**

Andrés Ricardo Pérez Riera¹, Augusto Hiroshi Uchida², Celso Ferreira³, Celso Ferreira Filho⁴, Edgardo Schapachnik⁵, Sergio Dubner⁶, Li Zhang⁷, Paulo Jorge Moffa⁸.

For International VCG investigators. ABC Faculty of Medicine (FMABC), Foundation of ABC (FUABC) - Santo André^{1;3;4}, Brazil; Heart Institute of the University of São Paulo Medical School - São Paulo, Brazil^{2;8}; Dr. Cosme Argerich Hospital - Buenos Aires, Argentina⁵; Clínica and Maternidad Suizo Argentina - Buenos Aires, Argentina⁶; LDS Hospital, University of Utah, Salt Lake City, Utah, USA⁷.

Electro-Vectorcardiographic Section, ABC Medical School, ABC Foundation, Santo André - São Paulo, Brazil.

Contact data:

Andrés R. Pérez Riera, MD

Rua Sebastião Afonso, 885 - Jd. Miriam 04417- 100 – Sao Paulo – Brazil

Phone: (55 11) 5621-2390 Fax: (55 11) 5625-7278/ 5506-0398

E-mail: riera@uol.com.br

Key words: Early repolarization variant • Pericarditis • Acute coronary syndrome • Brugada syndrome • Differential diagnosis •

Abstract

Early repolarization variant (ERV or ERPV) is an enigmatic electrocardiographic phenomenon, characterized by prominent J wave and ST-segment elevation in multiple leads. Recently, there has been renewed interest in ERV because of similarities to the arrhythmogenic Brugada syndrome (BrS). Not much is known about the epidemiology of ERV and several studies have reported that this condition is associated with a good prognosis. Both syndromes exhibit some similarities including the ionic underlying mechanism, the analogous responses to changes in heart rate and autonomic tone, sympathicomimetics (isoproterenol test) as well as in sodium channel and beta-blockers. These observations raise the hypothesis that ERV may be not as benign as traditionally believed. Additionally, there are documents showing that ST-segment height in the man is greatly influenced by central sympathetic nervous activity, both at baseline and during physiologic and pharmacological stress.

Central sympathetic dysfunction regularly results in multilead ST-segment elevation or J wave that decreases or below isoelectric baseline during low dose isoproterenol infusion.

In this review, we describe the characteristics of ERV and the main differences with acute pericarditis, acute myocardial infarction/injury and Brugada syndrome.

Introduction

Definition

ERV is an enigmatic idiopathic electrocardiographic phenomenon, characterized by prominent J wave and ST-segment elevation, concave to the top, predominantly in left precordial leads, although ERV is typically characterized by a diffuse elevation of the ST segment of upper concavity, ending in a positive large T wave from V₂ to V₄ or V₅¹. While the etiology of ERV has not been clearly defined, the current opinion is that this finding is seen in individuals with high vagal tone or loss of sympathetic tone.

Critical discussion of semantics: denominations used in literature

The term "early repolarization" is not appropriate because it's meaningless. Repolarization in the ventricular myocardium begins almost immediately with QRS onset.

The denomination Early Repolarization Syndrome (ERS) is not correct if we define syndrome as a group of symptoms that collectively indicate or characterize a disease, psychological disorder, or other abnormal condition, or a complex of symptoms indicating the existence of an undesirable condition or quality. However, there is a third meaning of the term that could make the denomination of syndrome appropriate: a distinctive or characteristic pattern of behavior. A syndrome is a characteristic ECG pattern, and its behavior always or nearly always has a benign course.

We do not think the denomination Benign Early Repolarization (BER) is appropriate neither, because it indicates a type of given clinical evolution, and recent studies have cast a doubt about whether this electrocardiographic pattern is really benign. ERV may not always be benign and it can become a substrate for ventricular arrhythmias, sudden cardiac death (SCD), and hypercontractility cardiomyopathy in certain subjects, including certain high-performance athletes. Athletes with symptoms of syncope, especially in exertion, warrant a complete evaluation. The treatment of athletes and other individuals with life-threatening ventricular arrhythmias has been revolutionized by the implantable cardioverter defibrillator (ICD), a device that offers excellent protection from SCD. Defining those athletes who would benefit from an ICD is not always clear. Furthermore, participation in competitive athletics for athletes with life-threatening arrhythmias or structural heart disease known to put the athlete at risk for life-threatening arrhythmias is usually prohibited². Additionally ERV probably represents part of a

spectrum of cardiovascular anomalies related to nonischemic ST elevation, including Brugada syndrome (BrS), and that it may also have a molecular genetic origin of variable penetrance³.

The denomination Early Repolarization Pattern is correct, since it indicates that it is characterized by a given electrocardiographic pattern.

Therefore, we believe that the most appropriate denominations are Early Repolarization Variant or Early Repolarization Pattern, because both refer to the existence of a given electrocardiographic variant or pattern.

Others denominations

Early Repolarization (ER), early repolarization pattern, Benign Early Repolarization (BER), Early Repolarization Syndrome (ERS), Early premature repolarization.

Prevalence

ERV is found in approximately 1% to 2% of the young adult population and in up to 13%⁴ to 48%⁵ of patients presenting with chest pain in the emergency rooms and coronary care units.

ERV generally occurs in the absence of myocardial disease.

Gender

Predominance in young black males. Disproportionate infrequency in white females⁶. There are also male:female differences in BrS, ERV and SCD. The differences in the underlying mechanisms observed remain to be elucidated fully, but are likely to involve the influence of gonad steroids⁷.

Age. ERV is common in people under the age of 30 years old. There is a decreasing incidence with advancing age.

Race. Predominance in African-Americans descendants⁸. However a review of literature suggests that the pattern is equally frequent in all races.

Physical Activity. Predominant in more athletically active people and more infrequent in sedentary⁹.

Spinal cord injury. There is a higher prevalence of ERV in individuals with spinal cord injury at levels of injury that can disrupt central sympathetic command of the heart (at the C5 to C6 levels) with high vagal tone and loss of sympathetic tone¹⁰.

Electrocardiographic features:

Ventricular repolarization, as well as depolarization, is altered in young, healthy males with ERV compared to age-matched healthy controls. Ventricular depolarization and repolarization indices in ERV subjects are not associated to each other.

Heart rate

Predominant sinus bradycardia frequently associated with phasic sinus arrhythmia. Resting sinus bradycardia is a very common feature among athletes (89%) and only in 36% of cases of sedentary age-matched healthy controls¹¹.

PR interval

First degree AV block is observed in 5% to 39% among professional athletes. In the nonathlete population it is observed in 0.65% of cases. Shorter and depressed P-R interval is reported.

QRS axis

Vertical electrical axis is the rule¹². The frontal plane QRS axis and ST segment axis and T wave axis are all in the same direction.

QRS duration

This parameter is higher in ERV (90 ± 10 ms) subjects than in age-matched healthy controls (80 ± 10 ms)¹³. Contrarily, the mean QRS duration in BrS is 110 ± 2 ms. It is higher than in individuals with ERV who present a mean QRS duration of 90 ± 10 ms (up to 100 ms).

QRS morphology

Notching or slurring of the terminal QRS complex⁵. (**Figure 1**). A slur on the R wave. Prominent, relatively deep but narrow q waves may appear in the left precordial leads.

QRS voltage

Associated R waves are usually tall. Eventually, voltage criteria of Left ventricular hypertrophy are observed in male competitive athletes: $SV1+RV5 > 35$ mm (Sokolow index). High QRS voltage is more frequent in male athletes, but its correlation with left ventricular hypertrophy is low. Voltage decreases after deconditioning is slow. The distinction between the physiological athlete's heart and pathological conditions has critical implications for professional athletes. Criteria and guidelines for screening of athletes in competitive sports are recommended¹⁴.

An abrupt transition may occur from right-oriented complexes to left-oriented complexes in the precordial leads, secondary to counterclockwise rotation on precordial leads (**Figure 1**). About two-thirds of clockwise rotation and counterclockwise rotation could be attributed to the septal angle by anatomical rotation of the heart in one plane around the long axis, but other factors appear to be responsible for such ECG findings in the remaining one-third of cases. Relatively higher positions of the precordial ECG leads, as observed in the vertical heart, appeared to be responsible for clockwise rotation in some patients, and left septal fascicular block is suspected to be responsible for counterclockwise rotation in others patients¹⁵.

J-point elevation

Notching, irregular or slurring contour of the terminal QRS complex (J point). Variant of Osborn wave is seen in ERV. The Osborn wave arises from the R down stroke, frequently in V2 to V6. **(Figure 1)**

ST segment

Widespread ST segment elevation; (precordial greater than limb leads) **(Figure 1)**. The characteristic ST segment is elevated, upward, concave, confined more frequently in precordial leads, with reciprocal depression only in aVR. The concavity is observed at the initial up-sloping portion of ST segment or upwardly concave ST segment morphology. Unfortunately, concave ST morphology cannot be used to rule out ST elevation from acute myocardial infarction (AMI) with left anterior descending coronary occlusion because it is common in these circumstances¹⁶. The ST elevation is most frequently evident in ECG lead V4. There is a distinct J wave and ST segment in the left precordial leads V4 through V6. The ST elevation in ERV is usually < 2 mm (but can rarely be > 5 mm) in the precordial leads and the greatest ST elevation is usually seen in the mid-to-left precordial leads. The ST segment elevation is usually < 0.5 mm in the limb leads.

T wave characteristics. Concordant T waves of large amplitude (prominent, matching T waves), typical pseudo-asymmetrical ("symmetroid") or slightly asymmetrical, matching T waves often of large amplitude, upright, tall and peaked, most conspicuously from V₂ to V₄ or V₅, sometimes seen in leads DII, DIII and aVF as a rule. T waves may appear as of large amplitude, "peaked" or pointed, symmetric and matching. Vagotonic or high T wave voltages followed by U waves are frequent when sinus bradycardia is present. Tall, positive and symmetric or symmetroid T waves are not only seen occasionally in the very early stages of MI, but also in hyperkalemia and in ERV sinus bradycardia. **(Figure 1)**

QT intervals:

QT maximum: The maximum Q-onset-T-end interval. This parameter is higher in ERV subjects than in normal controls ¹³.

QTp maximum: maximum Q-onset-T-peak interval. This parameter is higher in ERV subjects than in age-matched healthy controls. (11.3)

Rate-corrected QTc maximum: This parameter is lower in ERV subjects than in age-matched healthy controls.

QTpc maximum: This parameter is lower in ERV subjects than in age-matched healthy controls.

U wave: because bradycardia U waves are frequent, in ERV they are best observed in the V3 lead. U waves are frequent when sinus bradycardia is present.

Other ECG characteristics of ERV

Relative temporal stability of the ST segment and T wave pattern is observed.

Reciprocal changes are not seen in ERV. There are no evolutionary short-term changes in the ST segment and T waves; and Q waves do not appear

Treadmill stress ECG

Exercise and isoproterenol tend to normalize the ST segment elevation. A progressive decrease in ST segment elevation and normalization of the ECG with mild exercise was a predictable response in patients who had ERV with otherwise normal ECGs and no history of cardiovascular disease. This phenomenon may be clinically useful as a bedside diagnostic tool in evaluating patients who present with ERV, otherwise normal ECGs, and negative cardiac history, in which the diagnosis of acute myocardial infarction/injury or pericarditis is being considered. These findings warrant formal evaluation in a prospective clinical trial⁶.

The presence of ERV does not preclude diagnosis of exercise-induced myocardial ischemia by treadmill testing, and coronary vaso-occlusive lesions may be demonstrated in some patients with the ERV pattern on ECG.

Vectocardiographic features in ERV (Figure 2)

- 1) VCG markers of spatial T amplitude: This parameter is higher in ERV subjects than in age-matched healthy controls.
- 2) Spatial QRS amplitude: This parameter is higher in ERV subjects than in age-matched healthy controls.
- 3) Spatial QRS-T angle: This parameter is higher in ERV subjects than in age-matched healthy controls.
- 4) A stable ECG pattern is a very important feature for differential diagnosis with AMI and pericarditis (both have dynamic ECG changes)¹⁷.

Other clinical characteristics

Negative cardiac injury markers;

Normal cardiac stress test or angiography.

Electrophysiological mechanism of ERV

In ERV, there is a voltage gradient but no **increased** dispersion of action potential duration (APD). That is why these patients show ST elevation but do not develop arrhythmias. ERV is not a proarrhythmic condition. In the ERV the I_{to} current is relatively small and consequent partial depression of the dome occurs without the development of phase 2 reentry. **Figure 3** shows the AP modifications in ERV.

J wave is associated with ERV and BrS. ST-segment elevation, as seen in BrS and acute coronary syndrome (ACS), cannot be fully explained by using the classical concept of an "injury

current" that flows from injured to uninjured myocardium. Rather, ST-segment elevation may be largely secondary to a loss of the AP dome in the epicardium, but not the endocardium¹⁸.

Madias¹⁹ reports a case of ERV with accelerated atrioventricular conduction (short PR interval) and incomplete right bundle branch block (IRBBB). These two features could represent ECG "correlates" of ERV, which are characterized by accelerated repolarization and depolarization, and are due to a rapid conduction through all or some component(s) of the atria/AV-node/His bundle/left bundle branch/left ventricle "chain," leading to a short PR interval and early and accelerated activation of the left ventricle, with resultant IRBBB. It is possible that the accelerated atrioventricular conduction and IRBBB could have also occurred in a patient who happened to have ERV. Finally, the occasional occurrence of morbidity and mortality in a patient with ERV does not mitigate (at least until we know more) the time-honored belief that the ERPV is, after all, a benign ECG variant. Similarly in BrS, probably we have both repolarization disorder (nonuniform abbreviation of RVOT epicardial cells) and depolarization disorder (conduction delay in the RVOT) in association. The first one is due to an imbalance between the depolarizing and repolarizing currents during phase 1 of the AP, most particularly in cells expressing a large, transient outward I_{to} current, such as the epicardial cells of the RVOT. In patients with loss-of-function **SCN5A** mutations that result in less I_{Na} during phase 1, the large I_{to} current may prematurely repolarize the membrane and produce a loss of the dome (phase 2) of the AP, that may generate phase 2 reentries, that can cause PVT/FV. The large transmural voltage gradients generated by the short AP in the RVPT epicardium are thought to be the basis of the ECG patterns of BrS (**Figure 4**). The second one is an alternative hypothesis for the ECG alterations based on right conduction delay in the RVOT as we observed in BrS VCGs²⁰. The mechanisms underlying the BrS ECG pattern are reviewed by Meregalli et al²¹.

Although ERV is considered benign, its arrhythmogenic potential still remains unknown. Recently Letsas et al²² reported the case of a 39-year-old male with a family history of sudden death and an ECG consistent with ERV.

The ST segment elevation is attributed to shortening of ventricular action potential in some epicardial regions. In partial support of this theory are the observations that exercise and sympathicomimetics (isoproterenol test) make the ST segment become isoelectric. In most cases this was accompanied by shorter QT and longer QTc intervals. The same effects were observed after physical exertion, but not after atropine or amyl-nitrite. Propranolol administration exaggerated ST elevation. Considering the mechanism with which isoproterenol acts and some analogies with the electrocardiographic picture experimentally obtained by means of the unilateral stimulation of the stellate ganglions, the hypothesis is advanced that the normal variant of ERV is related to an enhanced activity of the right sympathetic nerves²³⁻²⁴.

ERV is seen in individuals with high vagal tone, such as athlete's heart.

Central sympathetic dysfunction regularly results in multilead ST-segment elevation that decreases to or below isoelectric baseline during low dose isoproterenol infusion. Unlike normal subjects and individuals with normal variant ST-segment elevation, ST height is not altered by exercise. These findings document that ST-segment height in men is greatly influenced by

central sympathetic nervous activity, both at baseline and during physiological and pharmacological stress²⁵.

The duration of overlap between the onset of ventricular recovery and the end of the depolarization was determined by Mirvis using the body surface isopotential maps in young volunteers with ST segment elevation in absence of heart disease. The author's data suggest that (1) standard precordial leads do not accurately predict maximal torso potentials during ST segment, and (2) the degree of overlap between repolarization and depolarization is not a major determinant of precordial voltage. The author concludes that the rationale for the use of the term "early repolarization" to describe this clinical condition is not substantiated²⁶.

In experimental models, the ECG signature of ERV can be converted to that of the BrS, increasing the possibility that ERV may not be as always benign, and that under certain conditions known to predispose to ST-segment elevation, patients with ERV may be at greater risk. Further clinical and experimental data are necessary to test these hypotheses, and the characteristics of ERV need to be more fully delineated within the framework of what has been learned about the BrS in recent years¹.

T wave marks the phase 3 of ventricular repolarization and is a symbol of transmural dispersion of repolarization (TDR) in the ventricles. An excessively prolonged QT interval with enhanced TDR predisposes people to develop torsade de pointes. The malignant "R-on-T" phenomenon, i.e., an extrasystole that originates on the preceding T wave, is due to transmural propagation of phase 2 reentry or phase 2 early afterdepolarization²⁷.

A physiological U wave is thought to be due to delayed repolarization of the Purkinje system during phase 4. U wave occurs during phase 4 of monophasic action potential, i.e. it is recorded in the ECG simultaneously as phase 4 is occurring.

Differential diagnosis with ST segment elevation syndromes and J-wave syndrome

ERV is often misdiagnosed as ACS, BrS or other diseases that may involve elevated ST-segment, and careful examination of the ECGs, echocardiogram, troponin I and the patients' history of heart diseases may help differentiate this entity from these diseases²⁸. Clinical judgment, a meticulous clinical history, careful physical examination, the ECG and echocardiogram analysis play a key role in the differential diagnosis. Furthermore patients with ERV and without cardiac disease can avoid unnecessary and potentially harmful procedures such as fibrinolysis and coronary angiography. Fortunately, emergency physicians show a low rate of ECG misinterpretation in patients with chest pain and ST-segment elevation. The clinical consequences of this misinterpretation are minimal²⁹.

The presence of S-T elevation in a patient with chest pain of possible cardiac origin mandates hospitalization and cardiac monitoring, even if the ECG may confirm a classic pattern of ERV; in this context, the diagnosis of ERV is one of exclusion. Recognition of this clinical entity and the use of previous ECGs for comparison would in most cases forestall the administration of thrombolytic agents to patients with S-T segment elevation due to ERV³⁰. Although its

diagnostic information is essential, other non-invasive laboratory tests are sometime needed, such as the treadmill stress ECG, serial bioenzymatic markers (enzymes, cardiac troponin I (cTnI), myosin light chain-(MLC-1), and creatine kinase-MBmass), and myocardial perfusion scintigraphy (SPECT and Gated-SPECT) at rest or under physical or pharmacologic stress¹.

Brady et al²⁹ concluded that AMI is not the commonest cause of ST segment elevation in chest pain patients from a university hospital emergency department. LVH is most often responsible for electrocardiographic ST segment elevation followed by AMI and LBBB, which occur at equal frequencies.

Table 1 shows the less common causes of ST segment elevation

1) BrS;

2) Idiopathic ventricular fibrillation related to a prominent J wave in the inferior leads (a variant of BrS with ST-segment elevation in the inferior leads but no coved or saddleback ST-segment elevation in the right precordial leads.)³¹ Gussak³² named this wave as lambda wave due to its morphology;

3) Arrhythmogenic Right Ventricular Dysplasia: Sometimes, the electrocardiographic phenotype is impossible to differentiate from the electrocardiographic pattern in BrS³³⁻³⁴. In these cases, observed in the so-called minor or concealed forms, only magnetic nuclear resonance is useful in differentiating both entities;

4) J wave syndrome:

(4.1) J wave in hypothermal patients

(4.2) J wave in normothermal patients³⁵.

(4.2.A) Nervous system injuries: acute brain injury, i.e. subarachnoid hemorrhage, cardiac arrest, and dysfunction of cervical sympathetic system³⁶.

(4.2.B) Extreme hypercalcemia³⁷⁻³⁸⁻³⁹⁻⁴⁰⁻⁴¹⁻⁴².

5) Marked hyperpotassemia⁴³.

6) Myocardial bridging of the left anterior descending artery⁴⁴.

7) Mitral valve prolapse syndrome⁴⁵;

8) Prinzmetal's angina secondary to coronary artery spasm: reversible ST segment elevation⁴⁵.

9) Acute Aortic dissection of the ascending aorta (type A)⁴⁶.

11) Transient left ventricular apical ballooning syndrome, Transient apical ballooning syndrome without coronary stenosis, Tako-tsubo cardiomyopathy or "broken heart": an acute and unique cardiac syndrome characterized by typical ischemic chest symptoms (chest pain or dyspnea), with ECG that shows ST-segment elevation and T-wave inversion, and minor elevated cardiac enzyme levels. Cardiac catheterization reveals absence of coronary stenosis.

Left ventriculography and cardiac magnetic resonance imaging shows apical akinesia and compensatory hypercontractility of the basal ventricular segments (apical ballooning). Left ventricular systolic function recovers from ejection fraction. Wall abnormalities return to

normal can occur after as long as 3 months. This new clinical entity may have a catecholamine-mediated neurogenic mechanism as the etiopathogenic substrate.

12) Acute Myocarditis or myopericarditis⁴⁷.

13) Chagasic cardiomyopathy⁴⁸.

14) Hypertrophic cardiomyopathy: The electrocardiographic features of hypertrophic cardiomyopathy are numerous, including ST segment elevation that may simulate other ST segment elevation syndromes⁴⁹.

15) After mitral valvuloplasty⁵⁰.

16) Septic noncardiogenic shock⁵¹.

17) Cardiac tumor⁵².

18) Acute pancreatitis: It is considered a stress-related cardiomyopathy similar to transient apical ballooning syndrome without coronary stenosis⁵³. More than 50% of the patients with acute pancreatitis have ECG abnormalities, and these changes could be related also to electrolyte alterations⁵⁴.

19) Anaphylactic reaction/anaphylactic shock⁵⁵.

20) Gallbladder disease: acute cholecystitis or biliary colic may be associated with angina pectoris, arrhythmias, or nonspecific ST-T wave changes on the ECG. A vagally mediated cardio-biliary reflex is the presumed cause of these changes. The signs and symptoms of gallbladder and heart disease may overlap, making diagnosis difficult⁵⁶.

MAIN DIFFERENTIAL DIAGNOSIS

1) Acute Coronary Syndrome:

The diagnosis of ACS in patients presenting to the emergency department with chest pain is still challenging. The most important differential diagnoses to ERV are pericarditis and ACS⁴⁻¹⁷.

It is necessary and very important to consider the history, the symptoms, the laboratory findings and the serial ECGs. On adult chest pain patients, ST segment elevation criteria that include reciprocal changes identify patients who stand to benefit most from early interventional strategies. Fifty-one percent of patients whose prehospital 12-lead ECG met 1 mm or more ST segment elevation criteria had non-acute myocardial infarction (AMI) diagnoses. ST segment elevation alone lacks the positive predictive value necessary for reliable prehospital AMI diagnosis. Inclusion of reciprocal changes in prehospital ECG myocardial infarction criteria improved the positive predictive value to more than 90% and included a significant majority (62% to 86%) of AMI patients with ST segment elevation who received thrombolytic therapy within five hours after hospital arrival⁵⁷.

The ST elevation on the resting ECG can be either a sign of acute ischemia or evolving AMI.

There is a case report in a patient with myocardial bridging of the left anterior descending artery with the combined electrocardiographic abnormality of Brugada-like or ERV, which was misdiagnosed as AMI⁴⁴.

2) Acute Pericarditis

It provokes subepicardial mural injury of the atria, leading to a STa vector. PR segment depression, a manifestation of atrial injury, may be seen.

Because the atria walls are thin, the vector points to the opposite direction of the P Vector. This produces depression of the PR segment. This slightly descending segment between the end of the P wave and the onset of QRS complex is typical of acute pericarditis and is found in about 50% of cases. PR depression is generally seen in leads V3 to V5 and sometimes in the frontal leads.

Depression of the PR segment is very specific of acute pericarditis and is attributed to subepicardial atrial injury and occurs in all leads except aVR and V1. These leads may exhibit PR-segment elevation⁵⁸.

No reciprocal ST segment depression is observed (except in aVR and V1). This is an important feature differentiating acute pericarditis from AMI.

In Acute pericarditis the ST segment elevation is generally 1-2 mm and rarely exceeds 2.3 mm. There is a concave upwards ST elevation in most leads.

Acute pericarditis has 3 stages:

Stage I: Diffuse concave-upward ST-segment elevation with concordance of T waves; ST-segment depression in aVR or V1; PR-segment depression; low voltage; absence of reciprocal ST-segment changes

Stage II: ST segments return to baseline; T-wave flattening

Stage III: T-wave inversion

Stage IV: Gradual resolution of T-wave inversion.

All 4 stages are present in only 40% to 50% of patients or less.

Stage One ST segment deviations are virtually diagnostic of acute pericarditis when typically distributed among limb and precordial ECG tracings. Atypical ECG responses include absence of ST deviations, which conceal the diagnosis, and restricted distribution of ST deviations, which suggests myocardial injury.

Among 44 consecutive patients with acute pericarditis, 19 (43%) had atypical ECGs. Although all 19 had a pericardial rub, eight had no ST deviations in the limb leads and seven developed no ST changes, including three with no ECG abnormalities of any kind. Patients with typical ECGs by ST segment criteria were more likely to progress to T wave inversion. PR segment deviations occurred in 14 patients with typical, and 14 with atypical ECGs. In four of the latter, the PR segment shifts were the only ECG sign. Presence or absence of heart disease and etiology of pericarditis could not be statistically associated with particular electrocardiographic responses⁵⁹

The ST vector on the Frontal plane in acute pericarditis is situated between +30 to + 70°; thus, there is ST segment elevation in DI, DII and aVF, and ST depression on the aVR lead. There may be isoelectric or slight elevation in leads aVL and DIII, depending on the ST vector,

pointing more to the right or more to the left. On precordial leads ST elevation is observed in all leads from V2 to V6; and in V1 it may be depressed.

Unlike ERV, T waves are usually of low amplitude, and heart rate is usually increased.

T-wave inversion developed in stage III of acute pericarditis and subacute pericarditis in the majority of cases and is generally symmetric. T wave negativity is best seen in the precordial leads V3 to V6. T wave negativity in pericarditis develops after the ST segment has returned to the isoelectric line.

An ST/T ratio greater than or equal to 0.25 in lead V6 identified the patients with pericarditis and excluded normal variant⁶⁰.

The ST/T ratio greater than 0.25 in V4, V5 is also a significant discriminator. Thus, if V6 is unavailable, an ST/T ratio greater than or equal to 0.24 in V5, V4 or DI is highly suggestive of acute pericarditis. Ratio of the amplitude of the onset of the ST segment to the amplitude of the T wave in V6 lead. An ST/T ratio greater than or equal to 0.25 discriminates the ECGs of all patients with acute pericarditis from ERV.

Exercise testing is contraindicated during active pericarditis because of the possibility of myocarditis. In a patient suspected of having ischemic heart disease, a pericardial rub appeared for the first time following a maximal exercise test, during which the elevated J-points descended to baseline.

Transient, exercise-induced ST elevation has been reported to occur in conjunction with acute pericarditis and may be mistaken for ischemic pain in the acute care setting. Patients with known pericarditis are usually not subjected to stress testing because of the possibility of myocarditis. When the diagnosis is uncertain, however, persistence of ST elevation in response to exercise stress testing may aid in the distinction between pericarditis and ERV inasmuch as in the latter condition, ST elevation returns to the isoelectric line⁶¹. Exercise-induced resolution of ST elevation, however, although uncommon, may occur in pericarditis⁶².

A T-wave amplitude in lead V6 of less than or equal to 0.3 mV diagnosed acute pericarditis. The ratio of the amplitude of the onset of the ST segment to the apex of the T wave in that lead (ST/T ratio in V6) proved to be the most reliable discriminator. Only lead V6 is used. If $A/B > 25\%$, suspect pericarditis. If $A/B < 25\%$, suspect ERV. This is calculated by dividing the millimeters of ST-segment elevation by the millimeters to the tallest point of the T wave. Each value is measured from the isoelectric point⁶⁰. If V6 is unavailable, an ST/T ratio greater than or equal to 0.24 in V5, V4 or I is highly suggestive of acute pericarditis. An ST/T ratio greater than or equal to 0.25 in V6 discriminated the ECGs of all patients with acute pericarditis from normal variants

3) BrS:

The ERV shares remarkable cellular, ionic, and electrocardiographic similarities with the BrS and idiopathic ventricular fibrillation (a variant of the BrS with ST-segment elevation in inferior leads) ²².

ST-segment elevation in an apparently structurally normal heart is associated with an ECG J wave, which can be observed in the ERV, idiopathic ventricular fibrillation (VF), and BrS⁶³. In ERV, there is a voltage gradient but no increased dispersion of APD.

POSSIBLE SIMILARITIES BETWEEN ERV AND BrS

- 1) More frequent in males;
- 2) Both occur more frequently in young adults and in individuals without apparent structural heart disease;
- 3) Both may influence just the V₁-V₂ leads: Rarely (9%), can ST elevation be observed in ERV only in the right precordial leads: V₁-V₂, or in the inferior ones⁴.

When ST elevation is normal, it can reach up to 3 mm in V₂-V₃, especially in young people. In those individuals over 40 years, it seldom exceeds 2 mm. Both can show incomplete RBBB pattern or right bundle branch conduction disorder: in BrS, it can present atypical features, RBBB-like and of the saddle type by exclusive elevation of the J point. S wave with delay in the left leads: DI, aVL, V₅ and V₆, could be absent as it is to be expected in a classic RBBB. The elements considered as typical in BrS are: 1) elevation of the terminal part of QRS (prominent J wave); 2) elevated and descending ST, not related to lesion of ischemic (idiopathic) injury; 3) negative T wave in the right precordial leads; 4) normal QTc; 5) absence of final delay in left leads as it would be expected in a classic RBBB⁶⁴.

In ERV, when associated to athlete's heart, QRS can present a moderate extension (100 ms to 110 ms) in 15% of the cases, which in nonathlete, normal population, in a 2.4% is called outflow tract hypertrophy. In this case r' does not exceed the 5 mm and is lower than S in the same lead: rSr';

- 4) Both may improve repolarization during the stress test with use of isoproterenol;
- 5) Both respond to a shortening of AP phase 2 in a part of ventricular thickness, and intensification of fast repolarization notch (phase 1) mediated by transmural dispersion of ventricular repolarization by a larger notch in the I_{to} channel⁶⁵.
- 6) The alteration of the I_{to} and I_{Ca²⁺-L} channels in BrS and in ERV are the electrophysiologic substrate that explains the J point and ST segment elevation, because they cause the intensified notch in phase 1 and suppression in phase 2 duration in the epicardium and in the endocardium of ventricular wall thickness.

Elements for differential diagnosis:

1) Family background

ERV: negative

BrS: frequently positive

2) Race:

ERV: predominantly in African descendents⁶⁶.

BrS: predominantly in Asian (58%) and Caucasian people⁶⁷.

3) Response to IC group antiarrhythmic agents:

BrS: flecainide, used in a 10 mg/Kg dosage in 10 minutes, increases ST elevation and QRS duration in a more significant way in patients with BrS than in individuals without the entity, and only in those it triggers ventricular extrasystoles⁶⁸.

ERV: it can induce a pattern similar to BrS; however, the degree of ST elevation caused by the drug is much higher in patients with BrS than in patients without the disease.

Table 2 makes a comparison among ERV, acute pericarditis, AMI and BrS.

Comparison of ECG changes associated with ERV, Acute Pericarditis, Myocardial Infarction and BrS

	ERV	ACUTE PERICARDITIS	AMI	BrS type 1
ST segment appearance	Concave to the top	Concave to the top	Concave to the top	Convex to the top
Pathological Q waves	Absent.	Absent.	Present.	Absent.
Mirror image changes	Only in aVR	Absent.	Present.	Possible.
Leads involved	Limb and precordial	Limbs and precordial	Segmentary pattern	Right precordial.
R voltage	Normal or minimally augmented	Normal	Lost	Normal.
PR interval	Not affected	Possible depression	Variable	50% prolongation.
ST/T ratio in lead V6	<0.25	>0.25	Not applicable.	Not applicable.

4) J-WAVE SYNDROME

J wave is associated with ERV and BrS. ST-segment elevation, as seen in BrS and ACS, cannot be fully explained by using the classic concept of an "injury current" that flows from injured to uninjured myocardium. Instead, ST-segment elevation may be largely secondary to a loss of the AP dome in the epicardium, but not the endocardium¹⁸.

The syndrome shares remarkable cellular, ionic, and electrocardiographic similarities with BrS and idiopathic ventricular fibrillation (a variant of BrS with ST-segment elevation in inferior leads)²².

ST-segment elevation in an apparently structurally normal heart is associated with an ECG J wave, which can be observed in ERV, idiopathic VF, and BrS⁶³. In ERV, there exists a voltage gradient but no increased dispersion of APD.

References

- 1) Gussak I, Antzelevitch C. Early repolarization syndrome: Clinical characteristics and possible cellular and ionic mechanisms. *J Electrocardiol.* 2000; 33: 299-309.
- 2) Link MS, Wang PJ, Estes NA 3rd. Ventricular arrhythmias in the athlete. *Curr Opin Cardiol* 2001; 16:30-39.
- 3) Boineau JP. The early repolarization variant--normal or a marker of heart disease in certain subjects. *J Electrocardiol.* 2007; 40: 3.e11-16.
- 4) Hasbak P, Engelmann MD. Early repolarization. ST-segment elevation as a normal electrocardiographic variant. *Ugeskr Laeger.* 2000; 162: 5928-5929.
- 5) Brady WJ, Chan TC. Electrocardiographic manifestations: benign early repolarization. *J Emerg Med.* 1999; 17:473-478.
- 6) Spratt KA, Borans SM, Michelson EL. Early repolarization: normalization of the electrocardiogram with exercise as a clinically useful diagnostic feature. *J Invasive Cardiol.* 1995; 7:238-242.
- 7) James AF, Choisy SC, Hancox JC. Recent advances in understanding sex differences in cardiac repolarization. *Prog Biophys Mol Biol.* 2007; 94: 265-319.
- 8) Saviolo R, Spodick HD. Electrocardiographic responses to maximal exercise during acute pericarditis and early repolarization. *Chest* 1986; 90: 460-462.
- 9) Klatsky AL, Oehm R, Cooper RA, Udaltsova N, Armstrong MA. The early repolarization normal variant electrocardiogram: correlates and consequences. *Am J Med.* 2003; 115:171-177.
- 10) Marcus RR, Kalisetti D, Raxwal V, Kiratli BJ, Myers J, Perakash I, Froelicher VF. Early repolarization in patients with spinal cord injury: prevalence and clinical significance. *J Spinal Cord Med.* 2002; 25:33-38.
- 11) Bianco M, Bria S, Gianfelici A, Sanna N, Palmieri V, Zeppilli P. Does early repolarization in the athlete have analogies with the Brugada syndrome? *Eur Heart J* 2001; 22:504-510.
- 12) Mehta M, Jain AC, Mehta A. Early repolarization. *Clin Cardiol.* 1999; 22:59-65.
- 13) Dilaveris P, Pantazis A, Gialafos E. Assessment of ventricular repolarization alterations in subjects with early repolarization. *Int J Cardiol.* 2004; 96: 273-279.
- 14) Chee CE, Anastassiades CP, Antonopoulos AG. Cardiac hypertrophy and how it may break an athlete's heart--the Cypriot case. *Eur J Echocardiogr.* 2005; 6: 301-307.
- 15) Tahara Y, Mizuno H, Ono A, Ishikawa K. Evaluation of the electrocardiographic transitional zone by cardiac computed tomography. *J Electrocardiol.* 1991; 24: 239-245.

- 16) Smith SW. Upwardly concave ST segment morphology is common in acute left anterior descending coronary occlusion. *J Emerg Med.* 2006; 31: 69-77.
- 17) Turnipseed SD, Bair AE, Kirk JD, Diercks DB, Tabar P, Amsterdam EA. Electrocardiogram differentiation of benign early repolarization versus acute myocardial infarction by emergency physicians and cardiologists. *Acad Emerg Med.* 2006; 13:961-966.
- 18) Yan GX, Lankipalli RS, Burke JF, Musco S, Kowey PR. Ventricular repolarization components on the electrocardiogram: cellular basis and clinical significance. *J Am Coll Cardiol.* 2003; 42: 401-409.
- 19) Madias JE. Early repolarization associated with accelerated atrioventricular conduction (short PR interval) and incomplete right bundle branch block: postulated mechanisms. *J Electrocardiol.* 2007 Jul 11; [Epub ahead of print].
- 20) Perez Riera AR, Schapachnick E, Dubner S, Zhang L. The Characteristic Vectorcardiographic Changes in Patients with Brugada Syndrome Supplement to JACC Journal of the American College of Cardiology pp: 31A ABSTRACTS- Cardiac Arrhythmias; March 6, Volume 49, No. 9 (Supplement A) 2007 1.00 p.m. Presented at American College of Cardiology 56th. Annual Scientific Session www.onlinehacc.org.
- 21) Meregalli PG Pathophysiological mechanisms of Brugada syndrome: depolarization disorder, repolarization disorder, or more? *Cardiovasc Res.* 2005;67:367-378.
- 22) Letsas KP, Efremidis M, Pappas LK, Gavrielatos G, Markou V, Sideris A, Kardaras F. Early repolarization syndrome: is it always benign? *Int J Cardiol.* 2007; 114: 390-392.
- 23) Morace G, Padeletti L, Porciani MC. Effect of isoproterenol on the "early repolarization" syndrome. *Am Heart J.* 1979; 97:343-347.
- 24) Ziesenhenn K, Metzner C. Problems of so-called functional ECG changes. *Z Gesamte Inn Med.* 1982; 37:155-158.
- 25) Lehmann KG, Shandling AH, Yusi AU. Altered ventricular repolarization in central sympathetic dysfunction associated with spinal cord injury. *Am J Cardiol.* 1989; 63:1498-1504.
- 26) Mirvis DM. Evaluation of normal variations in S-T segment patterns by body surface isopotential mapping: S-T segment elevation in absence of heart disease. *Am J Cardiol.* 1982; 50:122-128.
- 27) Hlaing T, DiMino T, Kowey PR, Yan GX. ECG repolarization waves: their genesis and clinical implications. *Ann Noninvasive Electrocardiol.* 2005; 10:211-223.
- 28) Guo ZG, Peng J, Meng SR, Wang P. Differential diagnosis of early repolarization syndrome in patients with ST-segment elevation: report of 5 cases. *Di Yi Jun Yi Da Xue Xue Bao.* 2002; 22: 1033.
- 29) Brady WJ, Perron A, Ullman E. Errors in emergency physician interpretation of ST-segment elevation in emergency department chest pain patients. *Acad Emerg Med.* 2000; 7:1256-1260.
- 30) Eastaugh JA. The early repolarization syndrome. *J Emerg Med.* 1989; 7: 257-262.

- 31) Riera AR, Ferreira C, Schapachnik E. Brugada syndrome with atypical ECG: downsloping ST-segment elevation in inferior leads. *J Electrocardiol.* 2004; 37:101-104.
- 32) Gussak I, Bjerregaard P, Kostis J. Electrocardiographic "lambda" wave and primary idiopathic cardiac asystole: a new clinical syndrome? *J Electrocardiol.* 2004; 37:105-107.
- 33) D'Onofrio A, Cuomo S, Musto B, Boccalatte A. Right bundle branch block, persistent ST-segment elevation in V1-V3 and sudden cardiac death: always a distinct syndrome? *G Ital Cardiol.* 1995; 25:1171-1175.
- 34) Corrado D, Nava A, Buja G, et al. Familial cardiomyopathy underlies syndrome of right bundle branch block, ST segment elevation and sudden death. *J Am Coll Cardiol* 1996, 27: 443-448.
- 35) Burali A, Porciello PI. Osborn wave in normothermic patients? *G Ital Cardiol.* 1991; 21:1005-1009.
- 36) Carrillo-Esper R, Limon-Camacho L, Vallejo-Mora HL, Contreras-Dominguez V, Hernandez-Aguilar C, Carvajal-Ramos R, Salmeron-Najera P. Non-hypothermic J wave in subarachnoid hemorrhage *Cir Cir.* 2004; 72:125-129.
- 37) Kraus F: Ueber die Wirkung des Kalziums auf den Kreislauf. *Dtsch Med Wochenschr* 1920; 46:201-203.
- 38) Sridharan, MR, Horan LG.: Electrocardiographic J waves of hypercalcemia. *Am J. Cardiol* 1984; 54:672-673.
- 39) Jenkins JK, Best TR, Nicks SA, Murphy FY, Bussell KL, Vesely DL. Milk-alkali syndrome with a serum calcium level of 22 mg/dl and J waves on the ECG. *South Med J.* 1987; 80: 1444-1449.
- 40) Ahmed R, Yano K, Mitsuoka T, Ikeda S, Ichimaru M, Hashiba K. Changes in T wave morphology during hypercalcemia and its relation to the severity of hypercalcemia. *J Electrocardiol.* 1989; 22: 125-132.
- 41) Otero J, Lenihan DJ. The "normothermic" Osborn wave induced by severe hypercalcemia. *Tex Heart Inst J.* 2000; 27: 316-317.
- 42) Topsakal R, Saglam H, Arinc H, Eryol NK, Cetin S. Electrocardiographic J wave as a result of hypercalcemia aggravated by thiazide diuretics in a case of primary hyperparathyroidism. *Jpn Heart J.* 2003; 44:1033-1037.
- 43) Ortega-Carnicer J, Benezet J, Ruiz-Lorenzo F, Alcázar R. Transient Brugada-type electrocardiographic abnormalities in renal failure reversed by dialysis. *Resuscitation.* 2002; 55:215-219.
- 44) Ozeke O, Aras D, Deveci B, Yildiz A, Maden O, Selcuk MT. Brugada-like early repolarization pattern misdiagnosed as acute anterior myocardial infarction in a patient with myocardial bridging of the left anterior descending artery. *Mt Sinai J Med.* 2006; 73:627-630.

- 45) Mautner RK, Katz GE, Iteld BJ, Phillips JH. Coronary artery spasm: a mechanism of chest pain in selected patients with the mitral valve prolapse syndrome. *Chest*. 1981; 79: 449-453.
- 46) Bonnefoy E, Godon P, Kirkorian G, Chabaud S, Touboul P. Significance of serum troponin I elevation in patients with acute aortic dissection of the ascending aorta. *Acta Cardiol*. 2005; 60:165-170.
- 47) Thanjan MT, Ramaswamy P, Lai WW, Lytrivi ID. Acute myopericarditis after multiple vaccinations in an adolescent: case report and review of the literature. *Pediatrics*. 2007; 119:1400-1403.
- 48) Rodriguez-Salas LA, Klein E, Acquatella H, Cataliotti F, Davalos V V, Gomez-Mancebo JR, Gonzalez H, Bosch F, Puigbo JJ. Echocardiographic and Clinical Predictors of Mortality in Chronic Chagas' Disease. *Echocardiography*. 1998;15:271-278.
- 49) Khan IA, Ajatta FO, Ansari AW. Persistent ST segment elevation: a new ECG finding in hypertrophic cardiomyopathy. *Am J Emerg Med*. 1999; 17: 296-299.
- 50) Ludman PF, Hildick-Smith D, Harcombe A, Shapiro LM. Transient ST-segment changes associated with mitral valvuloplasty using the Inoue balloon. *Am J Cardiol*. 1997; 79: 1704-1705.
- 51) Tomcsányi J, Somló M, Szabó M, Zsoldos A, Marosi A, Bózsik B. Acute ST segment elevation during noncardiogenic shock *Orv Hetil*. 2005; 146:971-974.
- 52) Matana A, Zaputović L, Lucin K, Kastelan ZM. Persistent and progressive ST segment elevation caused by myocardial metastasis. *Tumori*. 2006; 92:452-454.
- 53) Sankri-Tarbichi AG, Mathew PK, Matos M, Hsi D. Stress-related cardiomyopathy. *Heart Lung*. 2007; 36:43-46.
- 54) Rubio-Tapia A, García-Leiva J, Asensio-Lafuente E, Robles-Díaz G, Vargas-Vorácková F. Electrocardiographic abnormalities in patients with acute pancreatitis. *J Clin Gastroenterol*. 2005; 39: 815-818.
- 55) Gikas A, Lazaros G, Kontou-Fili K. Acute ST-segment elevation myocardial infarction after amoxicillin-induced anaphylactic shock in a young adult with normal coronary arteries: a case report. *BMC Cardiovasc Disord*. 2005;5:6.
- 56) Krasna MJ, Flancbaum L. Electrocardiographic changes in cardiac patients with acute gallbladder disease. *Am Surg*. 1986;52:541-543.
- 57) Otto LA, Aufderheide TP. Evaluation of ST segment elevation criteria for the prehospital electrocardiographic diagnosis fo acute myocardial infarction. *Ann Emerg Med*. 1994; 23:17-24.
- 58) Spodick DH. Diagnostic electrocardiographic sequences in acute pericarditis. Significance of PR segment and PR vector changes. *Circulation* 1973; 48:575-580.
- 59) Bruce MA, Spodick DH. Atypical electrocardiogram in acute pericarditis: characteristics and prevalence. *J Electrocardiol*. 1980; 13:61-66.
- 60) Ginzton LE, Laks MM. The differential diagnosis of acute pericarditis from the normal variant: new electrocardiographic criteria. *Circulation*. 1982; 65:1004-1009.

- 61) Chapman DW, Overholt E. Acute benign idiopathic pericarditis; a report of twenty cases. *AMA Arch Intern Med.* 1957; 99:708-715.
- 62) Finkelhor RS, Newhouse KE, Vrobel TR, Miron SD, Bahler RC. The ST segment/heart rate slope as a predictor of coronary artery disease: comparison with quantitative thallium imaging and conventional ST segment criteria. *Am Heart J.* 1986; 112:296-304.
- 63) Shu J, Zhu T, Yang L, Cui C, Yan GX. ST-segment elevation in the early repolarization syndrome, idiopathic ventricular fibrillation, and the Brugada syndrome: cellular and clinical linkage. *J Electrocardiol.* 2005; 38(4 Suppl): 26-32.
- 64) Hiss RG, Lamb LE. Electrocardiographic findings in 122,043 individuals. *Circulation* 1962; 25:947-961.
- 65) Antzelevitch Ch, Xin Yan G, Shimuzi W, et al. Electrical heterogeneity, the ECG, and Cardiac Arrhythmias. In Zipes DP, Jalife J *Cardiac Electrophysiology From Cell to Bedside*, Third Edition. W.B. Saunders Company.2000. Chapter 26 p: 222-238.
- 66) Grusin H. Peculiarities of the African's electrocardiogram and the changes observed in serial studies. *Circulation* 1954; 9: 860-867.
- 67) Nademanee K, Veerakul G, Nimmannit S, Chaowakul V, Bhuripanyo K, Likittanasombat K, Tunsanga K, Kuasirikul S, Malasit P, Tansupasawadikul S, Tatsanavivat P. Arrhythmogenic marker for the sudden unexplained death syndrome in Thai men. *Circulation.* 1997; 96:2595-2600.
- 68) Shimizu W, Antzelevitch C, Suyama K, Kurita T, Taguchi A, Aihara N, Takaki H, Sunagawa K, Kamakura S. Effect of sodium channel blockers on ST segment, QRS duration, and corrected QT interval in patients with Brugada syndrome. *J Cardiovasc Electrophysiol* 2000; 11:1320-1329.

Figure 1

ECG OF EARLY REPOLARIZATION VARIANT

Name: S. D. C.

Date: 03/26/2001

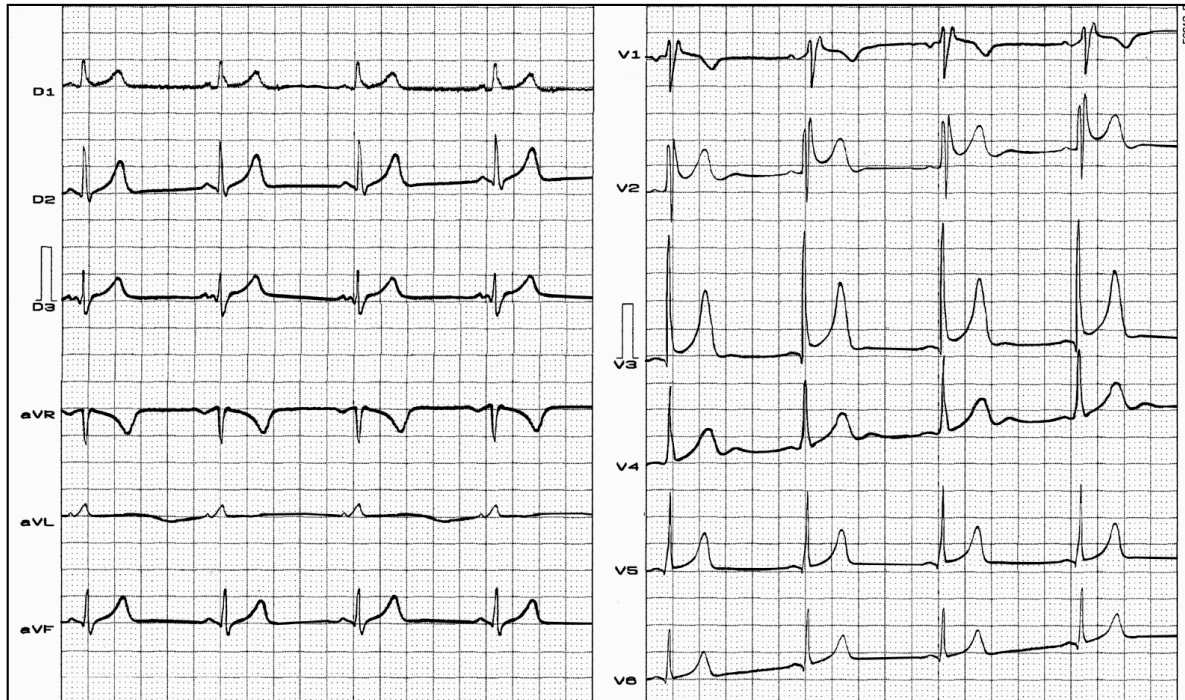
Age: 28 y.

Sex: M.

Race: Caucasian.

Weight: 62 Kg .

Height: 1.70 m



Clinical diagnosis: Mitral valve prolapse. Early Repolarization Variant. Pseudo Brugada Type 2 pattern. Pseudo IRBBB. QRS with triphasic rSr' pattern in V1 lead. We observe in V2 and V3 contiguous leads ST segment elevation upwardly concave equal or higher ≥ 2 mm.

Conclusion: ECG of Early Repolarization Variant.

Figure 2

ECG/VCG CORRELATION ON HORIZONTAL PLANE

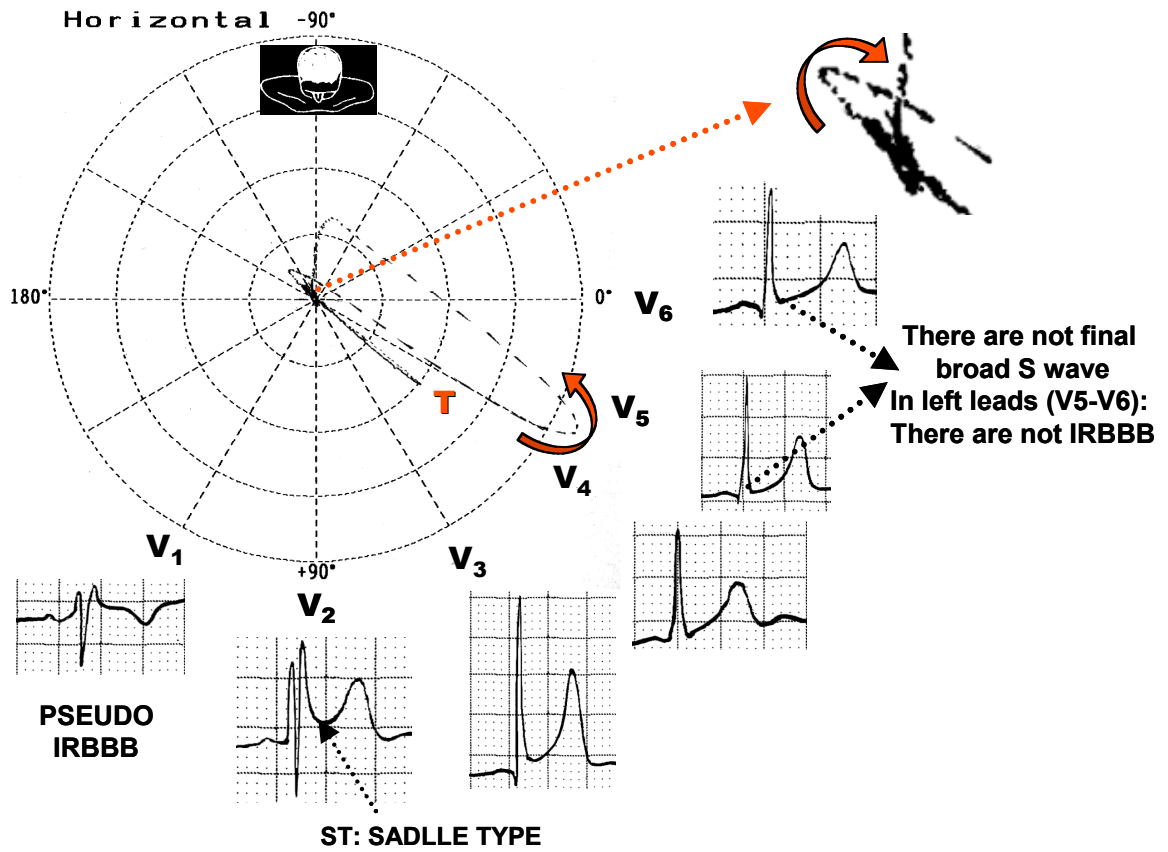


Figure 3

CHARACTERISTICS OF ACTION POTENTIAL IN EARLY REPOLARIZATION VARIANT
AND ECG CORRELATION

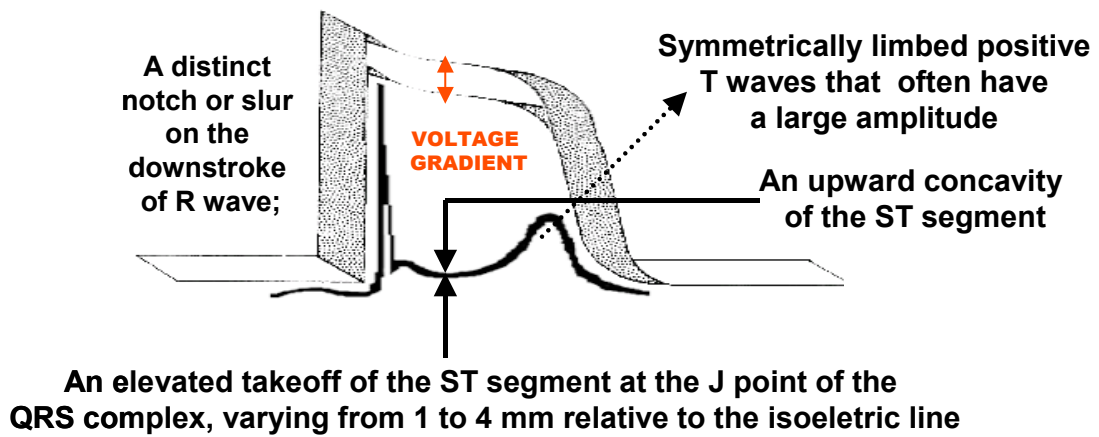


Figure 4

CHARACTERISTICS OF ACTION POTENTIAL IN BRUGADA SYNDROME

