

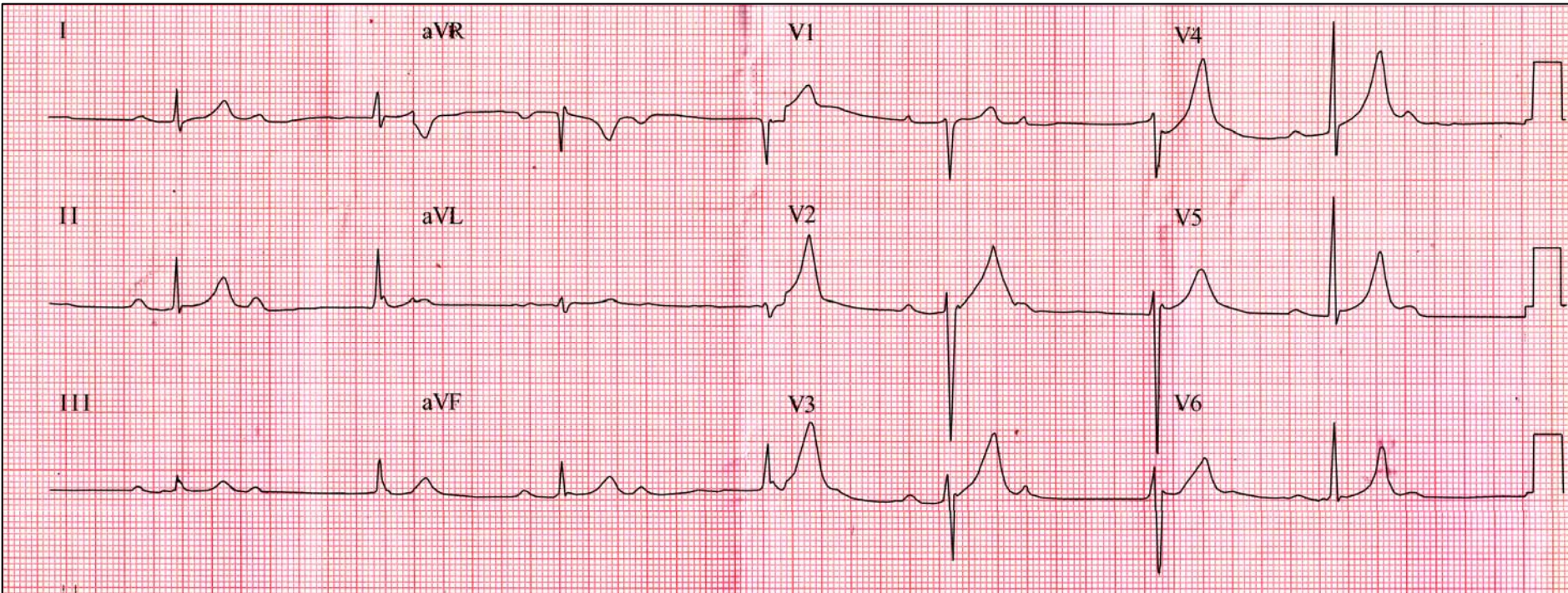
THIRD DEGREE AV BLOCK WITH HIGH OR HISIAN COMMAND (TYPICAL OF CONGENITAL FORMS)

Name: DAMP
Weight: 71 Kg

Sex: Male
Height: 1.75 m

Age: 21 y.
Date: 20/10/2003

Race: Caucasian



Clinical diagnosis: Congenital complete AV block.

ECG diagnosis: atrial HR: 81bpm, QRS duration; 78bpm, Ventricular command with a higher rate, narrow QRS complex QT: 604ms; QTc: 528ms; tall T waves, probably normal for age.

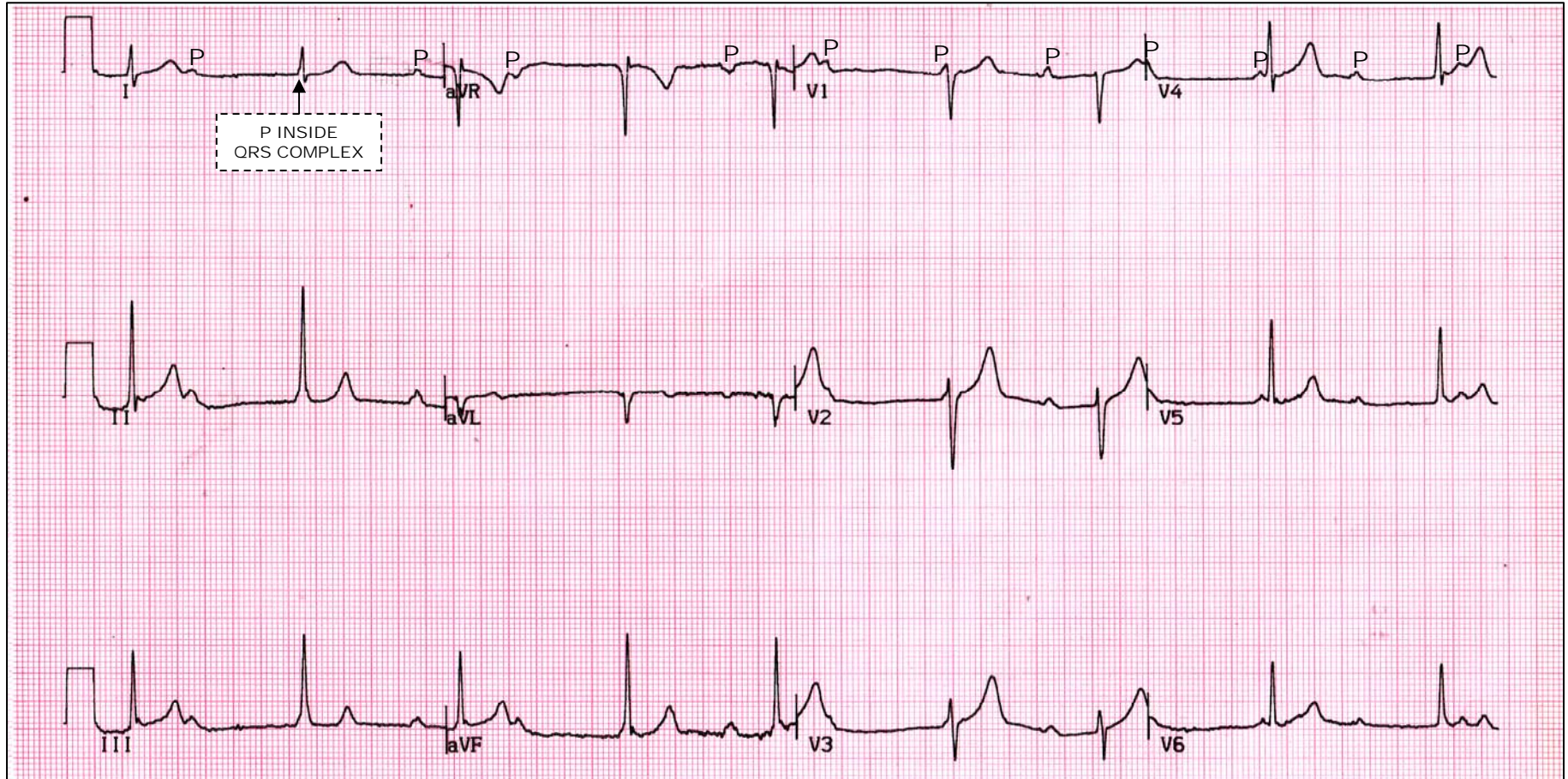
THIRD DEGREE AV BLOCK WITH HIGH OR HISIAN COMMAND (TYPICAL OF CONGENITAL FORMS) THE SAME PATIENT 3 YEARS LATER

Name: DAMP
Weight: 70 Kg

Sex: Male
Height: 1.75 m

Age: 24 y.
Date: 20/10/2006

Race: Caucasian



Clinical diagnosis: Congenital complete AV block.

ECG diagnosis: ventricular HR: 48bpm, QRS duration: 78ms, atrial HR: 81bpm.