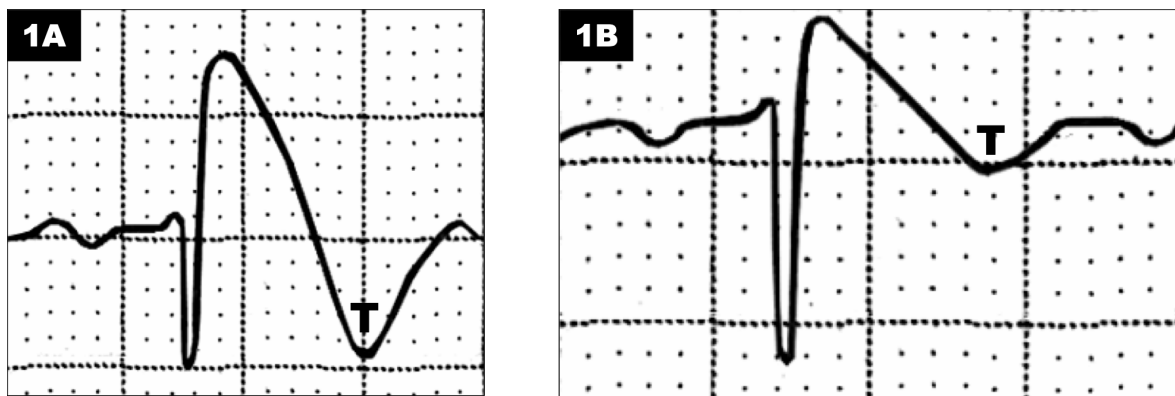


J-ST-T SEGMENT ABNORMALITIES IN RIGHT PRECORDIAL LEADS (V1-V2) OR ANTERO SEPTAL WALL (V1-V3) AND INFERIOR LEADS IN THE BRUGADA SYNDROME

Since the 1st Consensus about BrS, three electrocardiographic patterns are acknowledged, termed types 1, 2 and 3 [1](#). As soon as type 1 is observed (which is very rare), it is diagnostic for the syndrome. Patterns type 2 and 3 are much more frequent and found as normal variants quite often, and are included among end conduction disorders.

Figure 1

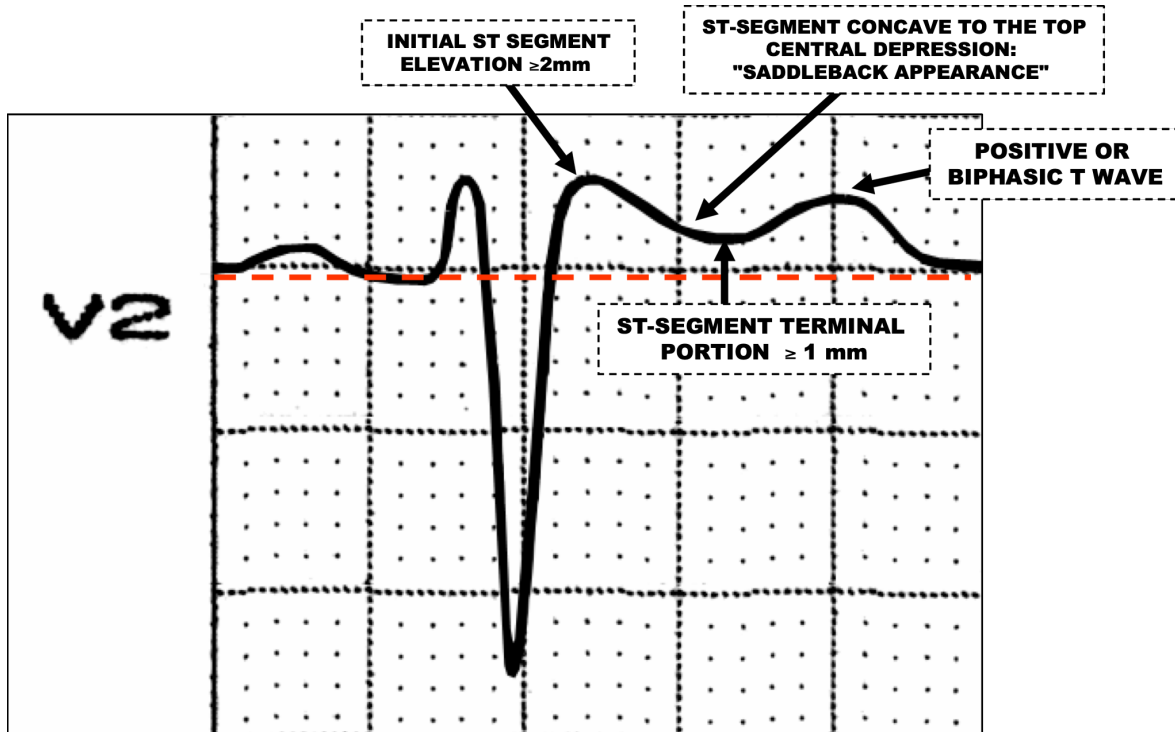
ELECTROCARDIOGRAPHIC PATTERN TYPE 1



J point and ST-segment elevation $\geq 2\text{mm}$ or $0,2\text{mV}$, convex to the top (1A) or descending straight/oblique (1B), followed by negative T wave.

Figure 2

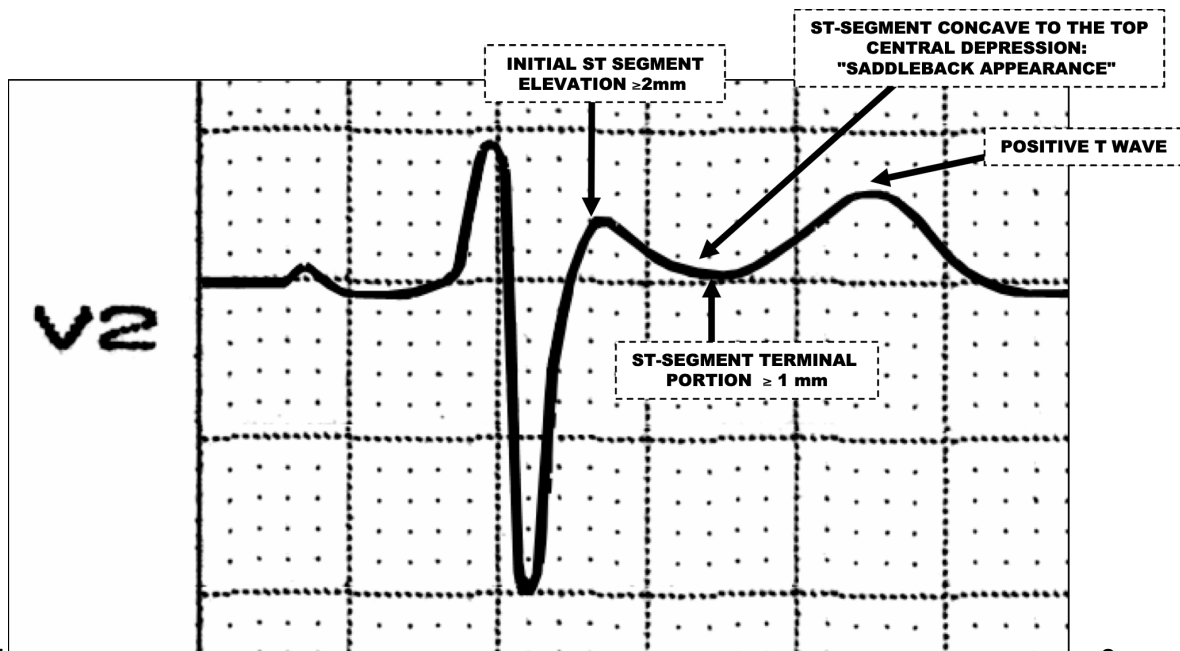
ELECTROCARDIOGRAPHIC PATTERN TYPE 2



Electrocardiographic pattern type 2 is characterized by presenting initial ST segment $\geq 2\text{ mm}$ in the right precordial leads (V1 and V2) or from V1 through V3; and "saddleback appearance" $\geq 1\text{ mm}$ in the terminal portion, followed by positive or biphasic T wave.

Figure 3

ELECTROCARDIOGRAPHIC PATTERN TYPE 3



Type 3, ST segment has a "saddleback appearance", with initial ST segment elevation ≥ 2 mm and terminal portion ≤ 1 mm followed by positive T wave.

ST segment abnormalities in V1-V3 leads (modified from Wilde AA, et al¹)

Table 1

	Type 1*	Type 2	Type 3
--	---------	--------	--------

J point level	≥2 mm	≥2 mm	≥2 mm
T wave polarity	Negative	Positive or biphasic	Positive
ST-T configuration	Superior or descending straight/oblique convexity	In "saddleback"	In "saddleback"
ST segment terminal portion	Gradually descending	Elevation ≥1mm	Elevation <1mm

CLASSIFICATION PROPOSAL OF BRUGADA TYPE 1 ECG PATTERN

We suggest splitting type 1 into Types 1A, 1B, and 1C.

Figure 4

Type 1A: convex to the top or "bull-terrier wave."

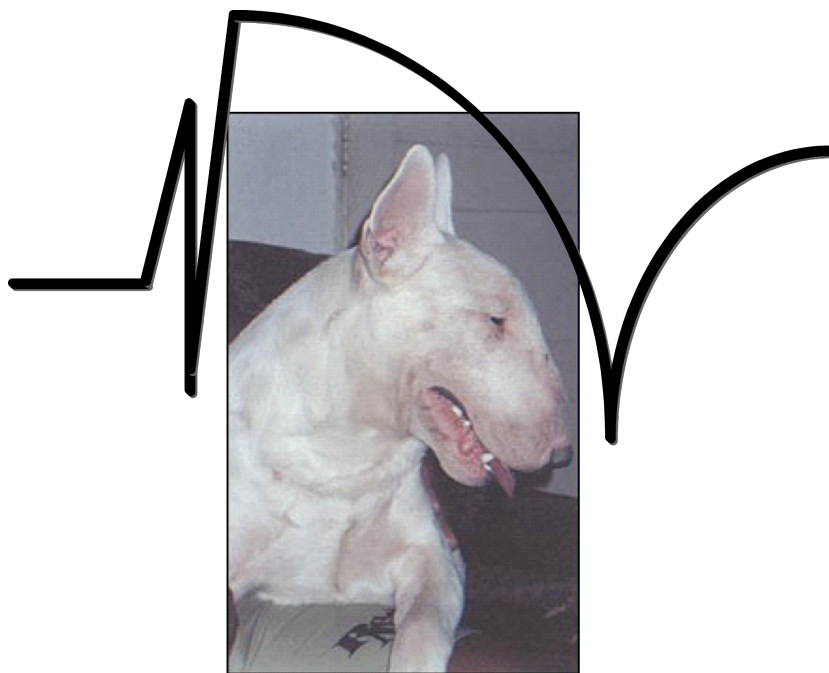
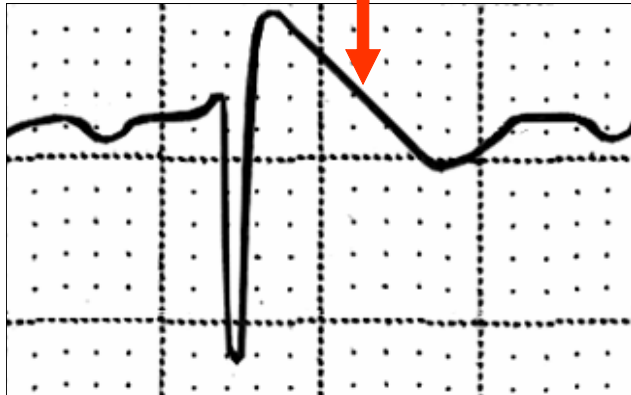
Figure 5

Type 1B: descending straight/oblique: Triangular shape

TYPE IB

**DESCENDING STRAIGHT/OBLIQUE:
TRIANGULAR SHAPE**



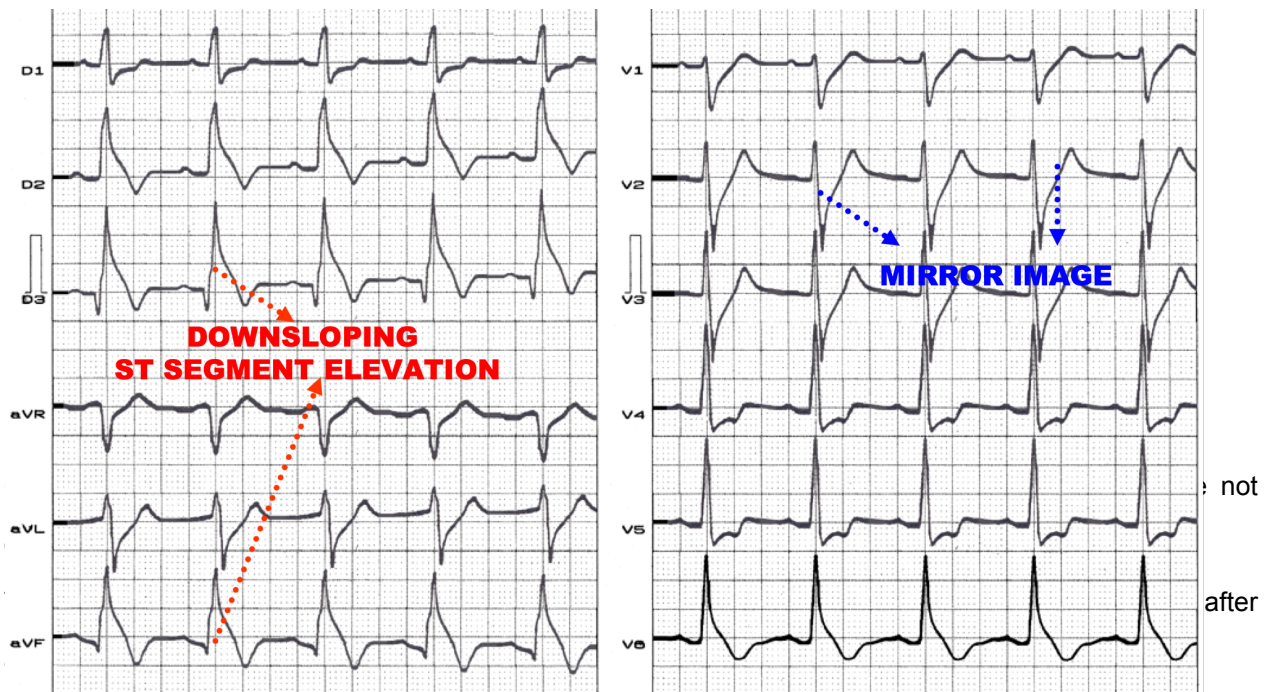
$V_1 - V_2$ or V_3

Figure 6

Type 1C: ST-segment elevation in inferior or inferior-apical leads "Lambda" (λ) or Gussak wave.

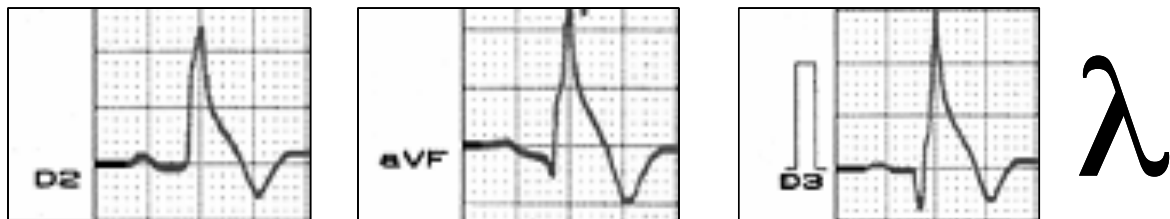

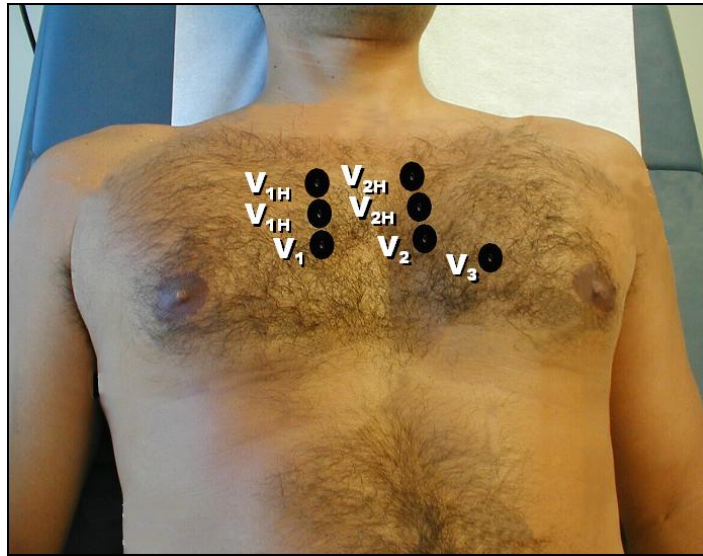
Figure 7



Brugada-type ECG phenotype is much more frequent than the syndrome: from 12,000 ECG from nonselected and noncardiac patients collected prospectively in a large teaching Hospital for a 2-year period, there were 52 cases identified with electrocardiographic Brugada sign². The frequency of Brugada-type electrocardiographic pattern in the southern region of Turkey, was around 0.48% of ECGs in the general population, from which 0.40% showed saddleback-type pattern, and only 0.08% type 1 (coved type); while the latter is more prevalent in young men³.

The placement of exploring electrodes from V1 and V2, one or two intercostal spaces above (third or second) increases diagnostic sensitivity, due to an increase in the percentage of detection of Brugada sign. Additionally, the ECG recording placing the exploring electrodes V1 and V2, one or two intercostal spaces above (third or second) could be essential for diagnosis⁴.

Figure 8



- V_1 – Over the 4th intercostal space, just to the right of the sternum.
- V_2 – Over the 4th intercostal space, just to the left of the sternum
- V_3 – Midway between V_2 and V_4 .
- V_{1H} – Over the 3rd or 2nd intercostal space, just to the right of the sternum.
- V_{2H} – Over the 3rd or 2nd intercostal space, just to the left of the sternum.

RIGHT VENTRICLE REGIONS AND THEIR CORRESPONDING LEADS

The right ventricle has five regions that are better detected by the following leads:

- 1) V_2 and V_3 : trabecular area;
- 2) $V_3 - V_4$: Low right paraseptal area;
- 3) V_1 to V_4 : Free wall;
- 4) aVF , V_4R and V_5R : Right Ventricle Inflow Tract (RVIT);
- 5) aVR , V_{1H} , V_{2H} , V_{3H} : \longrightarrow **RVOT**: the area affected in the Brugada syndrome.

References

- 1) Wilde AA, Antzelevitch C, Borggrefe M, Brugada J, Brugada R, et al. Study Group on the Molecular Basis of Arrhythmias of the European Society of Cardiology. Proposed diagnostic criteria for the Brugada syndrome. *Eur Heart J* 2002; 23:1648-54.
- 2) Monroe MH, Littman L. Two-year case collection of the Brugada syndrome electrocardiogram pattern at a large teaching hospital. *Clin Cardiol* 2000;23:849-851.
- 3) Bozkurt A, Yas D, Seydaoglu G, Acarturk E. Frequency of Brugada-Type ECG Pattern (Brugada Sign) in Southern Turkey. *Int Heart J.* 2006; 47:541-547.
- 4) Teijeiro R, Garro HA, Acunzo RS, Albino E, Chiale PA. Recording of high V1-V3 precordial leads may be essential to the diagnosis of Brugada syndrome during the ajmaline test. *J Cardiovasc Pharmacol Ther.* 2006; 11:153-155.