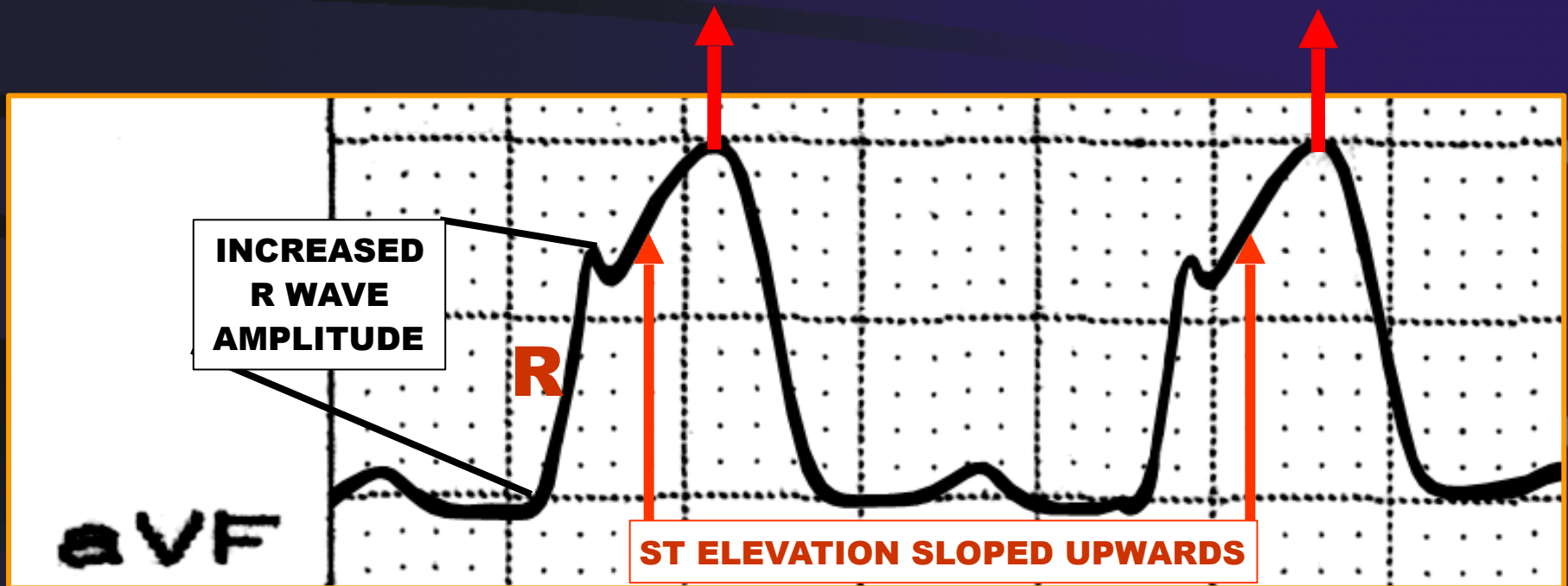




FACULDADE DE MEDICINA DO ABC

THE 'HYPERACUTE EARLY INJURY PHASE' IN MYOCARDIAL INFARCTION

TALL, WIDENED T WAVES

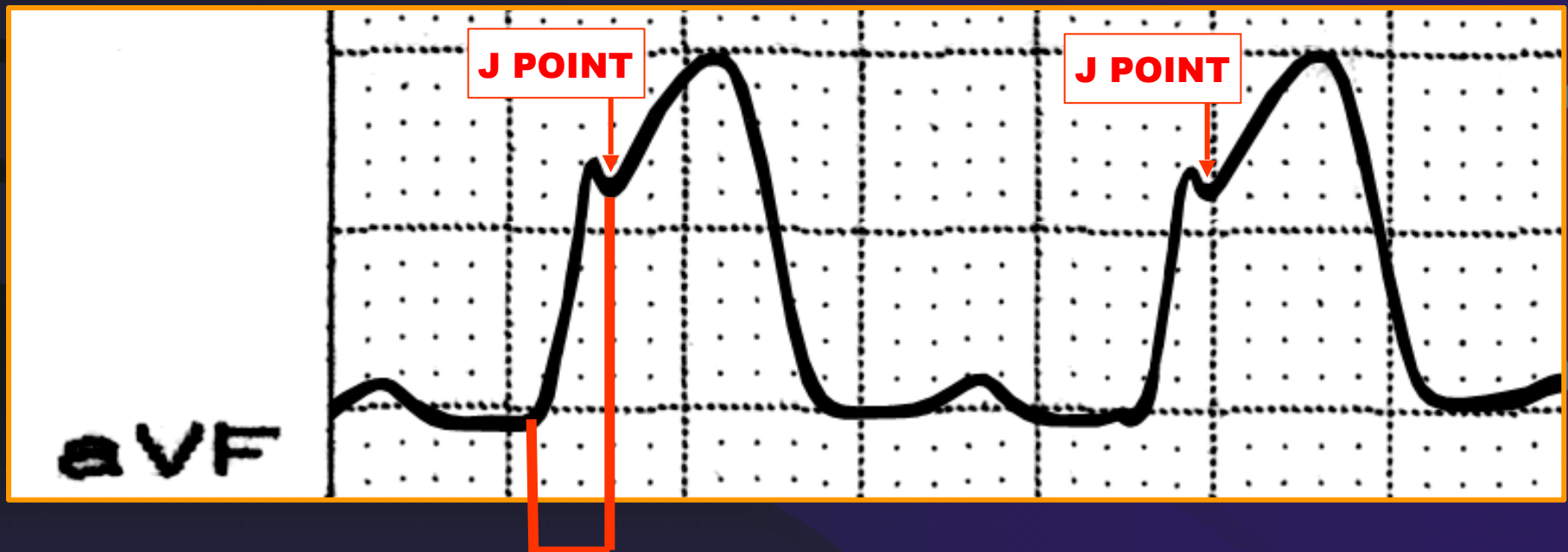


Note that Q waves are not seen early on.



FACULDADE DE MEDICINA DO ABC

THE 'HYPERACUTE EARLY INJURY PHASE' IN MYOCARDIAL INFARCTION



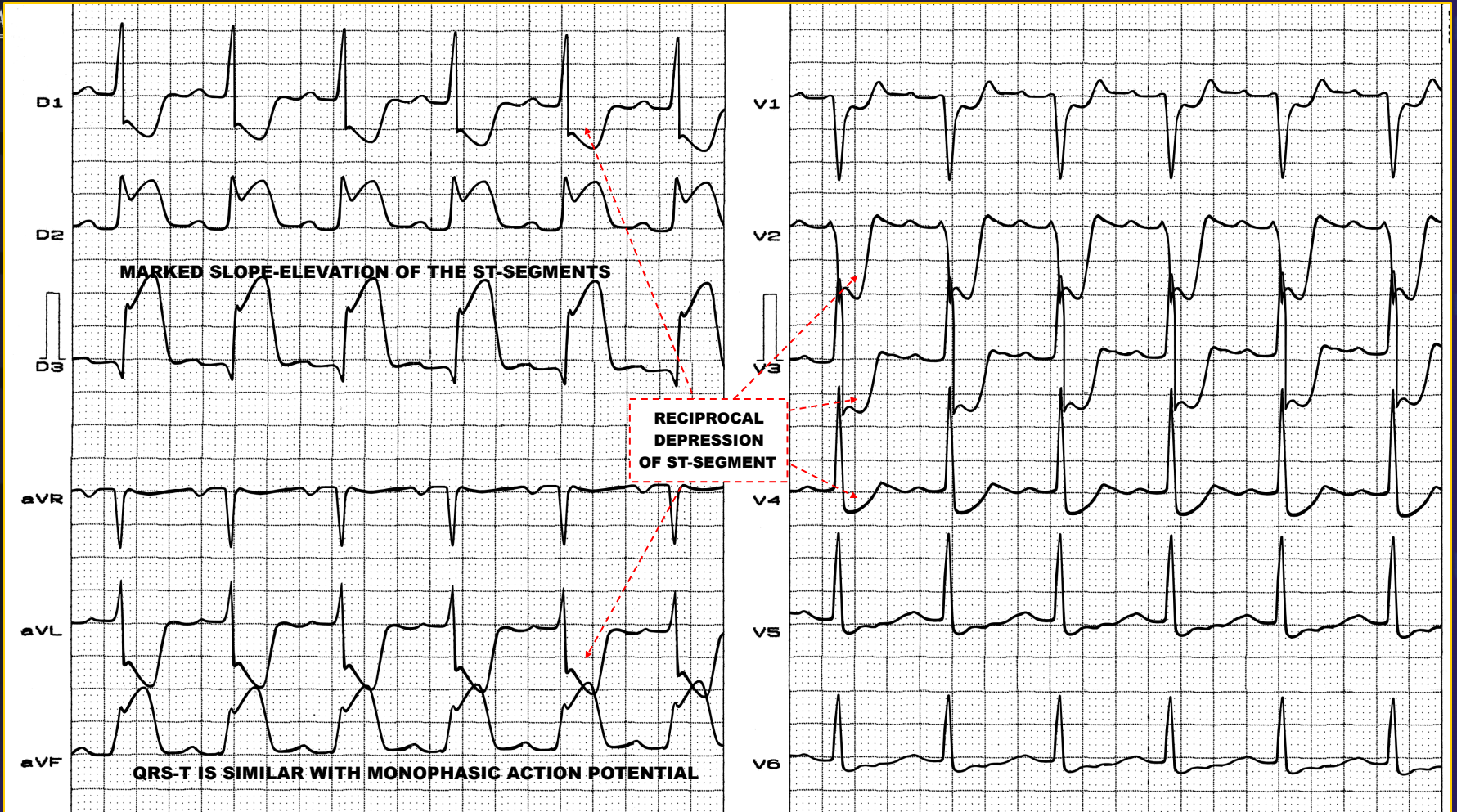
VAT / ID

>80ms (NORMAL: <40ms)

Next slide full 12-lead ECG of this case.

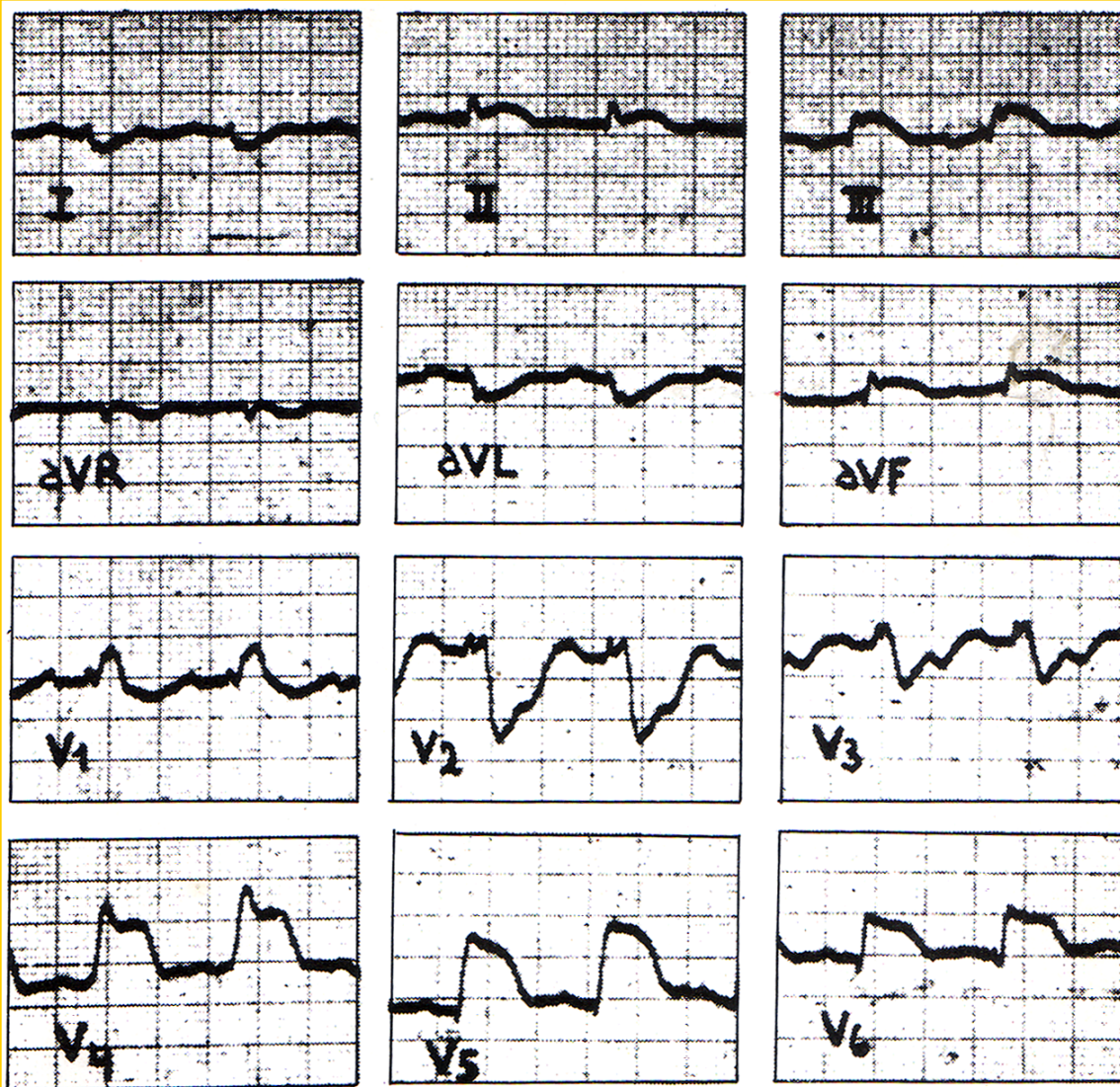


THE 'HYPERACUTE EARLY INJURY PHASE' IN INFERIOR MYOCARDIAL INFARCTION



Man, 55 years old, 3 hours onset chest pain, first ECG in his home.

CHAGASIC MYOCARDITIS SIMULATING 'HYPERACUTE EARLY INJURY PHASE' OF INFERIOR MYOCARDIAL INFARCTION



Rosenbaum MB. Chagasic Myocardiopath.
Prog Cardiovasc Dis. 1964; 117:199-225.