

# CASE REPORT

## 61 YO WOMAN WITH SYNCOPE EPISODE

**Case from Dr. Raimundo Barbosa Barros – Fortaleza – Ceará, Brasil**

**Final Analysis:**

**Andrés Ricardo Pérez Riera, MD**

**Chief of Electovectorcardiography Sector - Cardiology Discipline - ABC  
Faculty – ABC Foundation – Santo André – São Paulo – Brazil**

**[riera@uol.com.br](mailto:riera@uol.com.br)**

Dear Professor Andrés, I would like to share this interesting from our files. Unfortunately, there are not clinical description data. The tracings belong to a 61 yo woman, with positive history of syncope and without drugs.

We will show an ECGs chronological sequence

Thank you in advance, we are waiting for your valuable opinions

Hug

Raimundo Barbosa Barros, MD – Fortaleza, Ceará – Brazil

---

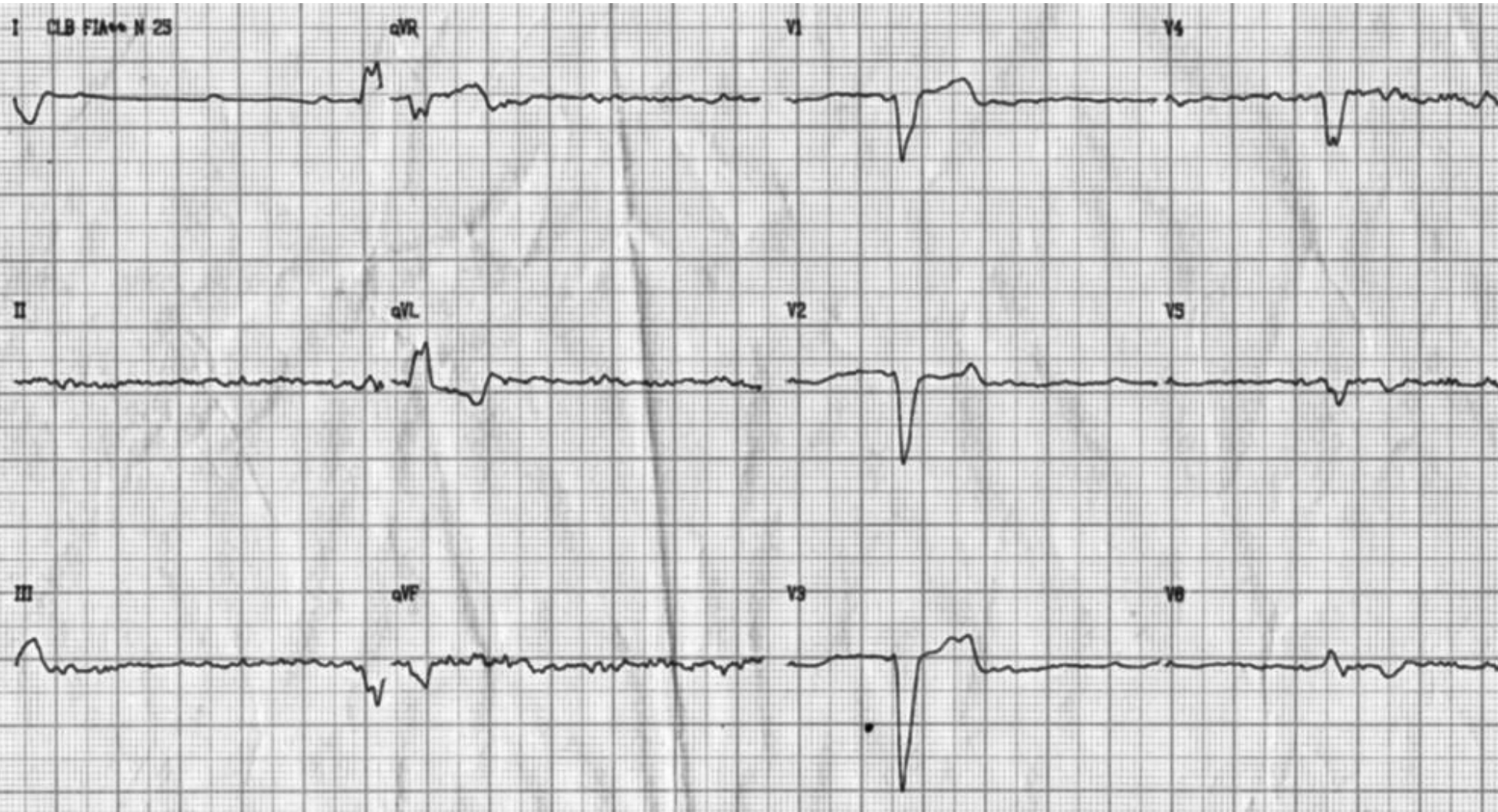
Prezado Professor Andrés, gostaria de compartilhar este caso interessante do nosso arquivo. Não há muitos detalhes clínicos. Apenas para análise dos colegas do foro. Paciente feminina, 61 anos, sem uso de medicação com história de síncope.

ECG1 - admissão; ECG2 - após MP provisório; ECGs 3, 4 e 5 em dias diferentes com o MP desligado.

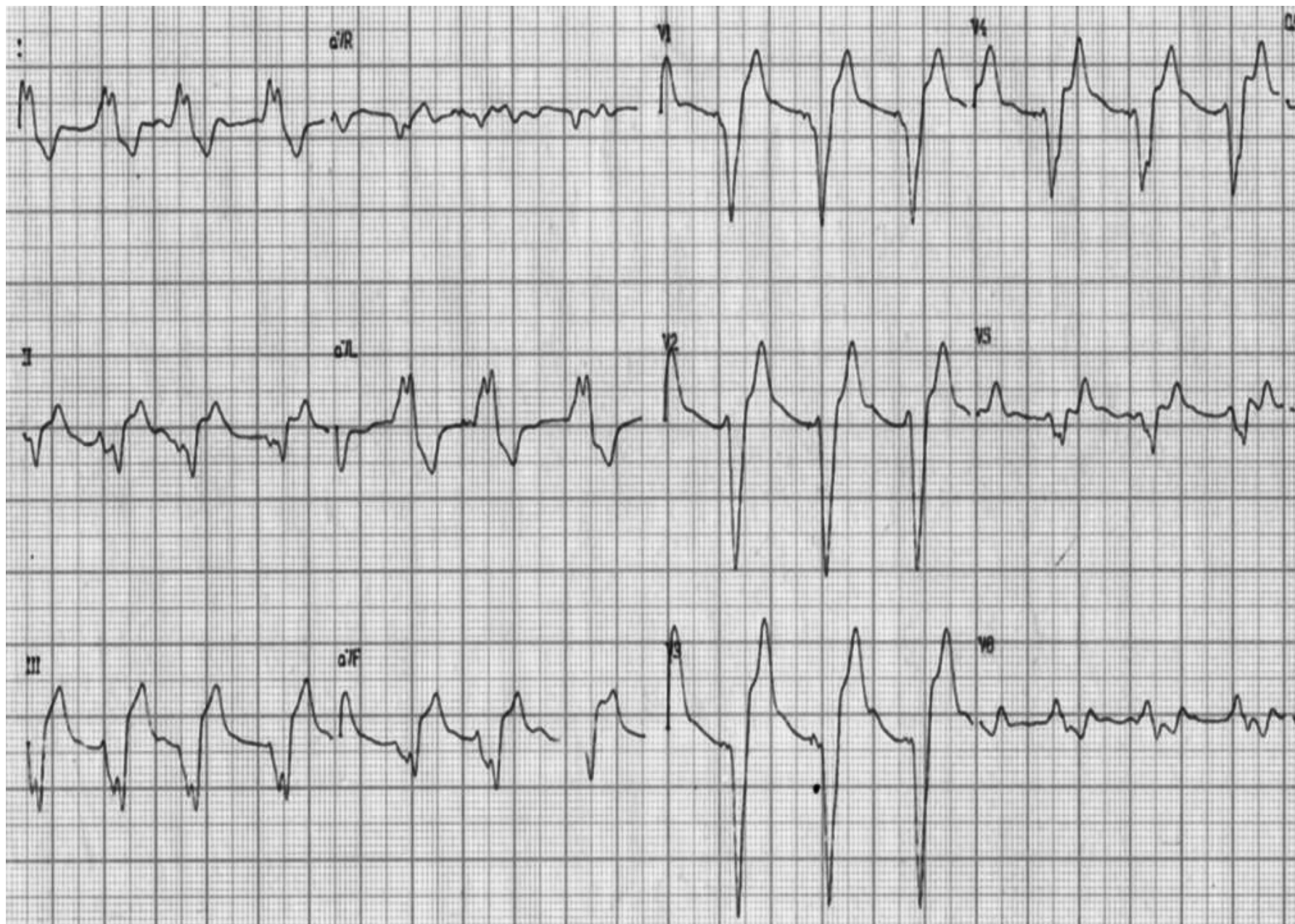
Um abraço

Raimundo Barbosa

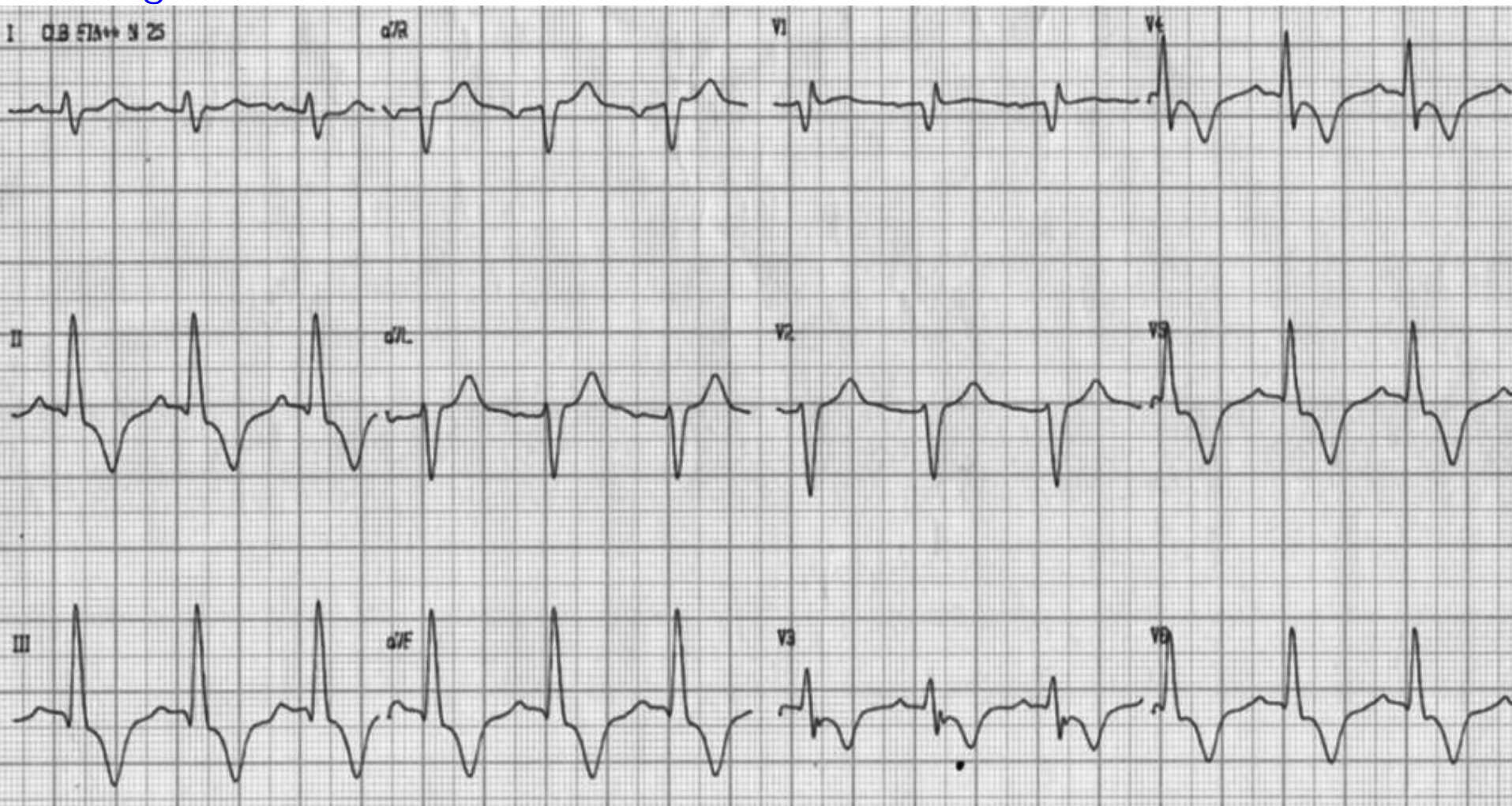
# First ECG - Admission



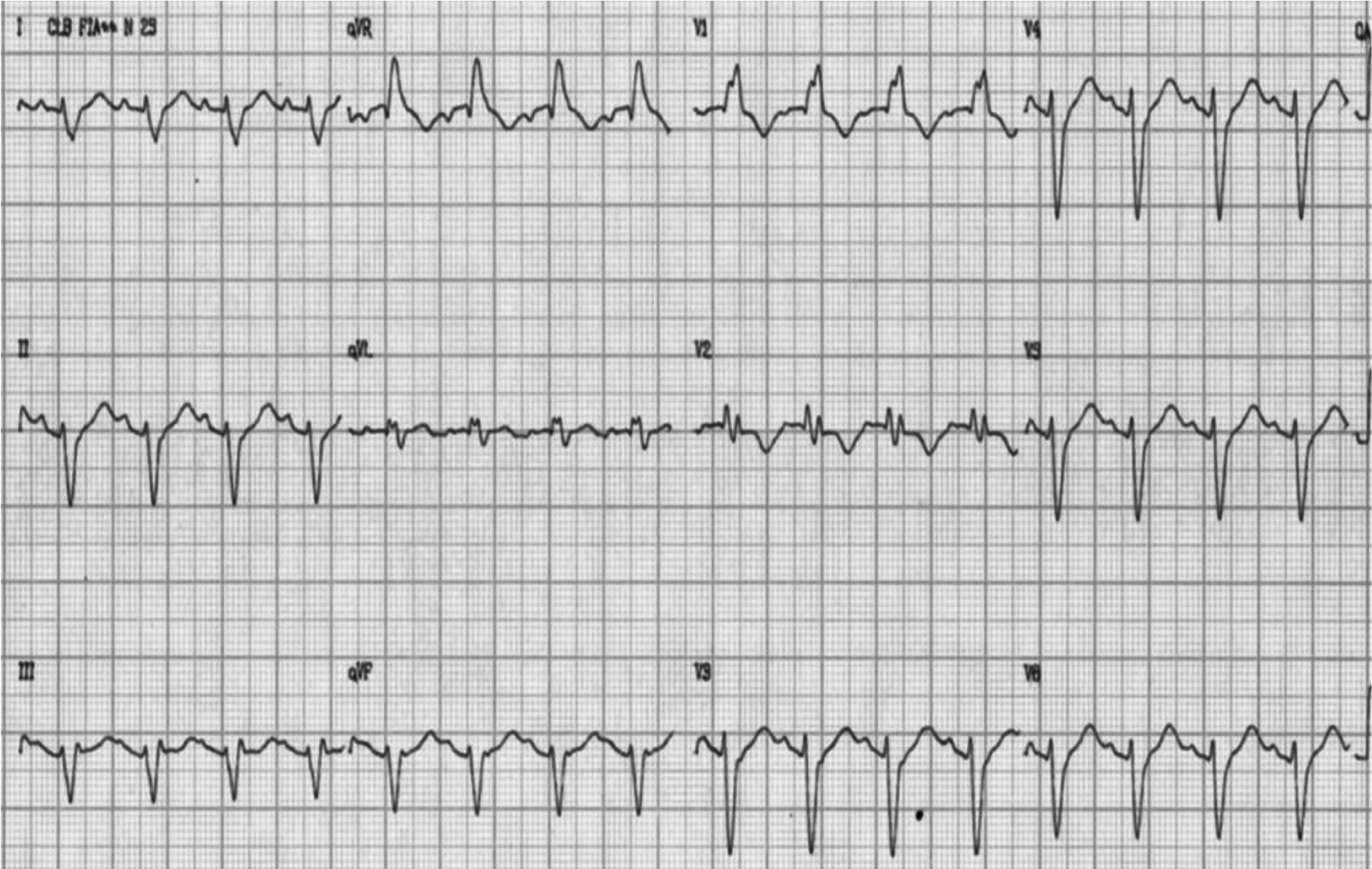
# Second ECG - After temporary Pacemaker implantation



Third ECG – With the pacemaker turned off. **Com o marcapasso desligado.**



Fourth ECG – Similar to ECG number 3, but in another day.



# Fifth ECG - Similar to ECG numbers 3 and 4, but in another day.

