

A Surgical Case for Cardiac Resynchronization Therapy

Balaram, Sandhya

Case Report:

The patient is a 75 year old male with a history of hypertension, coronary artery disease, cerebrovascular accident, peripheral vascular disease, diabetes mellitus, and ulcerative colitis who underwent coronary artery bypass surgery x 4 after multiple failed PTCA/stenting procedures. His postoperative ejection fraction was recorded as 10%. He had a subsequent ventricular fibrillation arrest one month postoperatively and an AICD was placed at that time. 6 months later he returned for an upgrade and placement of a bi-ventricular CRT device. A coronary sinus lead was unable to be passed under fluoroscopy and he was referred for robotic-assisted epicardial lead insertion.

Preoperative transesophageal echocardiogram with viability assessment and tissue Doppler imaging to determine the point of latest activation was performed. The point of latest activation was shown to be present on the basilar aspect of the posterior wall. The patient had evidence of viability in this region.

He was taken to the operating room for placement of two LV epicardial leads along the posterior basilar wall of the LV. R waves measured 10 in this region with an impedance of 850 ohms and a pacing threshold of 0.7.

Procedure Details:

Once in the operating room, the patient is intubated with a double lumen endotracheal tube allowing single (right) lung ventilation. Two external defibrillator patches are placed on the patient. The area of latest contraction is identified preoperatively by echocardiography and this area is targeted for lead placement. The patient is placed in the full left posterolateral thoracotomy position and is prepped and draped in the usual sterile fashion.

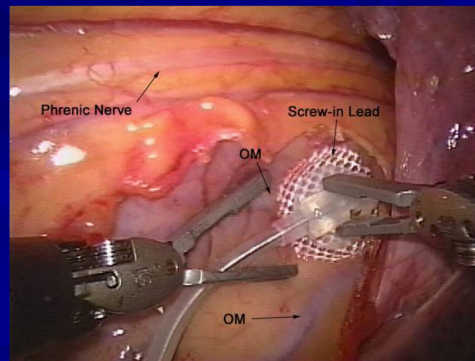
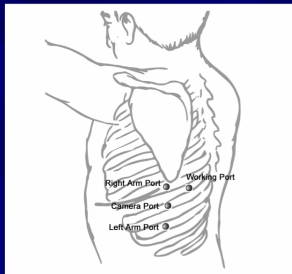
The robotic camera and instruments are then introduced. Single lung ventilation is initiated and CO₂ is insufflated into the thoracic cavity. The camera port is placed in the 7th intercostal space in the posterior axillary line. The right da Vinci port is introduced in the 5th intercostal space in the posterior axillary line. The left port is introduced in the 9th intercostal space in the posterior axillary line. A 10-mm working port is placed posterior to the camera port in the 7th intercostal space.

Cardiac Resynchronization Therapy Symposium

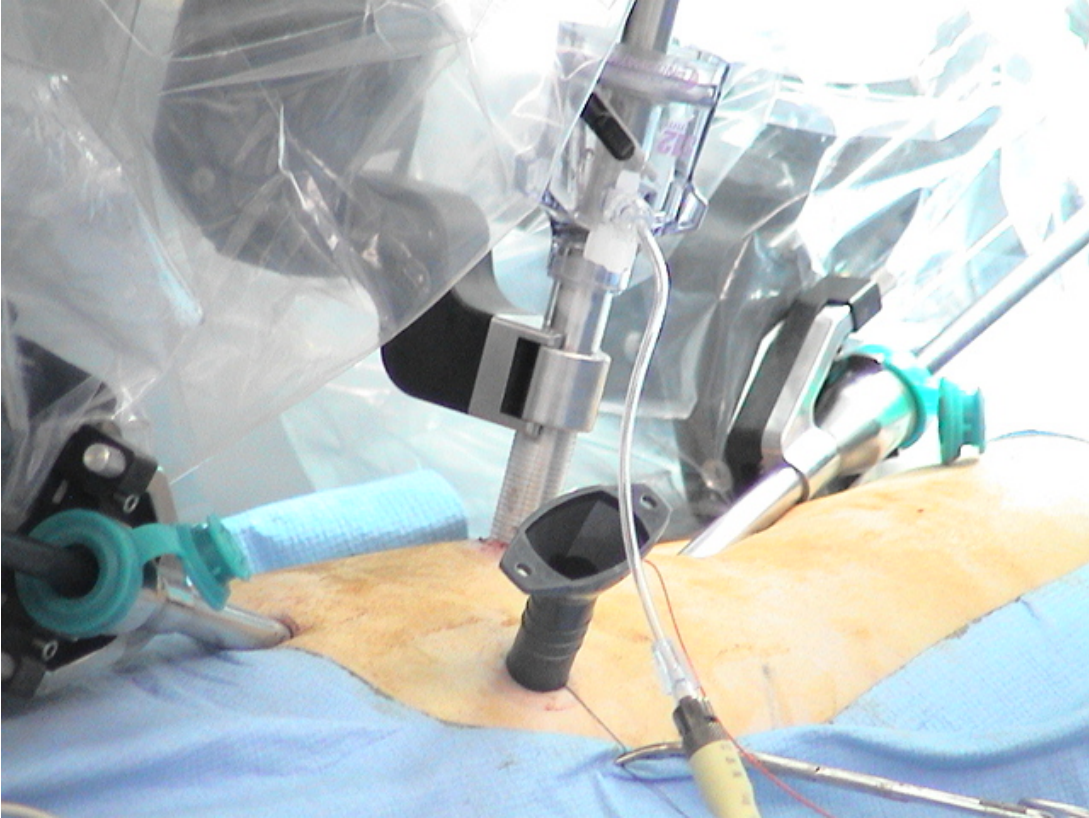
Using the robotic arms, the pericardium is opened posterior to the phrenic nerve. If this is not possible secondary to individual patient anatomy, the pericardium may be opened anterior to the phrenic nerve with attempts to identify the obtuse marginal vessels. The epicardial leads are screwed into the heart using the robotic arms. The pericardium is then loosely reapproximated over the leads and the proximal end of the leads are placed in a temporary subcutaneous pocket in the chest wall.

All the incisions are closed and the patient is turned to the supine position and repped and draped. The leads are then tunneled subcutaneously up to the pacemaker device, attached, and checked. One lead is selected for insertion into the device and the second is used as a back-up lead and left posteriorly within the pocket. The patient is awakened, extubated, and transferred to the recovery room.

Operative Technique: The Posterior Approach



Cardiac Resynchronization Therapy Symposium





Robotic LV Epicardial Lead Placement

Advantages

- Direct placement on any portion of the LV
- Implant success rate is 100%
- Minimally invasive
- **LV mapping allows site-directed approach for each patient**

Disadvantages

- General anesthesia
- Double lumen intubation
- Single lung ventilation

Cardiac Resynchronization Therapy Symposium

Discussion

Most series of surgical epicardial lead placement have been reported in the setting of prior failure of CS lead insertion. The majority of these patients are highly selected and represent a different population than the patients undergoing primary implantation.

Our group at St. Luke's-Roosevelt Hospital Center in New York has reported extensively on the short- and medium-term follow-up of robotic LV lead placement for biventricular pacing [1-3]. Between 2002 and 2005, 60 patients have undergone robotic LV lead placement. The majority of these patients have had robotic LV lead implantation for a failure of CS lead placement (83%). The operative results have been similar to those described by other groups with a 100% success rate for LV lead placement and a very low conversion rate to mini-thoracotomy (3%). All patients in this robotic series have been extubated in the operating room and median ICU and hospital lengths of stay have been 0.5 days and 1.5 days respectively. None of the patients required peri-operative inotropes. The last 20 patients in this series have undergone pre-operative TDI site localization and post-operative TDI pacing optimization. Post-operative morbidity has included one episode of pneumonia and two patients with intercostal neuropathy. No patients required re-intubation and there were no episodes of respiratory failure. Significant ventricular remodeling has been observed over the mean follow-up of 16.7 ± 9.5 months (range, 3–36 months) with statistically significant improvements in systolic LV internal dimension index and diastolic LV internal dimension index. Improvements in LV ejection fraction and New York Heart Association (NYHA) class have also been observed. The three-month clinical response rate has been 81%. Over the 36-month follow-up there have been four deaths (all of whom were initial non-responders). There have been three non-responders who remain alive with heart failure, one non-responder who underwent heart transplantation and four patients who worsened after an initial response for an overall response rate of 75% over the mean 17-month follow-up.

Although no prospective, randomized comparison has yet been performed between surgical epicardial LV lead placement and CS lead placement, Mair et al. have reported results on a retrospective comparison [4]. The study group included 79 patients undergoing CS lead insertion and 16 patients undergoing LV epicardial lead placement through a limited left lateral thoracotomy. The patients undergoing surgically placed LV leads included nine patients with failed CS leads and seven patients undergoing primary implant. All patients undergoing surgical placement of the epicardial LV lead achieved posterolateral lead placement as opposed to only 70% in the transvenous CS group. Length of stay was not statistically different between the two groups. Over a mean follow-up of 16 months, CS lead thresholds were significantly higher than surgically placed epicardial leads with seven CS leads having a pacing threshold of $>4 V/0.5$ ms versus no epicardial leads with a pacing threshold greater than $1.8 V/0.5$ ms. In follow-up, 25 CS lead-related complications occurred, compared with one in the surgical group.

Cardiac Resynchronization Therapy Symposium

Recent literature has emphasized optimizing site-directed left ventricular lead placement using ventricular mapping [5]. The target zone for LV lead placement should correspond to the latest point of both electrical and mechanical activation. Historically, this has been labeled as the posterolateral wall midway between the base and the apex of the left ventricle. With pre-operative imaging, the area of latest mechanical activation can now be more accurately localized. Tissue Doppler imaging (TDI) can be used to characterize the contraction of myocardial segments in time. By color-coding the segments, the target area of the left ventricle can be easily identified and more specifically defined. Multiple contraction waveforms can be imaged on line and the latest point of mechanical activation can be localized. These pre-operative imaging techniques allow for documentation of dyssynchrony in those patients evaluated for CRT with a widened QRS on baseline ECG. However, these techniques may also serve in the future to identify dyssynchrony in heart failure patients with no evidence of intraventricular conduction delay on baseline ECG.

Use of the optimal pacing site of latest activation to determine exact placement of the epicardial LV lead was also recently shown to result in maximal reverse remodeling [6,7]. Measurement of myocardial velocity with tissue strain imaging (TSI) provides information regarding the site of maximal LV delay. Use of this preoperative mapping technique demonstrated marked reverse remodeling and statistically significant improvements in systolic function [6]. More importantly, those patients whose LV lead was placed one segment away from the recommended area had less remodeling and those >1 segment away showed no significant reverse remodeling [6]. This data demonstrates the importance of individualized, targeted lead placement to maximize patient outcomes after CRT. The use of robotic epicardial lead insertion has been of significant benefit in combining preoperative determination of placement site with safe LV lead placement. As we move forward with this technology, we can continue to expect further benefits of precise placement of LV leads in cardiac resynchronization therapy.

Cardiac Resynchronization Therapy Symposium

References

1. DeRose JJ, Jr., Belsley S, Swistel DG, Shaw R, Ashton RC, Jr. Robotically-assisted left ventricular epicardial lead implantation for biventricular pacing: The posterior approach. *Ann Thorac Surg* 2004; 77: 1472–1474.
2. DeRose JJ, Jr., Kypson AP. Robotic arrhythmia surgery and resynchronization. *Am J Surg* 2004; 188 (4A suppl 1): 104S–111S.
3. DeRose JJ, Jr., Balaram S, Ro C et al. Midterm follow-up of robotic biventricular pacing demonstrates excellent lead stability and improved response rates. *Innovations* 2006;1:105-110.
4. Mair H, Sachweh J, Meuris B et al. Surgical epicardial left ventricular lead versus coronary sinus lead placement in biventricular pacing. *Eur J Cardiothorac Surg* 2005; 27: 235–242.
5. Steinberg JS, DeRose JJ. The rationale for nontransvenous leads and cardiac resynchronization devices. *Pacing Clin Electrophysiol* 2003; 26: 2211–2212.
6. Murphy RT, Sigurdsson G, Mulamalla S, Agler D, Popovic ZB, Starling RC, Wilkoff BL, Thomas JD, Grimm RA. Tissue synchronization imaging and optimal left ventricular pacing site in cardiac resynchronization therapy. *Am J Cardiol*. 2006 Jun 1;97(11):1615-21. Epub 2006 Apr 7.
7. Rovner A, de Las Fuentes L, Faddis MN, Gleva MJ, Davila-Roman VG, Waggoner AD. Relation of left ventricular lead placement in cardiac resynchronization therapy to left ventricular reverse remodeling and to diastolic dyssynchrony. *Am J Cardiol*. 2007 Jan 15;99(2):239-41. Epub 2006 Nov 21