

Name: JTR

Sex: Male

Age: 54 yo.

Race: Caucasian

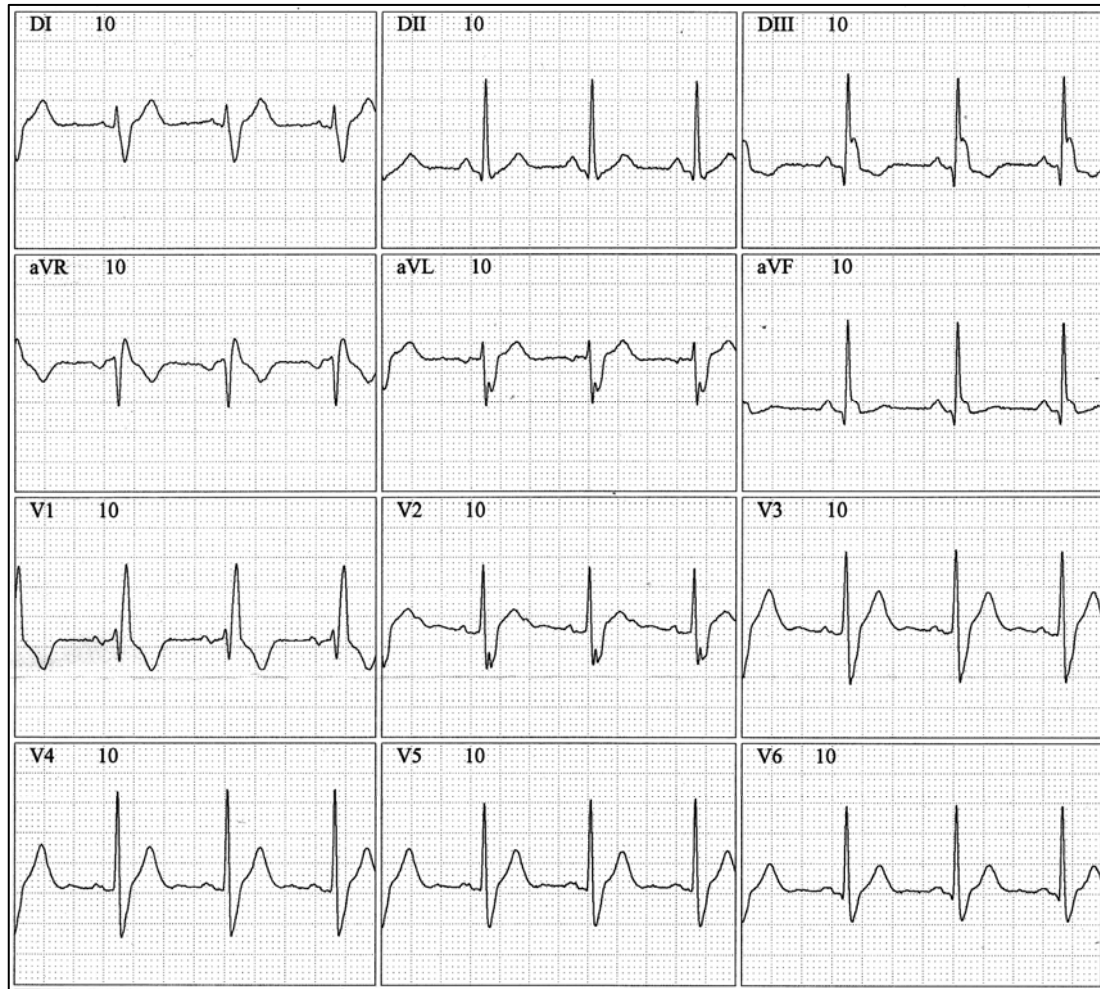
Weight: 72 Kg

Height: 1,72 m

Biotype: Normoline

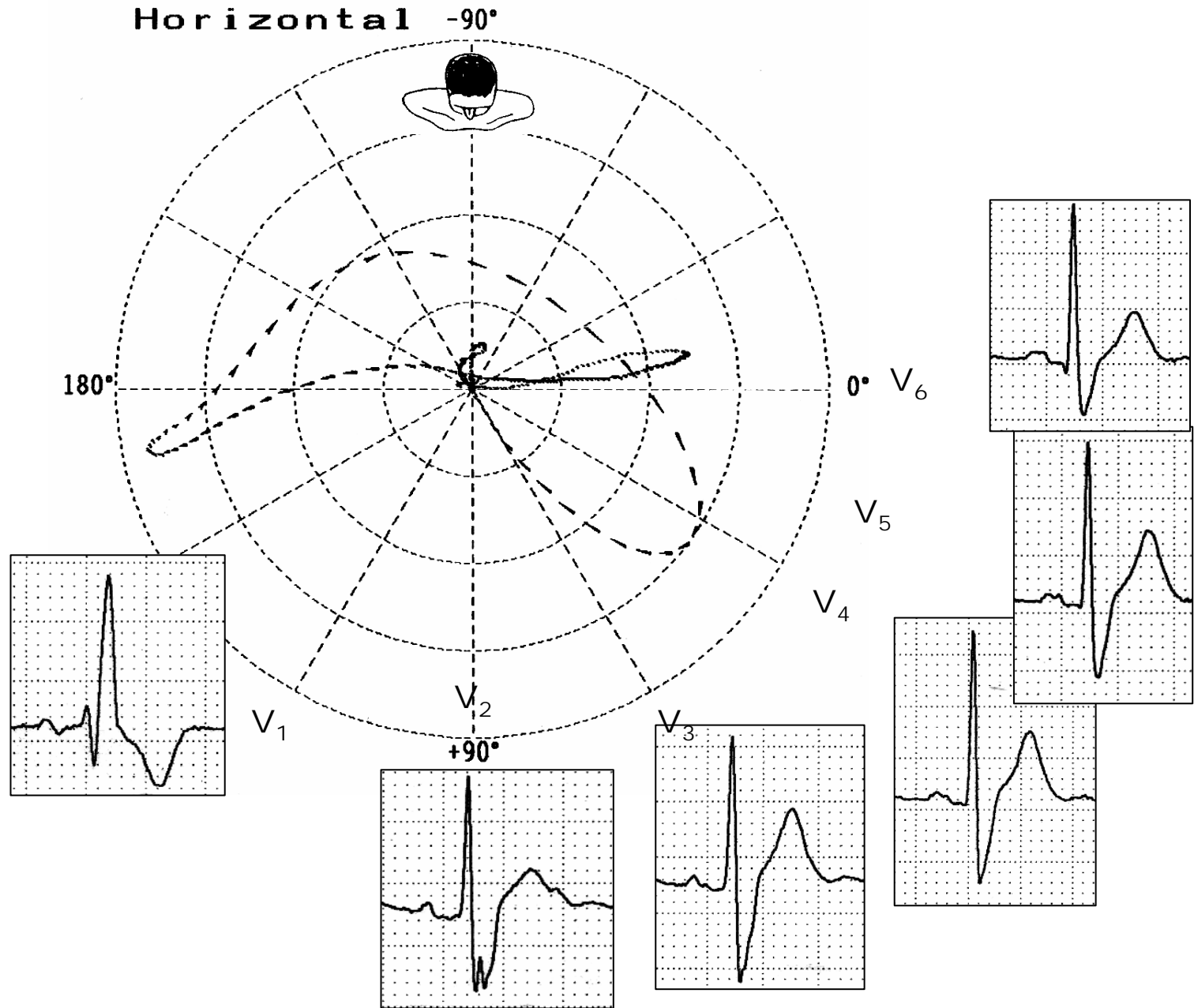
Date: 12/02/2008

Medication: Sinvastatin 20mg/day.

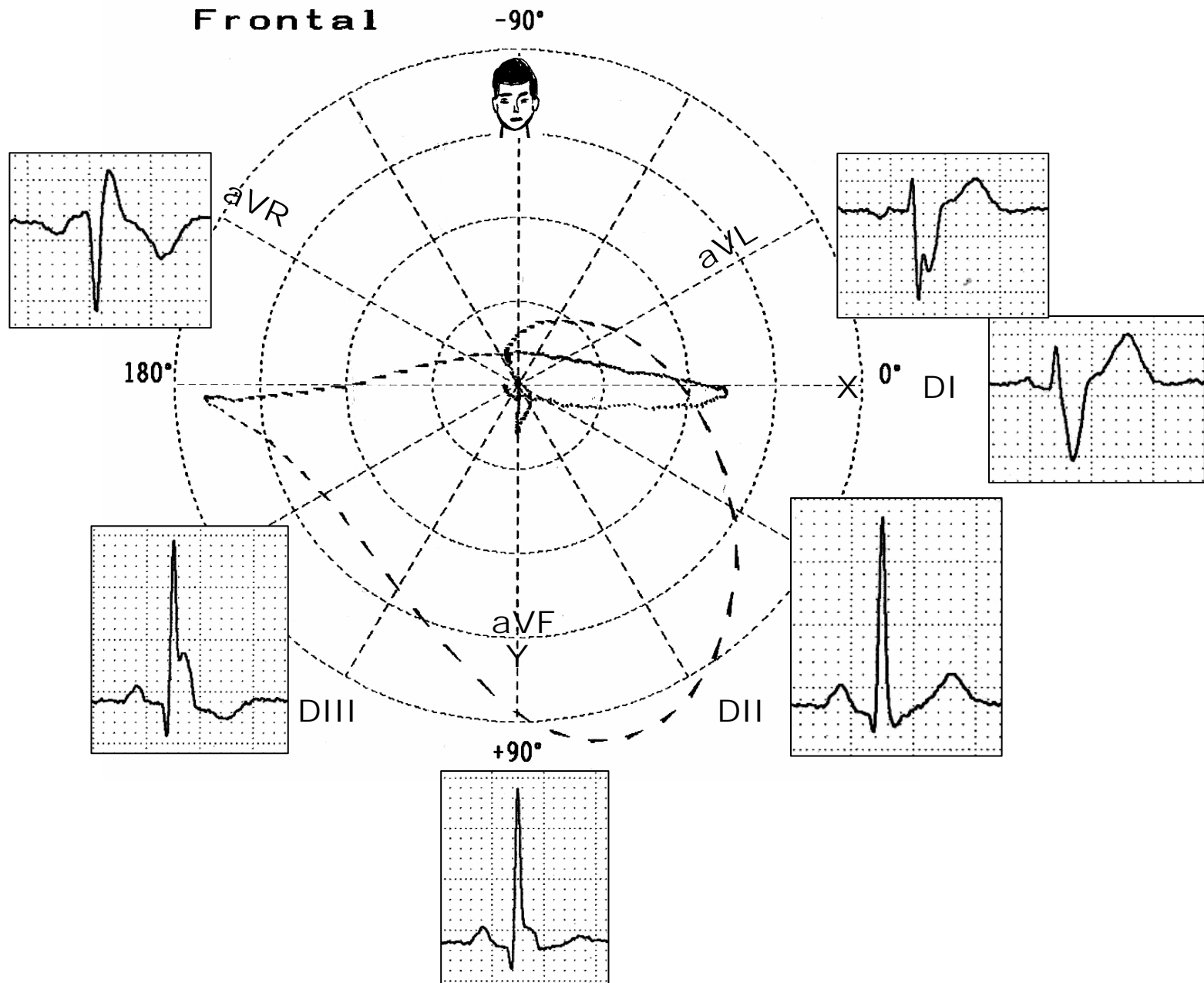


ECG diagnosis: ?

ECG/VCG HORIZONTAL PLANE CORRELATION



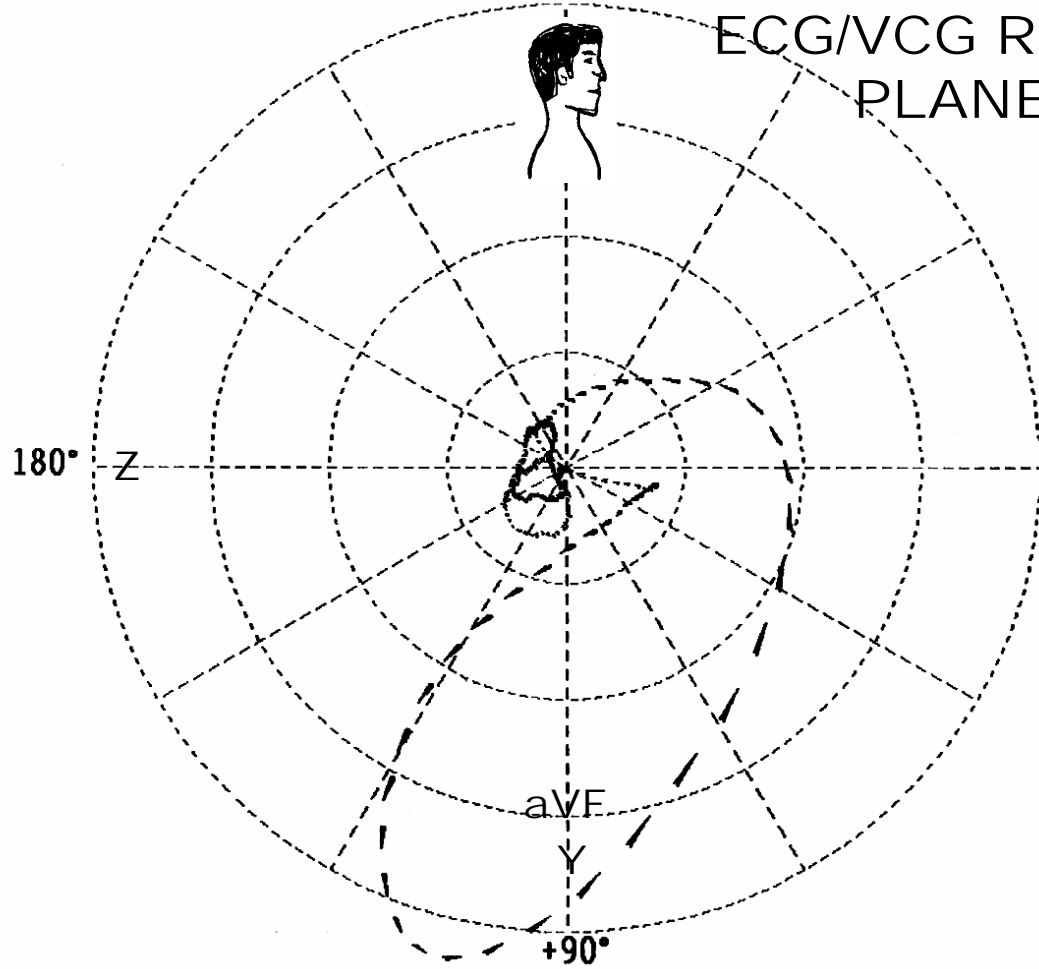
ECG/VCG FRONTAL PLANE CORRELATION



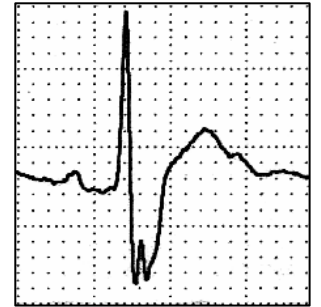Sagittal

-90°

ECG/VCG RIGHT SAGITTAL PLANE CORRELATION

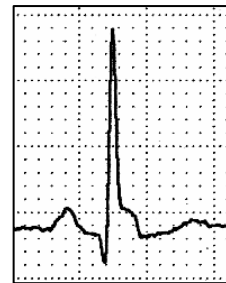

0° V₂



aVF

+90°



FINAL DIAGNOSIS

- ???.